

# Reproducibility of 3 mm-Slice-Thick Reconstruction of Paranasal Sinus Computed Tomography Scans

Matti Karjalainen<sup>1\*</sup>, Anna Julkunen<sup>2,3\*</sup>, Antti Markkola<sup>4</sup>, Prasun Dastidar<sup>5</sup>, Heini Huhtala<sup>6</sup>, Mikko Suvinen<sup>1,7</sup>, Anna-Maija Kuukka<sup>1</sup>, Markus Rautiainen<sup>1,8</sup>, Jura Numminen<sup>1#</sup>, Sanna Toppila-Salmi<sup>2,9#</sup>

<sup>1</sup>Department of Otorhinolaryngology, University of Tampere, Tampere, Finland

<sup>2</sup>Transplantation Laboratory, Haartman Institute, University of Helsinki, Helsinki, Finland

<sup>3</sup>Department of Oral and Maxillofacial Diseases, University of Helsinki and Helsinki University Hospital, Helsinki, Finland

<sup>4</sup>University of Helsinki and HUS Imaging, Helsinki, Finland

<sup>5</sup>Medical Imaging Centre, Department of Radiology, Tampere University Hospital, Finland

<sup>6</sup>School of Public Health, University of Tampere, Tampere, Finland

<sup>7</sup>Department of Otorhinolaryngology, Tampere City Hospital, Tampere, Finland

<sup>8</sup>Department of Ear and Oral diseases, Tampere University Hospital, Tampere, Finland

<sup>9</sup>Department of Allergy, University of Helsinki and Helsinki University Hospital, Helsinki, Finland

Email: [sanna.salmi@helsinki.fi](mailto:sanna.salmi@helsinki.fi)

Received 19 January 2016; accepted 23 March 2016; published 28 March 2016

Copyright © 2016 by authors and Scientific Research Publishing Inc.

This work is licensed under the Creative Commons Attribution International License (CC BY).

<http://creativecommons.org/licenses/by/4.0/>



Open Access

## Abstract

**Background:** After the failure of medical treatment, the surgery of chronic rhinosinusitis (CRS) is planned according to endoscopic and paranasal sinus computed tomography (CT) findings. **Objective:** The aim of this prospective study was to evaluate whether this study method might be eligible in studies aiming at radiation dose reduction. Sinus CT scans were chosen as a model because of the high variation of the radiological anatomy of surgically important sinonasal structures. We hypothesized that 3 mm-slice-thick reconstruction CT had poor reproducibility. **Methods:** 59 CRS patients underwent routine multi-detector sinus CT (CT<sub>MD</sub>). CT<sub>3mm</sub> was reconstructed from CT<sub>MD</sub> data-sets. Lund-Mackay (LM) scores and 43 other structural parameters were analyzed blinded. Agreement was studied between CT<sub>MD</sub> and CT<sub>3mm</sub> (intra-observer reproducibility), and between three observers (inter-observer reproducibility) by using Cohen's kappa. **Results:** The inter-observer agreement was moderate (kappa 0.4 - 0.6,  $p < 0.01$ ) in the majority of structures of CT<sub>3mm</sub> scans. The intra-observer reproducibility of CT<sub>3mm</sub> scans was very good in most structures, however, it was poor in important structures such as frontal and sphenoid recess, lamina pa-

\*Matti Karjalainen and Anna Julkunen have equally contributed to this work.

#Jura Numminen and Sanna Toppila-Salmi are shared last authors.

pyraeae, and location of optic nerve or anterior ethmoidal artery. The grade of surgeon's confidence of CT<sub>3mm</sub> in comparison to CT<sub>MD</sub> was lower (kappa 0.2 - 0.4,  $P < 0.05$ ). Conclusion: This methodology might have some use in studies aiming at radiation dose reduction. As was expected, 3 mm-slice-thick reconstruction CT had poor reproducibility and surgeon's confidence. More recent methods such as cone beam computed tomography scans have nowadays more relevant dose reduction potential.

## Keywords

**Chronic Rhinosinusitis, Computed Tomography, Image Reconstruction, Inter-Observer Agreement, Intra-Observer Agreement, Kappa, Radiation-Dose Reduction, Reproducibility, Paranasal Sinus, Sinus Imaging**

---

## 1. Introduction

Chronic rhinosinusitis (CRS) is a common, multifactorial and variable disease with a prevalence of around 10% - 16% [1]. The diagnostics of CRS is based on typical symptoms and clinical findings [1]. Computed tomography (CT) scans are the imaging modality of choice confirming the extent of pathology and the need for surgery. The main findings in CRS are mucosal changes within the osteomeatal complex and/or sinuses. Other characteristic findings are air-fluid levels, mucosal thickening and opacification of the normally aerated sinus lumen. The only CRS indicating change can be sclerotic, thickened bone of the sinus wall [1]. The number of anatomical variants is very high in paranasal sinuses [2] [3]. Several of them are located close to sinonasal surgical area and thus the intraoperative lesions of them may lead to severe illness or be life threatening. The operatively important structures are insertion of middle turbinate and the uncinated process, the location of anterior ethmoidal artery, and Keros class, Infraorbital cells, position of the Agger nasi cell, and the anatomical variants located in the operative area [4]-[6]. Studies demonstrate that there is dose-reduction potential of CT scans [7]-[10].

The aim of this prospective study was to evaluate whether our method might be eligible in studies aiming at radiation dose reduction. Sinus CT scans were chosen as a model because of the high variation of the radiological anatomy of surgically important sinonasal structures. We hypothesized that 3 mm-slice-thick reconstruction of sinus CT scans had poor dose-reduction potential and inter-observer agreement.

## 2. Materials and Methods

### 2.1. Patients

This prospective cohort study was carried out in the Department of Otorhinolaryngology at Tampere University Hospital, Finland from 2006 to 2015. The study was approved by the ethical committee of the Pirkanmaa Hospital District (no 96032). Written informed consent was obtained of each participant. A random sample of 59CRS patients, who were evaluated to benefit from sinus CT scans during 2006-2007, was enrolled to this study. Patient data was collected from medical records and by a questionnaire at the time the sinus CT was performed. The follow-up data of sinonasal operations and time of surgery was collected from patient records of Tampere University Hospital or Tampere City Hospital in 2015 in average 9 years after the time of performing sinus CT scans. None of the subjects had used Aspirin desensitization, allergen immunotherapy, or anti IgE therapy prior to or during the sinus CT scans or during the follow-up.

### 2.2. CT Scans

The patients underwent routine sinus multiple detector computed tomography (CT<sub>MD</sub>) examinations for clinical purposes. Two different CT<sub>MD</sub> machines were used: GE Light Speed 16 (GE Healthcare, Milwaukee, Wisconsin) and Philips Brilliance 64 (Philips, Best, the Netherlands). The patients were imaged in supine position with a kilovoltage of 120 kV and a milliamperere second of 100 mAs. In the GE machine, the slice thickness was 0.625 mm with coronal reconstructions at 1.5 mm. In the Philips machine, the slice thickness was 0.9 mm with coronal reconstructions at 0.9 mm. Both were three dimensional (3D) in nature without any gap. In all cases, the imag-

ing was performed using a bone filter technique. The imaging covered the entire sinonasal area both in the axial and coronal directions. The coronal reformations spanned through the entire area, starting from the anterior wall of the frontal sinuses and ending to the level of the posterior wall of the sphenoid sinuses. We performed 3 mm-slice-thick reconstructions ( $CT_{3mm}$ ) from coronal, sagittal and axial data sets of  $CT_{MD}$ . The coronal reformations in the  $CT_{MD}$  and  $CT_{3mm}$  spanned through the entire area, starting from the anterior wall of the frontal sinuses and ending at the level of the posterior wall of the sphenoid sinuses.

### 2.3. Evaluation of CT Scans

$CT_{MD}$  and  $CT_{3mm}$  scans were observed by three independent observers blinded to each other and to the patient history data. The observation of the same patient's scans occurred at least one week apart. The focus was to compare agreement between  $CT_{MD}$  and  $CT_{3mm}$  scans and between three observers in evaluating CRS-related changes and radiological anatomy of the structures. The observers were an experienced head and neck radiologist (AM), an experienced ENT- and rhinosurgeon (JN), and a fifth year ENT resident (ST-S). They filled in a 49 -item form of sinonasal structures from both scans and from both sides of each patient (**Table 3**). Similar forms were filled from  $CT_{MD}$  and  $CT_{3mm}$  scans. Evaluation of the same patient's scans occurred at least 7 days apart. All asked structures had 2 - 5 different choices. Before starting the evaluation of the CT scans, all choices were carefully discussed by the observers. Observers also made a pilot of 15 CT scans in order to make sure that all observers understood how to fill in the forms. The Radiologist did not respond to the questions: "Need for septoplasty" and "Grade of surgeon's confidence based on images".

### 2.4. Data Analysis

Statistical analysis was carried out by the SPSS Base 15.0 Statistical Software Package (SPSS Inc., Chicago, IL, USA). Cohen's kappa was used to compare the degree of agreement of  $CT_{MD}$  and  $CT_{3mm}$  scans (e.g. intraobserver agreement); and the inter-observer agreement of  $CT_{3mm}$  scans. The calculation is based on the difference between how much agreement is actually present compared to how much agreement would be expected to be present by chance alone. The established interpretation of Kappa-value is classified into 6 subgroups: Poor  $\leq 0.2$ , Fair 0.21 - 0.4, Moderate 0.41 - 0.6, Good 0.61 - 0.8, and Very Good 0.81 - 1.0. A value under zero means that the agreement is worse than by chance, and the value range is from -1 to +1. Two-tailed P-values of  $<0.05$  were considered statistically significant.

## 3. Results

### 3.1. Patient Characteristics

The characteristics of patients are shown in **Table 1**. The mean (min-max) age was 43 (13 - 77) years by the time of taking the CT scans. 54.2% of patients underwent sinonasal operation within a year after the CT scans were performed (**Table 1**). Of these patients that were operated at the time of CT scans, 7 (21.9%) underwent revision sinonasal surgery in average 3 years later. 47.5% of patients reported suffering from diseases (other than CRS) with regular need of medications. The most frequent diseases were (number of patients): heart and vascular diseases [11], hypothyreosis [8], migraine [3] and arthrosis/arthritis [4].

### 3.2. Inter-Observer Agreement of $CT_{3mm}$ Scans

Lund-MacKay scores (**Table 2**) and 43 other structures were evaluated by a radiologist, an ENT surgeon and an ENT resident from both  $CT_{MD}$  and reconstructed  $CT_{3mm}$  scans (**Table 2**, **Table 3**). The inter-observer agreement for  $CT_{3mm}$  scans was moderate (kappa 0.4 - 0.6) in the majority of structures (**Table 3**). In  $CT_{3mm}$  scans, the surgically important structures with greatest disagreement were found in Keros classification (radiologist vs. ENT resident), the location of anterior ethmoidal artery and optic nerve (all observers), prominent ethmoid bulla (ENT resident vs. ENT surgeon), and thickness and contact to middle turbinate of orbital lamina of ethmoidal bone (radiologist vs. ENT surgeon) (**Figure 1**, **Table 3**).

### 3.3. Intra-Observer Agreement

We compared the degree of agreement between  $CT_{MD}$  and  $CT_{3mm}$  scans of the Lund-MacKay scores and 43 oth-

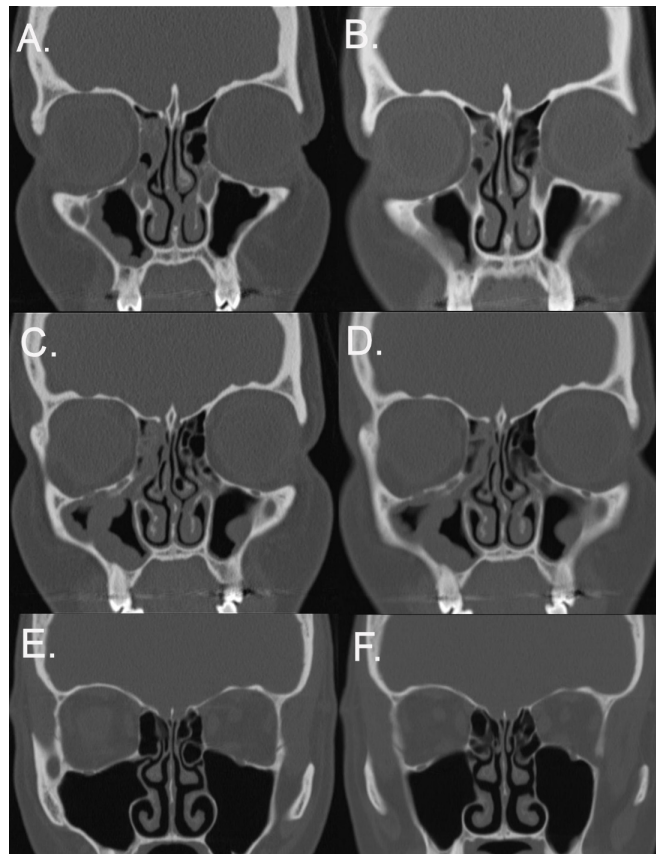
**Table 1.** Characteristics of the patients.

		Chronic rhinosinusitis patients	
		n (59)	%
Gender	Male	27	45.8
	Female	32	54.2
Age	≥45 years	35	59.3
	<45 years	24	40.7
Smoking	No	30	50.8
	Ex	11	18.6
	Current	15	25.4
	Unknown	3	5.1
Allergic rhinitis	No	34	57.6
	Yes	23	39.0
	Unknown	2	3.4
Asthma	No	45	76.3
	Yes	12	20.3
	Unknown	2	3.4
Nasal polyps	No	42	71.2
	Yes	15	25.4
	Unknown	2	3.4
Duration of symptoms	<1 year	8	13.6
	1 - 4.9 years	23	39.0
	5 - 14.9 years	14	23.7
	≥15 years	11	18.6
	Unknown	3	5.1
Antibiotic courses during the past 2 years	No	11	18.6
	1 - 3	22	37.3
	4 - 9	14	23.7
	≥10	10	16.9
	Unknown	2	3.4
Current use of intranasal corticosteroids	No	15	25.4
	Yes	42	71.2
	Unknown	2	3.4
≥1 peroral corticosteroid course(s) during the past 1 year	No	55	98.2
	Yes	1	1.8
	Unknown	3	5.1
Previous sinonasal operation(s)	No	45	76.3
	Yes	14	23.7
Radiological signs in CT <sub>3mm</sub> scans of previous sinus operation	No	46	78.0
	Yes	13	22.0
Sinonasal operation performed within a year after the CT scans	No	25	42.4
	Yes	32	54.2
	Unknown	2	3.4
≥1 sinonasal operation(s) during the 9-year follow-up	No	47	79.7
	Yes	10	16.9
	Unknown	2	3.4
Current symptoms by VAS, mean (min - max)	Sense of smell	3.2	(0 - 10)
	Post-nasal drip	5.0	(0 - 10)
	Obstruction	5.5	(0 - 10)
	Facial pain	4.9	(0 - 10)

Abbreviation: VAS = visual analogue scale (0 - 10).

**Table 2.** Medians and interquartile ranges (Q1 - Q3) of the radiologic Lund McKay (LM) scores evaluated by the radiologist from multi-detector sinus computed tomography scans (CT<sub>MD</sub>) from 59 patients suffering from chronic rhinosinusitis.

LM score	Right		Left	
	Median	Q <sub>1</sub> - Q <sub>3</sub>	Median	Q <sub>1</sub> - Q <sub>3</sub>
Frontal sinus	0	0 - 1	0	0 - 1
Anterior ethmoidal sinus	1	0 - 1	0	0 - 1
Ostiomeatal unit	0	0 - 2	0	0 - 2
Posterior ethmoidal sinus	1	0 - 1	0	0 - 1
Sphenoid sinus	0	0 - 1	0	0 - 1
Maxillary sinus	0	0 - 1	1	1 - 1
LM score total	3	1 - 6	4	1 - 5

**Figure 1.** Two cases suffering from chronic rhinosinusitis and who underwent routinely multi-detector sinus computed tomography scans (CT<sub>MD</sub>) ((A) (C) (E)). CTs with 3 mm slice thickness (CT<sub>3mm</sub>) were reconstructed from CT<sub>MD</sub> data-sets in order to evaluate radiation dose reduction potential ((B) (D) (F)). (A) Patient 1, CT<sub>MD</sub>, Frontal recess and ostium. (B) Patient 1, CT<sub>3mm</sub>, representative slice from Frontal recess and ostium with slightly limited visualization. (C) Patient 1, CT<sub>MD</sub>, Ostiomeatal complex (D) Patient 1, CT<sub>3mm</sub>, representative slice from Ostiomeatal complex with slightly limited visualization. (E) Patient 2, CT<sub>MD</sub>, Anterior Ethmoidal artery sulcus (F) Patient 2, CT<sub>3mm</sub>, representative Anterior Ethmoidal artery sulcus, with strongly limited visualization.

er structures evaluated by the radiologist. In general, the intra-observer agreement was very good (kappa 0.8 - 1.0) in the majority of structures, such as Lund Mackay scores (Table 4). Yet, several surgically important structures did not show adequate agreement: OMC-area, frontal and speno-ethmoid recess, lamina papyrae, and optic nerve (Table 4). Anterior ethmoidal artery was responded to be undetectable in 95% of the CT<sub>3mm</sub> scans, but only in 13% of the CT<sub>MD</sub> scans (Figure 1).

**Table 3.** Inter-observer agreement of CT<sub>3mm</sub> for 49 sinonasal structures. 59 patients suffering from chronic rhinosinusitis underwent routine multi-detector sinus computed tomography scans (CT<sub>MD</sub>). CTs with 3 mm slice thickness (CT<sub>3mm</sub>) was reconstructed from CT<sub>MD</sub> data-sets. The order of the structures is the same as they were in the evaluation form. P-values by kappa-test. ENT = Ear nose throat; OMC = Ostiomeatal complex, uncin. = Uncinated; proc. = process. – = The Radiologist did not respond to the questions; “Need for septoplasty” and “Grade of surgeon’s confidence based on images”.

	Radiologist vs. ENT resident			Radiologist vs. ENT surgeon			ENT surgeon vs. ENT resident					
	right		left	right		left	right		left			
	kappa	p	kappa	p	kappa	p	kappa	p	kappa	p		
Lund-Mackay Frontal sinus	0.736	<0.01	0.887	<0.01	0.733	<0.01	0.827	<0.01	0.560	<0.01	0.869	<0.01
Lund-Mackay Anterior ethmoidal sinus	0.746	<0.01	0.702	<0.01	0.734	<0.01	0.760	<0.01	0.869	<0.01	0.679	<0.01
Lund-Mackay Ostiomeatal unit	0.389	<0.01	0.660	<0.01	0.852	<0.01	0.618	<0.01	0.474	<0.01	0.488	<0.01
Lund-Mackay Posterior ethmoidal sinus	0.630	<0.01	0.727	<0.01	0.794	<0.01	0.870	<0.01	0.798	<0.01	0.819	<0.01
Lund-Mackay Sphenoid sinus	0.736	<0.01	0.653	<0.01	0.851	<0.01	0.672	<0.01	0.631	<0.01	0.630	<0.01
Lund-Mackay Maxillary sinus	0.632	<0.01	0.749	<0.01	0.684	<0.01	0.738	<0.01	0.680	<0.01	0.788	<0.01
Sinus mucosal abnormalities of Frontal sinus	0.561	<0.01	0.600	<0.01	0.420	0.824	0.520	<0.01	0.564	<0.01	0.692	<0.01
Sinus mucosal abnormalities of Anterior ethmoidal sinus	0.737	<0.01	0.688	<0.01	0.676	<0.01	0.770	<0.01	0.722	<0.01	0.722	<0.01
Sinus mucosal abnormalities of Posterior ethmoidal sinus	0.517	<0.01	0.604	<0.01	0.623	<0.01	0.673	<0.01	0.760	<0.01	0.802	<0.01
Sinus mucosal abnormalities of Sphenoid sinus	0.578	<0.01	0.482	<0.01	0.627	<0.01	0.455	<0.01	0.593	<0.01	0.586	<0.01
Sinus mucosal abnormalities of Maxillary sinus	0.440	<0.01	0.452	<0.01	0.481	<0.01	0.505	<0.01	0.510	<0.01	0.511	<0.01
Hypoplasia/normal/hyperplasia of Frontal sinus	0.586	<0.01	0.258	<0.03	0.457	<0.01	0.434	<0.01	0.546	<0.01	0.129	0.342
Hypoplasia/normal/hyperplasia of Anterior ethmoidal sinus	1.00	<0.01	1.00	<0.01	1.00	<0.01	1.00	<0.01	1.00	<0.01	1.00	<0.01
Hypoplasia/normal/hyperplasia of Posterior ethmoidal sinus	1.00	<0.01	1.00	<0.01	1.00	<0.01	1.00	<0.01	1.00	<0.01	1.00	<0.01
Hypoplasia/normal/hyperplasia of Sphenoid sinus	0.636	<0.01	0.348	0.026	0.161	0.209	0.195	0.181	0.200	<0.01	-0.077	<0.849
Hypoplasia/normal/hyperplasia of Maxillary sinus	0.489	<0.01	0.543	<0.01	0.083	1.00	0.285	<0.01	1.00	<0.01	0.354	<0.01
Need for septoplasty	-	-	-	-	-	-	-	-	0.140	<0.378	0.644	<0.01
Septal deviation obstructing middle meatus	0.268	<0.086	0.777	<0.01	0.431	<0.015	-0.038	1.00	0.288	0.184	0.481	<0.071
Septum turbinate	1.00	<0.01	0.363	<0.01	-0.062	<0.01	-0.035	<0.01	-0.094	0.809	-0.138	0.421
Septum deviation	0.177	0.189	0.222	0.096	0.782	<0.01	0.352	<0.02	0.222	0.090	0.492	<0.01
Septum, Crest	1.00	<0.01	-0.069	1.000	0.535	0.018	0.557	<0.01	1.00	<0.01	-0.050	<0.01
Septum, Spur	0.404	<0.01	0.553	<0.01	0.290	<0.05	0.350	<0.01	0.671	<0.021	0.439	<0.01
Previous sinus surgery performed	0.939	<0.01	0.765	<0.01	0.873	<0.01	0.809	<0.01	0.937	<0.01	0.879	<0.01
Infraorbital cell	0.307	<0.01	0.350	<0.01	0.221	<0.01	0.331	<0.01	0.118	<0.01	0.232	<0.01
Paradoxical Middle turbinate	0.232	<0.01	0.254	<0.01	0.501	0.01	0.513	0.051	0.167	<0.01	0.269	<0.01
Paradoxical Superior turbinate	0.061	0.019	0.068	0.019	0.239	<0.01	0.234	<0.01	0.233	<0.01	0.247	<0.01

## Continued

Atrophy-normal-hypertrophy of Inferior turbinate	0.402	<0.01	0.382	<0.01	0.434	<0.01	0.343	<0.01	0.477	<0.01	0.258	<0.01
Atrophy-normal-hypertrophy of Middle turbinate	0.387	<0.01	0.461	<0.01	0.279	<0.01	0.335	<0.01	0.396	<0.01	0.296	0.014
Pneumatized Superior turbinate	0.127	<0.01	0.157	<0.01	0.391	<0.01	0.435	<0.01	0.387	<0.014	0.387	<0.014
Pneumatized Middle turbinate	0.447	<0.01	0.464	<0.01	0.479	<0.01	0.473	<0.01	0.490	<0.01	0.447	<0.01
Concha bullosa superior	0.165	<0.01	0.142	<0.01	0.251	<0.087	0.271	<0.045	0.344	<0.01	0.250	0.07
Mucosa of pneumatized Middle turbinate	0.564	<0.01	0.535	<0.01	0.531	<0.01	0.692	<0.01	0.404	<0.01	0.458	<0.01
Mucosa of pneumatized Superior turbinate	0.157	<0.01	0.141	<0.01	0.227	<0.083	0.266	<0.043	0.261	<0.01	0.168	0.024
OMC region, Prominent ethmoidal bulla	0.380	0.014	0.429	<0.01	0.224	0.045	0.211	0.062	0.215	<0.051	0.177	0.145
OMC region, Hiatus	0.583	<0.01	0.432	<0.01	0.393	<0.01	0.230	<0.031	0.501	<0.01	0.441	<0.01
OMC region, Infundibulum	0.415	<0.01	0.394	<0.01	0.571	<0.01	0.553	<0.01	0.538	<0.01	0.405	<0.01
OMC region, Maxillary antrum	0.452	<0.01	0.291	<0.01	0.422	<0.01	0.530	<0.01	0.549	<0.01	0.464	<0.01
OMC region, Superior attachment of uncinat process	0.281	<0.01	0.429	<0.01	0.391	<0.01	0.431	<0.01	0.491	<0.01	0.432	<0.017
OMC region, Accessory maxillary sinus ostium	0.416	<0.01	0.376	<0.01	0.390	<0.01	0.535	<0.01	0.266	<0.014	0.262	<0.016
OMC region, Pneumatized superior attachment of uncin. proc.	0.251	<0.01	0.325	<0.01	0.426	<0.118	0.541	0.01	0.411	<0.01	0.325	<0.01
Frontal recess	0.254	<0.01	0.275	<0.01	0.677	<0.01	0.589	<0.01	0.289	<0.01	0.242	<0.01
Sphenoidal recess	0.302	<0.01	0.322	<0.01	0.663	<0.01	0.599	<0.01	0.293	<0.01	0.308	<0.01
Anterior ethmoidal artery	0.094	<0.01	0.094	<0.01	-0.092	<0.01	-0.095	<0.01	0.036	<0.869	0.006	1.00
Optic nerve	-0.021	<0.01	1.00	<0.01	0.258	0.024	0.264	0.023	-0.031	0.169	1.00	<0.01
Thickness of orbital lamina of ethmoidal bone	1.00	<0.01	1.00	<0.01	-0.019	1.00	-0.017	1.00	1.00	<0.01	1.00	<0.01
Contact to middle turbinate of orbital lamina ethmoidal bone	1.00	<0.01	1.00	<0.01	-0.023	<0.01	-0.023	<0.01	1.00	<0.01	1.00	<0.01
Keros classification	-0.044	0.667	-0.009	1.00	0.444	<0.01	0.437	<0.01	0.260	<0.01	0.260	<0.01
Grade of surgeon's confidence based on images	-	-	-	-	-	-	-	-	0.299	<0.01	0.299	<0.01
Mucosa of nasal cavity (extent of edema)	0.039	<0.01	1.00	<0.01	0.018	<0.01	1.00	<0.01	0.385	<0.01	0.238	0.169
Mucosa of nasal cavity (normal-polypous)	0.046	<0.01	1.00	<0.01	0.022	<0.01	1.00	<0.01	0.372	<0.01	0.265	0.022

Agreement	kappa
poor	≤0.2
fair	0.21 - 0.4
moderate	0.41 - 0.6
good	0.61 - 0.8
very good	0.81 - 1.0

**Table 4.** Comparison of agreement between two types of sinus computed tomography scans (CT<sub>MD</sub> and CT<sub>3mm</sub>) of 49 sinonasal structures that were evaluated by the Radiologist. CTs with 3 mm slice thickness (CT<sub>3mm</sub>) were reconstructed from CT<sub>MD</sub> data-sets of 59 patients. The alphabetical order of the structures and the level of intra-observer agreement. The order of the structures is the same as they were in the evaluation form (shown in Table 3). All P values < 0.01 by kappa-test. OMC = Ostiomeatal complex. <sup>1</sup>Evaluated by the ENT surgeon.

Poor	Fair	Moderate	Good	Very good
Anterior ethmoidal artery	Grade of surgeon's confidence based on images OMC region, Hiatus	Concha bullosa superior OMC region, Maxillary antrum OMC region, Superior attachment of uncinatate process Optic nerve Pneumatized Superior turbinate Thickness of orbital lamina of ethmoidal bone	Atrophy-normal hypertrophy of Superior turbinate Frontal recess Infraorbital cell Lund-Mackay Maxillary sinus OMC region, Accessory maxillary sinus ostium OMC region, Infundibulum OMC region, Pneumatized superior attachment of uncinatated process OMC region, Prominent ethmoid bulla Sphenothmoidal recess	Atrophy-normal hypertrophy of Middle turbinate Atrophy-normal hypertrophy of Middle turbinate Contact to middle turbinate of orbital lamina of ethmoidal bone Hypoplasia/normal/hyperplasia of Anterior ethmoidal sinus Hypoplasia/normal/hyperplasia of Frontal sinus Hypoplasia/normal/hyperplasia of Maxillary sinus Hypoplasia/normal/hyperplasia of Posterior ethmoidal sinus Hypoplasia/normal/hyperplasia of Sphenoid sinus Keros classification Lund-Mackay Anterior ethmoidal sinus Lund-Mackay Frontal sinus Lund-Mackay Ostiomeatal unit Lund-Mackay Posterior ethmoidal sinus Lund-Mackay Sphenoid sinus Mucosa of nasal cavity(extent of edema) Mucosa of nasal cavity(normal-polypous) Mucosa of pneumatized Middle turbinate Need for septoplasty <sup>1</sup> Paradoxical Middle turbinate Paradoxical Superior turbinate Pneumatized Middle turbinate Previous sinus surgery performed Septal deviation obstructing middle meatus <sup>1</sup> Septum, Crest Septum deviation Septum turbinate Septum, Spur Sinus mucosal abnormalities of Anterior ethmoidal sinus Sinus mucosal abnormalities of Frontal sinus Sinus mucosal abnormalities of Maxillary sinus Sinus mucosal abnormalities of Posterior ethmoidal sinus Sinus mucosal abnormalities of Sphenoid sinus

Agreement	kappa
poor	≤0.2
fair	0.21 - 0.4
moderate	0.41 - 0.6
good	0.61 - 0.8
very good	0.81 - 1.0



### 3.4. Operative Confidence of CT<sub>3mm</sub> Scans

ENT surgeon and ENT resident estimated operative certainty of CT<sub>3mm</sub> in comparison to CT<sub>MD</sub>. ENT surgeon responded that the operative confidence is good in 69.6% of CT<sub>MD</sub> scans, and 64.3% of CT<sub>3mm</sub> scans. The intra-observer agreement in the grade of ENT surgeon's confidence of CT<sub>3mm</sub> in comparison to CT<sub>MD</sub> was moderate (kappa 0.4,  $P = 0.005$ ). ENT resident responded that the operative confidence is good in 73.2% of CT<sub>MD</sub> scans, but only in 37.5% of CT<sub>3mm</sub> scans. The intra-observer agreement in the grade of ENT resident's confidence of CT<sub>3mm</sub> in comparison to CT<sub>MD</sub> was thus poor (kappa 0.2,  $P = 0.035$ ).

## 4. Discussion

This study was carried out to evaluate whether the used method would be eligible when studying radiation dose reduction potential. As an example, we compared two techniques of paranasal sinus CT scans. From the CT scans we evaluated important structures of CRS diagnostics and operation. By reformatting the CT<sub>3mm</sub> images, we were able to evaluate the same patient exactly without additional imaging. Patient selection was performed randomly from a doctor's reception. A heterogeneous patient group made the extrapolation of the results possible for clinical practice

We found that inter-observer agreement was only moderate in CT<sub>3mm</sub> scans. This finding is in line with our unpublished data that inter-observer agreement is at similar level also in the conventional CT<sub>MD</sub> scans. This might be due to the fact that sinonasal anatomy is highly variable. Intra-observer agreement between CT<sub>3mm</sub> and CT<sub>MD</sub> scans was very good in most structures. However, it was fair to poor in several surgically important structures. The grade of young surgeons' confidence was relatively good with CT<sub>MD</sub> scans whereas the grade of confidence was poor with CT<sub>3mm</sub> scans. Taking together, CT<sub>3mm</sub> scans seemed not to be clinically relevant imaging method.

Previously, it has been shown that CRS diagnostics is possible with other reduced radiation CT-techniques. However, the surgical aspects have not been dealt with in these studies [7]-[9]. Our current study showed that it was possible to reduce the radiation dose and increase slice thickness without compromising the excellent bone and soft tissue contrast. However, successful endoscopic sinus surgery (ESS) requires detailed knowledge of the highly variable anatomy of the nasal cavities, the ostiomeatal unit, and the skull base. In addition, the vital structures especially the optic nerve and the anterior ethmoid artery and their relationship to operational areas need to be clear.

Multi-detector CT technology comprises multiple detectors that are equivalent to slices. Conventional CT<sub>MD</sub> comprises consecutive slices with a thickness of 0.6 - 1.5 mm and causes a radiation dose of 0.5 mSv on average. Technological improvement has been rapid resulting in 4-, 8-, 16-, 32-, 40- and 64-detector machines. It is known that there is no safe radiation dose. In all exposure quantities, there is a corresponding mutational risk [11]. The head and neck region, the eyes and thyroid gland are the most radiosensitive organs. In addition to the cancer risk, radiation-induced cataracts are possible after multiple exposures [3]. Image quality is affected by image noise or quantum mottle and is almost always directly related to the radiation dose. Keeping this in mind, the cone beam computed tomography seems to be relevant recent implementation in CT imaging. Essentially, it could be the best compromise so far between low radiation and excellent image quality [12]-[15].

As a conclusion, our study demonstrated that this methodology was easy to use and might have some use in studies aiming at radiation dose reduction. As was expected, 3 mm-slice-thick reconstruction CT had poor reproducibility and surgeon's confidence. More recent methods such as cone beam computed tomography scans have nowadays more relevant dose reduction potential.

## Acknowledgements

The authors thank research nurse Marja-Leena Oksanen for her excellent assistance. The study was supported in part by research grants from the Ahokas Foundation, Competitive Research Funding of the Tampere University Hospital (Grants 9H067, 9J108, 9L087), the Finnish Medical Society Duodecim, the Finnish Society of Allergy and Immunology, Finnish Society of Otorhinolaryngology-Head and Neck Surgery, Helsinki University Central Hospital Research Funds, the Ida Monti Foundation, the Jane and Aatos Erkkö Foundation, the Väinö and Laina Kivi Foundation, and the Yrjö Jahnesson Foundation.

## Author Contributions

STS and JN provided the study plan (with MR, PD and MS), made the applications and recruited the subjects. AM, STS and JN evaluated the CT scans. AMK, MS and STS collected the clinical data. AJ, MK, AMK, HH, and STS performed the data management. MK, AJ, JN and STS wrote the manuscript. All authors reviewed critically the manuscript.

## References

- [1] Fokkens, W.J., Lund, V.J., Mullol, J., Bachert, C., Alobid, I., Baroody, F., *et al.* (2012) European Position Paper on Rhinosinusitis and Nasal Polyps 2012. *Rhinology Supplement*, **23**, 3 p Preceding Table of Contents, 1-298.
- [2] Food and Drug Administration (2002) FDA Public Health Notification: Reducing Radiation Risk from Computed Tomography for Pediatric and Small Adult Patients. *Pediatric Radiology*, **32**, 314-316. <http://dx.doi.org/10.1007/s00247-002-0687-6>
- [3] Zammit-Maempel, I., Chadwick, C.L. and Willis, S.P. (2003) Radiation Dose to the Lens of Eye and Thyroid Gland in Paranasal Sinus Multislice CT. *The British Journal of Radiology*, **76**, 418-420. <http://dx.doi.org/10.1259/bjr/82798696>
- [4] Lund, V.J. and Kennedy, D.W. (1997) Staging for Rhinosinusitis. *Otolaryngology—Head and Neck Surgery*, **117**, S35-S40. [http://dx.doi.org/10.1016/s0194-5998\(97\)70005-6](http://dx.doi.org/10.1016/s0194-5998(97)70005-6)
- [5] Holbrook, E.H., Brown, C.L., Lyden, E.R. and Leopold, D.A. (2005) Lack of Significant Correlation between Rhinosinusitis Symptoms and Specific Regions of Sinus Computer Tomography Scans. *American Journal of Rhinology*, **19**, 382-387.
- [6] Hopkins, C., Browne, J.P., Slack, R., Lund, V. and Brown, P. (2007) The Lund-Mackay Staging System for Chronic Rhinosinusitis: How Is It Used and What Does It Predict? *Otolaryngology—Head and Neck Surgery*, **137**, 555-561. <http://dx.doi.org/10.1016/j.otohns.2007.02.004>
- [7] Brem, M.H., Zamani, A.A., Riva, R., Zou, K.H., Rumboldt, Z., Hennig, F.F., *et al.* (2007) Multidetector CT of the Paranasal Sinus: Potential for Radiation Dose Reduction. *Radiology*, **243**, 847-852. <http://dx.doi.org/10.1148/radiol.2433050207>
- [8] Mulkens, T.H., Broers, C., Fieuws, S., Termote, J.L. and Bellnick, P. (2005) Comparison of Effective Doses for Low-Dose MDCT and Radiographic Examination of Sinuses in Children. *AJR American Journal of Roentgenology*, **184**, 1611-1618. <http://dx.doi.org/10.2214/ajr.184.5.01841611>
- [9] Abul-Kasim, K., Strombeck, A. and Sahlstrand-Johnson, P. (2011) Low-Dose Computed Tomography of the Paranasal Sinuses: Radiation Doses and Reliability Analysis. *American Journal of Otolaryngology*, **32**, 47-51. <http://dx.doi.org/10.1016/j.amjoto.2009.08.004>
- [10] Demeslay, J., Vergez, S., Serrano, E., Chaynes, P., Cantet, P., Chaput, B., *et al.* (2015) Morphological Concordance between CBCT and MDCT: A Paranasal Sinus-Imaging Anatomical Study. *Surgical and Radiologic Anatomy*, **38**, 71-78.
- [11] Frush, D.P., Slack, C.C., Hollingsworth, C.L., Bisset, G.S., Donnelly, L.F., Hsieh, J., *et al.* (2002) Computer-Simulated Radiation Dose Reduction for Abdominal Multidetector CT of Pediatric Patients. *AJR American Journal of Roentgenology*, **179**, 1107-1113. <http://dx.doi.org/10.2214/ajr.179.5.1791107>
- [12] Miracle, A.C. and Mukherji, S.K. (2009) Conebeam CT of the Head and Neck, Part 1: Physical Principles. *AJNR American Journal of Neuroradiology*, **30**, 1088-1095. <http://dx.doi.org/10.3174/ajnr.A1653>
- [13] Miracle, A.C. and Mukherji, S.K. (2009) Conebeam CT of the Head and Neck, Part 2: Clinical Applications. *AJNR American Journal of Neuroradiology*, **30**, 1285-1292. <http://dx.doi.org/10.3174/ajnr.A1654>
- [14] Campbell Jr., P.D., Zinreich, S.J. and Aygun, N. (2009) Imaging of the Paranasal Sinuses and In-Office CT. *Otolaryngologic Clinics of North America*, **42**, 753-764. <http://dx.doi.org/10.1016/j.otc.2009.08.015>
- [15] Viera, A.J. and Garrett, J.M. (2005) Understanding Interobserver Agreement: The Kappa Statistic. *Family Medicine*, **37**, 360-363.

## Abbreviations

CT = Computed tomography;  
CRS = Chronic rhinosinusitis;  
ENT = Ear nose throat.