



PIRJO HONKANEN

Metacarpophalangeal Arthroplasty and  
Partial Wrist Fusion as a Surgical Treatment  
in Rheumatoid Hand Disease



ACADEMIC DISSERTATION

To be presented, with the permission of  
the board of the School of Medicine of the University of Tampere,  
for public discussion in the Small Auditorium of Building M,  
Pirkanmaa Hospital District, Teiskontie 35,  
Tampere, on February 24th, 2012, at 12 o'clock.

UNIVERSITY OF TAMPERE

## ACADEMIC DISSERTATION

University of Tampere, School of Medicine  
Tampere University Hospital, Departments of Internal Medicine, Orthopaedics and Physiatrics  
Helsinki University Central Hospital, Department of Medicine  
COXA Hospital for Joint Replacement, Tampere  
Päijät-Häme Social and Health Care, Lahti  
Rheumatism Foundation Hospital, Heinola  
Finland

*Supervised by*

Professor Matti U. K. Lehto  
University of Tampere  
Finland  
Professor Yrjö T. Konttinen  
University of Helsinki  
Finland

*Reviewed by*

Docent Juhana Leppilahti  
University of Oulu  
Finland  
Docent Tuulikki Sokka-Isler  
University of Eastern Finland  
Finland

Copyright ©2012 Tampere University Press and the author

Distribution  
Bookshop TAJU  
P.O. Box 617  
33014 University of Tampere  
Finland

Tel. +358 40 190 9800  
Fax +358 3 3551 7685  
taju@uta.fi  
www.uta.fi/taju  
<http://granum.uta.fi>

Cover design by  
Mikko Reinikka

Acta Universitatis Tamperensis 1698  
ISBN 978-951-44-8698-2 (print)  
ISSN-L 1455-1616  
ISSN 1455-1616

Acta Electronica Universitatis Tamperensis 1164  
ISBN 978-951-44-8699-9 (pdf)  
ISSN 1456-954X  
<http://acta.uta.fi>

*To Petri, Pia and Sanna*



# ABSTRACT

The typical manifestations of the rheumatoid hand are ulnar drift of the knuckle joints and palmar subluxation of the wrist joint. The wrist collapse facilitates a progression of metacarpophalangeal (MCP) joint deformities, and thus in operative treatment the wrist joint deformity is corrected before MCP joint surgery. Total arthrodesis of the wrist and silicone arthroplasty of the MCP joints have been the gold standards for long in rheumatoid hand surgery. The main problem of the total fusion is the loss of motion of the wrist joint, and after silicone MCP arthroplasty the breakage of the implants and deterioration of the clinical outcome in long-term follow-up.

The aim of this dissertation was to study the effect of partial radiocarpal arthrodesis on rheumatoid hand alignment, function and pain, and to analyse the biocompatibility and clinical results of a novel bioabsorbable 96L/4D poly-L/D-lactide copolymer (PLDLA) implant, also to compare the outcome of PLDLA implant arthroplasty with that of the conventional silicone Swanson prosthesis.

In partial radiocarpal arthrodesis Study (I) 23 patients and 26 wrists (Larsen II-III) were recruited for a prospective non-randomised study and clinical and radiological evaluation were performed at a mean of 5.8-year follow-up. In Studies II and III 23 consecutive patients (80 joints) undergoing MCP arthroplasty using a novel bioabsorbable PLDLA implant were enrolled, and clinical and radiological evaluation was made at minimum 1-year follow-up and at mean 59 months after surgery, the latter follow-up time exceeding the resorption time of the implant. In a randomised clinical Study IV, the outcome of the PLDLA implant was compared to the outcome of the conventional silicone Swanson prosthesis in 52 patients (53 hands and 175 joints) at a mean follow-up of 2 years. In all studies only patients with an inflammatory arthritis diagnosis were included.

Partial radiocarpal arthrodesis gave good pain relief and subjective patient satisfaction was good, 17 out of 23 patients were totally pain-free and satisfaction was excellent or good in 20 patients. The active range of motion (63°) at final follow-up enables most of the activities of daily living. Correction of the ulnar translocation malalignment was achieved and maintained. No serious adverse events were observed after MCP joint arthroplasty with the novel bioabsorbable PLDLA implant. The clinical results (pain relief, range of motion (ROM), correction of the ulnar deviation and volar subluxation) obtained using PLDLA implants in the non-randomised studies (II-III) were comparable to earlier silicone arthroplasty results, and the clinical outcome of the Study III with the follow-up exceeding the resorption time of the implant did not differ substantially from the outcome of Studies II and IV with follow-up time under the bioabsorbtion time of the implant. In the randomised Study IV improvement in pain relief, ROM, power grip and correction of the ulnar deviation were similar in the PLDLA and Swanson groups. Palmar subluxation improved significantly in both groups, but at follow-up, palmar dislocation was observed more frequently in the PLDLA group (44 joints) than in the Swanson group (10 joints).

# TIIVISTELMÄ

Reuman aiheuttamia tyyppimuutoksia kädessä ovat rystysnivelten ulnaarideviaatio ja/tai palmaarisubluksaatio virheasento sekä ranteen palmaari- ja ulnaarisubluksaatio. Ranteen virheasento edesauttaa rystysmuutosten kehittymistä ja siksi ranteen virheasento korjataan ennen rystysnivelten leikkausta. Reumakäden yleisimpiä leikkauksia ovat pitkään olleet rannenivelen kokoluudutus ja rystysnivelten tekonivelleikkaus silikoniproteesilla. Ranteen kokoluudutusleikkauksen väistämätön haitta on rannenivelen liikkeen menettäminen. Silikonitekonivelten hajoaminen ja saavutetun leikkaustuloksen huononeminen vuosien saatossa ovat tavanomaisia ongelmia rystystekonivelleikkauksen jälkeen.

Väitöskirjatutkimuksen tarkoituksena oli ensinnäkin selvittää ranteen radiokarpaalisen osaluudutusleikkauksen vaikutusta reumakäden asentoon, toimintaan ja kipuun. Toisekseen selvitettiin uuden biokorvautuvan maitohappopohjaisen tekonivelen (96L/4D poly-L/D-lactide) soveltuvuutta ja tuloksia reumapotilaiden rystystekonivelleikkauksissa sekä verrattiin biokorvautuvan tekonivelen tuloksia perinteiseen Swanson silikonitekoniveleen.

Prospektiiviseen ei-randomisoituun ranteen radiokarpaali osaluudutustutkimukseen (I) rekrytoitiin 23 potilasta käsittäen 26 Larsen II-III destruoitunutta rannetta. Kliiniset ja radiologiset tulokset 20 potilaasta ja 23 ranteesta arvioitiin keskimäärin 5.8 vuotta leikkauksesta. Tutkimusten II ja III potilasmateriaali muodostui 23 peräkkäisestä potilaasta (80 nivelestä), joille tehtiin rystystekonivelleikkaus uudella biokorvautuvalla PLDLA tekonivelellä. Kliininen ja radiologinen arvio tehtiin vähintään yksi vuosi leikkauksesta ja keskimäärin 59 kuukautta leikkauksesta, jolloin biokorvautuva materiaali aikaisempien tutkimusten mukaan on poistunut elimistöstä. Randomisoidussa kliinisessä tutkimuksessa (IV) PLDLA implantilla tehtyjen rystystekonivelleikkausten tuloksia verrattiin perinteisellä Swanson silikonitekonivelellä tehtyjen leikkausten tuloksiin 52 potilaalla (53 kättä ja 175 niveltä) keskimäärin kaksi vuotta leikkauksesta.

Radiokarpaalisella ranteen osaluudutusleikkauksella saavutettiin hyvä kivun lievitys, täysin kivuttomia oli 17 potilasta 23 potilaasta. Tyytyväisyys leikkaustulokseen oli erinomainen tai hyvä 20 potilaalla. Saavutettu keskimääräinen aktiivi liikeala (63°) mahdollistaa suuren osa päivittäisistä askareista. Ulnaarinen siirtymä korjaantui hyvin leikkauksella ja tulos säilyi seuranta-ajan.

Uudella biokorvautuvalla PLDLA tekonivelellä ei todettu vakavia haittavaikutuksia. Kliiniset tulokset, käsittäen kivun lievittymisen, liikealan, ulnaarideviaatiovirheasennon korjaantumisen ja palmaarisen subluksaation korjaantumisen, PLDLA implantilla olivat ei-randomisoiduissa tutkimuksissa (II-III) vertailukelpoisia aikaisemmin silikonitekonivelillä julkaistuihin tuloksiin. Tutkimuksen III, jonka seuranta-aika ylitti biokorvautuvan materiaalin resorptioajan, tulokset eivät eronneet merkittävästi lyhyemmän seuranta-ajan tutkimusten (II ja IV) tuloksista. Randomisoidussa tutkimuksessa (IV) kivun helpottumisessa, liikealassa, puristusvoimassa tai ulnaarideviaation korjaantumisessa ei ollut eroa PLDLA ja Swanson ryhmien välillä. Palmaarinen subluksaatio korjaantui molemmissa ryhmissä, mutta palmaarista dislokaatiota oli PLDLA ryhmässä enemmän (44 nivelessä) kuin Swanson ryhmässä (10 nivelessä).

# Contents

ABSTRACT .....	5
TIIVISTELMÄ .....	6
ABBREVIATIONS.....	9
LIST OF ORIGINAL PUBLICATIONS .....	10
INTRODUCTION.....	11
REVIEW OF THE LITERATURE.....	13
1. Rheumatoid arthritis.....	13
2. Rheumatoid hand .....	14
2.1 Pathophysiology .....	15
2.2 Clinical evaluation.....	17
2.3 Surgical treatment.....	19
2.3.1 Indications.....	19
2.3.2 General principles .....	20
2.3.3 Methods .....	21
3. Radiocarpal partial wrist arthrodesis in rheumatoid hand surgery.....	22
3.1 Pathophysiological and kinematic basis.....	22
3.2 Indications .....	23
3.3 Surgical technique .....	23
3.4 Outcome .....	25
3.4.1 Clinical outcome.....	25
3.4.2 Radiological outcome .....	27
4. MCP arthroplasty in rheumatoid hand surgery .....	28
4.1 Indications .....	28
4.2 Methods .....	28
4.2.1 Development of the implants.....	28
4.2.2 Silicone implant arthroplasty.....	30
4.2.3 Soft tissue balancing.....	32
4.3 Results of silicone implant arthroplasty .....	33
4.3.1 Outcome evaluation .....	33
4.3.2 Clinical results .....	33
4.3.3 Radiological results .....	38
5. Bioabsorbable polymers in orthopaedic implants .....	40
5.1 Material and properties.....	40
5.2 96L/4D poly-L/D-lactide copolymer.....	42
AIMS OF THE STUDY.....	44

MATERIAL AND METHODS .....	45
1. Patient selection and study design .....	45
2. Bioabsorbable MCP implant scaffold .....	46
2.1 Manufacturing .....	46
2.2 Implant properties .....	46
3. Surgical technique and postoperative rehabilitation .....	47
3.1 Partial radiocarpal arthrodesis .....	47
3.2 MCP arthroplasty with Swanson and MCP scaffold implant .....	48
4. Clinical examination .....	50
4.1 Evaluation of alignment and range of motion .....	50
4.2 Evaluation of functionality of the hand .....	50
4.2.1 Functional grips .....	50
4.2.2 ADL abilities and activities .....	51
4.3 Evaluation of subjective outcome .....	51
4.4 Complications and adverse events .....	51
5. Radiological evaluation .....	51
5.1 Evaluation of consolidation .....	52
5.2 Evaluation of the correction of the malalignment .....	52
5.3 Evaluation of progression of joint deterioration .....	52
5.4 Evaluation of osteolysis .....	53
6. Statistical methods .....	53
SUMMARY OF THE RESULTS .....	54
1. Clinical and radiological outcome of partial radiocarpal arthrodesis in the treatment of instable rheumatoid wrist (Study I) .....	54
2. Clinical and radiological results of bioabsorbable 96L/4D poly- L/D-lactide copolymer implant in MCP arthroplasty .....	55
2.1 Outcomes prior to material bioabsorption (Studies II and IV) .....	55
2.2 Outcomes beyond the bioabsorption time (Study III) .....	56
3. Outcome of 96L/4D poly-L/D-lactide copolymer implant compared to Swanson silicone prosthesis (Study IV) .....	56
DISCUSSION .....	60
1. Radiocarpal partial arthrodesis in rheumatoid hand surgery .....	60
2. 96L/4D poly-L/D-lactide copolymer implant in MCP arthroplasty .....	61
3. Methodological considerations .....	62
4. Future considerations .....	63
SUMMARY AND CONCLUSIONS .....	65
ACKNOWLEDGEMENTS .....	66
REFERENCES .....	68



# ABBREVIATIONS

ACR	American College of Rheumatology
ADL	activities of daily living
CCP	cyclic citrullinated peptide antibody
CHR	carpal height ratio
CIT	crossed intrinsic transfer
CT	computed tomography
DIP	distal interphalangeal
DISI	dorsiflexed intercalated segmental instability
DMARDs	disease-modifying antirheumatic drugs
DRUJ	distal radioulnar joint
ECU	extensor carpi ulnaris
IP	interphalangeal
MCP	metacarpophalangeal
MHQ	Michigan Hand Outcomes Questionnaire
PGA	polyglycolide
PLDLA	96L/4D poly-L/D-lactide copolymer implant
PLA	polylactide
PIP	proximal interphalangeal
RA	rheumatoid arthritis
RF	rheumafactor
RL	radiolunate
RCT	randomized controlled trial
ROM	range of motion
RSL	radioscapholunate
TFCC	triangular fibrocartilage complex
TNF	tumor necrosis factor
VISI	volar intercalated segmental instability

# LIST OF ORIGINAL PUBLICATIONS

This dissertation is based on the following original publications, which are referred to in the text by their Roman numerals (I-IV).

- I Honkanen PB, Mäkelä S, Konttinen YT, Lehto MUK. Radiocarpal arthrodesis in the treatment of the rheumatoid wrist. A prospective midterm follow-up. *J Hand Surg Br* 2007; 32E:4:368-376.
- II Honkanen P, Kellomäki M, Lehtimäki MY, Törmälä P, Mäkelä S, Lehto MUK: Bioreconstructive joint scaffold implant arthroplasty in metacarpophalangeal joints: Short-term results of a new treatment concept in rheumatoid arthritis patients. *Tissue engineering* 2003; 9:5:957-965.
- III Honkanen PB, Kellomäki M, Konttinen YT, Mäkelä S, Lehto MUK. A midterm follow-up study of bioreconstructive polylactide scaffold implants in metacarpophalangeal joint arthroplasty in rheumatoid arthritis patients. *J Hand Surg Eur* 2009;34:179-85.
- IV Honkanen PB, Tiihonen R, Skyttä ET, Ikävalko M, Lehto MUK, Konttinen YT. Bioreconstructive poly-L/D-lactide implant compared with Swanson prosthesis in metacarpophalangeal joint arthroplasty in rheumatoid patients: a randomized clinical trial. *J Hand Surg Eur* 2010;35:746-53.

# INTRODUCTION

The typical rheumatoid hand deformity, consisting of palmar and ulnar subluxation of the wrist, ulnar drift and/or palmar subluxation of the MCP joints and swan neck or boutonnière deformity of the fingers, has been a frequent manifestation in rheumatoid arthritis (RA) patients with long-standing erosive disease. The wrist malalignment leads to the deformity of the MCP joints (Pahle & Raunio, 1969; Taleisnik, 1989; Shapiro, 1996; van Vugt, van Jaarsveld, Hofman, Helders, & Bijlsma, 1999). The destructive changes caused by RA are often significant and the rheumatoid hand disease can even pose a threat to independence in self-care (Pap, Angst, Herren, Schwyzer, & Simmen, 2003; Ghattas, Mascella, & Pomponio, 2005; Papp, Athwal, & Pichora, 2006). The aims of surgical intervention of the rheumatoid hand are pain relief, restoration of function, interruption of the mechanisms responsible for the joint destruction, correction of deformities, improvement in the appearance of the hand and in some cases protection against further destruction (Simmen, Bogoch, & Goldhahn, 2008; Trieb, 2008).

The surgical treatment of the rheumatoid hand needs to be started in the wrist joint because of the effect of the wrist malalignment on the development of ulnar drift in the knuckle joints. RA of the wrist typically begins in the radiocarpal joint, at the same time when the cartilage and motion of the midcarpal joint are preserved, which enables the use of partial radiocarpal arthrodesis operation as an early treatment of the rheumatoid wrist (J.K. Stanley & Boot, 1989; Arimitsu, Murase, Hashimoto, Oka, Sugamoto, Yoshikawa, & Moritomo, 2007). Pain alleviation is well achieved with radiocarpal arthrodesis, and the subjective satisfaction is excellent or good in 74% to 87% of cases (Linscheid & Dobyns, 1985; Chamay & Della Santa, 1991; Gaulke, Suppeln, Hildebrand, Citak, Hufner, & Krettek, 2010). The ROM of the wrist maintained after radiocarpal arthrodesis varies widely between studies. A decrease in the wrist motion in all directions, but significant only for wrist flexion, has been noted in many studies (Borisch & Haussmann, 2002; Ishikawa, Murasawa, & Nakazono, 2005; Masuko, Iwasaki, Ishikawa, Kato, & Minami, 2009). In studies with a five-year follow-up or more, as many as half of the cases have been reported to develop changes in the midcarpal joint after radiocarpal arthrodesis (Borisch & Haussmann, 2002; Ishikawa et al., 2005).

MCP joint arthroplasty is indicated in advanced stages of destruction associated with pain or functional impairment. The reconstructive surgery of rheumatoid MCP joints was started with interposition arthroplasties using patient's own tissues as a spacer (Vainio, Reiman, & Pulkki, 1967; Tupper, 1989). Many prosthetic designs have been introduced to MCP joint replacement over the last 50 years, but due to the high rate of implant fractures and dislocations, bone loss or recurrence of the ulnar drift, many of the designs have been withdrawn from the market (Wilson & Carlblom, 1989; Linscheid, 2000; Merolli, 2009). The one-piece silicone implant designed by Swanson in the 1960's has remained for several decades the joint replacement of choice for the MCP joints in RA patients. The active ROM after silicone MCP arthroplasty varies from 27° to 56°, and it is either slightly improved from the preoperative ROM or more often sustained at the preoperative level. Typically the extension lag is improved whereas the flexion arc is diminished. The correction of the ulnar deviation is regularly achieved, and the postoperative deviation varies from 4° to 23°.

Clinical and radiological benefits of silicone MCP joint arthroplasty are often lost in long-term follow-up. Only 28% of patients were pain free and only 38% were satisfied with function in the study by Goldfarb and Stern (2003) at 14-year follow-up. Wilson et al. (1993) reported over 20 degrees recurrence of ulnar deviation in 43% of cases after 14-year follow-up. Survival at five years using revision surgery as an endpoint has been reported to be 92-97% and at 10 years 83-90% (Hansraj, Ashworth, Ebramzadeh, Todd, Griffin, Ashley, & Cardilli, 1997; Trail, Martin, Nuttall, & J.K. Stanley, 2004; Parkkila, Belt, Hakala, Kautiainen, & Leppilahti, 2006). However, using fracture of the implant as the end point, survival was only 58% at 10 years (Trail et al., 2004). Osteolysis around the silicone implant is common. In a randomised controlled trial (RCT), comparing Swanson and Sutter prostheses, only 60% of the metacarpals in the Swanson group and 23% in the Sutter group were free of osteolytic changes at 58-month follow-up. Osteolysis perforating the cortex was reported in 5% of Swanson cases and in 30% of Sutter cases (Parkkila, Belt, Hakala, Kautiainen, & Leppilahti, 2005).

Our first study evaluates outcomes of partial radiocarpal arthrodesis in RA patients. The usability of the novel bioabsorbable 96L/4D poly-L/D-lactide copolymer joint scaffold in MCP joint arthroplasty was evaluated in Studies II-IV. The first study was an open clinical trial (Study II) to investigate short-term biocompatibility and function of PLDLA implants. The third study evaluates clinical and radiological outcomes of PLDLA implants at a mean of 59 months after surgery, a follow-up time which exceeds the resorption time of the implant. The results of the PLDLA implants were compared with those of the conventional Swanson silicone implant in the randomised clinical trial in Study IV.

# REVIEW OF THE LITERATURE

## 1. Rheumatoid arthritis

Natural course of RA is persistent inflammation which leads to destruction of synovial joints. Loss of functional capacity in daily living, work disability, and premature death are severe consequences of untreated RA. The joint involvement in RA appears in a typical distribution, the small joints in the hands and feet being most often symmetrically involved. The majority of patients are positive for rheumafactor (RF) and/or cyclic citrullinated peptide antibody (CCP). Genetic and environmental factors are involved in the pathogenesis, but the initiating cause remains unknown (Isenberg, Maddison, Woo, Glass, & Breedveld, 2004).

The prevalence of RA in Finland is about 0.8%, and incidence about 40/100,000 of the adult population. Mean age at diagnosis has increased, according to the study by Aho and co-workers by 7.6 years from 1975 to 1990 (Kaipiainen-Seppanen, Aho, Isomaki, & Laakso, 1996; Aho, Kaipiainen-Seppanen, Heliovaara, & Klaukka, 1998.) RA affects more women than men: 70% of patients with RA are women.

The multifactorial and still unclear pathogenesis is under active research. Rheumatoid synovial fluid and synovial membrane in diarthroidal joints have been observed to contain a wide variety of activated cell types like neutrophils, dendritic cells, T- and B- lymphocytes and macrophages, which produce a variety of cytokines. The cytokines, the best known being tumour necrosis factor- $\alpha$  (TNF- $\alpha$ ), interleukin-1 and other interleukins, are essential messenger molecules in many phases of the inflammatory process in RA (Harris, 1990; Isenberg et al., 2004).

Chronic synovial inflammation leads in the long term to destructive changes in the joints and periarticular tissues, resulting in pain, stiffness and loss of function. Systemic extra-articular features related to RA include amyloidosis, lymphadenopathy, rheumatoid nodules and vasculitis and may cause morbidity in patients. RA has a wide clinical spectrum, which varies from mild joint symptoms to severe inflammation and damage in multiple joints (Isenberg et al., 2004; Trieb, 2008.) Recent studies show that aggressive treatment with a combination of synthetic disease-modifying antirheumatic drugs (DMARDs) and biologics starting already in the early disease can retard the radiologic progression of the disease (Korpela, Laasonen, Hannonen, Kautiainen, Leirisalo-Repo, Hakala, Paimela, Blafield, Puolakka, & Mottonen, 2004; Kourbeti & Boumpas, 2005; Rantalaiho, Korpela, Laasonen, Kautiainen, Jarvenpaa, Hannonen, Leirisalo-Repo, Blafield, Puolakka, Karjalainen, & Mottonen, 2010) .

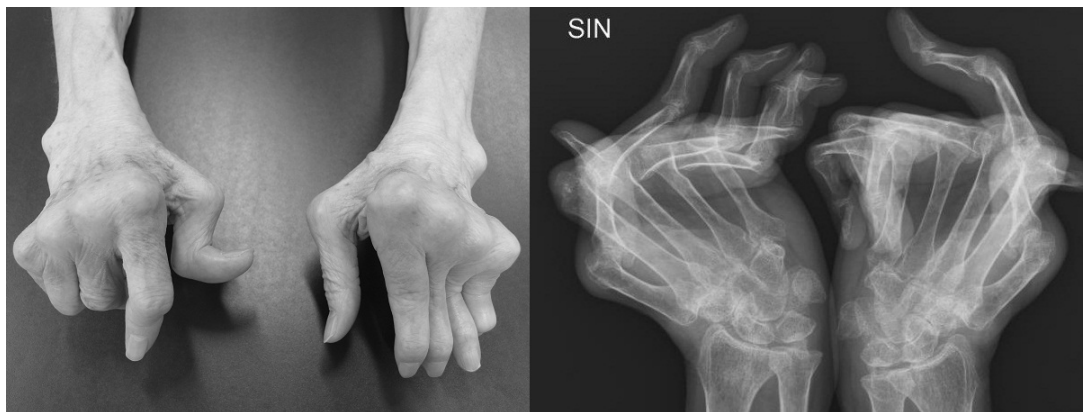The increasing knowledge of the immunopathogenesis of RA has enabled the development of new pharmaceuticals. Transition from sequential monotherapy with DMARDs to a combination DMARD therapy in the 1990's and the licensing of biological therapies in the 2000's together with early initiation of medication have improved outcomes related to many long-term consequences of inflammation such as joint deformity, functional decline, work disability, and premature death (Pincus, Sokka, & Kautiainen, 2005; Puolakka, Kautiainen, Mottonen, Hannonen, Korpela, Hakala, Jarvinen, Ahonen, Forsberg, & Leirisalo-Repo, 2005; Sokka, 2009). Declining needs for total joint replacements and other RA-related surgery has been reported during last decade in Western countries (Weiss, Ehlin, Montgomery, Wick, Stark, & Wretenberg, 2008; Kolling, Herren, Simmen, & Goldhahn, 2009; Louie &

Ward, 2010; Hekmat, Jacobsson, Nilsson, Petersson, Robertsson, Garellick, & Turesson, 2011; Khan & Sokka, 2011).

## 2. Rheumatoid hand

In RA patients the metacarpophalangeal (MCP), proximal interphalangeal (PIP), and wrist joints are involved early and frequently, and arthritic involvement in proximal joints has an influence on the distal joints as well. This involvement is collectively defined as ‘rheumatoid hand disease’ (Straub, 1959; Abboud, Beredjikian, & Bozentka, 2003; Ghattas et al., 2005). Classically the rheumatoid hand deformity is composed of palmar and ulnar subluxations of the wrist, ulnar drift and/or palmar subluxation of the MCP joints and Swan neck or boutonnière deformity of the fingers (D. Stanley & Norris, 1988).

**Figure 1. Clinical and radiological picture of rheumatoid hand**



In patients who were diagnosed RA in the 1970's, before treatment with DMARD combinations and biologics, wrist involvement was reported to affect up to 50% of patients within the first 2 years after the onset of the disease, increasing to >90% after 10 years, and in the majority of the patients this involvement was bilateral (Hamalainen, Kammonen, Lehtimaki, Nurmi, Repo, Ikavalko, Niskanen, & Kaarela, 1992; Trieb, 2008). In the study by Belt and co-workers (1998) assessing radiological destruction in the hand joints 20 years after the diagnosis of seropositive RA destructive changes were more severe proximally and diminished distally, in contrast to osteoarthritis. Rheumatoid hand disease can significantly affect the activities of daily living (ADL), and may be a threat to independence in self-care, thus representing a major problem for RA patients (Ghattas et al., 2005; Pap et al., 2003).

The aggressive treatment strategy to treat patients with RA early with tight control toward remission combined with new medications has improved patients' clinical status and joint destructions have decreased significantly in comparison with previous decades (Pincus et al., 2005; Rantalaiho et al. 2010). Concomitantly with improved medical treatment studies suggesting decreasing tendency of rheumatoid hand surgery have recently been published from Western countries (Weiss et al., 2008; Kolling et al., 2009; Louie & Ward, 2010).

## 2.1 Pathophysiology

The synovial inflammation and formation of pannus tissue causes cartilage and subchondral bone damage and destruction in the joints. The inflammation process and intra-articular pressure stretches the joint capsule and periarticular structures, including ligaments and tendons, causing joint instability and deterioration of the function (D. Stanley & Norris, 1988; Trieb, 2008). The joint laxity induces subluxation, which in association with imbalance of forces leads to progressive joint damage and deformity (J.K. Stanley, 1999).

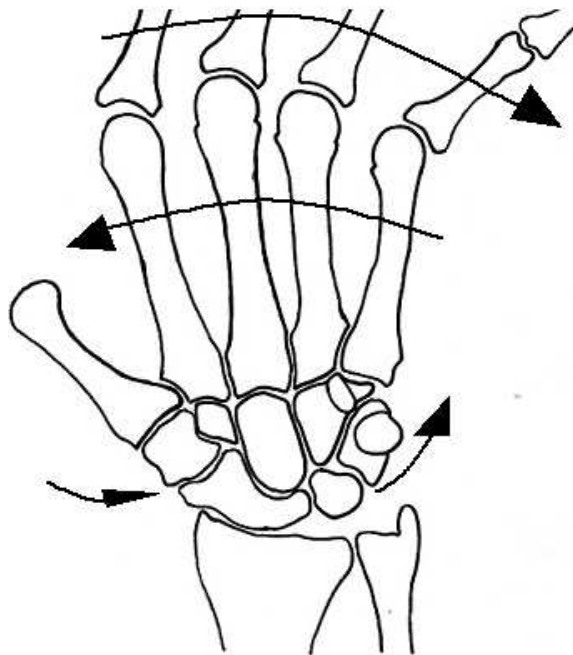
The wrist is the key joint in rheumatoid arthritis of the hand (Taleisnik, 1989; Flury, Herren, & Simmen, 1999). RA can affect the three main joint systems of the wrist: the distal radioulnar joint (DRUJ), the radiocarpal joint and less frequently the midcarpal joint (D. Stanley & Norris, 1988, Tubiana, 1998; Blomqvist, Haglund, Knutson, Lundborg, Marké, Nived, Rydholm, Sollerman, & Svensson, 2000). Inflammatory synovitis and fluid weaken the radiocarpal ligaments leading to a loss of ligamentous support and carpal collapse. The carpal bones translocate in ulnar, proximal and palmar directions, partially due to the palmar and ulnar inclination of the radius. Palmar flexion of the scaphoid often occurs and contributes to the ulnar translocation and radial deviation of the carpus (Linscheid & Dobyns, 1971; Taleisnik, 1989). Synovitis in the DRUJ joint weakens the triangular fibrocartilage complex (TFCC) and leads to sliding of the extensor carpi ulnaris (ECU) tendon in a palmar direction, inducing ulnar translocation and supination of the carpus. The ulnar head is dorsally prominent, called *caput ulnae syndrome*, which at worst can lead to extensor tendon ruptures of the overriding tendons. The cartilage and bony destruction caused by the arthritic process together with the dislocation of the wrist leads to loss of the height of the carpus. All these changes together reduce the effectiveness of the extrinsic finger muscles, crossing the wrist joint (D. Stanley & Norris, 1988; Taleisnik, 1989; Shapiro, 1996; Tubiana, 1998; Arimitsu et al., 2007; Little & Stern, 2007.)

Ulnar drift, malalignment of the knuckle joints, is perhaps the most characteristic manifestation of the rheumatoid hand (Blomqvist et al., 2000). The multifactorial pathophysiology of MCP joints in RA can be divided into three main elements: anatomical causes, causes linked to rheumatoid arthritis pathology and indirect causes (Egloff, 1998). The MCP joints have three planes of motion, extension-flexion, radial-ulnar deviation and axial rotation. The main stabilizers of the MCP joints, radial and ulnar collateral ligaments, are tight only in flexion. This diminishes the inherent stability of these joints (Stirrat, 1996; Feldon, Terrono, Nalebuff, & Millender, 2005). In many hand activities the MCP joints are used not in pure flexion but together with ulnar deviation and rotation (Flatt, 1996). The metacarpal heads display anatomically a slight ulnar slope, and the ulnar collateral ligament has been reported to be stronger than the radial collateral ligament, which both contribute to the ulnar drift (Stirrat, 1996; Egloff, 1998; Abboud et al., 2003; Feldon et al., 2005). The capsular-ligamentous laxity and osteo-cartilaginous destruction of the MCP joints caused by the arthritis are major elements in the pathophysiology of ulnar drift in RA. The weakening of the sagittal bands enables the extensor tendon to migrate in an ulnar direction into the valleys between the metacarpal heads,

which induces an imbalance of the extrinsic tendon forces (Wilson & Carlblom, 1989; Abboud et al., 2003; Little & Stern, 2007). Synovitis also attenuates the flexor tendon sheets, which transfers the pulling forces in a palmar direction. The shift of the position of the tendons steadily increases the aberrant pull on the joint, and the condition becomes self-perpetuating (Flatt, 1996). As the deformity progresses the MCP joints become set in a flexed position as the ulnar intrinsics and abductor digiti minimi muscles gradually tighten (Stirrat, 1996).

In the 1960's Shapiro showed that rheumatic wrist collapse leads to radial deviation of the metacarpals and subsequently to ulnar drift of the MCP joints. Pahle and Raunio (1969) confirmed this observation in a study of fused rheumatoid wrists. A significant positive correlation between the angles of radial deviation of the wrist and ulnar deviation of the fingers was also reported in a study by van Vugt and co-workers (1999).

**Figure 2. Mechanical pathophysiology of an unstable rheumatoid hand**



The question is still if wrist collapse can initiate dislocation of the rheumatoid digits, but at least it is clear that wrist malalignment facilitates the progression of the finger deformities (Taleisnik, 1989).

Swan neck and boutonnière finger deformities arise from an imbalance of very complex, delicately balanced extrinsic and intrinsic tendon systems, and these deformities, although not unique to RA, are initiated by synovitis in RA (Rizio & Belsky, 1996; Feldon et al., 2005). Swan neck deformity, hyperextension at the proximal interphalangeal (PIP) joint with a flexion deformity at the distal interphalangeal (DIP) joint arises from an imbalance originating in the MCP, PIP or DIP joints. Boutonnière deformity, which refers to a PIP joint in a flexion contracture combined with a reciprocal hyperextension of the DIP joint, is induced by synovitis in the PIP joint.

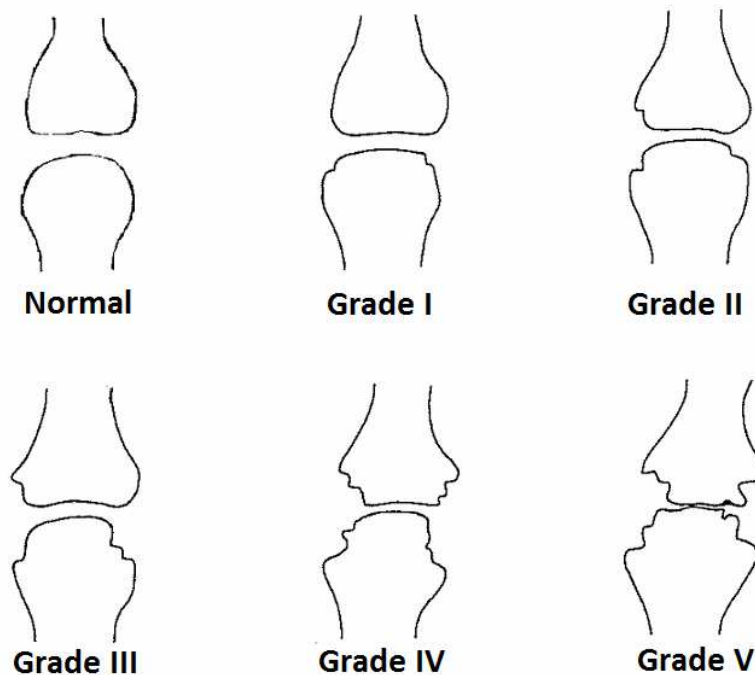


## 2.2 Clinical evaluation

The rheumatoid inflammatory process itself and damage to the joint and periarticular soft tissue cause swelling, pain, stiffness, weakness, motion restrictions and function deficiency in the hand (J. K. Stanley, 1999). In the patient's history symptoms, disease activity, current medication, and previous surgical procedures performed to the elbow, wrist and fingers need to be recorded. The patient-specific difficulties with ADL tasks requiring strength or dexterity give important information. Swelling, tenderness and malalignment in different joints and tendons are examined by inspection and palpation (Shapiro, 1996; Trieb, 2008). In the evaluation of functional deficit, assessments of the range of motion (ROM) in different joints, grip strength, pinch power and separate tendon functions are used. The consequences of the functional deficits in the ADL and quality of life can be quantified using tests simulating ADL tasks and standardized patient self-assessments (Pap et al., 2003; Bjork, Thyberg, Haglund, & Skogh, 2006; Simmen et al., 2008; Trieb, 2008). Dias et al. (2009) described the 'working space of the hand' as a new concept to evaluate rheumatoid hand function. The difference between the flexion and extension volumes is the working space, which takes into account multiple deformities of the hand. The functional disability score was significantly related to changes in the working space as defined in this novel concept (Dias, Smith, Singh, & Ullah, 2009). The physical examination of the wrist and hand need to be bilateral and the elbow and shoulder joints of the ipsilateral side should also be evaluated (Abboud et al., 2003; Trieb, 2008). Tenosynovitis and bone deformities, which may lead to flexor or extensor tendon rupture, should be checked (Abboud et al., 2003). Compressive neuropathies are often overlooked, because sensory disturbances may be regarded as a minor annoyance compared to other RA-related problems (Moran & Bishop, 2007).

Standardised radiographs form the basis for the evaluation of the joint destruction stage and localization in the rheumatoid hand. Radiographs are also the keystone in the evaluation of the progression of joint destruction (Shapiro, 1996). Two radiological scoring methods are commonly used to assess joint damage in RA. In the Sharp method a total of 23 joints in the hands and wrists are scored on a graded scale for erosions and narrowing of the joint space (Sharp, 1989). The widely used Larsen classification including five grades has been applied to different joints, which all have their individual grades (Larsen, Dale, & Eek, 1977; Larsen, 1995).

**Figure 3. Schematic presentation of Larsen grading**



In the evaluation of finger deformities and often in parallel with the radiological classification, a specific clinical staging is used to record the functional capacity (Stirrat, 1996; Abboud et al., 2003). In the evaluation of the wrist the Wrightington classification combines the current radiological findings and reasonable surgical choices at four different stages of the destruction (Hodgson, Stanley, & Muirhead, 1989). On the basis of the radiological long-term analysis of the natural course of the rheumatoid wrist, Simmen and Huber (1992) described rheumatoid wrist involvement according to the type of destruction instead of its extent, their intention being to enable proper selection of surgical treatment modalities at an early stage of the disease. This Schulthess classification distinguishes three types of rheumatoid wrist involvement with different long-term courses of joint destruction. Type 1 (ankylosis) wrists have a tendency to lose motion and may progress to a spontaneous fusion. The ankylosis pattern is typical for juvenile idiopathic arthritis. Type 2 (secondary osteoarthritis) wrists demonstrate an osteoarthritis type destruction with cartilage loss associated with osteophyte formation and capsule shrinkage and sclerosis, which all help to maintain joint stability. Patients with the most common type 3 (destabilization) wrist involvements develop radiocarpal instability on the basis of ulnar and palmar subluxation of the carpus (Simmen & Huber, 1992; Simmen, 1998; Flury et al., 1999). Type 3 deformity often requires early osseous stabilization to prevent disintegration and disability (Flury et al., 1999). Specific radiographic parameters such as carpal height ratio (CHR), ulnar translocation and scapholunate dissociation have been reported to correlate with the Schulthess classification, contributing to the grading of the wrist into one of these three types (Flury et al., 1999). The weaknesses of the Schulthess classification are inadequate reproducibility (interobserver agreement) and a large number of cases in which the damage in radiographs is insufficient to reveal a type. However, it provides reliable identification of wrists that are at a risk of becoming severely unstable (Zangger, Kachura, & Bogoch, 1999).

## 2.3 Surgical treatment

RA is a systemic disease affecting also extra-articular tissues, and its natural course is progressive and incurable (J. K. Stanley, 1998). RA disease progression has effectively been slowed by modern therapeutic drugs and active treatment strategies aiming at remission, and rates of RA-related surgery have reported to decrease during last years (Kolling et al., 2009; Louie & Ward, 2010; Hekmat et al., 2011). Not all patients with RA need rheumatic surgery during their lifetime, but of those who require surgical treatment many need several operations (Blomqvist et al., 2000). The assessment of the need of a rheumatic patient for surgical treatment and the advantages, disadvantages and the sequence and timing of various surgical procedures are best performed by a specialized team, consisting of a rheumatologist, an orthopaedic and/or hand surgeon experienced in surgery for patients with RA, an occupational therapist, a physiotherapist and a social worker (Souter, Sheffield, McGullough, Meggitt, & Swann, 2002; Simmen et al., 2008).

### 2.3.1 Indications

There are many options for surgical intervention in the rheumatoid hand, but they all share common goals aiming to relieve pain, restore function and quality of life, interrupt the mechanisms responsible for the joint destruction, correct deformities, improve appearance and in some cases provide prophylaxis against further destruction (Simmen et al., 2008; Trieb, 2008). The surgical procedures are often performed on multiple interactive indications. Pain and impaired hand function are common indications for rheumatoid hand surgery (Blomqvist et al., 2000). Tendon rupture - or imminent risk thereof - should be an absolute indication for surgical intervention. The causes of the rupture, synovitis and mechanical compression, are direct risk factors for the rupture of the adjacent tendons. Synovitis stretches the supporting ligaments around the joint and leads to joint instability and finger deformities, hence if synovitis persists for 3–6 months despite optimal medical treatment, surgical treatment should be considered (Chung & Kotsis, 2010). The natural course of the disease of the joints involved should be taken into account in the determination of the indications for surgery and in the selection of surgical methods (Blomqvist et al., 2000; Simmen et al., 2008). The indications for surgery are strengthened if both hands are involved and in cases where improved hand function will permit the use of a cane for ambulation (Bogoch & Judd, 2002).

In the study by Chung and co-workers (2006) the variable most significantly associated with the willingness of RA patients to choose MCP joint arthroplasty was decreased hand function, followed by pain. Hand aesthetics was not a statistically significant predictor, but the authors concluded that patients may be reluctant to admit that they are seeking hand surgery primarily to improve the appearance of their hands. Improvement in hand appearance after MCP arthroplasty has been reported to correlate strongly with overall patient satisfaction (Bogoch & Judd,

2002; Mandl, Galvin, Bosch, George, Simmons, Axt, Fossel, & Katz, 2002). Rheumatoid hand deformities are often easily noticeable because the hands are not generally covered by any garment, thus the aesthetics needs to be evaluated as one of the indications for operative treatment. The eventual complications following surgery or the consequences of doing nothing, for example in a flail wrist with persistent synovitis, are weighed and discussed with the patient when considering surgical treatment of the rheumatoid hand (Trieb, 2008).

### 2.3.2 General principles

Surgical planning for patients with a systemic and chronic disease needs to include a holistic assessment of the patient. There is wide variation in the activity level of the RA patients. Patient needs in professional and social functions differ; someone prefers stability and strength of the hands, whereas another needs mobility of the hands. Rheumatoid involvement of the elbow or shoulder may significantly affect the overall success of the hand surgery. An eventual walking aid needs to be taken into account when a surgical method is chosen. The rheumatoid hand is assessed bilaterally in detail as an entity, and the surgical treatment is planned with an appreciation of the natural history of the disease and the pathophysiology of the deformities. One important principle is that even advanced deformities with architectural disorganization of multiple joints do not by themselves constitute an indication for surgery, because many patients maintain good hand function in spite of significant deformities. Progression of the disease and deformity in a specific joint should be taken into consideration when establishing an orthopaedic intervention protocol in order to achieve maximal patient benefit. Reconstructive operations should be performed before the development of severe loss of tissue and incurable disability (Souter, 1979; J. K. Stanley, 1998; Feldon et al., 2005; Simmen et al., 2008; Toyohara, Ishikawa, Abe, Nakazono, & Murasawa, 2009.)

The concept “start with a winner” stated by the eminent rheumasurgeon William Souter, i.e. to perform the most beneficial and easily rehabilitated procedure first, is a valuable approach when surgical interventions are planned, particularly when multiple joints are damaged and symptomatic, as it facilitates patient’s acceptance and cooperation (Souter, 1979; O’Brien, 1996; Blomqvist et al., 2000). The deformities in the proximal joints are corrected before distal articulations, with the exception of urgent surgery performed for nerve compression and impending tendon rupture. The malalignment in the wrist has to be treated before MCP joint arthroplasties are performed (D. Stanley & Norris, 1988; J. K. Stanley, 1999; Burke, 2011). The maximum extent of surgery in one session is tailored according to the general health of the patient and according to the duration of the tourniquet application. Stabilizing operations and mobilizing operations have to be performed in different sessions to facilitate postoperative rehabilitation (J. K. Stanley, 1992; Abboud et al., 2003; Little & Stern, 2007; Trieb, 2008.)

A patient suffering from RA should also be carefully assessed preoperatively from the anaesthesiological point of view. The systemic extra-articular manifestations of RA and medication may cause kidney and/or liver failure. Occipito-atlanto-axial and subaxial cervical spine instability should be evaluated prior to anaesthesia to protect it during induction and the patient should be placed in

the proper surgical position. Cricoarytenoid and other laryngeal joints may be affected by RA. Dermal tissue is often atrophic and special care should be taken not to damage it (Abboud et al., 2003; Trieb, 2008)

### 2.3.3 Methods

The use of pure synovectomy or tenosynovectomy has decreased with the introduction of effective disease modifying therapies, but persistent symptomatic synovitis without articular surface destruction resistant to modern pharmacotherapy remains a valid indication for synovectomy operation. The synovectomy relieves pain and swelling, but there is no evidence available indicating that it reduces the antigen load or immune inflammation or alters the radiological disease progression in the longterm. Tenosynovectomy is used to prevent tendon ruptures and as a method to increase mobility, but the documentation on its prophylactic effects is weak (Simmen et al., 2008.) In the randomized clinical trial (RCT) performed by Nakamura and co-workers (2000) a radical multiple synovectomy was reported to have an anti-rheumatic effect by itself. Simultaneous synovectomies were performed on as many joints as possible in RA patients who did not respond to intensive conventional medical treatment, including combinations of methotrexate, sulphasalazine, bucillamine and corticosteroids. At a minimum follow-up of three years significantly more patients in the synovectomy treatment group were in clinical remission according to the ACR (American College of Rheumatology) criteria than in the group treated without surgery, but no differences were seen in the radiological deterioration. Synovectomy is always performed together with any surgical joint interventions in rheumatoid hand surgery as an additional procedure (Blomqvist et al., 2000; Simmen et al., 2008; Chung & Kotsis, 2010.)

Soft-tissue balancing surgery is used to treat typical rheumatoid hand deformities; ulnar drift, shoemaker's thumb, boutonnière deformity and swan-neck deformity when the joint is still radiologically well preserved. These deformities can be counteracted or corrected by various tendon transfer procedures, the release of tight ligaments or shortening of stretched ligaments (Blomqvist et al., 2000). Despite a trend towards improved functional outcomes reported in a systematic literature review, irrefutable evidence to support a long-term functional benefit of these procedures in RA patients is still lacking (Ghaffas et al., 2005). Nervus medianus entrapment in the carpal canal is common in rheumatoid hand due to the synovitis of the flexor tendons, which increases the pressure in the canal. In the operation meticulous tenosynovectomy is performed in addition to the discision of the transverse ligament. Tendon ruptures, more common in extensors, are reconstructed by suturing the end of the ruptured tendon to an adjacent tendon, using tendon transfer procedures, or in multiple tendon ruptures using free tendon grafts. The treatment of tendon ruptures is usually combined with the resection of the ulnar head and with arthrodesis or arthroplasty surgery to eliminate the articular cause of the tendon rupture (Moran & Bishop, 2007; Simmen et al., 2008; Chung & Kotsis, 2010.)

In the joints with cartilage or bone destruction either arthrodesis or arthroplasty are the surgical options. Arthrodesis is preferred in the joints in which stability is more important than mobility, and when painlessness is highly valued. The wrist,

DIP joints, MCP and IP joints of the thumb are typically fused in the rheumatoid hand (Blomqvist et al., 2000). Total wrist arthrodesis is a well-established, safe and reliable method for patients with advanced arthritic changes. In the early stages of RA, partial wrist arthrodesis preserves a significant range of motion but also enables stabilisation of the wrist (Trieb, 2008). The variable and often poor bone quality in RA should be taken into account when the fixation method is selected for arthrodesis surgery. Arthrodesis is sometimes the only possible treatment option in the most advanced destructions including notable malalignment with major bone defects (Blomqvist et al., 2000).

In rheumatoid hand destroyed joints can be replaced with artificial joints (arthroplasty with endoprosthesis) or endogenous tissues (interposition arthroplasty), such as tendon, ligaments or connective tissue. In MCP joints one-piece silicone implant arthroplasty has been widely used and is well documented in RA patients, but deterioration of the results initially achieved over time is commonly reported (Goldfarb & Dovan, 2006). Problems associated with rheumatoid hand arthroplasties are the accurate placement of the physiologic centre of rotation of a joint, fixation of the prosthesis to bone and imbalance in the soft tissue with a tendency for malalignment in the joint (Blomqvist et al., 2000). Prosthetic development in small joint arthroplasties is an ongoing process, and issues such as biocompatibility, ease of implantation and stability must be taken into consideration (Linscheid, 2000). Long-term problems requiring revision surgery after a primary wrist arthroplasty are still common (Ghattas et al., 2005; Trieb, 2008). In the review article by Cavaliere and Chung (2008) the authors concluded that hand function after wrist arthroplasty may not be significantly better than after an arthrodesis, and that current evidence does not support the widespread implementation of wrist arthroplasty in RA. In the PIP joints, the inherent lack of ligament support as well as tendon imbalances in RA make the arthroplasty procedure an unsure option (Chung & Kotsis, 2010).

The reliable evaluation of new surgical methods requires extensive clinical trials involving large numbers of patients, and the evaluation of these new methods in RA patients (as distinguished from the much larger and homogenous osteoarthritis patient population) is an ongoing challenge (Simmen et al., 2008). However, patients should be informed of the options available in surgical treatment by surgeons specialised in rheumasurgery (Chung & Kotsis, 2010).

### 3. Radiocarpal partial wrist arthrodesis in rheumatoid hand surgery

#### 3.1 Pathophysiological and kinematic basis

RA of the wrist typically begins in the radiocarpal joint, preserving the midcarpal joint (J. K. Stanley & Boot, 1989). The radiocarpal joint is anatomically less stable than the midcarpal joint and more susceptible to instability caused by the disease process (Ishikawa et al., 2005). It was reported that there were no further subluxations and that the functional range of motion was maintained after a

spontaneous radiolunate fusion in RA. This gave rise to the idea of a new surgical method to stabilise the rheumatoid wrist (Linscheid & Dobyns, 1971; Chamay, Della Santa, & Vilaseca, 1983). The instability problems often occurring in the carpus after the commonly used distal ulnar head resection likewise stimulated interest in partial wrist arthrodesis operation. Chamay was the first to report a radiolunate fusion procedure for the rheumatoid wrist (Chamay et al., 1983). Compared to the most frequently used operation in rheumatoid wrist surgery, total arthrodesis, the range of motion preserved after a partial radiocarpal arthrodesis is an obvious advantage.

The functional motion in the wrist necessary for most ADL is from 10° of flexion to 35° of extension (Brumfield & Champoux, 1984; Palmer, Werner, Murphy, & Glisson, 1985). The combination of radial deviation and extension with ulnar deviation and flexion (the dart thrower's motion) has been described as the dominant motion arc for many occupational activities (Li, Kuxhaus, Fisk, & Christophel, 2005; Rohde, Crisco, & Wolfe, 2010). Relevant in this context, the scaphoid and lunate motion is minimal throughout the dart thrower's motion arc (Werner, Green, Short, & Masaoka, 2004). Yayama *et al.* (2007) reported that disturbed coupling of flexion-extension and radio-ulnar deviation results in difficulties in the cooperative movements and have a great influence on daily activities in the RA wrist joint (Yayama, Kobayashi, Kokubo, Inukai, Mizukami, Kubota, Ishikawa, Baba, & Minami, 2007). In unstable rheumatoid wrists the congruity in the midcarpal joint is generally well preserved and the contribution of the midcarpal motion has been shown to be 2/3 relative to the total wrist motion (Arimitsu et al., 2007; Arimitsu, Sugamoto, Hashimoto, Murase, Yoshikawa, & Moritomo, 2008).

### 3.2 Indications

Partial radiocarpal arthrodesis is indicated in the rheumatoid wrist with pain and/or chronic synovitis in spite of conservative treatment. The midcarpal joint has to be relatively well preserved (Chamay & Della Santa, 1991; Ishikawa, Hanyu, Saito, & Takahashi, 1992). In RA radiocarpal arthrodesis has been used in unstable wrist destruction with an ulnar translocation and/or a palmar subluxation of the carpus. Theoretically, surgical stabilisation and correction of the malalignment in the carpus may also prevent or delay the development of the ulnar drift of the fingers (Doets & Raven, 1999; Herren & Ishikawa, 2005).

### 3.3 Surgical technique

Radiocarpal arthrodesis and radioulnar arthrodesis are the most commonly used methods of limited arthrodeses in rheumatoid wrist due to early arthritic destruction of both radiocarpal and radioulnar joints, which is combined with a tendency to develop instability in the radiocarpal joint (J. K. Stanley & Boot, 1989; Arimitsu et

al., 2008). The other partial arthrodesis techniques described in the literature are rarely used in the rheumatoid hand. The isolated radiolunate (RL) arthrodesis enables the stabilisation and repositioning of the carpus, but if there is an adjoining destruction of the radioscaphoid joint, the scaphoid is added to the fusion (radioscapholunate or RSL arthrodesis) (Ishikawa et al., 1992; Herren & Ishikawa, 2005).

A dorsal straight skin incision is the most widely used surgical approach (J. K. Stanley & Boot, 1989; Chamay & Della Santa, 1991; Herren & Ishikawa, 2005), but an oblique exposure has also been described (Ishikawa et al., 1992). The extensor retinaculum is opened longitudinally at the sixth compartment and raised as a radially-based flap, opening the extensor compartments. The synovectomy of the extensor tendons is performed routinely, and usually the terminal branch of the posterior interosseus nerve is resected. The ulnar head resection is typically combined with radiocarpal arthrodesis.

Preparation of the surfaces of the lunate fossa of the radius and proximal lunate in the RL arthrodesis, and also of the surfaces of the scaphoid fossa of the radius and proximal scaphoid bone in the RSL arthrodesis is done to the level of the subchondral cancellous bone. This enables the consolidation of the arthrodesis. The aim is to reposition the lunate to a neutral and as physiological position as possible (Linscheid & Dobyns, 1985; J. K. Stanley & Boot, 1989; Chamay & Della Santa, 1991; Herren & Ishikawa, 2005; Ishikawa et al., 2005). In advanced cases, with fixed carpal collapse, Borisch and Haussmann (2002) reported that anatomical repositioning of the lunate leads to midcarpal dislocation and precipitates a secondary osteoarthritis, however neutral positioning of bones in the dorsovolar dimension was recommended. Bone grafting of the resected ulnar head is often needed for a good repositioning and to fill the gap between the lunate and radius and, in RSL arthrodesis, also between the scaphoid and radius. A slight distraction of the lunate seems to enable more free rotation to the scaphoid and slightly better postoperative ROM (Linscheid & Dobyns, 1985; Masuko et al., 2009). The reduction is temporarily maintained with K-wires and repositioning is checked using fluoroscopy. Staples, screws, miniplates, K-wires or sliding graft of the radius can be used for final fixation. Gaulke and co-workers (2010) reported a high rate of radiological complications of staple fixation in the RL fusion. The capsule and retinaculum are closed to stabilise the ulnar stump. The retinaculum is divided and one part is sutured above the extensors to prevent a bowstring phenomenon.

A short arm cast or splint is applied for 6-8 weeks. After signs of consolidation in the radiographies, mobilisation of the wrist can be started. Usually mobilisation is started six weeks after the operation, but has been started already 2 weeks postoperatively when plate fixation was used (J. K. Stanley & Boot, 1989) or only after 12 weeks when fixation with K-wire was used (Linscheid & Dobyns, 1985).



## 3.4 Outcome

### 3.4.1 Clinical outcome

Pain alleviation is successfully achieved with radiocarpal arthrodesis. Some pain alleviation may result from simultaneous synovectomy, ulnar head resection and resection of the posterior interosseus nerve, which are typically combined with radiocarpal arthrodesis (Borisch & Haussmann, 2002; Masuko et al., 2009). The progression of arthritis, secondary osteoarthritis in the midcarpal joint and hardware displacement are the main reasons for pain after surgery. Subjective satisfaction is excellent or good after radiocarpal arthrodesis from 74% to 87% of cases (Linscheid & Dobyns, 1985; J. K. Stanley & Boot, 1989; Chamay & Della Santa, 1991; Gaulke et al., 2010).

The ROM of the wrist maintained after radiocarpal arthrodesis varies widely between studies. A decrease of wrist motion in all directions, but significantly only for wrist flexion, has been reported in many studies. In contrast to other publications Doets and Raven (1999) reported a postoperative increase in mobility in all directions with the exception of wrist flexion. The extension-flexion motion ranges from 36° to 70° after radiocarpal arthrodesis, representing 56 – 93% of the preoperative arc of motion. ROM in the great majority of operated cases is within a satisfactory and functional range (Masuko et al., 2009). In the study by Doets and Raven (1999) the postoperative extension-flexion ROM was 74°, being two degrees more than preoperatively. After RL fusion the range of motion is wider and better preserved than after RSL fusion (Meyerdierks, Mosher, & Werner, 1987; Ishikawa et al., 2005). Borisch and Haussmann (2002) reported that the reduction in the wrist movement was not dependent on the preoperative mobility of the wrist, but the postoperative mobility was lower in Larsen Grade IV wrists than in Larsen grade III wrists. The mobility of RL arthrodesis has been reported to be better in RA than in trauma patients or in cadaver studies, probably due to the laxity of the ligamentous structures in RA (Watson, Goodman, & Johnson, 1981; Meyerdierks et al., 1987; Chamay & Della Santa, 1991). Supination and pronation of the forearm increase in most cases because of the resection of the distal ulna.

Grip power improves modestly after radiocarpal arthrodesis (Linscheid & Dobyns, 1985; J. K. Stanley & Boot, 1989; Chamay & Della Santa, 1991; Ishikawa et al., 1992; Ishikawa et al., 2005; Masuko et al., 2009) but alteration of hand function has been reported only in two publications, in which the evaluations were performed using questionnaires. Amelioration was observed in 60 – 67% of patients (J. K. Stanley & Boot, 1989; Gaulke et al., 2010).

Some wrists become totally fused after radiocarpal arthrodesis. In the study by Ishikawa et al. (2005) 12% of wrists had evolved into total fusion at the mean follow-up of three years. If further spontaneous arthrodesis occurs, the wrist remains in a functional position (Linscheid & Dobyns, 1985; Ishikawa et al., 1992). Surgical conversion to total arthrodesis was performed in 8-9% after radiocarpal arthrodesis due to progressive midcarpal destruction or recurrence of painful synovitis (Doets & Raven, 1999; Borisch & Haussmann, 2002).

**Table 1.** Summary of studies evaluating outcome of partial radiocarpal wrist arthrodesis in rheumatoid hand surgery

Study	Type <sup>1</sup>	Wrists (n)	Follow-up (months)	Pain <sup>2</sup>	Subjective satisfaction <sup>2</sup>	ROM post (pre) <sup>3</sup>	Grip power post (pre)	Midcarpal destruction <sup>4</sup>	Total fusion reoperation (n)
Stanley and Boot (1989)	pros	16	24	13 painless	12 excellent or good	52 (56)	3.2 (2.5) lbs	12 (75%)	
Chamay and Della Santa (1991)	retro	21	49	13 painless	11 entirely satisfied	69 (-)			1
Ishikawa et al. (1992)	pros	25	36	21 painless		36 (64)	114 (80) mmHg	12 (48%)	
Doets and Raven (1999)	pros	39	60	VAS 8.3	VAS 9	74 (72)			4
Borisch and Haussmann (2002)	retro	91	60	48 painless	88 same operation again	46 (74)		66 (72%)	6
Ishikawa et al. (2005)	retro	25	156	22 painless		35 (54)	141 (100) mmHg	9 (36%)	0
Gaulke et al. (2009)	pros	20	19	14 painless	18 very good or good	43 (108)	0.28 (0.17) bar		
Masuko et al. (2009)	retro	12	69	12 none or mild	12 excellent or good	68 (88)	17.8 (12.0) kg	2 (17%)	0
Gaulke et al. (2010)	retro	22	60	13 painless	18 excellency or good	70 (-)		2	

<sup>1</sup> prospective or retrospective study

<sup>2</sup> VAS 10 indicates no pain or fully satisfied

<sup>3</sup> range of motion, post = at follow-up, pre = preoperatively

<sup>4</sup> number and proportion of the joints in which some midcarpal changes were evaluated at follow-up compared to preoperative x-rays

The most common complication after radiocarpal arthrodesis is primary intra-articular displacement of the fixation material (Linscheid & Dobyns, 1985; Ishikawa et al., 2005). In the study by Borisch and Haussmann (2002) with a larger patient population malposition of fixation material was observed in 4% of cases. Occurrences as high as 31% and 41% of malposition of fixation material have been reported, and the use of intraoperative radiologic control has been recommended (Doets & Raven, 1999) while some surgeons have changed from staples to miniplates (Gaulke et al., 2010).

### 3.4.2 Radiological outcome

Radiocarpal arthrodesis prevents dislocation of an unstable rheumatoid wrist (Della Santa & Chamay, 1995), and non-union rates are low, on average 4 - 6% (Linscheid & Dobyns, 1985; J. K. Stanley & Boot, 1989; Chamay & Della Santa, 1991; Ishikawa et al., 1992; Borisch & Haussmann, 2002). Redislocation and bony fusion in an undesirable position are more frequent concerns (Gaulke et al., 2010). Particular index measurements are made from radiographs to evaluate the position of the carpus. Carpal height improves after surgery because of the repositioning of the carpal bones and bone grafting, but reverts near to the preoperative level over time (Della Santa & Chamay, 1995; Ishikawa et al., 2005). The deterioration in carpal height has been found to be similar after RL arthrodesis as in non-operated contralateral wrists, which may reflect the effects of the rheumatoid disease itself (Della Santa & Chamay, 1995). Ulnar translocation often improves after radiocarpal arthrodesis (Della Santa & Chamay, 1995), and has been reported to remain unchanged in 10-year follow-up (Linscheid & Dobyns, 1985; Doets & Raven, 1999; Borisch & Haussmann, 2002; Ishikawa et al., 2005). However, in the study by Doets and Raven (1999) slow but significant deterioration in ulnar translocation was reported after the RL arthrodesis.

The midcarpal joint changes after radiocarpal arthrodesis have been reported to develop in as many as half of the cases in studies with over five-year follow-up. In the study by Ishikawa et al. (2005) widening of the lunocapitate joint space (>2 mm), was observed in 16% of wrists, and narrowing (<1 mm) in 20% at mean 13-year follow-up. In 12% of cases the wrist joint was totally fused. However, in 64% of the wrists the midcarpal joint was well preserved. Borisch and Haussmann (2002) reported arthritic changes in 37% of wrists, and osteoarthritic changes in 35% of wrists at mean 60-month follow-up. In their study an exceptionally high proportion (44%) of the wrists was further destroyed (Larsen IV), and they observed lesser destruction in the midcarpal joint in early stage disease. Most patients remain asymptomatic despite midcarpal deterioration, probably because of a better intrinsic stability in the midcarpal than in the radiocarpal joint (J. K. Stanley & Boot, 1989; Ishikawa et al., 1992; Doets & Raven, 1999).

## 4. MCP arthroplasty in rheumatoid hand surgery

### 4.1 Indications

The indication for MCP joint arthroplasty in RA is radiographic joint destruction accompanied by pain or functional impairment. The improvement in the appearance of the hand is also highly valued by patients (Mandl et al., 2002; Massy-Westropp, Massy-Westropp, Rankin, & Krishnan, 2003; Chung, Kotsis, & Kim, 2004; Goldfarb & Dovan, 2006). A typical functional impairment arises from palmar subluxation and ulnar deviation of the MCP joints causing loss of extension and difficulties to grasp, especially large objects. Pain in the MCP joints may itself inhibit hand function. Joint replacement surgery in MCP joints is used in advanced stages, and in many patients all four MCP joints are replaced simultaneously. Some patients adapt well to major deformities, at least partially because of the slow progression, and if the function is sufficient for the patient's needs, surgery is not indicated. Progressive bone destruction and the feasibility of soft tissue balancing should, however, be considered in the timing of MCP surgery (Goldfarb & Dovan, 2006).

### 4.2 Methods

#### 4.2.1 Development of the implants

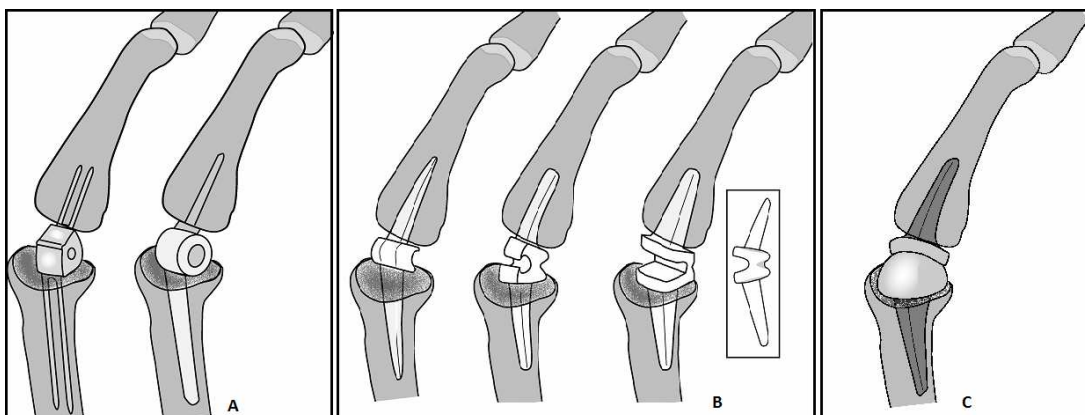
Reconstructive surgery in rheumatoid MCP joints was started with simple joint resections (Ruther, Verhestraeten, Fink, & Tillmann, 1995). Many autoarthroplasty techniques using the patient's own tissue as an interposition material were described before implant arthroplasty was developed. In Vainio resection arthroplasty an extensor tendon is interposed and fixed into the volar plate (Vainio et al., 1967). Tupper's method uses a volar plate as an interposition (Tupper, 1989). Simple joint resection surgery and soft tissue interposition arthroplasties have been reported to cause problems due to limited motion, lack of stability and recurrent deformity, and nowadays the use of these techniques is relatively rare (Ruther et al., 1995; Gotze & Jensen, 2000).

The development of hand joint implants has not advanced as favourably as the development of hip and knee joint prostheses. The small sizes of the joints, their participation in delicate kinetic chains and their complex soft tissue investments in relationships to adjacent rays are challenges for joint replacement surgery in the hand. Inflammatory attenuation of supporting soft tissue and osteoporotic bone with varying degrees of bone erosions impose additional needs for proper implant stability and fixation in rheumatoid hands, and RA is by far the most important

indication for MCP joint replacement (Linscheid, 2000; W. L. Parker, Rizzo, Moran, Hormel, & Beckenbaugh, 2007). The aims for the development of MCP joint implants are restoration of a functional range of motion, adequate stability, biologic compatibility, adequate material wear and strength characteristics, provision for easy implantation and allowance for soft tissue reconstruction. A proper implant also enables revision surgery without major bone loss and tissue damage (Linscheid, 2000).

Many prosthetic designs have been introduced into MCP joint replacement over the last 50 years. These can be grouped into one of three basic designs: the hinged prosthesis, the flexible prosthesis, and the third-generation resurfacing prosthesis (Merolli, 2009). The earliest implants were hinged metallic prostheses, which had a high failure rate and are no longer in use. Polyethylene was introduced as a bearing material to reduce friction, and it often replaced at least one stem. Cemented implants were implemented to ensure implant fixation, but due to high failure rates and laborious operating technique they were withdrawn from the market (Wilson & Carlblom, 1989). Flexible prostheses, which were manufactured of silicone rubber alone or combined with Dacron, were introduced in the 1960's. The one-piece implant of silicone elastomer developed by A.B. Swanson in 1964 is still the gold standard in MCP joint replacement surgery in RA patients. Development work on prostheses aiming to restore the normal joint anatomy has been continued. Designs which aim to reproduce the anatomical centre of rotation and to fit better into the phalangeal and metacarpal bone canals have been introduced. The third-generation resurfacing prostheses comprise surface replacement prostheses and devices that represent a hybrid of hinged and flexible prostheses (Joyce, 2004; W. Parker, Moran, Hormel, Rizzo, & Beckenbaugh, 2006). Numerous third-generation devices have been produced and implanted but now appear to be no longer in use; implant fractures and dislocations, bone loss, recurrence of ulnar drift and decreasing hand function over time have been reported as consequences of their use. Implantation techniques have also been found too demanding to reproduce consistently good results (Beevers & Seedhom, 1995; Cook, Beckenbaugh, Redondo, Popich, Klawitter, & Linscheid, 1999; Linscheid, 2000).

**Figure 4. History and development of MCP joint prostheses. (A) hinged implants, (B) flexible designs and (C) resurfacing prosthesis**



The pyrolytic carbon implant is the best documented surface replacement prosthesis for the MCP joints. Pyrolytic carbon coating is wear-resistant and chemically stable, and has an elastic modulus similar to that of cortical bone. The elastic component dampens stresses at the bone prosthetic interface and enhances biological fixation (Cook et al., 1999). The two-piece non-constrained implant allows for preservation of the collateral ligaments and requires only minimal joint resection, but the disadvantages are the risk of subluxation and dislocation, especially when the surrounding soft tissues are loose or damaged. A non-constrained prosthesis requires a very precise placement of the device and adequate sizing to ensure a proper soft-tissue balancing (Goldfarb & Dovan, 2006; W. Parker et al., 2006). A long-term study reporting minimum 10-year follow-up shows good results, with 5- and 10-year survival rates at 82% and 81% respectively; however, patients treated in this series had only minor preoperative deformities, subluxations or dislocations of the MCP joints (Cook et al., 1999). Parker et al. (2007) reported increased radiolucent seam around the pyrolytic carbon implants in 95% of RA cases with a longer than 1-year follow-up.


Designs of the MCP prosthesis matching the anatomy of the natural joint more closely have been produced and tried but have not yet demonstrated long-term clinical success in cases of severe RA, although slightly better results have been achieved in OA. RA of the MCP joint poses a severe and ongoing challenge to any prosthesis implanted (Joyce, 2004; Goldfarb & Dovan, 2006).

#### 4.2.2 Silicone implant arthroplasty

For several decades the one-piece silicone implant designed by Swanson has remained the joint replacement of choice for the MCP joints. According to the data in the Norwegian Arthroplasty Register 1,400 Swanson prostheses were implanted out of a total of 2,154 MCP prostheses over the period 1994 to 2002 (Joyce, 2004). In the USA the Swanson implant has been reported to have about 75% of the market for implants for use in the RA hand (Chung et al., 2004). Later developments in the Swanson prosthesis have been alterations in the composition of the silicone polymer to provide better resistance to tear propagation and metal grommets at the stem-hub junction to protect the implant from abrasion and prevent erosions at the bone ends. The high-performance (HP) elastomer was developed in 1974, and since 1986 Swanson prostheses have been manufactured of HP-100 silicone elastomer (Swanson, Poitevin, de Groot Swanson, & Kearney, 1986; Linscheid, 2000; Joyce, 2004). The change of silicone material has had a positive effect on fracture rates, but the benefit of the grommets has not been clinically confirmed and they are not widely used (Beevers & Seedhom, 1995; Schmidt, Willburger, Ossowski, & Miehle, 1999; Joyce, 2004).

The Swanson prosthesis has a spacer located in the joint level with two adjoining stems attached to it and to be implanted to the proximal and distal intramedullar canals. A wide, convex dorsal arch in the hinge area holds the bone ends apart and favours motion in the flexion plane.

**Figure 5. Swanson silicone MCP joint prosthesis ap and lateral view**



The stems act like pistons within the bone to permit more motion, and they also help to maintain alignment during the encapsulation process in the early phase after implantation. The development of a proper capsule is extremely important for the outcome, especially for the stability of the joint (Swanson, 1997). The formation of a functional and stable fibrous capsule requires the initiation of early motion using sophisticated and lengthy postoperative orthoses (Egloff, 1998; Goldfarb & Dovan, 2006).

The Swanson prosthesis has been reported to flex at the hinge after a flexion angle of  $45^\circ$  has been passed, but below that the implant flexes at the stem-hinge interface (Beevers & Seedhom, 1995). Modifications of the Swanson implant have been developed to improve the biomechanics and to reduce force transfer into the implant (Joyce, 2004; Escott, Ronald, Judd, & Bogoch, 2010). In the Sutter prosthesis introduced in 1987 (nowadays called Avanta) a similar silicone polymer (Silastic) is used and the stems have the same shape, but the axis of rotation has been placed more palmarly to facilitate extension by increasing the extensor moment arm. The hinge is enlarged and between the stems and hinge area is a sharp angled border to reduce the risk of palmar bony impingement (Bass, Stern, & Nairus, 1996). The NeuFlex prosthesis introduced in 1998 has a preflexed  $30^\circ$  angle in the hinge and the centre of the rotation is located palmarly with respect to the longitudinal axis of the implant. The idea of the design is to simulate the relaxed position of the hand, to offer better ROM by increasing flexion and to reduce pistoning of the stems (Delaney, Trail, & Nuttall, 2005). All silicone implants have a tendency to fracture in or near the centrepiece of the hinge element, and they have been considered unsuitable for younger patients who apply greater forces and place higher demands on their implants (Linscheid, 2000; Joyce, 2004). Expectancy of outcome and demands on loading of the MCP joint implants have increased among RA patients with more active lifestyle as a consequence of improved medication, and the search for improved MCP implants will continue (Joyce, 2004; Goldfarb & Dovan, 2006).

### 4.2.3 Soft tissue balancing

In the RA hand there are often disturbances throughout the entire kinetic chain from the wrist to the distal interphalangeal joint. This, combined with the suboptimal properties of the available MCP implants, necessitates a careful approach to soft tissue reconstruction in MCP joint replacement surgery. Release of a contracted ulnar collateral ligament and volar capsule are routinely performed and many also release ulnar intrinsic muscles, including the abductor digiti minimi. Some surgeons prefer to save the ulnar intrinsic muscle of the index finger in order to preserve the function of the first palmar interosseus muscle in pinch grip (Stirrat, 1996; Abboud et al., 2003). After the bone resection and the release of the contracted soft tissues, it should be possible to displace the proximal phalanx onto the dorsum of the metacarpal (Wilson & Carlblom, 1989; Goldfarb & Dovan, 2006).

The radial collateral ligament may be tightened by duplicating it or by proximal re-attachment through a drill hole to the metacarpal bone. Many surgeons perform this for all joints if needed, but some prefer to do it only in the index finger (Delaney et al., 2005; Moller, Sollerman, Geijer, Kopylov, & Tagil, 2005; Pettersson, Wagnsjo, & Hulin, 2006). If the collateral ligament is severely attenuated, a radial reconstruction can be done with the volar capsule and half of the volar plate, which are attached to the origin of the collateral ligament (Stirrat, 1996; Sunil & Kleinert, 2006). In cases with major erosions on the phalangeal bones the distal insertion of the radial collateral ligament has to be checked and reconstruction is performed if needed (Wilson & Carlblom, 1989). Reinsertion of both collateral ligaments to the metacarpal bone has been described with surface replacement prostheses (Rittmeister, Porsch, Starker, & Kerschbaumer, 1999). Crossed intrinsic transfer (CIT) has been used in MCP arthroplasty surgery to enhance and maintain the correction of the ulnar drift. In the retrospective study by Clark and co-workers (2001) the CIT group had less ulnar drift compared to the non-CIT group at a mean follow-up of 50 months, and CIT was described as one of the factors which improved silastic MCP joint arthroplasty survival in a retrospective radiological study with 17-year follow-up (Trail et al., 2004). In the randomised comparative study by Pereira et al. (2001) it was concluded that CIT does not significantly affect the outcome of silicone implant arthroplasty of the MCP joints in rheumatoid patients. In the majority of publications concerning silicone MCP arthroplasty in RA CIT was performed on only a few patients with severe deformities. The reconstruction of the extensor mechanism by reefing the radial sagittal band and centralising the extensor tendon is essential and routinely done for soft tissue balancing. There is a paucity of research data proving the value of soft tissue reconstruction techniques, and in widely varying perioperative situations the surgeon's decision is based on clinical experience.



## 4.3 Results of silicone implant arthroplasty

### 4.3.1 Outcome evaluation

Because of the systemic and progressive nature of RA it is difficult to assess the outcome of a particular surgical procedure in rheumatoid hands, especially in the longterm (Goldfarb & Stern, 2003). Confounding factors influencing the outcome include impairment of adjacent joints, condition of the soft tissues, medication and variation in disease severity between patients and variation in disease activity of an individual patient (Nalebuff, 1984; Ruther et al., 1995; Synnott, Mullett, Faull, & Kelly, 2000). The discrepancy between fair clinical results and good subjective results after MCP arthroplasty has been reported in many studies (Schmidt, Willburger, Miehle, & Witt, 1999; Synnott et al., 2000; Bogoch & Judd, 2002; Chung et al., 2004). Mandl and co-workers (2002) investigated which outcomes correlate most strongly with patient satisfaction in a retrospective study evaluating 26 RA patients with 160 MCP silastic implants at mean 5.5 years after surgery. This study found that postoperative patient satisfaction correlated most strongly with the appearance of the hand. Pain and to a lesser degree, subjective assessment of function, also correlated with satisfaction. Objective measures such as strength and range of motion correlated only minimally with patient satisfaction (Mandl et al., 2002). The patient-centred determinants of outcome in rheumatoid hand surgery have been emphasised in the recent literature (Mandl et al., 2002; Chung et al., 2004; Goldfarb & Dovan, 2006; W. L. Parker et al., 2007). However, the determination of the subjective outcome of surgical treatment of patients with RA has confounding factors similar to those already mentioned above for objective outcome evaluation. The effect of overall health status on specific outcomes should also be considered (Goldfarb & Stern, 2003).

### 4.3.2 Clinical results

Before year 2005 most publications concerning silicone MCP joint arthroplasty in RA were retrospective studies; only one randomised study comparing the Swanson implant with the Sutter implant (McArthur & Milner, 1998) and a few prospective studies of Swanson arthroplasty (Kirschenbaum, Schneider, Adams, & Cody, 1993; Hansraj et al., 1997; Schmidt, Willburger et al., 1999) were published. RCTs comparing Avanta and NeuFlex to the Swanson prosthesis and Swanson arthroplasty with medical treatment have been published in the past few years (Delaney et al., 2005; Moller et al., 2005; T. Parkkila et al., 2005; Tagil, Geijer, Malcus, & Kopylov, 2009). Patient satisfaction and subjective results were basically good, but clinical outcome assessed by quantitative measurements was only fair.

In the clinical outcome of Avanta or NeuFlex compared with the Swanson prosthesis no significant differences were observed. In the study by McArthur and Milner (1998) improvement in grip strength and ROM was better in the Swanson group than in the Avanta group, but this finding has not been confirmed in other

studies (Moller et al., 2005; T. Parkkila et al., 2005; Tagil et al., 2009). The fracture rate was higher with Avanta prosthesis (36%) compared to the Swanson prosthesis (11%) in the study by Tägil et al. (2009) in which 18 patients with 72 implants were followed-up for 60 months. On the other hand in the study comparing 89 Swanson implants to 126 Avanta (Sutter) implants no significant difference was observed in the fracture rate 58 months after surgery (T. J. Parkkila et al., 2006), (Table 3). In studies comparing NeuFlex implants with Swanson implants slightly better flexion measurements were reported, but no significant differences were observed in ROM (Delaney et al., 2005; Escott et al., 2010). The subjective evaluation of function improvement according to the Michigan Hand Outcome Questionnaire (MHQ) was better in the Swanson than in the NeuFlex group (Escott et al., 2010).

The active ROM after silicone MCP arthroplasty varies from 27° to 56°, and it is either slightly improved from the preoperative ROM or more often sustained at the preoperative level. Deterioration of ROM has also been reported, mainly due to a distinct decrease in the flexion arc (Hansraj et al., 1997; Schmidt, Willburger et al., 1999; T. Parkkila et al., 2005.) The extension lag is systematically improved and postoperative extension lags ranging from 7° to 31° have been reported, whereas a mild deterioration in flexion arc is a typical finding (Table 2). Only in the study by Pettersson and co-workers (2006) comparing NeuFlex and Avanta prostheses was postoperative flexion higher than the preoperative flexion, and an exceptionally good flexion arc (83° and 82°) was reported for both groups. Silicone MCP joint arthroplasty does not restore normal motion in the MCP joints, but because the arc of motion shifts toward more extension, it improves hand function by allowing patients to hold larger objects (Chung, Kowalski, Myra Kim, & Kazmers, 2000). The effect of MCP arthroplasty on palmar subluxation has not been separately described in the literature but the extension lag reflects to some extent the palmar dislocation. The correction of the ulnar deviation is achieved systematically, and postoperative deviation varies from 4° to 23° (Table 2). Slight improvements in grip strength measurements have not been statistically significant in most studies (Schmidt, Willburger et al., 1999; Chung et al., 2004; Delaney et al., 2005; Moller et al., 2005; T. Parkkila et al., 2005; Tagil et al., 2009)), but significant improvement in grip strength has also been reported (Pereira & Belcher, 2001; Pettersson et al., 2006). The small patient groups, 18 – 45 patients, divided into two study groups in these controlled trials, may have influenced the outcome of these studies. In the RCT study by Escott et al. (2010) grip strength improved significantly, when the larger Jamar grip position 4 (2-7/8”) was used in both the Swanson and NeuFlex groups, but not when the two smaller positions 2 or 3 were used, which on the other hand is the grip position which has been used in many earlier studies.

**Table 2.** Summary of selection of studies evaluating clinical outcome of silicone MCP arthroplasty in rheumatoid hand

Study	Implant	N		Follow-up (months)	Extension deficit	Flexion	ROM change	Ulnar deviation	Scores
		Patients	Joints						
Vahvanen and Viljakka (1986)	Swanson	32	107	45	7	41		9,11,12,15*	
Gellman et al. (1997)	Swanson	264	901	96	10	60	+	15	
Hansraj et al. (1997)	Swanson	71	170	63	28	55	-		UEFT +
Rothwell et al. (1997)	Swanson	21	92	38	16	51		4	
Schmidt et al. (1999)	Swanson	28	102	102	10	45	-	10	
Synnott et al. (2000)	Swanson	25	98	30	20	60		14	Jebsen-Taylor +
Clark et al. (2001)	Swanson CIT/no <sup>1</sup>	28/45	112/180	54/46	15/14	52/52		6/14	
Goldfarb and Stern (2003)	Swanson	36	208	168	23	59	0	16	
Delaney et al. (2005)	Swanson/ NeuFlex	10/12	37/40	24	19/16	59/72	+/+	7/9	SODA +/+
Möller et al. (2005)	Swanson/ Avanta	30	120	24	16/19	47/61	0 / +	10/13	Sollerman 0/0
Parkkila et al. (2005)	Swanson/ Avanta	45	75/99	58	12/16	54/63	-/-	5/7	
Pettersson et al. (2006)	NeuFlex/ Avanta	40	78/78	12	20/21	83/82	+/+		COPM +/+
Tägil et al. (2009)	Swanson/ Avanta	18	72	60	14/17	41/53	0/0	7/12	Sollerman 0/0
Chung et al. (2009)	Swanson/ no operation <sup>2</sup>	45/72		12	29/49	60/83	+/0	13/34	MHQ +/0, AIMS2 0/0
Chung et al. (2009)	Swanson less/more severe <sup>3</sup>	70		12	26/31	56/63	0/+	9/18	MHQ +/+, AIMS2 0/0,
Escott et al. (2010)	Swanson/ NeuFlex	33	160	12	14/21	56/75	+/+	7/10	Sollerman +/+, MHQ +/+

+ = improvement from preoperative, - = deterioration , 0 = no change compared to preoperative

\* by each finger

<sup>1</sup> comparison between operation technique with crossed intrinsic transfer or without

<sup>2</sup> comparison between Swanson arthroplasty and conservative treatment

<sup>3</sup> comparison between less severe and more severe MCP destruction

Patient-centred outcome evaluation instruments, such as the MHQ, have been used in recent studies, and they have shown an improvement in all subscores describing patient's hand-specific function, ADL, pain, work performance, aesthetics and satisfaction (Chung et al., 2004; Chung, Burns et al., 2009; Escott et al., 2010). Pain relief was achieved in 71-100% of patients, but only 28-54% of patients were totally pain free (Vahvanen & Viljakka, 1986; Bass et al., 1996; Gellman, Stetson, Brumfield, Costigan, & Kuschner, 1997; Hansraj et al., 1997; Goldfarb & Stern, 2003). However, in the study by Pettersson et al. (2006) no significant difference was found in pain (evaluated by VAS) postoperatively compared with preoperative values. Improvement in the appearance of the hand is highly appreciated by patients, and is commonly achieved after MCP silicone arthroplasty (Vahvanen & Viljakka, 1986; Kirschenbaum et al., 1993; Bass et al., 1996; Schmidt, Willburger et al., 1999; Mandl et al., 2002; Chung et al., 2004; Moller et al., 2005; Chung et al., 2009; Escott et al., 2010). In the study by Tägil et al. (2009) improved aesthetics correlated positively with most of the subjective outcome variables.

The outcome after silicone MCP joint arthroplasty deteriorates over long-term follow-up. Goldfarb and Stern (2003) reported that only 28% of patients were pain free and 38% were satisfied with function at 14-year follow-up. Extension lag deteriorated from postoperatively achieved 11° to 23° and ulnar deviation from 5° to 16°, but in both variables final assessments were still better than the preoperative values (Goldfarb & Stern, 2003). Wilson et al. (1993) reported recurrence of ulnar deviation over 20° in 43% of cases at 14-year follow-up. Survival at five years using revision surgery as an endpoint has been reported to be 92-97% and at 10 years 83-90% (Hansraj et al., 1997; Trail et al., 2004; T. J. Parkkila et al., 2006), but using fracture of the implant as the endpoint survival deteriorated to 58% at 10 years (Trail et al., 2004), (Table 3). Silicone synovitis does not appear to be a critical issue for silicone MCP joint arthroplasty, however, even silicone lymphadenopathy has been reported at distant locations (Paplanus & Payne, 1988; Abboud et al., 2003; Trail et al., 2004).

**Table 3.** Summary of studies presenting fracture rate after silicone MCP joint arthroplasty in rheumatoid patients

Study	Implant	N Patients	Joints	Follow-up (months)	Probable fracture <sup>1</sup> (%)	Fracture (%)	Osteolysis (% of joints )	Survival % <sup>2</sup> (revision )	Survival % <sup>3</sup> (fracture)
Vahvanen and Viljakka (1986)	Swanson	32	107	45	10	4	24		96
Kirschenbaum et al. (1993)	Swanson	27	144	102		10	100 <sup>4</sup>		90
Wilson et al. (1993)	Swanson	35	375	168	17	6	14		94
Bass et al. (1996)	Avanta	34	168	27	10	20			80
		10	40	36	5	45			55
Gellman et. (1997)	Swanson	264	901	96		14			86
Hansraj et al. (1997)	Swanson	71	170	63	28	0.7	8	5yrs 94%, 10yrs 90%	94
Schmidt et al. (1999)	Swanson	28	102	102		27	89		73
Goldfarb and Stern (2003)	Swanson	36	208	168	22	63	29		37
Trail et al. (2004)	Swanson	381	1336	204		66		63	34
				120		42		83	58
Delaney et al. (2005)	Swanson/ NeuFlex	10/12	37/40	24		0/0			100
Möller et al. (2005)	Swanson/ Avanta	30	120	24	15/13	13/20			87/80
Parkkila et al. (2006)	Swanson/ Avanta	53	89/126	58	35/26	34/26		92/97	66/74
Pettersson et al. (2006)	NeuFlex/ Avanta	40	78/78	12		3/6		100	97/94
Tägil et al. (2009)	Swanson/ Avanta	18	72	60		11/36			89/64

<sup>1</sup> in addition to confirmed fracture

<sup>2</sup> revision as endpoint

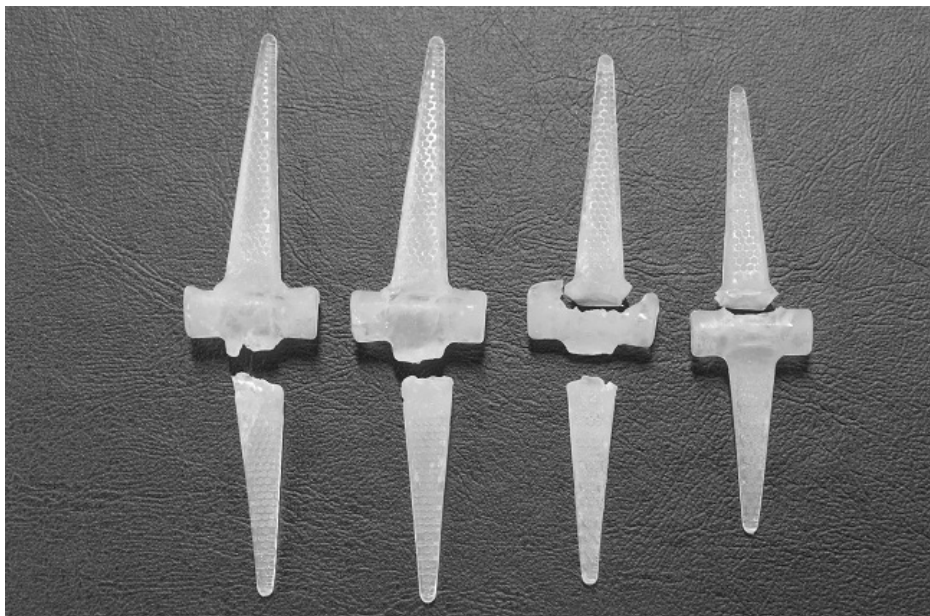
<sup>3</sup> fracture of the implant as endpoint

<sup>4</sup> some erosion of the metacarpals and the proximal phalanx

### 4.3.3 Radiological results

Silicone implants have been associated with progressive bone destruction and implant fracture, but bone erosions and osseous architecture vary considerably after silicone MCP joint arthroplasty and are difficult to quantify accurately and objectively (Kirschenbaum et al., 1993). Definition of implant fracture in plain x-rays is difficult, thus in many studies the following three-step classification has been used: definitely fractured implants, possibly fractured (=severely deformed) implants and intact implants. According to the widely used criteria of Bass et al. (1996) a definite implant fracture is noted (1) when there are lucent lines or fragmentation of the midportion of the implant, (2) when there is a translation in the coronal or sagittal plane of the base of the proximal phalange relative to the neck of the metacarpal of more than one-half the diameter of either bone and (3) when there is a proximodistal overlap of the base of the proximal phalange and the neck of the metacarpal of more than one-half of the width of the midportion of the implant. CT scan has also been used to improve the accuracy of implant fracture diagnosis (Sollerman & Geijer, 1996; Tagil et al., 2009). The majority of fractures occur at the junction of the distal stem and the hinge (Trail et al., 2004).

**Figure 6. Fractured Swanson implants from one patient's MCP joints obtained in revision operation**



Implant fracture rate is low, from 0 to 17%, in short-term studies, but increases over time, and in studies with long-term follow-up (14 and 17 years) implant fracture rates as high as 63-66% have been reported (Schmidt et al., 1999; Goldfarb & Stern, 2003; Trail et al., 2004; Moller et al., 2005; Escott et al., 2010). In a

randomised study comparing Swanson and Sutter implants (Parkkila et al. 2006), fracture rates assessed according to Bass et al. (1996), were 34% in the Swanson group and 26% in the Sutter group at four-year follow-up, but the difference between the groups was not statistically significant. Comparable fracture rates were reported in an RCT by Tägil et al. (2009) using CT scan for fracture diagnosis. At five years 11% of the Swanson implants and 36% of the Avanta (Sutter) implants were broken ( $P=0.05$ ) but fractures did not change the subjectively assessed outcome (Table 3).

The loss of alignment in the wrist has been reported to be an important factor for failure in long-term outcome after MCP arthroplasty (Ruther et al., 1995). According to Trail et al. (2004), the greater the radial deviation malposition of the wrist was, the more likely was the implant to break and require revision. Men had a greater risk of implant fracture than women (Moller et al., 2005). The wider postoperative ROM at three months was reported to represent a risk of implant fracture. An increase in ROM later during follow-up has been figured to be a consequence of implant fracture (Tagil et al., 2009). The preoperative deformity degree showed no correlation with implant fracture in a prospective study by Möller et al. (2005), but the number of fractured implants was low (20). In a retrospective study by Trail et al. (2004) in which 76 out of 1,336 implants were revised and 66% of the implants were radiographically fractured after 17 years of follow-up, the less the preoperative ulnar deviation was, the lower were the fracture and revision rates.

The morbidity associated with the fractured prosthesis is not very high because the implant functions as a spacer rather than as an articulating prosthesis, and scar tissue formation around the implant called “encapsulation” supports the joint (Abboud et al., 2003; Joyce, 2004). The status of the implant does not significantly affect the ROM of the MCP joint in the long term (Goldfarb & Stern, 2003; Moller et al., 2005) but recurrence of ulnar deviation is more common in fractured implants than in non-fractured implants (Bass et al., 1996; Goldfarb & Stern, 2003; Tagil et al., 2009). Ulnar drift impairs cosmetic appearance, and cosmetic appearance has been reported to be negatively related to implant fracture (Moller et al., 2005).

Silicone implants are known to cause osteolysis around the implant and bone shortening of the metacarpal and proximal phalanx at long-term follow-up, but the incidence of these changes after silicone MCP arthroplasty varies widely in different studies. Osteolytic changes were reported even in 89% of joints in the studies in which implants were produced of previously used silastic elastomer (Schmidt, Willburger et al., 1999), but also in series with the currently used silastic elastomer considerable effects on adjacent bone have been reported (Moller et al., 2005; Parkkila et al., 2006). In the study by Goldfarb and Stern (2003) at 14 years postoperatively the final metacarpal length was 90% of the length of the metacarpal immediately postoperatively, and the length of the proximal phalanx was 94% of the preoperative length. The majority of patients showed a moderate loss in bone lengths, but in six out of eighteen hands the metacarpal length was decreased by > 16% and by > 25% in three out of eighteen hands. They also reported significant loss in the MCP joint space width (subsidence) comparing the measurements performed immediately after surgery to those performed during final follow-up (Goldfarb & Stern, 2003). The incidence of osteolysis after MCP arthroplasty was evaluated in a prospective, randomised study in Swanson and Sutter prostheses (Parkkila et al. 2005) in which 75 Swanson implants and 99 Sutter implants were radiographically evaluated at 58 months postoperatively. The Sutter group had a significantly increased rate of osteolysis when compared with the Swanson group.

In the Swanson group 60% of metacarpal bones were free of osteolytic changes, whereas only 23% of metacarpals were intact in the Sutter group. Osteolysis perforating the cortex was reported in 5% of the Swanson implants and in 30% of the Sutter implants. In another study by the same research group 282 Sutter implants were evaluated after a mean of 5.7 years, and osteolytic changes were present in 50% of metacarpal and in 54% of phalangeal bones. They found that osteolysis was more severe in the fractured implant cases. There was also a correlation between osteolysis and hand dominance. They concluded that in the dominant hand prostheses are exposed to more use, and this may be the cause of the correlation with the osteolysis (Parkkila et al., 2006).

It has been claimed that implants which provide long-term stability with less bone reaction are needed (Goldfarb & Dovan, 2006), and the Swanson prosthesis can be viewed as offering a known performance – a benchmark against which other MCP prostheses can be judged. The Swanson prosthesis poses a challenge to implants, and not only by the easiness of implantation and good cost-effectiveness (Joyce, 2004).

## 5. Bioabsorbable polymers in orthopaedic implants

### 5.1 Material and properties

In the last few decades bioabsorbable polymers and composites have been investigated in an attempt to achieve an implant the biodegradation of which would accompany the regeneration of the damaged tissue. The goal of non-degradable implants is to replace the damaged tissue but they have only a limited ability to integrate with the adjacent tissue and to transfer the mechanical loads appropriately to the surrounding tissues. The aim of biodegradable materials is to act as a physical support for the repairing tissue with the ability to promote cell adhesion, proliferation and differentiation. More recently, biomolecules, such as drugs and growth factors, have been added to stimulate and regulate the activity of the cells entrapped in the bioabsorbable biomaterial scaffolds (Koort, Makinen, Suokas, Veiranto, Jalava, Tormala, & Aro, 2008; Santin, 2009.)

Bioabsorbable sutures have been routinely used in clinical surgery for over 30 years. In orthopaedic surgery bioabsorbable implants are available for the stabilisation of fractures, osteotomies, bone grafts and fusions, as well as for reattachment of ligaments, tendons, meniscal tears and other soft tissue structures. Bioabsorbable implants should have adequate initial mechanical strength, but lose their strength gradually during the healing process to enable uncomplicated tissue repair. Avoidance of implant removal operation is one of the advantages of biodegradable devices and highly valued, especially in cranio-maxillofacial and paediatric surgery. The bioabsorbable polymers most intensively studied for the



manufacture of implants and for surgical use are poly- $\alpha$ -hydroxyacids, especially polyglycolide (PGA), polylactide (PLA) and their copolymers. PGA is relatively hydrophilic, highly crystalline, and degrades and loses its strength rapidly in the body, which may lead to fluid accumulation and sterile sinus formation. PGA as a homopolymer is nowadays used mainly in paediatric surgery and also in other applications when glycolide is copolymerised with lactides to form polylactide-glycolide copolymers (Waris, Konttinen, Ashammakhi, Suuronen, & Santavirta, 2004). Lactic acid monomer occurs in two stereoisomeric forms, L- and D-lactic acid, and lactide dimer in LL, DD and DL forms. The L-isomeric form of polylactide (PLLA) is relatively hydrophobic and partially crystalline, and therefore, its complete biodegradation and bioabsorption takes several years. By combining D-isomers with L-lactic acid, copolymers of DD-, DL- and LL-lactide e.g. (P(L/D)LA) can be manufactured which biodegrade more rapidly than pure PLLA. Various degradation rates of the polymer can be achieved by varying the percentage of each component (L or D) in the polymer structure. In fracture fixation the mechanical strength of the implant is important; whereas porous scaffolds have been used to guide tissue growth in bone defects and high initial strength is not in all cases such a critical property (Kellomäki, Niiranen, Puumanen, Ashammakhi, Waris, & Tormala, 2000). These different bioabsorbable polymers can be engineered to alter their material properties and degradation characteristics (Ambrose, & Clanton, 2004). The most commonly used devices in orthopaedic surgery are made of poly L-lactide (PLLA) and different copolymers of polylactides (P(L/D)LA) and polyglycolide (PLGA), and pins, rods, screws, miniplates, tacks and anchors have been manufactured (Middleton & Tipton, 2000; Ashammakhi, Suuronen, Tiainen, Tormala, & Waris, 2003).

Biodegradation of poly- $\alpha$ -hydroxyacids generally occurs in two phases. It begins with hydrolysis of the polymer chains, leading first to a reduction in molecular weight, followed by loss of the mechanical strength. In the second phase the implant loses its form and disintegrates physically into small particles, and finally into oligomers and monomers which are eliminated through normal metabolic pathways (Ambrose & Clanton, 2004). Biodegradation is influenced by chemical and physical factors, such as the chemical composition of the polymer, its molecular weight and orientation, monomer concentration, geometric isomerism, crystallinity, volume and porosity of the implant, the sterilisation method, and the presence of impurities in the polymer. Environmental factors, such as implantation location, mechanical stress transferred to the device, and vascularity in the implantation site also affect the biodegradation process (Kellomäki & Törmälä, 2003). Degradation is generally faster *in vivo* than *in vitro*, in human tissues than in animal experiments, and in well vascularised cancellous bone than in subcutaneous tissue (Middleton & Tipton, 2000; Ambrose & Clanton, 2004; Waris et al., 2004).

Adverse tissue reactions, such as fluid accumulation, sinus formation and osteolysis, have been reported around bioabsorbable implants, especially if produced from pure homopolymeric PGA or PLLA. The newer generation bioabsorbable copolymers are generally well tolerated by living tissues, but tissue reaction to bioresorbable implants occurs to some extent with most of the currently available materials (Ashammakhi et al., 2003; Ambrose & Clanton, 2004). The reported incidences of inflammatory reactions to newer copolymers have been low. These reactions have not been accompanied by clinical symptoms and have had no clear effect on the final outcome (Joukainen, Pihlajamäki, Makela, Ashammakhi, Viljanen, Patiala, Kellomäki, Tormala, & Rokkanen, 2000; Ashammakhi,

Peltoniemi, Waris, Suuronen, Serlo, Kellomaki, Tormala, & Waris, 2001; Ashammakhi et al., 2003; Lazennec, Madi, Rousseau, Roger, & Saillant, 2006). However, cases where bioabsorbable devices had to be removed due to major inflammatory reactions have also been reported (Chen, Chang, Lu, Chang, Tsai, & Huang, 2010; Givissis, Stavridis, Papagelopoulos, Antonarakos, & Christodoulou, 2010). Despite the variable clinical picture of the tissue reactions, the histologic picture is consistent: a sterile, nonspecific inflammatory response with multinuclear foreign body giant cells. Polymeric debris is usually visible and osteolytic lesions are often found. The timing of the foreign-body response is thought to be related to the two phases of polymer degradation (Ambrose & Clanton, 2004). The risk of adverse tissue reactions increases if the implant volume is high and debris particles are produced rapidly, and if the clearing capacity of the surrounding tissue is exceeded. Poor vascularity and a thin soft tissue layer at the implantation site decrease the clearing capacity of the tissue (Ambrose & Clanton, 2004; Givissis et al., 2010).

## 5.2 96L/4D poly-L/D-lactide copolymer

At the beginning of the 1990's a fibrous cushion made of commercially available PGA (90% glycolide and 10% L-lactide) sheets (Vicryl® and Ethisorb®) was introduced for revision and badly destroyed MCP joint arthroplasties in rheumatoid patients by a group of orthopaedic researchers in Tampere University Hospital (Lehtimäki, Lehto, Kellomäki, Paasimäki, Makela, Honkanen, & Törmälä, 1998). The biodegradable cushion was intended to act as the tendon, mimicking Vainio arthroplasty (Vainio, 1989), and the aim was to find a material that could work as a scaffold for the fibroblast proliferation and connective tissue ingrowth. Unpublished observations showed that the resorption time of both commercial materials was discovered to be too short, which led to premature collapse of the joint space. However, the research and development work in Tampere University Hospital continued in collaboration with the biomaterial research group of Tampere University of Technology, with the aim of developing a bioresorbable implant with suitable mechanical properties coupled with optimal degradation rate so that the implant would enable ingrowth of host tissue into the scaffold. The first implant shape was a rectangular cushion, but soon the circular, highly porous, disc-like implant made of poly-L/D-lactide copolymer fibres with an L:D monomer ratio of 96:4 was designed (96L/4D poly-L/D-lactide copolymer).

The same copolymer has been in clinical use in meniscus arrows, in nails and in suture anchors, and the first commercial implants made of this material have been in the market since 1999. 96L/4D poly-L/D-lactide copolymer has been studied in several experimental indications and with cells *in vitro*. These studies have shown that 96L/4D poly-L/D-lactide copolymer is non-cytotoxic and supports attachment and ingrowth of tissue. Typical histological findings are mild tissue reactions, reaching their peak around 24 weeks then subsiding for up to 54 weeks. Macroscopic degradation of the material is achieved by 156 weeks (Cordewene, van Geffen, Joziase, Schmitz, Bos, Rozema, & Pennings, 2000; Saikku-Backstrom, Tulamo, Raiha, Kellomäki, Toivonen, Tormala, & Rokkanen, 2001; Maenpää, Ella, Mauno, Kellomäki, Suuronen, Ylikomi, & Miettinen, 2010).

*In vitro* experiments have shown that the filaments retain at least 50% of their tensile strength for 13 weeks, and scaffolds retain their shape for at least the same length of time (Paatola, Kellomäki, & Törmälä, 2000; Ellä, Annala, Länsman, Nurminen, & Kellomäki, 2011). In animal tests some connective tissue ingrowth into the mesh structure was already observed after the first week. 96L/4D poly-L/D-lactide copolymer scaffolds implanted in rat subcutis were filled with fibrous tissue by 3 weeks, and at 24 weeks each PLDLA filament within the bundle of PLDLA fibres was surrounded by a thin layer of fibrous connective tissue. Fibrous tissue collagen fibres became more organised over time. At 48 weeks a dense connective tissue capsule had formed around each PLDLA fibre and around each individual PLDLA filament (Kellomäki, Puumanen, Waris, & Törmälä, 2000; Lansman, Paakko, Ryhanen, Kellomäki, Waris, Tormala, Waris, Ashammakhi, 2006).

Waris and co-workers (2008) compared the biological behaviour, bioabsorption and biocompatibility of bioreconstructive and Swanson silicone interposition arthroplasties in the fifth MCP joints of minipigs. The 96L/4D poly-L/D-lactide copolymer joint scaffold maintained the width of the arthroplasty joint space and induced fibrous tissue ingrowth *in situ*. The porous structure of the scaffold was finally completely invaded by loose fibrous tissue, which along with the degradation of the scaffold matured and condensed into dense fibrous connective tissue. The collagen framework was more prominent on the volar side of the scaffold than on its dorsal side, which was interpreted so that compression loading associated with joint flexion stimulates fibrogenesis. Collagen fibres were oriented in a longitudinal fashion adapting to the flexion-extension movements of the joint. No differences were noted in ROM or stability between the 96L/4D poly-L/D-lactide copolymer scaffold and Swanson groups. In the Swanson implant group one minipig developed a sinus at the operation site two months postoperatively, but in the 96L/4D poly-L/D-lactide copolymer scaffold group no adverse tissue reactions were noted (Waris, Ashammakhi, Lehtimäki, Tulamo, Kellomäki, Tormala, & Konttinen, 2008).

96L/4D poly-L/D-lactide copolymer joint scaffolds were almost completely degraded at three years (Waris et al., 2008), which is comparable to reports with 96L/4D poly-L/D-lactide copolymer rods in osteotomy surgery in sheep and rabbits (Saikku-Backstrom et al., 2001; Saikku-Backstrom, Tulamo, Raiha, Pohjonen, Toivonen, Tormala, & Rokkanen, 2004). Resorption of the 96L/4D poly-L/D-lactide copolymer cushions evaluated by histological data, CT and MRI was reported in sheep spinal fusion to be complete at 3 years (Lazennec et al., 2006). No inflammatory reactions developed in the tissues surrounding the 96L/4D poly-L/D-lactide copolymer implants or they have been mild in animal experiments (Isotalo, Alarakkola, Talja, Tammela, Valimaa, & Tormala, 1999; Saikku-Backstrom et al., 2001; Saikku-Backstrom et al., 2004; Lansman et al., 2006; Lazennec et al., 2006; Waris et al., 2008).

# AIMS OF THE STUDY

The aim of this study was to investigate the clinical value of partial radiocarpal wrist arthrodesis in rheumatoid hand disease and the outcome of a novel bioabsorbable implant in MCP joint replacement surgery in rheumatoid arthritis patients. The specific aims were:

1. To analyse the effect of partial radiocarpal arthrodesis in a prospective midterm study with respect to clinically relevant parameters, alignment, pain and range of motion
2. To analyse the short-term biocompatibility and function of an implant produced of 96L/4D poly-L/D-lactide copolymer in an open clinical trial in the treatment of metacarpophalangeal joints in rheumatoid arthritis patients
3. To analyse the mid-term clinical performance of the abovementioned MCP implants, including evaluation of eventual peri-implant osteolysis developing as a result of resorption of the 96L/4D poly-L/D-lactide copolymer implants at the timepoint when they are already totally resorbed
4. To compare the novel 96L/4D poly-L/D-lactide copolymer implant with the conventional silastic Swanson implant in MCP joint arthroplasty

# MATERIAL AND METHODS

## 1. Patient selection and study design

The thesis is composed of three different patient materials. Only patients with inflammatory arthritis diagnoses were included. In the first material all patients undergoing radiocarpal arthrodesis in the Department of Orthopaedics in Tampere University Hospital between 1995 and 1999 were recruited for a prospective study. The patient material included 23 patients and 26 wrist joints. The indication for the operation was pain or chronic wrist synovitis with radiocarpal destruction or dislocation of the radiocarpal joint seen in X-rays. Defects of the cartilage in the midcarpal joint visible in routine radiographs were considered to be a contraindication for this operation. Outcomes of 23 wrists in 20 patients were evaluated at a mean of 5.8 years follow-up.

The patient material in Studies II and III was composed of 23 consecutive rheumatoid arthritis patients who between 1997 and 2000 underwent primary or revision MCP arthroplasty in 80 joints with novel bioabsorbable implants made of 96L/4D poly-L/D-lactide copolymer. The indication for the operation was rheumatoid deformation of the MCP joints affecting ADL. Results of 54 joints in 15 patients were reported at a minimum of 1 year follow-up, and the outcome of 23 patients (80 joints) was presented at mean 59 months after operation, which exceeds the resorption time of 96L/4D poly-L/D-lactide copolymer implants according to earlier published animal experiments.

The third patient material in Study IV was recruited for a randomised parallel group trial, carried out at two centres, Tampere University Hospital and the Rheumatism Foundation Hospital in Heinola. The inclusion criterion was rheumatoid arthritis in MCP joints impairing ADL. Second or later revision operations were excluded. Randomisation was done using a random digit table and allocation concealment using sealed sequentially numbered envelopes. Patients were randomised to either the investigational device (bioabsorbable 96L/4D poly-L/D-lactide copolymer implant) or the comparator device (conventional silicone Swanson prosthesis) groups. Results in 52 patients (53 hands and 175 joints) at a mean follow-up of 2 years were evaluated.

All patients were informed of the study protocol and written consent was obtained from each patient. Studies I-IV were approved by the Ethics Committee of the Tampere University Hospital and Pirkanmaa Hospital District, and Study IV also by the Ethics Committee of Päijät-Häme Central Hospital and Päijät-Häme Social and Health Care District. In addition, the approval from the Finnish Medicine Agency was obtained for Study IV.

## 2. Bioabsorbable MCP implant scaffold

### 2.1 Manufacturing

The investigational implants were manufactured at the Institute of Biomaterials, Tampere University of Technology. The polymer used in these studies was medicalgrade and highly purified (residual monomer content 0.1% according to the manufacturer) polylactide L- and D-copolymer with an L:D monomer ratio of 96:4 (PLA96; Purac Biochem, Gorinchem, The Netherlands). After pre-drying the polymer was melt-spun to 4-filament fibre. This process was initially performed using an Axon BX-15 single screw extruder (screw diameter 15 mm; ratio of screw length to diameter 24; Axon, Åstorp, Sweden) with a spinneret with four orifices (each with a diameter of 0.5 mm). The PLA96 used in Study IV was processed to 4-filament fibres using Gimac microextruder (Gimac, Gastronno, Italy) with a screw diameter of 12 mm and single orifice diameter of 0.4 mm. Four-ply multifilament yarn was knitted to a tubular mesh, using a tubular single jersey knitting machine with a ½" needle barrel (Elha R-1S, Textilmaschinenfabrik Harry Lucas, Neumünster, Germany). The knitted tube was reeled to circular cushion-like implants and heat-treated above the glass transition temperature of polymer in molds. In the beginning the reeling process was performed manually, but this production step was later performed using semiautomatic reeling equipment. The porosity of the scaffolds was assessed by determining the weight and size of the scaffolds and calculating against the solid piece of PLA96. The single-packed implants were sterilised by  $\gamma$ -irradiation (commercial service supplier, nominal irradiation dose 25 kGy).

### 2.2 Implant properties

The circular, disc-like 96L/4D poly-L/D-lactide copolymer implant scaffolds used in these studies were made of the same material that has been in the market and used in various devices for bone and soft tissue fixation since the late 1990s.

**Figure 7. PLDLA bioabsorbable MCP joint implant**



The 96L/4D poly-L/D-lactide copolymer joint scaffold is knitted and highly porous, enabling needle perforation during surgical fixation, and the implant is clearly flexible. The properties of the implants were found to enable fibrous tissue growth into the implant and the implant has good biocompatibility with bone tissue. Implants with diameters of 12, 14, 16 and 18 mm having a nominal thickness of 4.5 mm (range 4.3–4.7) were used in these studies. The purpose was to use an implant size as close to the joint size as possible. The stemless implant enables bone grafting into medullar canals in the same operation.

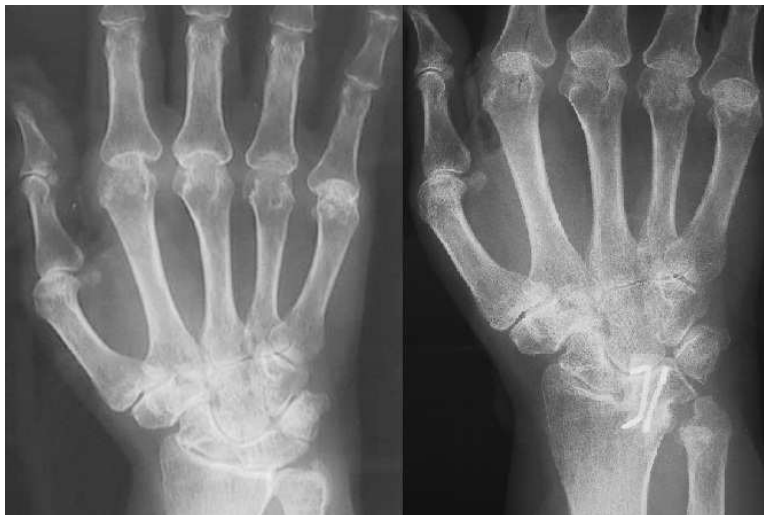### 3. Surgical technique and postoperative rehabilitation

#### 3.1 Partial radiocarpal arthrodesis

Anaesthesia was mainly produced by plexus block. All operations were performed using a tourniquet, and a prophylactic antibiotic (cefuroxime) was used preoperatively. Synovectomy of the extensor tendons and radiocarpal, midcarpal and radioulnar joints were routinely performed in all cases. A segment of the posterior interosseous nerve was resected in all cases. Ulnar head resection was performed in all cases except one. Capsule opening was performed using a mildly S-shaped longitudinal incision. In radiolunate arthrodeses, the surface of the lunate fossa of the radius and the surface of the lunate bone in contact with it were resected back to the cancellous bone, but the contours of the bones were maintained as well as possible. In radioscapolunate arthrodesis, the contact surfaces of the scaphoid fossa of the radius and of the scaphoid bone were also similarly prepared. Reduction of the lunate bone in radiolunate arthrodesis cases, or of both the lunate and the scaphoid bones in the radioscapolunate arthrodesis cases, was performed to correct the ulnar translocation and palmar subluxation malalignments of the wrists. Volar and dorsal intercalated segmental instabilities (VISI and DISI) of the lunate were

carefully corrected. Compression and temporary fixation were achieved with AO-forceps and two short 0.8 mm K-wires. The alignment of the capitate bone in relation to the scaphoid and the lunate was evaluated in flexion–extension motion. If any torque seemed to exist, their relative position was adjusted. Reposition was also checked with C-arm imaging before final fixation. Bone grafting was not routinely used, but any space between the bones to be fused was filled with bone graft obtained from the resected ulnar head. The lunate, or both the lunate and scaphoid bones were fixed to the radius. In 16 cases this fixation was performed with metal staples, in six cases with bioabsorbable Biofixs rods and in one case both devices were used (Figure 8). The extensor retinaculum was split transversely and the proximal part was stitched under the extensor tendons to stabilise the distal ulna. The distal part of the retinaculum was reattached dorsally to the extensor tendons to prevent the bowstringing phenomenon. Bulky dressings and a dorsal plaster cast were applied at the end of the operation. These were replaced by a dorsal individual static splint on the second postoperative day and this splint was used for six weeks, during which time only light use of the hand was permitted.

**Figure 8. X-ray of radiolunate arthrodesis pre- and postoperatively**



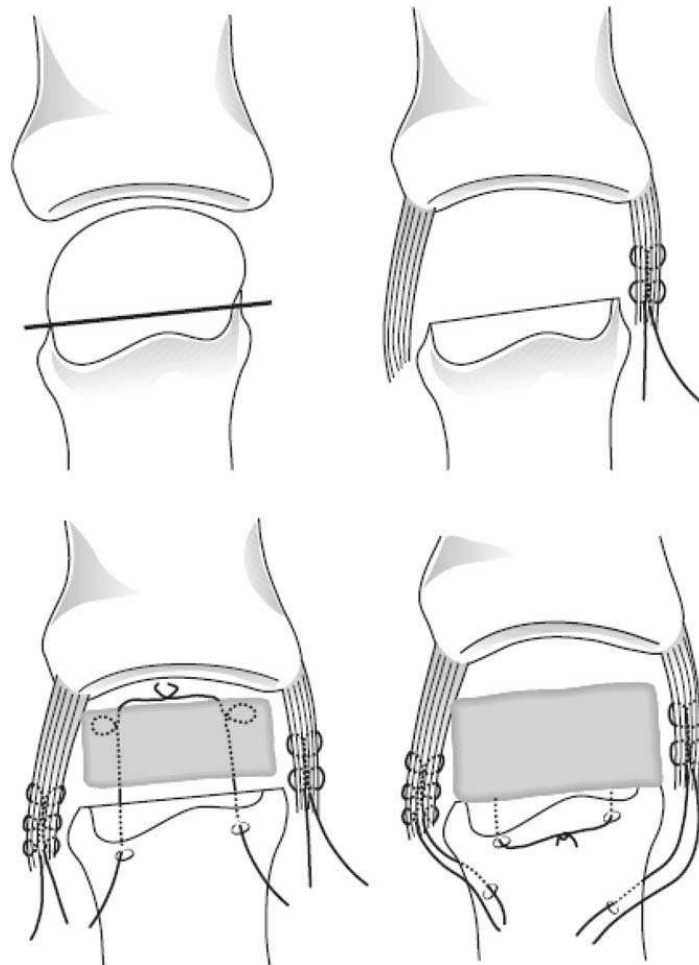
### 3.2 MCP arthroplasty with Swanson and MCP scaffold implant

Regional plexus anaesthesia was administered by anaesthesiologists. A preoperative prophylactic antibiotic was routinely used. Operations were performed using a tourniquet. Transverse skin incision was performed over the knuckles. The extensor hood was opened longitudinally from the radial side in Studies II-III, and either a radial or ulnar approach was used in Study IV. The joint capsule was opened longitudinally and synovectomy was carried out. The metacarpal head was resected just distal to the collateral ligament insertions both in Swanson and PLDLA arthroplasty. The quantity and quality of soft tissue balancing in the operation were determined by analysis of the grade and type of the deformity. When ulnar deviation



existed, the proximal bony attachment of ulnar collateral ligament was released. Deliberation of the volar capsule under the metacarpal bone and release of the volar plate were performed to achieve adequate correction of volar subluxation. Ulnar intrinsic muscle contractures were released when required. The abductor digiti minimi of the fifth finger was always dissected. The 96L/4D poly-L/D-lactide copolymer scaffold was fixed with absorbable sutures through the metacarpal bone via the volar plate.

**Figure 9. Surgical technique for primary MCP arthroplasty using P(L/D)LA 96/4 scaffolds**

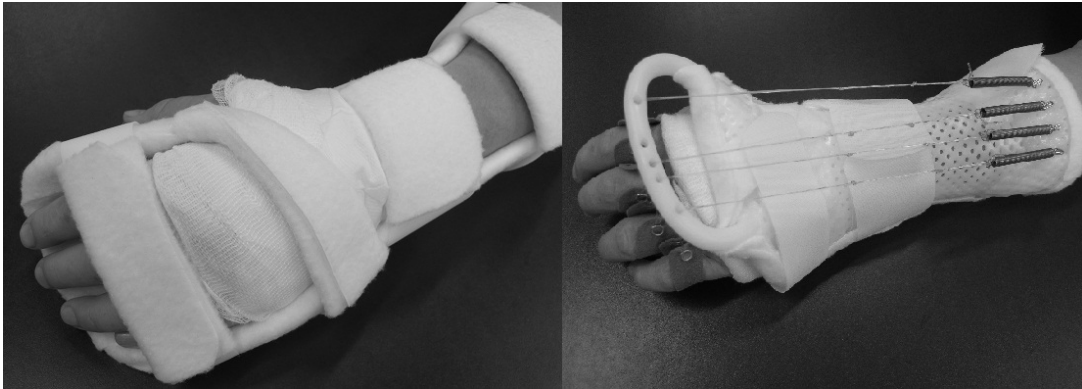


© Originally published in The Journal of Hand Surgery Eur 2010. Sagepublications.

Intramedullary bone grafting using morcelised allograft and/or autograft bone was performed in revision arthroplasties. Balancing and tightening of the collateral ligaments were performed by duplicating or refixing the ligament more proximally through drill holes in the proximal metacarpal bone. At the end, the extensor tendon was centralised.

In rehabilitation, the operated MCP joints were supported with a palmar static splint at night. Active and passive range of movement exercises were assisted with low-profile dynamic dorsal splinting starting 10 days postoperatively and continued for up to 12 weeks (Figure 10). Light ADL, like eating and personal hygiene, was allowed immediately after the use of the dynamic splint was initialised. The rehabilitation was controlled by an occupational therapist.

**Figure 10. Volar static and dorsal dynamic splints in rehabilitation after MCP joint replacement surgery**



## 4. Clinical examination

### 4.1 Evaluation of alignment and range of motion

The range of motion of the MCP joints was evaluated by measuring active flexion and lack of active extension from the dorsal side using a goniometer. The deficiency in total finger flexion was recorded in Study III using the distance between finger tips and the distal palmar crease. The active ROM of the wrist was measured dorsally using a goniometer. Ulnar deviation, the angle between the metacarpal and the proximal phalangeal bone, was measured clinically using a goniometer and with the fingers in maximal active extension. The measurements were performed preoperatively and postoperatively at the follow-up visits.

### 4.2 Evaluation of functionality of the hand

#### 4.2.1 Functional grips

Grip strength was measured using a Jamar dynamometer (Preston, Jackson, MI, USA) with the handle in position two. The mean value of three grip strength measurements was calculated in Studies II and III, and the best value of three consecutive measurements was recorded in Studies I and IV. The postoperative measurements of the hand operated on were compared to preoperative assessments and to the postoperative measurements of the contralateral hand. Tip pinch grip was assessed for each finger with a wooden bead of 10 mm diameter and graded as normal, applied or not able.

#### 4.2.2 ADL abilities and activities

The functionality of the hand in ADL was evaluated pre- and postoperatively by an occupational therapist in Studies II, III and IV. A therapist performed simulated ADL tests, such as ability to handle a knife and fork (precision grip) and a jug with capacity of 0.5 litres (cylinder and transverse volar grip). In the precision grip assessment the patient used a knife and fork to cut a piece of resistive exercise putty (Rolyan A497-280, diameter 7.5 cm). In the cylinder grip test the patient was asked to decant 1 dl of water from a jug to a glass (diameter 6–7 cm), whereas decanting the water back to the jug was assessed as a transverse palmar grip. These functional grips were graded as normal, alternative way or not able, and the alternative way meaning to be able to perform the task but not in the manner requested. The timed ‘Box and Block’ (in Studies II, III and IV) and ‘Nine hole’ (in Studies II and III) tests were performed pre- and postoperatively by both hands separately to evaluate the change in the dexterity of the hand operated on. Ability to take care of personal hygiene, dressing, eating and housework were assessed by questioning and graded ‘no difficulties’, ‘some difficulties’, and ‘considerable difficulties’ or ‘not able to do’ (in Studies II and III).

#### 4.3 Evaluation of subjective outcome

Pain and satisfaction were assessed using a questionnaire. A verbal rating scale for pain evaluation was used in Studies I-III, and the visual analogous scale (0-100, 0 indicates no pain) was used in Study IV. Patient satisfaction was assessed using a scale reporting excellent, good, satisfactory or poor results.

#### 4.4 Complications and adverse events

Infections and any kind of wound healing problems were recorded as complications, and likewise abnormal tissue reactions (swelling or redness) in Studies II-IV.

### 5. Radiological evaluation

Standardised anteroposterior, supine oblique and lateral X-rays of the hand and wrist were taken preoperatively and at the follow-up visits postoperatively. The supine oblique projection was taken using a cradle to enhance the repeatability.

Preoperatively, structural changes of the MCP joints and the wrist were graded using the Larsen score.

## 5.1 Evaluation of consolidation

In the partial wrist fusion study (Study I) the consolidation of the arthrodesis at the follow-up was evaluated in radiographs. The incorporation of the bone grafts was evaluated in radiographs in the revision cases.

## 5.2 Evaluation of the correction of the malalignment

The carpal ulnar distance ratio (Youm, McMurthy, Flatt, & Gillespie, 1978) was used to measure ulnar translocation before partial wrist arthrodesis operation and to assess the correction of the malalignment at follow-up. Volar and dorsiflexed intercalated segmental instabilities (VISI and DISI) of the lunate were measured to evaluate the dislocation of the wrist on the frontal axis. The carpal height ratio was used to reflect the cartilage and bone destruction stage in the wrist joint as well as palmar dislocation of the carpal bones. Ulnar and radial deviations of the wrist pre- and postoperatively were evaluated by measuring the angle between the longitudinal axis of the third metacarpal bone and that of the radius in the anteroposterior projection.

Palmar subluxation of the MCP joints was assessed from standardised supine oblique radiographs with the fingers at maximal active extension. The difference between the dorsal levels of the metacarpal bone and proximal phalanx was measured in millimetres (Study II) or graded as 'no palmar subluxation', 'palmar subluxation' and 'dislocation' (Study IV) or graded as 'no subluxation', 'subluxation less than 50% of metacarpal thickness', 'subluxation more than 50% of metacarpal thickness' and 'complete dislocation' (Study III). In the dislocation category the dorsal cortex of the proximal phalanx lay under the palmar cortex of the metacarpal bone.

## 5.3 Evaluation of progression of joint deterioration

In the partial wrist arthrodesis study the degree of midcarpal joint destruction in the wrist was evaluated at final follow-up from the supine oblique and anteroposterior projections and categorised into three groups, viz. intact midcarpal joint space, narrowed midcarpal joint space and destroyed midcarpal joint, in which erosions or

other bone deformities were observed. The effect on clinical outcome of the midcarpal joint destruction after partial wrist arthrodesis was evaluated.

## 5.4 Evaluation of osteolysis

The joint space indicating the distance between the metacarpal and proximal phalanx bone ends in supine oblique radiographs from the radioulnar middle point of the joint was measured preoperatively. This was compared with the final follow-up value after the MCP joint arthroplasty to reflect the osteolysis of the metacarpal or proximal phalangeal bone. The maximal depth of osteolysis at the ends of the metacarpal and proximal phalangeal bones was measured from both projections. In addition, implant fractures and cortical bone perforations were evaluated from radiographs

## 6. Statistical methods

The numerical variables were presented as means with standard deviations (or range) or as medians and quartiles depending on data distribution. The categorical variables were reported as absolute and relative frequencies. Unpaired t-test and one-way ANOVA were used to analyse differences between groups for normally distributed variables, whereas skewed data were analysed with Mann–Whitney test. Analyses between pre- and postoperative nonparametric variables were made with Wilcoxon test and in case of numerical and normally distributed variables paired samples t-test was used. Categorical variables were analysed using crosstabulations with Fisher's exact test. In comparing classified variables pre- and postoperatively in case of small sample size  $\kappa$ - and  $\gamma$ -statistics were used. Spearman's correlation coefficient was used to analyse the strength of the associations for skewed variables, whereas Pearson's  $r$  was used for normally distributed variables. SPSS for Windows statistical software (Chigaco, IL, USA) was used to analyse the data.

Sample size estimation was performed in Study IV using active ROM in the MCP joint as a primary outcome. A difference of  $10^\circ$  (and standard deviation of  $15^\circ$ ) was considered to be a clinically significant difference between the groups. After power calculations using 5% type I error, 80% power and 0.10 effect size, 80 patients were recruited to allow a safety margin for drop-outs.

# SUMMARY OF THE RESULTS

## 1. Clinical and radiological outcome of partial radiocarpal arthrodesis in the treatment of instable rheumatoid wrist (Study I)

The subjective outcome after partial radiocarpal arthrodesis was good. Significant pain alleviation was achieved ( $p=0.001$ ) so that 17 out of the 23 wrists operated on were painless at final follow-up (mean 5.8 years). Patient satisfaction was excellent or good for 20 wrists and satisfactory for one wrist. In two patients with poor satisfaction, arthritis progressed to the midcarpal joint and necessitated total arthrodesis of the wrist.

The active ROM  $63^\circ$  at the final follow-up was functionally satisfactory. Mean flexion was  $29^\circ$  representing 67% of preoperative flexion, and the extension was  $34^\circ$ , representing 92% of the preoperative value. No deterioration in active ROM developed between 1 year and the final follow-up. The mean power grip was 17 kg pre-operatively and 20 kg at the final follow-up ( $p=0.288$ ). Factors correlating with postoperative grip power were pre-operative grip power of the same hand ( $r=0.683$ ), the post-operative grip power of the contralateral hand ( $r=0.906$ ) and pain ( $r=-0.570$ ).

Consolidation of the arthrodesis was seen in radiographs in all cases, and the correction of the dislocation was achieved in most of the wrists. The carpal ulnar distance ratio was 0.26 (SD 0.05) pre-operatively and 0.30 (SD 0.06) postoperatively, which indicates that correction of the ulnar translocation of the carpus was achieved ( $p=0.015$ ). In 15 wrists out of 23 metacarpal angulations (the angle between the third metacarpal and the radius) was between  $5^\circ$  radial deviation and  $10^\circ$  ulnar deviation. In the frontal axis, the position of the lunate was neutral in 16 wrists, and slight VISI deformity was found in four wrists and DISI in three wrists. As expected, impairment of flexion was greater than the average in DISI wrists. The ROM seemed to be best sustained in the neutral group, in which the postoperative ROM was  $68^\circ$  (84% of pre-operative ROM), compared to the postoperative ROM in the VISI group ( $52^\circ$ , 63% of the preoperative ROM) or in the DISI group, in which the postoperative ROM was  $55^\circ$  and 72% of the pre-operative value. No statistical significance was seen between these small-sized groups.

In addition to two cases with arthritis progression in the midcarpal joint leading to total arthrodesis, in eight wrists the midcarpal joint was narrowed and in five cases some bone destruction in the midcarpal joint was observed. The destruction degree of the midcarpal joint at the final follow-up did not affect ROM or grip strength, but correlated with pain and subjective results.

## 2. Clinical and radiological results of bioabsorbable 96L/4D poly-L/D-lactide copolymer implant in MCP arthroplasty

### 2.1 Outcomes prior to material bioabsorption (Studies II and IV)

96L/4D poly-L/D-lactide copolymer scaffold had open and interconnected porosity throughout the implant structure, and the calculated porosity of the scaffolds was approximately 80% (75-83%). Remaining tensile strength, *in vitro* in phosphate buffer saline (pH 7.4, temp 38°), was 50% at 12 weeks.

Pain relief was achieved well. All patients reported relief from pain at follow-up in Study II, and median pain (VAS, 0-100) improved significantly, from 40 to 6, in Study IV. Active extension improved and flexion deteriorated, thus the arc of active ROM shifted towards extension in both studies. The average range of motion, obtained by pooling ROM data of individual fingers was 51° at follow-up in both studies, and preoperatively it was 46° in Study II and 41° in Study IV. The improvement in the power grip strength (from 9.4 kg to 11.7 kg) was statistically significant ( $p=0.016$ ) in Study IV, but the change from 8.0 kg to 8.2 kg was not statistically significant ( $p=0.80$ ) in Study II.

In Study IV hand function was evaluated by ADL mimicking tasks in which MCP joints are involved. An improvement in these functional tests was observed except in the tip pinch grip of the index finger and in the precision grip (handling of the knife and fork). Improved ability to eat and to take care of personal hygiene was observed in Study II. In the Box and Block dexterity test the results improved from preoperative 59 to postoperative 66 ( $p=0.001$ ). Subjective satisfaction was excellent or good in 20 out of 27 patients in Study IV and in seven out of 15 patients in Study II.

The correction of ulnar deviation was achieved well as it improved from preoperative mean 26° to postoperative mean 6° ( $p=0.001$ ) in Study II, and from preoperative (MCPII-III-IV-V) 13-26-32-41 to postoperative 2-8-7-10 in Study IV. Palmar subluxation improved significantly in both studies. Palmar subluxation of more than half of the bone height was present in 56% of the MCP joints preoperatively and in 6% at follow-up in Study II. In Study IV preoperatively in the 'no palmar subluxation' group there were nine joints and in the 'dislocation' group 19 joints, and at follow-up 40 and six joints respectively.

## 2.2 Outcomes beyond the bioabsorption time (Study III)

The clinical outcome of the study with longer follow-up did not differ substantially from the outcome of the studies performed with follow-up shorter than the bioabsorption time of the implant. Pain was alleviated in all 23 patients, and at final follow-up 13 patients were pain-free and 10 patients reported occasional pain. The mean extension deficit of the MCP joints improved from 32° preoperatively to 15° at final follow-up, and mean MCP flexion deteriorated from 76° to 63° respectively. The outcome of ROM was maintained between intermediate (14 months) and final follow-up (59 months).

The ability to perform personal ADL (dressing, eating and personal hygiene) improved, but no effect was observed on the ability to work, study or carry out exercise and leisure activities. Pinch grip improved, but no significant changes were observed in the other grasps. Grip strength deteriorated in the hand operated on from preoperative median 6 kg to postoperative 4.5 kg ( $p=0.043$ ), and in the hand not operated on from 8 kg to 6.5 kg ( $p=0.010$ ). At intermediate follow-up grip strength median was 7 kg in the hand operated on and 9 kg in the non-operated hand, which may also have been influenced by postoperative intensive rehabilitation supervised by an occupational therapist. Patient satisfaction was excellent or good in 12 out of 23 patients.

The correction of the ulnar deviation was achieved and well sustained. The preoperative ulnar deviations were 14°, 22°, 28° and 37° for the index, middle, ring and little fingers, respectively. At intermediate follow-up the corresponding figures were 3°, 9°, 7° and 7° and at final follow-up 0°, 5°, 7° and 10°. Palmar subluxation exceeded half of the bone thickness in 39 out of 80 joints before surgery and in nine joints (out of 80) at final follow-up, and in 71 joints (89%) the palmar subluxation was less than half of the bone thickness at the final follow-up and in 27 (34%) joints palmar subluxation did not occur at all. Some statistically insignificant tendency of progression in palmar subluxation was observed between the intermediate and the final follow-up visits.

Osteolytic changes were minor and confined to joint surface areas, but were not found in the diaphyseal bone. Osteolytic changes exceeding 2 mm had developed on the surfaces of the metacarpal and/or proximal phalangeal bone surfaces in three out of 80 cases between 3-month and final follow-up. In conclusion, implant absorption did not induce any significant osteolysis. None of the implants had to be revised.

## 3. Outcome of 96L/4D poly-L/D-lactide copolymer implant compared to Swanson silicone prosthesis (Study IV)

The clinical outcomes of MCP joint arthroplasty using 96L/4D poly-L/D-lactide copolymer implant or Swanson silicone implant were quite similar at a mean of 24 months of follow-up. Median pain decreased significantly from preoperative 37 (VAS, 0-100) to 5 in the Swanson group, and from 40 to 6 in the PLDLA group.



Active extension improved and flexion deteriorated equally in both groups, except flexion of the IV MCP joint, which deteriorated less in the Swanson group, from 77° to 73° ( $p=0.304$ ) than in the PLDLA group, from 79° to 65° ( $p<0.001$ ) (Table 4).

Functional grip assessments improved on preoperative values except precision grip and transverse volar grip in the PLDLA group. However, no statistically significant differences were observed in postoperative functional grip assessments between the Swanson and PLDLA groups. The Box and Block dexterity test improved in the PLDLA group (from 59 to 66,  $p=0.001$ ), whereas the change from 60 to 64 in the Swanson group was not statistically significant ( $p=0.136$ ). No difference was observed in outcome of power grip strength between the Swanson and PLDLA groups. In the Swanson group power grip improved from 9.7 kg to 11.4 kg ( $p=0.01$ ) and in the PLDLA group from 9.4 kg to 11.7 kg ( $p=0.016$ ). Patient satisfaction at follow-up was similar in the Swanson and PLDLA groups. Subjective outcome was excellent or good in 17 patients in the Swanson group and in 20 patients in the PLDLA group.

A significant and comparable improvement was achieved in ulnar drift correction in the Swanson and PLDLA group. In the Swanson group ulnar deviations at follow-up were 3°, 5°, 5° and 6° in the index, middle, ring and little fingers, respectively, and in the PLDLA group 2°, 8°, 7° and 10°, with no difference between the groups pre- or postoperatively (Table 4).

**Table 4.** Active range of motion (degrees) and ulnar deviation (degrees) in Swanson and PLDLA arthroplasty groups before operation and at the follow-up (mean 24 months after surgery)

	Swanson			PLDLA			p-value <sup>3</sup>	p-value <sup>4</sup>
	Preoperative	Follow-up	p-value <sup>1</sup>	Preoperative	Follow-up	p-value <sup>2</sup>		
<b>Extension</b>								
<b>lack</b>								
MCP II	25	15	0.001	27	16	0.001	0.615	0.664
MCP III	33	17	<0.001	37	22	<0.001	0.548	0.238
MCP IV	29	15	0.012	40	17	<0.001	0.147	0.760
MCP V	32	14	0.001	31	8	<0.001	0.902	0.225
<b>Flexion</b>								
MCP II	75	67	<0.001	73	66	0.009	0.669	0.752
MCP III	82	72	<0.001	81	71	<0.001	0.789	0.736
MCP IV	77	73	0.304	79	65	<0.001	0.743	0.031
MCP V	77	66	0.005	73	58	0.002	0.405	0.203
<b>Ulnar deviation</b>								
MCP II	12	3	0.004	13	2	0.001	0.704	0.506
MCP III	21	5	<0.001	26	8	<0.001	0.244	0.186
MCP IV	26	5	<0.001	32	7	<0.001	0.403	0.507
MCP V	34	6	<0.001	41	10	<0.001	0.385	0.263

<sup>1</sup> A comparison before vs. after Swanson arthroplasty

<sup>2</sup> A comparison before vs. after PLDLA arthroplasty

<sup>3</sup> A comparison of preoperative values between Swanson and PLDLA

<sup>4</sup> A comparison of follow-up values between Swanson and PLDLA

Palmar subluxation improved significantly in both groups, but at follow-up palmar dislocation was observed more frequently in the PLDLA group (44 joints) than in the Swanson group (10 joints). The recurrence of palmar subluxation was less than the height of the metacarpal bone in 38 out of 44 joints in the PLDLA group, and in 10 out of 10 joints in the Swanson group (Table 5). Twelve (10 %) Swanson implants were broken in radiological analysis at follow-up. In addition, perforation of the phalangeal cortex was noted in two fingers.

**Table 5.** Palmar subluxation in Swanson and PLDLA arthroplasty before operation and at the follow-up (mean 24 months after surgery)

	Swanson						PLDLA									
	Preoperative			Follow-up			p-value <sup>1</sup>	Preoperative			Follow-up			p-value <sup>2</sup>	p-value <sup>3</sup>	p-value <sup>4</sup>
	A	B	C	A	B	C		A	B	C	A	B	C			
MCP II	4	17	4	21	4	0	<0.001	0	18	5	9	12	2	0.008	0.164	0.001
MCP III	4	17	4	22	3	0	<0.001	2	16	4	7	13	2	0.038	0.578	<0.001
MCP IV	8	8	5	19	2	0	0.001	3	12	4	13	5	1	0.001	0.368	0.079
MCP V	6	7	7	19	1	0	0.001	4	10	6	11	8	1	0.003	0.862	0.004

A=no palmar subluxation B=palmar subluxation C=luxation

<sup>1</sup> A comparison before vs. after Swanson arthroplasty

<sup>2</sup> A comparison before vs. after PLDLA arthroplasty

<sup>3</sup> A comparison of preoperative values between Swanson and PLDLA

<sup>4</sup> A comparison of follow-up values between Swanson and PLDLA

# DISCUSSION

## 1. Radiocarpal partial arthrodesis in rheumatoid hand surgery

In this thesis the results of subjective satisfaction and pain after partial radiocarpal arthrodesis were comparable to those of earlier studies in rheumatoid patients (Stanley, 1989; Doets & Raven, 1999; Borisch & Haussmann, 2002; Ishikawa et al., 2005). When ROM has been used as the outcome measure, wide variation has been reported. A decrease of wrist motion in all directions or only of wrist flexion has commonly been described (Ishikawa et al., 1992; Borisch & Haussmann, 2002; Ishikawa et al., 2005). Postoperative ROM in our study (63°) is slightly better than on average in earlier publications. This is due at least in part to patient selection; in our study none of the cases were advanced Larsen IV stage patients. Overall the ROM after partial radiocarpal fusion is wide enough to enable ADL tasks according to biomechanical studies (Brumfield & Champoux, 1984; Ryu, Cooney, Askew, An, & Chao, 1991). Despite pain alleviation, correction of the malalignment and stability of the wrist, the effect of radiocarpal fusion on grip power is not clear. The evaluation of grips in the rheumatoid hand is in general challenging, because it changes depending on the state of the joints of the whole hand.

Radiocarpal arthrodesis enables repositioning of the ulnar translocation and palmar subluxation of the rheumatoid wrist, and the corrected position was maintained in this study as in the long-term study with 13 years of follow-up by Ishikawa et al. (2005). The effect of the radiocarpal fusion on ulnar drift in the rheumatoid hand has not been established, but malalignment of the wrist joint seems to aggravate the ulnar shift of the metacarpophalangeal joints (DiBenedetto, Lubbers, & Coleman, 1991; van Vugt et al., 1999), and the reconstructive surgery of MCP joints has commonly been reported to be shortlived in cases with wrist malposition (Burke, 2011).

The main problem after radiocarpal fusion is the radiological progression of midcarpal joint destruction, which has on average been observed already at two year follow-up in many studies (Linscheid & Dobyns, 1985; Stanley, 1989; Ishikawa et al., 1992). Ishikawa et al. (2005) reported midcarpal destruction in 36% of cases at mean 13-year follow-up, whereas in the study by Borisch and Haussmann (2002) at five-year follow-up destruction of the midcarpal joint was observed in 73% of the wrists. Borisch and Haussmann (2002) stretched the indications further than other authors; 44% of their cases being Larsen grade IV. In our study including only Larsen II and III cases midcarpal destruction was observed in 57% of cases at mean 5.8 years after surgery, and the changes did not affect ROM, but pain and subjective satisfaction were inferior to cases in which the midcarpal joint was well preserved. Destruction in the midcarpal joint appears to be less symptomatic and better tolerated than destruction in the radiocarpal joint, probably because the midcarpal joint has greater intrinsic stability (Doets & Raven, 1999; Arimitsu et al., 2007).

The literature on radiocarpal arthrodesis is not extensive, but the reported variation in the results is wide. Differences in patient selection and in the indications are one reason for this, but in addition the radiocarpal arthrodesis operation is prone to technical errors. However, this study, together with the earlier literature, shows that radiocarpal arthrodesis provides a satisfactory outcome if the arthritic destruction is limited to the radiocarpal area and the rheumatic disease itself is under control. It preserves the mobility and bone stock of the wrist, and the survival seems to be better than in joint replacement surgery with today's implants. Either total arthrodesis or arthroplasty can be performed without any problems after partial radiocarpal arthrodesis if further progression occurs.

## 2. 96L/4D poly-L/D-lactide copolymer implant in MCP arthroplasty

MCP joint deformity is responsible for the greater part of the impairment of the aesthetics in rheumatoid hand, and also substantially inhibits hand function. This deformity in its advanced stages consists of cartilage and/or bone destruction and soft tissue imbalance, thus, in addition to the joint replacement, soft tissue balancing is also necessary in its surgical treatment. The problems associated with the use of the gold standard silicone MCP implant, such as fractures of the implant, periprosthetic bone osteolysis, deterioration of the outcome and technical difficulties in revision surgery, have led to development work to invent alternative implants. Aseptic loosening problems often occurring with metallic and other inelastic implants, especially in the rheumatoid hand, directed the product development in our team to materials with better biocompatibility with soft rheumatic bone. The bioabsorbable 96L/4D poly-L/D-lactide copolymer, which has been used in orthopaedic devices available on the market since 1999, was chosen as the raw material. The manufacturing process was developed with the aim of creating an implant with desirable mechanical properties associated with an optimal degradation rate, and enabling ingrowth of host tissue into the device.

In the preliminary studies (II and III) no serious adverse events were reported, and the clinical outcome was comparable with the results of silicone arthroplasty in the literature, although 63% of the joints operated on were Larsen IV and V, and although the material included a large number of revision arthroplasties (over 30% of the joints operated on). Active extension improved and flexion deteriorated, which also has been a typical finding after MCP silicone arthroplasties. Transferring the arc of ROM towards extension improves the ability to grip larger objects. Improvement in the ability to perform personal ADL (dressing, eating and personal hygiene) was also assessed. The postoperative ranges of motions (from 46° to 51°) are slightly above the average ROMs after silicone MCP arthroplasty as reported in the literature. Correction of ulnar drift and palmar subluxation were achieved, and well maintained, also beyond the resorption time of the implant. However, a statistically insignificant tendency of progression in palmar subluxation was observed between intermediate and final follow-up. An important aspect disclosed by these studies was that no adverse tissue reactions occurred, either in the phase of

mechanical strength loss or in the monomer elimination phase. Osteolytic changes were minimal, on average 59 months after surgery in 4% of cases over 2 mm resorption was measured, and never exceeded 4 mm. This indicates indirectly that the degradation rate and volume of the implant were on a par with the clearing capacity of the tissue.

Compared to the Swanson prosthesis a fairly similar outcome was observed on average two years after surgery. Improvement was observed in lack of extension, pain, ulnar drift, power grip and functional grips, and no statistically significant differences were seen in postoperative values between the PLDLA and Swanson groups. Palmar subluxation improved significantly in both groups, but in the PLDLA group there was a tendency of the volar subluxation to recur. In the Swanson group no palmar subluxation was seen in 82% of joints at follow-up, whereas only 48% of joints were in proper alignment in the PLDLA group. Although the palmar subluxation was mainly partial and only 7% of the joints were totally dislocated, the maintenance of palmar alignment in the PLDLA group was not as good as in the Swanson group. Assessments of palmar subluxation have not been reported in the literature of silicone MCP arthroplasties, whereas the recurrence of the ulnar drift has been a common finding. The problem is the inaccuracy of the evaluation of the palmar subluxation. Clinical assessment by inspection and palpation is unreliable and radiological assessment is heavily dependent on the quality and standardisation of the X-rays. The implications of the recurrence of palmar subluxation for the outcome of MCP arthroplasty are uncertain. Theoretically palmar subluxation impairs extension, but in this study lack of extension at follow-up in the PLDLA group was similar to that in the Swanson group. The recurrence of palmar displacement was partial, which may explain the good extension. The motion of the joint along the implant axis, for which the exact alignment of the joint is necessary, is important for the survival of biostable prostheses, but when bioabsorbable implants are used implant fracture is not an issue. However, in the long run palmar subluxation probably disturbs the sensitive tendon balance of the fingers.

Implant fracture and related problems do not occur when PLDLA bioabsorbable implants are used, thus the patients can be allowed to carry heavy objects. Bone osteolysis seems to be rare at the midterm follow-up (4%), and is restricted to joint surface area and does not occur in the diaphyseal area. A stemless PLDLA implant enables bone grafting into the intramedullary canals in revision surgery, which is one of the distinct advantages of this implant. The correction of ulnar drift was maintained well in all studies.

### 3. Methodological considerations

The data in all studies in the present thesis was collected prospectively but only one study (IV) was a randomised clinical trial, and no control groups were included in the other studies. The randomised study was not double-blinded. The investigators also operated on patients and took care of postoperative controls seeing the chosen implant in the operation and in the x-rays. Small sample size was a weakness in Studies I, II and III. Partial arthrodesis of the wrist (Study I) is a relatively

infrequent operation, which limits patient recruitment. The significance of the results is diminished by the small sample sizes; especially in subgroup analyses such as those in Study I. Limited material is explicable in the implementation of the novel device in Studies II and III, in which the short-term biocompatibility and mid-term clinical outcome of the 96L/4D poly-L/D-lactide copolymer implant were studied. In the world of science these descriptive and observational studies are obviously not ranked as highly as randomised double-blinded studies, but in the literature on rheumatoid hand surgery randomised clinical trials are rare.

Radiological measurements are prone to inaccuracy due to the variation in x-ray projections, especially when the findings are minor, as in the examination of bone erosions and osteolysis in this study. In Studies I-III the x-rays were taken in the same unit and education of the projections was provided before the study to improve repeatability. A cradle was used to enhance the standardisation of the supine oblique projection of the hand.

## 4. Future considerations

The conservative treatment of rheumatoid arthritis has improved significantly in recent years, which presumably inhibits the arthritic progression of the midcarpal joint after partial radiocarpal arthrodesis. Active and close co-operation between rheumatologists and surgeons, which improves the timing of surgical interventions, should be strengthened. Partial wrist arthrodesis is a typical example of an operation with a limited “time window” for its performance, but compared to the gold standard total arthrodesis operation it preserves the motion of the wrist joint. The variation in the outcome after partial wrist arthrodesis in the treatment of the rheumatoid hand partly reflects the technical demands of the operation. The results of a technically demanding operation can be improved by cumulative experience based on increasing volumes of operations performed by a single surgeon, which in relatively infrequent operations means that some specialisation and centralisation are useful.

In this thesis the outcome of the novel 96L/4D poly-L/D-lactide copolymer implant in the treatment of rheumatoid hand MCP joints is overall comparable with that of the gold standard silicone prosthesis, and due to recently acquired CE marking wider clinical experience can be gathered. A higher volar subluxation tendency in the PLDLA group compared to the Swanson group was seen in the randomised study (IV), and this must be followed and studied more closely, especially beyond the resorption time of the implant. The degradation of scaffolds can be tailored by material technical actions, for example changing polymer and fibre processing conditions (Paakinaho, Ellä, Syrjälä, & Kellomäki, 2009). The design with polyethylene oxide and polybutylene terephthalate stems did not yield on improvement, because major osteolysis and inflammatory foreign-body reaction were reported in the experimental study in minipigs (Waris, Ashammakhi, Lehtimäki, Tulamo, Tormala, Kellomäki, & Kontinen, 2008). In addition to the development work of implant design, the enhancement of the balancing technique of the soft tissues may reduce the tendency of volar subluxation.

Rheumatoid arthritis patients present in increasingly better condition and have a more active lifestyle due to effective medical treatment, which may also imply more powerful use of hands operated on and greater loads on the silicone MCP joints. The need for longlasting implants with less bone reaction in more active patients is also evident. Active basic and clinical research work is needed to find suitable materials and designs for the implants for this small market.



## SUMMARY AND CONCLUSIONS

1. Partial radiocarpal arthrodesis in surgery of the rheumatoid wrist in Larsen II-III stages yields good pain relief and subjective satisfaction and preserves the functional range of motion of the joint. Ulnar translocation malalignment can be corrected and maintained.
2. MCP joint arthroplasty with the novel bioabsorbable 96L/4D poly-L/D-lactide copolymer implant enables correction of ulnar drift, relieves pain and restores the arc of motion towards extension.
3. Clinical results beyond the resorption time of the 96L/4D poly-L/D-lactide copolymer implant were sustained and comparable with earlier silicone arthroplasty results. Osteolytic changes were minimal at average 59 months of follow-up.
4. The subjective and objective outcomes of bioabsorbable 96L/4D poly-L/D-lactide copolymer arthroplasty were comparable to those of Swanson arthroplasty except for more frequent recurrence of palmar subluxation in the PLDLA group.

# ACKNOWLEDGEMENTS

I have been working on this research for a long time, which means that numerous people need to be fully acknowledged. I wish to thank you all – and I hope that I have remembered to express my deepest thanks to you already during the time we spent together.

My supervisors, Professor Matti U.K. Lehto and Professor Yrjö T Konttinen, truly deserve the most sincere thanks. Matti Lehto introduced me to rheumaorthopaedics – both to the clinical work and to research activities – at the end of the 1990s. His persevering support and guidance were invaluable in carrying out this work. Yrjö T. Konttinen helped me solve numerous challenging problems and his enthusiastic attitude brought me back to research activities. I am deeply grateful to him for the enhancement of my scientific writing.

I want to express my gratitude to all co-authors of the original articles. I am extremely grateful to Professor Minna Kellomäki for introducing me to the world of bioabsorbable materials and her comments on my manuscript text concerning material technology. I want especially to thank Tiina Parviainen and Raili Salmelin for their invaluable help in statistics.

I am deeply grateful to all the doctors, nurses and hand therapists involved in this study, including those at the Heinola Rheumatism Foundation Hospital. I want to thank the entire personnel in the Centre of Rheumatic Diseases at Tampere University Hospital, and especially my nearest workmates in the Rheumaorthopaedic Division for their positive attitude and comprehensive care of the patients. I also wish express my sincere thanks to my friend, our professional occupational therapist, Siru Mäkelä for her contribution to this research work and for her long-lasting support and encouragement. I have been privileged indeed to have such a team around me in both clinical and research work.

I also wish to express my sincere gratitude to the personnel at Tampere University Library, Department of Health Sciences and mainly the same people at the former Medical Library of Tampere University Hospital for their unfailing help with literature and with the computer programs.

I wish to warmly thank Virginia Mattila MA for her careful and effective revision of the English language in this dissertation.

My warmest thanks also go to the official reviewers of this dissertation, Docent Juhana Leppilahti and Docent Tuulikki Sokka-Isler, for highlighting the weak points in the dissertation manuscript. Your comments led to an improvement of this manuscript and provided me with some new insights into the theme of this work.

Moreover, I want to thank all my dear friends for their encouragement and for offering me something else to think about and do – outdoor living, dining and philosophical discussions – late into the evenings.

Most of all, I want to thank my husband Petri for his endless optimism, encouragement and love during these years; and our children, Pia and Sanna, for bringing joy and cheerful challenges to my everyday life. I am fortunate to have Risto in our family; he radiates positive attitude and light wherever he appears. I also wish to express my gratitude to my parents and my parents-in-law for their support.

And finally, I want to thank the Finnish Research Foundation for Orthopaedics and Traumatology, the competitive research funding of the Pirkanmaa Hospital District, the Tampere Science Foundation and the Tampere branch of the Finnish Rheumatism Association for their financial support of this study.

# REFERENCES

- Abboud, J. A., Beredjikian, P. K., & Bozentka, D. J. (2003). Metacarpophalangeal joint arthroplasty in rheumatoid arthritis. *Journal of the American Academy of Orthopaedic Surgeon* 11(3), 184-191.
- Aho, K., Kaipiainen-Seppanen, O., Heliövaara, M., & Klaukka, T. (1998). Epidemiology of rheumatoid arthritis in Finland. *Seminars in Arthritis & Rheumatism* 27(5), 325-334.
- Ambrose, C. G., & Clanton, T. O. (2004). Bioabsorbable implants: Review of clinical experience in orthopedic surgery. *Annals of Biomedical Engineering* 32(1), 171-177.
- Arimitsu, S., Murase, T., Hashimoto, J., Oka, K., Sugamoto, K., Yoshikawa, H., & Moritomo, H. (2007). A three-dimensional quantitative analysis of carpal deformity in rheumatoid wrists. *Journal of Bone & Joint Surgery - British Volume* 89(4), 490-494.
- Arimitsu, S., Sugamoto, K., Hashimoto, J., Murase, T., Yoshikawa, H., & Moritomo, H. (2008). Analysis of radiocarpal and midcarpal motion in stable and unstable rheumatoid wrists using 3-dimensional computed tomography. *Journal of Hand Surgery - American Volume* 33(2), 189-197.
- Ashammakhi, N., Peltoniemi, H., Waris, E., Suuronen, R., Serlo, W., Kellomäki, M., . . . Waris, T. (2001). Developments in craniomaxillofacial surgery: Use of self-reinforced bioabsorbable osteofixation devices. *Plastic & Reconstructive Surgery* 108(1), 167-180.
- Ashammakhi, N., Suuronen, R., Tiainen, J., Tormala, P., & Waris, T. (2003). Spotlight on naturally absorbable osteofixation devices. *Journal of Craniofacial Surgery* 14(2), 247-259.
- Bass, R. L., Stern, P. J., & Nairus, J. G. (1996). High implant fracture incidence with sutter silicone metacarpophalangeal joint arthroplasty. *Journal of Hand Surgery - American Volume* 21(5), 813-818.
- Beevers, D. J., & Seedhom, B. B. (1995). Metacarpophalangeal joint prostheses. A review of the clinical results of past and current designs. *Journal of Hand Surgery - British Volume* 20(2), 125-136.
- Belt, E. A., Kaarela, K., & Lehto, M. U. (1998). Destruction and reconstruction of hand joints in rheumatoid arthritis. A 20 year followup study. *Journal of Rheumatology* 25(3), 459-461.

- Bjork, M., Thyberg, I., Haglund, L., & Skogh, T. (2006). Hand function in women and men with early rheumatoid arthritis. A prospective study over three years (the swedish TIRA project). *Scandinavian Journal of Rheumatology* 35(1), 15-19.
- Blomqvist, P., Haglund, U., Knutson, K., Lundborg, G., Marké, L., Nived, O., . . . Svensson, B. (2000). Rheumatic diseases-surgical treatment. A systematic literature review by SBU-the swedish council on technology assessment in health care. *Acta Orthopaedica Scandinavica Supplementum* 294:1-88.
- Bogoch, E. R., & Judd, M. G. (2002). The hand: A second face? *Journal of Rheumatology* 29(12), 2477-2483.
- Borisch, N., & Haussmann, P. (2002). Radiolunate arthrodesis in the rheumatoid wrist: A retrospective clinical and radiological longterm follow-up. *Journal of Hand Surgery - British Volume* 27(1), 61-72.
- Brumfield, R. H., & Champoux, J. A. (1984). A biomechanical study of normal functional wrist motion. *Clinical Orthopaedics & Related Research* (187), 23-25.
- Burke, F. D. (2011). The rheumatoid metacarpophalangeal joint. *Hand Clinics* 27(1), 79-86.
- Cavaliere, C. M., & Chung, K. C. (2008). A systematic review of total wrist arthroplasty compared with total wrist arthrodesis for rheumatoid arthritis. *Plastic & Reconstructive Surgery* 122(3), 813-825.
- Chamay, A., & Della Santa, D. (1991). Radiolunate arthrodesis in rheumatoid wrist (21 cases). *Annals of Hand and Upper Limb Surgery* 10(3), 197-206.
- Chamay, A., Della Santa, D., & Vilaseca, A. (1983). Radiolunate arthrodesis - factor of stability for the rheumatoid wrist. *Annales De Chirurgie De La Main* 2(1), 5-17.
- Chen, C. Y., Chang, C. H., Lu, Y. C., Chang, C. H., Tsai, C. C., & Huang, C. H. (2010). Late foreign-body reaction after treatment of distal radial fractures with poly-L-lactic acid bioabsorbable implants: A report of three cases. *Journal of Bone & Joint Surgery - American Volume* 92(16), 2719-2724.
- Chung, K. C., Burke, F. D., Wilgis, E. F., Regan, M., Kim, H. M., & Fox, D. A. (2009). A prospective study comparing outcomes after reconstruction in rheumatoid arthritis patients with severe ulnar drift deformities. *Plastic & Reconstructive Surgery* 123(6), 1769-1777.
- Chung, K. C., Burns, P. B., Wilgis, E. F., Burke, F. D., Regan, M., Kim, H. M., & Fox, D. A. (2009). A multicenter clinical trial in rheumatoid arthritis comparing silicone metacarpophalangeal joint arthroplasty with medical treatment. *Journal of Hand Surgery - American Volume* 34(5), 815-823.

- Chung, K. C., & Kotsis, S. V. (2010). Outcomes of hand surgery in the patient with rheumatoid arthritis. *Current Opinion in Rheumatology* 22(3), 336-341.
- Chung, K. C., Kotsis, S. V., & Kim, H. M. (2004). A prospective outcomes study of swanson metacarpophalangeal joint arthroplasty for the rheumatoid hand. *Journal of Hand Surgery - American Volume* 29(4), 646-653.
- Chung, K. C., Kotsis, S. V., Kim, H. M., Burke, F. D., & Wilgis, E. F. (2006). Reasons why rheumatoid arthritis patients seek surgical treatment for hand deformities. *Journal of Hand Surgery - American Volume* 31(2), 289-294.
- Chung, K. C., Kowalski, C. P., Myra Kim, H., & Kazmers, I. S. (2000). Patient outcomes following swanson silastic metacarpophalangeal joint arthroplasty in the rheumatoid hand: A systematic overview. *Journal of Rheumatology* 27(6), 1395-1402.
- Clark, D. I., Delaney, R., Stilwell, J. H., Trail, I. A., & Stanley, J. K. (2001). The value of crossed intrinsic transfer after metacarpophalangeal silastic arthroplasty: A comparative study. *Journal of Hand Surgery - British Volume* 26(6), 565-567.
- Cook, S. D., Beckenbaugh, R. D., Redondo, J., Popich, L. S., Klawitter, J. J., & Linscheid, R. L. (1999). Long-term follow-up of pyrolytic carbon metacarpophalangeal implants. *Journal of Bone & Joint Surgery - American Volume* 81(5), 635-648.
- Cordewene, F. W., van Geffen, M. F., Joziassse, C. A., Schmitz, J. P., Bos, R. R., Rozema, F. R., & Pennings, A. J. (2000). Cytotoxicity of poly(96L/4D-lactide): The influence of degradation and sterilization. *Biomaterials* 21(23), 2433-2442.
- Delaney, R., Trail, I. A., & Nuttall, D. (2005). A comparative study of outcome between the neuflex and swanson metacarpophalangeal joint replacements. *Journal of Hand Surgery - British Volume* 30(1), 3-7.
- Della Santa, D., & Chamay, A. (1995). Radiological evolution of the rheumatoid wrist after radio-lunate arthrodesis. *Journal of Hand Surgery - British Volume* 20(2), 146-154.
- Dias, J. J., Smith, M., Singh, H. P., & Ullah, A. S. (2009). The working space of the hand in rheumatoid arthritis: Its impact on disability. *Journal of Hand Surgery: European Volume* 34(4), 465-470.
- DiBenedetto, M. R., Lubbers, L. M., & Coleman, C. R. (1991). Relationship between radial inclination angle and ulnar deviation of the fingers. *Journal of Hand Surgery - American Volume* 16(1), 36-39.
- Doets, H. C., & Raven, E. E. (1999). A procedure for stabilising and preserving mobility in the arthritic wrist. *Journal of Bone & Joint Surgery - British Volume* 81(6), 1013-1016.

- Egloff, D. (1998). Arthroplasties of the metacarpophalangeal joints in the rheumatoid hand. In Y. Allieu (Ed.), *The rheumatoid hand and wrist: Surgical treatment, medical treatment - physiotherapy and rehabilitation* (pp. 105-120). Paris France: Expansion Scientifique Publications.
- Ellä, V., Annala, T., Länsman, S., Nurminen, M., & Kellomäki, M. (2011). Knitted polylactide 96/4 L/D structures and scaffolds for tissue engineering shelf life, in vitro and in vivo studies. *Biomatter* 1(1), 1-12.
- Escott, B. G., Ronald, K., Judd, M. G., & Bogoch, E. R. (2010). NeuFlex and swanson metacarpophalangeal implants for rheumatoid arthritis: Prospective randomized, controlled clinical trial. *Journal of Hand Surgery - American Volume* 35(1), 44-51.
- Feldon, P., Terrono, A. L., Nalebuff, E. A., & Millender, L. H. (2005). Rheumatoid arthritis and other connective tissue diseases. In D. P. Green, R. N. Hotchkiss, W. C. Pederson & S. W. Wolfe (Eds.), *Greens's operative hand surgery* (pp. 2049-2136). Philadelphia, Pennsylvania: Elsevier Churchill Livingstone.
- Flatt, A. E. (1996). Ulnar drift. *Journal of Hand Therapy* 9(4), 282-292.
- Flury, M. P., Herren, D. B., & Simmen, B. R. (1999). Rheumatoid arthritis of the wrist. classification related to the natural course. *Clinical Orthopaedics & Related Research* (366), 72-77.
- Gaulke, R., Suppelna, G., Hildebrand, F., Citak, M., Hufner, T., & Krettek, C. (2010). Radiolunate fusion in the rheumatoid wrist with shapiro staples: Clinical and radiological results of 22 cases. *Journal of Hand Surgery: European Volume* 35(4), 289-295.
- Gellman, H., Stetson, W., Brumfield, R. H., Jr, Costigan, W., & Kuschner, S. H. (1997). Silastic metacarpophalangeal joint arthroplasty in patients with rheumatoid arthritis. *Clinical Orthopaedics & Related Research* (342), 16-21.
- Ghattas, L., Mascella, F., & Pomponio, G. (2005). Hand surgery in rheumatoid arthritis: State of the art and suggestions for research. *Rheumatology* 44(7), 834-845.
- Givissis, P. K., Stavridis, S. I., Papagelopoulos, P. J., Antonarakos, P. D., & Christodoulou, A. G. (2010). Delayed foreign-body reaction to absorbable implants in metacarpal fracture treatment. *Clinical Orthopaedics & Related Research* 468(12), 3377-3383.
- Goldfarb, C. A., & Dovan, T. T. (2006). Rheumatoid arthritis: Silicone metacarpophalangeal joint arthroplasty indications, technique, and outcomes. *Hand Clinics* 22(2), 177-182.
- Goldfarb, C. A., & Stern, P. J. (2003). Metacarpophalangeal joint arthroplasty in rheumatoid arthritis. A long-term assessment. *Journal of Bone & Joint Surgery - American Volume* 85-A(10), 1869-1878.

- Gotze, J. P., & Jensen, C. H. (2000). Follow-up of volar plate interposition arthroplasty (tupper) of the metacarpophalangeal joints in rheumatoid hands: Preliminary findings. *Scandinavian Journal of Plastic & Reconstructive Surgery & Hand Surgery* 34(3), 249-251.
- Hamalainen, M., Kammonen, M., Lehtimäki, M., Nurmi, V. -, Repo, A., Ikavalko, M., . . . Kaarela, K. (1992). Epidemiology of wrist involvement in rheumatoid arthritis. In B. R. Simmen, & F. -. Hagen (Eds.), *The wrist in rheumatoid arthritis* (pp. 1-8). Basel: Karger.
- Hansraj, K. K., Ashworth, C. R., Ebrahimzadeh, E., Todd, A. O., Griffin, M. D., Ashley, E. M., & Cardilli, A. M. (1997). Swanson metacarpophalangeal joint arthroplasty in patients with rheumatoid arthritis. *Clinical Orthopaedics & Related Research* (342), 11-15.
- Harris, E. D., Jr. (1990). Rheumatoid arthritis. pathophysiology and implications for therapy. *New England Journal of Medicine* 322(18), 1277-1289.
- Hekmat, K., Jacobsson, L., Nilsson, J. A., Petersson, I. F., Robertsson, O., Garellick, G., & Turesson, C. (2011). Decrease in the incidence of total hip arthroplasties in patients with rheumatoid arthritis--results from a well defined population in south sweden. *Arthritis Research & Therapy* 13(2), R67.
- Herren, D. B., & Ishikawa, H. (2005). Partial arthrodesis for the rheumatoid wrist. *Hand Clinics* 21(4), 545-552.
- Hodgson, S. P., Stanley, J. K., & Muirhead, A. (1989). The wrightington classification of rheumatoid wrist X-rays: A guide to surgical management. *Journal of Hand Surgery - British Volume* 14(4), 451-455.
- Isenberg, D. A., Maddison, P. J., Woo, P., Glass, D., & Breedveld, F. C. (Eds.). (2004). *Oxford textbook of rheumatology* (3rd ed.). Great Clarendon Street, Oxford OX2 6DP: Oxford University Press.
- Ishikawa, H., Hanyu, T., Saito, H., & Takahashi, H. (1992). Limited arthrodesis for the rheumatoid wrist. *Journal of Hand Surgery - American Volume* 17(6), 1103-1109.
- Ishikawa, H., Murasawa, A., & Nakazono, K. (2005). Long-term follow-up study of radiocarpal arthrodesis for the rheumatoid wrist. *Journal of Hand Surgery - American Volume* 30(4), 658-666.
- Isotalo, T., Alarakkola, E., Talja, M., Tammela, T. L., Valimaa, T., & Tormala, P. (1999). Biocompatibility testing of a new bioabsorbable X-ray positive SR-PLA 96/4 urethral stent. *Journal of Urology* 162(5), 1764-1767.
- Joukainen, A., Pihlajamäki, H., Makela, E. A., Ashammakhi, N., Viljanen, J., Patiala, H., . . . Rokkanen, P. (2000). Strength retention of self-reinforced drawn poly-L/DL-lactide 70/30 (SR-PLA70) rods and fixation properties of distal



- femoral osteotomies with these rods. an experimental study on rats. *Journal of Biomaterials Science, Polymer Edition* 11(12), 1411-1428.
- Joyce, T. J. (2004). Currently available metacarpophalangeal prostheses: Their designs and prospective considerations. *Expert Review of Medical Devices* 1(2), 193-204.
- Kaipiainen-Seppänen, O., Aho, K., Isomäki, H., & Laakso, M. (1996). Incidence of rheumatoid arthritis in Finland during 1980-1990. *Annals of the Rheumatic Diseases* 55(9), 608-611.
- Kellomäki, M., Niiranen, H., Puumanen, K., Ashammakhi, N., Waris, T., & Tormala, P. (2000). Bioabsorbable scaffolds for guided bone regeneration and generation. *Biomaterials* 21(24), 2495-2505.
- Kellomäki, M., Puumanen, K., Waris, T., & Törmälä, P. (2000). *In vivo* degradation of composite membrane of P(e-CL/LLA) 50/50 film and P(L/D)LA 96/4 mesh. In H. Stallforth, & P. Revell (Eds.), *Materials for medical engineering* (pp. 73-79). Weinheim, Germany: Wiley-VCH.
- Kellomäki, M., & Törmälä, P. (2003). Processing of resorbable poly- $\alpha$ -hydroxy acids for use as tissue-engineering scaffolds. In A. P. Hollander, & P. V. Hatton (Eds.), *Methods in molecular biology* (pp. 1-10) The Human Press Inc.
- Khan, N. A., & Sokka, T. (2011). Declining needs for total joint replacements for rheumatoid arthritis. *Arthritis Research & Therapy*, 13(5), 130-131.
- Kirschenbaum, D., Schneider, L. H., Adams, D. C., & Cody, R. P. (1993). Arthroplasty of the metacarpophalangeal joints with use of silicone-rubber implants in patients who have rheumatoid arthritis. long-term results. *Journal of Bone & Joint Surgery - American Volume* 75(1), 3-12.
- Kolling, C., Herren, D. B., Simmen, B. R., & Goldhahn, J. (2009). Changes in surgical intervention patterns in rheumatoid arthritis over 10 years in one centre. *Annals of the Rheumatic Diseases*, 68(8), 1372-1373.
- Koort, J. K., Mäkinen, T. J., Suokas, E., Veiranto, M., Jalava, J., Tormala, P., & Aro, H. T. (2008). Sustained release of ciprofloxacin from an osteoconductive poly(DL)-lactide implant. *Acta Orthopaedica* 79(2), 295-301.
- Korpela, M., Laasonen, L., Hannonen, P., Kautiainen, H., Leirisalo-Repo, M., Hakala, M., . . . FIN-RACo Trial, G. (2004). Retardation of joint damage in patients with early rheumatoid arthritis by initial aggressive treatment with disease-modifying antirheumatic drugs: Five-year experience from the FIN-RACo study. *Arthritis & Rheumatism* 50(7), 2072-2081.
- Kourbeti, I. S., & Boumpas, D. T. (2005). Biological therapies of autoimmune diseases. *Current Drug Targets - Inflammation & Allergy* 4(1), 41-46.

- Lansman, S., Paakko, P., Ryhanen, J., Kellomaki, M., Waris, E., Tormala, P., . . . Ashammakhi, N. (2006). Poly-L/D-lactide (PLDLA) 96/4 fibrous implants: Histological evaluation in the subcutis of experimental design. *Journal of Craniofacial Surgery* 17(6), 1121-1128.
- Larsen, A. (1995). How to apply larsen score in evaluating radiographs of rheumatoid arthritis in long-term studies. *Journal of Rheumatology* 22(10), 1974-1975.
- Larsen, A., Dale, K., & Eek, M. (1977). Radiographic evaluation of rheumatoid arthritis and related conditions by standard reference films. *Acta Radiologica: Diagnosis* 18(4), 481-491.
- Lazennec, J. Y., Madi, A., Rousseau, M. A., Roger, B., & Saillant, G. (2006). Evaluation of the 96/4 PLDLLA polymer resorbable lumbar interbody cage in a long term animal model. *European Spine Surgery* 15, 1545-1553.
- Lehtimäki, M., Lehto, M., Kellomäki, M., Paasimäki, S., Mäkelä, S., Honkanen, P., & Törmälä, P. (1998). Resorboituva tekonivel reumapotilaiden rystysnivelten hoidossa. *Suomen Ortopedia Ja Traumatologia* 21, 368-370.
- Li, Z. M., Kuxhaus, L., Fisk, J. A., & Christophel, T. H. (2005). Coupling between wrist flexion-extension and radial-ulnar deviation. *Clinical Biomechanics* 20(2), 177-183.
- Linscheid, R. L. (2000). Implant arthroplasty of the hand: Retrospective and prospective considerations. *Journal of Hand Surgery - American Volume* 25(5), 796-816.
- Linscheid, R. L., & Dobyns, J. H. (1971). Rheumatoid arthritis of the wrist. *Orthopedic Clinics of North America* 2(3), 649-665.
- Linscheid, R. L., & Dobyns, J. H. (1985). Radiolunate arthrodesis. *Journal of Hand Surgery - American Volume* 10(6 Pt 1), 821-829.
- Little, K. J., & Stern, P. J. (2007). Rheumatoid arthritis - skeletal reconstruction. In T. E. Trumble, & J. E. Budoff (Eds.), *Hand surgery update IV* (pp. 655-672). Rosemont, Illinois: American Society for Surgery of the Hand.
- Louie, G. H., & Ward, M. M. (2010). Changes in the rates of joint surgery among patients with rheumatoid arthritis in california, 1983-2007. *Annals of the Rheumatic Diseases* 69(5), 868-871.
- Maenpää, K., Ella, V., Mauno, J., Kellomäki, M., Suuronen, R., Ylikomi, T., & Miettinen, S. (2010). Use of adipose stem cells and polylactide discs for tissue engineering of the temporomandibular joint disc. *Journal of the Royal Society Interface* 7(42), 177-188.

- Mandl, L. A., Galvin, D. H., Bosch, J. P., George, C. C., Simmons, B. P., Axt, T. S., . . . Katz, J. N. (2002). Metacarpophalangeal arthroplasty in rheumatoid arthritis: What determines satisfaction with surgery? *Journal of Rheumatology* 29(12), 2488-2491.
- Massy-Westropp, N., Massy-Westropp, M., Rankin, W., & Krishnan, J. (2003). Metacarpophalangeal arthroplasty from the patient's perspective. *Journal of Hand Therapy* 16(4), 315-319.
- Masuko, T., Iwasaki, N., Ishikawa, J., Kato, H., & Minami, A. (2009). Radiolunate fusion with distraction using corticocancellous bone graft for minimizing decrease of wrist motion in rheumatoid wrists. *Hand Surgery* 14(1), 15-21.
- McArthur, P. A., & Milner, R. H. (1998). A prospective randomized comparison of sutter and swanson silastic spacers. *Journal of Hand Surgery - British Volume* 23(5), 574-577.
- Merolli, A. (2009). Prosthesis for the joints of the hand. In A. Merolli, & T. J. Joyce (Eds.), *Biomaterials in hand surgery* (pp. 47-68). Italia: Springer Verlag.
- Meyerdierks, E. M., Mosher, J. F., & Werner, F. W. (1987). Limited wrist arthrodesis: A laboratory study. *Journal of Hand Surgery - American Volume* 12(4), 526-529.
- Middleton, J. C., & Tipton, A. J. (2000). Synthetic biodegradable polymers as orthopedic devices. *Biomaterials* 21(23), 2335-2346.
- Moller, K., Sollerman, C., Geijer, M., Kopylov, P., & Tagil, M. (2005). Avanta versus swanson silicone implants in the MCP joint--a prospective, randomized comparison of 30 patients followed for 2 years. *Journal of Hand Surgery - British Volume* 30(1), 8-13.
- Moran, S. L., & Bishop, A. T. (2007). Clinical update: Surgical management of rheumatoid hand. *Lancet* 370(9585), 372-374.
- Nakamura, H., Nagashima, M., Ishigami, S., Wauke, K., & Yoshino, S. (2000). The anti-rheumatic effect of multiple synovectomy in patients with refractory rheumatoid arthritis. *International Orthopaedics* 24(5), 242-245.
- Nalebuff, E. A. (1984). The rheumatoid hand. reflections on metacarpophalangeal arthroplasty. *Clinical Orthopaedics & Related Research* (182), 150-159.
- O'Brien, E. T. (1996). Surgical principles and planning for the rheumatoid hand and wrist. *Clinics in Plastic Surgery* 23(3), 407-420.
- Paakinaho, K., Ellä, V., Syrjälä, S., & Kellomäki, M. (2009). Melt spinning of poly(L/D)lactide 96/4: Effects of molecular weight and melt processing on hydrolytic degradation. *Polymer Degradation and Stability* 94(3), 438-442.

- Paatola, T., Kellomäki, M., & Törmälä, P. (2000). Poly (L/D) lactide 96/4 copolymer filaments. *Proceedings of FiberMed* 261-265.
- Pahle, J. A., & Raunio, P. (1969). The influence of wrist position on finger deviation in the rheumatoid hand. A clinical and radiological study. *Journal of Bone & Joint Surgery - British Volume* 51(4), 664-676.
- Palmer, A. K., Werner, F. W., Murphy, D., & Glisson, R. (1985). Functional wrist motion: A biomechanical study. *Journal of Hand Surgery - American Volume* 10(1), 39-46.
- Pap, G., Angst, F., Herren, D., Schwyzer, H. K., & Simmen, B. R. (2003). Evaluation of wrist and hand handicap and postoperative outcome in rheumatoid arthritis. *Hand Clinics* 19(3), 471-481.
- Paplanus, S. H., & Payne, C. M. (1988). Axillary lymphadenopathy 17 years after digital silicone implants: Study with x-ray microanalysis. *Journal of Hand Surgery - American Volume* 13(3), 399-400
- Papp, S. R., Athwal, G. S., & Pichora, D. R. (2006). The rheumatoid wrist. *Journal of the American Academy of Orthopaedic Surgeons* 14(2), 65-77.
- Parker, W., Moran, S. L., Hormel, K. B., Rizzo, M., & Beckenbaugh, R. D. (2006). Nonrheumatoid metacarpophalangeal joint arthritis. unconstrained pyrolytic carbon implants: Indications, technique, and outcomes. *Hand Clinics* 22(2), 183-193.
- Parker, W. L., Rizzo, M., Moran, S. L., Hormel, K. B., & Beckenbaugh, R. D. (2007). Preliminary results of nonconstrained pyrolytic carbon arthroplasty for metacarpophalangeal joint arthritis. *Journal of Hand Surgery - American Volume* 32(10), 1496-1505.
- Parkkila, T., Belt, E. A., Hakala, M., Kautiainen, H., & Leppilahti, J. (2005). Comparison of swanson and sutter metacarpophalangeal arthroplasties in patients with rheumatoid arthritis: A prospective and randomized trial. *Journal of Hand Surgery - American Volume* 30(6), 1276-1281.
- Parkkila, T., Hakala, M., Kautiainen, H., Leppilahti, J., & Belt, E. A. (2006). Osteolysis after sutter metacarpophalangeal arthroplasty: A prospective study of 282 implants followed up for 5.7 years. *Scandinavian Journal of Plastic & Reconstructive Surgery & Hand Surgery* 40(5), 297-301.
- Parkkila, T. J., Belt, E. A., Hakala, M., Kautiainen, H. J., & Leppilahti, J. (2006). Survival and complications are similar after swanson and sutter implant replacement of metacarpophalangeal joints in patients with rheumatoid arthritis. *Scandinavian Journal of Plastic & Reconstructive Surgery & Hand Surgery* 40(1), 49-53.

- Pereira, J. A., & Belcher, H. J. (2001). A comparison of metacarpophalangeal joint silastic arthroplasty with or without crossed intrinsic transfer. *Journal of Hand Surgery - British Volume* 26(3), 229-234.
- Pettersson, K., Wagnsjo, P., & Hulin, E. (2006). NeuFlex compared with sutter prostheses: A blind, prospective, randomised comparison of silastic metacarpophalangeal joint prostheses. *Scandinavian Journal of Plastic & Reconstructive Surgery & Hand Surgery* 40(5), 284-290.
- Pincus, T., Sokka, T., & Kautiainen, H. (2005). Patients seen for standard rheumatoid arthritis care have significantly better articular, radiographic, laboratory, and functional status in 2000 than in 1985. *Arthritis & Rheumatism* 52(4), 1009-1019.
- Puolakka, K., Kautiainen, H., Mottonen, T., Hannonen, P., Korpela, M., Hakala, M., . . . FIN-RACo Trial, G. (2005). Early suppression of disease activity is essential for maintenance of work capacity in patients with recent-onset rheumatoid arthritis: Five-year experience from the FIN-RACo trial. *Arthritis & Rheumatism* 52(1), 36-41.
- Rantalaiho, V., Korpela, M., Laasonen, L., Kautiainen, H., Jarvenpaa, S., Hannonen, P., . . . FIN-RACo Trial, G. (2010). Early combination disease-modifying antirheumatic drug therapy and tight disease control improve long-term radiologic outcome in patients with early rheumatoid arthritis: The 11-year results of the finnish rheumatoid arthritis combination therapy trial. *Arthritis Research & Therapy*, 12(3), R122.
- Rittmeister, M., Porsch, M., Starker, M., & Kerschbaumer, F. (1999). Metacarpophalangeal joint arthroplasty in rheumatoid arthritis: Results of swanson implants and digital joint operative arthroplasty. *Archives of Orthopaedic & Trauma Surgery* 119(3-4), 190-194.
- Rizio, L., & Belsky, M. R. (1996). Finger deformities in rheumatoid arthritis. *Hand Clinics* 12(3), 531-540.
- Rohde, R. S., Crisco, J. J., & Wolfe, S. W. (2010). The advantage of throwing the first stone: How understanding the evolutionary demands of homo sapiens is helping us understand carpal motion. *Journal of the American Academy of Orthopaedic Surgeons* 18(1), 51-58.
- Ruther, W., Verhestraeten, B., Fink, B., & Tillmann, K. (1995). Resection arthroplasty of the metacarpophalangeal joints in rheumatoid arthritis. results after more than 15 years. *Journal of Hand Surgery - British Volume* 20(5), 707-715.
- Ryu, J. Y., Cooney, W. P., 3rd, Askew, L. J., An, K. N., & Chao, E. Y. (1991). Functional ranges of motion of the wrist joint. *Journal of Hand Surgery - American Volume* 16(3), 409-419.

- Saikku-Backstrom, A., Tulamo, R. M., Raiha, J. E., Kellomaki, M., Toivonen, T., Tormala, P., & Rokkanen, P. (2001). Intramedullary fixation of cortical bone osteotomies with absorbable self-reinforced fibrillated poly-96L/4D-lactide (SR-PLA96) rods in rabbits. *Biomaterials* 22(1), 33-43.
- Saikku-Backstrom, A., Tulamo, R. M., Raiha, J. E., Pohjonen, T., Toivonen, T., Tormala, P., & Rokkanen, P. (2004). Intramedullary fixation of femoral cortical osteotomies with interlocked biodegradable self-reinforced poly-96L/4D-lactide (SR-PLA96) nails. *Biomaterials* 25(13), 2669-2677.
- Santin, M. (2009). Potential applications of tissue engineering in hand surgery. In A. Merolli, & T. J. Joyce (Eds.), *Biomaterials in hand surgery* (pp. 13-29). Italia: Springer-Verlag.
- Schmidt, K., Willburger, R., Ossowski, A., & Miehle, R. K. (1999). The effect of the additional use of grommets in silicone implant arthroplasty of the metacarpophalangeal joints. *Journal of Hand Surgery - British Volume* 24(5), 561-564.
- Schmidt, K., Willburger, R. E., Miehle, R. K., & Witt, K. (1999). Ten-year follow-up of silicone arthroplasty of the metacarpophalangeal joints in rheumatoid hands. *Scandinavian Journal of Plastic & Reconstructive Surgery & Hand Surgery* 33(4), 433-438.
- Shapiro, J. S. (1996). The wrist in rheumatoid arthritis. *Hand Clinics* 12(3), 477-498.
- Sharp, J. T. (1989). Radiologic assessment as an outcome measure in rheumatoid arthritis. *Arthritis & Rheumatism* 32(2), 221-229.
- Simmen, B. R. (1998). Patterns of carpal collapse in rheumatoid arthritis. In Y. Allieu (Ed.), *The rheumatoid hand and wrist: Surgical treatment, medical treatment - physiotherapy and rehabilitation* (pp. 12-20). Paris France: Expansion Scientifique Publications.
- Simmen, B. R., Bogoch, E. R., & Goldhahn, J. (2008). Surgery insight: Orthopedic treatment options in rheumatoid arthritis. *Nature Clinical Practice Rheumatology* 4(5), 266-273.
- Simmen, B. R., & Huber, H. (1992). The rheumatoid wrist: A new classification related to the type of the natural course and its consequences for surgical therapy. In B. R. Simmen, & F. Hagena (Eds.), *The wrist in rheumatoid arthritis* (pp. 13-25). Basel: Karger.
- Sokka, T. (2009). Long-term outcomes of rheumatoid arthritis. *Current Opinion in Rheumatology* 21(3), 284-290.
- Sollerman, C. J., & Geijer, M. (1996). Polyurethane versus silicone for endoprosthetic replacement of the metacarpophalangeal joints in rheumatoid

- arthritis. *Scandinavian Journal of Plastic & Reconstructive Surgery & Hand Surgery* 30(2), 145-150.
- Souter, W. A. (1979). Planning treatment of the rheumatoid hand. *Hand* 11(1), 3-16.
- Souter, W. A., Sheffield, C. J. G., McGullough, C. J., Meggitt, B. F., & Swann, M. (2002). *Rheumatoid surgery in the united kingdom and ireland*. Edinburgh: The Rheumatoid Arthritis Surgical Society, Albamedia.
- Stanley, J. K. (1998). Surgery for rheumatoid arthrtitis in the hand and wrist. In Y. Allieu (Ed.), *The rheumatoid hand and wrist: Surgical treatment, medical treatment - physiotherapy and rehabilitation* (pp. 181-202). Paris France: Expansion Scientifique Publications.
- Stanley, D., & Norris, S. H. (1988). The pathogenesis and treatment of rheumatoid wrist and hand deformities. *British Journal of Hospital Medicine* 39(2), 156-160.
- Stanley, J. K. (1992). Conservative surgery in the management of rheumatoid disease of the hand and wrist. *Journal of Hand Surgery - British Volume* 17(3), 339-342.
- Stanley, J. K. (1999). Soft tissue surgery in rheumatoid arthritis of the hand. *Clinical Orthopaedics & Related Research* (366), 78-90.
- Stanley, J. K., & Boot, D. A. (1989). Radio-lunate arthrodesis. *Journal of Hand Surgery - British Volume* 14(3), 283-287.
- Stirrat, C. R. (1996). Metacarpophalangeal joints in rheumatoid arthritis of the hand. *Hand Clinics* 12(3), 515-529.
- Straub, L. R. (1959). The rheumatoid hand. *Clinical Orthopaedics* 15, 127-139.
- Sunil, T. M., & Kleinert, H. E. (2006). Fashioning a new radial collateral ligament during arthroplasty of the finger metacarpophalangeal joints in rheumatoid arthritis. *Techniques in Hand & Upper Extremity Surgery* 10(2), 79-86.
- Swanson, A. B. (1997). Silicone rubber implants for replacement of arthritic or destroyed joints in the hand. 1968. *Clinical Orthopaedics & Related Research* (342), 4-10.
- Swanson, A. B., Poitevin, L. A., de Groot Swanson, G., & Kearney, J. (1986). Bone remodeling phenomena in flexible implant arthroplasty in the metacarpophalangeal joints. long-term study. *Clinical Orthopaedics & Related Research* (205), 254-267.
- Synnott, K., Mullett, H., Faull, H., & Kelly, E. P. (2000). Outcome measures following metacarpophalangeal joint replacement. *Journal of Hand Surgery - British Volume* 25(6), 601-603.

- Tagil, M., Geijer, M., Malcus, P., & Kopylov, P. (2009). Correlation between range of motion and implant fracture: A 5 year follow-up of 72 joints in 18 patients in a randomized study comparing swanson and Avanta/Sutter MCP silicone prosthesis. *Journal of Hand Surgery: European Volume* 34(6), 743-747.
- Taleisnik, J. (1989). Rheumatoid arthritis of the wrist. *Hand Clinics* 5(2), 257-278.
- Toyohara, I., Ishikawa, H., Abe, A., Nakazono, K., & Murasawa, A. (2009). Disease activity and the course of wrist joint deterioration over 10 years in the patients with early rheumatoid arthritis. *Modern Rheumatology* 19(1), 47-52.
- Trail, I. A., Martin, J. A., Nuttall, D., & Stanley, J. K. (2004). Seventeen-year survivorship analysis of silastic metacarpophalangeal joint replacement. *Journal of Bone & Joint Surgery - British Volume* 86(7), 1002-1006.
- Trieb, K. (2008). Treatment of the wrist in rheumatoid arthritis. *Journal of Hand Surgery - American Volume* 33(1), 113-123.
- Tubiana, R. (1998). Pathogenesis of the deformities of the rheumatoid wrist. In Y. Allieu (Ed.), *The rheumatoid hand and wrist: Surgical treatment, medical treatment - physiotherapy and rehabilitation* (pp. 5-12). Paris France: Expansion Scientifique Publications.
- Tupper, J. W. (1989). The metacarpophalangeal volar plate arthroplasty. *Journal of Hand Surgery - American Volume* 14(2 Pt 2), 371-375.
- Vahvanen, V., & Viljakka, T. (1986). Silicone rubber implant arthroplasty of the metacarpophalangeal joint in rheumatoid arthritis: A follow-up study of 32 patients. *Journal of Hand Surgery - American Volume* 11(3), 333-339.
- Vainio, K. (1989). Vainio arthroplasty of the metacarpophalangeal joints in rheumatoid arthritis. *Journal of Hand Surgery - American Volume* 14(2 Pt 2), 367-368.
- Vainio, K., Reiman, I., & Pulkki, T. (1967). Results of arthroplasty of the metacarpophalangeal joints in rheumatoid arthritis. *Wiederherstellungschirurgie Und Traumatologie* 9, 1-7.
- van Vugt, R. M., van Jaarsveld, C. H., Hofman, D. M., Helders, P. J., & Bijlsma, J. W. (1999). Patterns of disease progression in the rheumatoid wrist: A long-term followup. *Journal of Rheumatology* 26(7), 1467-1473.
- Waris, E., Ashammakhi, N., Lehtimäki, M., Tulamo, R. M., Kellomäki, M., Tormala, P., & Konttinen, Y. T. (2008). The use of biodegradable scaffold as an alternative to silicone implant arthroplasty for small joint reconstruction: An experimental study in minipigs. *Biomaterials* 29(6), 683-691.
- Waris, E., Ashammakhi, N., Lehtimäki, M., Tulamo, R. M., Tormala, P., Kellomäki, M., & Konttinen, Y. T. (2008). Long-term bone tissue reaction to polyethylene



- oxide/polybutylene terephthalate copolymer (polyactive) in metacarpophalangeal joint reconstruction. *Biomaterials* 29(16), 2509-2515.
- Waris, E., Konttinen, Y. T., Ashammakhi, N., Suuronen, R., & Santavirta, S. (2004). Bioabsorbable fixation devices in trauma and bone surgery: Current clinical standing. *Expert Review of Medical Devices* 1(2), 229-240.
- Watson, H. K., Goodman, M. L., & Johnson, T. R. (1981). Limited wrist arthrodesis. part II: Intercarpal and radiocarpal combinations. *Journal of Hand Surgery - American Volume* 6(3), 223-233.
- Weiss, R. J., Ehlin, A., Montgomery, S. M., Wick, M. C., Stark, A., & Wretenberg, P. (2008). Decrease of RA-related orthopaedic surgery of the upper limbs between 1998 and 2004: Data from 54,579 swedish RA inpatients. *Rheumatology*, 47(4), 491-494.
- Werner, F. W., Green, J. K., Short, W. H., & Masaoka, S. (2004). Scaphoid and lunate motion during a wrist dart throw motion. *Journal of Hand Surgery - American Volume* 29(3), 418-422.
- Wilson, R. L., & Carlblom, E. R. (1989). The rheumatoid metacarpophalangeal joint. *Hand Clinics* 5(2), 223-237.
- Wilson, Y. G., Sykes, P. J., & Niranjana, N. S. (1993). Long-term follow-up of swanson's silastic arthroplasty of the metacarpophalangeal joints in rheumatoid arthritis. *Journal of Hand Surgery - British Volume* 18(1), 81-91.
- Yayama, T., Kobayashi, S., Kokubo, Y., Inukai, T., Mizukami, Y., Kubota, M., . . . Minami, A. (2007). Motion analysis of the wrist joints in patients with rheumatoid arthritis. *Modern Rheumatology* 17(4), 322-326.
- Youm, Y., McMurthy, R. Y., Flatt, A. E., & Gillespie, T. E. (1978). Kinematics of the wrist. I. an experimental study of radial-ulnar deviation and flexion-extension. *Journal of Bone & Joint Surgery - American Volume* 60(4), 423-431.
- Zangger, P., Kachura, J. R., & Bogoch, E. R. (1999). The simmen classification of wrist destruction in rheumatoid arthritis. experience in patients with early disease. *Journal of Hand Surgery - British Volume* 24(4), 400-404.

# Bioreconstructive Joint Scaffold Implant Arthroplasty in Metacarpophalangeal Joints: Short-Term Results of a New Treatment Concept in Rheumatoid Arthritis Patients

P.B. HONKANEN, M.D.,<sup>1</sup> M. KELLOMÄKI, Dr.Tech.,<sup>2</sup> M.Y. LEHTIMÄKI, M.D., Ph.D.,<sup>1</sup>  
P. TÖRMÄLÄ, Ph.D.,<sup>2</sup> S. MÄKELÄ, O.T.,<sup>1</sup> and M.U.K. LEHTO, M.D., Ph.D.<sup>3</sup>

## ABSTRACT

Swanson silicone implant is the “gold standard” of metacarpophalangeal joint reconstruction in rheumatoid arthritis (RA) patients. However, durability problems of silicone implants have led us to develop a new technique based on bioreconstructive implants. PLA96 (poly-L,D-lactide copolymer, L:D ratio of 96:4) scaffolds were engineered. Bioabsorption and substitution of porous PLA96 scaffold with living tissue eventually produce a neojoint. In the current prospective study, 23 RA patients (80 joints) were operated on, using PLA96 implants. Fifteen patients (54 joints) have been monitored for at least 1 year. Pain alleviation was well achieved. Range of motion improvement was emphasized to extension direction of functional arc. The average ulnar deviation was preoperatively 26°, and at follow-up it was 6°. Volar subluxation was noticeable in 56% of joints preoperatively and in 6% at 1-year follow-up. This is the first report of the formation of a living, functional joint *in situ* by means of a synthetic bioreconstructive joint scaffold. Results of this preliminary short-term study are comparable with previously published data on silicone arthroplasty. However, bioreconstructive prostheses can aid in preventing problems that occur with biostable prostheses. Tissue engineering has created a new era in the reconstruction of damaged joints.

## INTRODUCTION

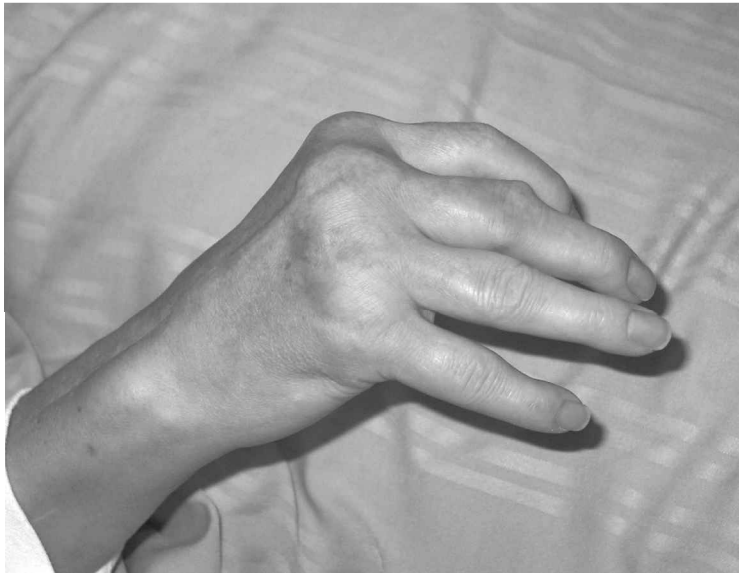**T**HE ARTHRITIC DESTRUCTION of metacarpophalangeal (MCP) joints in rheumatoid arthritis (RA) typically leads to ulnar deviation and volar subluxation of the fingers, which greatly impairs the function of the hand, especially the ability to grasp objects of large size (Fig. 1).<sup>1</sup> The MCP joint, with its complex musculotendinous system, its unusual mobility and stability, and its large applied stresses, has proved to be a difficult challenge in joint replacement design. The nonprosthetic tendon and

volar plate interposition arthroplasties are of historic interest, and continue to have occasional usage.<sup>1</sup> The prosthetic arthroplasty of MCP joints of the fingers was begun with metallic devices in the 1950s.<sup>2</sup> A large number of nonmetallic materials including pyrolytic carbon, ceramics, and ultrahigh molecular weight polyethylene have been used to manufacture MCP joint prosthesis.<sup>3,4</sup> The reports of those studies include several complications: bone resorption, prosthesis migration, infections, foreign body reactions, and prosthesis dismantling.<sup>3,4</sup> It was in the late 1960s that silicone devices were devel-

<sup>1</sup>Division of Orthopedics, Department of Surgery and Department of Physiatrics, Tampere University Hospital and Medical School University of Tampere, Tampere, Finland.

<sup>2</sup>Institute of Biomaterials, Tampere University of Technology, Tampere, Finland.

<sup>3</sup>Coxa, Hospital for Joint Replacement, Tampere, Finland.



**FIG. 1.** Preoperative photograph of the rheumatoid hand with typical volar subluxation and ulnar deviation of the fingers. Picture has been taken with maximum active extension.

oped and the concept of prosthetic replacement of MCP joints became widely accepted and applied.<sup>2</sup>

A one-piece silicone implant with stems and a spacer in the middle is most commonly used for the reconstruction of MCP joints in RA patients. In the operation the stems of the implant are placed in the bone cavities of metacarpus and proximal phalanx. The spacer sets between the bone ends and acts as a joint spacer during the encapsulation process, when the body forms a fibrous capsule around the implant.<sup>5</sup> The most used and best documented implant is the so-called Swanson prosthesis.

Breakage of the implants has been a common problem in silicone arthroplasty series. Depending on the length of the follow-up period and study methods used, a range of 5–82% prevalence has been reported in different studies.<sup>6</sup> Particles released from either intact or broken prosthesis cause tissue reactions such as foreign body granulation in the joint and around the prosthesis inducing osteolysis.<sup>7,8</sup> Resorption of the bone due to the implant or progressive disease can make reoperation using stemmed prosthesis difficult or even impossible to perform. Especially in such cases an implant without stems would be preferable because it enables intramedullary bone grafting.

In clinical work patients with one or more previous silicone arthroplasties with prominent ulnar deviation and volar subluxation of the fingers due to breakage of the implant are commonly met. Usually in these cases silicone arthroplasty is not possible to perform because of insufficient bone stock, as discussed above. Some salvage operation should be offered for the patient to maintain his or her ability to perform daily activities.

The principle of *in vivo* tissue engineering, meaning that a porous scaffold is implanted *in situ* and filled with in-grown tissue, thus forming a living, functional tissue or organ, was applied in studies preceding current experiments. In 1994 the concept of the bioreconstructive joint scaffold was developed in our group by performing a first prospective study using commercially available bioabsorbable Vicryl and Ethisorb fleeces folded into small, rectangular scaffolds.<sup>9</sup> The innovation for the experiment was the so-called Vainio method, in which the extensor tendon is folded between the ends of the metacarpus and phalanx. The tendon creates a sliding surface between the bone ends and acts as a counterforce to volar subluxation tendency.<sup>10</sup>

The folded scaffold was intended to behave in a similar way as the tendon. However, the resorption time of both tested materials was too short. The tissue did not have enough time to regenerate and mature, and the joint space collapsed. The principal idea of the scaffold, however, proved to be clinically successful and a scaffold consisting of a porous bioabsorbable poly-L,D-lactide copolymer with an L:D monomer ratio of 96:4 (PLA96) with longer absorption time was designed. The scaffold is intended to be a temporary support and to be filled in by the ingrowing tissue of the host and later to be completely replaced by new living tissue. Thus it can be used to reconstruct a functional joint and the patient can use the hand better than preoperatively. The preceding *in vitro* experiments have shown that the filaments retain at least 50% of their tensile strength for 13 weeks (phosphate-buffered saline [PBS], pH 7.4, 37°C), and scaffolds retain their shape for at least the same amount of time.<sup>11</sup>

Compared with the complete loss of tensile strength of Ethisorb fibers *in vivo* in 4 weeks (our unpublished results) the strength retention is remarkably longer. The 50% strength retention in 13 weeks has been estimated as minimum strength retention time to keep up the joint space long enough for tissue maturation. In animal tests, connective tissue ingrowth into the mesh structure has been observed after the first week,<sup>12</sup> PLA96 scaffolds implanted in rat subcutis were filled with tissue in 3 weeks,<sup>13</sup> and self-reinforced PLA96 copolymer rods were totally absorbed within 3 years.<sup>14</sup>

The purpose of the present study was to evaluate the clinical, radiological, and functional outcomes of PLA96 joint scaffold arthroplasty in severe arthritic destruction and revision operation after failure of silicone arthroplasties in the metacarpophalangeal joints of RA patients.

## MATERIALS AND METHODS

### *Scaffolds*

Polymer used in this study was medical-grade and highly purified (residual monomer content < 0.1%, according to the manufacturer) polylactide L- and D-copolymer with an L:D monomer ratio of 96:4 (PLA96; Purac Biochem, Gorinchem, The Netherlands). Intrinsic viscosity, *i.v.*, (chloroform, 25°C) was 6.8 dL/g and heat of fusion (value corresponding to crystallinity) was 40.1 J/g (both according to manufacturer). Before processing, the polymer was predried.

Four-ply multifilament yarn was melt-spun from PLA96, using an Axon BX-15 single screw extruder (screw diameter 15 mm; ratio of screw length to diameter 24; Axon, Åstorp, Sweden) with a spinneret with four orifices (each with a diameter of 0.5 mm). The lowest barrel temperature was 158°C and the die temperature was 260°C. The yarn was oriented by drawing it freely in a two-step process to a draw ratio of about 4.5.

The yarn was knitted to a tubular mesh, using a tubular single jersey knitting machine (Textilmaschinenfabrik Harry Lucas, Neumünster, Germany). The knitted tube was rolled to cylindrical scaffolds and heat-treated above glass transition temperature ( $T_g$ ) of polymer in the molds. All the samples were packed and sterilized by  $\gamma$  irradiation before use.

### *Methods for yarns and scaffolds*

All the yarns (four-ply multifilaments) were incubated in PBS (pH 7.4, 37°C) for periods of 1, 2, 4, 6, 8, 10, 13, 16, and 19 weeks. The solutions were changed regularly every two weeks and the buffer capacity of the solution was checked by pH measurements. Before testing, all the samples were rinsed with deionized water.

The yarns were tested at a cross-head speed of 30

mm/min, using an Instron 4411 materials testing machine (Instron, High Wycombe, UK). Pneumatic grips were used, and the gauge length was 100 mm. Initial tensile results were measured on dry specimens, and after *in vitro* hydrolysis wet specimens were tested. Mean and standard deviations of stress and strain at maximum load were calculated ( $n = 10$ ).

Porosity of the scaffolds was calculated by determining the weight and size of the scaffolds and calculating against the solid piece of PLA96.

Pore size measurements were done for  $\gamma$ -sterilized samples. Scaffolds were fixed in epoxy resin. Fixed scaffolds were cut into three sections both in height and in diameter planes and surfaces were polished. Thirty randomly chosen distances between the fibrils in the yarns (small pores) and between the yarns (large pores) were measured on the basis of optical microscopy images of each section. Measured values were multiplied by 1.6 to estimate round pores.

### *Patients*

Twenty-three rheumatoid arthritis (RA) patients with, altogether, 80 operated metacarpophalangeal (MCP) joints were operated on, using PLA96 scaffolds. All patients were informed of the study protocol and asked to participate. Clinical use of the new interposition joint scaffold prosthesis was confirmed by permission of the Ethics Committee of the Tampere University Hospital and Pirkanmaa Hospital District (Tampere, Finland). During the study 15 patients and their 54 joints reached the follow-up stage of 1 year and the outcome is reported in this study. Average follow-up is 1 year and 8 months (12–27 months). There were 13 women and 2 men; the mean age of the patients at the time of operation was  $54 \pm 13$  (range, 37–78) years. The mean duration of rheumatoid arthritic diagnosis was  $17 \pm 8$  (range, 7–41) years. The preoperative mean value of C-reactive protein in patients was  $21 \pm 12$  (range, 8–39) and the sedimentation rate was  $15 \pm 13$  (range, 4–40). Eight patients were using cytotoxic medication and 13 patients received glucocorticoid medication at the time of operation. The average time of cytotoxic medication usage was  $5.9 \pm 3.7$  (range, 0.5–11) years and that of glucocorticoid medication was  $9.5 \pm 4.7$  (range, 0.5–15) years. The MCP joint of the index finger (MCP II) was operated on in all 15 patients, the MCP joint of the middle finger (MCP III) in 14 patients, MCP IV in 12 patients, and MCP V in 13 patients. The preoperative radiological destruction stage of the operated joints, according to Larsen (scale, I–V),<sup>15</sup> was stage III in 2 of the operated joints (4%), stage IV in 21 joints (39%), and stage V in 13 joints (24%). Stage V presents the most severe destruction of the joint. Previous silicone arthroplasty had been performed for 6 (40%) patients and thus in 18 (33%) joints.

### Surgical technique and rehabilitation

Operations were performed with a tourniquet (100 mmHg above systolic blood pressure). Preoperative prophylactic antibiotic (cefuroxime) was used. In the operation resection of the bone was equal to Swanson arthroplasty. The quantity and quality of soft tissue balancing in the operation were determined by grade and type of deformity. When ulnar deviation existed, the proximal bony attachments of both collateral ligaments were released. Deliberation of the volar capsule under metacarpal bone and release of the volar plate were performed to achieve adequate correction of volar subluxation. Ulnar intrinsic muscle contractures were released when required. The abductor digiti minimi of the fifth finger was always dissected. The PLA96 scaffold was fixed with resorbable sutures through the metacarpal bone via the volar plate.

Intramedullary bone grafting was performed in revision arthroplasties. Balancing and tightening of the collateral ligaments were performed by duplicating or re-fixing the ligament more proximally through drill holes in the proximal metacarpal bone. At the end, the extensor tendon was centralized.

In rehabilitation, the operated MCP joints were supported with a volar static splint during the first 10 days after operation. Active and passive range of movement exercises were assisted with a low-profile dynamic dorsal splinting starting 10 days postoperatively and continued up to 12 weeks. Light activities of daily living (ADL), like eating and personal hygiene, were allowed immediately after dynamic splint initialization. The rehabilitation was controlled by an occupational therapist.

### Methods for patient examination

The clinical, radiological, and functional assessments were carried out preoperatively and at follow-up (3 months and 1 and 2 years after surgery). Fifteen patients (54 joints) were monitored for at least 1 year. The mean follow-up time in this prospective study was 1 year and 8 months, with a range of 12 months to 2 years and 3 months. Functional measurements and interviews were performed by the same occupational therapist. Volar subluxation (sliding of the proximal phalange in the palmar direction) and joint space were measured from volar oblique radiographs. Subjective pain was evaluated with a verbal rating scale. Active flexion, lack of active extension, and ulnar deviation (proximal phalange deflection to the lateral side) were measured clinically from a dorsal aspect according to the standards of the American Academy of Orthopaedic Surgeons.<sup>16</sup> Grip strength was measured with a Jamar dynamometer (handle position 2) and according to the standards of the American Society of Hand Therapists.<sup>17</sup> The mean value of three grip strength measurements was considered.

Results are presented as mean, range, standard deviation, and proportion. Statistical analysis of mean values was made using paired sample *t* test. In comparing classified variables pre- and postoperatively the measure used was either  $\kappa$  (for  $2 \times 2$  tables), or  $\gamma$  (for  $m \times n$  tables,  $m$  or  $n > 2$ ) statistics. In the case of  $\kappa$  and  $\gamma$  a value near 0 corresponds to discordance between the variables involved (e.g., lack of correlation between two variables). A  $\gamma$  value between 0.4 and 0.7 indicates a moderate concordance, and a value  $> 0.7$  great concordance, between the variables. A  $\kappa$  value  $< 0.20$  means poor, 0.21–0.40

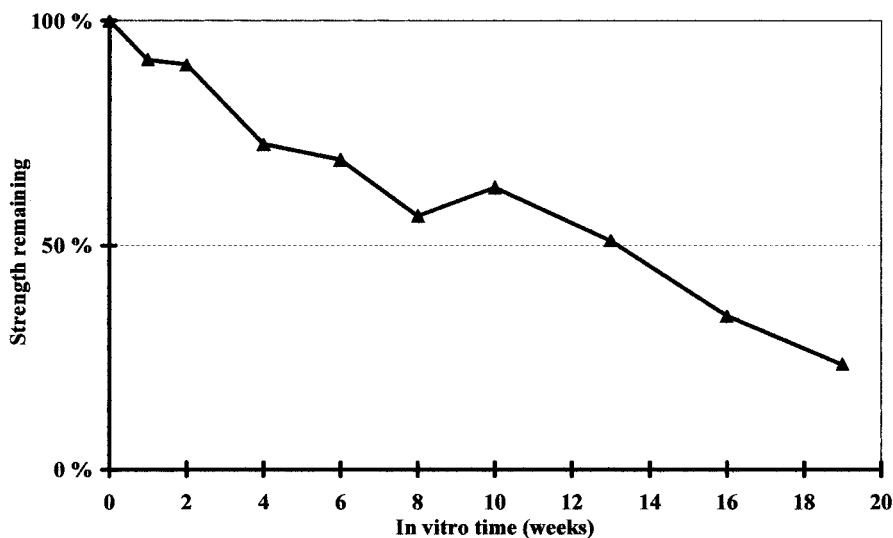



FIG. 2. Remaining tensile strength (%) of PLA96 yarn plotted against weeks *in vitro*.



**FIG. 3.** The PLA96 joint scaffold implant.

fair, 0.41–0.60 moderate, 0.61–0.80 good, and 0.81–1.00 very good concordance. A good congruence between pre- and postoperative values means lower effectiveness of the operation.

**RESULTS**

*Yarns and scaffolds*

Diameter of single filament varied between 70 and 80  $\mu\text{m}$ . Processing and  $\gamma$  irradiation decreased the intrinsic viscosity of PLA96 to 1.28 dL/g. Initial tensile strength of the  $\gamma$ -sterilized yarns was  $345 \pm 40.7$  MPa and strain at maximum load was  $31 \pm 3.1\%$ . Within 19 weeks *in vitro* the tensile strength of the yarn had dropped to  $81 \pm 11.0$  MPa, that is, 23% of initial strength (Fig. 2).

A typical scaffold is shown in Fig. 3. Calculated porosity of the scaffolds was approximately 80% (varied from 75 to 83%). Scaffolds had open and highly interconnected porosity throughout the structure, because the porosity is formed by mesh loops and by layers of the mesh. Generally, pores can be divided into small pores, meaning spaces between the filaments in yarn, and large pores, consisting of pores inside and between the loops. The average diameter of the small pores was 86  $\mu\text{m}$  and the average diameter of the large pores was 547  $\mu\text{m}$ . In prac-

tice, scaffolds have pores ranging from tens of micrometers up to 1 mm, because of the structure.

*Clinical results*

All patients reported relief from pain at the follow-up of 1 year and 8 months (12–27 months) (Table 1). The range of motion (ROM) improved from a nonfunctional arc of flexion to a more functional arc of extension (Table 2). Preoperatively, the mean ROM of operated joints was  $46^\circ$ , and postoperatively it was  $51^\circ$ . The ROM did not decrease in any of the patients during follow-up. The functional results presented in Table 3 show that patients were able to handle daily activities better than preoperatively.

Volar subluxation of more than half of the bone height was present in 30 joints (56%) preoperatively and in 3 joints (6%) at follow-up (Table 4). Preoperatively, the average ulnar deviation of operated joints was  $26 \pm 18^\circ$  (range, 3– $51^\circ$ ), and at follow-up it was  $6 \pm 7^\circ$  (3– $30^\circ$ ) ( $p < 0.001$ ). The strength of the grip was sustained. Preoperatively, the measurement was 8.0 kg (mean) and postoperatively 8.2 kg (mean), respectively ( $p = 0.80$ ). At follow-up the mean joint space measured from X-rays was  $2.4 \pm 1.6$  (range, 0–6 mm).

The cosmetic appearance was good; no swelling or fistula formation was observed at the follow-up (Fig. 4). The subjective satisfaction preoperatively was poor in 10 patients and tolerable in 5 patients. Postoperative subjective satisfaction was excellent or good in seven patients, satisfactory in seven patients. There was one patient with poor subjective outcome, and this patient had a humerus fracture with partial radialis paresis 1 year and 2 months after MCP arthroplasty. The fractured humerus may have influenced the overall welfare of the patient.

**DISCUSSION**

Most of the more recent small joint surgeries have been done with biostable joint prostheses, generally Swanson prostheses. A tissue-engineering approach to create new tissue formation in the joint cavity to form a functional neojoint has not been reported previously. Thus, the bioreconstructive MCP joint scaffold prosthesis is a new

**TABLE 1. PAIN PREOPERATIVELY AND AT FOLLOW-UP<sup>a</sup>**

	No pain	Mild pain in daily activities	Severe pain in daily activities	Severe pain at rest
Preoperatively	5	8	1	1
Postoperatively	10	5	0	0
	$\gamma = 0.71$			

<sup>a</sup>Number of patients.

TABLE 2. RANGE OF MOTION<sup>a</sup>

	MCP II	MCP III	MCP IV	MCP V	All operated joints
Active flexion					
Preoperatively	72	76	80	73	75
Postoperatively	68	75	68	62	69
	$p = 0.06$	$p = 0.4$	$p = 0.0001$	$p = 0.029$	
Active extension lack					
Preoperatively	25	28	34	29	29
Postoperatively	19	23	17	13	18
	$p = 0.15$	$p = 0.22$	$p = 0.01$	$p = 0.06$	

Abbreviations: MCP II, index finger metacarpophalangeal joint; MCP III, middle finger metacarpophalangeal joint; MCP IV, ring finger metacarpophalangeal joint; MCP V, little finger metacarpophalangeal joint.

<sup>a</sup>In degrees.

concept in joint replacement surgery and the results of this short-term study suggest that it may be possible to treat joints in this way.

The function of scaffolds in this particular indication is to create and maintain a space between the bone ends. The surrounding tissue preferably invades the pores of the scaffold and fills in the empty space. The tissue will later function as a neojoint. The scaffold is porous, having all pore sizes from some tens of micrometers in diameter to more than 1 mm in diameter. Most probably the pores are smaller *in situ* because of the compression caused by bones and ligaments. Filling in the scaffold with tissue probably occurs, because in follow-up radiographs an empty space is seen where the implant was placed. At that time the scaffold has already degraded to such an extent that it no longer withstands applied loads.

The first 10 days in static splint allow undisturbed growth of tissue into the scaffolds. By that time the scaffold is relatively well filled with tissue, because tissue ingrowth had occurred completely in 3 weeks in subcutaneous tissue in rats.<sup>13</sup> At the 3-month follow-up time the dynamic splint was removed from the patients and tissue had probably filled in the scaffold completely. By the 1-year follow-up time, the yarns of the scaffold carry

no load, because of degradation, but they still may support the joint cavity. The empty space seen in radiographs where the scaffold had been placed is at that time most probably a combination of the patient's own tissue and remainders of the PLA96 scaffold.

Although all the operated joints were extensively destroyed by RA and the current material included a great number of revision arthroplasties (40% of the patients and 33% of the operated joints), which are in most cases impossible to treat by any other method, the results are promising and functionality of the hands was at least comparable to those previously reported for silicone arthroplasties.<sup>6</sup>

ROM improved slightly and was broad enough. It is important that the ROM was postoperatively at a good level in the extension–flexion arc for hand function, which enables the patient to grip larger objects. This was seen as improved ability to perform daily activities, such as eating and taking care of personal hygiene. Correction of rheumatic deformations, volar subluxation, and ulnar deviation was achieved and well preserved at least over 12–27 months of follow-up. According to animal and *in vitro* studies most of the PLA material degrades in this time. Individual results had not deteriorated during this

TABLE 3. ACTIVITIES OF DAILY LIVING<sup>a</sup>

	Eating		Personal hygiene	
	Preoperatively	Postoperatively	Preoperatively	Postoperatively
No problem	0	7	0	3
Some problems	11	6	11	11
Considerable problems	4	2	4	1
	$\gamma = 0.59$		$\gamma = 0.33$	

<sup>a</sup>Number of patients.

TABLE 4. VOLAR SUBLUXATION<sup>a</sup>

	<2 mm	3–5 mm	>6 mm	κ
MCP II				
Preoperatively	4 <sup>b</sup>	5	6	
Postoperatively	13	1	1	0.07
MCP III				
Preoperatively	4	3	6	
Postoperatively	9	4	0	0.14
MCP IV				
Preoperatively	2	3	8	
Postoperatively	7	5	1	0.31
MCP V				
Preoperatively	2	1	10	
Postoperatively	4	8	1	-0.09

Abbreviations: See Table 2.

<sup>a</sup>Measured from oblique X-rays.

<sup>b</sup>The values indicate the number of joints.

follow-up time. However, a longer follow-up time is certainly needed to assure permanence of the results after degradation of the PLA scaffold.

In severely deformed rheumatoid hands (fixed deformity) it may occasionally be difficult to achieve proper balancing of soft tissues. When a silicone implant is put in place under compromised circumstances the imbalanced stress to the implant and the sharp irregularities of the resected bones can easily lead to implant breakage and consequently to recurrence of deformity and pain as well as loss of function. With bioconstructive

and bioabsorbable prostheses we can avoid the problems of broken implants. This type of bioconstructive implant has no stems but the implant is sutured with bioabsorbable stitches inside the joint space. Thus the implant causes no stress and shields the metacarpal diaphysis, which is valuable especially in cases with major bone resorption.

In revision arthroplasties the stemless implant also makes it possible to use intramedullar bone grafting to fill osteolytic cavities. An example of such a patient with major bone resorption caused by implant stems preoper-

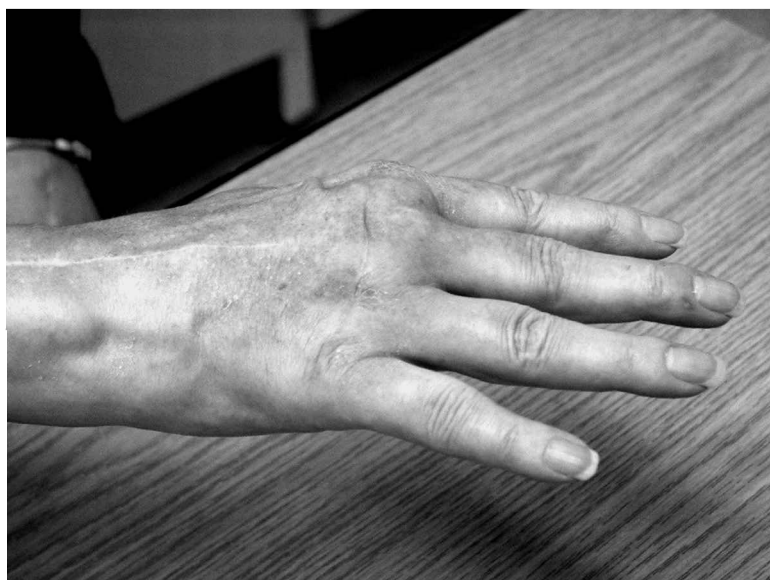
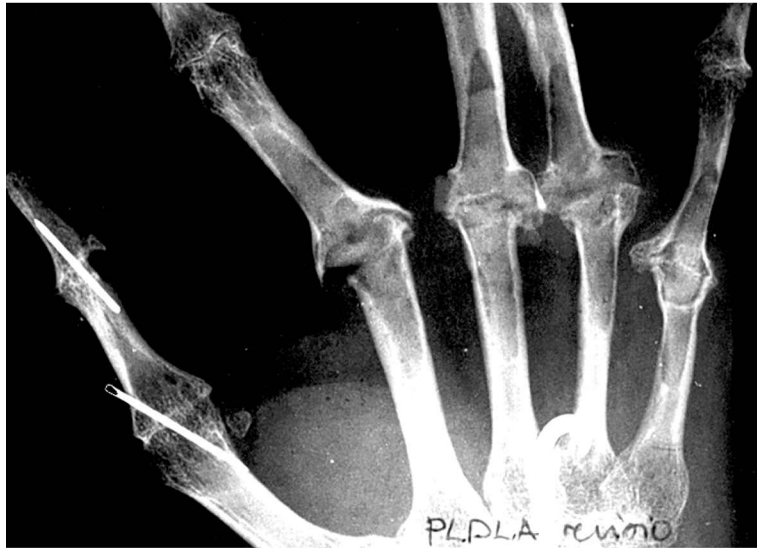

FIG. 4. Postoperative photograph at 3-month follow-up (same patient as in Fig. 1), with maximum active extension. Finger alignment has improved and extension lack reduced. Cosmetic reformation is noticeable.

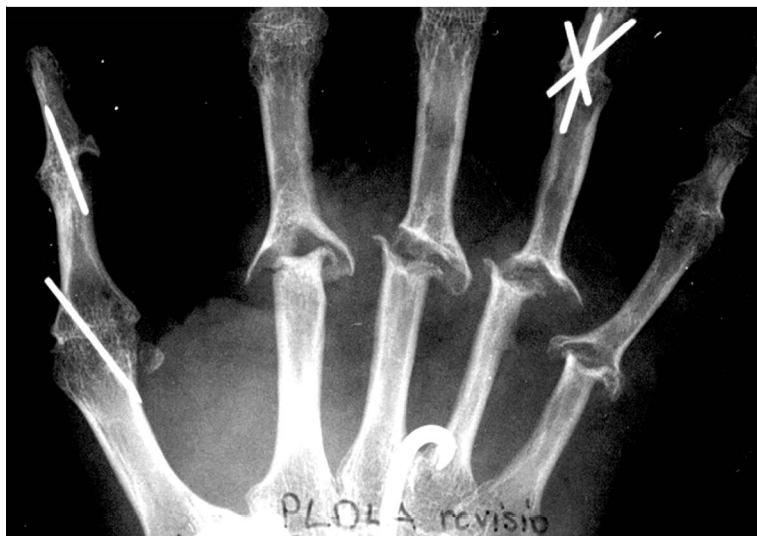



**FIG. 5.** Preoperative radiograph of a revision arthroplasty case. Swanson arthroplasty was performed 10 years previously. Extensive thinning of the diaphyseal cortices around the Swanson implant stems can be seen.

actively is presented in Fig. 5. In PLA96 arthroplasty the bone cavities were filled in with allograft bank bone, PLA96 scaffold was fixed in its place, and all necessary soft tissue balancing was done. The situation 2 years postoperatively, when PLA96 is heavily degraded, is shown in Fig. 6. Remodeling of the bone and thickening of the cortices can clearly be seen and there is a space between the metacarpus and proximal phalange, indicating present material.

The balancing of the joint is crucial, and the joint should be tight enough at the end of the operation to allow absorption of the implant without malalignment of the hand bones. At the clinical examination it was noticed that the MCP joints functioned and glided nearly like a normal joint and not like a hinge, as is commonly experienced with silastic implants. None of the joints has been opened so far, and thus no histological observations of the quality and quantity of the tissue exist.



**FIG. 6.** Postoperative radiograph of the same patient 2 years after PLA96 joint scaffold arthroplasty. In the operation intramedullary defects have been filled with autologous bone graft. Postoperative remodeling of the bone and thickening of the cortices can be observed. “Empty” space between metacarpus and proximal phalanx indicates the location of bioconstructive joint scaffold implant and in-grown soft tissue.

Follow-up of the present patients to determine the long-term results of this new technique of arthroplasty continue. A check-point at 4 years has been chosen to confirm the situation for those joints from which PLA96 has been completely disappeared. A randomized prospective multicenter study using PLA96 joint scaffold and Swanson implants has also started, to confirm these promising preliminary results.

## REFERENCES

1. Stirrat, C.R. Metacarpophalangeal joints in rheumatoid arthritis of the hand. *Hand Clin.* **12**, 515, 1996.
2. Beckenbaugh, R.D. The development of an implant for the metacarpophalangeal joint of the fingers. *Acta Orthop. Scand.* **70**, 107, 1999.
3. Linscheid, R.L., and Rochester, M.N.V. Implant arthroplasty of the hand: Retrospective and prospective considerations. *J. Hand Surg. Am.* **25**, 796, 2000.
4. Allieu, Y. *The Rheumatoid Hand and Wrist*. Paris: Expansion Scientific Publications, 1998.
5. Swanson, A.B. Flexible implant arthroplasty for arthritic finger joints: Rationale, technique and results of treatment. *J. Bone Joint Surg. Am.* **54**, 435, 1972.
6. Chung, K.C., Kowalski, C.P., Kim, H.M., and Kazmers, I.S. Patient outcomes following Swanson silastic metacarpophalangeal joint arthroplasty in the rheumatoid hand: A systematic overview. *J. Rheumatol.* **27**, 1395, 2000.
7. Bass, R.L., Stern, P.J., and Nairus, J.G. High implant fracture incidence with Sutter silicone metacarpophalangeal joint. *J. Hand Surg. Am.* **21**, 813, 1996.
8. Wanivenhaus, A., Lintner, F., Wurnig, C., and Missaghi-Schinzl, M. Long-term reaction of the osseous bed around silicone implants. *Acta Orthop. Scand.* **110**, 146, 1991.
9. Lehtimäki, M., Paasimaa, S., Lehto, M., Kellomäki, M., Mäkelä, S., and Törmälä, P. Development of the metacarpophalangeal joint arthroplasty with a bioabsorbable prosthesis. Abstract presented at the Scandinavian Hand Society Meeting, Oslo, Norway, 1998. Abstract no. 02.
10. Vainio, K. Vainio arthroplasty of the metacarpophalangeal joints in rheumatoid arthritis. *J. Hand Surg. Am.* **14**, 367, 1989.
11. Paatola, T., Kellomäki, M., and Törmälä, P. Poly (L/D) lactide 96/4 copolymer filaments. In: *Proceedings of FiberMed 2000*, Tampere, Finland, 2000, pp. 261–265.
12. Kellomäki, M., Puumanen, K., Waris, T., and Törmälä, P. *In vivo* degradation of composite membrane of P(e-CL/L-LA) 50/50 film and P(L/D)LA 96/4 mesh. In: Stallforth, H., and Revell, P., eds. *Materials for Medical Engineering: Euromat, Vol. 2*. Weinheim, Germany: Wiley-VCH, 2000, pp. 73–79.
13. Kellomäki, M., Kulmala, T., Ellä, V., Länsman, S., Ashammakhi, N., Waris, T., and Törmälä, P. *In vitro* and *in vivo* behaviour of bioreconstructive P(L/D)LA (96/4) knitted scaffolds. Abstract presented at the Symposium on Tissue Engineering Science: Critical Elements in the Research and Development Continuum, May 19–23, Myconos, Greece, 2002. Abstract no. 49.
14. Saikku-Bäckström, A., Tulamo, R.-M., Pohjonen, T., Törmälä, P., Riihjä, J.E., and Rokkanen, P. Material properties of absorbable self-reinforced fibrillated poly-96L/4D-lactide (SR-PLA96) rods: A study in vitro and in vivo. *J. Mater. Sci. Mater. Med.* **10**, 1, 1999.
15. Larsen, A., Dale, K., and Eek, M. Radiographic evaluation of rheumatoid arthritis by standard reference films. *Acta Radiol. Diagn.* **18**, 481, 1977.
16. Schneider, H.J., and Callahan, M.E. *Rehabilitation of the hand*. In: *Surgery and Therapy*. Toronto, ON, Canada: Mosby, 1990.
17. Mathiowetz, V., Weber, K., Volland, G., and Kashman, N. Reliability and validity of grip and pinch strength evaluations. *J. Hand Surg. Am.* **9**, 222, 1984.

Address reprint requests to:  
*P.B. Honkanen, M.D.*  
*Department of Surgery*  
*Tampere University Hospital*  
*P.O. Box 2000*  
*33521 Tampere, Finland*

*E-mail:* pirjo.honkanen@fimnet.fi