

# Chronic occupational paronychia secondary to digital pilonidal sinus from dog grooming

Mikko P. Räisänen <sup>1,2,\*</sup>, Heidi Furu <sup>3</sup>, Aleksi Reito <sup>4</sup> and Randy R. Bindra <sup>5</sup>

<sup>1</sup>Faculty of Medicine and Health technology, Tampere Universities, Arvo Ylpön katu 34, 33520 Tampere, Finland

<sup>2</sup>Department of Orthopedics, Traumatology and Hand surgery, Kuopio University Hospital, Puijonlaaksontie 2, 70200 Kuopio, Finland

<sup>3</sup>Department of Public Health, Helsinki University, Topeliuksenkatu 5, 00260 Helsinki, Finland

<sup>4</sup>Department of Musculoskeletal Diseases, Tampere University Hospital, Elämäntie 2, 33520 Tampere, Finland

<sup>5</sup>Griffith University School of Medicine and Dentistry, Parklands Dr, Southport QLD 4215, Australia

\*Corresponding author: Mikko Petteri Räisänen, (mikko.raisanen@tuni.fi).

## Abstract

Pilonidal sinus is a recognized occupational condition sometimes seen in barbers and pet groomers, and it involves most commonly interdigital spaces. We present a previously unreported case of chronic paronychia with 2 separate digital pilonidal sinuses resulting from multiple embedded hair fragments in the eponychium of a dog groomer, who had been repeatedly treated with antibiotics with no success and ended up having surgical treatment. The objective of this study is to remind readers of this rare but possible occupational disease, particularly among employees working with hair, and to emphasize the importance of preventive measures to prevent its occurrence. Intraoperatively, a crescent of eponychial skin parallel to the proximal nail fold was excised, which incorporated the sinuses. Additionally, the nail plate was removed, and multiple hair fragments were retrieved from the nail folds. At the follow-up, the infection had resolved, and nail growth had resumed. Additional animal hair was found in the nail folds, as the patient continued to work without protective gloves. This case highlights the importance of considering embedded hair as a potential cause for chronic paronychia in individuals with occupations involving hair cutting and grooming. Chronic hand infection poses a risk of infection contaminating clients or patients; for example, a veterinarian should not operate with an infected hand. The costs of sickness absences are considerable for all the stakeholders. The use of protective gloves, hand hygiene, skin care, and thorough removal of loose hair fragments should be emphasized for workers in professions dealing with animal or human hair.

## Key points

This study presents a previously unreported case of chronic paronychia with 2 separate digital pilonidal sinuses caused by multiple embedded hair fragments in the eponychium of a dog groomer. The patient had been repeatedly treated with antibiotics without the desired response, ultimately requiring surgical intervention. This case highlights the importance of considering embedded hair as a potential cause of chronic paronychia in individuals with occupations involving hair cutting and grooming, for example, hairdressers, barbers, and dog groomers. The use of protective gloves, hand hygiene, skin care, and thorough removal of loose hair fragments should be emphasized for workers in professions dealing with animal or human hair, as these practices can prevent significant costs for the employee, the employer, and society from sickness absences.

**Keywords:** chronic; occupational disease; paronychia; digital pilonidal sinus; infection; finger.

## Introduction

Infective paronychia is one of the most common infectious conditions of the hand, and it is mostly thought to be a nail disease due to bacterial or fungal infection where the nail and skin meet at the side or the base of a fingernail or toenail. Chronic paronychia refers to induration of the eponychium and nail plate deformity from repetitive acute nail infection, most often caused by prolonged exposure to water or irritative chemicals. The etiology can be also multifactorial including repeated minor trauma.

Pilonidal sinus is a chronic inflammatory condition caused by the penetration of hair fragments into the skin, which triggers an

inflammatory response, leading to the formation of a sinus and eventually a cyst. Although the sacrococcygeal area is the most common location for pilonidal sinus, it can also occur in various body sites such as the intermammary space, umbilicus, or the foot, where anatomical features facilitate the accumulation, penetration, or entrapment of hair growth. In the hand, this condition predominantly involves interdigital spaces<sup>1-4</sup> in patients working in occupations dealing with hair, such as barbers, hair stylists, and pet groomers<sup>2-7</sup> and is sometimes referred to as barber's disease. There are no reported incidences, and most articles refer to it as a rare occupational disease. However, it seems to be heavily

Received: June 11, 2024. Revised: October 20, 2024. Accepted: November 7, 2024

© The Author(s) [2024]. Published by Oxford University Press on behalf of the Japan Society for Occupational Health.

This is an Open Access article distributed under the terms of the Creative Commons Attribution NonCommercial-NoDerivs licence

(<http://creativecommons.org/licenses/by-nc-nd/4.0/>), which permits non-commercial reproduction and distribution of the work, in any medium, provided the original work is not altered or transformed in any way, and that the work properly cited. For commercial re-use, please contact reprints@oup.com for reprints and translation rights for reprints. All other permissions can be obtained through our RightsLink service via the Permissions link on the article page on our site-for further information please contact journals.permissions@oup.com.

underreported, as a German study of 100 barbers revealed that over 90% of hairdressers reported human hair penetrations, and that they regularly removed them by themselves.<sup>8</sup> According to the UK Dog Grooming Association, pilonidal sinuses are a well-recognized hazard among groomers. It can occur in various areas such as the interdigital spaces of the hands and feet, and multiple locations around the human body.<sup>8</sup> Occupational pilonidal sinuses differ from other types by appearing in non-hair-bearing areas and containing hair from clients or patients, rather than the individual's own hair.

There are 3 reported cases in the literature of a digital pilonidal sinus. One case describes a chronic finger pulp infection in a dog groomer,<sup>2</sup> whereas 2 similar cases involved osteomyelitis in a dog groomer and a barber.<sup>9,10</sup> Additionally, paronychia resulting from a single hair strand embedded in a lateral nail fold has been reported in a hairdresser.<sup>11</sup> Our case of chronic paronychia with 2 digital pilonidal sinuses due to multiple hair fragments embedded in the eponychium in a dog groomer is, to our knowledge, unique and previously unreported. This study serves to alert occupational health care professionals to this preventable occupational disease through appropriate protection measures.

## Case presentation

A 49-year-old female dog groomer was referred for consultation with a hand surgeon for suspected mucous cyst between the proximal nail bed and distal interphalangeal joint. She had a 3-year history of swelling and redness in the right ring fingernail, that is, the nail of the fourth finger on her right hand, which had been treated by a general practitioner. The condition had failed to respond to oral antibiotics and topical antifungal agents. There was no discharge from the swelling. The patient had no allergies or skin conditions, including any significant skin dryness. In addition, the patient reported a history of a previous pilonidal sinus in the forearm. She was aware that the sinus was related to dog grooming and of the risks but found that wearing gloves interfered with her ability to work, so she continued to work without any formal protection. The patient did not believe that the nail problem was related to the forearm sinus and assumed it was nail infection caused by her hands being wet for prolonged periods. The patient signed a patient consent and approved the publication of the case report.

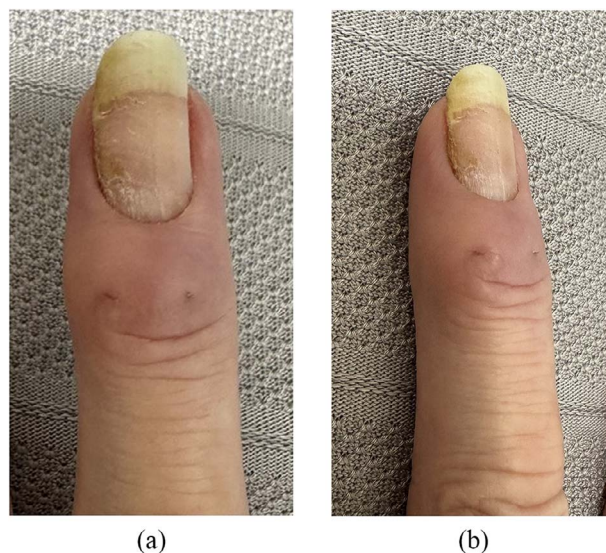
## Investigations

Examination of the right ring finger revealed enlarged and thickened eponychium with nail ridging suggestive of chronic paronychia (Figure 1). Two sinuses were visible in the eponychium with possible hair follicle visible under magnification. The finger range of motion was unaffected. Radiographic imaging of the finger was normal with no signs of osteomyelitis.

## Treatment

Due to the chronicity of the condition and failure of nonoperative measures, the patient was offered surgical intervention. Operative treatment options were discussed, and the patient consented to nail plate removal and marsupialization to include the visible eponychial sinuses.

The procedure was performed with wrist block and conscious sedation. A 3-mm wide crescent of eponychial skin parallel to the proximal nail fold was excised (Figure S1). The excised skin incorporated the 2 visible sinuses. Following elevation of the skin flap, hair fragment was identified in the depth of each sinus



**Figure 1.** Preoperative photos showing 2 digital pilonidal sinuses in the eponychium, with nail ridging suggestive of chronic paronychia: A. dorsal; B. oblique.

and removed. The nail plate was elevated and removed to get access to the lateral nail folds (Figure S2). Multiple fragments of hair were retrieved from the nail folds on either side of the nail bed (Figures S3 and S4, Videos S1 and S2). The surgical site was irrigated with hydrogen peroxide and saline (Figure S5). Finger dressing was applied.

## Outcome and follow-up

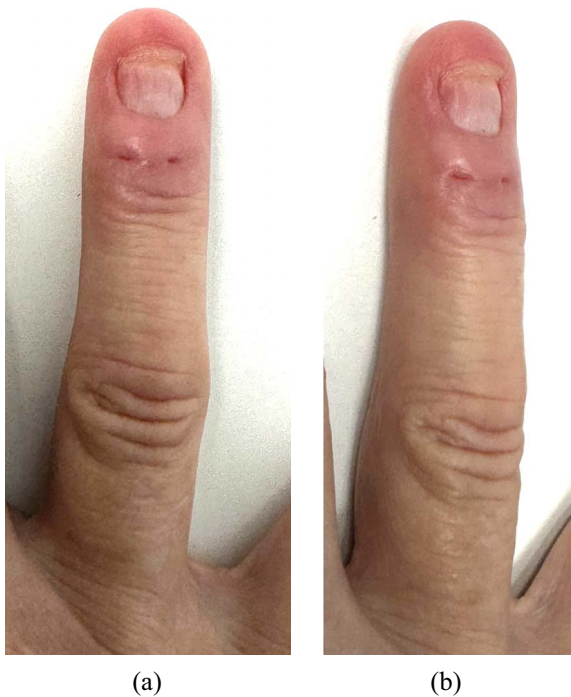Microbiological cultures revealed *Pseudomonas aeruginosa*, and the patient responded to a course of oral ciprofloxacin. The nail plate did not show any fungal hyphae, and fungal cultures were negative after 6 weeks.

The histopathological examination of the excised skin revealed an apparent dermal sinus with adjacent scar tissue. Within the scar tissue, there was evidence of chronic inflammation associated with focal foreign material, indicating that all observed changes were related to a previous penetrating injury caused by a foreign object, leading to secondary sinus formation. Other potential causes of a dermal sinus, such as a pilonidal sinus, were also recommended for consideration. There was no evidence of dysplasia or malignancy, and the report should be closely correlated with the clinical findings as usual.

During postoperative hand therapy, further hair fragments were removed from the nail folds after the patient admitted to returning to work without protective gloves. At surgical review 3 months after surgery the patient reported no symptoms. The wound had healed completely, and the area of excised skin had epithelialized. There was nail plate regeneration without any signs of infection (Figure 2).

## Discussion

This report is the first to present a chronic occupational paronychia caused by a digital pilonidal sinus with multiple hair particles in a dog groomer. Although such sinuses have been observed in the hands of barbers, particularly in interdigital spaces, they should be acknowledged as a potential cause of paronychia across



**Figure 2.** 3-months follow-up photos showing the excised digital pilonidal sinuses and the formation of a new healthy fingernail: A. dorsal; B. oblique.

all professions related to manual handling of hair including dog groomers.

In a previous report of paronychia caused by pet hair, a hair strand was found in the lateral nail fold that was managed by removal of the hair strand alone without addressing the nail itself.<sup>11</sup> Ramilo et al<sup>4</sup> presented a case related to a pet groomer who had a more typical pilonidal sinus in the interdigital space of a hand. The patient underwent sinusectomy and debridement, leading to successful healing by secondary intention. Shikowitz-Behr and Freedman<sup>3</sup> reported a case similar to that of Ramilo et al, but that did not resolve with the initial operation and necessitated a second, more extensive procedure. Brutus and Chang<sup>2</sup> presented a case of a dog groomer who had multiple sinuses around both the fifth metacarpophalangeal joint and the volar side of the small finger pulp on the right hand. Surgical treatment successfully cured these sinuses. Stone<sup>12</sup> presented a case of chronic paronychia in which hair acted as a foreign body. However, the infection had started when the patient had been working as a baker and later he took part-time work as a barber. Also, no digital pilonidal sinus was noted. Hair was diagnosed with punch biopsy through the posterior nail fold.

Dog hairs, similar to human hair, have been linked to interdigital pilonidal sinuses, a phenomenon also seen among barbers.<sup>10</sup> Typically thick, stiff, and straight, with limited flexibility, dog hairs can resemble sharp needles when clipped. Additionally, their cuticles may form a tile-like structure, acting as barbed hooks. These hairs tend to be adhesive, often moist and/or electrostatic during grooming.<sup>13</sup>

As in the presented case, operative treatment is typically indicated for most symptomatic interdigital pilonidal sinus cases.<sup>1,7</sup> Although the clinical course often resolves on its own, the disease can advance to more severe forms, such as osteomyelitis and recurrent infections.<sup>10</sup> Recurring infections are consistently more challenging to treat than initial ones, necessitating more

extensive surgical interventions and extended recovery periods. The onset of osteomyelitis presents an even greater challenge, often demanding prolonged courses of antibiotics, including intravenous administration, and frequently requiring more extensive excisions, which may involve the partial or complete removal of the infected bone.

Despite comprehensive literature reports on this condition among pet groomers, there is currently a lack of comprehensive guidelines to ensure the practice of protective measures for this population of workers. This gap could be attributed to underreporting of cases, physicians' unfamiliarity with the condition, or affected groomers not seeking assistance.

In this case the problem returned when the patient continued working without gloves and other protective measures, emphasizing the need for proper protection. Using gloves is important, but as animal hairs vary in thickness and sharpness, they might penetrate the gloves<sup>7</sup> as well and also find their way under clothing.<sup>8</sup> Thus, meticulous hygiene, changing clothes, and thorough removal of loose hair parts after each workday is recommended.<sup>1,10,14</sup> Although the case presented here did not have significant skin dryness, it is crucial to prioritize proper care for the skin of the hands, especially in occupations that involve frequent hand washing and a risk of skin dryness,<sup>15</sup> such as hairdressing. One simple method is to regularly apply hand cream.<sup>16-18</sup>

Chronic hand infection poses a risk of infection contaminating clients or patients; for example, a veterinarian should not undertake operative work with an infected hand. The costs of resulting sickness absences are considerable for the employee, the employer, and society. Any chronic infective process in the hands of patients engaged in occupations that handle hair fragments, such as barbers, veterinarians, animal caretakers, or pet groomers, should consider embedded hair as a potential underlying cause. Future research should conduct a systematic review of occupational-related infectious diseases in the hand area among professionals dealing with hair. Additionally, more research on the incidence of occupational pilonidal sinus of professionals handling human or animal hair is needed.

Highlighting the need to understand this condition, 80% of all hair penetrations in the body occur in the hand, with the palm being at the highest risk, followed by the dorsal side of the second and third fingers distal to the distal interphalangeal joint, and the back of the hand.<sup>8</sup> In conclusion, heightened awareness among physicians regarding chronic paronychia secondary to digital pilonidal sinus can facilitate accurate diagnosis, optimal treatment, and proper patient education.

## Author contributions

Mikko P. Räsänen (Conceptualization, Formal analysis, Investigation, Writing—original draft, Visualization), Heidi Furu (Writing—review & editing), Aleksu Reito (Writing—review & editing), and Randy R. Bindra (Conceptualization, Investigation, Resources, Writing—review & editing, Supervision). All authors have read and approved the final version of the article to be published and have agreed to be accountable for all aspects of the work in ensuring that questions related to the accuracy or integrity of any part of the work are appropriately investigated and resolved.

## Supplementary material

Supplementary material is available at *Journal of Occupational Health* online.

## Funding

The authors report that there was no funding source for the work that resulted in the article or the preparation of the article.

## Conflicts of interest

The authors declare no conflicts of interest.

## Data availability

Data of this case report are available for researchers who provide a methodologically sound proposal, and reviewers of the journal in which the article will be published (Table S1). Proposals should be directed to mikko.raisanen@tuni.fi. To gain access, data requestors will need to sign a data access agreement.

## References

- Adams CI, Petrie PW, Hooper G. Interdigital pilonidal sinus in the hand. *J Hand Surg Br.* 2001;**26**(1):53-55. <https://doi.org/10.1054/jhsb.2000.0494>
- Brutus JP, Chang MC. Multiple pilonidal sinuses of both hands in a dog groomer: a case report. *Hand Surg Rehabil.* 2024;**43**(1):101625. <https://doi.org/10.1016/j.hansur.2023.11.010>
- Shikowitz-Behr L, Freedman AM. Recurrent interdigital pilonidal sinus in a dog groomer. *J Hand Microsurg.* 2016;**08**(02):113-114. <https://doi.org/10.1055/s-0036-1585469>
- Ramilo R, Jao-Tan C, Angeles C, Jamisola L, Pascasio MN. Interdigital pilonidal sinus: an occupational disease of pet groomers. *Health Sci J.* 2019;**9**(1):26-28. <https://www.herdin.ph/index.php/herdin-journals?view=research&cid=73911>
- Efthimiadis C, Kosmidis C, Anthimidis G, et al. Barber's hair sinus in a female hairdresser: uncommon manifestation of an occupational disease: a case report. *Cases J.* 2008;**1**(1):214. <https://doi.org/10.1186/1757-1626-1-214>
- Jochims J, Brandt KA. Interdigital pilonidal sinus ("barber's disease")—a rare occupational disease. *Chirurg.* 1998;**69**(11):1280-1281. <https://doi.org/10.1007/s001040050570>
- Uysal AC, Orbay H, Uraloglu M, Sensoz O, Hyakusoku H. Rare occupational disease of hair dressers: interdigital pilonidal sinus. *J Nippon Med Sch.* 2007;**74**(5):364-366. <https://doi.org/10.1272/jnms.74.364>
- Doll D, Maier K, Albers K, et al. Another common sharp hair fragment disease – barbers' anterior disease (BAD). *Pilonidal Sinus J.* 2019;**5**(1):1-15
- Grant I, Mahaffey PJ. Pilonidal sinus of the finger pulp. *J Hand Surg Br.* 2001;**26**(5):490-491. <https://doi.org/10.1054/jhsb.2001.0580>
- Mohanna P, Al-Sam S, Flemming A. Subungual pilonidal sinus of the hand in a dog groomer. *Br J Plast Surg.* 2001;**54**(2):176-178. <https://doi.org/10.1054/bjps.2000.3457>
- Allouni A, Yousif A, Akhtar S. Chronic paronychia in a hairdresser. *Occup Med (Lond).* 2014;**64**(6):468-469. <https://doi.org/10.1093/occmed/kqu075>
- Stone OJ. Chronic paronychia in which hair was a foreign body. *Int J Dermatol.* 1975;**14**(9):661-663. <https://doi.org/10.1111/j.1365-4362.1975.tb00159.x>
- Schröder CM, Merk HF, Frank J. Barber's hair sinus in a female hairdresser: uncommon manifestation of an occupational dermatosis. *J Eur Acad Dermatol Venereol.* 2006;**20**(2):209-211. <https://doi.org/10.1111/j.1468-3083.2006.01400.x>
- Papa CA, Ramsey ML, Tyler WB. Interdigital pilonidal sinus in a dog groomer. *J Am Acad Dermatol.* 2002;**47**(5):S281-S282. <https://doi.org/10.1067/mjd.2002.109256>
- Loh EDW, Yew YW. Hand hygiene and hand eczema: a systematic review and meta-analysis. *Contact Derm.* 2022;**87**(4):303-314. <https://doi.org/10.1111/cod.14133>
- Bissett L. Skin care: an essential component of hand hygiene and infection control. *Br J Nurs.* 2007;**16**(16):976-981. <https://doi.org/10.12968/bjon.2007.16.16.27075>
- Lakshmi C, Srinivas CR. Hand eczema: an update. *Indian J Dermatol Venereol Leprol.* 2012;**78**(5):569-582. <https://doi.org/10.4103/0378-6323.100547>
- Lodén M. Role of topical emollients and moisturizers in the treatment of dry skin barrier disorders. *Am J Clin Dermatol.* 2003;**4**(11):771-788. <https://doi.org/10.2165/00128071-200304110-00005>