

FULL-LENGTH ORIGINAL RESEARCH

Semiautomated classification of nocturnal seizures using video recordings

Jukka Peltola^{1,2}  | Pabitra Basnyat¹  | Sidsel Armand Larsen³ |
 Tim Østerkjærhuus⁴ | Torsten Vinding Merinder⁴ | Daniella Terney³ |
 Sándor Beniczky^{3,4,5} 

¹Tampere University Hospital and Tampere University, Tampere, Finland

²Neuro Event Labs, Tampere, Finland

³Department of Clinical Neurophysiology, Danish Epilepsy Center, Dianalund, Denmark

⁴Department of Clinical Neurophysiology, Aarhus University Hospital, Aarhus, Denmark

⁵Department of Clinical Medicine, Aarhus University, Aarhus, Denmark

Correspondence

Jukka Peltola, Department of Neurology, Faculty of Medicine and Health Technology, Tampere University, B237, Kauppi campus, Arvo Ylpön katu 34, Tampere 33520, Finland.
 Emails: jukka.peltola@tuni.fi; jukka.peltola@pshp.fi

Abstract

Objective: The objective of this study was to evaluate the accuracy of a semiautomated classification of nocturnal seizures using a hybrid system consisting of an artificial intelligence-based algorithm, which selects epochs with potential clinical relevance to be reviewed by human experts.

Methods: Consecutive patients with nocturnal motor seizures admitted for video-electroencephalographic long-term monitoring (LTM) were prospectively recruited. We determined the extent of data reduction by using the algorithm, and we evaluated the accuracy of seizure classification from the hybrid system compared with the gold standard of LTM.

Results: Forty consecutive patients (24 male; median age = 15 years) were analyzed. The algorithm reduced the duration of epochs to be reviewed to 14% of the total recording time (1874 h). There was a fair agreement beyond chance in seizure classification between the hybrid system and the gold standard (agreement coefficient = .33, 95% confidence interval = .20–.47). The hybrid system correctly identified all tonic–clonic and clonic seizures and 82% of focal motor seizures. However, there was low accuracy in identifying seizure types with more discrete or subtle motor phenomena.

Significance: Using a hybrid (algorithm–human) system for reviewing nocturnal video recordings significantly decreased the workload and provided accurate classification of major motor seizures (tonic–clonic, clonic, and focal motor seizures).

KEYWORDS

artificial intelligence, automated detection, hybrid system, nocturnal seizures, seizure classification, video analysis

1 | INTRODUCTION

The inaccurate identification of seizure types is a major challenge in the diagnosis and treatment of epilepsy. Descriptions of paroxysmal events obtained from patients and eyewitnesses are often unreliable and lead to erroneous classification.¹ Inpatient video-electroencephalography (EEG) is the gold standard for electroclinical characterization of epileptic seizures, especially when there is diagnostic uncertainty in classifying seizure types or epilepsy syndrome. However, video-EEG may be impractical for some patients who have a low frequency of events.² Other factors, such as geographical limitations and transportation constraints, may restrict access to video-EEG, and socioeconomic conditions may hinder the availability of video-EEG, particularly in developing countries, thus leading to a longer delay in a definitive diagnosis.³

Visual analysis of video recordings of motor seizures by experts significantly increased the accuracy of seizure classification compared to patients' and eyewitnesses' description of seizures.¹ Expert interpretation of home video recordings (smartphone video) was accurate in diagnosing epileptic seizures 89%–94% of the time.^{4,5} However, smartphone video recordings may also be misleading, because the start of the seizure is typically missing, and occasionally, only the postictal period is recorded. An additional difficulty is recording nocturnal seizures with smartphones. Whole-night recordings capture these events, but browsing whole-night recordings to find and interpret nocturnal seizures carries considerable workload.

Published results on video-based automated seizure detection have been promising.^{6,7} We took this one step further by using a semiautomated (hybrid) system to classify the seizure types from the automatically detected events. We hypothesized that automated detection of potentially relevant epochs will decrease the workload, and video assessment of these epochs by human experts will give high specificity. In this prospective study, we compared the accuracy of semiautomated seizure classification from the hybrid system with the gold standard of video-EEG recordings (including polygraphic channels) from the epilepsy monitoring unit. We evaluated the decrease in workload by using the algorithm that detects potentially relevant epochs to determine the extent of data reduction.

2 | MATERIALS AND METHODS

Patients with suspected epilepsy were admitted to the Danish Epilepsy Center and Aarhus University Hospital for long-term video-EEG monitoring as part of their diagnostic workup. Inclusion criteria were patients with nocturnal motor seizures; exclusion criteria were patients

Key Points

- We evaluated a semiautomated classification of nocturnal seizures using video analysis
- The hybrid system consisted of an artificial intelligence algorithm, selecting potentially relevant epochs for review by human experts
- The algorithm reduced the duration of video recordings to be reviewed by humans to 14%
- For all seizure types, there was a fair agreement beyond chance with the gold standard
- The hybrid system accurately identified all tonic-clonic and clonic seizures and 82% of focal motor seizures

who did not have nocturnal motor seizures or detections during the monitoring, and patients with unclassified seizures (i.e., when the gold standard could not provide a seizure classification). The study was approved by the regional ethics committee (SJ-756). Patients and caregivers gave their informed consent.

These patients were also monitored with a CE-marked novel video/audio-based seizure detection system (Nelli).^{8,9} Nelli detects activity that is indicative of seizure events with a positive motor component using audio/video recordings. Pretrained detection models with selected thresholds provide captured events including securely accessible audio/video recordings of those events to clinical professionals. Clinical professionals then utilize the captured events and recording to confirm and classify the events accordingly. The hybrid system uses computer vision and machine learning to detect relevant epochs potentially containing seizures or other paroxysmal episodes, and human experts visually assess these epochs. The input is an audio-video recording using a specialized, high-definition video camera and microphones. This mobile recording system can be set up at home or in hospital settings. A previously developed artificial intelligence-based algorithm with a predefined cutoff value was used to mark epochs with potential seizures/clinical episodes in optical flow/audio data.⁹ The detection threshold was set to maximum sensitivity, yielding an event for every period of detectable motion. Subsequently, human experts blinded to all other data visually assessed the videos during the detected periods and classified the motor seizures. Figure 1 shows the analysis workflow diagram.

The two experts assessing the Nelli videos were trained in clinical neurophysiology. First, they independently classified the algorithm-detected epoch. Afterward, they discussed their interpretation and, based on consensus discussion, established the classification. This

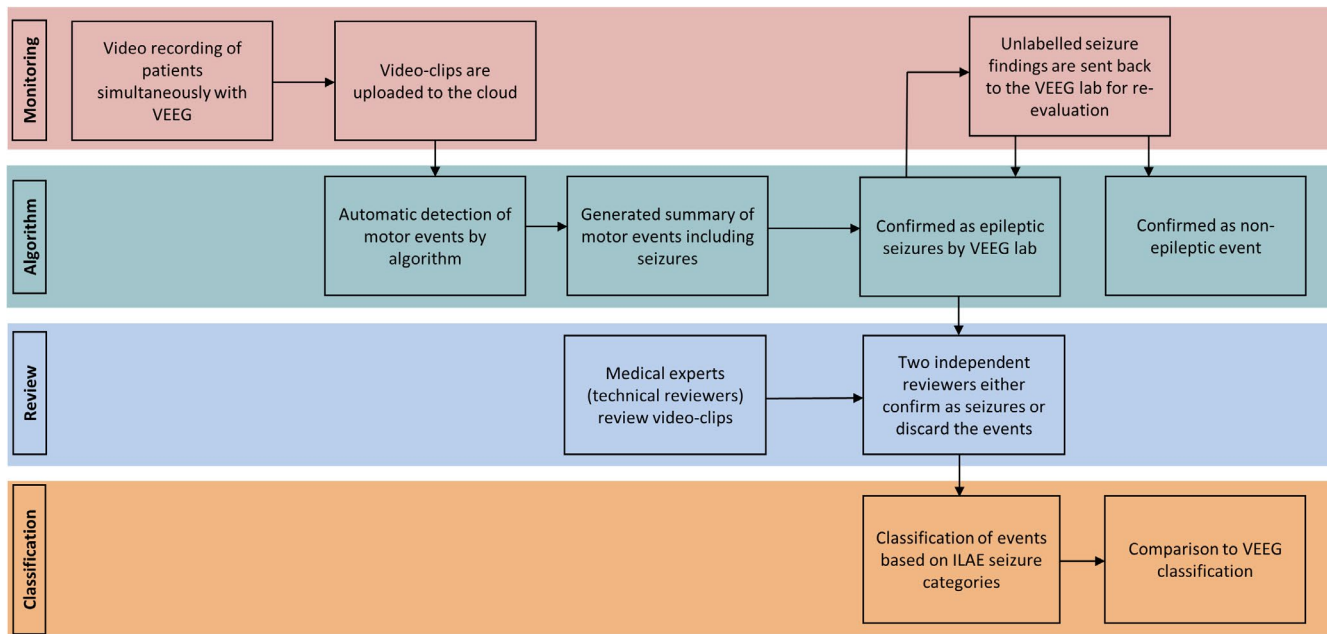


FIGURE 1 Schematic presentation of the Nelli workflow. ILAE, International League Against Epilepsy; VEEG, video-electroencephalography

TABLE 1 Seizure types based on ILAE classification

| | |
|---|---|
| 1 | Focal to bilateral tonic-clonic seizures or generalized tonic-clonic seizures |
| 2 | Clonic seizures |
| 3 | Tonic seizures |
| 4 | Epileptic spasms |
| 5 | Myoclonic seizures |
| 6 | Focal motor seizures |
| 7 | To make a distinction from typical focal motor seizures, an additional seizure type “subtle seizure” with no or minimal behavioral features was constructed (not included in ILAE-recognized seizure types) |

Abbreviation: ILAE, International League Against Epilepsy.

classification was the index test, that is, the outcome of the hybrid system.

The gold standard was derived from the assessment of the long-term video-EEG recordings by another group of experts (i.e., other than the ones who assessed the Nelli videos). The recording array comprised EEG (19–25 electrodes for diagnostic monitoring and 40 electrodes for patients undergoing presurgical evaluation), electrocardiographic, and surface electromyography electrodes, placed as specified in the guidelines of the International Federation of Clinical Neurophysiology.¹⁰ Two experts blinded to the results of the hybrid system evaluated the video-EEG recording data and classified the recorded clinical episodes. Any discrepancies were resolved through a

consensus discussion with a third expert. The gold standard was then compared with the index test (i.e., the classification of the hybrid system). Epochs marked by the hybrid system, but originally not marked by the gold standard, were re-evaluated to ensure that no relevant epoch was overseen.

The seizures were categorized into seizure types according to International League Against Epilepsy classification,¹¹ as shown in Table 1.

The index test from the hybrid system was compared with the gold standard at the seizure-type level. Hence, when a patient had several types of seizure, each of them was compared separately. We compared the agreement between the hybrid system and the gold standard using Gwet’s agreement coefficient (AC1).¹² The analyses were done using Stata version 15.1.

3 | RESULTS

Of the 90 consecutive patients admitted for long-term video-EEG monitoring, 40 patients (24 male, 16 female) fulfilled the inclusion criteria (Figure 2). Median age was 15 years (range = 2–59 years).

A total of 1874 h have been monitored. Device deficiency was 10.3% of the total recording time, resulting in 25 failed nights out of the total of 248 nights. Automatic detection markedly reduced the duration of epochs that had to be reviewed by experts to 259 h (13.8% of the total recording time), with 100% sensitivity for epochs with seizures (i.e., no seizures were left undetected by the

algorithm). Figure 3 shows the graphical user interface displayed to the users after automated detection. The users can quickly access the epochs that were considered relevant to review by the algorithm.

Table 1 summarizes the seizure classifications from the semiautomated (hybrid) system compared with the

gold standard. For all recorded seizure types, there was a fair agreement beyond chance in seizure classification ($AC1 = .33$; 95% confidence interval = .20–.47) between the hybrid system and the gold standard. The hybrid system correctly identified all tonic-clonic and clonic seizures and correctly identified 82% of the focal motor

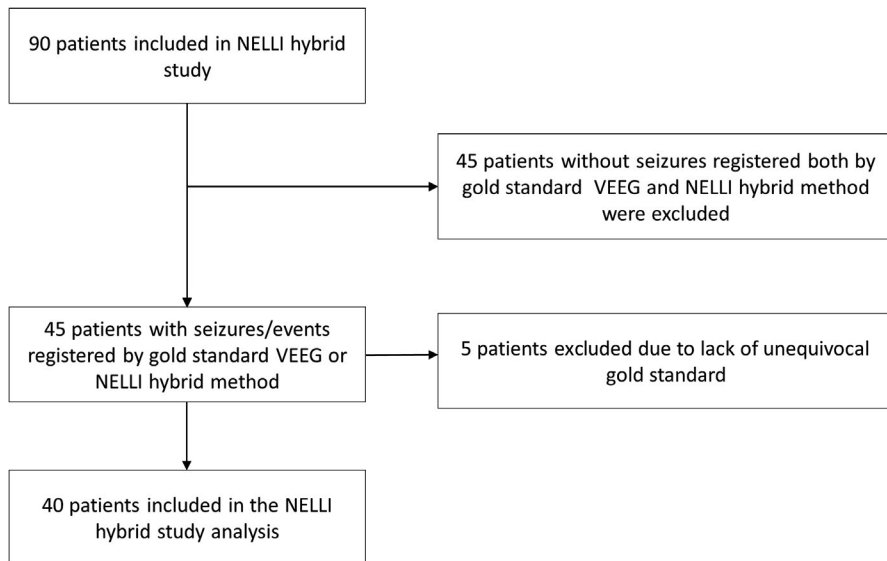


FIGURE 2 Flowchart of patients enrolled in the Nelli hybrid study. VEEG, video-electroencephalography



FIGURE 3 Graphical user interface view. Epochs detected by the algorithm (seizure candidate events) are depicted over a 6-day period with a lighter color and small squares. Three different types of seizures were identified by human annotators and marked by larger dots. The time of the day is represented on the x-axis. White background color refers to registration periods. The videos of the epoch can be reviewed by clicking on a dot (subwindow)

seizures. However, there was lower accuracy in detecting more discrete motor seizures (myoclonic jerks, tonic seizures, and epileptic spasms). Table 2 provides the classification of seizure types in individual patients by the Nelli hybrid system compared to gold standard video-EEG.

Detailed demographic data and seizure types of all included patients are presented in Table S1.

4 | DISCUSSION

We evaluated a semiautomated classification of nocturnal seizures using a video/audio-based automated detection system (Nelli) by selecting potentially relevant epochs for subsequent review by human experts. This hybrid system significantly reduced the workload of humans: only 14% of the total recording time had to be reviewed by human experts. None of the seizures remained undetected by the algorithm. All motor seizures with major motor seizure symptoms (tonic-clonic and clonic seizures) and most of the focal motor seizures (82%) were correctly classified by the hybrid system. However, the overall agreement with the gold standard was lower in the whole cohort because of the low accuracy in classifying other motor seizure types.

The motor components of the misclassified seizures were discrete or subtle. Nocturnal tonic seizures were often unnoticeable under the blanket, yet they were clearly identifiable on the surface electromyographic electrodes, which were part of the gold standard, as they were included as a polygraphic channel in the recording array, in addition to the EEG channels. Similarly, many misclassified myoclonic seizures and epileptic spasms were barely discernible on the video recordings. This explains the poor performance of the semiautomated video analysis for these seizure types and shows that video-EEG recordings (including polygraphic channels) remain the best method to classify epileptic seizures.

There are a few seizure detection devices that are cleared by regulatory bodies to identify tonic-clonic seizures,¹³ but none of these devices can be used to classify seizures. According to previous studies, the variation in sensitivity for automated video-based detection of seizures depends on the seizure type, with the best performance of 94%–100% for convulsive seizures⁷ but less accurate detection of hyperkinetic and tonic seizures, with a sensitivity of 57%.⁶ The Nelli algorithm used in this study for detecting potentially relevant clinical episodes provides an evolving detection paradigm based on specific biomarkers of visual dataflow,⁹ and prepares the detected epochs for further evaluation/classification by human experts. Moreover, audio seizures have been shown to serve as a useful tool for seizure classification¹⁴

TABLE 2 Classification of seizure types in individual patients by the Nelli hybrid system compared to gold standard video-electroencephalography

| Gold standard | Positive predictive value | 3/10 | 1/3 | 3/5 | 5/7 | 6/7 | 9/26 | 0/9 | Sensitivity |
|-----------------|---------------------------|----------------|----------------|----------------|----------------|-------------|-----------------|------------|-------------|
| Myoclonic | 3 ^a | | | | 1 | | | 2 | 3/6 |
| Clonic | | 1 ^a | | | | | | | 1/1 |
| Spasm | 3 | | 3 ^a | | | 1 | | 4 | 3/11 |
| Tonic | 2 | | 2 | 5 ^a | | 1 | | | 5/10 |
| Tonic-clonic | | | | | 6 ^a | | | | 6/6 |
| Focal motor | | | 1 | | 1 | | 9 ^a | | 9/11 |
| Subtle seizures | | | | | | | | 3 | 0/3 |
| No seizure | 2 | 1 | | | 1 | | 15 | | |
| Nelli hybrid | | | | | | | | | |
| | Myoclonic | Clonic | Spasm | Tonic | Tonic-clonic | Focal motor | Subtle seizures | No seizure | |

^aNumber of seizures matches between the gold standard and Nelli hybrid.

and can be combined in a multimodal way to better differentiate video-based detections from false positives. Recently, smartphone videos taken by patient caregivers have been successfully used for the differential diagnosis of paroxysmal neurologic events, for the diagnostic evaluation of psychogenic nonepileptic seizures, and for identifying semiological seizure classification types, giving further recognition to video-based devices/systems.⁴

The strength of this study is a rigorous assessment of the performance of the Nelli hybrid system in a blinded setting without any prior information on the patients or their seizure types against video-EEG monitoring at a well-established epilepsy center. The limitations include the lack of some seizure types, such as hyperkinetic seizures, in the patient population, which included 90 consecutive preplanned registrations, but only 29 patients had seizures within the scope of this study. As a technical limitation of the Nelli system, the camera must be placed so that it observes the patient's body and limbs to detect movement, especially small movements that can be difficult to recognize using marker-free systems, especially if part of the patient's body is covered by a blanket.⁹ The current challenge for video detection systems is the recognition of seizures with more subtle motor features, as was observed in our study, which benefits only part of the patient population.¹⁵ Therefore, reliable detection of subtle seizures might be a future goal for seizure monitoring devices to serve a larger population of epilepsy patients.

5 | CONCLUSIONS

Semiautomated video analysis can be an important tool for classifying major motor seizures, especially in patients with rare nocturnal seizures, where reviewing whole video recordings by human experts is not feasible due to the huge workload. By decreasing the amount of time for reviewing by human experts, the hybrid, algorithm-human expert system will enable the monitoring of patients with nocturnal seizures, even when seizures are rare.

ACKNOWLEDGMENTS

We thank the patients and their caregivers who participated in this study and the personnel of the epilepsy monitoring units of involved centers.

CONFLICT OF INTEREST

J.P. has participated in conducting clinical trials for Eisai, UCB, and Bial; received research grants from Eisai, Medtronic, UCB, and LivaNova; received speaker honoraria from LivaNova, Eisai, Medtronic, Orion Pharma, and UCB; received support from LivaNova, Eisai, Medtronic, and UCB for travel to congresses; and participated on

advisory boards for Arvelle, Novartis, LivaNova, Eisai, Medtronic, UCB, and Pfizer. He is one of the shareholders of Neuro Event Labs. During the study, the institution of S.A.L. received compensation for her time spent on this project, and she has served as a consultant for Neuro Event Labs. S.B. has served as a scientific consultant for Epihunter and received speaker fees from Natus Neuro and Eisai. None of the other authors has any conflict of interest to disclose. We confirm that we have read the Journal's position on issues involved in ethical publication and affirm that this report is consistent with those guidelines.

ORCID

Jukka Peltola  <https://orcid.org/0000-0002-4119-8063>

Pabitra Basnyat  <https://orcid.org/0000-0002-2239-7681>

Sándor Beniczky  <https://orcid.org/0000-0002-6035-6581>

REFERENCES

1. Beniczky SA, Fogarasi A, Neufeld M, Andersen NB, Wolf P, van Emde W, et al. Seizure semiology inferred from clinical descriptions and from video recordings. How accurate are they? *Epilepsy Behav.* 2012;24:213–5.
2. Duun-Henriksen J, Baud M, Richardson MP, Cook M, Kouvas G, Heasman JM, et al. A new era in electroencephalographic monitoring? Subscalp devices for ultra-long-term recordings. *Epilepsia.* 2020;61:1805–17.
3. Cascino GD. Clinical indications and diagnostic yield of video-electroencephalographic monitoring in patients with seizures and spells. *Mayo Clin Proc.* 2002;77:1111–20.
4. Tatum WO, Hirsch LJ, Gelfand MA, Acton EK, LaFrance WC, Duckrow RB, et al. Assessment of the predictive value of outpatient smartphone videos for diagnosis of epileptic seizures. *JAMA Neurol.* 2020;77:593–600.
5. Amin U, Primiani CT, MacIver S, Rivera-Cruz A, Frontera AT, Benbadis SR. Value of smartphone videos for diagnosis of seizures: everyone owns half an epilepsy monitoring unit. *Epilepsia.* 2021;62(9):e135–9.
6. Geertsema EE, Thijs RD, Gutter T, Vledder B, Arends JB, Leijten FS, et al. Automated video-based detection of nocturnal convulsive seizures in a residential care setting. *Epilepsia.* 2018;59(Suppl 1):53–60.
7. van Westrhenen A, Petkov G, Kalitzin SN, Lazeron RHC, Thijs RD. Automated video-based detection of nocturnal motor seizures in children. *Epilepsia.* 2020;61:S36–40.
8. Peciola S, Himanen SL, Knight A, Dibué-Adjei M, Rainesalo S, Peltola J. Under-reporting of nocturnal seizures using video-based home monitoring: a case study on the evaluation of the effect of vagal nerve stimulation. *Epileptic Disord.* 2018;20:535–40.
9. Ojanen P, Knight A, Hakala A, Bondarchik J, Noachtar S, Peltola J, et al. An integrative method to quantitatively detect nocturnal motor seizures. *Epilepsy Res.* 2021;169:106486.
10. Seeck M, Koessler L, Bast T, Leijten F, Michel C, Baumgartner C, et al. The standardized EEG electrode array of the IFCN. *Clin Neurophysiol.* 2017;128:2070–7.

11. Fisher RS, Cross JH, D'Souza C, French JA, Haut SR, Higurashi N, et al. Instruction manual for the ILAE 2017 operational classification of seizure types. *Epilepsia*. 2017;58:531–42.
12. Gwet KL. Computing inter-rater reliability and its variance in the presence of high agreement. *Br J Math Stat Psychol*. 2008;61:29–48.
13. Beniczky S, Wiebe S, Jeppesen J, Tatum WO, Brazdil M, Wang Y, et al. Automated seizure detection using wearable devices: a clinical practice guideline of the International League Against Epilepsy and the International Federation of Clinical Neurophysiology. *Epilepsia*. 2021;62:632–46.
14. Hartl E, Knoche T, Choupina HMP, Rémi J, Vollmar C, Cunha JPS, et al. Quantitative and qualitative analysis of ictal vocalization in focal epilepsy syndromes. *Seizure*. 2018;60:178–83.
15. Ahmedt-Aristizabal D, Fookes C, Denman S, Nguyen K, Fernando T, Sridharan S, et al. A hierarchical multimodal

system for motion analysis in patients with epilepsy. *Epilepsy Behav*. 2018;87:46–58.

SUPPORTING INFORMATION

Additional supporting information may be found in the online version of the article at the publisher's website.

How to cite this article: Peltola J, Basnyat P, Armand Larsen S, Østerkjærhuus T, Vinding Merinder T, Terney D, et al. Semiautomated classification of nocturnal seizures using video recordings. *Epilepsia*. 2022;00:1–7. <https://doi.org/10.1111/epi.17207>