



Research paper

Reduction in median nerve cross-sectional area at the forearm correlates with axon loss in carpal tunnel syndrome

Lauri Martikkala^{a,*}, Katri Mäkelä^a, Sari-Leena Himanen^{a,b}^a Department of Clinical Neurophysiology, Pirkanmaa Hospital District, Medical Imaging Centre and Hospital Pharmacy, Tampere University Hospital, Tampere, Finland^b Faculty of Medicine and Health Technology, Tampere University, Tampere, Finland

ARTICLE INFO

Article history:

Received 23 May 2020

Received in revised form 22 April 2021

Accepted 3 June 2021

Available online 24 June 2021

Keywords:

Carpal tunnel syndrome

Ultrasound

Needle electromyography

Retrograde axonal atrophy

ABSTRACT

Objective: To explore the relationship between axon loss and measured cross-sectional areas of the median nerve (MN) in severe carpal tunnel syndrome (CTS).

Methods: In this retrospective study of 158 examined wrists, we compared axon loss to the ultrasound parameters MN cross-sectional area at the wrist (wCSA), MN cross-sectional area at the forearm (fCSA) and wrist-to-forearm ratio (WFR), in patients with moderate to extreme CTS. Axon loss was evaluated by needle electromyography (EMG) of the abductor pollicis brevis muscle (spontaneous activity and reduction of interference pattern).

Results: Both the spontaneous activity and interference pattern reduction correlated negatively to fCSA ($r = -0.189$, $p = 0.035$; $r = -0.210$, $p = 0.019$; respectively). In moderate CTS, both the spontaneous activity and interference pattern reduction correlated positively to WFR ($r = 0.231$, $p = 0.048$; $r = 0.232$, $p = 0.047$; respectively). The WFR was highest when slight spontaneous activity was detected. Neither wCSA nor WFR correlated with axon loss in severe and extreme CTS.

Conclusions: The fCSA is smaller when axon loss in CTS is more prominent. The WFR is highest when CTS is associated with slight axon loss of the MN.

Significance: CTS might cause retrograde axonal atrophy detected as small fCSA. Prominent axon loss in CTS may reduce the diagnostic value of WFR.

© 2021 International Federation of Clinical Neurophysiology. Published by Elsevier B.V. This is an open access article under the CC BY-NC-ND license (<http://creativecommons.org/licenses/by-nc-nd/4.0/>).

1. Introduction

Carpal tunnel syndrome (CTS) is the most common peripheral neuropathy, with an estimated prevalence of 3% in the general population (Sadosky et al., 2008). CTS is caused by entrapment of the median nerve (MN) in the carpal tunnel at the wrist (Wahab et al., 2017). In mild cases of CTS, there is a loss of myelin insulation (demyelination) of the MN, while axon loss of the MN is associated with more severe CTS (Caetano, 2003; Stevens, 1997; Werner and Andary, 2011). Traditionally, the diagnosis of CTS

Abbreviations: CTS, carpal tunnel syndrome; MN, median nerve; NCS, nerve conduction studies; EDX, electrodiagnostic studies; EMG, needle electromyography; APB, abductor pollicis brevis; HRUS, high-resolution ultrasound; wCSA, median nerve cross-sectional area at the wrist; WFR, wrist-to-forearm ratio; fCSA, median nerve cross-sectional area at the forearm; IP, interference pattern; RAA, retrograde axonal atrophy.

* Corresponding author at: Department of Clinical Neurophysiology, Tampere University Hospital, Medical Imaging Centre and Hospital Pharmacy, Pirkanmaa Hospital District, PO BOX 2000, FI 33521 Tampere, Finland.

E-mail address: laurimartikkala@gmail.com (L. Martikkala).

<https://doi.org/10.1016/j.cnp.2021.06.001>

2467-981X/© 2021 International Federation of Clinical Neurophysiology. Published by Elsevier B.V.

This is an open access article under the CC BY-NC-ND license (<http://creativecommons.org/licenses/by-nc-nd/4.0/>).

has been based on symptoms, clinical assessment and nerve conduction studies (NCS). When necessary, the NCS are complemented with needle electromyography (EMG), both of which are part of electrodiagnostic studies (EDX). Axon loss of the MN in CTS can be evaluated by EMG of the abductor pollicis brevis (APB) muscle.

High-resolution ultrasound (HRUS) of the MN has become an important part of CTS diagnosis. The most studied single HRUS parameter in diagnostics of CTS is the cross-sectional area of the MN at the wrist (wCSA). Another HRUS parameter is wrist-to-forearm ratio (WFR), which is calculated by dividing wCSA by the cross-sectional area of the MN at the forearm (fCSA) (Hobson-Webb et al., 2008). Other HRUS parameters such as power Doppler sonography and shear wave elastography have been under research as well (Cingoz et al., 2018; Dejacco et al., 2013).

In our previous study (Martikkala et al., 2020), we found that the wCSA and WFR correlate with neurophysiological CTS severity. However, in severe CTS, the reliability of the wCSA and WFR as indicators of CTS severity was impaired. Even some normal wCSA and WFR values were found in severe cases of CTS. Our findings were supported by a previous study, which found that wCSA

decreases when CTS progresses from moderate to severe (Moghtaderi et al., 2012).

In the present study, we wanted to explore the relationship between the measured MN cross-sectional areas and axon loss of the MN, evaluated by EMG of the APB muscle, in moderate to extreme CTS. Our hypothesis was that substantial axon loss in CTS might hamper the reliability of HRUS as a diagnostic method.

2. Methods

2.1. Material

The material of this retrospective study comprises 158 examined wrists from 113 patients who had EDX findings suggesting moderate to extreme CTS. Exclusion criteria were previously performed carpal tunnel decompressive surgery, cervical radiculopathy (detected in EMG) and either previously diagnosed polyneuropathy or findings suggesting polyneuropathy in the EDX.

Patients included in the study had been referred to the EDX due to upper limb symptoms suggesting probable carpal tunnel syndrome, or due to more unspecific symptoms of the upper limb(s). The EDX and HRUS studies were performed in 2017 at the Department of Clinical Neurophysiology of Tampere University Hospital as part of patient care. All consecutive patients who underwent both the EDX and HRUS of the MN and did not meet any of the exclusion criteria were included into this retrospective study.

2.2. Electrodiagnostic studies and patient classification

The routine upper limb EDX protocol of our laboratory consists of the NCS and EMG. At the minimum, the NCS consists of sensory neurography of the median, ulnar and radial nerves and motor neurography of the median and ulnar nerves. EMG is performed on 1–2 muscles per myotome from myotomes C5 to T1, innervated by different peripheral nerves, including at least one muscle in the forearm innervated by the MN (usually the flexor carpi radialis muscle). The EMG study includes the evaluation of spontaneous activity (fibrillation potentials and positive sharp waves) in the resting state of the muscle and an estimation of the interference pattern (IP) in muscle activation, grading of fasciculations, and visual estimation of motor unit morphology (amplitude, duration, polyphasic units).

The EDX parameters of the consecutive patients were evaluated retrospectively for the study. At this stage, the exclusion criteria (previously performed carpal tunnel decompressive surgery, cervical radiculopathy, previously diagnosed polyneuropathy) were checked. In addition, if the EDX findings suggested neurogenic lesion, other than CTS, the patient was excluded from the study.

The included NCS parameters were the antidromically registered sensory nerve action potential amplitude and the sensory conduction velocity of the MN (stimulated at the wrist and registered at digits 2, 3 and 4), with the compound muscle action potential amplitude and MN distal motor latency stimulated at the wrist and registered from the APB muscle. These parameters were used to categorize the examined wrists into moderate, severe and extreme CTS categories according to the NCS-based Padua classification (Padua et al., 1997). Distal motor latency >4.1 ms was considered abnormal. Patients with only mild CTS were excluded because axon loss of the MN is not usually associated with mild CTS (Stevens, 1997; Werner and Andary, 2011).

From the EMG parameters, the findings of the MN innervated APB muscle were included into the study. The occurrence of spontaneous activity (fibrillation potentials and positive sharp waves) was scored with a scale from 0 to 4 as follows; 0: no spontaneous activity; 1: single potentials in at least two sites; 2: moderate num-

bers of potentials in at least three sites; 3: several potentials in all sites; 4: profuse potentials in all areas, filling the screen. The interference pattern (IP) was scored with a scale from 0 to 4 as follows; 0: normal IP; 1: slightly reduced IP; 2: moderately reduced IP; 3: severely reduced IP; 4: no activated motor unit potentials. Spontaneous activity and reduced IP were considered to present axonal loss (Kimura, 1984). However, since IP reduction can be caused by demyelination, a reduced IP was scored only if the motor units presented signs of neurogenic lesion (abnormally high amplitude, long duration and/or polyphasic appearance). The presence/absence of spontaneous activity did not affect the scoring of the IP.

2.3. Ultrasound assessment

All patients also underwent HRUS of the MN directly after the EDX. Both the EDX and HRUS were performed by the same clinical neurophysiologist or a registrar specializing in clinical neurophysiology.

The HRUS device used was GE Healthcare Logiq E9 (GE Healthcare, Milwaukee, WI) with a 12.0 MHz ML 6–15-D linear transducer. The MN cross-sectional area at the wrist was measured where the median nerve appeared to be at its largest at the proximity of the carpal tunnel inlet. To calculate the WFR, the cross-sectional area of the MN was also measured at the border of the middle and distal thirds of the forearm. The cross-sectional area was measured inside the hyperechoic epineurium by direct free-hand tracing. All measurements were rounded to the nearest square millimetre.

2.4. Statistical analysis

Statistical analyses were performed using IBM SPSS version 22.0 (SPSS Inc, Chicago, IL). Significant associations and correlations were defined using chi-square test, Mann-Whitney *U* test, Kruskal-Wallis test followed by pairwise comparisons with Bonferroni-corrected Dunn's tests, and Spearman's rho, when appropriate.

3. Results

In total, the wrists of 113 patients (68 females, 45 males) were included into the study. Of these, 45 patients had bilateral CTS. The age of the subjects varied from 23 to 93 years, and the mean age was 62 years. Out of 158 examined wrists, 93 (59%) were in the moderate category, 49 (31%) were in the severe category and 16 (10%) were in the extreme CTS category. The reports of 25 wrists lacked the fCSA. Therefore, the number of analyzed WFR values was 133. Descriptive values of the wCSA, fCSA and WFR are shown in Table 1. The severity of CTS, based on NCS-based Padua classification, did not show significant correlations with the wCSA, WFR or fCSA (Spearman's rho).

Male subjects had larger fCSA than female ($p = 0.006$, Mann-Whitney *U* test, Table 2), but other HRUS parameters did not present any significant differences between genders. The age of the subjects was negatively associated with wCSA ($r = -0.246$, $p = 0.002$, Spearman's rho), but correlations with fCSA and WFR remained nonsignificant.

Spontaneous activity was present in about 30% of the examined APB muscles. The quantified occurrence of spontaneous activity in different CTS categories is presented in Table 3. Profuse spontaneous activity was only found in extreme CTS, whereas in the moderate CTS category spontaneous activity was sparse.

IP reduction manifested in about 70% of the APB muscles. The degree of IP reduction in different CTS categories is presented in Table 3. In almost 50% of the APB muscles in the moderate CTS cat-

Table 1

Descriptive values of wCSA, fCSA and WFR (mean, standard deviation, minimum, maximum, median and number of wrists) in different CTS severity categories. Unit of measure in wCSA and fCSA is mm².

CTS category	Mean	SD	MIN	MAX	Median	n
wCSA						
Moderate	14.4	5.9	7.0	52.0	13.0	93
Severe	15.7	6.6	8.0	34.0	14.0	49
Extreme	14.1	4.4	9.0	23.0	14.5	16
Total	14.8	6.0	7.0	52.0	14.0	158
fCSA						
Moderate	6.1	1.5	4.0	12.0	6.0	81
Severe	6.3	1.8	3.0	11.0	6.0	39
Extreme	5.3	1.1	4.0	7.0	5.0	13
Total	6.1	1.6	3.0	12.0	6.0	133
WFR						
Moderate	2.4	0.7	1.3	4.9	2.3	81
Severe	2.4	0.9	1.0	4.8	2.2	39
Extreme	2.4	0.5	1.8	3.3	2.3	13
Total	2.4	0.7	1.0	4.9	2.3	133

wCSA = cross-sectional area at the wrist, fCSA = cross-sectional area at the forearm, WFR = wrist-to-forearm ratio, CTS = carpal tunnel syndrome.

Table 2

Effect of gender on HRUS parameters.

		Mean	SD	MIN	MAX	Median	n
Female	wCSA	14.4	5.1	8.0	34.0	13.0	92
	fCSA	5.7	1.2	3.0	10.0	6.0	75
	WFR	2.4	0.7	1.3	4.8	2.3	75
Male	wCSA	15.4	7.1	7.0	52.0	14.0	66
	fCSA	6.6	1.8	4.0	12.0	6.0	58
	WFR	2.4	0.8	1.0	4.9	2.2	58

Table 3

Occurrence of spontaneous activity and IP reduction in different CTR categories.

CTS category	Degree of spontaneous activity					Degree of reduced interference pattern				
	0	1	2	3	4	0	1	2	3	4
Moderate	87.1%	5.9%	4.7%	2.3%	0.0%	46.4%	38.1%	10.7%	4.8%	0.0%
Severe	55.3%	17.0%	21.3%	6.4%	0.0%	10.6%	29.8%	40.4%	17.1%	2.1%
Extreme	25.0%	0.0%	37.5%	31.3%	6.2%	0.0%	0.0%	12.4%	43.8%	43.8%
Total	70.3%	8.7%	13.5%	6.8%	0.7%	29.9%	31.3%	20.4%	12.9%	5.5%

Spontaneous activity: 0 = no spontaneous activity; 1 = single potentials in at least two sites; 2 = moderate numbers of potentials in at least three sites; 3 = several potentials in all sites; 4 = profuse potentials in all areas, filling the screen.

Interference pattern: 0 = normal IP; 1 = slightly reduced IP; 2 = moderately reduced IP; 3 = severely reduced IP; 4 = no activated motor unit potentials.

egory, no IP reduction was seen. In the extreme CTS category, no motor units were activated in over 40% of wrists.

Both the amount of spontaneous activity and the degree of IP reduction correlated negatively with the fCSA when all CTS categories were pooled ($r = -0.189$, $p = 0.035$; $r = -0.210$, $p = 0.019$; respectively, Spearman's rho). See Fig. 1 and Fig. 2 for scatterplots. The negative correlations between the fCSA and the amount of spontaneous activity as well as the fCSA and the degree of IP reduction were emphasized when the severe CTS category was considered separately, ($r = -0.346$, $p = 0.034$; $r = -0.342$, $p = 0.035$; respectively, Spearman's rho).

Neither the amount of spontaneous activity nor the degree of IP reduction correlated with the wCSA or the WFR when all CTS categories were pooled. When the CTS categories were considered separately, both the amount of spontaneous activity and the degree of IP reduction correlated positively with the WFR in the moderate CTS category ($r = 0.231$, $p = 0.048$; $r = 0.232$, $p = 0.047$; respectively, Spearman's rho).

Across the different degrees of spontaneous activity, there were statistically significant differences in WFR between groups 0 (median 2.20, mean 2.36 ± 0.68) and 1 (median 2.90, mean 3.12 ± 0.82), and also between groups 1 and 2 (median 2.20 and

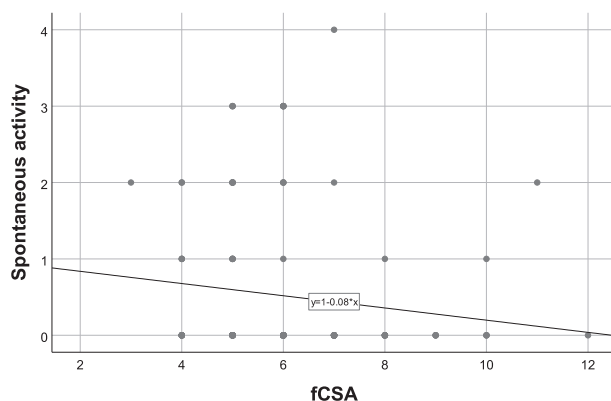


Fig. 1. Scatterplot indicating the relation of the cross-sectional area of the median nerve at the forearm (fCSA) to the spontaneous activity. Note that the majority of the dots are overlapping.

mean 2.16 ± 0.57) ($p = 0.034$, $p = 0.032$, respectively, Bonferroni-corrected Dunn's test) (Fig. 3). There were no statistically significant differences in wCSA or fCSA across the different degrees of

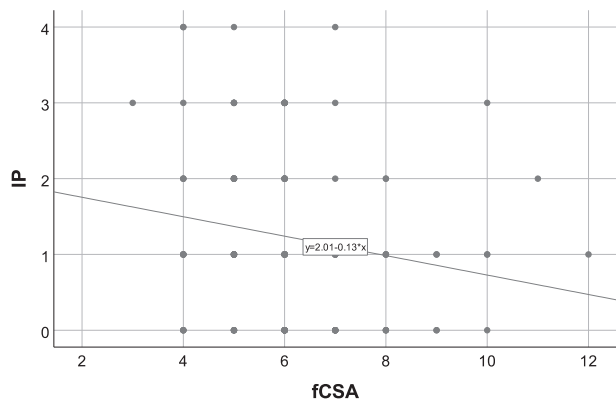


Fig. 2. Scatterplot indicating the relation of the cross-sectional area of the median nerve at the forearm (fCSA) to the interference pattern reduction (IP). Note that the majority of the dots are overlapping.

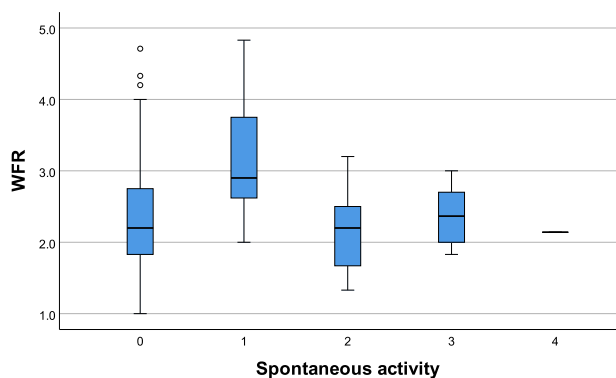


Fig. 3. Box plot of the wrist-to-forearm ratio (WFR) in different degrees of spontaneous activity. The WFR was significantly smaller in groups 0 and 2 than in group 1 ($p = 0.034$ and $p = 0.032$, respectively, Bonferroni-corrected Dunn's test). No statistical significance was found between groups 1 and 3, or between groups 1 and 4. The box indicates the first and third quartile, the thick line within the box represents the median and the bars represent the minimum and maximum values of WFR in each subgroup of the spontaneous activity. The small circles represent outliers.

spontaneous activity ($p = 0.125$, $p = 0.117$, respectively, Kruskal-Wallis test).

4. Discussion

The most interesting finding of our study was that the fCSA is smaller when axon loss in CTS is prominent. This could indicate that axon loss due to severe CTS may cause atrophy of the MN proximally, at the forearm. To our knowledge, this ultrasound finding has not been previously presented. Contradictorily, a previous study did not find any significant difference in fCSA between the study's two patient groups – the one with and one without findings suggesting axon loss (Deng et al., 2018). However, the methods used by Deng et al. (2018) differ from ours, as in their study axon loss was evaluated by the NCS. We defined axon loss with EMG of the APB muscle by specifying the amount of spontaneous activity and the degree of IP reduction, concurrently differentiating axon loss from demyelination. In this way, our study adds to the body of knowledge on the neurophysiology of CTS, as often only NCS is performed when CTS is considered.

However, it can be questioned whether axon loss due to CTS can cause measurable HRUS changes to the MN as far from the entrapment site as at the forearm. Previous studies have found that MN

motor conduction velocity at the forearm decreases in CTS (Buchthal et al., 1974; Stoehr et al., 1978). This is thought to be caused by a conduction block of the large myelinated fibres at the wrist in standard NCS (Stevens, 1997; Wilson, 1998) and/or by retrograde axonal atrophy (RAA) of the MN (Chang et al., 1993, 2000, 2002, 2004, 2008; Pease et al., 1990; Uchida and Sugioka, 1993). The latter is supported by animal models (Anderson et al., 1970; Dyck et al., 1981), detected proximal axonal changes in traumatic peripheral nerve injuries (Gunasekera et al., 2011) and a recent study that found a negative correlation between the wCSA and the forearm mixed nerve amplitude (Choi et al., 2020). The finding of our study may also be explained by RAA. Other etiologies for neurodegeneration, such as amyotrophic lateral sclerosis, have also been shown to cause detectable reduction in the cross-sectional areas of peripheral nerves (Schreiber et al., 2015; Nodera et al., 2014). However, we excluded more proximal lesions of the MN as well as C8/T1 nerve root lesions and any significant polyneuropathies that could cause measurable changes in fCSA with a comprehensive EDX study of the upper limb.

The strength of correlation between wCSA and the severity of CTS has varied greatly in previous studies (Bayrak et al., 2007; Billakota and Hobson-Webb, 2017; El Miedany et al., 2004; Ha et al., 2017; Kang et al., 2012; Karadağ et al., 2010; Kwon et al., 2014; Lee et al., 2005; Mhoon et al., 2012; Padua et al., 2008; Pinilla et al., 2008; Ting et al., 2019; Wiesler et al., 2006; Żyluk et al., 2014). In our previous study (Martikkala et al., 2020), we found that the variance of the wCSA as well as the variance of WFR grows as CTS severity increases. In our present study, which included only wrists with moderate to extreme CTS, the wCSA and WFR did not correlate with the severity of CTS or with the axon loss of the MN. However, in the moderate CTS category, the WFR was larger when the axon loss of the MN was more abundant. In that way, the WFR appears to be highest when there is slight axon loss of the MN (evaluated by the spontaneous activity) (Fig. 3). With more abundant spontaneous activity the WFR was even smaller. Therefore, in severe CTS, WFR might give too mild estimate on degree of axon loss. Combining the findings of our previous study and the present study, it seems that the wCSA and WFR follow a more linear growth in mild and moderate CTS that causes demyelination and slight axon loss of the MN at most. When axon loss is more prominent, the wCSA and WFR seem to behave more unpredictably, which reduces their reliability to indicate the severity of CTS.

Recently, patient age has been shown to have an effect on the diagnostic accuracy of HRUS in determining the diagnosis and categorizing of the severity of CTS (Moschovos et al., 2019; Gregoris and Bland, 2019). In this present study, a slight negative correlation between patient age and wCSA was found, which is in line with the previous literature (Moschovos et al., 2019; Gregoris and Bland, 2019). However, fCSA did not show a similar correlation, indicating that age does not affect fCSA, at least in patients with moderate to extremely severe CTS.

Entrapment of a peripheral nerve has been shown to cause edema and fibrosis of the nerve (Rempel and Diao, 2004), both of which are also possible factors to the variance of wCSA. However, slightly in contradiction with our findings, a negative correlation between wCSA and motor unit number estimation of the APB muscle in CTS patients was found in a previous study (Bayrak et al., 2007). Moreover, in another study, a negative correlation was found between the WFR and the distal sensory nerve action potential amplitude (stimulated at the palm and registered at the third digit), which was considered to represent axon loss (Moon et al., 2017). The mentioned finding of Moon et al. might correspond to our finding that the WFR is greater when axon loss evident in patients with moderate CTS. However, comparison of the studies

is difficult, because the methods used to divide wrists into subgroups and to evaluate axon loss were different.

This research is subject to several limitations. Over two thirds of the examined APB muscles showed no spontaneous activity, but the IP was noticeably reduced in over 70% of the studied APB muscles (Table 3). Both are markers of axon loss, but spontaneous activity is associated with subacute axon loss and it decreases after collateral reinnervation. Therefore, the timing of the EDX might substantially affect the amount of detected spontaneous activity. On the other hand, IP reduction is a more subjective variable, and its interpretation might at least partially be affected by a conduction block at the carpal tunnel. To ensure that the IP reduction was at least partially caused by axon loss, we required neurogenic changes in motor unit potentials (abnormally high amplitude, long duration and/or polyphasic appearance) in addition to reduced IP. Yet neither of these markers of axon loss are flawless. Moreover, the EDX and HRUS were performed by the same physician, who therefore was not blinded to the results. Furthermore, many of the presented associations are rather weak, which may be at least partly explained by the moderate size of the study material. Therefore, the associations should be preferably verified within a larger study material.

Clinically our findings suggest that substantial axon loss of the MN in CTS may hamper the reliability of the wCSA and WFR in grading CTS severity. Therefore, caution is needed when using HRUS in diagnosing and grading the severity of CTS. Because fCSA seems to be smaller when axon loss is prominent in moderate to extreme CTS, possibly due to retrograde axonal atrophy, a large fCSA finding on a CTS patient could suggest that axon loss of the MN is probably not substantial. Further studies are needed to determine the optimal ways in which to use HRUS in diagnosing and grading CTS.

Funding

This study was financially supported by Competitive State Research Financing of the Expert Responsibility area of Tampere University Hospital (Grants 9U007, 9V005).

Declaration of Competing Interest

The authors declare that they have no known competing financial interests or personal relationships that could have appeared to influence the work reported in this paper.

Acknowledgement

None.

References

- Anderson, M.H., Fullerton, P.M., Gilliat, R.W., Hern, J.E., 1970. Changes in the forearm associated with median nerve compression at the wrist in the guinea-pig. *J. Neurol. Neurosurg. Psychiatry* 33, 70–79.
- Bayrak, I.K., Bayrak, A.O., Tilk, H.E., Nural, M.S., Sunter, T., 2007. Ultrasonography in carpal tunnel syndrome: comparison with electrophysiological stage and motor unit number estimate. *Muscle Nerve* 35, 344–348.
- Billakota, S., Hobson-Webb, L.D., 2017. Standard median nerve ultrasound in carpal tunnel syndrome: A retrospective review of 1,021 cases. *Clin. Neurophysiol. Pract.* 2, 188–191.
- Buchthal, F., Rosenfalck, A., Trojaborg, W., 1974. Electrophysiological findings in entrapment of the median nerve at wrist and elbow. *J. Neurol. Neurosurg. Psychiatry* 37, 340–360.
- Caetano, M.R., 2003. Axonal degeneration in association with carpal tunnel syndrome. *Arq. Neuropsiquiatr.* 61, 48–50.
- Chang, M.H., Liao, K.K., Chang, S.P., Kong, K.W., Cheung, S.C., 1993. Proximal slowing in carpal tunnel syndrome resulting from either conduction block or retrograde degeneration. *J. Neurol.* 240, 287–290.
- Chang, M.H., Chiang, H.T., Ger, L.P., Yang, D.A., Lo, Y.K., 2000. The cause of slowed forearm median conduction velocity in carpal tunnel syndrome. *Clin. Neurophysiol.* 111, 1039–1044.
- Chang, M.H., Wei, S.J., Chiang, H.L., Wang, H.M., Hsieh, P.F., Huang, S.Y., 2002. Does direct measurement of forearm mixed nerve conduction velocity reflect actual nerve conduction velocity through the carpal tunnel? *Clin. Neurophysiol.* 113, 1236–1240.
- Chang, M.H., Liu, L.H., Wei, S.J., Chiang, H.L., Hsieh, P.F., 2004. Does retrograde axonal atrophy really occur in carpal tunnel syndrome patients with normal forearm conduction velocity? *Clin. Neurophysiol.* 115, 2783–2788.
- Chang, M.H., Lee, Y.C., Hsieh, P.F., 2008. The role of forearm mixed nerve conduction study in the evaluation of proximal conduction slowing in carpal tunnel syndrome. *Clin. Neurophysiol.* 119, 2800–2803.
- Choi, J., Kim, S.U., Kim, D.G., Park, K.S., 2020. Characteristics of forearm mixed nerve conduction study in carpal tunnel syndrome: comparison with ultrasound assessments. *J. Clin. Neurosci.* 73, 155–158.
- Cingoz, M., Kandemirli, S.G., Alis, D.C., Samanci, C., Kandemirli, G.C., Adatepe, N.U., 2018. Evaluation of median nerve by shear wave elastography and diffusion tensor imaging in carpal tunnel syndrome. *Eur. J. Radiol.* 101, 59–64.
- Dejaco, C., Stradner, M., Zauner, D., Seel, W., Simmet, N.E., Klammer, A., et al., 2013. Ultrasound for diagnosis of carpal tunnel syndrome: comparison of different methods to determine median nerve volume and value of power Doppler sonography. *Ann. Rheum. Dis.* 72, 1934–1939.
- Deng, X., Chau, L.P., Chiu, S.Y., Leung, K.P., Li, S.W., Ip, W.Y., 2018. Exploratory use of ultrasound to determine whether demyelination following carpal tunnel syndrome co-exists with axonal degeneration. *Neural Regen. Res.* 13, 317–323.
- Dyck, P.J., Lais, A.C., Karnes, J.L., Sparks, M., Hunder, H., Low, P.A., et al., 1981. Permanent axotomy, a model of axonal atrophy and secondary segmental demyelination and remyelination. *Ann. Neurol.* 9, 575–583.
- El Miedany, Y.M., Aty, S.A., Ashour, S., 2004. Ultrasonography versus nerve conduction study in patients with carpal tunnel syndrome: substantive or complementary tests? *Rheumatology (Oxford)* 43, 887–895.
- Gregoris, N., Bland, J., 2019. Is carpal tunnel syndrome in the elderly a separate entity? Evidence from median nerve ultrasound. *Muscle Nerve* 60, 217–218.
- Gunasekera, S.M., Wijesekara, R.L., Sesath, H.G., 2011. Proximal axonal changes after peripheral nerve injury in man. *Muscle Nerve* 43, 425–431.
- Ha, D.S., Kim, H.S., Kim, J.M., Lee, K.H., 2017. The correlation between electrodiagnostic results and ultrasonographic findings in the severity of carpal tunnel syndrome in females. *Ann. Rehabil. Med.* 41, 595–603.
- Hobson-Webb, L.D., Massey, J.M., Juel, V.C., Sanders, D.B., 2008. The ultrasonographic wrist-to-forearm median nerve area ratio in carpal tunnel syndrome. *Clin. Neurophysiol.* 119, 1353–1357.
- Kang, S., Kwon, H.K., Kim, K.H., Yun, H.S., 2012. Ultrasonography of median nerve and electrophysiologic severity in carpal tunnel syndrome. *Ann. Rehabil. Med.* 36, 72–79.
- Karadağ, Y.S., Karadağ, O., Çiçekli, E., Öztürk, S., Kiraz, S., Ozbakir, S., et al., 2010. Severity of Carpal tunnel syndrome assessed with high frequency ultrasonography. *Rheumatol. Int.* 30, 761–765.
- Kimura, J., 1984. *Electrodiagnosis in Diseases of Nerve and Muscle: Principles and Practice*. F.A. Davis, Philadelphia.
- Kwon, H.K., Kang, H.J., Byun, C.W., Yoon, J.S., Kang, C.H., Pyun, S.B., 2014. Correlation between ultrasonography findings and electrodiagnostic severity in carpal tunnel syndrome: 3D ultrasonography. *J. Clin. Neurol.* 10, 348–353.
- Lee, C.H., Kim, T.K., Yoon, E.S., Dhong, E.S., 2005. Correlation of high-resolution ultrasonographic findings with the clinical symptoms and electrodiagnostic data in carpal tunnel syndrome. *Ann. Plast. Surg.* 54, 20–23.
- Martikkala, L., Himanen, S.L., Virtanen, K., Makela, K., 2020. The neurophysiological severity of carpal tunnel syndrome cannot be predicted by median nerve cross-sectional area and wrist-to-forearm ratio. *J. Clin. Neurophysiol.* <https://doi.org/10.1097/WNP.0000000000000696>.
- Mhoon, J.T., Juel, V.C., Hobson-Webb, L.D., 2012. Median nerve ultrasound as a screening tool in carpal tunnel syndrome: correlation of cross-sectional area measures with electrodiagnostic abnormality. *Muscle Nerve* 46, 871–878.
- Moghtaderi, A., Sanei-Sistani, S., Sadoughi, N., Hamed-Azimi, H., 2012. Ultrasound evaluation of patients with moderate and severe carpal tunnel syndrome. *Prague Med. Rep.* 113, 23–32.
- Moon, H.I., Kwon, H.K., Lee, A., Lee, S.K., Pyun, S.B., 2017. Sonography of carpal tunnel syndrome according to pathophysiological type: conduction block versus axonal degeneration. *J. Ultrasound Med.* 36, 993–998.
- Moschosov, C., Tsigvoulis, G., Kyrozis, A., Ghika, A., Karachalia, P., Voumvourakis, K., Chroni, E., 2019. The diagnostic accuracy of high-resolution ultrasound in screening for carpal tunnel syndrome and grading its severity is moderated by age. *Clin. Neurophysiol.* 130, 321–330.
- Nodera, H., Takamatsu, N., Shimatani, Y., Mori, A., Sato, K., Oda, M., et al., 2014. Thinning of cervical nerve roots and peripheral nerves in ALS as measured by sonography. *Clin. Neurophysiol.* 125, 1906–1911.
- Padua, L., LoMonaco, M., Gregori, B., Valente, E.M., Padua, R., Tonalì, P., 1997. Neurophysiological classification and sensitivity in 500 carpal tunnel syndrome hands. *Acta Neurol. Scand.* 96, 211–217.
- Padua, L., Pazzaglia, C., Caliandro, P., Granata, G., Foschini, M., Briani, C., et al., 2008. Carpal tunnel syndrome: ultrasound, neurophysiology, clinical and patient-oriented assessment. *Clin. Neurophysiol.* 119, 2064–2069.
- Pease, W.S., Lee, H.H., Johnson, E.W., 1990. Forearm median nerve conduction velocity in carpal tunnel syndrome. *Electromyogr. Clin. Neurophysiol.* 30, 299–302.

- Pinilla, I., Martín-Hervás, C., Sordo, G., Santiago, S., 2008. The usefulness of ultrasonography in the diagnosis of carpal tunnel syndrome. *J. Hand Surg. Eur.* 33, 435–439.
- Rempel, D.M., Diao, E., 2004. Entrapment neuropathies: pathophysiology and pathogenesis. *J. Electromyogr. Kinesiol.* 14, 71–75.
- Sadosky, A., McDermott, A.M., Brandenburg, N.A., Strauss, M., 2008. A review of the epidemiology of painful diabetic peripheral neuropathy, postherpetic neuralgia, and less commonly studied neuropathic pain conditions. *Pain Pract.* 8, 45–56.
- Schreiber, S., Abdulla, S., Debska-Vielhaber, G., Machts, J., Dannhardt-Stieger, V., Feistner, H., et al., 2015. Peripheral nerve ultrasound in amyotrophic lateral sclerosis phenotypes. *Muscle Nerve* 51, 669–675.
- Stevens, J.C., 1997. AAEM minimonograph #26: the electrodiagnosis of carpal tunnel syndrome. *American Association of Electrodiagnostic Medicine. Muscle Nerve* 20, 1477–1486.
- Stoehr, M., Petruch, F., Scheglmann, K., Schilling, K., 1978. Retrograde changes of nerve fibers with the carpal tunnel syndrome. An electroneurographic investigation. *J. Neurol.* 218, 287–292.
- Ting, B.L., Blazar, P.E., Collins, J.E., Mora, A.N., Salajegheh, M.K., Amato, A.A., et al., 2019. Median nerve ultrasonography measurements correlate with electrodiagnostic carpal tunnel syndrome severity. *J. Am. Acad. Orthop. Surg.* 27, e17–e23.
- Uchida, Y., Sugioka, Y., 1993. Electrodiagnosis of retrograde changes in carpal tunnel syndrome. *Electromyogr. Clin. Neurophysiol.* 33, 55–58.
- Wahab, K.W., Sanya, E.O., Adebayo, P.B., Babalola, M.O., Ibraheem, H.G., 2017. Carpal tunnel syndrome and other entrapment neuropathies. *Oman Med. J.* 32, 449–454.
- Werner, R.A., Andary, M., 2011. Electrodiagnostic evaluation of carpal tunnel syndrome. *Muscle Nerve* 44, 597–607.
- Wiesler, E.R., Chloros, G.D., Cartwright, M.S., Smith, B.P., Rushing, J., Walker, F.O., 2006. The use of diagnostic ultrasound in carpal tunnel syndrome. *J. Hand Surg. Am.* 31, 726–732.
- Wilson, J.R., 1998. Median mixed nerve conduction studies in the forearm: evidence against retrograde demyelination in carpal tunnel syndrome. *J. Clin. Neurophysiol.* 15, 541–546.
- Żyluk, A., Walaszek, I., Szlosser, Z., 2014. No correlation between sonographic and electrophysiological parameters in carpal tunnel syndrome. *J. Hand Surg. Eur.* 39, 161–166.