



The de Winter ECG pattern: Distribution and morphology of ST depression

Zhong-Qun Zhan MD¹ | Yang Li MS¹ | Li-Hong Han MS¹ | Kjell C. Nikus MD, PhD² | Yochai Birnbaum MD, FACC, FAHA³ | Adrian Baranchuk MD, FACC, FRCPC⁴

¹Department of Cardiology, Shenzhen Hospital-University of Chinese Academy of Sciences, Shenzhen, China

²Department of Cardiology, Heart Center, Tampere University Hospital, Tampere and Faculty of Medicine and Health Technology, Tampere University, Tampere, Finland

³The Section of Cardiology, Baylor College of Medicine and Texas Heart Institute, Baylor St. Luke Medical Center, Houston, TX, USA

⁴Department of Cardiology, Kingston General Hospital, Queen's University, Kingston, ON, Canada

Correspondence

Zhong-qun Zhan, Department of Cardiology, Shenzhen Hospital-University of Chinese Academy of Sciences, Guangming district, Shenzhen City 518107, China.
Email: zzqun21@126.com

Abstract

Background: The reported positive predictive value (PPV) for the “de Winter ECG pattern” to predict an acute left anterior descending artery (LAD) lesion is inconsistent. Besides, the morphology of upsloping or nonupsloping ST depression (STD) may have different significance of severity and prognostication.

Methods: We searched the MEDLINE database using “de Winter” or “junctional ST-depression with tall symmetrical T-waves” or “tall T wave” or “STEMI equivalent” as the item up to March 2020. We compared the ECG differences between the different culprit arteries and various morphological STD.

Results: A total of 70 patients with analyzable ECGs were included. In 60 patients (LAD group), the LAD was the culprit artery, while in 10 patients (non-LAD group), there were other etiologies. Maximal STD in V2 or V3 had a PPV of 89% of all patients and 98% of patients without ST elevation in V2 to detect an acute LAD lesion. The presence of q/Q-wave or poor R-wave progression in the precordial leads was significantly more often found in patients with upsloping STD than in patients with nonupsloping STD in the LAD group (84% vs. 27%, $p < .01$). In 18 patients, the ECG showed a change from upsloping to nonupsloping STD from the leads with maximal STD to the surrounding leads with less STD.

Conclusions: The location of the maximal STD in the precordial leads differs between patients with LAD as the culprit artery and other etiologies of the de Winter ECG pattern. Upsloping STD signifies more severe signs of ischemia than nonupsloping STD.

KEYWORDS

acute coronary occlusion, de Winter pattern, electrocardiogram, severity, upsloping ST depression

1 | INTRODUCTION

The primary purpose in describing any clinical or electrocardiographic (ECG) sign should be to help the practicing physicians

recognize the high-risk patients and guide therapeutic actions. In 2008, de Winter et al described an ECG pattern suggesting that it should be considered an ST-elevation myocardial infarction (STEMI) equivalent (de Winter, Verouden, Wellens, & Wilde, 2008), with the

This is an open access article under the terms of the Creative Commons Attribution-NonCommercial-NoDerivs License, which permits use and distribution in any medium, provided the original work is properly cited, the use is non-commercial and no modifications or adaptations are made.

© 2020 The Authors. *Annals of Noninvasive Electrocardiology* published by Wiley Periodicals LLC

potential to predict critical stenosis or occlusion of the left anterior descending coronary artery (LAD). This ECG pattern typically features junctional ST-segment depression (STD) followed by tall, symmetrical T waves in the precordial leads (Verouden et al., 2009). Although the pattern has a high positive predictive value (PPV) for critical stenosis or acute occlusion of a coronary artery, the reported PPV to detect an acute LAD lesion is highly inconsistent, ranging from 50% to 100% (Raja, Nanda, Pour-Ghaz, & Khouzam, 2019). Although the original description of STD was upsloping, de Winter et al (Verouden et al., 2009; de Winter et al., 2008) and other authors have included other forms of STD even in the original manuscript. The morphology of upsloping, horizontal, or downsloping STD may have different significance regarding the underlying physiology and/or prognosis (Misumida, Kobayashi, Schweitzer, & Kanei, 2015). We hypothesized that the pattern and distribution of the STD could aid in predicting the culprit artery and the severity of ischemia and therefore prognosis. To test the hypothesis, we reviewed the literature related to the de Winter ECG pattern and compared the ECG and clinical differences between various etiologies of the pattern, especially regarding culprit artery and various morphological STD.

2 | METHODS

We searched the MEDLINE using “de Winter (Title)” or “junctional ST-depression with tall symmetrical T-waves (Title)” or “tall T wave (Title)” or “STEMI equivalent (Title)” as the item up to March 2020. To avoid missing related articles, we also searched the original article (de Winter et al., 2008) that described the de Winter ECG pattern and 38 articles in the MEDLINE, where this article was cited.

Each article was read by three investigators (Zhan ZQ, L Y, and Han LH). We included articles, where the ECGs were shown and where the authors considered the ECG findings compatible with the de Winter pattern accompanied by the corresponding diagnosis and/or culprit artery. Every ECG was described by the authors as the de Winter pattern, and clinical data were extracted and independently analyzed by two investigators (L Y and Han LH). We excluded ECGs with poor printed quality. The J point was determined for each lead. Both ST-segment elevation (STE) and STD were measured at the J point in all leads. The TP segment was used as the iso-electric line. The continuous variables were calculated to the nearest 0.1 mV using the small squares as reference. In case of disagreement between the two investigators, we used the average of the measurements, and cases with disagreement in categorical variables were resolved by consensus. The following data were extracted or measured: sex; age; timing from symptom onset to recording of the ECG with the de Winter pattern, QRS width, pathological Q-wave or equivalent or poor R-wave progression in the precordial leads, location of the lead with maximal STD or maximal tall T wave, and the lead(s) with ST elevation (STE); the value of maximal STD, culprit artery, and culprit site with Thrombolysis In Myocardial Infarction (TIMI) or Rentrop flow grade; the morphology of STD (upsloping, horizontal, or downsloping pattern in the leads with STD); the morphological changes of the

STD from maximum to minimum (usually from V2/V3 to V5/V6) in the precordial leads; and the ST-T change pattern before and after the de Winter pattern in relation to the reperfusion therapy including typical STEMI, “hyperacute” tall T waves, de Winter pattern, and Wellens’ sign (Baranchuk & Bayés-Genis, 2016; Tzimas, Antiochos, & Monney, 2019).

All data were analyzed by SPSS 22.0. Data were expressed as mean \pm standard deviation for continuous variables and numbers (%) for categorical variables. Categorical variables were compared using the chi-square test or the Fisher exact test. A two-tailed probability value $< .05$ was considered statistically significant.

3 | RESULTS

A total of 51 out of 86 articles included 83 patients (Ahmadi, KhamenehBagheri, Vojdanparast, & Jafarzadeh-Esfehani, 2019; Canakci, Turgay, Acar, & Mert, 2018; Carr, O’Shea, & Hinfey, 2016; Carrington, Santos, Picarra, & De, 2018; Chen, Wang, & Huang, 2020; de Winter, Adams, & Amoroso, 2019; Fiol Sala, Bayés de Luna, Carrillo López, & García-Niebla, 2015; García-Izquierdo, Parra-Esteban, Mirelis, & Fernández-Lozano, 2018; Giovanni & Francesco, 2020; Goktas, Sogut, Yigit, & Kaplan, 2017; Grandjean, Degrauwe, Tessitore, & Iglesias, 2019; Hanna & Glancy, 2016; He, Liu, & Wang, 2020; Hennings & Fesmire, 2012; Karna, Chourasiya, Chaudhari, Bakrenia, & Patel, 2019; Lam, Cheung, Wai, Wong, & Tse, 2019; Li, Li, Man, Li, & Long, 2019; Lin, Wen, Wu, & Xu, 2019; Mahajan, Batra, & Gupta, 2018; Martínez-Losas & Fernández-Jiménez, 2016; Massobrio, Scarrone, & Valbusa, 2016; Montero Cabezas, Karalis, & Schalij, 2016; Montero-Cabezas, van-der-Kley, Karalis, & Schalij, 2015; Niimi, Ooka, Shiraishi, & Fukuda, 2019; Patel, Baker, Paterick, & Tajik, 2017; Pica, Ballestrero, Pistis, & Crimi, 2016; Pranata, Huang, & Damay, 2018; Qayyum, Hemaya, Squires, & Adam, 2018; Qu, Tao, & Liu, 2019; Rao, Wang, & Zhang, 2018; Rodrigues, Gomes, Drumond, & Pereira, 2016; Samadov, Akaslan, Cincin, Tigen, & Sari, 2014; Sunbul, Erdogan, Yesildag, & Mutlu, 2015; Thabouillot, Bouvier, & Roche, 2017; Tsutsumi & Tsukahara, 2018; Verouden et al., 2009; Viejo-Moreno, Rubio-Muñoz, Cabrejas-Aparicio, & Novo-García, 2018; Viejo-Moreno, Rubio-Muñoz, Cabrejas-Aparicio, & Novo-García, 2018; de Winter, Adams, Verouden, & de Winter, 2016; de Winter et al., 2008; Xu, Wang, Liu, & Chen, 2018; Xu, Jiang, & Feng, 2018; Xu, Lu, & Jin, 2019; Xu, Xu, Peng, & Huang, 2019; Xu, Zou, & Huang, 2019; Yang, Liu, Zhu, & Song, 2017; Yang, Ma, & Yin, 2019; Zhan, Nikus, & Birnbaum, 2020; Zhang et al., 2019; Zhao, Wang, & Yi, 2016; Zorzi et al., 2012) with ECGs described by the authors as the de Winter pattern. We excluded 13 patients due to poor ECG quality (de Winter et al., 2019; Viejo-Moreno et al., 2018; de Winter et al., 2016). The remaining 70 patients included 60 patients (Ahmadi et al., 2019; Canakci et al., 2018; Carr et al., 2016; Carrington et al., 2018; Fiol Sala et al., 2015; Giovanni & Francesco, 2020; Goktas et al., 2017; Grandjean et al., 2019; Hanna & Glancy, 2016; He et al., 2020; Hennings &

Fesmire, 2012; Lam et al., 2019; Li et al., 2019; Lin et al., 2019; Mahajan et al., 2018; Martínez-Losas & Fernández-Jiménez, 2016; Montero-Cabezas, van-der Kley, Karalis, & Schali, 2015; Niimi et al., 2019; Patel et al., 2017; Pica et al., 2016; Pranata et al., 2018; Qayyum et al., 2018; Qu et al., 2019; Rao et al., 2018; Rodrigues et al., 2016; Samadov et al., 2014; Thabouillot et al., 2017; Verouden et al., 2009; Viejo-Moreno et al., 2018; de Winter et al., 2008, 2016; Xu, Wang, et al., 2018; Xu, Jiang, et al., 2018; Xu, Lu, et al., 2019; Xu, Xu, et al., 2019; Yang et al., 2017, 2019; Zhang et al., 2019; Zhao et al., 2016; Zorzi et al., 2012), in whom the acute disease process was caused by a lesion in the LAD (LAD group), and 10 patients with another culprit artery or other etiology (non-LAD group): two patients with first diagonal branch (D1) occlusion (Lin et al., 2019; Montero Cabezas et al., 2016), one with obtuse marginal artery (OM) occlusion (Xu, Zou, et al., 2019), one with microvascular dysfunction (MVD; Chen et al., 2020), two with right coronary artery (RCA) disease (Karna et al., 2019; Tsutsumi & Tsukahara, 2018), two with left main coronary artery (LM) disease (Sunbul et al., 2015; Zhan et al., 2020), one possible LM case (Massobrio et al., 2016), and one myocarditis case (García-Izquierdo et al., 2018). Figure 1 shows the flow chart of patient selection for analysis.

The majorities of the patients were male (51 out of 56 patients, 91%). The age was 53 ± 13 years. Timing from symptom onset to recording the de Winter pattern was 99 ± 79 min. The heart rate when recording the ECG with de Winter pattern was

74 ± 18 bpm. The maximal amplitude of the STD was 3 ± 2 mm. The maximal amplitude of the positive (tall) T wave was 9 ± 3 mm. Table 1 shows the ECG and angiographic findings of the two groups.

When dividing the analyzed ECGs based on the lead with maximal STD, the results were as follows. In the LAD group, 9 patients had the maximal change in lead V2, 44 in V3, and 7 in V4, while there was no case with the maximal STD in lead V5. The corresponding numbers for non-LAD group were as follows: 1 in V2, 2 in V3, 6 in V4, and 1 in V5. The difference between the two groups was statistically significant ($p = .001$). Maximal STD in V2 or V3 had a PPV of 89% of all patients and 98% of patients without STE in V2-V6 to detect an acute LAD disease.

There were 42 patients, where the location of the culprit lesion with respect to the first septal branch (S1) and D1 in the LAD group could be defined. We divided the patients into two groups based on the location of the culprit lesion with respect to the LAD side branches. When the culprit lesion was proximal to the S1 and D1, there were 4 patients with the maximal STD in lead V2, 14 in V3, and 2 in V4. In contrast, there were 6 patients with the maximal STD in lead V2, 11 in V3, and 5 in V4, when the culprit site was distal to S1 and/or D1. The difference between the proximal and distal LAD occlusion site was not statistically significant ($p = .38$).

Regarding the distribution T-wave changes, there were 25 patients with the tallest positive T wave in lead V2, 30 in V3, and 5 in

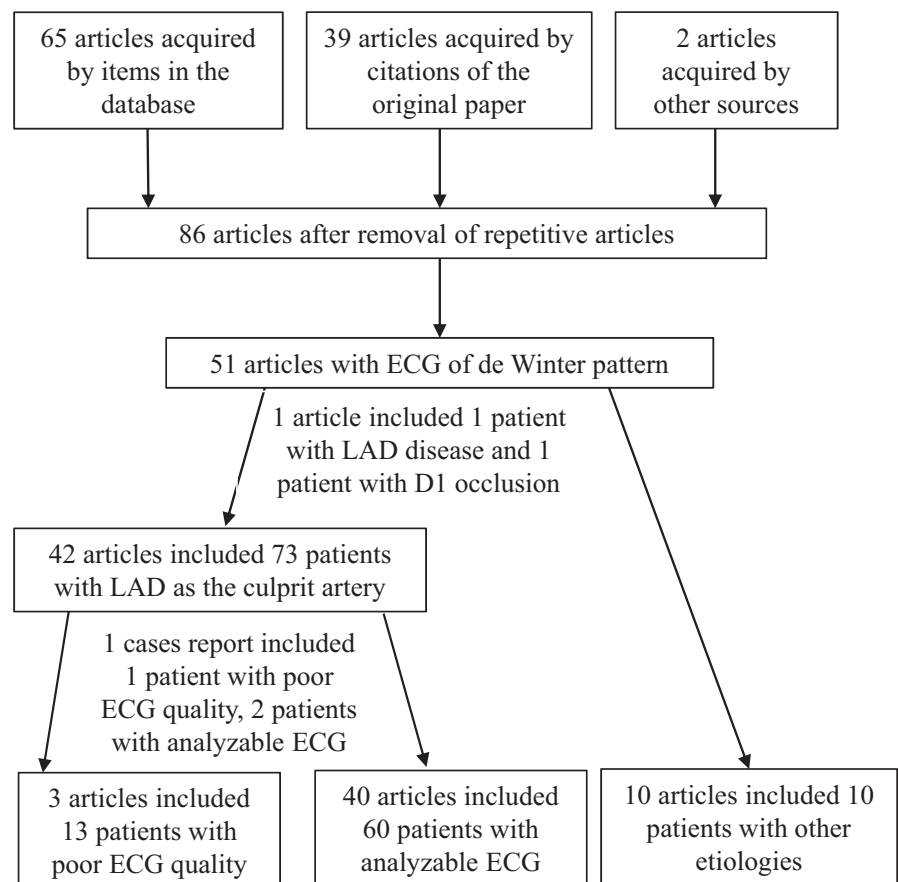


FIGURE 1 Flow chart of patient selection for analysis

TABLE 1 ECG and angiographic findings in patients with LAD as the culprit artery and other etiologies

	Culprit LAD (n = 60)	Other etiologies (n = 10)
Sinus rhythm	60 (100%)	9 (90%)
Heart rate (min ⁻¹)	74 ± 19 (n = 47)	76 ± 6 (n = 7)
QRS width ≤ 110 ms	56 (93%)	7 (70%)
QRS width > 110 ms	4 (7%)	3 (30%)
Amplitude of maximal ST depression (mm)	3 ± 2	4 ± 2
Amplitude of maximal positive T wave (mm)*	10 ± 3	7 ± 2
Lead with maximal ST depression*		
V2	9 (15)	1 (10)
V3	44 (73)	2 (20)
V4	7 (12)	6 (60)
V5	0 (0)	1 (10)
Lead with maximal positive T wave		
V2	25 (42)	3 (30)
V3	30 (50)	5 (50)
V4	5 (8)	2 (20)
Lead with ST elevation		
V1	23 (38)	3 (20)
aVR	57 (95)	3 (30)
V1-V2	7 (12)	1 (10)
III and/or aVF, II	4 (7)	1 (10)
aVL and/or I	14 (23)	4 (40)
Pathological Q wave or equivalent		
aVL and/or I	13 (22)	5 (50)
III and/or aVF	1 (2)	2 (20)
q/Q-wave or poor R-wave progression in V1-V3/V4	44 (73)	4 (40)
ST-T pattern dynamics		
From STEMI to de Winter sign before reperfusion	13 (22)	0 (0)
From tall T wave to de Winter sign before reperfusion	2 (3)	0 (0)
From de Winter sign to Wellens' sign before reperfusion	1 (2)	0 (0)
From de Winter sign to Wellens' sign after reperfusion	1 (2)	0 (0)
From STEMI to de Winter sign after thrombolysis	2 (3)	0 (0)

(Continues)

TABLE 1 (Continued)

	Culprit LAD (n = 60)	Other etiologies (n = 10)
From de Winter sign to STEMI after PCI	9 (15)	0 (0)
Morphology of ST depression from maximum to minimum (usually from V2/V3 to V5/V6)		
Upsloping	37 (62)	8 (80)
Horizontal	4 (7)	0(0)
Downsloping	2 (3)	1 (10)
From upsloping to nonupsloping	12 (20)	0 (0)
From horizontal to downsloping	5 (8)	1 (10)
Angiographic findings		
TIMI 2–3 flow	11 (28) (n = 39)	4 (50) (n = 8)
TIMI 0–1 flow	28 (72) (n = 39)	4 (50) (n = 8)
LAD before S1 and D1	20 (48) (n = 42)	–
LAD distal to S1 or D1	22 (52) (n = 42)	–

Abbreviations: D1, first diagonal branch; LAD, left anterior descending coronary artery; PCI, percutaneous coronary intervention; S1, first septal branch.

* $p < .01$.

V4 in the LAD group, in contrast to 3 in V2, 5 in V3, and 2 in V4 in the non-LAD group. The difference between the two groups was not statistically significant ($p = .48$).

In the LAD group, some patients presented other signs of anterior myocardial infarction: 23% with STE in aVL and/or I, 73% with pathological q/Q-wave or poor R-wave progression in leads V1/V2-V3/V4, 12% with STE in V1-V2, and 7% with STE in the inferior leads. In the non-LAD group, the de Winter pattern was present in the inferior and V3-V6 leads associated with RCA occlusion, in leads V2-V6 and inferior leads related to occlusion of a gigantic OM branch, in leads V2-V6 related to D1 occlusion, and in V2-V4 leads possibly by microvascular dysfunction in the myocardial region perfused by the LAD. The de Winter pattern associated with anterolateral or inferolateral leads with other concomitant markers of extensive myocardial ischemia, such as striking QRS widening and STE in aVR higher than in V1, was present in patients with LM or likely LM disease.

Regarding the morphology of STD from maximum to minimum (usually from V2/V3 to V5/V6) in the LAD group, there were 43 (72%) patients with a similar type of STD in the lead with maximal STD and the neighboring lead(s): 37 (62%) with upsloping STD, 4 (7%) with horizontal STD, and 2 (3%) with downsloping STD. The remaining 17 (28%) patients showed differences between the lead with maximal STD and the neighboring lead(s). These differences are shown in detail in Table 1. Examples of different morphology of ST depression are shown in Figure 2.

In the LAD group, pathological q/Q-wave or poor R-wave progression was associated with upsloping STD in 41 (84%) patients,

while the corresponding number for nonupsloping STD was 3 (27%) ($p < .01$). Similar results were observed in the non-LAD group: Upsloping STD was present in LM disease (Massobrio et al., 2016; Sunbul et al., 2015; Zhan et al., 2020), MVD (Chen et al., 2020), RCA (Tsutsumi & Tsukahara, 2018), and D1 (Lin et al., 2019; Montero Cabezas et al., 2016) occlusion. The de Winter pattern with upsloping STD in the inferior leads and downsloping STD in V2–V6 by an OM occlusion evolved to q waves in the inferior leads and normal R wave in leads V2–V6 after successful percutaneous coronary intervention (PCI; Xu, Zou, et al., 2019).

Regarding dynamics of ST-T ECG category during the evolving disease process in 28 patients in the LAD group, there was a change from anterior STEMI to the de Winter pattern before reperfusion in 13 patients. Other changes are infrequent, and they are presented in detail in Table 1. In 39 patients in the LAD group, where data of the

TIMI flow grade were available. Total/subtotal LAD occlusion with TIMI 0–1 flow was reported in 28 (72%) patients with the LAD as the culprit artery, in contrast to 11 (28%) patients with TIMI 2–3 flow on angiography.

4 | DISCUSSION

Traditionally, the ST segment was measured 0.08 s after the J point, but later on, upsloping configuration was not thought to represent ischemia. In 1955, Pruitt et al described a patient with STD and tall, sharply peaked positive T waves in leads V3–V5 one hour after an episode with severe chest pain (Pruitt, Klakeg, & Chapin, 1955). Two days later, the ECG showed deep inverted T waves in leads V2–V4 that in the 1980s was named the Wellens' sign. Later on, Sclarovsky et al. presented a patient with unstable angina, where the initial ECG presentation was STD with an upsloping or downsloping ST level and a peaked positive T wave in the precordial leads, describing the phenomenon as regional myocardial ischemia (Sclarovsky, Rechavia, & Strasberg, 1988). In 2008, de Winter et al presented patient cases associated with subtotal or total occlusion of the LAD, with junctional STD (STD at the J point ≥ 1 mm) followed by tall, symmetrical T waves in the precordial lead in their ECG (de Winter et al., 2008).

4.1 | The distribution of the de Winter pattern in different ECG leads and the culprit artery

This review demonstrates that the lead distribution of the ECG with the maximal STD differs between patients with the LAD as the culprit artery and those, where this ECG sign was related to other etiologies. The difference was statistically significant. The “core ischemia” lead with maximal STD was located to V2 (15%) or V3 (73%) in the majority of patients with LAD as the culprit artery. Although the difference between proximal and distal LAD culprit lesions was not significant regarding the distribution of the lead with maximal STD, there were 6 out of 7 patients presenting maximal STD in V4 in combination with STE in V1–V2. This could possibly be due to concomitant STE in V1–V2 counteracting the STD in V3. Maximal STD in V2 or V3 had a PPV of 89% of all patients and 98% of patients without STE in V2 to detect an acute LAD disease. Thus, we consider that leads V2 and V3 express the core ischemia when the LAD is the culprit artery. Regarding the ECG changes in the patients with other etiologies, the number of patients was extremely small. Therefore, it is not possible to draw any firm conclusions about the association between the location of the de Winter pattern in different ECG leads and the culprit lesion or other background factors.

We observed that it could be important to include other ECG signs of ischemia associated with the de Winter pattern to predict the culprit artery. STE in V1–V2/V3 as a STEMI (or equivalent) and pathological Q-wave or poor R-wave progression may indicate myocardial necrosis or stunning, and QRS widening may express extensive myocardial involvement (Zhan et al., 2020). There were three

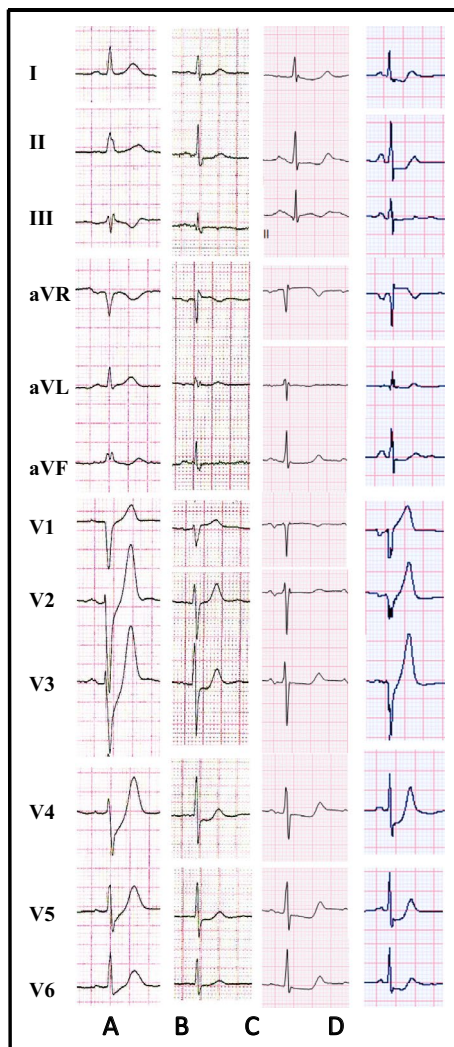


FIGURE 2 Examples of different morphology of ST depression. Panel (a) shows upsloping ST depression in leads V2–V6. Panel (b) shows horizontal ST depression in leads V3–V6. Panel (c) shows downsloping ST depression in leads V3–V6. Panel (d) shows a change from upsloping to nonupsloping ST depression from lead V3 to lead V6

patients with LM or likely LM disease with de Winter pattern in leads considered as expressing ischemia of the anterolateral or inferolateral wall perfused by the LM. However, there were also other characteristics of STEMI, such as STE in the lateral or inferior limb leads, or non-ST-elevation MI with STE in aVR higher than in V1. Therefore, ECG findings, such as STE, Q wave, and QRS width, and the location of the de Winter pattern in different ECG leads should be used together to predict the culprit artery and to assess the extent of myocardial ischemia.

The difference regarding the maximal magnitude of positive tall T wave between the two groups was not statistically significant. In the majority of patients, the highest T wave was located to V2 or V3, which probably reflects both ischemia and the baseline magnitude of the T wave. Morris et al. (Morris & Body, 2017) in a systemic review found that all ECGs with the de Winter pattern showed both maximal STD and peaked T-wave location in V3. Their study included a review of 24 ECGs up to October 2016.

4.2 | Upsloping STD signifying more severe ischemia than nonupsloping STD

In 43 of the 60 patients with a LAD-related culprit lesion, the type of ST-segment deviation was similar in the lead with maximal STD (core of ischemia lead) and in the neighboring leads. In the other 17 patients, differences were observed. The most frequent pattern was upsloping STD in the lead with maximal STD and nonupsloping STD in the neighboring leads. The differences could be due to varying severity and extent of myocardial ischemia, anatomical differences, or myocardial protection. Thus, upsloping was seen more frequently in the leads with maximal STD.

The presence of pathological q/Q-wave or poor R-wave progression was significantly more often found in patients with upsloping STD than in patients with nonupsloping STD. Two patients with LAD occlusion showed downsloping STD in leads V2/V3-V6. One evolved to upsloping STD for 10 min and then to the Wellens' sign with normal R-wave progression. The other patient showed total LAD occlusion with well-developed (Rentrop 3) collaterals. The de Winter pattern with upsloping STD in the inferior leads and downsloping STD in V2-V6 was found in a patient, who had an obtuse marginal branch occlusion. Small Q waves developed in the inferior leads with normal R-wave progression in leads V2-V6. These presentations seem to suggest that downsloping STD associates with less ischemia and less necrosis, although the small number of patients needs to be taken into account. In a small retrospective analysis of patients with non-ST-elevation MI, patients with upsloping STD had higher peak troponin, lower left ventricular ejection fraction, higher angiographic thrombus rate, higher rate of in-hospital revascularization, and all-cause death than patients with nonupsloping STD (Misumida et al., 2015). These facts suggest that upsloping STD signifies more severe ischemia than horizontal or downsloping STD. Based on our findings, we consider upsloping STD > 1mm at the J point followed by tall, prominent, symmetrical T waves together with an absence of

STE in leads V2-V6 as the main criteria of the de Winter pattern. This type should probably indeed be treated as STEMI equivalent, with prompt recognition and early intervention^[(Raja et al., 2019)].

4.3 | Possible background mechanism for the de Winter pattern

The theoretical explanation for LAD occlusion without STE includes an anatomical variant of the Purkinje fibers with endocardial conduction delay or lack of activation of sarcolemmal adenosine triphosphate-sensitive potassium channels by ischemic ATP depletion (Verouden et al., 2009). However, regional subendocardial ischemia with myocardial protection through collateral circulation or ischemic preconditioning or existing forward flow most probably is the pathophysiologic background of the de Winter pattern (Gorgels, 2009; Nikus, Pahlm, & Wagner, 2010). The evidence from this review also supports regional subendocardial ischemia as the background mechanism for the de Winter pattern. The upsloping STD as well as the tall, peaked T waves is physiologically attributed to a—hypoxia-driven—alteration in ATP-dependent potassium channels, resulting in a delay in repolarization in the subendocardial region, with a change in the transmembrane action potential shape (Fiol Sala et al., 2015).

Some case reports with serial ECG recordings enabled us to observe the transformation of the ST-T patterns before and after reperfusion therapy. There were 16 patients with a change in the ST-T pattern before reperfusion: 13 presenting mutual transformation between anterior STEMI and de Winter pattern, two presenting between hyperacute tall T wave and the de Winter pattern, and one patient presenting with the de Winter pattern, which evolved to the Wellens' sign. Thus, the de Winter pattern, STEMI, hyperacute T waves, and even the Wellens' sign can change from one pattern to another. Different ST-T patterns probably signify different severities of ischemia: STEMI resulting from transmural ischemia, "hyperacute" tall T waves signifying myocardial ischemia less involvement of the epicardium, the de Winter pattern representing regional subendocardial ischemia, and the Wellens' sign representing a postischemic stage probably reflecting edema-induced transient inhomogeneity of repolarization between apical and basal left ventricular regions (Migliore, Zorzi, & Marra, 2011). There were two patients presenting as STEMI, where the ECG pattern evolved to the de Winter pattern after thrombolysis. This change could be explained by effective thrombolytic therapy, thus decreasing the severity of ischemia. The fact that collateral circulation was found in some patients and 28% of the patients with LAD disease with TIMI 2–3 flow on angiography also suggests subendocardial ischemia as the essence of the de Winter pattern. As stated before, the de Winter sign of the upsloping type probably represents severe regional subendocardial ischemia. Thus, the probability of pathological q/Q waves or poor R-wave progression is higher in these cases than in those without the changes. The development of Q waves in the precordial leads after successful PCI is not infrequent in patients with the de Winter pattern (Zorzi

et al., 2012). Based on these facts, patients with the de Winter sign should be treated as STEMI equivalent to improve the prognosis. In general, the development of Q waves in acute MI is determined by the total size rather than the transmural extent of the underlying MI (Moon, Perez De Arenaza, & Elkington, 2004).

Nine patients presented the de Winter pattern evolving to STEMI after PCI. All the patients had total occlusion of the LAD. Microcirculatory dysfunction resulting from microcirculatory embolism (Ramaraj & Movahed, 2008) and rapidly developing myocardial necrosis (Montisci, Ruscazio, & Tona, 2019) may attribute to the transformation. We speculate that microcirculatory dysfunction after the intervention could result in occlusion of pre-existing collateral circulation to the distal LAD. Preservation of microvascular function after acute MI is not only related to the extent of transmural myocardial necrosis but also is an essential factor influencing regional left ventricular recovery (Montisci et al., 2019).

Of note, upsloping STD is not a specific marker of ischemia as it is often associated with increased heart rate (Desai, Crugnale, Mondeau, Helin, & Mannting, 2002; Polizos & Ellestad, 2006) and can even be found in myocarditis (García-Izquierdo et al., 2018) and post-supraventricular tachycardia (Khalid & Birnbaum, 2016). Upsloping STD in patients with chest pain without tachycardia, with concomitant tall symmetrical T waves and even pathological Q wave or equivalent is the typical feature for patients with ongoing ischemia, while upsloping STD with tachycardia in asymptomatic or atypical cases is the characteristic for patients, where the background factor is other than ischemia (Alam, Nikus, Fiol, Bayes de Luna, & Birnbaum, 2019; Khalid & Birnbaum, 2016).

5 | LIMITATIONS

The baseline characteristics of the patients, the biochemical (such as the value of troponin and brain natriuretic peptide) results, and echocardiographic and prognostic data were not reported in most of the cases. Thus, we could not compare the biochemical and echocardiographic data and prognosis between the different culprit arteries and various morphological STD. We also could not use uni- or multivariate logistic regression analysis to identify the prognostic significance of different morphological STD. A prospective study is needed to investigate the clinical and prognostic significance of different morphological STD. The majority of the patients were reviewed from case reports, which could pose selection bias in this patient cohort.

CONFLICT OF INTEREST

All authors have reported that they have no relationships relevant to the contents of this article to disclose.

ORCID

Zhong-Qun Zhan  <https://orcid.org/0000-0002-0982-5194>
 Yochai Birnbaum  <https://orcid.org/0000-0001-7653-6328>
 Adrian Baranchuk  <https://orcid.org/0000-0002-3042-6569>

REFERENCES

- Ahmadi, M., KhamenehBagheri, R., Vojdanparast, M., & Jafarzadeh-Esfehani, R. (2019). Wolff-Parkinson-White syndrome and de Winter patterns; An implication for paying special attention to electrocardiogram. *ARYA Atheroscler*, 15(4), 201–204.
- Alam, M., Nikus, K., Fiol, M., Bayes de Luna, A., & Birnbaum, Y. (2019). Upsloping ST depression: Is it acute ischemia? *Annals of Noninvasive Electrocardiology*, 24(3), e12607
- Baranchuk, A., & Bayés-Genis, A. (2016). Naming and classifying old and new ECG phenomena. *Canadian Medical Association Journal*, 188(7), 485–486. <https://doi.org/10.1503/cmaj.151209>
- Canakci, M. E., Turgay Yildirim, Ö., Acar, N., & Mert, K. U. (2019). Evaluation of acute anterior myocardial infarction cases with de-Winter T waves by coronary angiography images. *Turkish Journal of Emergency Medicine*, 19(2), 83–86. <https://doi.org/10.1016/j.tjem.2018.10.003>
- Carr, M. J., O'Shea, J. T., & Hinfey, P. B. (2016). Identification of the STEMI-equivalent de Winter electrocardiogram pattern after ventricular fibrillation cardiac arrest: A case report. *Journal of Emergency Medicine*, 50(6), 875–880.
- Carrington, M., Santos, A. R., Picarra, B. C., & Pais, J. A. (2018). De Winter pattern: a forgotten pattern of acute LAD artery occlusion. *BMJ Case Reports*, bcr-2018-226413. <https://doi.org/10.1136/bcr-2018-226413>
- Chen, S., Wang, H., & Huang, L. (2020). The presence of De Winter electrocardiogram pattern following elective percutaneous coronary intervention in a patient without coronary artery occlusion: A case report. *Medicine (Baltimore)*, 99(5), e18656.
- de Winter, R. W., Adams, R., Amoroso, G., Appelman, Y., ten Brinke, L., Huybrechts, B., ... de Winter, R. J. (2019). Prevalence of junctional ST-depression with tall symmetrical T-waves in a pre-hospital field triage system for STEMI patients. *Journal of Electrocardiology*, 52, 1–5.
- de Winter, R. W., Adams, R., Verouden, N. J., & de Winter, R. J. (2016). Precordial junctional ST-segment depression with tall symmetric T-waves signifying proximal LAD occlusion, case reports of STEMI equivalence. *Journal of Electrocardiology*, 49(1), 76–80.
- de Winter, R. J., Verouden, N. J., Wellens, H. J., & Wilde, A. A. (2008). A new ECG sign of proximal LAD occlusion. *New England Journal of Medicine*, 359(19), 2071–2073.
- Desai, M. Y., Crugnale, S., Mondeau, J., Helin, K., & Mannting, F. (2002). Slow upsloping ST-segment depression during exercise: does it really signify a positive stress test? *American Heart Journal*, 143(3), 482–487.
- Fiol Sala, M., Bayés de Luna, A., Carrillo López, A., & García-Niebla, J. (2015). The "De Winter Pattern" can progress to ST-segment elevation acute coronary syndrome. *Revista Española de Cardiología*, 68(11), 1042–1043.
- García-Izquierdo, E., Parra-Esteban, C., Mirelis, J. G., & Fernández-Lozano, I. (2018). The de Winter ECG pattern in the absence of acute coronary artery occlusion. *Canadian Journal of Cardiology*, 34(2), 209.e1–e3.
- Giovanni, B., & Francesco, C. (2020). de Winter's Pattern: An unusual but very important electrocardiographic sign to recognize. *CJC Open*, 2(1), 22–25.
- Goktas, M. U., Sogut, O., Yigit, M., & Kaplan, O. (2017). A novel electrocardiographic sign of an ST-segment elevation myocardial infarction-equivalent: De Winter syndrome. *Cardiology Research*, 8(4), 165–168.
- Gorgels, A. P. (2009). Explanation for the electrocardiogram in subendocardial ischemia of the anterior wall of the left ventricle. *Journal of Electrocardiology*, 42(3), 248–249.
- Grandjean, T., Degrauwe, S., Tessitore, E., & Iglesias, J. F. (2019). The 'de Winter' electrocardiogram pattern as a ST-elevation myocardial infarction equivalent: a case report. *European Heart Journal - Case Reports*, 3(4), 1–5.

- Hanna, E. B., & Glancy, D. L. (2016). The de Winter electrocardiographic pattern of proximal left anterior descending coronary artery occlusion. *American Journal of Cardiology*, 118(7), 1095–1096.
- He, D., Liu, Z., Wang, X., Jiang, Y. M., Zhang, Y., Li, J. P., & Huo, Y. (2020). De Winter syndrome & dynamic ECG evolution [published online ahead of print]. *QJM*, 113(4), 280–282.
- Hennings, J. R., & Fesmire, F. M. (2012). A new electrocardiographic criteria for emergent reperfusion therapy. *American Journal of Emergency Medicine*, 30(6), 994–1000.
- Karna, S., Chourasiya, M., Chaudhari, T., Bakrenia, S., & Patel, U. (2019). De Winter sign in inferior leads: A rare presentation. *Heart Views*, 20(1), 25–27.
- Khalid, U., & Birnbaum, Y. (2016). Clinical significance of upsloping ST depression on resting electrocardiogram. *Annals of Noninvasive Electrocardiology*, 21(2), 202–205.
- Lam, R. P. K., Cheung, A. C. K., Wai, A. K. C., Wong, R. T. M., & Tse, T. S. (2019). The de Winter ECG pattern occurred after ST-segment elevation in a patient with chest pain. *Internal and Emergency Medicine*, 14(5), 807–809.
- Li, X. Y., Li, X., Man, Q. S., Li, Y., & Long, Y. (2019). An electrocardiogram case of De Winter's T-waves evolving into Wellens' waves. *Zhonghua Xin Xue Guan Bing Za Zhi*, 47(11), 918–920.
- Lin, Y. Y., Wen, Y. D., Wu, G. L., & Xu, X. D. (2019). De Winter syndrome and ST-segment elevation myocardial infarction can evolve into one another: Report of two cases. *World J Clin Cases*, 7(20), 3296–3302.
- Mahajan, K., Batra, A., & Gupta, A. (2018). de Winter sign—A STEMI equivalent. *Indian Heart Journal*, 70(5), 761–764.
- Martínez-Losas, P., & Fernández-Jiménez, R. (2016). de Winter syndrome. *Canadian Medical Association Journal*, 188(7), 528.
- Massobrio, L., Scarrone, A., & Valbusa, A. (2016). ECG pattern of STEMI equivalent without coronary occlusion. *Journal of Electrocardiology*, 49(2), 248–249.
- Migliore, F., Zorzi, A., Marra, M. P., Basso, C., Corbetti, F., De Lazzari, M., ... Iliceto, S. (2011). Myocardial edema underlies dynamic T-wave inversion (Wellens' ECG pattern) in patients with reversible left ventricular dysfunction. *Heart Rhythm: the Official Journal of the Heart Rhythm Society*, 8(10), 1629–1634.
- Misumida, N., Kobayashi, A., Schweitzer, P., & Kanei, Y. (2015). Prevalence and clinical significance of up-sloping ST-segment depression in patients with non-ST-segment elevation myocardial infarction. *Cardiology Research*, 6(4–5), 306–310.
- Montero Cabezas, J. M., Karalis, I., & Schalij, M. J. (2016). De Winter electrocardiographic pattern related with a non-left anterior descending coronary artery occlusion. *Annals of Noninvasive Electrocardiology*, 21(5), 526–528.
- Montero-Cabezas, J. M., van-der Kley, F., Karalis, I., & Schalij, M. J. (2015). Proximal left anterior descending artery acute occlusion with an unusual electrocardiographic pattern: Not everything is ST elevation. *Revista Española de Cardiología*, 68(6), 541–543.
- Montisci, R., Ruscazio, M., Tona, F., Corbetti, F., Sarais, C., Marchetti, M. F., ... Meloni, L. (2019). Coronary flow reserve is related to the extension and transmural of myocardial necrosis and predicts functional recovery after acute myocardial infarction. *Echocardiography*, 36(5), 844–853.
- Moon, J. C. C., Perez De Arenaza, D., Elkington, A. G., Taneja, A. K., John, A. S., Wang, D., ... Pennell, D. J. (2004). The pathologic basis of Q-wave and non-Q-wave myocardial infarction: a cardiovascular magnetic resonance study. *Journal of the American College of Cardiology*, 44(3), 554–560.
- Morris, N. P., & Body, R. (2017). The De Winter ECG pattern: morphology and accuracy for diagnosing acute coronary occlusion: systematic review. *European Journal of Emergency Medicine*, 24(4), 236–242.
- Niimi, N., Ooka, R., Shiraishi, Y., & Fukuda, K. (2019). de Winter ST-T complex [published online ahead of print]. *QJM: An International Journal of Medicine*, hcz295.
- Nikus, K., Pahlm, O., Wagner, G., Birnbaum, Y., Cinca, J., Clemmensen, P., ... de Luna, A. B. (2010). Electrocardiographic classification of acute coronary syndromes: a review by a committee of the International Society for Holter and Non-Invasive Electrocardiology. *Journal of Electrocardiology*, 43(2), 91–103.
- Patel, N., Baker, S. M., Paterick, T. E., & Tajik, A. J. (2017). The de Winter variation: Anterior ST-elevation myocardial infarction. *American Journal of Medicine*, 130(3), 288–289.
- Pica, S., Ballestrero, G., Pistis, G., & Crimi, G. (2016). Acute stent thrombosis unveils two electrocardiogram patterns in a patient with 'De Winter T-waves' anterior myocardial infarction. *European Heart Journal*, 37(35), 2735.
- Polizzo, G., & Ellestad, M. H. (2006). The value of upsloping ST depression in diagnosing myocardial ischemia. *Annals of Noninvasive Electrocardiology*, 11, 237–240.
- Pranata, R., Huang, I., & Damay, V. (2018). Should de Winter T-wave electrocardiography pattern be treated as ST-segment elevation myocardial infarction equivalent with consequent reperfusion? A dilemmatic experience in rural area of Indonesia. *Case Reports in Cardiology*, 2018, 6868204.
- Pruitt, R. D., Klakeg, C. H., & Chapin, L. E. (1955). Certain clinical states and pathologic changes associated with deeply inverted T waves in the precordial electrocardiogram. *Circulation*, 11(4), 517–530.
- Qayyum, H., Hemaya, S., Squires, J., & Adam, Z. (2018). Recognising the de Winter ECG pattern – A time critical electrocardiographic diagnosis in the Emergency Department. *Journal of Electrocardiology*, 51(3), 392–395.
- Qu, B., Tao, G., & Liu, R. (2019). An emergency ECG sign of ST elevation myocardial infarction. *BMC Cardiovascular Disorders*, 19(1), 130.
- Raja, J. M., Nanda, A., Pour-Ghaz, I., & Khouzam, R. N. (2019). Is early invasive management as ST elevation myocardial infarction warranted in de Winter's sign—a "peak" into the widow-maker. *Annals of Translational Medicine*, 7(17), 412.
- Ramaraj, R., & Movahed, M. R. (2008). Microvascular dysfunction following primary percutaneous coronary intervention in the setting of ST-elevation myocardial infarction. *Journal of Invasive Cardiology*, 20(11), 603–614.
- Rao, M. Y., Wang, Y. L., Zhang, G. R., Zhang, Y., Liu, T., Guo, A. J., ... Wang, M. (2018). Thrombolytic therapy to the patients with de Winter electrocardiographic pattern, is it right? *QJM: An International Journal of Medicine*, 111(2), 125–127.
- Rodrigues, R. C., Gomes, S., Drumond, A., & Pereira, D. (2016). De Winters modified electrocardiogram pattern. *Neth Heart J*, 24(5), 364–365.
- Samadov, F., Akaslan, D., Cincin, A., Tigen, K., & Sari, I. (2014). Acute proximal left anterior descending artery occlusion with de Winter sign. *American Journal of Emergency Medicine*, 32(1), 110.e1–110.e1103.
- Sciarovsky, S., Rechavia, E., Strasberg, B., Sagie, A., Bassevich, R., Kusniec, J., ... Agmon, J. (1988). Unstable angina: ST segment depression with positive versus negative T wave deflections—clinical course, ECG evolution, and angiographic correlation. *American Heart Journal*, 116(4), 933–941.
- Sunbul, M., Erdogan, O., Yesildag, O., & Mutlu, B. (2015). De Winter sign in a patient with left main coronary artery occlusion. *Advances in Interventional Cardiology*, 11(3), 239–240.
- Thabouillot, O., Bouvier, F., & Roche, N.-C. (2017). De Winter's wave. *Emergency Medicine Journal*, 34, 851.
- Tsutsumi, K., & Tsukahara, K. (2018). Is the diagnosis ST-segment elevation or non-ST-segment elevation myocardial infarction? *Circulation*, 138(23), 2715–2717.
- Tzimas, G., Antiochos, P., Monney, P., Eeckhout, E., Meier, D., Fournier, S., ... Schläpfer, J. (2019). Atypical electrocardiographic presentations in need of primary percutaneous coronary intervention. *American Journal of Cardiology*, 124(8), 1305–1314.

- Verouden, N. J., Koch, K. T., Peters, R. J., Henriques, J. P., Baan, J., van der Schaaf, R. J., ... de Winter, R. J. (2009). Persistent precordial "hyperacute" T-waves signify proximal left anterior descending artery occlusion. *Heart*, *95*(20), 1701–1706.
- Viejo-Moreno, R., Rubio-Muñoz, J., Cabrejas-Aparicio, A., & Novo-García, E. (2018). Something more than simple non-ST segment elevation acute coronary syndrome: the De Winter pattern. Algo más que un simple SCASEST: patrón de De Winter. *Emergencias*, *30*(6), 439–440.
- Viejo-Moreno, R., Rubio-Muñoz, J., Cabrejas-Aparicio, A., & Novo-García, E. (2018). Something more than simple non-ST segment elevation acute coronary syndrome: The De Winter pattern. *Emergencias*, *30*(6), 439–440.
- Xu, J., Wang, A., Liu, L., & Chen, Z. (2018). The de winter electrocardiogram pattern is a transient electrocardiographic phenomenon that presents at the early stage of ST-segment elevation myocardial infarction. *Clinical Cardiology*, *41*(9), 1177–1184.
- Xu, M. M., Jiang, L., & Feng, N. N. (2018). De Winter syndrome: A case report. *Zhonghua Xin Xue Guan Bing Za Zhi*, *46*(3), 230–231.
- Xu, W. W., Lu, L., & Jin, M. J. (2019). De Winter electrocardiogram pattern—An unusual ST-segment elevation myocardial infarction equivalent pattern [published online ahead of print]. *JAMA Internal Medicine*, *179*(11), 1575.
- Xu, W., Xu, L., Peng, J., & Huang, S. (2019). Thrombolytic therapy in a patient with chest pain with de Winter ECG pattern occurred after ST-segment elevation: A case report. *Journal of Electrocardiology*, *56*, 4–6.
- Xu, W., Zou, H., & Huang, S. (2019). Junctional ST-depression and tall symmetrical T-waves with an obtuse marginal artery occlusion: A case report. *Journal of Electrocardiology*, *54*, 40–42.
- Yang, W., Liu, H., Zhu, M., & Song, Z. (2017). The de Winter electrocardiographic pattern of proximal left anterior descending occlusion. *American Journal of Emergency Medicine*, *35*(6), 937.e1–e3.
- Yang, Y., Ma, Y., Yin, D. A., Zhang, Y., Song, W., Cheng, Y., ... Lu, Y. (2019). Atypical and delayed de Winter electrocardiograph pattern: A case report. *Medicine (Baltimore)*, *98*(18), e15436.
- Zhan, Z. Q., Nikus, K., & Birnbaum, Y. (2020). Different ECG patterns of left main coronary artery occlusion signifying varying degrees of ischemic severity. *Journal of Electrocardiology*, *60*, 12–14.
- Zhang, L., Fan, Y., Xu, J., Yan, J., Ruan, Q., & Jiang, X. (2019). De Winter syndrome may be an early electrocardiogram pattern of acute myocardial infarction, two cases report [published online ahead of print]. *Annals of Noninvasive Electrocardiology*, e12729.
- Zhao, Y. T., Wang, L., & Yi, Z. (2016). Evolvement to the de Winter electrocardiographic pattern. *American Journal of Emergency Medicine*, *34*(2), 330–332.
- Zorzi, A., Perazzolo Marra, M., Migliore, F., Tarantini, G., Iliceto, S., & Corrado, D. (2012). Interpretation of acute myocardial infarction with persistent 'hyperacute T waves' by cardiac magnetic resonance. *European Heart Journal: Acute Cardiovascular Care*, *1*(4), 344–348.

How to cite this article: Zhan Z-Q, Li Y, Han L-H, Nikus KC, Birnbaum Y, Baranchuk A. The de Winter ECG pattern: Distribution and morphology of ST depression. *Ann Noninvasive Electrocardiol.* 2020;25:e12783. <https://doi.org/10.1111/anec.12783>