Tampere University

RAMI TAULU

A Comparison of Drug-Eluting Stent and Intranasal Corticosteroid Spray in the Treatment of Chronic Rhinosinusitis

Tampere University Dissertations 331

Tampere University Dissertations 331

RAMI TAULU

A Comparison of Drug-Eluting Stent and Intranasal Corticosteroid Spray in the Treatment of Chronic Rhinosinusitis

ACADEMIC DISSERTATION
To be presented, with the permission of
the Faculty of Medicine and Health Technology
of Tampere University,
for public discussion in the auditorium F114
of the Arvo building Arvo Ylpön katu 34, Tampere,
on 27th of November 2020, at 12 o'clock

ACADEMIC DISSERTATION
Tampere University, Faculty of Medicine and Health Technology
Finland

Responsible supervisor and Custos	Professor Markus Rautiainen University of Tampere Finland	
Supervisor	Docent Jura Numminen University of Tampere Finland	
Pre-examiners	Docent Juha Seppä University of Eastern Finland Finland	Docent Karin Blomgren University of Helsinki Finland
Opponent	Professor Olli-Pekka Alho University of Oulu Finland	

The originality of this thesis has been checked using the Turnitin OriginalityCheck service.

Cover design: Roihu Inc.

ISBN 978-952-03-1744-7 (print)
ISBN 978-952-03-1745-4 (pdf)
ISSN 2489-9860 (print)
ISSN 2490-0028 (pdf)
http://urn.fi/URN:ISBN:978-952-03-1745-4

PunaMusta Oy – Yliopistopaino
Vantaa 2020

To my families

ACKNOWLEDGEMENTS

First, I am deeply grateful to my supervisor Professor Markus Rautiainen, MD, PhD for his support and guidance. Thank you for always believing in me and this dissertation project, even when my own faith faltered. I have really appreciated your positivity and the humane way you treat other people.

Second, I would also like to thank my other supervisor Docent Jura Numminen, MD, PhD. You have always found time for me and this project. Although I was forced to leave the fine art of rhinosurgery, I will always be grateful for all the mentoring and teaching you have given me. I am also honoured to call you my friend.

I am also indebted to the official pre-examiners of this thesis, Docent Juha Seppä, MD, PhD and Docent Karin Blomgren, MD, PhD for their valuable work and constructive criticism.

I would also like to express my sincere gratitude to my co-author Argyro Bizaki-Vallaskangas, MD, PhD for her invaluable contribution to this study.

I wish to express my thanks to research nurse Piitu Oksanen for "keeping all the threads" of our study tied tightly together. I have greatly appreciated your efficient work and commitment.

I would also like to thank Peter Heath, MA for the skilful revision of the language of this dissertation. I really enjoyed it when you explained the mysteries of the English language to me.

I am thankful to Mika Helminen, MSc for helping me navigate through the hard storms of statistics.

Every day, I feel privileged to be able to do the work I love. You, my colleagues and co-workers at the ENT-department of Tampere University Hospital are the main reason for this. Especially, I want to thank our Team of Head and Neck Surgery,

Elina Halme, MD, PhD, Lassi Raittinen MD, PhD, Henry Blomster MD, PhD and Saara Markkanen MD, PhD (soon). You are the best team a man can hope to be a member of.
Saara, when this dissertation is published, I will know that the defence of your dissertation has been a success. I want to apologise for how much I unashamedly took advantage of you when preparing for the defence of this dissertation. It was just way too easy to always ask: "Saara, what should I do next…".

From the bottom of my heart, I am thankful to the members of "The Nuclear Family", Tommi Koivu, MD, PhD, Docent Niko Sillanpää, MD, PhD, Olli "pHoo" Tähtinen MD, PhD. My Brothers in Arms in Azeroth, I cannot find the right words to express how much your friendship means to me, now and forever.
In particular, I want to thank you Niko, my friend and co-author. You are the friend that everyone (who does research) should have. I (and my dissertation) owe you a great debt for all your linguistic and scientific help.

I owe my deepest gratitude to my parents Tarja and Eino for giving me such a loving, caring and safe home and childhood. You have always loved and supported me unconditionally. My brothers, Jussi and Perttu, you are not so bad…

And finally, Kaisu, my dear, patient, understanding wife. I can thank you for almost everything, but I especially thank you for enduring me all these years. To my dear children, Oona and Aaro, I can honestly say that you two are the only real accomplishment in my life that really matters. In the words of Juha Tapio: "Siellä muistathan sen, isä on susta ylpeä ain".

This study was supported by the Finnish ORL-HNS Foundation and the Finnish Medical Foundation.

Ylöjärvi, October 2020
Rami Taulu

ABSTRACT

Topical corticosteroid therapy is the first-line treatment of chronic rhinosinusitis (CRS). The topical administration route of nasal sprays or drops often leads to suboptimal drug delivery inside the paranasal sinuses and correspondingly to suboptimal treatment results. The Relieva Stratus™ MicroFlow Spacer is a drug-eluting stent (DES) that is temporarily implanted into the ethmoid sinus to provide local and targeted delivery of the corticosteroid to the mucosa in order to relieve symptoms and avoid sinus surgery.

The aim of this prospective, randomised, clinical study was to compare the efficacy and safety of the DES and optimally dosed, regularly used topical intranasal corticosteroid (ICS) spray therapy in patients with CRS. Further, to evaluate whether image-guided navigation (IGS)-assisted DES insertion into the ethmoid sinus would prove to be more useful than fluoroscopic guidance. And finally, to evaluate whether a DES implanted in the ethmoid sinuses can prevent sinus surgery.

Sixty-three adult patients (44 women, 19 men) with ethmoidal involvement in cone beam computed tomography (CBCT) whose first-line medical treatment with topical ICSs had failed and who were candidates for endoscopic sinus surgery (ESS) were randomised into two groups with the following parameters: age, sex, asthma, nasal polyposis, and the use of tobacco. Patients in the DES group (n=34) received stents filled with 24 mg of triamcinolone acetonide (Kenalog40®) solution on both sides, whereas patients in the nasal spray group (n=29) used triamcinolone acetonide nasal spray (Nasacort® 55ug/dose) 2 doses/day on both sides for six months. The first 13 patients were implanted with DES by using fluoroscopy and the remaining patients underwent IGS-assisted DES insertion. The main outcome variable was the 22 item Sinonasal Outcome Test (SNOT-22). Visual analogue scale (VAS), direct nasal endoscopy, and rhinometric measurements were performed at the beginning of the study, and after three months and six months of follow-up. CBCT imaging of the paranasal sinuses was performed before the therapeutic interventions and at the end of the follow-up period. Patients were followed up prospectively for six months and at 36 months to find out whether they had undergone ESS. A total of 57 patients (DES n=28, nasal spray n=29) were available for analysis at both timepoints.

Both treatment modalities significantly improved quality of the life (QoL) as measured with SNOT-22 score with no significant difference being found between the two groups. The VAS score decreased in both groups – improvements were significant at three and six months in the nasal spray group, but a significant difference was noted only at three months in the DES group. There was a statistically significant increase in total nasal cavity volumes in the ICS spray group, but not in the DES group. No other differences in the mean total resistance in rhinomanometry, endoscopic score or Lund-Mackay staging system score was found between the groups.

ESS could be prevented in almost half of the patients in both groups at 6 months (DES 13/28, 46%, nasal spray 14/29, 48%). At 36 months, 20/28 (71%) of the patients in the DES group and 18/29 (62%) in the nasal spray group had been operated. There were no significant differences between the groups at either timepoint. Fourteen of the 19 (74%) smokers and 16 of the 38 (42%) non-smokers were operated at the 6-month timepoint ($p=0.024$).

There were no immediate or delayed complications or significant adverse effects. The IGS-assisted approach improved the accuracy of the insertion and made it possible to treat precisely the diseased cells identified in preoperative CT imaging.

We found the insertion of the DES easy and safe to perform. Due to radiation protection concerns, the complexity and variability of ethmoidal cavity anatomy and the vital anatomical structures surrounding the ethmoidal cells, we recommend the use of optical IGS in the insertion.

Patients benefitted from both DES and ICS spray and QoL improved in both groups. We could not find any significant difference between the treatments except the greater increase in the total nasal cavity volumes favouring the nasal spray group.

In the medium term (6 months), ESS can be prevented by both therapies in almost half of cases. This preventive effect was, however, somewhat diminished in the long term (36 months).

These results emphasise the importance of optimal dosing technique, motivation and regular, long-term administration of topical ICS therapy in the primary treatment of CRS.

Because of the good results for the nasal spray and the much higher material and operating room costs associated with the DES, we cannot recommend the use of the DES over nasal spray as a monotherapeutic treatment for CRS.

TIIVISTELMÄ

Paikallisesti nenään käytetty kortikosteroidisumute on pitkittyneen nenän sivuontelotulehduksen ensisijainen hoitomuoto. Tämän hoitomuodon suurin ongelma on, ettei nenäkäytävään sumutettu lääkeaine pääse suljettujen, sairaiden sivuonteloiden sisälle, jolloin hoidon teho jää osittaiseksi. Leikkaussaliolosuhteissa suoraan seulalokeroiden sisälle asetettava lääkeannostelija Relieva Stratus™ MicroFlow Spacer (Relieva Stratus) vapauttaa kortikosteroidia paikallisesti, jolloin sairastuneiden sivuonteloiden sisälle saadaan korkea lääkepitoisuus.
Tämän väitöskirjan tarkoituksena on selvittää Relieva Stratus-lääkeannostelijan tehoa ja turvallisuutta verrattuna samaa kortikosteroidia sisältävään nenäsumutteeseen pitkittynyttä sivuontelotulehdusta sairastavilla potilailla. Lisäksi halutaan arvioida, voidaanko lääkeannostelijaa käyttämällä vähentää laajempaa ja riskialttiimpaa sivuontelokirurgiaa, ja onko leikkausnavigaattoriavusteinen tekniikka läpivalaisutekniikkaa käyttökelpoisempi lääkeannostelijan asetuksessa.

Tutkimukseen valittiin 63 aikuista potilasta, joilla oli todettu kartiokeilatietokonetomografialla varmistettu pitkittynyt sivuontelotulehdus, ja joiden oli arvioitu hyötyvän sivuonteloleikkauksesta. Potilaat satunnaistettiin kahteen ryhmään sukupuolen, iän, astman, nenäpolypoosin ja tupakoinnin suhteen. Lääkeannostelijaryhmälle (34 henkilöä) asennettiin triamsinoloniasetonidia (Kenalog40® 40 mg/ml) vapauttava lääkeannostelija molemmille puolille seulalokeroihin. Nenäsumuteryhmä (29 henkilöä) käytti samaa kortikosteroidia sisältävää nenäsumutetta (Nasacort® 55ug/annos) kuuden kuukauden ajan. Läpivalaisutekniikalla lääkeannostelija asetettiin 13 ensimmäiselle potilaalle ja lopuille 21 potilaalle käyttäen leikkausnavigaattoria.

Päämuuttuja tutkimuksessa oli nenän ja nenän sivuonteloiden sairauksiin kehitetty tautikohtainen oire- ja elämänlaatumittari SNOT-22. Oireita arvioitiin myös Visual Analogue Scale (VAS) -mittarilla. Lisäksi potilaita tutkittiin sivuonteloiden kartiokeilatietokonetomografiatutkimuksella, nenän tähystyksellä sekä nenän virtaus- ja tilavuustutkimuksilla. Seurantakäynnit toteutettiin kolme ja kuusi kuukautta hoidon aloituksen jälkeen. Kolme vuotta tutkimuksen jälkeen kartoitettiin, oliko potilaille tehty tutkimuksen jälkeen sivuonteloleikkauksia. Tutkimuksen päättyessä

tutkimuksessa oli mukana yhteensä 57 potilasta (28 lääkeannostelijaryhmässä, 29 nenäsumuteryhmässä).

Molempien ryhmien potilaiden oireet vähenivät ja elämänlaatu parani SNOT-22-mittarilla mitattuna sekä kolmen että kuuden kuukauden kuluttua hoidon aloittamisesta. Ryhmien välillä ei todettu tilastollisesti merkitsevää eroa. Oireet vähenivät molemmissa ryhmissä myös VAS-mittarilla arvioituna. Nenäsumuteryhmässä havaittiin molemmilla seurantakäynneillä tilastollisesti merkitsevä nenäkäytävän kokonaistilavuuden kasvu. Vastaavaa kasvua ei havaittu lääkeannostelijaryhmässä ja tämä tulos oli ainoa, jossa löydettiin tilastollinen ero tutkimusryhmien välillä.

Lähes puolet molempien ryhmien potilaista ei enää tarvinnut sivuonteloleikkausta hoidon aloitusta seuranneen puolen vuoden seurantajakson jälkeen. Potilaan tupakointi lisäsi leikkaushoidon tarvetta; tupakoivista potilaista leikkaushoitoon päätyi 74% ja tupakoimattomista 42%. Hoidon teho vaikutti säilyvän, sillä kolmasosalle tutkimukseen osallistuneista potilaista ei tehty sivuonteloleikkausta kolmen vuoden tutkimuksen aikana. Tutkimusryhmien välillä ei todettu tilastollisesti merkitsevää eroa leikkaukseen hakeutumisessa.

Leikkausnavigaattoria käyttäen lääkeannostelija pystyttiin ohjaamaan tarkasti haluttuun sivuonteloon. Läpivalaisutekniikalla ei päästy yhtä tarkkaan lopputulokseen. Lisäksi läpivalaisutekniikka, toisin kuin leikkausnavigaattori, edellyttää potilaalle ja henkilökunnalle haitallisen röntgensäteilyn käyttöä. Näin ollen leikkausnavigaattoriavusteista tekniikkaa voitiin pitää kokonaisuudessaan käyttökelpoisempana ja turvallisempana menetelmänä. Uuden lääkeannostelijan käyttö oli helppoa ja turvallista. Merkittäviä haittavaikutuksia ei havaittu asetuksen yhteydessä tai myöhemmin seurannan aikana.

Potilaiden oireet vähenivät ja elämänlaatu koheni sekä lääkeannostelija- että nenäsumuteryhmässä. Koska varsin kalliin lääkeannostelijan asettaminen seulalokeroihin vaatii leikkaussaliolosuhteet, läpivalaisun tai leikkausnavigaattorin käytön, ja sisältää mahdollisuuden haittavaikutuksiin, ei lääkeannostelijan käyttöä voida suositella pitkittyneen sivuontelotulehduksen ainoana hoitomuotona. Vastaavaan hoitotulokseen voidaan päästä turvallisemmalla ja varsin edullisella kortikosteroidinenäsumutteen käytöllä. Kiinnittämällä huomiota nenäsumutteen lääkkeenottotekniikan opetukseen, ja kannustamalla potilasta lääkkeen säännölliseen käyttöön, voidaan parantaa pitkittyneen sivuontelotulehduksen hoitotuloksia, sekä parhaassa tapauksessa leikkaushoidon tarve häviää lähes joka toiselta potilaalta.

CONTENTS

ABBREVIATIONS

AERD	aspirin-exacerbated respiratory disease
BSP	balloon sinuplasty
CBCT	cone beam computed tomography
CRS	chronic rhinosinusitis
CRSsNP	chronic rhinosinusitis without nasal polyps
CRSwNP	chronic rhinosinusitis with nasal polyps
CT	computed tomography
DES	drug-eluting stent
EPOS	European Position Paper on Rhinosinusitis and Nasal Polyps
ESS	endoscopic sinus surgery
FDA	The US Food and Drug Administration
ICS	intranasal corticosteroid
Ig	immunoglobulin
IGS	image-guided surgery
IL	interleukin
LM-score	Lund-Mackay score
MCC	mucociliary clearance
MRI	magnetic resonance imaging
NP	nasal polyp
NSAID	non-steroidal anti-inflammatory drug
OR	odds ratio
QoL	quality of life
RCT	randomised, clinical trial
Relieva Stratus	Relieva Stratus™ Microflow Spacer
SNOT-20	20 item sinonasal outcome test
SNOT-22	22 item sinonasal outcome test
Th	T helper cell
USD	Unites States dollars
VAS	visual analogue scale

LIST OF ORIGINAL COMMUNICATIONS

I Taulu R, Numminen J, Bizaki A, Rautiainen M. 2015. Image-guided, navigation-assisted Relieva Stratus MicroFlow Spacer insertion into the ethmoid sinus. Eur Arch Otorhinolaryngology. 272(9):2335-40.

II Taulu R, Numminen J, Bizaki A, Rautiainen M. 2017. A prospective, randomized clinical study comparing drug eluting stent therapy and intranasal corticoid steroid therapy in the treatment of patients with chronic rhinosinusitis. Rhinology. 55(3):218–226.

III Taulu R, Sillanpää N, Numminen J, Rautiainen M. 2020. Ethmoidal drug-eluting stent therapy is not superior to nasal corticosteroid spray in the prevention of endoscopic sinus surgery: results from a randomised, clinical trial. Clinical Otolaryngology. 45(3):402-408

The publications are referred to in the text by their roman numerals.

.

1 INTRODUCTION

Chronic rhinosinusitis (CRS) is a common health problem which places a significant economic burden on society and health care systems and adversely impacts quality of life (QoL). The estimated prevalence of CRS in Western populations varies a lot, ranging from 2% to 12% (Xu et al. 2016, Blackwell et al. 2014), depending on the diagnostic criteria and study designs used. The estimated annual direct cost of the management of adult CRS to the health care system of the United States of America in 2011 was as high as 12.5 billion United States dollars (USD) (Caulley et al. 2015). A rough estimation of the overall indirect cost in 2014 was $13 billion USD (Rudmik et al. 2014a). In Finland, there are no data on the yearly medical costs caused by CRS or the exact prevalence of CRS within the Finnish population. It is known, however, that CRS has a major impact on QoL and is comparable to other common chronic diseases, such as ischemic heart disease, congestive heart failure and back pain (Gliklich and Metson 1995).

CRS is a general term that describes a group of disorders characterised by chronic inflammation of the mucosa of the nose and the paranasal sinuses with symptoms that have persisted for more than 12 weeks (Fokkens et al. 2020). The aims of the treatment of CRS include reduction of mucosal oedema and inflammation, the re-establishment of sinus ventilation and the eradication of infecting pathogens. Intranasal corticosteroid (ICS) therapy is the first-line treatment of CRS. Moreover, there is robust evidence on the efficacy of topically administered glucocorticoid therapy in the treatment of CRS with (CRSwNP) or without (CRSsNP) nasal polyps (NP) (Snidvongs et al. 2011, Kalish et al. 2012, Lund et al. 2004). The topical administration route is safe and only minor side effects, such as mucosal irritation, crusting and minor nose bleeds, have been reported (Snidvongs et al. 2011). Several large prospective studies have shown that endoscopic sinus surgery (ESS) is an effective and safe method of treatment for patients with CRS when drug therapy has failed (Noon and Hopkins 2016, Georgalas et al. 2014). One of the advantages of ESS is that the delivery of the topical glucocorticoids to the paranasal sinuses is easier postoperatively (Harvey et al. 2008, Grobler et al. 2008).

The complexity of the sinus anatomy and the mucosal oedema of CRS patients cause major problems in the delivery of the drug to the affected paranasal sinus mucosa, and thus worsen treatment outcomes (Snidvongs et al. 2008). Although ESS has proved to be a quite safe method for treating patients with CRS, there are known to be some minor adverse effects that include bleeding, infection and synechia formation. In addition, rare major complications, such as orbital emphysema or damage to extraocular muscles, blindness, vascular damage, cerebrospinal fluid leak, intracranial injury or death, have been reported (McMains 2008). Thus, the study of more conservative and less invasive ways to treat CRS is warranted.

The Relieva Stratus™ Micro-flow Spacer (Relieva Stratus; Acclarent Inc. California, USA) is a drug-eluting stent (DES) that is inserted directly into the affected paranasal sinuses to achieve local, controlled release of a known dose of corticosteroid drug in order to avoid surgery and to preserve normal ethmoid sinus anatomy.

This dissertation describes a safer and more accurate technique for inserting the DES precisely into the involved ethmoidal sinuses with the aid of image-guided navigation. Above all, this dissertation describes the first prospective, randomised clinical trial (RCT) comparing the efficacy of a DES therapy (The Relieva Stratus) and the regularly used and optimally dosed topical ICS therapy in the treatment of patients with CRS and evaluates the safety of the DES. In addition, this dissertation evaluates whether the DES could better prevent ESS compared to standard non-invasive therapy using nasal spray in patients suffering from CRS.

2 REVIEW OF THE LITERATURE

2.1 Anatomy and physiology of the paranasal sinuses and nasal cavities

The paranasal sinuses are paired air-containing cavities that are located in the maxillary, ethmoidal, sphenoidal and frontal bones. The paranasal sinuses are connected to the nasal cavity to form a complex anatomical system at the entrance of the upper airway. Healthy, normal sinuses are air-filled cavities lined with a thin layer of mucosa, which is mostly lined by simple ciliated columnar type cells with a few goblet cells and glands (Watelet and Van Cauwenberge 1999). The nasal cavities and sinuses vary between children and adults in both size and proportion (Wolf, Anderhuber et al. 1993). The maxillary sinuses are the largest of the sinuses; the total volume can reach 15 ml, and they are located in the body of the maxilla (Watelet 1999). The form and size of the frontal sinuses vary a lot. In 3% to 5% of individuals, the frontal sinus is completely absent in one or both sides. (Watelet 1999). The sphenoid sinus is surrounded by many important structures, such as the internal carotid artery, the optic nerves, the cavernous sinus and the sella turcica. There are approximately 8 to 15 air-filled ethmoidal cells divided into anterior and posterior cells by a structure called the basal lamella (Watelet 1999). The anterior ethmoidal cells drain into the middle meatus and the posterior cells into the superior meatus. The ethmoidal cells are in the anterior portion of the skull base. The roof of the ethmoidal cells, called the lateral lamella of the cribriform plate, is an extremely thin bone. It is the thinnest part of the skull base, and therefore at risk of iatrogenic injury during ESS. Ethmoidal cells are laterally separated from the orbit by the lamina papyracea, which is, as its name implies, a paper-thin sheet of bone (Jones 2001). The nasal cavity opens anteriorly in the nostrils and connects posteriorly to the nasopharynx. The lateral nasal wall consists of the inferior, middle and superior turbinates. In some cases, a fourth turbinate called the supreme turbinate may also exist. The middle meatus plays a major role in the pathophysiology of CRS. It contains the openings of the maxillary, frontal and the anterior parts of the ethmoid sinuses. An active mucociliary clearance (MCC) mechanism carries sinus secretions through the ostia into the nasal cavity. This final common pathway of the anterior

ethmoid sinus-middle meatus region is called the ostiomeatal complex. Any process that causes ostial occlusion or ventilation defects of the ostiomeatal complex results in inflammation that can lead to secondary disease in the frontal or maxillary sinuses.

Theories of the function and importance of the paranasal sinuses are controversial. Moreover, none of theories have as yet been proven. The paranasal sinuses may, for example, have arisen as an aid to facial growth and architecture or they may persist as residual remnants of an evolutionary structure of yet unknown purpose. They may simply act to improve nasal function. It has been demonstrated that they may also act as an adjunct in the production of and as reservoirs for nitric oxide and facilitate the immune defences of the nasal cavity (Lundberg et al. 1995, Andersson et al. 2002). The sinuses might absorb trauma in order to protect the brain or make the skull lighter. Other hypotheses seem less valid. Thus, the paranasal sinuses probably do not contribute to efficient air conditioning by increasing the contact between the mucosa and inspired air, nor to speech resonance or olfaction. (Watelet 1999, Keir 2009)

2.2 Chronic rhinosinusitis

2.2.1 Definition

The term rhinosinusitis is preferred because rhinitis and sinusitis almost always co-exist. It is difficult to make a distinction between the pathophysiology of the nasal and sinus mucosa. Based on the European Position Paper on Rhinosinusitis and Nasal Polyps (EPOS) 2020 , CRS in adults is defined as an inflammatory disease of the nose and paranasal sinuses, persisting at least 12 weeks without complete resolution, and is characterised by the presence of at least two or more symptoms, one of which should be either nasal blockade/obstruction/congestion or nasal discharge (anterior/posterior nasal drip) and/or facial pain/pressure and/or reduction or loss of smell. However, symptoms alone have high sensitivity but too low specificity. Therefore, the symptoms should be complemented with objective findings that included either positive endoscopic signs NPs and/or mucopurulent discharge from the middle meatus and/or oedema/mucosal obstruction primarily in the middle meatus) and/or computed tomography (CT) changes (mucosal changes within the ostiomeatal complex and/or sinuses). (Fokkens et al. 2020)

2.2.2 Epidemiology

The prevalence of CRS is under debate. The problem is that the diagnostic criteria used in studies of CRS vary a great deal, and there is no single diagnostic test that provides an accurate diagnosis. Most studies are based on either population-based survey responses or administrative database coding, both of which have diagnostic limitations. Also, the heterogeneity in what is coded as CRS and the absence of common consensus on the definition of CRS makes it challenging to define an accurate prevalence rate. (Rudmik 2017)

The National Health Interview Survey (NHIS) for American adults in 2012 reported that 12% of adults had been told by a doctor or other health professional that they had rhinosinusitis, making it one of the most common chronic disease. The data were collected on 34 525 adults (Blackwell et al. 2014). In a large Canadian national health survey-based cross-sectional study with over 70 000 participants, the prevalence of self-reported CRS was 5%, and it was more common in women, older adults, smokers, lower-income families and individuals with chronic lower respiratory tract diseases. If respondents answered positively to the question: "Do you have sinusitis diagnosed by a health professional?", they were considered to have sinusitis. The limitation of that study and the previous one was that it failed to discriminate between acute rhinosinusitis and CRS. (Chen et al. 2003). Prior to the European international multicentre CRS (GA2LEN) study, the prevalence figures for Europe were practically unavailable. The definition of CRS was based on the EPOS 2007 diagnostic criteria. In the questionnaire, which was sent via post, questions were asked on symptoms of CRS, doctor diagnosed CRS, allergic rhinitis, age, gender and smoking history. Data were obtained from 57 128 responders who were living in 12 European countries. The overall prevalence of CRS was 10.9% and was more common in smokers. When patients reported CRS diagnosed by a physician, the prevalence of CRS was 5%. (Hastan et al. 2011). The prevalence and risk factors of CRS are quite different and depend on the criteria used. A study from South Korea compared the prevalence and risk factors of CRS using two different diagnostic criteria with the same statistical data. The prevalence of symptoms-based CRS was 10.8% (797 of 7 394) and that of endoscopy-based CRS was 1.2% (88/7 343) (Kim et al. 2016). A retrospective health care administrative database study that included 2 925 930 adults living in Alberta, Canada estimated that the prevalence of diagnosed CRS was between 2% and 3% (Xu et al. 2016). In an evaluation of the United States Medical Expenditure Panel Survey database, the prevalence rate of CRS was found to be around 4.9% (Bhattacharyya 2011).

It seems therefore that the prevalence of CRS diagnosed within health care systems utilizing more advanced diagnostic tools is between 1% and 3%. Yet, the prevalence among Western populations may be as high as 12%.

The estimation of the prevalence of NPs in the Nordic population is reported to be between 2% and 4% (Hedman et al. 1999, Johansson et al. 2003).

2.2.3 Pathogenesis

Historically, CRSsNP was considered to be the result of an incompletely treated or unresolved bacterial infection, whereas CRSwNP was regarded as an end stage of a non-infectious disorder linked to severe atopy (Lam et al. 2015). Nowadays, there is common consensus that the inflammation of CRS results from a dysfunctional host environment interacting with different exogenous factors, and the site of this interface is the sinonasal mucosa (Kern et al. 2008, Tan et al. 2010). Microbes, toxins and allergens are thought to be the main environmental factors in CRS, while host factors consist of properties of the immune system.

2.2.3.1 Environmental factor hypotheses

2.2.3.1.1 Fungal hypothesis

Fungi and bacteria are thought to be the most important environmental factors in CRS. The fungal hypothesis suggests a much bigger role for fungi, especially common airborne moulds such as *Alternaria*, in the pathophysiology of CRS (Sasama et al. 2005, Ponikau et al. 1999). This hypothesis has, however, been largely rejected by other investigators (Ebbens et al. 2008). There are multiple arguments against this theory. Although different studies have agreed that fungi can be identified in the nose and paranasal sinuses of nearly all individuals with CRS, they are also present in healthy controls (Ebbens et al. 2008). Eosinophils are an important cell type in the fight against parasitic infection, but they do not play a role in the defence against fungi. Attempts to replicate the primary study to prove the sensitisation to fungi have failed in CRS patients (Douglas et al. 2007). Double-blind, placebo-controlled trials have demonstrated negative results on antifungal drugs in the treatment of CRS (Kennedy et al. 2005, Ebbens et al. 2006). However, fungi may still play an important role as a disease modifier. Proteases from fungi induce inflammatory responses by

altering the permeability of the epithelial barrier and by the induction of proinflammatory cytokines through protease-activated receptors (Yike 2011).

2.2.3.1.2 Bacterial hypothesis

The presence of intramucosal bacteria, biofilms, dysbiosis of microbiomes and superantigens have been suggested to play a role in the pathogenesis of CRS. There have been many attempts to identify the links between specific bacteria and CRS. With the exception of *Staphylococcus aureus*, however, the association between any single species and CRS is low (Bachert et al. 2008).

2.2.3.1.3 Microbiome hypothesis

Recent studies have shifted the paradigm away from one causative biological agent towards disease resulting from a change or dysbiosis in microbial community structure (Wagner Mackenzie et al. 2017). Like the intestine, the upper respiratory tract has a microbiome of its own that maintains the homeostasis of respiratory health. New, more sensitive culture independent technologies have enabled the study of human microbiome in a new way (Wagner Mackenzie et al. 2017). At present, the studies are still limited. Although they show similarity in bacterial load, they also show different kinds of diversity between CRS patients and healthy controls (Feazel et al. 2012, Boase et al. 2013, Wagner Mackenzie et al. 2017). It has been hypothesised that altering the sinus microbiome may favourably alter the course of CRS (Sivasubramaniam and Douglas 2018). Perhaps, in the future we will have mucus transplantation to the nose?

2.2.3.1.4 Biofilm hypothesis

Bacteria exist in two forms – planktonic or biofilm – which demonstrate differential growth and gene expression patterns. In planktonic form, bacteria are free floating; in biofilm form, the form in which almost all (99.9%) of bacteria seems to exist, bacteria form closely organised microcolonies encased in an extracellular matrix (Donlan, and Costerton 2002). This extracellular matrix is composed of polysaccharides, proteins and nucleic acids. Bacteria living in a biofilm have significant benefits compared to free-floating bacteria. This distinct phenotype makes them more resistant to conventional antibiotics and also protects them against host defence mechanisms. (Donlan, and Costerton 2002). To date, the direct role of biofilms in the pathogenesis of CRS has not been proven (Foreman et al. 2011).

2.2.3.1.5 *Staphylococcus aureus* superantigen hypothesis

Bacterial biofilms, especially biofilms produced by *Staphylococcus aureus,* are an important source of superantigens. These super antigenic exotoxins trigger massive, uncontrolled immunologic responses that release inflammatory cytokines and activate up to 25% of the T cell population (Llewelyn and Cohen 2002). This leads to the Th2 immune response with eosinophilic inflammation and polyp formation found in CRSwNP. The data from a 2014 meta-analysis (Ou et al. 2014) of 340 cases showed a significantly greater association between CRSwNP and positive *Staphylococcus aureus* cultures (OR 4.85) and between CRSwNP and directly measured superantigens (OR 12.07). Ou J et.al. concluded that while the meta-analysis was limited by the variation in study designs and patient populations, the data supported the idea that the *Staphylococcus aureus* superantigen may be a risk factor for the persistence and severity of CRS with NPs, and that the presence of *Staphylococcus aureus* superantigens is related to the disease severity of CRSwNP (Ou et al. 2014). Staphylococcal toxins have been found in approximately 50% of Caucasian patients with CRSwNP (Wang et al. 2008). Thus, about half of CRSwNP patients with similar CRSwNP phenotype have no evidence of super antigenic responses, indicating that superantigens are not needed for the typical inflammation seen in CRSwNP (Seiberling et al. 2005). Further, although *Staphylococcus aureus* enterotoxins are clearly disease modifiers, the evidence for a direct causal relationship of *Staphylococcus aureus* superantigens in CRSwNP patients is lacking (Seiberling et al. 2005).

2.2.3.2 Host factor associated hypotheses

Lam et al. (2015) summarise the host factor associated hypothesis as follows: "The mucosal immune system possessed the inherent capability to protect the host from injury induced by environmental agents. First in contact with the outside world is the physical or mechanical barrier, consisting of airway mucus, the MCC and tight junctional complexes between epithelial cells, all acting to limit stimulation of the immune system by foreign material. Backing up this mechanical barrier is the innate immune system, which in part consists of endogenous antimicrobials secreted either constitutively or inducibly by various host cell types into the nasal mucus. Lastly, if the foreign pathogenic stimulus is sufficiently strong, an adaptive immune response with highly specific T and B proliferation will be initiated." (Lam et al. 2015)

2.2.3.2.1 Immune barrier hypothesis

The immune barrier hypothesis of CRS suggests that defects in the mechanical and innate immune protective barrier promote antigen passage and processing across the nasal epithelium and leads to chronic inflammation in CRS when challenged by relatively common microbial agents. These barrier defects may be caused by genetic, epigenetic or environmental influences. (Kern et al. 2008).

2.2.3.2.2 Epithelial barrier and mucociliary clearance

MCC plays a major role in removing foreign particles and pathogens from the upper airways. MCC relies upon mucus production and transport (Baroody 2007). Genetic defects that affect the MCC, such as primary ciliary dyskinesia and cystic fibrosis, have a correlation with CRS (Afzelius and Mossberg 1980, Illing and Woodworth 2014). Seshadri et al. reported that the expression of pendrin, an epithelial anion transport, is increased in the NPs of patients with CRS. Increased pendrin expression might lead to chronic inflammation, increased mucus production and decreased MCC, leading to frequent bacterial infection and colonisation (Seshadri et al. 2015). Several pathogens, and especially the toxins they produce, that include *Haemophilus influenzae, Streptococcus pneumoniae, Staphylococcus aureus, Aspergillus fumigatus and Pseudomonas aeruginosa* impair ciliary motion (Amitani et al. 1995, Gudis et al. 2012, Shen et al. 2012). The blockage of sinus ostia or the accumulation of mucus can lead to poor oxygen delivery and hypoxia. Blount et al. found that hypoxia led to decreased transepithelial transport. They suggested that persistent hypoxia may lead to acquired defects in sinonasal Cl- transport, and thus affects mucociliary function in CRS (Blount et al. 2011).

Epithelial cells of the sinonasal mucosa are linked by tight and adherent junctions that create a relatively impermeable barrier. NPs express decreased levels of adhesion complex proteins, leading to a weakened mechanical barrier (Zuckerman et al. 2008, Richer et al. 2008). Zuckerman J et al. speculated that weakened desmosomal junctions in nasal mucosa, secondary to inflammatory cytokines, may contribute to the formation of nasal polyposis (Zuckermanet al. 2008). Oncostatin M is a member of the IL-6 family of cytokines. Pothoven K. et al. found that Oncostatin M levels were increased in NP tissues derived from patients with CRSwNP. They also demonstrated that stimulation with Oncostatin M at concentrations like those seen in vivo were sufficient to cause a significant loss of barrier function and disorganisation of tight junction structure. These findings suggest that Oncostatin M might be mediating epithelial barrier dysfunction in patients with CRS (Pothoven

et al. 2015). Pathogens secrete several virulence factors that can directly impact the epithelial barrier. Elastase, secreted by *Pseudomonas aeruginosa*, increases the permeability of airway epithelial cells owing to the disruption of tight junctions (Nomura et al. 2014). Malik et al. showed in their data that secreted products from *Staphylococcus aureus* compromise the epithelial barrier function of primary human nasal epithelial cells in vitro (Malik et al. 2015).

Overall, the above data suggest that impairments in MCC are found in both forms of CRS, but the increased permeability of the epithelial cells is more closely linked with CRSwNP.

2.2.3.2.3 Innate immunity

The innate immune system is an inborn defence that is present before the first contact with a pathogen. Different kinds of environmental stimuli that affect the mechanical barrier may activate an innate immune response. Cytoplasmic pattern recognition receptors found in sinonasal epithelial cells and other cell types recognise pathogens associated molecular patterns. Cellular damage is sensed through the damage-associated molecular patterns. The combined signal of foreign material plus cellular damage triggers an innate response releasing of host defence molecules, cytokines, and chemokines. These molecules promote an inflammatory response and activate innate effector cells, such as eosinophils, mast cells, neutrophils, and macrophages. Normally, in a healthy subject, crosstalk between epithelial cells, dendritic cells and innate lymphoid cells leads to the appropriate innate and adaptive response to foreign stimuli and maintains mucosal homeostasis. (Bachert et al. 2014)

The toll-like receptor family is the best studied class of pattern recognition receptors in CRS. They are a family of 10 integral membrane glycoproteins which are expressed on sinonasal epithelium. They may also have an important role in local defence in nasal mucosa and contribute to the development of CRS (Lane et al. 2006, Dong et al. 2005). New data show that T2R bitter and T1R sweet taste receptors also play a role in the pathogen detection network, functioning as pattern recognition receptors on epithelial cells of the sinonasal mucosa and regulating multiple innate immune responses. Polymorphisms of these taste receptors also appear to be involved in the pathophysiology of CRS (Lee and Cohen 2014).

At a basal state, sinonasal epithelial cells release antimicrobial molecules at a steady rate. This secretion increases during infection upon the stimulation of pattern recognition receptors. These antimicrobial molecules include lactoferrin, lysozyme, defensins, antitrypsin, S100 proteins and innate immune proteins of the palate lung and nasal epithelial clone (PLUNC) family (Schleimer 2017). There is an anatomic

site-specific distribution of these proteins in sinonasal tissues, suggesting the possibility of the specialised regional functions of these proteins within the sinonasal cavity (Seshadri, Rosati et al. 2013). Some of these antimicrobial molecules have been found to be diminished in CRS, suggesting that these defects in the innate immune system might lead to an increased susceptibility to bacterial and fungal colonisation in patients with CRS (Tieu et al. 2009).

2.2.3.2.4 Adaptive immunity

The adaptive immune system consists of highly specific T cells and B cells, which are capable of fighting against pathogens and coordinating the inflammatory responses. Th1, Th2 and Th17 are the three most prominent inflammatory pathways in CRS. Specifically, these different inflammatory pathways function in host defence, in response to different types of pathogens and play an important role in the type of mucosal inflammation. (Bachert et al. 2014). Furthermore, Th1-mediated neutrophilic inflammation is generally described to be dominant in patients with CRSsNP. Conversely, Th2-driven eosinophilic inflammation is found to be more prominent in CRSwNP in Caucasian patients, allergic fungal rhinosinusitis and aspirin-exacerbated respiratory disease (AERD) Th17 pathway is associated with CRSwNP patients of Asian origin (Smith et al. 2018).

CRSwNP is the most thoroughly studied form of CRS. In CRSwNP, specific epithelial cell-derived cytokines, thymic stromal lymphopoietin, IL-33 and IL-25 directly activate innate lymphocyte 2 populations, which then produce Th2-cell-associated cytokines including IL-4, IL-5 and IL-13 and promote type 2 inflammation (Artis and Spits 2015). Thymic stromal lymphopoietin also triggers dendritic cell-mediated Th2 inflammatory responses, which then enhance IL-1-dependent Th2 cytokine production in mast cells (Nagarkar et al. 2013). High levels of thymic stromal lymphopoietin have been identified in patients with CRSwNP, suggesting an important role in the inflammation seen in patients with CRSwNP. (Nagarkar et al. 2013). Eosinophilic NPs contain double the number of innate lymphocyte 2s vs. non-eosinophilic polyps (Walford et al. 2014) A genetic analysis of 284 patients with CRS found that IL-33 was significantly associated with NPs (Buysschaert et al. 2010). Elevated local IgE levels are a signature sign in NPs (Kim and Cho 2017). Interestingly, the inflammation pattern of CRSwNP is remarkably different between Asian and Western populations, with Th1/Th17, neutrophilic dominance in patients born in Southern China and Th2, eosinophilic dominance in patients born in Belgium (Zhang et al. 2008).

Although CRSsNP is more prevalent than CRSwNP, there have been far fewer studies concerning the pathophysiology of CRSsNP. Earlier, CRSsNP was characterised more by type 1 neutrophilic inflammation with elevated levels of interferon gamma and transforming growth factor beta. (Van Zele et al. 2006). However, IL-6, IL-8, IL-17 and type 1 interferons also have important roles in the pathophysiology of CRSsNP (Bachert and Akdis 2016a). The most recent results about inflammatory cytokine levels in CRSsNP are, however, inconsistent. In a more recent study, no difference was found in the expression of interferon gamma messenger RNA or protein expression between CRSsNP and CRSwNP (Stevens, Ocampo et al. 2015). Moreover, Wang and colleagues showed that subtypes with all Th1/Th2/Th17 cytokine profiles were found in both CRSwNP and CRSsNP (Wang et al. 2016). The data suggest that CRSsNP is not pure type 1 inflammation, and that it can be more like a disease with a mixture of different inflammatory pathways.

Derucke L et. al. found that the number of T cells from sinonasal mucosal samples were significantly higher in CRSwNP compared with CRSsNP or control nasal tissue studied with flow cytometry and intracellular cytokine staining. The profile of the T cell population of CRSsNP patients was similar to that of healthy controls. Based on the results of interferon gamma staining, the majority of T cells in each study group were Th1 cells, and Th2 cells were only observed in patients with polyps (Derycke et al. 2014).

Regulatory T cells modulate the strength of T cell response. However, the information on regulatory T cell in CRS pathogenesis has been conflicting. FoxP3 is the main transcriptional regulator of regulatory T cells. The expression of FoxP3 has been demonstrated to be decreased in NP tissue, suggesting the deficiency or dysfunction of regulatory T cells in CRSwNP (Van Bruaene et al. 2008). A more recent study identified a significant increase in regulatory T cells and Th17 cells in polyps from CRSwNP patients compared to the polypoid tissue from CRSsNP patients. Interestingly, they found that these cellular differences were not present in the CRSwNP, CRSsNP and control groups when the peripheral blood or nonpolypoid mucosal tissue were studied (Miljkovic et al. 2016).

B cells may also significantly contribute to the pathogenesis of CRSwNP. B cell activating factor of the tumor necrosis factor (TNF) family (BAFF) plays an important role in B cell survival, proliferation and maturation. Furthermore, it has been shown to be elevated in NPs compared with inferior turbinate tissue from CRS or healthy subjects. (Kato et al. 2008). NPs have been shown to contain significantly more B cells, plasma cells and antibodies than mucosal samples from healthy controls. (Hulse et al. 2013). In particular, the immunoglobulins (Ig) IgG1, IgG2,

IgG4, IgA, IgE and IgM were found to be increased. This effect seems to be local because these antibodies or cells cannot be found in the peripheral blood of the same CRSwNP patients (Hulse et al. 2013). There is a scarcity of data on the specificities of the antibodies found in NPs. However, specific IgE antibodies against *Staphylococcus aureus* have been isolated from the NPs of CRSwNP patients (Chen et al. 2016). The function of IgD has been a puzzle in immunology since its discovery in 1964. Interestingly, local IgD levels were elevated in the sinonasal tissue samples of CRSsNP patients compared to healthy controls. This antibody elevation was associated with increased local IL-2 levels and the presence of pathogenic bacteria IgD. The authors suggest that IgD might contribute to protective mucosal immunity or inflammation or respond to bacterial infection in CRSsNP patients (Min et al. 2017).

2.2.3.2.5 Tissue remodelling

Several inflammatory and remodelling factors are elevated in CRS. Cellular remodelling is a process in which the production and degradation of the extracellular matrix are balanced. Moreover, transforming growth factor beta is a key mediator in this remodelling process. It attracts fibroblasts, induces their proliferation and up-regulates extracellular matrix synthesis (Bachert and Holtappels 2015). A high transforming growth factor beta protein expression was found in CRSsNP, whereas in CRSwNP patients and healthy controls the expression of the protein was low. This supports the hypothesis that CRSsNP and CRSwNP might be two different disease entities (Van Bruaene et al. 2009).

Traditionally, CRSsNP is characterised by fibrosis, basement membrane thickening and goblet cell hyperplasia, whereas NPs are histologically characterised by intense oedema or the formation of pseudocysts filled with plasma proteins, mainly albumin. Unlike CRSsNP which might be a purer remodelling disease, CRSwNP has features from a chronic inflammation and tissue remodelling origin. Meng J et al. studied the early pathological features of NPs. They found a complex network of processes in the formation of CRSwNP that included gross epithelial damage, repair reactions, eosinophil and macrophage cell infiltration and tissue remodelling (Meng et al. 2013). Takabayashi T. et al. showed an impairment of fibrin degradation caused by a reduction of tissue plasminogen activator and abnormal fibrin deposition in NPs. They speculated that abnormal fibrin deposition might be the cause of the formation of intense oedema or pseudocysts in NPs. Excessive fibrin deposition, resulting from reduced fibrinolysis, may reflect Th2 inflammatory responses and may have a pathogenic role in CRSwNP (Takabayashi et al. 2013).

Hypoxia is a potent stimulus for inflammation and remodelling. Hypoxic conditions present in the sinus tissue could increase the production of proinflammatory and remodelling cytokines and growth factors that contribute to the recruitment of neutrophils and eosinophils and lead to the inflammation observed in CRS. The hypoxic conditions caused by the occlusion of the sinus ostia may induce transforming growth factor beta-rich neutrophilic inflammation and fibrosis. (Steinke et al. 2008, Early et al. 2007)

2.2.4 Burden of chronic rhinosinusitis

2.2.4.1 Economic aspects

Administrative databases may provide a more accurate and more useful estimate of prevalence that better reflects the economic burden than the prevalence rates obtained from population studies, which tend to overestimate the true prevalence.

The overall costs of CRS consist of direct (a cost associated with producing a unit of health output) and indirect (a cost that is not the result of producing a unit of health output) costs (Smith and Rudmik 2013). Direct costs mostly originate from outpatient visits, medical therapy and surgery (Caulley et al. 2015). Conversely, indirect costs typically result from the loss of labour input or reduced productivity while at work. CRS mostly affects patients in their most productive work years. Therefore, the socioeconomic impacts of CRS are larger than those of other chronic diseases that tend to involve more elderly patients.

Bhattacharyya et al. reported that the national health care costs of CRS in the USA in 2007 was approximately 8.6 billion USD (9.9 billion converted to 2014 USD) (Bhattacharyya 2011). Caylley et al. surveyed the same MEPS-database. In their study, a prevalence-based approach was used to estimate the cost of disease by using a 4-part model for CRS in 2011. The overall direct cost attributable to CRS in the USA was found to approach 12.5 billion USD per year (Caulley et al. 2015).

In 2014, Rudmik et al. studied a cohort of prospectively enrolled patients with refractory CRS and found the indirect mean costs to be 10.077 USD per patient per year. Thus, using a conservative prevalence estimate, the overall indirect cost of refractory CRS exceeded 13 billion USD (Rudmik et al. 2014a). In 2003, Bhattacharyya prospectively studied 322 patients with CRS and quantified workdays missed and reported an estimated cost of 880 USD per patient per year. The overall yearly economic cost per patient with CRS was 2 188 USD (Bhattacharyya 2003).

It is probable that the per capita economic burden of CRS in Finland is significantly lower than that reported in these studies, considering the low cost-effectiveness of the United States of America health care system.

2.2.4.2 Impact on quality of life

CRS has a substantial impact on health-related QoL. The most common symptoms of medically refractory CRS are nasal congestion, fatigue, headache, decreased sense of smell and facial pain/pressure. Headache is the most disabling of these symptom (Soler et al. 2008). Brandsted et al. reported that 25% of patients with sinonasal symptoms also had a diagnosis of depression, which is a larger proportion than in the general population. They concluded that CRS patients with and without depression had similarly poor disease-specific symptoms. Moreover, after ESS, the depressed patients had poorer disease-specific and overall QoL outcomes (Brandsted and Sindwani 2007). Benninger et al. reported that patients with CRS have significantly reduced sleep and sexual activity scores on the Rhinosinusitis Disability Index. A recent Finnish population-based matched cohort study by Alakärppä A et al. showed a significant improvement in QoL measured with 22 item Sinonasal Outcome Test (SNOT-22) after ESS. In the study, 84 ESS patients and 206 healthy controls were enrolled. At entry, the mean SNOT-22 score was 35.1 in the ESS group and 17.7 in the control group. At 12 months after ESS, the mean change in SNOT-22 scores was -18.0 (CI 11.4-19.9) (Alakärppä et al. 2017). There were significant improvements in scores of sexual function and sleep after ESS (Benninger et al. 2010). In another study, 158 patients with CRS referred for otolaryngologic care were evaluated with the Medical Outcome Study Short-form 36-Item Health Survey. The measures of bodily pain, general health, vitality and social functioning in patients with CRS were found to be significantly lower than in patients with angina, back pain, congestive heart failure and chronic obstructive pulmonary disease (Gliklich and Metson 1995).

2.2.5 Diagnosis and measurements of chronic rhinosinusitis

2.2.5.1 Symptoms

There have been surprisingly few epidemiological studies reporting symptoms in CRS. Most studies use a questionnaire asking patients to rate the severity of specific symptoms, and thereby encourage patients to report only those items listed and to report symptoms that they might not have done so if asked to provide a list of symptoms without guidance. (Fokkens et al. 2012). The symptoms listed are mostly those that are used as a definition of CRS. The most common symptoms and the most studied ones are nasal obstruction (81%-95%), followed by facial congestion/pressure-fullness (70%-85%), discoloured nasal discharge (51%-83%) and hyposmia (61-69%) (Orlandi and Terrell 2002, Bhattacharyya 2003). CRS may be accompanied by other nonspecific symptoms, such as headache (50%-83%), fever (9%-33%), cough (39%-65%), halitosis (37%-53%), fatigue (67%-84%), dental pain (23%-51%), ear pressure/pain (42%-68%) and other nonspecific signs and symptoms (Orlandi and Terrell 2002, Bhattacharyya 2003).

The presence of polyposis increases the risk of hyposmia (OR 2.4) and anosmia (OR 13.2) in patients with CRS (Litvack et al. 2008). In a cohort of 126 CRS patients, Banjeri and colleagues showed that nasal obstruction and hyposmia or anosmia were more significantly linked with CRSwNP, whereas patients with CRSsNP had more facial pain or pressure. They also concluded that patients with CRSwNP had more symptoms, underwent surgery more often, had higher CT scan scores and used more medication than CRSsNP patients (Banerji et al. 2007). Similar results were reported in a study of 251 patients. CRSwNP patients had significantly worse nasal symptoms, olfactory and nasal obstruction, whereas patients with CRSsNP suffered more from fatigue symptoms, had sleep problems and functional disturbances (Gregurić et al. 2016).

Odontogenic infections, non-invasive fungal balls and sinonasal tumours should be kept in mind as a differential diagnosis, especially when patients have unilateral CRS symptoms or findings in the radiographic examinations.

2.2.5.2 Endoscopy

Anterior rhinoscopy allows only visualisation of the anterior one-third of the nasal cavity. Moreover, with anterior rhinoscopy, only large polyps or profuse purulent secretions can be seen. In most cases, however, this is inadequate to diagnose CRS.

Nasal endoscopy can be performed with a flexible or rigid endoscope. Nasal endoscopy gives an excellent view of the sinus drainage pathways in the middle meatus, sphenoethmoidal recess and nasopharynx. Purulent secretion or oedema in the middle meatus, or polyps in the nasal cavity support the diagnosis of CRS.

A systematic review assessed three studies concerning the diagnostic value of nasal endoscopic findings in adults suspected of having CRS. The prevalence of CT-diagnosed CRS was 40% to 56%. Findings in nasal endoscopy, as described in an earlier chapter, have an added value for ruling in CRS of 25% to 28% and an added value of ruling out CRS by normal nasal endoscopy of 5% to 30%. The authors recommend not performing CT if there are positive findings in endoscopy because CT is expensive and does not provide conclusive information (Wuister et al. 2014). Bhattacharyya et al. concluded that in patients with symptoms of CRS, nasal endoscopy improves diagnostic accuracy and should be used as an early diagnostic tool. Nasal endoscopy may therefore decrease the use of CT, reducing costs and radiation exposure (Bhattacharyya and Lee 2010).

2.2.5.3 Imaging

Although plain sinus x-ray may have some usefulness in the diagnosis of acute rhinosinusitis and in screening for various other pathological conditions in the sinonasal cavities, it has only limited value in the diagnosis of CRS. (Mafee et al. 2006). The use of CT has noticeably improved the quality of imaging of the paranasal sinuses compared to plain-film sinus radiography. Today, CT is the current gold standard imaging modality for the pathology of the paranasal sinuses due to the detailed bony structure identification and good visualisation of the skull base. However, CT of the paranasal sinuses should not be used as a first line method in the diagnosis of CRS because of exposure to radiation. CT should therefore only be considered when ESS is being planned after failed medical treatment or when complications of CRS are suspected. Mucosal thickening inside the sinuses and sclerosis of the bone is often seen in CT scan images of CRS patients (Mafee et al. 2006).

A lot of interest has recently been devoted to improving the resolution and reducing the radiation dose. Mozzo et al. introduced a new type of volumetric CT that uses cone-beam imaging instead of the traditional fan-beam technique. This new technique was first utilised in dentomaxillofacial imaging (Mozzo et al. 1998). Fakhran et al. compared CBCT to multidetector CT and reported that the effective radiation dose for their scanners ranged from 0.67 mSv to 2.15 mSv compared to a published estimated dose of 0.2 mSV for CBCT (Fakhran et al. 2014). De Cock et al. concluded that CBCT and multislice CT are both suitable for the evaluation of sinonasal polyposis. In patients with CRSwNP, clinically important structures of the paranasal sinuses can be better detected with multislice CT, whereas in patients without NPs, CBCT better defines the important surrounding structures. However, they concluded that with a lower radiation dose (63 μSv vs. 108 μSv), CBCT can be used for the evaluation of the sinonasal structures in CRSwNP patients. (De Cock et al. 2015). The accuracy of CBCT scanning is high, and CBCT findings are well correlated with sinus endoscopy findings (Zojaji et al. 2015). Considering the high accuracy, excellent bone definition, and lower costs and radiation doses, CBCT is a real option for CT in the assessment of CRS.

Due to its superior soft tissue definition, magnetic resonance imaging (MRI) is better than CT in differentiating inflammatory processes from neoplastic ones. The complications of rhinosinusitis, such as intracranial or intraorbital abscesses, are also best evaluated using MRI. (Mafee et al. 2006). One of the major advantages of MRI compared to CT is that MRI does not entail the use of radiation. In most cases, a combination of MRI and CT imaging allows a better evaluation of the disease if fungal sinusitis, pyocele or malignancies of the paranasal sinuses or skull base are suspected (Eggesbø 2006).

2.2.5.4 Imaging for staging of chronic rhinosinusitis

Several different kinds of CT-based radiological staging systems have been developed, but the most used is the Lund-Mackay (LM) scoring system (Oluwole et al. 1996). This validated test was developed as a simple instrument to help in making treatment decisions (Lund and Mackay 1993). The evaluation of CT images is easy and does not require radiology training. Each sinonasal cavity is evaluated on CT images as completely clear, partly opaque or completely opaque, which results in a simple numeric score. This scoring scheme has been shown to have high intra-observer inter-observer reliability (Oluwole et al. 1996). To date, it has been mostly used for research purposes. Hopkins et al. evaluated LM-staging in a large

prospective study of 1 840 patients undergoing ESS. There was no correlation between LM and SNOT-22 scores, but LM-score associated with grade of polyposis. The LM-score correlated with symptom reduction, complication rates and revision rates. The authors could not find an absolute threshold for ESS, but patients with higher scores had more extensive surgery. (Hopkins et al. 2007).

The LM-staging system has been criticised for its inability to track progression or reduction of the disease volume. A more detailed Zinreich modified staging system has been developed from the original LM-staging system to achieve better accuracy (Zinreich 2004). This system grades the rhinosinusitis inflammation on CT images to four stages using 25% intervals and includes a 5-point inflammation score. Unlike the LM-staging system, the Zinreich modified staging system does not evaluate the ostiomeatal complex. Okushi et al. compared these two systems. They could not conclude whether one system was superior to the other. However, the modified staging system provided a more granular gradation of CRS inflammation compared to the LM system and had acceptable accuracy (Okushi et al. 2013).

A more accurate staging system has recently been introduced. Valtonen et. al. published a novel method to evaluate the changes in the thickness of mucous membrane in sinuses using volumetric measurement of the sinuses from CBCT scans. The volumetric measurement correlates well with the LM and Zinreich modified systems, but it is much more accurate in picking up small changes in the thickness of mucous membrane (Valtonen et al. 2018).

2.2.5.5 Acoustic rhinometry

Acoustic rhinometry is a technique that provides an estimate of the cross-sectional area and volume of the nasal cavity as a function of the distance from the nostril. Based on acoustic reflection, the technique is non-invasive, rapid and requires only a little co-operation from the patient. Furthermore, it does not require any flow through the nose for the measurement, and thus can be used also when the nose is totally occluded (Hilberg et al. 1989).

AR is used as a reliable tool to evaluate the dimensional changes of the nasal cavity before and after a given sinonasal surgery. (Grymer 2000). Numminen J and colleagues demonstrated that acoustic rhinometry is a clinically and scientifically reliable method for measuring the geometry of the nasal cavity, especially in the anterior and middle parts of the nasal cavities (Numminen et al. 2003). Measurements of the total cavity were found to be the most sensitive measure of change in nasal patency by decongestion (Straszek et al. 2007). The alternating

congestion of the nasal cavities (the nasal cycle) can affect the measurements that are snapshots in time. Despite the nasal cycle, the total resistance of the nasal cavities appears to remain relatively constant in time (Hanif et al. 2000).

2.2.5.6 Rhinomanometry

Rhinomanometry is a method that provides a quantitative measure of nasal airway resistance. It involves the measurement of nasal airflow and the pressure gradient required to achieve that flow from which nasal airway resistance can then be calculated (Ottaviano 2016). Rhinomanometry has been used for the evaluation of anatomical (Pirilä and Tikanto 2009) and mucosal (Ciprandi et al. 2006) nasal obstruction, and the pre- and post-treatment results of surgical or medical therapy (Bizaki et al. 2016, Thulesius et al. 2014).

2.2.5.7 Quality of life measurements

QoL is the most important thing when measuring success of treatment or surgery from the patient's point of view. Endoscopic and radiologic improvements do not matter if the patient does not feel better. However, the concept of QoL is hard to define. In 1995, the World Health Organization defined QoL as follows: individuals perception of their position in life in the context of the culture and value systems in which they live and in relation to their goals, expectations, standards and concerns (Kuyken, et al. 1995). Health-related QoL narrows QoL to aspects relevant to health. Patient-reported outcome measures are questionnaires that measure the patients´ view of their health. Furthermore, patient-reported outcome measures are increasingly used in the medical field of otorhinolaryngology to measure clinical effectiveness and QoL (Alakärppä and Alho 2012). QoL is measured using different kinds of instruments, typically questionnaires that provide scores according to the severity or impact of disease. Some patient-reported outcome measures are disease-specific, specifically developed for particular conditions, while others are generic, designed for use in all patients (Fokkens et al. 2012).

There are various validated QoL tests available for use in CRS in the adult population. The most used and recommended disease-specific QoL instrument for CRS is the SNOT-22 QoL questionnaire. SNOT-22 is a patient-reported measure of outcome developed for use in CRS with or without nasal polyposis. It has been validated in different languages, also in Finnish in 2017 and contains 22 individual

questions about nasal symptoms and covers a broad range of health and health-QoL problems, including physical problems, functional limitations and emotional consequences (Hopkins et al. 2009, Hytönen et al. 2017), see appendix. A systematic review and meta-analysis showed that mean change in SNOT-22 score across patients who have undergone ESS to treat CRS was 24.4 (range, 12.7 to 44.8 between studies). They also concluded that the change of SNOT-22 score varied a lot between the studies and was influenced by a number of different factors, including baseline SNOT-22 score, asthma and the length of follow-up (Soler, Jones et al. 2018). The threshold for the minimally important clinical change in SNOT-22 score that can be detected by a patient is considered to be 8.9 points (Hopkins et al. 2009).

The most widely used generic health status instrument for patients with CRS is Medical Outcome Study Short Form 36. It is also used in other chronic disease, and thus enables comparisons of the QoL of patients with CRS and other patient groups. It contains a set of eight domains of health: physical functioning, role limitations due to physical problems, role limitations due to emotional problems, social functioning, mental health, energy/vitality, pain and general health perception. It is validated and has been used to evaluate the impact of CRS on QoL and the treatment outcomes of CRS (Ragab et al. 2010, Gliklich 1995).

2.2.5.8 Visual analogue scale

Visual analogue scale (VAS) is a psychometric response scale that is widely used to quantify the severity of symptoms as perceived by the patient. These kinds of symptoms and attitudes are believed to range across a continuum of values and cannot be directly measured easily. VAS is usually a 10-cm long horizontal line with word anchors at each end representing the extremes of the feeling. Patients are instructed to mark the point on the line that best corresponds to their symptom severity. This validated test is easy to use by both patients and health care professionals. (Klimek et al. 2017, Doulaptsi et al. 2018).

2.2.6 Conditions associated with chronic rhinosinusitis

2.2.6.1 Asthma

There are epidemiological and clinical data showing that CRS and asthma coexist in the same patients. A study of over 52 000 adults living in 12 European countries found a strong association between the self-reported prevalence of asthma and CRS (OR 3.47) in all age groups. The correlation with asthma was stronger in patients who reported both CRS and allergic rhinitis (OR 11.85) (Jarvis et al. 2012). The CRS patients with asthma had a significantly higher prevalence of NPs (47% vs. 22%), olfactory dysfunction (26% vs. 6%) and nasal congestion (85% vs. 60%) than those without asthma (Seybt et al. 2007). CRS and asthma share the same immune process involving the contiguous upper and lower airway system; however, their relationship is poorly understood (Brożek et al. 2017). There is a positive correlation between the severity of asthma with the severity of the mucosal abnormalities seen in sinus CT scans (Bresciani et al. 2001).

A systematic review and meta-analysis concluded that ESS improved overall asthma control. The frequency of asthma exacerbations decreased in 84.8% of patients and the number of hospitalisations in 64.4% of patients. In addition, a diminished use of oral corticosteroids was seen in 72.8% of patients; inhaled corticosteroid use decreased in 28.5% of patients and bronchodilator use decreased in 36.3% of patients. However, the pulmonary function remained unchanged (Vashishta et al. 2013). In a retrospective database analysis of 9 105 patients who underwent ESS in the United States in 2008, asthma was a significant determinant of CRS cost. CRS patients with asthma had a greater total number of surgeries, an increased rate of inpatient and outpatient admissions and greater drug utilization when compared to CRS patients without asthma (Benninger and Holy 2014).

There are data from population-based studies that support evidence of a connection between nasal polyposis and asthma (Klossek et al. 2005, Johansson et al. 2003).

2.2.6.2 Allergy

It is a commonly accepted theory that sinonasal inflammation may obstruct the ostia of the paranasal sinuses and may therefore be part of the pathophysiology of CRS. Oedema caused by allergic rhinitis may also occlude the ostiomeatal complex and

affect the ventilation of the sinus cavities, leading to mucus retention and inflammation of the paranasal sinuses. This idea is supported by the finding that allergic patients had significantly more mucosal findings in CT imaging compared with nonallergic patients (Kirtsreesakul and Ruttanaphol 2008, Berrettini et al. 1999). Epidemiological data show an increased prevalence of atopy in patients with CRS (54% to 84% had positive skin prick tests) (Emanuel and Shah 2000, Benninger 1992, Tan et al. 2011). However, the causal relationship between allergy and CRS has remained controversial. To date, there have been no controlled trials on the role of allergy in the pathophysiology of CRS. Furthermore, there have been no controlled trials showing that the treatment of allergy would change the course of CRS and vice versa. In 2014, Wilson and colleagues conducted an evidence-based review of the association between allergy and CRS. Of the 9 studies included in the review that addressed the relationship between allergy and CRSsNP, 4 studies showed an association and 5 did not. Ten studies reported an association between allergy and CRSwNP, 7 studies reported no association and 1 study reported a possible association. They concluded that the role of allergy in CRSwNP and CRSsNP continues to be controversial, with the level of evidence being poor. Based on the available data, the recommendation is that allergy testing and treatment are an option in CRS (Wilson et al. 2014).

2.2.6.3 Aspirin-exacerbated respiratory disease

AERD is a chronic eosinophilic inflammatory disorder of the respiratory tract occurring in patients with non-allergic asthma and CRSwNP, where symptoms are exacerbated by non-steroidal anti-inflammatory drugs (NSAID), including aspirin (Kowalski et al. 2019). It is a specific type of non-allergic hypersensitivity. Synonyms in use for this disease include Samter´s syndrome/triad, Aspirin triad or NSAID-exacerbated respiratory disease. The disease was first described by Samter and Beers over fifty years ago (Samter and Beers 1968). AERD affects approximately 7% of adult asthmatic patients and 10% of patients with CRSwNP (Rajan, Wineinger et al. 2015). The clinical presentation of asthma is, however, more severe than in the general asthma population (Mascia et al. 2005). Moreover, CRSwNP patients with AERD undergo ESS more often, are younger at the time of the first surgery and have NP recurrence more frequently than patients without AERD (Stevens et al. 2017).

2.2.6.4 Ciliary impairment

Proper MCC eradicates both normal and pathological secretions from the upper and lower respiratory tract. MCC is the primary innate defence mechanism against inhaled particles. Healthy airways are covered by ciliated epithelium. Cilia beat in metachronal waves to move mucus out of the sinuses to the nasopharynx where it can be cleared by expectoration or swallowing. Proper ciliary function is needed for effective MCC. MCC also relies on mucus production, composition and transport. (Bustamante-Marin and Ostrowski 2017)

Ciliary dyskinesias are primarily the result rather than the cause of chronic sinusitis. Patients with CRS have a substantial loss of differentiated epithelial cells as well as ciliary defects which are studied under an electron microscope. (Al-Rawi et al. 1998). The normal mucociliary transit time is significantly prolonged when CRS is present (Penttilä et al. 1994, Mahakit and Pumhirun 1995).

In conditions which affect the MCC, CRS is a common problem. In patients with cystic fibrosis, a defect in the electrolyte transport causes abnormally thick, viscous mucus, leading to secondary ciliary malfunction and consequently CRS (Sheppard and Welsh 1999, Illing and Woodworth 2014). Patients with abnormal ciliary morphology, such as primary ciliary dyskinesia, have an abnormal ciliary function, and these patients typically suffer from chronic respiratory infections and CRS (Afzelius and Mossberg 1980).

2.2.6.5 Smoking

There is clear epidemiological evidence in the literature that smoking leads to an increased prevalence of CRS. Many population-based studies have suggested a dose-dependent effect in terms of the number of cigarettes smoked and the prevalence of self-reported CRS (Reh et al. 2012). This finding was confirmed in the large European GA2LEN study that showed that current smoking and the number of pack-years was associated with higher odds ratio (OR) of self-reported CRS (Hastan et al. 2011). In the Korea National Health and Nutrition Examination Survey study, 11 589 patients completed questionnaires on both rhinologic symptoms and smoking behaviour and underwent nasal endoscopy. The authors found a strong association between active smoking and CRS. The prevalence of CRS was found to increase by 1.5% for each yearly increase in the total smoking period (Lee et al. 2015).

Many studies have examined the pathophysiologic mechanisms of cigarette smoke on respiratory epithelium. Cigarette smoke impairs MCC, reduces cilia beat

and affects the ciliogenesis and epithelia regeneration process. (Tamashiro et al. 2009). There are also data supporting the hypothesis that smoking induces sinonasal biofilm formation in respiratory bacteria (Antunes et al. 2012, Goldstein-Daruech et al. 2011).

The results of studies evaluating the effects of smoking on ESS have been less conclusive. There are studies that report significantly poorer post-operative ESS clinical outcomes in patients who smoked, including a higher likelihood of not experiencing an improvement of symptoms (57.2% vs. 27.6%) after 12-month follow-up (Sobol et al. 1998) and a larger number of revision surgeries (20% vs. 7%) (Krzeski et al. 2011). In a prospective study, smoking was associated with worse postoperative QoL outcomes (Katotomichelakis et al. 2014). However, there are recent studies in which active smoking status does not alter postoperative improvements in health-related QoL after ESS (van der Veen et al. 2017, Rudmik et al. 2011a) or result in reoperations (Hox et al. 2012). Interestingly, in one study, smokers achieved a greater short-term QoL benefit than non-smokers (Das et al. 2007).

2.2.6.6 Immune deficiencies

Immune deficiencies are defects of the immune system, which cause more frequent and severe infections, and infections caused by unusual pathogens. Primary immune deficiencies are inherited disorders of immune function, whereas secondary immune deficiencies occur as the result of events such as a viral infection or iatrogenic immunosuppression. (Chiarella and Grammer 2017)

The presence of primary immune deficiency should be suspected in patients who have recurrent pneumonia and ear, sinus and/or cutaneous infections (McCusker et al. 2018). Several studies have shown a high prevalence of primary immune deficiencies, especially hypogammaglobulinemia, in patients with CRS. (Alqudah et al. 2010, Schwitzguébel et al. 2015). The most frequent and studied immune deficiency in patients with CRS is Ig deficiency. A meta-analysis revealed the prevalence of pooled IgG, IgA and IgM deficiencies to be 13% in patients with recurrent CRS and 23% in patients with difficult-to-treat CRS (Schwitzguébel et al. 2015). An unexpectedly high incidence of immunity dysfunctions has been found to be associated with refractory sinusitis patients. In a sample of 60 such patients that were studied with in vitro T-lymphocyte function testing, 55% showed an abnormal proliferative response to recall antigens (Chee et al. 2001). An investigation of the conditions complicating the usual management strategies of CRS, including primary

immune deficiencies, should be considered in patients with recalcitrant disease. A basic evaluation, consisting of quantitative serum Igs and functional antibody responses, may uncover treatable immune disorders (Mazza and Lin 2016). Secondary immune deficiencies are more and more common due to the increased use of immunosuppressive medication. Chemotherapy for B cell lymphoma and the use of rituximab, corticosteroids or immunosuppressive drugs were the most common causes of secondary antibody deficiency in a cohort study of 167 patients (Duraisingham et al. 2014).

2.2.7 Treatment

2.2.7.1 Conservative treatment

2.2.7.1.1 Steroids

Corticosteroids are widely used for the treatment of both CRSwNP and CRSsNP to decrease the inflammatory burden of the disease. Corticosteroids bind to glucocorticoid receptors in the cytoplasm and inhibit the expression of multiple inflammatory genes which cause multifactorial results, such as downregulation of the inflammatory cells and inhibition of the secretion of pro-inflammatory mediators during the late phase of the inflammatory response (Barnes 1998).

The topical administration route is safe and only minor side effects, such as mucosal irritation, crusting and minor nose bleeds, have been reported. No evidence of hypothalamic-pituitary-adrenal axis suppression or an increased risk of cataracts or glaucoma have been found in patients using topical ICSs. (Bensch 2016, Campbell 2018). Systemic absorption rates of topical ICSs are higher among the older corticosteroids, such as budesonide and beclomethasone vs. newer molecules such as fluticasone propionate and mometasone furoate (Derendorf and Meltzer 2008). Systemic corticosteroids have significant side effects which can be observed after a few days of use. Due to these side effects and potential complications, the long-term use of systemic corticosteroids is not recommended in the management of CRS. (Campbell 2018). Side effects from short-term use include adrenal insufficiency, mood changes, gastric ulcerations, insomnia, hypertension, hyperglycaemia, and glaucoma. The complications of long-term corticosteroid use include osteoporosis/osteopenia, cataracts, growth retardation in children, cushingoid body

habitus, electrolyte changes, pancreatitis, small bowel perforation, skin changes and, rarely, avascular necrosis of the femoral head (Campbell 2018).

Intranasal corticosteroids

A Cochrane meta-analysis published in 2016 included 18 RCTs (2 738 patients) evaluating ICSs (beclomethasone dipropionate, triamcinolone acetonide, flunisolide, budesonide) vs. placebo or no treatment. Of these 18 RCTs, fourteen included CRSwNP patients and four included CRSsNP patients (Chong et al. 2016a). Most of the data available were from CRSwNP patients. Based on this meta-analysis, there seems to be improvement for all four EPOS 2012 (Fokkens et al. 2012) criteria symptoms, a moderate benefit for nasal blockage and a small benefit for rhinorrhea. However, there is little information about QoL, and the quality of this evidence is very low (Chong et al. 2016a).

Leopold D et al. evaluated a novel exhalation delivery system with fluticasone in patients with CRSwNP. In total, 323 adult patients with moderate to severe nasal polyposis, many of whom had previously been treated with conventional corticosteroid nasal sprays, surgery, or both, were randomized to use the exhalation delivery system twice a day with fluticasone (93, 186 or 372 μg) or placebo in it for 24 weeks. At the end of the double-blind period, patients who got fluticasone (all doses) produced clinically and statistically significant improvements in all four diagnostically defining disease symptoms, polyp grade and QoL in patients with CRSwNP. Also, the number of patients eligible for surgery decreased by between 62% and 67%. (Leopold et al. 2019)

Zhou B et al. performed a randomised, double-blind study in which they randomised 748 adult Chinese patients with CRSwNP to use either mometasone furoate (200 μg) nasal spray twice per day or placebo spray. Polyp size score, congestion/obstruction, anterior rhinorrhea and sense of smell scores all demonstrated statistically superior efficacy vs. placebo after 16 weeks. Serious adverse effects were rare (0.5% and 0.8% corticosteroid and placebo groups, respectively). There was significantly more epistaxis with corticosteroid spray vs. placebo spray. (Zhou et al. 2016)

A comprehensive international consensus statement recommended the use of ICS (sprays or drops) for CRSwNP before or after sinus surgery based on the benefits of symptom relief, polyp size, endoscopic appearance, QoL scores and olfaction metrics. The consensus statement also recommended that ICS should be used in the treatment of CRSsNP based on the benefits of improvements of

symptoms and endoscopic disease severity scores (Orlandi et al. 2016). There is not sufficient evidence to suggest that one type of ICS would be more efficacious than another in patients with CRS, nor that the effectiveness of a spray differs from that of an aerosol (Chong et al. 2016b).

Oral steroids

Eight RCTs (474 participants with CRSwNP) were included in a meta-analysis that compared oral corticosteroids with placebo or no intervention. Results were reported at the end of a short-course of oral steroids lasting for two to three weeks. Patients experienced improvements in QoL scores and symptom severity, although this benefit was diminished at three to six months after the end of the treatment period (Head et al. 2016a).

A recent prospective, randomised, placebo-controlled study by Shen K et al. evaluated the potential benefit of oral corticosteroids after ESS. In total, 100 patients (of whom only 82 completed the 6-month follow-up) with CRSwNP were randomised to receive either oral prednisolone (30 mg per day) or placebo for two weeks after surgery. Surgical outcomes were evaluated 1, 3, and 6 months postoperatively with the VAS, SNOT-22 and Lund-Kennedy endoscopic scores. Subjective outcomes showed no significant difference at any of the follow-up points. A trend of endoscopic scores improvement was noted at 6 months post-operatively. (Shen et al. 2019)

An evidence-based risk analysis of oral corticosteroid use in patients with CRSwNP was simulated using literature-reported complication rates, QoL changes and Medicare costs. Results demonstrated that risks of medical management exceed the risks of ESS when patients required oral steroids more frequently than once every 2 years in CRSwNP, once per year in CRSwNP/asthma or twice per year for Samters's triad patients (Leung et al. 2014).

These results support the recommendation of the international consensus statement which advocates using oral corticosteroids only in the short-term management of CRSwNP. Longer-term or frequent use of corticosteroids for CRSwNP is not supported by the literature and carries an increased risk of harm to the patient (Orlandi et al. 2016).

2.2.7.1.2 Antileukotrienes

Cysteinyl leukotrienes are a class of inflammatory mediators that play an important role in asthma, allergic rhinitis and CRSwNP. Indeed, the upregulation of the leukotriene pathway has been demonstrated in these diseases. Leukotrienes are produced through arachidonic acid metabolism by eosinophils and mast cells (Smith and Sautter 2014). Several leukotriene antagonists that act as competitive antagonists of the CysLT1 receptor have been developed. These drugs are commonly prescribed as adjunctive therapeutics for asthma and allergic rhinitis. However, there is paucity of evidence regarding the efficacy of leukotriene antagonist therapy for CRSwNP. A systemic review and metanalysis was performed to evaluate studies that assessed the effectiveness of leukotriene antagonist therapy in CRSwNP patients. Five RCTs, which included a total of 179 patients, were analysed. They concluded that leukotriene antagonist therapy is superior to placebo in improving symptoms of CRS, but when compared to ICS, there was no difference between the treatment modalities (Wentzel et al. 2013). The current guidelines suggest that leukotriene antagonist therapy is associated with limited benefit in the treatment of CRSwNP and montelukast is an option for CRSwNP patients either in place of or in addition to ICSs (Orlandi et al. 2016).

2.2.7.1.3 Antibiotics

The role of antibiotics in the treatment of CRS is unclear, and there is little evidence to support their use. The role of infection in CRS is poorly understood, and the only well-defined role for antibiotics is for the treatment of acute rhinosinusitis episodes or their infectious complications (Barshak and Durand 2017). In addition to the antibacterial properties against many gram-positive and gram-negative bacteria, macrolides have also immunomodulatory effects, which have been proven to be beneficial when treating chronic lung diseases, such as cystic fibrosis (Cai et al. 2011) and chronic obstructive pulmonary disease (Herath and Poole 2013). Due to the inflammatory aetiology of CRS, it is possible that macrolide antibiotics are also effective in the treatment of CRS.

There has been only one randomised, placebo-controlled study evaluating the use of short-course antibiotics compared with placebo in adults with CRS. The results of the study showed no effect on patient outcomes (Sabino et al. 2017)

A recent review on systemic antibiotics for CRS found only three studies comparing systemic antibiotics with placebo (Van Zele et al. 2010, Videler et al. 2011, Wallwork et al. 2006), one study comparing systemic antibiotics vs. ICSs (Zeng et al.

2011) and one study comparing systemic antibiotics vs. oral corticosteroids (Van Zele et al. 2010). They concluded that there is truly little evidence that systemic antibiotics are effective in the treatment of CRS. However, they also reported a moderate level evidence of a modest improvement in disease specific QoL in adults with CRSsNP receiving a three-month course of macrolide antibiotics. (Head et al. 2016b)

There are no data supporting the theory that topical antibacterial therapy would be more effective in improving symptoms in patients with CRS compared to placebo (Desrosiers and Salas-Prato 2001, Videler et al. 2008).

The current guideline concluded that macrolides are beneficial in patients with CRSsNP, when evaluated with endoscopic scores and some symptoms, especially in patients with low IgE levels. These effects seem to be comparable to ICS therapy, but the effect does not last long after stopping the medication. For patients with CRSwNP, macrolides seem to reduce polyps in patients after ESS and improve CRS symptoms. The guideline recommends low-dose macrolide antibiotics as a treatment option for CRS patients. Topical antibiotics are not, however, recommended (Orlandi et al. 2016).

2.2.7.1.4 Biologic pharmacologic treatments

In recent years, there has been a growing interest in biologic drugs targeting specific inflammatory pathways. In western countries, 85% of CRSwNP cases exhibit the type 2 inflammatory pattern with expression of IL-4, -5 and -13 as well as increased concentrations of IgE, whereas in CRSsNP these biomarkers are scantily expressed (Bachert et al. 2017a). CRSwNP shares a similar inflammatory profile with atopic diseases, such as asthma, atopic dermatitis, food allergy and urticaria.

Anti-immunoglobulin E therapy

Omalizumab is a recombinant humanised monoclonal antibody that binds with free circulating IgE, leading to lower expression of IgE on the effector cells and inhibition of these cells (Lam et al. 2016). Omalizumab has been on the market for the treatment of severe asthma for more than 10 years, and has been proven safe in daily use (Humbert et al. 2014). There have been controversial results from two placebo controlled RCTs evaluating the efficacy of omalizumab in patients with CRSwNP. The first RCT showed a clinically significant decrease in polyp size and effect on airway symptoms in CRSwNP patients with asthma. The second one found

no clinical benefits of using omalizumab in patients with CRSwNP. (Gevaert et al. 2013, Pinto et al. 2010).

Anti-interleukin-5 therapy

The majority of CRSwNP patients have significant tissue eosinophilia and IL-5 expression. IL-5 is a major regulator for eosinophil survival, growth, recruitment and activation (Smith et al. 2018). Mepolizumab is a humanised monoclonal antibody targeting IL-5.

In a randomised placebo-controlled study of 30 patients, Gevaert et al. showed a significant reduction in NP size without improvement in symptoms in CRSwNP patients with severe eosinophilia treated with mepolizumab. (Gevaert et al. 2011). A randomised, double-blind, placebo-controlled trial of 105 patients with recurrent CRSwNP requiring ESS was conducted. Intravenous mepolizumab treatment significantly reduced the need for surgery (30% vs. 10%), improved NP scores and increased QoL compared with placebo. The treatment with mepolizumab was as safe as placebo. (Bachert et al. 2017).

Anti-interleukin-4/-interleukin-13 therapy

IL-4 is the most potent cytokine inducing the differentiation from Th0 cells to Th2 cells, and it also plays a key role in polyp formation (Bachert and Holtappels 2015). Dupilumab is a human monoclonal antibody against the IL-4 receptor α subunit that inhibits both IL-4 and IL-13 signalling. Dupilumab has been previously approved for severe asthma and moderate-to-severe atopic dermatitis. Dupilumab therapy was associated with reduced frequency of asthma exacerbations by 87% compared to placebo in patients with moderate to severe asthma. (Wenzel et al. 2013).

LIBERTY NP SINUS-24 (276 participants) and LIBERTY NP SINUS-52 (448 participants) were two multinational, multicentre, randomised, double-blind, placebo-controlled, parallel-group studies evaluating the efficacy of dupilumab in adults with severe CRSwNP. In LIPERTY SINUS-24, subcutaneous dupilumab 300 mg was compared to placebo for 24 weeks. LIPERTY SINUS-52 randomised patients to receive dupilumab 300 mg every 2 weeks for 52 weeks, dupilumab every 2 weeks for 24 weeks and then every 4 weeks for the remaining 28 weeks, or placebo. Dupilumab significantly improved all the primary endpoints (NP score,

nasal congestion or obstruction, and LM CT score) in both studies. Surprisingly, the placebo group had more adverse events than the study group. (Bachert et al. 2019).

A randomised, double-blind, placebo controlled, multinational trial in 60 adult patients with refractory CRSwNP was conducted to evaluate the efficacy of dupilumab. Subcutaneous dupilumab 300 mg (30 patients) or placebo (30 patients) was injected weekly for 16 weeks. Both study groups used ICS spray therapy during the treatment period. Subcutaneous dupilumab significantly reduced the endoscopic NP burden compared to placebo. Secondary outcomes also showed benefits for dupilumab therapy that included significant improvements in QoL, LM scores, olfaction, and in major symptoms. (Bachert et al. 2016b)

A recent Cochrane meta-analysis concluded that dupilumab improves QoL and reduces the NP burden in CRSwNP patients compared to placebo. It probably improves their symptoms, and they do not have more serious adverse events than those taking placebo. (Chong, Lee-Yee et al. 2020). Based on these results, dupilumab is the only biologic to have been approved by The US Food and Drug Administration (FDA) and the European Union for the treatment of CRSwNP.

2.2.7.1.5 Saline nasal irrigations

Multiple studies have demonstrated that saline irrigations reduce symptoms and improve the endoscopic and radiologic outcomes and QoL in patients with CRS (Casale et al. 2018, Chong et al. 2016c, Harvey et al. 2007). Low-pressure, high-volume isotonic saline irrigation has been proven superior to isotonic nasal spray in reducing sinonasal symptoms (Wormald et al. 2004). In their meta-analysis, Casale M et al. identified 11 studies involving 663 patients. Only a few studies, characterised by small patient populations, short observation periods and different clinical and diagnostic parameters, have been published on the subject. By analysing these studies, they found no clear consensus concerning the frequency and duration of treatment, the type of device, and the amount of solution to be used when treating CRS. Hypertonic saline seemed to be associated with better results in symptom scores and MCC than isotonic saline. (Casale et al. 2018). A systematic review and meta-analysis by Kanjawasee D et al. concluded that hypertonic solution was better than isotonic solution in improving symptoms in the treatment of sinonasal diseases. There was no difference in disease specific QoL, but hypertonic saline had more minor adverse events compared to isotonic saline. (Kanjanawasee et al. 2018). According to the current guideline, high-volume (>200 ml) nasal saline irrigations are strongly recommended as an adjunct to medical therapies. (Orlandi et al. 2016).

2.2.7.2 Surgical treatment

2.2.7.2.1 Endoscopic sinus surgery

There is an international consensus that ESS should be reserved for CRS patients who have failed initial, adequate medical treatment (Orlandi et al. 2016, Fokkens et al. 2012). Sinus surgery techniques have evolved over the past decades from open surgery to ESS, and nowadays to more mini-invasive techniques, such as balloon dilation. Sinus surgery involves the removal of the affected inflammatory tissue and the opening of the sinus ostia. The surgery is thought to improve the sinus ventilation, restore the MCC, decrease the inflammatory burden and help the delivery of topical drug delivery and sinus saline lavage postoperatively.

In a recently published meta-analysis evaluating the effectiveness of ESS in patients with CRS, the Cochrane collaboration found only three RCTs which met the inclusion criteria. The evidence obtained from these three studies does not, however, show any evidence that ESS would be better than either medical treatment or an inferior meatal antrostomy (Khalil and Nunez 2006). Blomqvist et. al randomised 32 CRSwNP patients to undergo unilateral ESS after pre-treatment with oral prednisolone for ten days and ICS spray bilaterally for 1 month. The ICS therapy continued postoperatively for one year. After the one-year study period, significant improvements were found on the operated side in the CT total scores compared with the medical treatment only. A significant association was also found between the differences in olfactory thresholds between the operated and unoperated sides (Blomqvist et al. 2009). Another study by Alobid et al. randomised 109 CRSwNP patients to receive either 2 weeks of oral prednisolone or to undergo ESS. All patients used ICSs for 1 year. QoL, nasal symptoms and polyp size were evaluated at 6 and 12 months. A significant improvement in all study parameters was found in both groups. However, polyp size was found to be smaller in the surgical group (Alobid et al. 2005).

Although there have been very few RCTs on surgery for CRS, there have been many well-designed cohort and case-control studies. Forty-two publications published between 1978 and 2005 were included from 632 articles initially analysed in the systematic review. Of these, between 78% and 88% of patients evaluated their symptoms to be improved after ESS. Based on the findings of these studies, major complications are relatively rare (0-1.5%), but especially case series studies showed a wide variation in incidence of mild complications (0.3-22.4%) (Dalziel et al. 2006). The National Comparative Audit of Surgery for Nasal Polyposis and CRS was a large, prospective cohort study covering 87 hospitals in England and Wales. In the

study, 3 128 CRS patients undergoing ESS were prospectively enrolled and followed at 3, 12, and 36 months post-operatively. A large, clinically significant improvement in SNOT-22 scores from the pre-operative period (mean = 42.0) to 3 months after surgery (mean = 25.5) was found. The results were similar at each timepoint studied. At three months after operation, 85% of patients felt their symptoms had been relieved. At all timepoints, CRSwNP patients reported greater symptom improvements after surgery than those with CRSsNP. At 12 months, 3.6% of patients and at 36 months 11.8% had undergone revision surgery. Minor intraoperatively adverse events were recorded for 6.6% of operations, and excessive bleeding (5%) was the most reported adverse event. Only seven intraorbital (0.2%) and two intracranial (0.06%) complications occurred. (Hopkins et al. 2006). Smith et al. prospectively evaluated 180 adult CRS patients who had failed initial medical management and were candidates for ESS. Patients were either offered the choice of continuing their ongoing medical therapy or to undergo ESS coupled with ongoing medical therapy. Of the 180 patients, 81 patients originally chose the medical treatment option and 99 ESS. At the 1-year endpoint, 115 patients were left in the study, 50 in the medical treatment group and 65 in the ESS group. Patients who underwent ESS had significantly better QoL scores compared to patients managed by medication alone (Smith et al. 2013). These studies confirm that ESS is a generally safe and effective treatment for patients with CRS.

A meta-analysis was performed to determine the mean change in SNOT-22 scores in CRS patients who had undergone ESS. A total of 40 from the 420 studies published 2008-2016 were accepted for analysis. Studies evaluating QoL outcomes showed significant improvement after ESS. The mean change in postoperative SNOT-22 scores across all studies was 24.4 points (Soler et al. 2018).

2.2.7.2.2 Image-guided navigation assisted surgery

Image guided surgery (IGS) systems have been developed to help surgeons localise anatomical structures intraoperatively. These systems enable the tracking of surgical instruments and the calculation of the position of the instrument's tip inside a preoperatively generated imaging volume in relation to live patient anatomy in real time. The position of the instrument is displayed on the screen of a 3D imaging workstation.

Different kinds of tracking techniques can be employed; the two most common are the optical and electromagnetic tracking systems. Optical systems are based on infrared light tracking the location of the surgical instrument by camera, whereas the electromagnetic system tracks the specific surgical instrument in the electromagnetic

field. The main disadvantages of these techniques are due to the principle of guidance the system employs. In optical systems, it is the need for a direct line of sight from camera to the patient and surgical instruments. In electromagnetic systems, the main disadvantage is the potential disturbance in the electromagnetic field caused by metallic objects.

In ESS, this technology helps to identify the critical structures, such as orbit, optic nerve, skull base and the carotid artery, surrounding the paranasal sinuses and potentially aids in decreasing complications. Due to the low baseline complication rate in ESS, most studies on the usefulness of IGS in ESS have lacked the power to identify a statistically significant effect. Another problem with studies comparing the complication rates is that IGS is often used in more complicated surgery, leading to selection bias. In a systematic review and meta-analysis, Vredenburg et al. included nine studies comparing ESS with and without IGS in patients undergoing complex sinus surgery. The meta-analysis of primary studies showed a decreased likelihood of total, major, and orbital complications in complex ESS performed with IGS (Vreugdenburg et al. 2016). Dalgorf et al. analysed 14 comparative cohort studies and found similar results. They concluded that the navigation assisted ESS in selected populations is associated with a lower risk of major and total complications compared with non-IGS sinus surgery (Dalgorf et al. 2013).

Only a small number of studies have evaluated IGS with respect to training and human factor issues. Manzey et al. conducted a nationwide survey of 213 surgeons in 112 German hospitals to assess the perceived performance change and human factors issues related to IGS. Surgeons reported improved performance and patient safety in relation to the use of IGS. However, they emphasised the allocation of a sufficient amount of time and training during the familiarisation period to the technique (Manzey et al. 2009). In a prospective, observational study of 311 patients operated on by 36 surgeons in 16 French hospitals, the use of a surgical navigation system increased the extent of surgery in 81% and had a positive impact on the stress perceived by surgeons in 95% of cases (Vicaut et al. 2019). Theodoraki et al. evaluated stress levels during ESS with and without the aid of navigation system at an early stage in ESS training. Eight surgeons in training and 32 CRS patients were included. After randomisation, one side was operated with IGS and the other side without. During the surgery, the surgeons were monitored by a biofeedback device measuring heart rate, heart variability, respiratory frequency, and masticator EMG. They also reported that the overall mental load of young surgeons in ESS is enormous. The use of IGS did not cause a higher stress level. However, in a

subgroup of residents who had performed more than 30 ESS procedures, IGS was associated with a slightly decreased mental workload (Theodoraki et al. 2015).

It has been proposed that IGS is not necessary for basic sinus surgeries (Dalgorf et al. 2013). However, a position statement of the American Academy of Otolaryngology & Head and Neck Surgery recommends the use of IGS for ESS in more complex surgeries, such as revision sinus surgery; in cases with distorted anatomy; extensive polyposis; diseases concerning the skull base, orbit, optic nerve or carotid artery; CSF rhinorrhea or skull base defects; benign and malignant tumours, and pathology involving the frontal, posterior ethmoid or sphenoid sinus (American Academy of Otolaryngology—Head and Neck Surgery 2012).

2.2.7.2.3 Balloon sinuplasty

Balloon sinuplasty (BSP) was first introduced in 2005 as a mini-invasive technique for the dilation of the ostia of the paranasal sinuses. The method can be used to dilate the maxillary, frontal and sphenoidal ostia. The technique involves the placement of a balloon catheter under transillumination or navigation into the sinus ostium. Inflation of the balloon then results in dilatation of the sinus ostium while preserving the normal anatomy and epithelial mucosa surrounding the ostium area.

Since the first preliminary studies regarding the safety and feasibility of BSP in 2006 (Bolger and Vaughan 2006, Brown and Bolger 2006), four prospective RCTs on the efficacy of BSP have been published. All four studies evaluated the change in 20 item Sinonasal Outcome Test (SNOT-20) or SNOT-22 scores following BSP vs. ESS in the treatment of CRS. In three of those studies patients underwent maxillary sinus ostium dilatation and in the study by Minni et al. the frontal sinus ostia were enlarged. Both groups significantly benefitted from the treatments, without a significant difference between the groups. (Achar et al. 2012, Bikhazi et al. 2014, Bizaki et al. 2014, Minni et al. 2018a)

A meta-analysis by Levy JM et al. concluded that the evidence on the role of BSP in CRS is currently incomplete. Improvements in QoL and LM CT scores have been reported in a limited adult population with CRS. The authors also emphasised that the extensive exclusion criteria in the current literature confine evaluation to a subgroup of CRS patients with limited disease, and the majority of studies are affected by potential conflict of interest and inherent bias (Levy et al. 2016).

A recent review article by Cingi C et al. concerning the current indications for BSP stated that BSP is a safe and effective treatment option for patients with CRSsNP and recurrent acute rhinosinusitis who are unresponsive to other treatment. The available evidence best supports treating disorders of the frontal, sphenoid and

maxillary sinuses with limited disease severity. BSP is not, however, recommend in patients with NPs or advanced ethmoidal disease or patients with headache that do not meet the diagnostic criteria for CRS or patients who do not have positive findings of sinus disease on both CT and based on sinonasal symptoms (Cingi et al. 2019).

2.2.7.2.4 Drug-eluting stents/implants

A stent is a device that is placed into a cavity temporarily to keep it open, promote wound healing, and relieve an obstruction. However, the FDA defines an implant as a device that can be placed into a naturally or surgically formed cavity of the human body and remain there for a period of 30 days or more (Parikh et al. 2014). Drug-eluting stents (DES) or implants are surgically inserted devices that facilitate healing of the affected tissue by releasing a loaded drug locally and continuously in a controlled manner for a desired period of time (Parikh et al. 2014). The complexity of the sinus anatomy and the mucosal oedema of CRS patients, however, cause major problems in drug delivery to the affected paranasal sinus mucosa (Snidvongs et al. 2008). In contrast, DESs allow a continuous, long-lasting drug release directly inside the diseased paranasal sinuses.

2.2.7.2.5 Stents for un-operated patients

Young L et.al showed that about half of the CRS patients failed adequate medical therapy and were offered surgery (Young et al. 2012). However, many patients chose not to be operated or were deemed unfit for surgery. For these CRS patients, there are few treatment options left. The Relieva Stratus or LYR-210, a novel biodegradable steroid drug delivery system, is one of them.

Relieva Stratus™ MicroFlow Spacer

The Relieva Stratus™ Micro-flow Spacer (Relieva Stratus; Acclarent Inc. California, USA) was introduced in 2009 (Catalano et al. 2009) for the minimally invasive treatment of chronic ethmoid mucosal disease. It is a method for delivering glucocorticoids directly to affected paranasal sinuses. The system was first developed for the treatment of ethmoidal sinuses in a preoperative setting, but it has also been used for the treatment of frontal disease. The triamcinolone acetonide solution (40 mg/ml) filled stent is temporarily implanted into the ethmoids under endoscopic view by using a trocar-based deployment guide. A total amount of 24 mg of solution

will leak out of the spores of the stent during a four-week period. After four weeks, the device is easily removed in an office setting.

A cadaveric study demonstrated that insertion of the Relieva Stratus into the ethmoidal sinus using fluoroscopy is relatively safe and easy to perform in the hands of a trained otolaryngologist. In the study, a DES was inserted into 12 ethmoidal cavities without injuring the orbit wall, skull base or sphenoid face. (Melroy and Kuhn 2009)

In an initial report, Catalano et al. evaluated the short-term outcomes and safety of the Relieva Stratus infused with triamcinolone acetonide. This was a prospective study of 23 patients with a total of 40 ethmoid sinuses implanted with a DES under endoscopic and fluoroscopic view. Patients were followed for six months. The authors reported that the Relieva Stratus was a safe and effective method of treatment for chronic ethmoid sinus disease. Outcomes were evaluated by observing changes in the SNOT-20 and LM CT scores. The mean SNOT-20 score improvement was 1.16 points ($p<0.001$). The ethmoid-specific (0.83, $p<0.001$) and the side-specific (2.80, $p<0.001$) mean score improvements of LM scores were also statistically significant. (Catalano et al. 2011)

In a prospective, randomised clinical study, Businco DR et.al. compared the efficacy and safety of the DES in allergic CRS patients to endoscopic ethmoidectomy. Seventy consecutive adult allergic patients with CRS were randomly divided into two groups to receive either a triamcinolone filled DES or ethmoidectomy. All patients had CRS according to EPOS 2007 and had completely opacified ethmoidal cavities (LM-score 4) in CT. There were no differences between the groups in the baseline data. In addition to ethmoidectomy, some patients were also operated with uncinectomy (21 patients, 10 in the DES group and 11 in the ethmoidectomy group) and dilatation of the frontal recess with balloon sinuplasty (16 patients, 9 in the DES group and 7 in the ethmoidectomy group). The evaluation of the patients was performed at the beginning and at the end of follow-up (after one year) by means of nasal endoscopy evaluated with the LM Endoscopic Appearance Score parameters; VAS for the subjective evaluation of the symptoms; SNOT-22 (5 most important items); rhinomanometry and paranasal sinus CT. No patients dropped out or were lost to follow-up. The most significant result was the substantial equivalence of the treatments. According to the reduction in VAS score and SNOT-22 score, both groups benefited from the treatments. Moreover, there were no differences between the groups in LM-scores. As one might expect, the endoscopic scores (discharge, scarring and crusting) were significantly worse in the ethmoidectomy group. The functional results in rhinomanometry were significantly

better in the DES group. The authors concluded that DES was efficacious when treating allergic CRS patients with ethmoidal involvement when conventional medical treatment has failed or when wishing to avoid the classic ethmoidectomy. (Businco et al. 2016)

Minni A et al. evaluated the efficacy and safety of BSP and DES (Relieva Stratus) in the management of CRS of the frontal sinus. This was a multicentre retrospective study of 54 adult patients (76 frontal sinuses) with CRSsNP. In the study, 41 frontal sinuses were treated with BSP alone and 35 with BSP + DES. The authors analysed both radiological and QoL results before operation and after 12 months. The SNOT-20 scores and LM-scores were reduced significantly in both groups without any significant difference between the groups. No patients were lost to the 12-month follow-up. In the BSP group, 37 frontal sinuses out of 41 (90.2%) and 31 frontal sinuses out of 35 (88.6%) in the BSP + DES group seemed patent at the one-year endoscopic evaluation. Their results confirmed the good safety and effectiveness of BSP in the management of frontal CRS. The use of BSP + DES was safe but did not have additional benefits compared to BSP alone. (Minni et al. 2018b)

In the literature, only a few complications involving the Relieva Stratus have been published. In one case, the device had been erroneously placed through the lamina papyracea into the orbit. Despite the removal of the device, the pupil of the affected eye remained dilated (Villari et al. 2012). In another case, the removal of the device after 4 weeks was forgotten, causing a worsening of CRS symptoms and facial pain. When the DES was finally removed at 7 months, chronic extensive inflammation with more local granulation tissue surrounding the device was found. The foreign body was removed without any complications or long-lasting adverse events (Sjogren et al. 2013). The FDA has reported one skull base injury caused by the insertion of the Relieva Stratus deployment guide through the posterior ethmoidal roof. The resultant cerebrospinal fluid leak was detected and treated without further complications (U.S. Food and Drug Administration 2010).

LYR-210

LYR-210 (Lyra Therapeutics, Watertown, MA, USA) is a biodegradable intranasal DES specifically designed to treat un-operated CRS patients who have failed medical management. The system contains mometasone furoate (2500 μg) with a polymeric matrix that releases mometasone furoate continuously at a constant dose over 24 weeks. The LYR-210 is inserted inside an intact middle meatus under endoscopic

guidance and topical anaesthesia during a routine physician visit. (Douglas et al. 2019)

LYR-210 is a novel device and still under phase 1 clinical trials. Safety and the early efficacy of the implant were evaluated in 20 patients with CRS who were candidates for ESS. No local serious product-related side effects were found. Furthermore, there was no evidence of systemic adverse events either. Serum cortisol, intraocular pressure and plasma drug concentrations were normal at all the time points tested. The SNOT-22 scores showed a significant improvement as early as week 1, and this significant improvement lasted for the whole 24-week trial period. The investigators concluded that insertion of LYR-210 is safe in an office setting, has an acceptable safety profile, and initial data suggest fast-acting and long-lasting symptom improvement during the 24-week treatment period. (Douglas et al. 2019)

2.2.7.2.6 Stents for post-operative care

The main findings in revision surgery performed as a result of suboptimal postoperative results after ESS are recurrent mucosal disease and polyposis, synechiae and neo-osteogenesis formation, lateralised middle turbinate and stenosis of sinus ostia. (Otto and DelGaudio 2010). Techniques to prevent these complications include topical and systemic steroids, nasal saline irrigations and postoperative debridement (Rudmik et al. 2011b). Systemic steroids are effective but have side effects. Post-operative topical corticosteroids have been proven to improve wound healing in addition to efficiently decreasing granulation formation and stroma thickness (Beule et al. 2008). However, the delivery of topical corticosteroids inside the operated sinuses and ensuring the drug is in contact with the mucosa has been proven difficult. With the DESs, it is possible to have a localised, continuous drug release directly to the diseased sinus mucosa with minimal side effects.

Propel®

The Propel® steroid-releasing implant (Intersect ENT, Palo Alto, California, USA) is a bioabsorbable stent containing a total of 370 μg of mometasone furoate. This spring-like implant, which dissolves in approximately 30 days, maintains the surgical opening after ethmoidectomy and delivers corticosteroid directly to the sinus mucosa. The stent is inserted inside of the middle meatus and the operated ethmoidal

cavity after ESS. It was developed to improve the results of surgery by decreasing postoperative inflammation, polyposis, synechia and middle turbinate lateralisation.

The efficacy and safety of the Propel® implant have been studied in three clinical trials. In a double-blind, multicentre RCT pilot study, Murr et al. compared the Propel® implant with a non-drug-eluting implant in 38 CRS patients. Implants were deployed in 76 ethmoid sinuses after ESS using an intrapatient control design. Compared to the placebo stent, the DES with mometasone furoate demonstrated a statistically significant reduction in inflammation at days 21 to 45 ($p<0.003$), the frequency of polyp formation ($p=0.0391$) and the frequency of significant adhesion ($p=0.0313$) (Murr et al. 2011).

Forwith et al. conducted a prospective, multicentre, single-cohort study enrolling 50 CRS patients undergoing ESS. Propel® implants were successfully inserted in 90 operated ethmoidal cavities. The endoscopic follow-up was performed at 60 days, and safety was assessed with ocular exams at baseline and at 30 days. Patients who received the Propel® implant showed a significant improvement in symptoms and QoL measured with SNOT-22 score at 6 months. The Propel® implant also significantly reduced the occurrence of inflammation, synechia's and polyp formation at 60 days. There was no evidence of ocular risk in safety assessment at 30 days. (Forwith et al. 2011)

The third, larger study was a double-blind, multicentre, intrapatient-controlled RCT with 105 CRS patients (210 sinuses) undergoing ESS. The aim of the trial was to compare the effect of a mometasone-releasing implant with a non-drug-releasing implant. The efficacy of the implant was determined by three surgeons from video-endoscopies. The primary endpoint was the need for postoperative interventions. The Propel® implant provided a 29.0% relative reduction in postoperative interventions ($p=0.028$), a 52% ($p=0.005$) reduction in adhesions and a 44.9% reduction in polyp formation ($p=0.002$) compared to the placebo implant. (Marple et al. 2012).

Based on these three trials, there is an evidence that The Propel® steroid-releasing implant is efficient in improving surgical outcomes without observable ocular safety risk.

An RCT evaluated the efficacy and safety of the Propel® implant inserted in the frontal sinus ostia after ESS in 80 patients with CRS. Using intrapatient control design, bilateral frontal sinusotomies were performed with one frontal sinus side randomised to receive a DES. At day 30, the need for postoperative interventions was significantly reduced in the frontal sinus side treated with the Propel® implant (11.5%) compared to the side treated with surgery only (32.8%), as evaluated by

clinical investigator and independent reviewer. In addition, a significant reduction in inflammation score and rate of frontal restenosis was found favouring the side treated with DES. The results favouring the DES continued were sustained through to day 90. No DES-related side effects were reported. (Luong et al. 2018)

Rudmik L et.al evaluated the cost-effectiveness of the Propel® implant compared to a non-drug-eluting sinus implant following ESS in patients with CRS. The results from this economic evaluation proposed that the insertion of the Propel® Sinus Implant into the ethmoid cavity following ESS for refractory CRS is a cost-effective intervention for preventing reintervention within 60 days after surgery. (Rudmik and Smith 2014b)

Sinuband FP®

Sinuband FP® (BioInspire Technologies, Palo Alto California, USA) is a bioabsorbable DES containing a total of 160 μg fluticasone propionate. It is a 2 cm × 2 cm thin film designed to be inserted directly on the operated walls of the ethmoidal cavity to enhance the acceleration of wound healing and recovery.

A partially double-blind RCT using an intrapatient study design to evaluate the efficacy and safety of the novel DES in patients with CRS was performed. Thirty patients were randomised to receive 2 of 3 treatments – SinuBand FP®, SinuBand® [without fluticasone propionate] or standard nasal pack [Merocel®]). SinuBand FP® showed local safety, no change in intraocular pressure and no significant change in 24-hour urine cortisol. SinuBand FP® was proven superior when assessing the polyp score compared to Merocel® ($p=0.03$) but not when compared to SinuBand® ($p=0.97$). Regarding inflammation, SinuBand FP® was slightly better than the other 2 treatments. However, the difference between the groups was non-significant. There were no significant differences between the groups in adhesion formation or Lund-Kennedy scores. The conclusion was that the use of SinuBand FP® is safe and showed evidence of efficacy. (Adriaensen et al. 2017)

Sinuva®

There are only limited treatment options left for patients with recalcitrant, recurrent nasal polyposis after ESS. The Sinuva® Sinus Implant by Intersect ENT (Menlo Park, CA, USA) is a novel, FDA approved, bioabsorbable, steroid-eluting implant that is designed to treat CRSwNP patients who have already had ESS. The implant

has a self-expanding, non-obstructive design and is composed of a biodegradable polymer matrix that contains a total of 1 350 µg of mometasone furoate. Furthermore, it provides a stable release of the drug over a period of 3 months. This implant can be inserted into the operated ethmoidal sinus cavity under local anaesthesia in an office setting (Lavigne et al. 2014).

There have been two well designed studies concerning the efficacy and safety of the Sinuva Sinus® Implant. The first of them was a blinded RCT including 100 CRSwNP patients with refractory to medical therapy and considered candidates for revision ESS. The patients were randomised either to undergo in-office bilateral stent placements (n=53) or have a sham operation (n=47). At three months, the patients treated with an implant had a significant reduction in bilateral polyp grade and ethmoid sinus obstruction. In addition, they also experienced a 2-fold improvement in the mean nasal obstruction/congestion score compared to controls. At three months, 53% of the treated patients compared to only 23% of controls no longer had indication for repeat ESS (Han et al. 2014). The results of the same study material were evaluated at 6 months in the study by Forwith K et al. The efficacy of the Sinuva Sinus® implant was found to sustain through 6 months evaluated with the same instruments used in the previously study. At 6 months, patients in the sham operation group had a 3.6 times higher risk of undergoing ESS compared to the patients treated with an implant (Forwith et al. 2016).

The second study was a prospective, double-blind, placebo controlled RCT including 300 adult patients with refractory CRSwNP who were candidates for revision surgery. Those patients randomised to the treatment group (n=201) underwent an in-office bilateral placement of two Sinuva® implants. The control group (n=99) underwent a sham operation. The subjective primary endpoint was the change in nasal obstructive/congestion score evaluated at day 30. The bilateral polyp grade, evaluated by an independent blinded panel, was used as an objective primary endpoint at day 90. Significant improvements were found in both primary endpoints favouring the treatment group. At day 90, the patients treated with implants also had a greater decrease in ethmoid sinus obstruction and had better symptom improvements in nasal obstruction/congestion and sense of smell, but not in facial pain/pressure. Also, the need for surgery was reduced by 61% in patients treated with implants. (Kern et al. 2018) The results of these two studies show the efficacy and safety of the Sinuva® Sinus Implant in patients with CRSwNP after ESS

In a recent meta-analysis, Goshtasbi K et.al conducted a systematic literature search to determinate the efficacy of DES in the management of CRS after ESS. Seven articles from 76 published studies were included in the meta-analysis. A total

of 444 DES and 444 control sinuses were evaluated as a collective cohort. Collective ORs were 0.45 ($p<0.001$) for postoperative need for intervention, 0.30 ($p<0.001$) for surgery and 0.58 ($p<0.001$) for use of oral steroids in patients treated with DES compared to controls. In addition, collective ORs for frontal sinus ostia patency, moderate-to-severe adhesion/scarring and increase in polyp score were 2.53 ($p<0.001$), 0.28 ($p<0.001$) and 0.42 ($p=0.002$), respectively. This evidence suggest that a DES can improve ESS outcomes by reducing rates of postoperative intervention and recurrent polyposis and inflammation, while at the same time promoting frontal sinus ostia patency. All the included and analysed studies were industry-sponsored, so ruling out publication bias was not possible. (Goshtasbi et al. 2019)

2.2.7.2.7 Other stents and the steroid-filled nasal packings

Various biodegradable or nondegradable materials have been used in postoperative nasal packing to prevent the need for revision surgery. There is, however, a lack of consensus regarding the optimal perioperative nasal packing regimen (Berlucchi et al. 2009, Verim et al. 2014). Recent studies have shown additional efficacy when the biodegradable materials have been filled or soaked with a corticosteroid elution.

Chitosan-dextran gel has been shown to be an effective postoperative absorbable nasal dressing. It also has haemostatic properties and improves wound healing and enhances sinus ostial patency (Ngoc Ha et al. 2013, Valentine et al. 2010). Chitosan is a chitin-based polymer that is found naturally in crustaceans.

The aim of a blinded RCT was to evaluate the effect of adding budesonide solution to chitosan-dextran gel on postoperative ostial stenosis and adhesion formation in CRSwNP patient after ESS. In total, 36 adults were randomised to receive either no treatment, chitosan-dextran gel, chitosan-dextran gel with 1 mg/2 ml budesonide or topical steroid cream to their left or right sinuses. All patients had bilateral total sphenoethmoidectomy with frontal recess clearance. Endoscopic features of wound healing and each sinus ostium were evaluated during the operation and at 2 weeks, 3 months and 12 months post operation. A significant reduction in stenosis within all 3 sinus ostia sites was identified when using chitosan-dextran gel + budesonide compared to the control group. The adhesion formation was significantly smaller in the chitosan-dextran gel + budesonide group (4%) compared to the control group (15%). The anti-stenotic effect continued in the frontal ostium at 12 months in the chitosan-dextran gel + budesonide group compared to the chitosan-dextran gel group. This study showed that chitosan-dextran gel, when

combined with corticosteroid solution, improves long-term sinus ostial patency and prevents adhesions. (Ha et al. 2018)

In a double-blinded RCT, Xu J et.al evaluated the effects of a triamcinolone-soaked biodegradable nasal dressing (Nasopore®) on subjective symptoms, wound healing and improvement of olfactory dysfunction in CRSwNP patients after ESS. Eighty patients were randomised to either have a normal saline-soaked (2 ml) nasal dressing or a triamcinolone impregnated (2 ml of a 10 mg/ml) dressing after surgery. SNOT-20 and the Korean version of the olfactory test, Sniffin´Stick and Perioperative Sinus Endoscopy Score (POSE) were used at 1 and 3 months to assess the patients. The nasal dressing soaked with corticosteroid solution showed a significant advantage over the saline-soaked dressing with regard to postoperative wound healing and improvement of olfactory function, but not to the subjective symptoms. (Xu et al. 2016)

3 AIMS OF THE STUDY

1. To set up an image-guided, navigation assisted DES insertion technique and to evaluate whether IGS-assisted DES insertion into the ethmoid sinus would prove to be more useful than fluoroscopic guidance (I)

2. To compare the efficacy of the DES for the ethmoid sinus to ICS spray therapy in patients with chronic ethmoiditis (II)

3. To evaluate the safety of the insertion of the DES and the adverse effects after stent application and to evaluate the intra- and postoperative safety of the DES (II)

4. To evaluate whether a DES implanted in the ethmoid sinuses can prevent sinus surgery better than ICS spray therapy (III)

4 MATERIAL AND METHODS

4.1 Patient selection

A prospective, randomised, clinical study was carried out at the Department of Otorhinolaryngology - Head and Neck Surgery at Tampere University Hospital, Finland over a 42-month period starting from December 2010 and ending in June 2014. All the recruited patients were referred from primary care clinics. A total of 63 consecutive adult with chronic ethmoiditis were enrolled in this study. To be included in this study, patients had to be diagnosed with CRS as outlined by the EPOS 2007 (Fokkens et al. 2007), had to have been treated for at least three months with topical ICSs without a satisfactory result and they had to be over 18 and under 65 years of age. CBCT imaging (Planmeca Max, Planmeca, Helsinki, Finland) was performed for each patient before the study to confirm CRS of the ethmoid sinuses, and LM-score had to be at least 2 for the ethmoid sinuses. Patients had to fulfil the indications for sinus surgery according to current Finnish national guidelines (Duodecim and the Finnish association of otorhinolaryngology and head and neck surgery 2018). Patients with previous sinus operations, AERD, diabetes or any other severe systemic disease, and glaucoma were excluded. In addition, patients who were pregnant upon enrolment to the study, who had LM-score of more than 1 in the maxillary, frontal or sphenoid sinus, who had a distance from the face of the ethmoid bulla to the face of the sphenoid sinus of less than 20 mm or who had severe polyposis (polyps growing beyond the medial meatus according to an endoscopic view) were not eligible for this study. Patients did not receive any financial compensation for their participation in this study.

4.2 Randomisation

Patients were randomised either into the DES group or the ICS spray group using Minim, a free MS-DOS program (a program for randomisation in clinical trials) that does allocation by minimisation and runs interactively throughout the study. Groups

were randomised with the following parameters: age, sex, asthma, nasal polyposis and use of tobacco.

4.3 Study protocol

The study protocol included four to five study visits (Figure 1). The first visit was an enrolment and randomisation visit, during which informed consent and patient history were obtained, direct nasal endoscopy was performed and CBCT scans were evaluated. From this point began a four-week wash-out period. Patients were forbidden from using any medication containing corticosteroids. Any other medication to treat the symptoms of CRS was allowed (no one used long-term, low-dose macrolide antibiotic drugs). At the beginning of the study, patients were informed that participation in the study did not rule out surgery after the end of study period. At the next visit, both groups were evaluated using SNOT-22, VAS, rhinomanometry, acoustic rhinometry and direct nasal endoscopy. In the DES group, all the patients underwent bilateral stent placement under general anaesthesia. Patients in the nasal spray group were instructed on the optimal way to administer the drug, and they were informed that the nasal spray dosers would be weighed at every visit to verify that the drug was being used as instructed. Any other drugs containing corticosteroids were forbidden in both groups for as long as the prospective part of the trial continued. The DES was removed after four weeks at an outpatient clinic under local anaesthesia. Follow-up visits were scheduled at three and six months after treatment, and the patients were again evaluated using SNOT-22, VAS, rhinomanometry, acoustic rhinometry and direct nasal endoscopy. The use of antibiotics was documented, and an additional sinus CBCT scan was taken at six months after treatment. Patients were regularly followed up for any adverse effects.

After six months, patients were asked about the severity of their symptoms and whether they felt they still needed surgery. The final decision to operate was based on the level of subjective relief of their symptoms and findings in CBCT images. Those patients who needed surgery were operated on within one month. Only one doctor (RT) conducted the follow-up visits to ensure that the evaluation of the severity of the symptoms was as uniform as possible. The extent of the surgery was based on the CBCT findings and the symptoms of the patients.

After the prospective part of the study, all patients, including those who ended up undergoing ESS or who were randomised to the DES group, were instructed in

the optimal way to administer the ICS spray. In addition, they were also encouraged to use the nasal spray regularly to treat their CRS.

In order to evaluate the long-term effect of the DES in comparison with the nasal spray in terms of the prevention of ESS (III), patient records were retrospectively reviewed and a letter was sent to patients to inquire whether ESS had been performed within a period of 30 months after the end of the prospective part of the study. The data were obtained retrospectively, but the study groups had been prospectively randomised, as described above.

The manufacturer of the Relieva Stratus recommends the stent to be inserted into the ethmoidal sinus complex using an endoscopic view with the aid of fluoroscopy. We wanted to set up a technique based on an IGS-assisted insertion. The first 26 consecutive patients who underwent DES placement into their ethmoidal sinuses formed the study group (I). The first 13 patients (26 sinuses) were implanted with the DES using fluoroscopy and the next 13 patients (26 sinuses) underwent IGS-assisted DES insertion.

All clinical examinations and operations were performed by the same doctor (RT).

Figure 1. Schedule and protocol of patient visits.

4.4 Demographic and baseline data (I-III)

A total of 63 patients were enrolled in the study and were randomised into the DES group (n=34) and nasal spray group (n=29). The first two DES patients were excluded because the reservoir of the stent contained too little corticosteroid

solution. Four patients in the DES group were lost to follow-up (one patient had severe CRS symptoms and was operated on immediately after the removal of the stent, one patient was obliged to use another corticosteroid drug because of another unrelated disease, one patient dropped out having been diagnosed with an unrelated serious disease and one patient dropped out for personal reasons). Finally, 57 patients (18 males and 39 females) were included in the analysis, 28 to the DES group and 29 to the control group treated with the ICS spray (Figure 2).

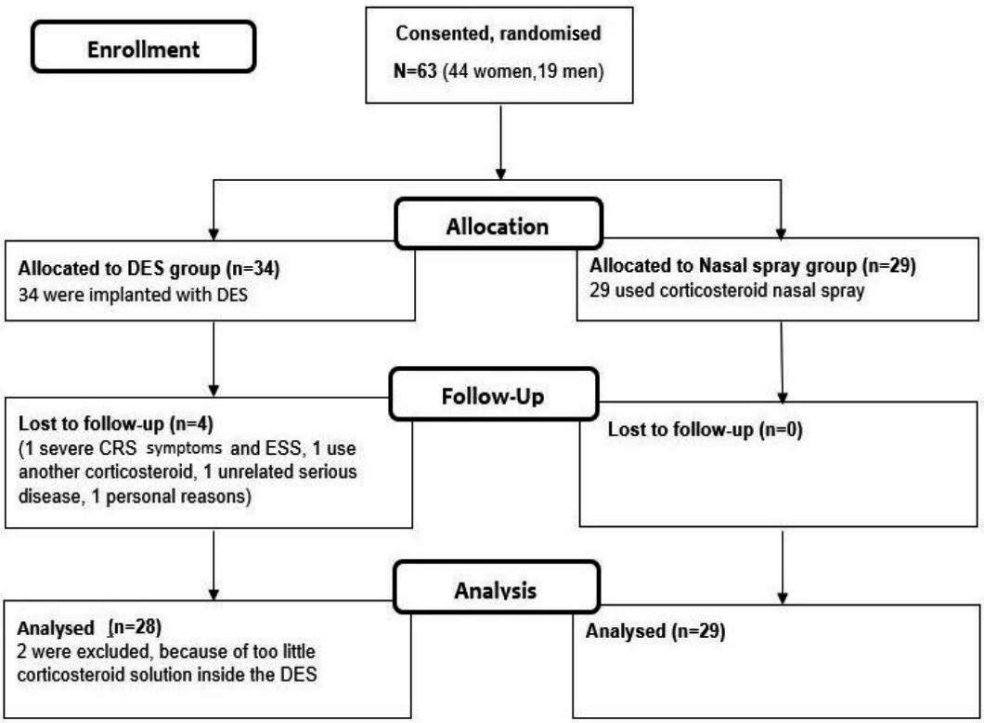

Figure 2. Consort flow diagram of the study.

No significant differences were identified between the groups when comparing the baseline demographic characteristics (Table 1). The main symptoms are identified in the Table 2. The use of saline nasal irrigation varied greatly; some of the patients used it daily and others only when they had many symptoms. No statistically significant difference was found between the groups at baseline in the SNOT-22 scores, VAS scores, endoscopic scores, LM-scores, total nasal volumes or the measurements of the total mean airway resistance (Table 3).

Table 1. Patient demographic characteristics

	DES (*n*=28)	Nasal spray (*n*=29)	Both groups (*n*=57)
Mean age ±*SD* (years)	42.9 ± 11.6	41.1 ± 12.6	42.0 ± 12.1
Sex (M/F)	8/20	10/19	18/39 (31.6%/68.4%)
Smokers	9	10	19 (33.3%)
Duration of symptoms (months) *M*±*SD*	59.4 ± 63.5	55.3 ± 63.3	58.3 ± 62.3
Polyps	5	4	9 (15.8%)
Allergy	8	13	21 (36.8%)
Asthma	4	5	9 (15.8%)
Usage of saline nasal irrigation	19	14	33 (57.9%)
Duration of use of steroid spray (months) before the study *M*±*SD*	20.9 ± 35.8	14.1 ± 26.0	17.4 ± 31.1
Number of courses of antibiotics/patient (6 months before the study) *M SD*	2.1 ± 2.1	2.2 ± 2.1	2.2 ± 2.1
Baseline SNOT-22 score, *M*±*SD*	43.9 ± 16.9	42.8 ± 14.2	43.3 ± 15.5
Baseline LM score, *M*±*SD*	10.6 ± 3.2	11.1 ± 2.6	10.9 ± 2.9

Table 2. Main symptoms

	DES (*n*=28)	Nasal spray (*n*=29)	Both groups (*n*=57)
Nasal blockage/ obstruction/congestion	27 (96.4%)	28 (96.6%)	55 (96.5%)
Nasal discharge	24 (85.7%)	25 (86.2%)	49 (86.0%)
Facial pain/pressure	23 (82.1%)	23 (79.3%)	46 (80.7%)
Reduction or loss of smell	11 (39.3%)	18 (62.1%)	29 (50.9%)

Table 3. Baseline data

	DES		Nasal spray		Both groups	
	Mean	±*SD*	Mean	±*SD*	Mean	±*SD*
SNOT-22	43.9	±16.9	42.8	±14.2	43.3	±15.5
VAS	5.3	±2.3	5.7	±2.6	5.5	±2.5
Acoustic rhinometry, total volume (cm^3)	7.7	±2.3	6.8	±2.0	7.3	±2.2
Rhinomanometry, total inspiratory nasal resistance (Pa/ cm^3/s)	0.23	±0.25	0.36	±0.35	0.30	±0.31
Endoscopic score	2.0	±1.7	1.9	±2.0	2.0	±1.8
LM score (before the trial)	10.6	±3.2	11.1	±2.6	10.9	±2.9

4.5 Clinical variables

Baseline characteristics included age, gender, smoking, duration of CRS symptoms, NPs, allergy, asthma, use of saline nasal irrigation, duration of use of nasal steroid spray, and number of courses of antibiotics (six months before the study). The patients were asked about the main CRS symptoms (nasal blockage/obstruction/congestion, nasal discharge, facial pain/pressure and reduction or loss of smell). These data were collected from a questionnaire of patient history given to the patients during the first study visit. Information on provisional ESS within 36 months of randomisation was gathered from patient records and by contacting the patients.

4.6 22 item Sinonasal Outcome Test, Quality of life questionnaire

The SNOT-22 is a validated, rhinosinusitis-specific QoL instrument that contains 22 individual questions about nasal symptoms and QoL (Hopkins et al. 2009). It has been validated also in Finnish in 2017 (Hytönen et al. 2017).The severity of each symptom is assessed on a scale of 0 to 5 (0=no symptom, 5=worst symptoms), resulting in a maximum complete score of 110. Patients completed the questionnaire after the wash out period, at three months and at six months.

4.7 Visual analogue scale

The VAS is a simple and frequently used method for the assessment of variations in the intensity of pain or different kinds of symptoms. The patients were given a 10 cm long VAS questionnaire and asked to mark the point that they felt represented their perception of their current state on the line between the endpoints. Patients were asked to score using the VAS (0-10 cm) question: "How troublesome are your CRS symptoms now?" (0 cm = not troublesome at all to 10 cm = worst thinkable).

4.8 Acoustic rhinometry and rhinomanometry

AR evaluates nasal cavity volume by analysing reflected sound waves introduced through the nostrils. An acoustic rhinometer A1 (GM instruments Ltd, Kilwinning, UK) was used for the measurements. For mucosal changes, the anterior and medium nasal cavity volume (between 2 cm and 5 cm from the nostril) was measured. The change in the total volume of the nasal cavity (2 cm-5 cm) without decongestants was analysed. At least three measurements were taken for each side.

The rhinomanometer NR6-2 (GM instruments Ltd, Kilwinning, UK) was used to determine the degree of nasal airway resistance. In CRS, this method can be used to confirm whether the improvement in nasal congestion is the result of a reduction in inflammation. In this study, we examined the change in the total inspiratory nasal resistance as a sign of the extent of mucosal inflammation.

Acoustic rhinometry and rhinomanometry were performed after the wash out period, at three months and at six months. All measurements were performed by the same experienced research nurse (PO).

4.9 Direct nasal endoscopy

In the study, we used the EPOS 2007 guideline for endoscopy scoring (0 = absence of polyps, 1 = polyps in middle meatus only, 2 = polyps beyond middle meatus but not blocking the nose completely, 3 = polyps completely obstructing the nose), oedema (0 = absent, 1 = mild, 2 = severe), discharge (0 =no discharge, 1 = clear, thin discharge, 2 = thick, purulent discharge), scarring (0 =absent, 1 = mild, 2 =severe) and crusting (0 = absent, 1 = mild, 2 = severe) (Fokkens et al. 2007). The patients' nasal cavities were examined with an endoscope and graded by the same operator (RT) at each visit.

4.10 Cone beam computed tomography of paranasal sinuses

A CBCT scanner (Planmeca Max, Planmeca, Helsinki, Finland) was used to scan the paranasal sinuses before the study and at the end of the study.

LM-score was used to evaluate the CBCT images. Because the target area of the Relieva Stratus is the ethmoidal cells, we found it unethical to treat patients with severe sinus pathology in the maxillary, frontal, and sphenoidal sinuses (an LM-score

of 2) with only the DES. Therefore, we excluded those patients who had an LM-score of more than 1 in the maxillary, frontal or sphenoidal sinuses. Thus, in our study, the maximum LM-score was 18 instead of the normal maximum score of 24. The LM-scores were analysed by the same doctor (RT).

4.11 The drug-eluting stent

The Relieva Stratus device was introduced in 2009 as a minimally invasive surgical tool to treat chronic ethmoidal sinusitis (Catalano et al. 2009). The stent is inserted into the ethmoidal sinus complex using an endoscopic view with the aid of fluoroscopy or IGS. The length of the MicroFlow Spacer is 17 mm, and the maximum width is 10 mm when the retention wings are opened (Figure 3). When filled up, the width of the drug containing MicroFlow Spacer is smaller, about 5 mm. To ensure safe insertion, the required distance between the anterior wall of the ethmoid bulla and the anterior face of the sphenoid must be more than 20 mm. Therefore, it is of the utmost importance to perform CT scans before the operation to measure this distance to make sure that there is enough space for safe insertion and to rule out any other anatomical abnormalities. The reservoir section of the device contains several hundreds of micropores that slowly release a therapeutic agent into the ethmoidal complex. This local and targeted method of drug delivery ensures a high concentration of the anti-inflammatory agent directly into the diseased mucosa. The FDA has only approved the Relieva Stratus implant loaded with sterile saline. In Europe, however, the device has a CE Mark approval that also covers the use of triamcinolone acetonide (40 mg/ml). The manufacturer of the device recommends that 0.3 ml of sterile saline or triamcinolone acetonide injectable solution (40 mg/ml) is injected into the catheter (Catalano et al. 2009). We found this amount to be too small because of the dead space in the catheter shaft. To ensure that the spacer reservoir is filled up, one needs to inject at least 0.6 ml of the solution into the catheter. Any excess solution leeches out into the ethmoidal cavities. If both sides are implanted, a total dose of 24 mg of triamcinolone solution will leak out of the pores over a period of four weeks. The mechanism of action will be topical, so no significant systemic effects are expected. However, there are patient groups, such as patients with diabetes or glaucoma, who may experience side effects from topical corticosteroids, so caution must be taken when treating these patients. Triamcinolone acetonide is widely used, and thus the potential side effects are well known (Derendorf and Meltzer 2008).

During the operation, all patients were under general anaesthesia. Local anaesthesia with topical cocaine (125 mg cocaine on each side diluted in 5 ml of 0.1 mg/ml adrenalin solution) soaked in the cottonoid patties was used. In addition to cocaine, local anaesthetic (Lidocain® 10 mg/ml cum adrenalin 10 µg/ml, Orion, Finland) was injected under the mucosa in the operation area.

During the study period, the cost of the MicroFlow Spacer in our hospital was 399 € and the cost of the deployment guide was 175 €. When treating both ethmoidal sinuses, the total cost of the devices was 973 €.

All the insertions of the DES were performed by the same surgeon (RT).

Figure 3. The Relieva Stratus filled with triamcinolone.

4.11.1 Stent implantation using fluoroscopic guidance

C-arm fluoroscopy (Philips BV Endura 9", Philips Oy Healthcare, Amsterdam, the Netherlands) guidance was employed for the first thirteen consecutive patients. The anterior face of the ethmoid bulla was exposed under direct endoscopic view (Figure 4). During the insertion of the stent, the access probe (trocar) and a delivery sheath were positioned in the inferomedial part of the bulla ethmoidalis to avoid the possibility of penetrating the skull base or lamina papyracea. C-arm fluoroscopy and a so-called "shark-fin" handle was used to ensure that the correct angle and trajectory were established. This was followed by the insertion of the delivery sheath-containing access probe into the ethmoidal cavities. The access probe was then withdrawn, and the delivery sheath was left inside the ethmoidal sinus. The Relieva Stratus and a catheter were inserted through the delivery sheath into the ethmoidal cells, and then the delivery sheath was completely withdrawn. Correct positioning of

the Relieva Stratus was confirmed by direct endoscopic visualisation and fluoroscopy (Figure 5). A total of 0.6 ml of triamcinolone acetonide injectable solution (Kenalog40®, 40 mg/ml, Bristol-Myers-Squibb Company) was then injected into the catheter. After this, the shaft of the catheter was cut, and the MicroFlow Spacer was left in the ethmoid sinus (Figure 6). There was no need for middle meatal packing. After four weeks, the stent was extracted at an outpatient clinic under local anaesthesia by simply removing it with Blakesley forceps or similar instrument.

To minimise the dose of radiation in our patients, we used only separate expositions; thus, we managed to cut radiation doses to as low as 0.1 mSv per patient. The use of the screening mode might enhance the accuracy of the implantation, but the radiation dose is also much higher.

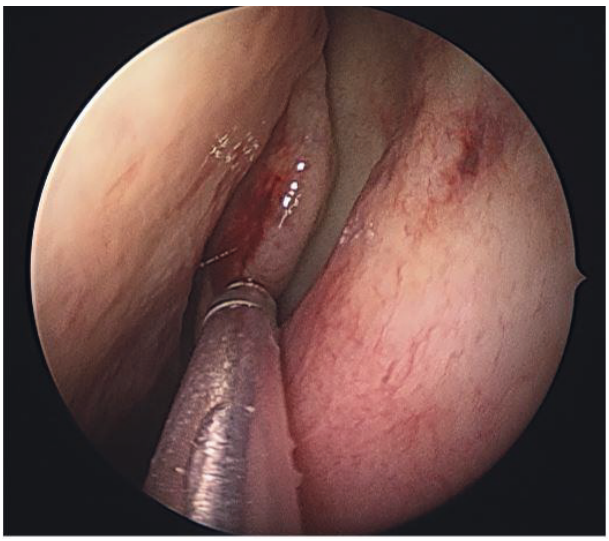

Figure 4. Endoscopic view of the trocar insertion.

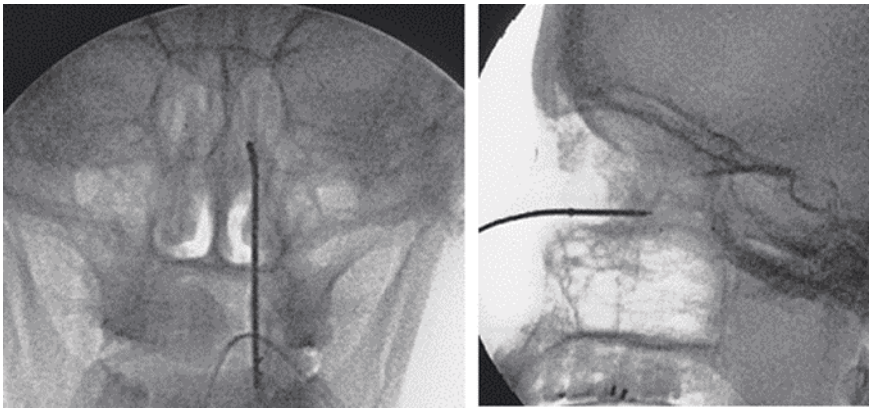

Figure 5. Fluoroscopic view of the Relieva Stratus insertion. The final position of another stent (the two dots) is almost too caudal.

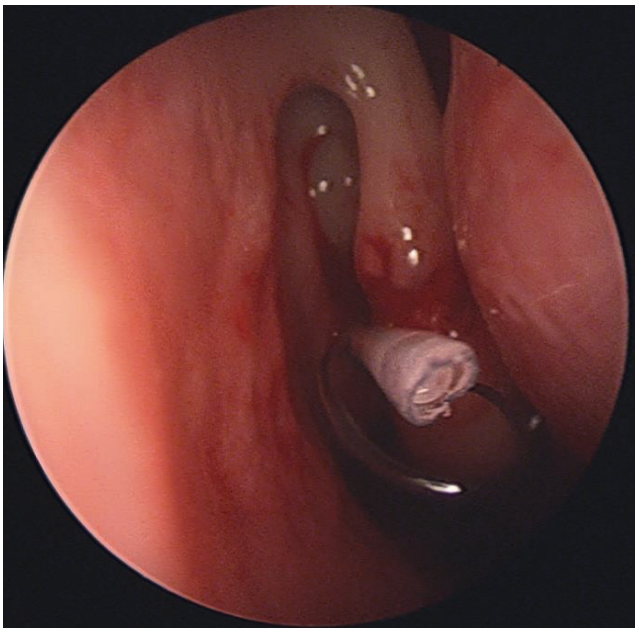

Figure 6. Endoscopic view of the final position of the DES. Only the cut end of the catheter shaft is visible in the image (right side).

4.11.2 Stent implantation with the aid of image-guided navigation

Optical IGS-assisted (BrainLAB Kolibri® image-guided surgery system) DES insertions were performed on the remaining 21 patients. The major advantage of an

optical IGS is its ability to register almost any rigid instrument as a tracker instrument. With optical IGS, one has a new, ready-to-use navigation-enabled instrument simply by attaching a wireless universal instrument adapter to the access probe and calibrating it. Patient registration is fast and takes around two minutes to set up. In the case of the Relieva Stratus device, the wireless universal instrument adapter was attached to the trocar; this new navigation-enabled instrument was then registered and calibrated (Figure 7). Before use, the accuracy of the IGS should be confirmed. Under endoscopic view, the tip of the trocar was placed in the anterior of the bulla ethmoidalis. With the aid of IGS, one can precisely pinpoint the tip of the instrument and safely navigate the DES into the worst affected ethmoidal cells (Figure 8). The rest of the procedure was performed as described in the previous paragraph.

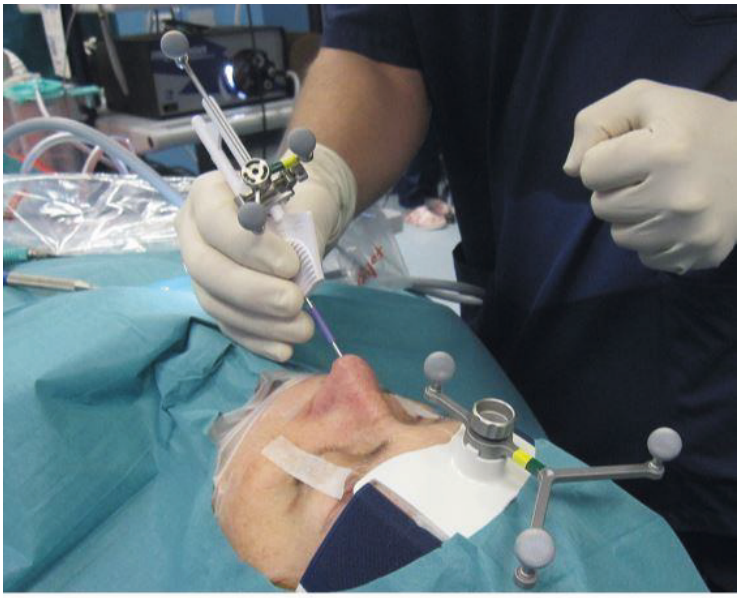

Figure 7. IGS-assisted trocar insertion.

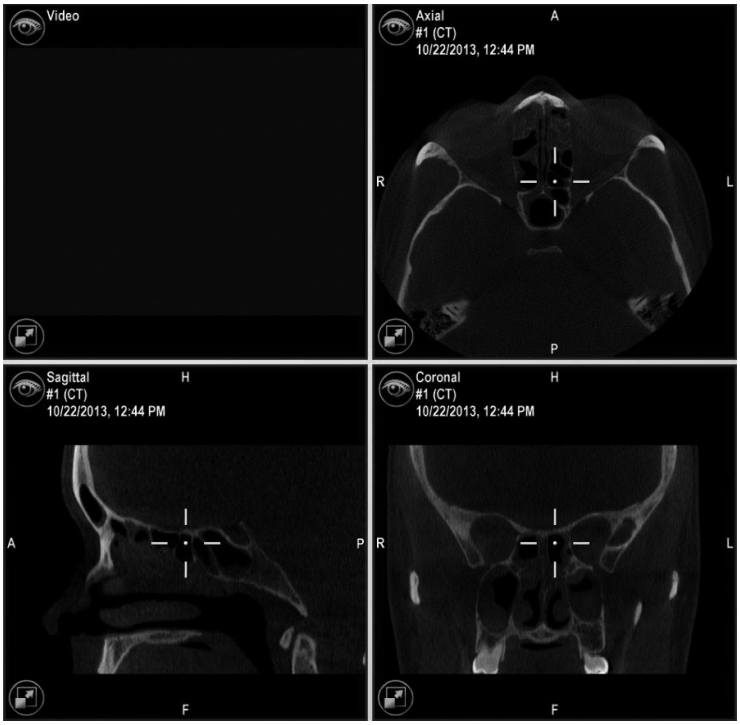

Figure 8. Three-dimensional view of the final position of the navigation-enabled trocar instrument.

4.12 Intranasal corticosteroid spray

The nasal spray control group (Nasacort®, Sanofi, triamcinolone acetonide, 55 ug/dose) used 2 doses/nostril/day for 6 months. Patients were instructed how to correctly apply the nasal spray, and they were also informed that the nasal spray dosers would be weighed at every visit to verify that the drug was being used as instructed. If 2 sprays per day on both sides were used, one bottle of ICS spray should last 30 days. Six nasal spray bottles were marked and weighed and given to the patients at the start of the trial. Patients returned all the bottles at the end of the trial and they were weighed again. The contents of one bottle weighed 15 grams, so if used as instructed, the sum of the contents of all of the bottles weighed 90 grams. The drugs (Kenalog40®, 40 mg/ml, Bristol-Myers-Squibb Company and Nasacort®, 55 ug/dose, Sanofi) used in this trial were purchased from the pharmacy of Tampere University Hospital.

4.13 Statistical analysis and sample size calculation

Statistical analysis and graphical representation of the results were performed using IBM SPSS version 21 software (SPSS Inc., Chicago, IL, USA). Within-group comparisons between baseline and follow-up scores were analysed with non-parametric Wilcoxon Signed Rank test (II). Differences between the groups were analysed with non-parametric Mann–Whitney U test (II-III). The differences between groups in categorical variables were assessed with Fisher´s exact test or Pearson´s Chi-squared test (III). P-values smaller than 0.05 were considered significant.

The sample size was calculated based on paired t-test. The primary variable was chosen to be the SNOT-22 score (II). The value for average SNOT-22 change was set to 12.6, and 20.0 was used as standard deviation (Hopkins et al. 2009). With alpha of 0.05 and power of 0.8, the calculation suggested that approximately 22 study patients would be needed to see the SNOT-22 change as statistically significant. A drop-out of patients in follow-up had to be taken into account, so approximately 30 patients in both groups (a total of 60) were required.

4.14 Ethical considerations

The trial protocol was approved by the Institutional Review Board of Pirkanmaa Hospital District, Tampere University Hospital (ETL code R10098M, EudraCT 2010-022188-37). For ethical reasons, at the time of the enrolment, all patients were added to the surgery queue to make sure that participation in the study would not further delay surgery should it be needed at the end of the study. Oral and written information about the trial protocol were given to the patients and the informed consent was obtained. This study was conducted according to the Declaration of Helsinki.

None of the authors had any conflict of interest with any financial organization. This study was not sponsored by Acclarent Inc or any other pharmaceutical company.

5 RESULTS

5.1 Efficacy of the drug-eluting stent and intranasal corticosteroid therapy (II)

At the three- and six-month follow-up visits, the total SNOT-22 score showed a significant improvement in both groups, with no significant difference between the groups. In the DES group, the mean change from the baseline score was -17.0 ± 16.7 (mean ± standard deviation [M±SD]) after three months and -12.0 ± 13.9 (M±SD) after six months. The same values in the nasal spray group were -10.1 ± 13.8 (M±SD) and -10.2 ± 15.9 (M±SD), respectively. There was a tendency for patients in the DES group to benefit more from the treatment after three months compared to the nasal spray group, but the difference was not statistically significant (p=0.078). (Table 4 and 5)

The average VAS score decreased in both groups. The mean changes were significant at three months and at six months in the nasal spray group, but in the DES group a significant difference was noted only at three months. There were no significant differences between the groups. (Table 4 and 5)

The total nasal volumes measured with acoustic rhinometry in the nasal spray group increased significantly at three months and six months. Total nasal volumes in the DES group did not show any significant changes from the baseline measurements. The differences between the groups were significant at both three months and six months. (Table 4 and 5)

There were no (significant) changes in rhinomanometry measurements or the endoscopic score at either three months or six months. No statistically significant difference was found between the groups either. (Table 4 and 5)

The use of the antibiotics was significantly reduced in both groups when comparing the mean number of courses of antibiotics to the six-month period before the beginning of the study and the trial period. No difference was found between the groups. (Table 4 and 5)

The patients returned 151 of the 174 nasal spray bottles (86.8%). The mean proportion of study medication used in the nasal spray group during the trial was 70.8%, which is equal to 63.8 grams of corticosteroid solution.

Table 4. Three-month change in measurements of DES and nasal spray groups.

Parameter group	**DES** Change from baseline Mean	±*SD*	Nasal spray Change from baseline Mean	±*SD*	Statistical difference between the groups
SNOT-22	-17.0 (*p*<0.001*)	±16.7	-10.1 (*p*=0.001*)	±13.8	*p*=0.078**
VAS	-1.9 (*p*=0.001*)	±2.4	-1.4 (*p*=0.006*)	±2.5	*NS*
Acoustic rhinometry, total nasal volume (cm3)	-0.33 (*NS*)	±2.8	1.2 (*p*=0.001*)	±2.3	*p*=0.025**
Rinomanometry, total inspiratory nasal resistance (Pa/ cm3/s)	0.03 (*NS*)	±0.29	-0.05 (*NS*)	±0.34	*NS*
Endoscopic score	-0.1 (*NS*)	±1.9	0.4 (*NS*)	±1.8	*NS*

*Wilcoxon signed ranks test, **Mann–Whitney U test

Table 5. Six-month change in measurements of DES and nasal spray groups.

Parameter group	**DES** Change from baseline Mean	±*SD*	**Nasal Spray** Change from baseline Mean	±*SD*	Statistical difference between the groups
SNOT-22	-12.0 (*p*<0.001*)	±13.9	-10.2 (*p*=0.002*)	±15.9	*NS*
VAS	-0.7 (*NS*)	±2.8	-1.4 (*p*=0.026*)	±3.1	*NS*
Acoustic rhinometry total nasal volume (cm^3)	-0.11 (*NS*)	±2.6	1.4 (*p*=0.002*)	±2.0	*p*=0.016**
Rinomanometry, total inspiratory nasal resistance (Pa/ cm^3/s)	0.12 (*NS*)	±0.58	-0.08 (*NS*)	±0.25	*NS*
Endoscopic score	0.1 (*NS*)	±1.5	-0.2 (*NS*)	±2.2	*NS*
LM score	-1.9 (*p*=0.056*)	±4.4	-0.7 (*NS*)	2.7	*NS*
Course of antibiotics/patient six months before trial vs follow-up time	-1.4 (*p*=0.013*)	±2.6	-1.8 (*p*<0.001*)	±2.1	*NS*

*Wilcoxon signed ranks test, **Mann–Whitney *U* test

5.2 Safety of the drug-eluting stent and intranasal corticosteroid therapy (II)

There were no significant immediate or delayed complications in either group. No DES had to be removed before the end of the four-week treatment period. After the insertion of the stent, some patients experienced minor sensations of local irritation. When the implant was removed, there was minor crusting (n=2) and a small amount of purulent discharge (n=3) around the cut end of the shaft of the catheter in the endoscopy in some patients. One patient was prescribed antibiotics

to treat these symptoms. Four patients had minor nose bleeds, which lasted for one to two days after the insertion of the implant; however, no interventions were needed to treat them. Two patients from the nasal spray group complained dryness of the nose.

5.3 Can endoscopic sinus surgery be prevented by using the drug-eluting stent or intranasal corticosteroid therapy? (III)

After the six-month follow up, 15/28 (53.6%) of the patients in the DES group and 15/29 (51.7%) in the nasal spray group underwent ESS. During the 6 to 36 months extended follow-up period, five more patients in the DES group and three more in the nasal spray group were operated. There were no statistical differences between the groups. After six-month follow-up, a total of 30/57 (52.6%) patients were operated with ESS and a further 38/57 (66.7%) during the full 36-month follow-up period.

Uncinectomy or middle meatal antrostomy was performed for all of the operated patients. Four patients underwent only middle meatal antrostomy or uncinectomy because there were only minor changes remaining in the ethmoids in the follow-up CBCT. Partial or total ethmoidectomies were performed on 89.5% (34/38) of the patients, sphenotomies in 2 patients and minimal frontal ostium sinotomy (draf IIa) in 2 patients.

The patients included in the study could have had partial opacification of sinuses (LM-score of 1) other than ethmoids. At the time of randomisation, partial opacification of at least one of the maxillary sinuses was found in 55 (96.5%), one of the sphenoid sinuses in 35 (61.4%) and one of the frontal sinuses in 33 patients (57.9%). After six months, the results were similar with the numbers being 55 (96.5%), 36 (63.1%) and 36 (56.1%), respectively. The mucosal disease was predominantly localised in the ethmoidal cavities and the partial opacification of the other sinuses was usually minor in severity and caused by the thickening of the mucosa on the walls of the sinuses.

The patients who underwent surgery had non-significantly higher baseline mean LM-scores. After the six-month study period, this difference was somewhat larger, but still non-significant. (Table 6)

The patients who were operated after 6 months had significantly higher baseline SNOT-22 scores, and they also benefitted less from the treatments than those patients who were not operated There was no difference in the mean change from

the baseline SNOT-22 score to the six-month score between the DES group and the nasal spray group among those patients who were operated right after the 6-month follow-up period or those patients who were not operated. (Table 6)

Smoking was the only variable that was significantly associated with ESS at 6 months, with 14 of the 19 (73.7%) smokers and 16 of the 38 (42.1%) non-smokers operated at this time point (p=0.024).

Table 6. Results

	Operated patients *M±SD*	**Un-operated patients** *M±SD*	Statistical difference between the groups	Statistical difference between the groups
Mean baseline LM-score	11.2 ± 2.7	10.5 ± 3.1	*NS*	
Mean LM-score after 6 mo	10.7 ± 3.0	8.3 ± 4.7	*NS* (*p*=0.073)	
Mean baseline SNOT-22 score	48.0 ± 14.8	38.0 ± 14.8	*p*=0.011	
Mean change in SNOT-22 scores after 6 mo	-6.3 ± 12.5	-16.4 ± 15.7	*p*=0.006	
Mean change in SNOT-22 scores after 6 mo in DES group	-6.1 ± 10.4	-18.8 ± 14.7	*NS*	*NS*
Mean change in SNOT-22 scores after 6 mo in nasal spray group	-6.5 ± 14.6	-14.2 ±16.8		

5.4 Image-guided drug-eluting stent insertion (I)

We found the image-guided DES insertion easy to perform. The calibration of the wireless universal instrument adapter to the trocar instrument was fast and easy to manage, and the accuracy of the IGS instrument was good enough to perform safe and precise implantation of the DES. When compared to fluoroscopic insertion, where you are worried about the location of the skull base and the lamina papyracea, the IGS insertion of the DES can be performed more cranially and laterally in the bulla ethmoidalis with smaller risk of perforation of the skull base or other sensitive structures. During the image-guided procedure, one can follow where the tip of trocar is placed in real time, and the DES can be navigated more precisely to those ethmoidal cells worst affected by CRS, based on the preoperative CT scans.

We found no immediate or delayed complications in either study group. After the operation, patients only experienced minor sensations of local irritation and most of them were totally pain-free. Many patients reported that they did not sense

anything out of the ordinary after the implantation. There were no significant adverse effects in either of the study groups. In three cases in the fluoroscopy group, the DES had been inserted too low into the superior meatus and outside the ethmoidal cavities. In two of the cases, the catheter was cut before this was noticed and the stent was lost.

6 DISCUSSION

6.1 General discussion

Topical steroids are beneficial in the treatment of CRS with and without polyps (Orlandi, Kingdom et al. 2016). However, the main disadvantage with the use of nasal sprays and drops is suboptimal drug delivery to the paranasal sinuses (Snidvongs et al. 2008). Another problem is wrong dosing technique and lack of motivation to use the medication as regularly and for as long as recommended (Philpott et al. 2018). Current standard surgical treatment for chronic inflammatory disease of the ethmoid sinus is endoscopic ethmoidectomy performed with a microdebrider, through-cutting forceps or a combination of the two. However, the widespread use of these tools has been known to cause minor complications, such as postoperative inflammation and middle meatal scarring. On very rare occasions, complications as severe as cerebrospinal fluid leak, orbital emphysema, and potential visual change or loss of vision can occur. The Relieva Stratus DES is an interesting mini-invasive option to deliver strong corticosteroid medication directly to the diseased paranasal sinus mucosa in order to avoid surgery and to preserve normal ethmoid sinus anatomy.

The results of a cadaveric study have demonstrated that the insertion of the Relieva Stratus into the ethmoidal sinus using fluoroscopy is relatively safe and easy (Melroy and Kuhn 2009). In addition to our trial, there has been only one published prospective, randomised clinical study evaluating the efficacy and safety of this DES. In that trial, the DES was compared to endoscopic ethmoidectomy in the management of 70 allergic, adult patients with CRS. The authors concluded that DES was safe and effective in the treatment of allergic patients with ethmoidal CRS when conventional medical treatment had failed or when wishing to avoid the classic endoscopic ethmoidectomy (Businco et al. 2016). There have been only a few complications involving the Relieva Stratus published in the literature (Villari et al. 2012, Sjogren et al. 2013, U.S. Food and Drug Administration 2010).

6.2 Drug-eluting stent therapy is safe and efficient (II)

Our hypothesis was that the patients in the DES group would experience better relief of symptoms compared to the patients in the ICS group. Our results did not support this hypothesis. We found that the QoL measured by SNOT-22 score improved significantly in both treatment groups at three and six months of observation. In addition, the VAS score decreased in both groups. The observed benefits of the ICS spray treatment measured by VAS were evident at three months and six months, but in the DES group a significant improvement was noted only at the three-month time point. There was a statistically significant increase in the total nasal cavity volumes measured with acoustic rhinometry in the ICS spray group at three months and six months, but not in the DES group. The most surprising result was the significant increase in QoL in the nasal spray group, although these patients had already used ICS spray before the study without notable relief of symptoms. The use of the nasal spray increased the total volume of the nasal cavities most likely by decreasing the mucosal swelling. These results emphasise the importance of the ideal dosing technique, motivation and regular, long-term administration of the topical corticosteroid medication.

At three months, the SNOT-22 scores were lower in the DES group compared to the nasal spray group. However, the difference was not statistically significant ($p=0.078$). The fat-soluble triamcinolone acetonide continued to have an effect on the mucosa after the Relieva Stratus had been removed from the ethmoid sinuses. It is likely that when reaching the six-month time point, the effect of the corticosteroid of the Relieva Stratus had already diminished, and thus the difference between the groups disappeared. This notion is also supported by the finding that there was no statistically significant improvement in VAS score at six months in the DES group. Like asthma, CRS is a chronic disease and corticosteroid medication simply reduces the inflammation caused by various aetiologies and relieves the symptoms; it does not, however, provide a definitive cure for the disease.

In the national comparative audit of surgery for nasal polyposis and CRS, SNOT-22 was able to discriminate between those patients known to suffer from CRS and a group of healthy controls. They found that the minimum clinical difference detectable with the SNOT-22 scoring scheme was 8.9 points. In the present study, the mean change in SNOT-22 scores after the treatment period was >10 in both groups. In that previous study, the mean preoperative SNOT-22 score of patients undergoing primary surgery was 39.6, which is similar to our results (43.3). (Hopkins et al. 2009)

In our study, the baseline LM-scores were quite low (10.6 ± 3.2 in the DES group and 11.1 ± 2.6 in the nasal spray group) because we excluded all patients who had LM-score of more than 1 in the maxillary, frontal or sphenoidal sinuses. Because the target area of the Relieva Stratus is ethmoidal cells, we found it unethical to treat patients with severe sinus pathology in maxillary, frontal, and sphenoidal sinuses (LM-score 2) with only the DES. Therefore, in our study, the maximum LM-score was 18 instead of the normal maximum of 24.

In the operating instructions provided by Acclarent Inc, and also in previous studies (Catalano et al. 2009), it is recommended that 0.31 ml of therapeutic agent should be injected into the catheter. We found this amount too small because of the dead space of the catheter shaft. To ensure that the spacer reservoir is filled, at least 0.6 ml of the solution must be injected into the catheter. Any excess solution leeches out into the ethmoidal cavities. This technical detail was the reason why we excluded the first two patients in the Relieva Stratus group.

When comparing antibiotic use six months before the study and then during the study, we found a significant decrease in both groups. It is most likely that before the study CRS symptoms were treated as acute bacterial rhinosinusitis. At the beginning of the study, the patients were educated about the inflammatory nature of CRS and the poor efficacy of short-term antibiotic treatment. Thereafter, the use of the antibiotics decreased dramatically.

In our study, the mean SNOT-22 score change after three months in patients treated with the DES was -17.0, which is quite similar to the results of the national comparative audit of surgery for nasal polyposis and CRS study (Hopkins et al. 2009), where the mean SNOT-22 score was 16.2 points lower after ESS surgery than preoperatively. Of course, the results of these two studies cannot be compared completely because of the methodological differences between the study designs, but our results indicate that Relieva Stratus is an effective therapy in treating patients with CRS.

We found the implantation of the DES with navigation easy and safe to perform. After the operation, patients experienced only minor sensations of local irritation and most of them were totally pain-free. Most of the patients stated that they could not sense anything out of the ordinary after the implantation. A little crusting and minor mucopurulent secretion around the cut end of the catheter due to foreign body reaction was found in five patients, but otherwise there were no informed adverse events in the DES group. Moreover, there were no topical long-term side effects inside the nose and paranasal sinuses concerning the use of the corticosteroid solution in the DES group. The most common side effects reported in the use of

ICSs are minor and include mucosal irritation, crusting and minor nose bleeds. In our trial, these adverse effects were rare and only two patients from the nasal spray group complained dryness of the nose.

6.3 Both the drug-eluting stent and intranasal corticosteroid therapy can prevent endoscopic sinus surgery (III)

At the end of the prospective follow-up at 6 months, nearly equal number of patients in both groups chose not to be operated, although at the beginning of the study all patients were guaranteed an operation should they still need it. In standard clinical workup, most or perhaps all of these patients would have been operated. Moreover, the spontaneous relief of symptoms would have been very unlikely considering the long duration of the symptoms (mean: 58 months). Thus, these treatments may prevent ESS in almost half of the cases in the medium term. This again emphasises the importance of properly instructing CRS patients on the optimal dosing technique and motivating the patients to ensure regular, long-term administration of the topical ICS therapy. Further, the effect of the Relieva Stratus, removed after one month, was sustained for six months. It is possible therefore that this kind of high-dose, targeted drug delivery can better heal the sinus mucosa and provide a prolonged anti-inflammatory effect and/or the long-acting, fat-soluble triamcinolone acetonide continues to have an effect on the mucosa even after the DES has been removed.

Three years after the initiation of the treatments, five more patients in the DES group and three in the nasal spray group had been operated with no statistically significant difference between the groups. The results suggest that ESS can be prevented in the long term with properly supervised corticosteroid therapy in close to one third of all surgical candidates referred to a tertiary centre.

The imaging findings in the non-ethmoidal sinuses were less severe and in only four patients were sinuses other than the ethmoids or maxillaries operated in addition to ethmoidectomy. The ethmoidectomy procedure included also middle meatal antrostomies or uncinectomies, as per our local clinical guideline. Four patients received only widening of the maxillary sinus opening because their findings in the ethmoids in the follow-up CBCT were none or minimal. Thus, in these patients, it is plausible that sinus disease other than ethmoidal contributed to the need for surgery. However, we chose to include these patients because they did have ethmoidal disease in the enrolment CBCT, still had CRS symptoms and it was

possible that surgery of the infundibular area could also have had a positive effect on the mucosal disease of the anterior ethmoidal sinuses.

The sensitivity of the LM-scoring system in the evaluation of the extent of the mucosal disease in the sinonasal cavities is suboptimal. The scoring system allocates the same score to both minimal mucosal swelling and subtotal opacification of the sinus. Hence, we did not find a significant difference in pre- or post-treatment LM-scores between those patients who underwent surgery and those who did not. It is probable that a more sensitive scoring system, such as the Zinreich modified staging system, could have identified significant differences between the groups.

There was a correlation between the baseline SNOT-22 values, the mean change from the baseline at 6 months, and whether the patients were operated or not with those patients with more severe symptoms and who were less responsive to therapy having higher odds of operation. This highlights the validity and usefulness of the SNOT-22 scoring system.

The findings of this study (III) strengthen the conclusion of our previous trial (II). We could find no therapeutic advantage for the use of the Relieva Stratus stent as a monotherapy compared to nasal corticoid spray therapy that would justify the increased costs, the need for general anaesthesia, and the risk of procedure-related complications associated with this technique.

We also found that smoking significantly predicted ESS (74% of smokers vs. 42% of non-smokers). We are unaware of previous studies that directly address whether tobacco use predicts the operative treatment of CRS among patients receiving topical corticosteroids. A recent systematic review (Christensen et al. 2018) of the association between cigarette smoke exposure and CRS reported that active smoking increases the risk of CRS with a dose-response pattern and that former smoker status and passive exposure may also increase the risk. The data indicate that the association between smoking and CRS outcomes is not benign, but the strength and magnitude of the effect of smoking are not fully characterised. The authors of the review concluded that there is not enough data to support smoking as a contraindication to surgical treatment of CRS because both smokers and non-smokers experience subjective improvements in symptoms after ESS.

6.4 Image guided insertion of the drug-eluting stent is superior to the fluoroscopic insertion (I)

In general, the use of C-arm fluoroscopy is quite laborious in the setting of paranasal sinus surgery. In the case of Relieva Stratus stent placements, fluoroscopic guidance accuracy is suboptimal; it is only adequate to prevent major complications, such as violations of the lamina papyracea and the skull base. Under fluoroscopic guidance, the insertion point in the anterior part of the bulla ethmoidalis is often too caudal and medial, which may lead to penetration to the superior meatus and implantation of the DES outside of the ethmoidal sinus. This problem was not observed in the case of IGS-assisted operations. In comparison to IGS, which enables real-time guidance during the procedure and the negotiation of specific predetermined ethmoidal cells, only the final position of the Relieva Stratus can be seen after insertion when separate exposition fluoroscopy is used. One of the major benefits of using IGS is operator confidence in knowing exactly where the tip of the trocar is. This speeds-up the procedure and enables the insertion of the DES much more cranially, without any risk of perforation of the skull base or other sensitive structures. Thus, an IGS-assisted approach improves the accuracy of the insertion and enables more precisely targeted treatment of the affected ethmoidal cells. This is especially useful when only part of the ethmoidal cavities is diseased. Another major disadvantage of the fluoroscopic approach is the radiation dose acquired by the patients and the surgical staff. During the learning phase in particular, longer screening times and several expositions are required to ensure correct positioning of the device. To minimise the dose of radiation in our patients, we used only separate expositions; thus, we managed to cut radiation doses to as low as 0.1 mSv per patient. The use of the screening mode might enhance the accuracy of the implantation, but then the radiation dose is also much higher.

6.5 Limitations

The main limitation of this study was the lack of a placebo group. It is possible and even probable that some of the positive effects, especially in the DES group, when treating patients with a novel surgical treatment were placebo. Lacking a placebo-controlled study design, we chose to compare the efficacy of the Relieva Stratus implant to a proven conservative treatment.

Further, the differing dropout rates in the two treatment groups warrant caution in the interpretation of the results.

The long-term data (III) were obtained retrospectively, but the study groups had been prospectively randomised, as described above. Direct inference about the efficacy of DES and nasal spray is not possible in this period because of confounding factors, such as the use of other corticosteroids and recall bias. However, the general preventive effect of the previous interventions can be evaluated.

Symptoms caused by the involvement of sinuses other than the ethmoids may have influenced the decision to proceed to ESS. However, all patients had CBCT-verified involvement of the ethmoid sinuses at enrolment and received therapy that potentially had a treatment effect on all sinuses.

The six-month follow-up time might be too short to evaluate the long-term effect of the DES. All the patients who participated in the study had severe symptoms and were candidates for surgery, so a six-month follow-up period was considered feasible, and we considered a longer follow-up to be unethical.

6.6 Clinical relevance

We found that Relieva Stratus implant is an effective and safe tool to treat ethmoidal CRS. The mean SNOT-22 score change after three months is comparable to the results after ESS (Hopkins et al. 2009). By using the Relieva Stratus implant, it is possible to prevent almost half the number of ESS in the medium term (6 months) and close to one third in the long term (36 months). However, the fact that the conservative treatment option with ICS spray is equally effective diminishes the clinical role of the DES as a primary monotherapy for CRS, especially when considering the additional cost, the need for general anaesthesia, and the potential side effects associated with the DES. The postoperative treatment of CRS after ESS includes local corticosteroid therapy (Fokkens et al. 2020). In our study, the DES has been investigated as a monotherapeutic treatment. It is possible that combined therapy with the DES and the ICS spray therapy could be even more efficient. The targeted administration of corticosteroids with DES might be a potential tool for the treatment of chronic ethmoiditis in cases where we want to boost the efficacy of the ICS spray therapy while avoiding systemic corticosteroids or surgery or when the diseased area in the ethmoidal sinuses is limited.

The surprising results were the significant increase in QoL and the preventive effect for ESS in the ICS group, since patients had already used corticosteroid nasal spray before the study without any significant results. This result emphasises the importance of the ideal dosing technique, motivation and the regular, long-term administration of the ICS therapy. t

In a sub-analysis of the data, we also found that smoking significantly predicted ESS. Our results suggest that smoking cessation in combination with topical corticosteroids might yield better prevention of ESS than corticosteroid treatment alone.

By setting up a new technique of image-guided insertion of the Relieva Stratus stent, we enhanced the accuracy of the insertion of the DES, and thus made it possible to precisely treat the diseased ethmoidal cells identified by preoperative CT imaging. This is especially useful when only part of the ethmoidal cavities is diseased. Another major advantage of using IGS-insertion is the lack of radiation exposure to patients and surgical staff.

At the time of writing of this dissertation, Acclarent Inc has discontinued the production of the Relieva Stratus. Some of the results of our studies, e.g., details of the insertion technique, are device-specific and cannot be generalised or applied to all stents or implants that are still on the market for related indications. However, the drug used in this study is well-known and widely used, and the device itself is just a vessel for the transport of the medication inside the ethmoidal cavities. Thus, the results of our studies add to the general body of knowledge in this field, i.e., the treatment of CRS with local corticosteroids and DES.

6.7 Future aspects

The Relieva Stratus DES cannot be studied further considering that it is no longer obtainable on the market. On a more general note, future DESs or implants may be specifically designed for maxillary, ethmoidal, sphenoidal or frontal sinuses. These implants can potentially be loaded with drugs other than steroids, depending on the facets of the disease that need to be treated, including high-dose antibiotics, anti-inflammatory medication, such as biological drugs, or a combination of drugs. The use of this kind of targeted drug delivery inside diseased sinuses enables, for example, much higher local antibiotic concentrations with little or no systemic side effects or problems with antibiotic resistance. CRS is, as the name implies, a chronic disease, so the ideal implants should be designed for a long-lasting and stable drug release

with minimal foreign body reactions. Implantations of these devices should be easy and safe to manage so that the procedure can be performed in an office setting.

7 CONCLUSIONS

1. Due to radiation protection concerns and the need for a better accuracy because of the complexity and variability of ethmoidal cavity anatomy and the vital anatomical structures surrounding the ethmoidal cells, optical IGS insertion of the DES is superior to fluoroscopic insertion.

2. Patients benefitted from the DES and ICS spray and QoL improved significantly for both groups. We could not find any significant difference between the treatments. Considering the additional costs, the need for general anaesthesia, and the potential side effects associated with the DES, its potential clinical role as a monotherapy for CRS appears to be limited. The good results of ICS spray emphasise the importance of optimal dosing technique, motivation and the regular, long-term administration of topical corticosteroid therapy in the primary treatment of CRS.

3. The insertion of the DES is easy and safe to perform with a small number of minimal post-operative adverse events.

4. In the medium term (6 months), ESS can be prevented by both therapies in almost half of cases. However, this preventive effect is somewhat diminished in the long term (36 months) with close to one third of patients avoiding ESS in both groups.

8 REFERENCES

ACHAR P, DUVVI S, KUMAR BN. 2012. Endoscopic dilatation sinus surgery (FEDS) versus functional endoscopic sinus surgery (FESS) for treatment of chronic rhinosinusitis: a pilot study. *Acta Otorhinolaryngologica Italica,* 32(5), pp. 314-319.

ADRIAENSEN G, LIM K, FOKKENS WJ. 2017. Safety and efficacy of a bioabsorbable fluticasone propionate-eluting sinus dressing in postoperative management of endoscopic sinus surgery: a randomized clinical trial. *International Forum of Allergy & Rhinology,* 7(8), pp. 813-820.

AFZELIUS BA, MOSSBERG B. 1980. Immotile cilia. *Thorax,* 35(6), pp. 401-404.

ALAKÄRPPÄ A, ALHO O. 2012. Patient-recorded outcomes and quality of life in evidence-based medicine databases on most common ear, throat and nose procedures: a systematic review. *Clinical Otolaryngology,* 37(6), pp. 436–445.

ALAKÄRPPÄ A, KOSKENKORVA T, KOIVUNEN P, ALHO O. 2017. Quality of life before and after sinonasal surgery: a population-based matched cohort study. *European Archives of Oto-Rhino-Laryngology,* 274(2), pp. 795-802.

ALOBID I, BENÍTEZ P, BERNAL-SPREKELSEN M, ROCA J, ALONSO J, PICADO C, MULLOL J. 2005. Nasal polyposis and its impact on quality of life: comparison between the effects of medical and surgical treatments. *Allergy,* 60(4), pp. 452-458.

ALQUDAH M, GRAHAM SM, BALLAS ZK. 2010. High prevalence of humoral immunodeficiency patients with refractory chronic rhinosinusitis. *American Journal of Rhinology & Allergy,* 24(6), pp. 409-412.

AL-RAWI M, EDELSTEIN DR, ERLANDSON R.A. 1998. Changes in nasal epithelium in patients with severe chronic sinusitis: a clinicopathologic and electron microscopic study. *The Laryngoscope,* 108(12), pp. 1816-1823.

AMERICAN ACADEMY OF OTOLARYNGOLOGY—HEAD AND NECK SURGERY. 2012-last update, Intraoperative Use of Computer Aided Surgery. Available: http://www.entnet.org/Practice/policyIntraOperativeSurgery.cfm [Accessed 6 April 2020].

AMITANI R, TAYLOR G, ELEZIS EN, LLEWELLYN-JONES C, MITCHELL J, KUZE F, COLE PJ, WILSON R. 1995. Purification and characterization of factors produced by Aspergillus fumigatus which affect human ciliated respiratory epithelium. *Infection and Immunity,* 63(9), pp. 3266-3271.

ANDERSSON JA, CERVIN A, LINDBERG S, UDDMAN R, CARDELL LO. 2002. The paranasal sinuses as reservoirs for nitric oxide. *Acta Oto-Laryngologica,* 122(8), pp. 861-865.

ANTUNES MB, CHI JJ, LIU Z, GOLDSTEIN-DARUECH N, PALMER JN, ZHU J, COHEN NA. 2012. Molecular basis of tobacco-induced bacterial biofilms: an in vitro study. *Otolaryngology--Head and Neck Surgery: Official Journal of American Academy of Otolaryngology-Head and Neck Surgery,* 147(5), pp. 876-884.

ARTIS D, SPITS H. 2015. The biology of innate lymphoid cells. *Nature,* 517(7534), pp. 293-301.

BACHERT C, ZHANG N, PATOU J, VAN ZELE T, GEVAERT P. 2008. Role of staphylococcal superantigens in upper airway disease. *Current Opinion in Allergy and Clinical Immunology,* 8(1), pp. 34-38.

BACHERT C, PAWANKAR R, ZHANG L, BUNNAG C, FOKKENS WJ, HAMILOS DL, JIRAPONGSANANURUK O, KERN R, MELTZER EO, MULLOL J, NACLERIO

R, PILAN R, RHEE, C, SUZAKI H, VOEGELS R, BLAISS M. 2014. ICON: chronic rhinosinusitis. *The World Allergy Organization Journal,* 7(1), pp. 25.

BACHERT C, HOLTAPPELS G. 2015. Pathophysiology of chronic rhinosinusitis, pharmaceutical therapy options. *GMS current topics in otorhinolaryngology, head and neck surgery,* 14, pp. 1-40.

BACHERT C, AKDIS CA. 2016a. Phenotypes and Emerging Endotypes of Chronic Rhinosinusitis. *The Journal of Allergy and Clinical Immunology. In Practice,* 4(4), pp. 621-628.

BACHERT C, MANNENT L, NACLERIO RM, MULLOL J, FERGUSON BJ, GEVAERT P, HELLINGS P, JIAO L, WANG L, EVANS RR, PIROZZI G, GRAHAM NM, SWANSON B, HAMILTON JD, RADIN A, GANDHI NA, STAHL N, YANCOPOULOS GD, SUTHERLAND ER. 2016b. Effect of Subcutaneous Dupilumab on Nasal Polyp Burden in Patients with Chronic Sinusitis and Nasal Polyposis: A Randomized Clinical Trial. *JAMA,* 315(5), pp. 469-479.

BACHERT C, GEVAERT P, HELLINGS P, 2017a. Biotherapeutics in Chronic Rhinosinusitis with and without Nasal Polyps. *The Journal of Allergy and Clinical Immunology. In Practice,* 5(6), pp. 1512-1516.

BACHERT C, SOUSA AR, LUND VJ, SCADDING GK, GEVAERT P, NASSER S, DURHAM SR, CORNET ME, KARIYAWASAM, HH, GILBERT J, AUSTIN D, MAXWELL AC, MARSHALL RP, FOKKENS WJ. 2017b. Reduced need for surgery in severe nasal polyposis with mepolizumab: Randomized trial. *The Journal of Allergy and Clinical Immunology,* 140(4), pp. 1024-1031.e14.

BACHERT C, HAN JK, DESROSIERS M, HELLINGS PW, AMIN N, LEE SE, MULLOL J, GREOS LS, BOSSO JV, LAIDLAW TM, CERVIN AU, MASPERO JF, HOPKINS C, OLZE H, CANONICA GW, PAGGIARO P, CHO SH, FOKKENS WJ, FUJIEDA S, ZHANG M, LU X, FAN C, DRAIKIWICZ S, KAMAT SA, KHAN A, PIROZZI G, PATEL N, GRAHAM NMH., RUDDY M, STAUDINGER H, WEINREICH D, STAHL N, YANCOPOULOS GD, MANNENT LP. 2019. Efficacy and safety of dupilumab in patients with severe chronic rhinosinusitis with nasal polyps (LIBERTY NP SINUS-24 and LIBERTY NP SINUS-52): results from two multicentre, randomised, double-blind, placebo-controlled, parallel-group phase 3 trials. *Lancet (London, England),* 394(10209), pp. 1638-1650.

BANERJI A, PICCIRILLO JF, THAWLEY SE, LEVITT RG, SCHECHTMAN KB, KRAMPER MA, HAMILOS DL. 2007. Chronic rhinosinusitis patients with polyps or polypoid mucosa have a greater burden of illness. *American Journal of Rhinology,* 21(1), pp. 19-26.

BARNES PJ. 1998. Anti-inflammatory actions of glucocorticoids: molecular mechanisms. *Clinical Science (London, England: 1979),* 94(6), pp. 557-572.

BAROODY FM. 2007. Mucociliary transport in chronic rhinosinusitis. *Clinical Allergy and Immunology,* 20, pp. 103-119.

BARSHAK MB, DURAND ML. 2017. The role of infection and antibiotics in chronic rhinosinusitis. *Laryngoscope Investigative Otolaryngology,* 2(1), pp. 36-42.

BENNINGER MS, 1992. Rhinitis, Sinusitis, and Their Relationships to Allergies. *American Journal of Rhinology,* 6(2), pp. 37-43.

BENNINGER MS. KHALID AN, BENNINGER RM, SMITH TL. 2010. Surgery for chronic rhinosinusitis may improve sleep and sexual function. *The Laryngoscope,* 120(8), pp. 1696-1700.

BENNINGER MS, HOLY CE. 2014. The Impact of Endoscopic Sinus Surgery on Health Care Use in Patients with Respiratory Comorbidities. *Otolaryngology–Head and Neck Surgery,* 151(3), pp. 508-515.

BENSCH GW. 2016. Safety of intranasal corticosteroids. *Annals of Allergy, Asthma & Immunology: Official Publication of the American College of Allergy, Asthma, & Immunology,* 117(6), pp. 601-605.

BERLUCCHI M, CASTELNUOVO P, VINCENZI A, MORRA B, PASQUINI E. 2009. Endoscopic outcomes of resorbable nasal packing after functional endoscopic sinus surgery: a multicenter prospective randomized controlled study. *European archives of oto-rhino-laryngology: official journal of the European Federation of Oto-Rhino-Laryngological Societies (EUFOS): affiliated with the German Society for Oto-Rhino-Laryngology - Head and Neck Surgery,* 266(6), pp. 839-845.

BERRETTINI S, CARABELLI A, SELLARI-FRANCESCHINI S, BRUSCHINI L, ABRUZZESE A, QUARTIERI F, SCONOSCIUTO F. 1999. Perennial allergic rhinitis and chronic sinusitis: correlation with rhinologic risk factors. *Allergy,* 54(3), pp. 242-248.

BEULE AG, SCHARF C, BIEBLER K, GÖPFERICH A, STEINMEIER E, WOLF E, HOSEMANN W, KAFTAN H. 2008. Effects of topically applied dexamethasone on mucosal wound healing using a drug-releasing stent. *The Laryngoscope,* 118(11), pp. 2073-2077.

BHATTACHARYYA N. 2003. The Economic Burden and Symptom Manifestations of Chronic Rhinosinusitis. *American Journal of Rhinology,* 17(1), pp. 27-32.

BHATTACHARYYA N, LEE LN. 2010. Evaluating the diagnosis of chronic rhinosinusitis based on clinical guidelines and endoscopy. *Otolaryngology--Head and Neck Surgery: Official Journal of American Academy of Otolaryngology-Head and Neck Surgery,* 143(1), pp. 147-151.

BHATTACHARYYA N. 2011. Incremental Health Care Utilization and Expenditures for Chronic Rhinosinusitis in the United States. *Annals of Otology, Rhinology & Laryngology,* 120(7), pp. 423-427.

BIKHAZI N, LIGHT J, TRUITT T, SCHWARTZ M, CUTLER J. 2014. Standalone balloon dilation versus sinus surgery for chronic rhinosinusitis: a prospective, multicenter, randomized, controlled trial with 1-year follow-up. *American Journal of Rhinology & Allergy,* 28(4), pp. 323-329.

BIZAKI AJ, TAULU R, NUMMINEN J, RAUTIAINEN M. 2014. Quality of life after endoscopic sinus surgery or balloon sinuplasty: a randomized clinical study. *Rhinology,* 52(4), pp. 300–305.

BIZAKI AJ, NUMMINEN J, TAULU R, RAUTIAINEN M. 2016. Decrease of nasal airway resistance and alleviations of symptoms after balloon sinuplasty in patients with isolated chronic rhinosinusitis: a prospective, randomised clinical study. *Clinical otolaryngology: official journal of ENT-UK; official journal of Netherlands Society for Oto-Rhino-Laryngology & Cervico-Facial Surgery,* 41(6), pp. 673-680.

BLACKWELL DL, LUCAS JW, CLARKE TC. 2014. Summary health statistics for U.S. adults: national health interview survey, 2012. *Vital and Health Statistics. Series 10, Data from the National Health Survey,* (260), pp. 1-161.

BLOMQVIST EH, LUNDBLAD L, BERGSTEDT H, STJÄRNE P. 2009. A randomized prospective study comparing medical and medical-surgical treatment of nasal polyposis by CT. *Acta Oto-Laryngologica,* 129(5), pp. 545-549.

BLOUNT A, ZHANG S, CHESTNUT M, HIXON B, SKINNER D, SORSCHER EJ, WOODWORTH BA. 2011. Transepithelial ion transport is suppressed in hypoxic sinonasal epithelium. *The Laryngoscope,* 121(9), pp. 1929-1934.

BOASE S, FOREMAN A, CLELAND E, TAN L, MELTON-KREFT R, PANT H, HU FZ, EHRLICH GD, WORMALD P. 2013. The microbiome of chronic rhinosinusitis: culture, molecular diagnostics and biofilm detection. *BMC infectious diseases,* 13(1), pp. 210.

BOLGER WE, VAUGHAN WC. 2006. Catheter-based dilation of the sinus ostia: initial safety and feasibility analysis in a cadaver model. *American Journal of Rhinology,* 20(3), pp. 290-294.

BRANDSTED R, SINDWANI R. 2007. Impact of depression on disease-specific symptoms and quality of life in patients with chronic rhinosinusitis. *American Journal of Rhinology,* 21(1), pp. 50-54.

BRESCIANI M, PARADIS L, DES ROCHES A, VERNHET H, VACHIER I, GODARD P, BOUSQUET J, CHANEZ P. 2001. Rhinosinusitis in severe asthma. *The Journal of Allergy and Clinical Immunology,* 107(1), pp. 73-80.

BROWN CL, BOLGER WE. 2006. Safety and feasibility of balloon catheter dilation of paranasal sinus ostia: a preliminary investigation. *The Annals of Otology, Rhinology, and Laryngology,* 115(4), pp. 293-301.

BROŻEK JL, BOUSQUET J, AGACHE I, AGARWAL A, BACHERT C, BOSNIC-ANTICEVICH S, BRIGNARDELLO-PETERSEN R, CANONICA GW, CASALE T, CHAVANNES NH, CORREIA DE SOUSA J, CRUZ AA, CUELLO-GARCIA CA, DEMOLY P, DYKEWICZ M, ETXEANDIA-IKOBALTZETA I, FLOREZ I, FOKKENS W, FONSECA J, HELLINGS PW, KLIMEK L, KOWALSKI S, KUNA P, LAISAAR K, LARENAS-LINNEMANN DE, LØDRUP CARLSEN KC, MANNING PJ, MELTZER E, MULLOL J, MURARO A, O'HEHIR R, OHTA K, PANZNER P, PAPADOPOULOS N, PARK H, PASSALACQUA G, PAWANKAR R, PRICE D, RIVA JJ, ROLDÁN Y, RYAN D, SADEGHIRAD B, SAMOLINSKI B, SCHMID-GRENDELMEIER P, SHEIKH A, TOGIAS A, VALERO A, VALIULIS A, VALOVIRTA E, VENTRESCA M, WALLACE D, WASERMAN S, WICKMAN M, WIERCIOCH W, YEPES-NUÑEZ JJ, ZHANG L, ZHANG Y, ZIDARN M, ZUBERBIER T, SCHÜNEMANN HJ. 2017. Allergic Rhinitis and its Impact on Asthma (ARIA) guidelines-2016 revision. *The Journal of Allergy and Clinical Immunology,* 140(4), pp. 950-958.

BUSINCO LDR, MATTEI A, LAURINO S, ANGELONE AM, LAURIELLO M, CRESCENZI D, ALESSIA DM, RADICI M, BUSINCO ADR. 2016. Steroid-Eluting Ethmoidal Stent Versus Antero-Posterior Ethmoidectomy: Comparison of Efficacy and Safety in Allergic Patients. *Otolaryngologia Polska = The Polish Otolaryngology,* 70(2), pp. 6-12.

BUSTAMANTE-MARIN XM, OSTROWSKI LE. 2017. Cilia and Mucociliary Clearance. *Cold Spring Harbor Perspectives in Biology,* 9(4).

BUYSSCHAERT ID, GRULOIS V, ELOY P, JORISSEN M, ROMBAUX P, BERTRAND B, COLLET S, BOBIC S, VLAMINCK S., HELLINGS PW, LAMBRECHTS D. 2010. Genetic evidence for a role of IL33 in nasal polyposis. *Allergy,* 65(5), pp. 616-622.

CAI Y, CHAI D, WANG R, BAI N, LIANG B, LIU Y. 2011. Effectiveness and safety of macrolides in cystic fibrosis patients: a meta-analysis and systematic review. *The Journal of Antimicrobial Chemotherapy,* 66(5), pp. 968-978.

CAMPBELL RG. 2018. Risks and management of long-term corticosteroid use in chronic rhinosinusitis. *Current opinion in otolaryngology & head and neck surgery,* 26(1), pp. 1-7.

CASALE M, MOFFA A, CASSANO M, CARINCI F, LOPEZ MA, TRECCA EMC, TORRETTA S, RINALDI V, PIGNATARO L. 2018. Saline nasal irrigations for chronic rhinosinusitis: From everyday practice to evidence-based medicine. An update. *International Journal of Immunopathology and Pharmacology,* 32, pp. 1-6.

CATALANO PJ, THONG M, GARG V. 2009. The MicroFlow Spacer: A drug-eluting stent for the ethmoid sinus. *Operative Techniques in Otolaryngology-Head and Neck Surgery,* 20(2), pp. 108-113.

CATALANO P, THONG M, WEISS R, RIMASH T. 2011. The MicroFlow Spacer: A Drug-Eluting Stent for the Ethmoid Sinus. *Indian Journal of Otolaryngology and Head & Neck Surgery,* 63(3), pp. 279-284.

CAULLEY, THAVORN, RUDMIK, CAMERON, KILTY. 2015. Direct costs of adult chronic rhinosinusitis by using 4 methods of estimation: Results of the US Medical Expenditure Panel Survey. *The Journal of Allergy and Clinical Immunology,* 136(6), pp. 1517-1522.

CHEE L, GRAHAM SM, CAROTHERS DG, BALLAS ZK. 2001. Immune dysfunction in refractory sinusitis in a tertiary care setting. *The Laryngoscope,* 111(2), pp. 233-235.

CHEN J, JAMES LK, DAVIES AM, WU Y, RIMMER J, LUND VJ, CHEN J, MCDONNELL JM, CHAN, HUTCHINS, G, CHANG TW, SUTTON BJ, KARIYAWASAM HH, GOULD HJ. 2016. Antibodies and superantibodies in patients with chronic rhinosinusitis with nasal polyps. *The Journal of Allergy and Clinical Immunology* 139(4), pp 1195-1204

CHEN Y, DALES R, LIN M. 2003. The epidemiology of chronic rhinosinusitis in Canadians. *The Laryngoscope,* 113(7), pp. 1199-1205.

CHIARELLA SE, GRAMMER LC. 2017. Immune deficiency in chronic rhinosinusitis: screening and treatment. *Expert Review of Clinical Immunology,* 13(2), pp. 117-123.

CHONG LY, HEAD K, HOPKINS C, PHILPOTT C, SCHILDER AGM, BURTON MJ. 2016a. Intranasal steroids versus placebo or no intervention for chronic rhinosinusitis. *The Cochrane Database of Systematic Reviews,* 4, pp. CD011996.

CHONG LY, HEAD K, HOPKINS C. PHILPOTT C, BURTON MJ, SCHILDER AGM. 2016b. Different types of intranasal steroids for chronic rhinosinusitis. *The Cochrane Database of Systematic Reviews,* 4, pp. CD011993.

CHONG LY, HEAD K, HOPKINS C, PHILPOTT C, GLEW S, SCADDING G, BURTON MJ, SCHILDER AGM. 2016c. Saline irrigation for chronic rhinosinusitis. *The Cochrane Database of Systematic Reviews,* 4, pp. CD011995.

CHONG L, PIROMCHAI P, SHARP S, SNIDVONGS K, PHILPOTT C, HOPKINS C, BURTON MJ. 2020. Biologics for chronic rhinosinusitis. *The Cochrane Database of Systematic Reviews,* 2, pp. CD013513.

CHRISTENSEN DN, FRANKS ZG, MCCRARY HC, SALEH AA, CHANG EH. 2018. A Systematic Review of the Association between Cigarette Smoke Exposure and Chronic Rhinosinusitis. *Otolaryngology--Head and Neck Surgery: Official Journal of American Academy of Otolaryngology-Head and Neck Surgery,* 158(5), pp. 801-816.

CINGI C, BAYAR MULUK N, LEE JT. 2019. Current indications for balloon sinuplasty. *Current Opinion in Otolaryngology & Head and Neck Surgery,* 27(1), pp. 7-13.

CIPRANDI G, CIRILLO I, VIZZACCARO A, PALLESTRINI E, TOSCA MA. 2006. Decongestion test in patients with allergic rhinitis: functional evaluation of nasal airflow. *American Journal of Rhinology,* 20(2), pp. 224-226.

DALGORF DM, SACKS R, WORMALD P, NAIDOO Y, PANIZZA B, UREN B, BROWN C, CUROTTA J, SNIDVONGS K, HARVEY RJ. 2013. Image-guided surgery influences perioperative morbidity from endoscopic sinus surgery: a systematic review and meta-analysis. *Otolaryngology--Head and Neck Surgery: Official Journal of American Academy of Otolaryngology-Head and Neck Surgery,* 149(1), pp. 17-29.

DALZIEL K., STEIN K, ROUND A, GARSIDE R, ROYLE P. 2006. Endoscopic sinus surgery for the excision of nasal polyps: A systematic review of safety and effectiveness. *American Journal of Rhinology,* 20(5), pp. 506-519.

DAS S, BECKER AM, PERAKIS H, PROSSER JD, KOUNTAKIS SE. 2007. The effects of smoking on short-term quality of life outcomes in sinus surgery. *The Laryngoscope,* 117(12), pp. 2229-2232.

DE COCK J, ZANCA F, CANNING J, PAUWELS R, HERMANS R. 2015. A comparative study for image quality and radiation dose of a cone beam computed tomography scanner and a multislice computed tomography scanner for paranasal sinus imaging. *European Radiology,* 25(7), pp. 1891-1900.

DERENDORF H, MELTZER EO. 2008. Molecular and clinical pharmacology of intranasal corticosteroids: clinical and therapeutic implications. *Allergy,* 63(10), pp. 1292-1300.

DERYCKE L, EYERICH S. VAN CROMBRUGGEN K, PÉREZ-NOVO C, HOLTAPPELS G, DERUYCK N, GEVAERT P, BACHERT C. 2014. Mixed T Helper Cell Signatures in Chronic Rhinosinusitis with and without Polyps. *PloS one,* 9(6), e97581.

DESROSIERS MY, SALAS-PRATO M. 2001. Treatment of chronic rhinosinusitis refractory to other treatments with topical antibiotic therapy delivered by means of a large-particle nebulizer: results of a controlled trial. *Otolaryngology--Head and Neck Surgery: Official Journal of American Academy of Otolaryngology-Head and Neck Surgery,* 125(3), pp. 265-269.

DONG Z, YANG Z, WANG C. 2005. Expression of TLR2 and TLR4 messenger RNA in the epithelial cells of the nasal airway. *American Journal of Rhinology,* 19(3), pp. 236-239.

DONLAN RM, WILLIAM COSTERTON JW. 2002. Biofilms: Survival Mechanisms of Clinically Relevant Microorganisms. *Clinical Microbiology Reviews,* 15(2), pp. 167-193.

DOUGLAS R, BRUHN M, TAN L, OOI E, PSALTIS A, WORMALD P. 2007. Response of peripheral blood lymphocytes to fungal extracts and staphylococcal superantigen B in chronic rhinosinusitis. *The Laryngoscope,* 117(3), pp. 411-414.

DOUGLAS RG, PSALTIS AJ, RIMMER J, KURUVILLA T, CERVIN A, KUANG Y. 2019. Phase 1 clinical study to assess the safety of a novel drug delivery system providing long-term topical steroid therapy for chronic rhinosinusitis. *International Forum of Allergy & Rhinology,* 9(4), pp. 378-387.

DOULAPTSI M, PROKOPAKIS E, SEYS S, PUGIN B, STEELANT B, HELLINGS P. 2018. Visual analogue scale for sino-nasal symptoms severity correlates with sino-nasal outcome test 22: paving the way for a simple outcome tool of CRS burden. *Clinical and Translational Allergy,* 8, pp. 32.

DUODECIM AND THE FINNISH ASSOCIATION OF OTORHINOLARYNGOLOGY AND HEAD AND NECK SURGERY, Published: 22 May 2018-last update, Finnish current care guideline for sinusitis. Available: https://www.kaypahoito.fi/en/ccs00022 [Accessed 22 February 2020].

DURAISINGHAM SS, BUCKLAND M, DEMPSTER J, LORENZO L, GRIGORIADOU S, LONGHURST HJ. 2014. Primary vs. secondary antibody deficiency: clinical features and infection outcomes of immunoglobulin replacement. *PloS One,* 9(6), e100324.

EARLY SB, HISE K, HAN J, BORISH L, STEINKE JW. 2007. Hypoxia stimulates inflammatory and fibrotic responses from nasal-polyp derived fibroblasts. *The Laryngoscope,* 117(3), pp. 511-515.

EBBENS FA, SCADDING GK, BADIA L, HELLINGS PW, JORISSEN M, MULLOL J, CARDESIN A, BACHERT C, VAN ZELE THIBAUT P J, DIJKGRAAF MGW, LUND V, FOKKENS WJ. 2006. Amphotericin B nasal lavages: not a solution for patients with chronic rhinosinusitis. *The Journal of Allergy and Clinical Immunology,* 118(5), pp. 1149-1156.

EBBENS F, FOKKENS W. 2008. The mold conundrum in chronic rhinosinusitis: Where do we stand today? *Current Allergy and Asthma Reports,* 8(2), pp. 93-101.

EGGESBØ HB. 2006. Radiological imaging of inflammatory lesions in the nasal cavity and paranasal sinuses. *European Radiology,* 16(4), pp. 872-888.

EMANUEL IA, SHAH, S.B., 2000. Chronic rhinosinusitis: allergy and sinus computed tomography relationships. *Otolaryngology--Head and Neck Surgery: Official Journal of American Academy of Otolaryngology-Head and Neck Surgery,* 123(6), pp. 687-691.

FAKHRAN S, ALHILALI L, SREEDHER G, DOHATCU AC, LEE S, FERGUSON B, BRANSTETTER BF. 2014. Comparison of simulated cone beam computed tomography to conventional helical computed tomography for imaging of rhinosinusitis. *The Laryngoscope,* 124(9), pp. 2002-2006.

FEAZEL LM, ROBERTSON CE, RAMAKRISHNAN VR, FRANK DN. 2012. Microbiome complexity and Staphylococcus aureus in chronic rhinosinusitis. *The Laryngoscope,* 122(2), pp. 467-472.

FOKKENS W, LUND V, MULLOL J. 2007. European position paper on rhinosinusitis and nasal polyps 2007. *Rhinology. Supplement,* 20, pp. 1-136.

FOKKENS WJ, LUND VJ, MULLOL J, BACHERT C, ALOBID I, BAROODY F, COHEN N, CERVIN A, DOUGLAS R, GEVAERT P, GEORGALAS C, GOOSSENS H, HARVEY R, HELLINGS P, HOPKINS C, JONES N, JOOS G, KALOGJERA L, KERN B, KOWALSKI M, PRICE D, RIECHELMANN H, SCHLOSSER R, SENIOR B, THOMAS M, TOSKALA E, VOEGELS R, WANG DY, WORMALD PJ. 2012. European Position Paper on Rhinosinusitis and Nasal Polyps 2012. *Rhinology. Supplement,* 23, pp. 3 p preceding table of contents, 1-298.

FOKKENS, LUND, HOPKINS C, HELLINGS PW, KERN R, REITSMA S, TOPPILA-SALMI S, BERNAL-SPREKELSEN M, MULLOL J, ALOBID I, TEREZINHA ANSELMO-LIMA W, BACHERT C, BAROODY F, VON BUCHWALD C, CERVIN A, COHEN N, CONSTANTINIDIS J, DE GABORY L, DESROSIERS M, DIAMANT Z, DOUGLAS RG, GEVAERT PH, HAFNER A, HARVEY RJ, JOOS GF, KALOGJERA L, KNILL A, KOCKS JH, LANDIS BN, LIMPENS J, LEBEER S,LOURENCO O, MATRICARDI PM, MECO C, O MAHONY L, PHILPOTT CM. RYAN D, SCHLOSSER R, SENIOR B, SMITH TL, TEELING T, TOMAZIC PV, WANG DY, WANG D, ZHANG L, AGIUS AM, AHLSTROM-EMANUELSSON C, ALABRI R, ALBU S, ALHABASH S, ALEKSIC A, ALOULAH M, AL-QUDAH M, ALSALEH S, BABAN MA, BAUDOIN T, BALVERS T, BATTAGLIA T, BEDOYA JD, BEULE A, BOFARES KM, BRAVERMAN I, BROZEK-MADRY E, RICHARD B, CALLEJAS C, CARRIE S, CAULLEY L, CHUSSI D, DE CORSO E, COSTE A, LAL D, EL HADI U, ELFAROUK A, ELOY PH, FARROKHI S, FELISATI G, FERRARI MD, FISHCHUK R, GRAYSON W, GONCALVES PM, GRDINIC B, GRGIC V, HAMIZAN AW, HEINICHEN JV, HUSAIN S, PING TI, IVASKA J, JAKIMOVSKA F, JOVANCEVIC L, KAKANDE E, KAMEL R, KARPISCHENKO S, KARIYAWASAM HH, KJELDSEN A, KLIMEK L, KIM SW, LETORT JJ, LOPATIN A, MAHDJOUBI A, NETKOVSKI J, NYENBUE TSHIPUKANE D, OBANDO-VALVERDE A, OKANO M, ONERCI M, ONG YK, ORLANDI R, OUENNOUGHY K, OZKAN M, PERIC A, PLZAK J, PROKOPAKIS E, PREPAGERAN N, PSALTIS A, PUGIN,B, RAFTOPULOS M, ROMBAUX P, SAHTOUT S, SARAFOLEANU C, SEARYOH K, RHEE C, SHI J, SHKOUKANI M, SHUKURYAN AK, SICAK M, SMYTH D, SNIDVONGS K, SOKLIC KOSAK T, STJARNE P. 2020. European Position Paper on Rhinosinusitis and Nasal Polyps 2020. *Rhinology,* 58(Suppl S29), pp. 1-464.

FOREMAN A, JERVIS-BARDY J, WORMALD P. 2011. Do biofilms contribute to the initiation and recalcitrance of chronic rhinosinusitis? *The Laryngoscope,* 121(5), pp. 1085-1091.

FORWITH KD, CHANDRA RK, YUN PT, MILLER SK, JAMPEL HD. 2011. ADVANCE: A multisite trial of bioabsorbable steroid-eluting sinus implants. *The Laryngoscope,* 121(11), pp. 2473-2480.

FORWITH KD, HAN JK, STOLOVITZKY JP, YEN DM, CHANDRA RK, KARANFILOV B, MATHENY KE, STAMBAUGH JW, GAWLICKA AK. 2016. RESOLVE: bioabsorbable steroid-eluting sinus implants for in-office treatment of recurrent sinonasal polyposis after sinus surgery: 6-month outcomes from a randomized, controlled, blinded study. *International Forum of Allergy & Rhinology,* 6(6), pp. 573-581.

GEORGALAS C, CORNET M, ADRIAENSEN G, REINARTZ S, HOLLAND C, PROKOPAKIS E, FOKKENS W. 2014. Evidence-based Surgery for Chronic Rhinosinusitis with and without Nasal Polyps. *Current Allergy and Asthma Reports,* 14(4), pp. 1-7.

GEVAERT P, VAN BRUAENE N, CATTAERT T, VAN STEEN K, VAN ZELE T, ACKE F, DE RUYCK N, BLOMME K, SOUSA AR, MARSHALL RP, BACHERT C. 2011. Mepolizumab, a humanized anti-IL-5 mAb, as a treatment option for severe nasal polyposis. *The Journal of Allergy and Clinical Immunology,* 128(5), pp. 989-8.

GEVAERT P, CALUS L, VAN ZELE T, BLOMME K, DE RUYCK N, BAUTERS W, HELLINGS P, BRUSSELLE G, DE BACQUER D, VAN CAUWENBERGE P, BACHERT C. 2013. Omalizumab is effective in allergic and nonallergic patients with nasal polyps and asthma. *The Journal of Allergy and Clinical Immunology,* 131(1), pp. 110-116.e1.

GLIKLICH RE, METSON R. 1995. The health impact of chronic sinusitis in patients seeking otolaryngologic care. *Otolaryngology--Head and Neck Surgery: Official Journal of American Academy of Otolaryngology-Head and Neck Surgery,* 113(1), pp. 104-109.

GOLDSTEIN-DARUECH N, COPE EK, ZHAO K, VUKOVIC K, KOFONOW JM, DOGHRAMJI L, GONZÁLEZ B, CHIU AG, KENNEDY DW, PALMER JN, LEID JG, KREINDLER JL, COHEN NA. 2011. Tobacco smoke mediated induction of sinonasal microbial biofilms. *PloS One,* 6(1), e15700.

GOSHTASBI K, ABOUZARI M, ABIRI A, YASAKA T, SAHYOUNI R, BITNER B, TAJUDEEN BA, KUAN EC. 2019. Efficacy of steroid-eluting stents in management of chronic rhinosinusitis after endoscopic sinus surgery: updated meta-analysis. *International Forum of Allergy & Rhinology*. 9(12), 1443-1450.

GREGURIĆ T, TRKULJA V, BAUDOIN T, GRGIĆ M, ŠMIGOVEC I, KALOGJERA L. 2016. Differences in the Sino-Nasal Outcome Test 22 and visual analog scale symptom scores in chronic rhinosinusitis with and without nasal polyps. *American Journal of Rhinology & Allergy,* 30(2), pp. 107-112.

GROBLER A, WEITZEL EK, BUELE A, JARDELEZA C, CHEONG YC, FIELD J, WORMALD P. 2008. Pre- and postoperative sinus penetration of nasal irrigation. *The Laryngoscope,* 118(11), pp. 2078-2081.

GRYMER LF. 2000. Clinical applications of acoustic rhinometry. *Rhinology. Supplement,* 16, pp. 35-43.

GUDIS D, ZHAO K, COHEN NA. 2012. Acquired cilia dysfunction in chronic rhinosinusitis. *American Journal of Rhinology & Allergy,* 26(1), pp. 1-6.

HA T, VALENTINE R, MORATTI S, HANTON L, ROBINSON S, WORMALD P. 2018. The efficacy of a novel budesonide chitosan gel on wound healing following endoscopic sinus surgery. *International Forum of Allergy & Rhinology,* 8(3), pp. 435-443.

HAN JK, FORWITH KD, SMITH TL, KERN RC, BROWN WJ, MILLER SK, OW RA, POETKER DM, KARANFILOV B, MATHENY KE, STAMBAUGH J, GAWLICKA AK. 2014. RESOLVE: a randomized, controlled, blinded study of bioabsorbable steroid-eluting sinus implants for in-office treatment of recurrent sinonasal polyposis. *International Forum of Allergy & Rhinology,* 4(11), pp. 861-870.

HANIF J, JAWAD SS, ECCLES R. 2000. The nasal cycle in health and disease. *Clinical Otolaryngology and Allied Sciences,* 25(6), pp. 461-467.

HARVEY R, HANNAN SA, BADIA L, SCADDING G. 2007. Nasal saline irrigations for the symptoms of chronic rhinosinusitis. *The Cochrane Database of Systematic Reviews,* (3), pp. CD006394.

HARVEY RJ, GODDARD JC, WISE S.K, SCHLOSSER RJ. 2008. Effects of endoscopic sinus surgery and delivery device on cadaver sinus irrigation. *Otolaryngology--Head and Neck*

Surgery: Official Journal of American Academy of Otolaryngology-Head and Neck Surgery, 139(1), pp. 137-142.

HASTAN D, FOKKENS W, BACHERT C, TOMASSEN P, NEWSON R, JARVIS D, BISLIMOVSKA J, BOCKELBRINK A, BOUSQUET P, BOUSQUET J, BROZEK G, BRUNO A, DAHLEN S, FORSBERG B, GUNNBJORNSDOTTIR M, KASPER L, KRAMER U, KOWALSKI M, LANGE B, LUNDBACK B, SALAGEAN M, TODO-BOM A, TOSKALA E, ZUBERBIER T. 2011. Chronic rhinosinusitis in Europe - an underestimated disease. A GA(2)LEN study. *Allergy* 66(9), pp. 1216-23.

HEAD K, CHONG LY, HOPKINS C, PHILPOTT C, BURTON MJ, SCHILDER AGM. 2016a. Short-course oral steroids alone for chronic rhinosinusitis. *The Cochrane Database of Systematic Reviews,* 4, pp. CD011991.

HEAD K, CHONG LY, PIROMCHAI P, HOPKINS C, PHILPOTT C, SCHILDER AGM, BURTON MJ. 2016b. Systemic and topical antibiotics for chronic rhinosinusitis. *The Cochrane Database of Systematic Reviews,* 4, pp. CD011994.

HEDMAN J, KAPRIO J, POUSSA T, NIEMINEN MM. 1999. Prevalence of asthma, aspirin intolerance, nasal polyposis and chronic obstructive pulmonary disease in a population-based study. *International Journal of Epidemiology,* 28(4), pp. 717-722.

HERATH SC, POOLE P. 2013. Prophylactic antibiotic therapy for chronic obstructive pulmonary disease (COPD). *The Cochrane Database of Systematic Reviews,* (11), pp. CD009764.

HILBERG O, JACKSON AC, SWIFT DL, PEDERSEN OF. 1989. Acoustic rhinometry: evaluation of nasal cavity geometry by acoustic reflection. *Journal of Applied Physiology (Bethesda, Md.: 1985),* 66(1), pp. 295-303.

HOPKINS C, BROWNE JP, SLACK R, LUND V, TOPHAM J, REEVES B, COPLEY L, BROWN P, VAN DER MEULEN J. 2006. The national comparative audit of surgery for nasal polyposis and chronic rhinosinusitis. *Clinical otolaryngology: official journal of ENT-UK; official journal of Netherlands Society for Oto-Rhino-Laryngology & Cervico-Facial Surgery,* 31(5), pp. 390-398.

HOPKINS C, BROWNE JP, SLACK R, LUND V, BROWN P. 2007. The Lund-Mackay staging system for chronic rhinosinusitis: how is it used and what does it predict? *Otolaryngology--Head and Neck Surgery: Official Journal of American Academy of Otolaryngology-Head and Neck Surgery,* 137(4), pp. 555-561.

HOPKINS C, GILLETT S, SLACK R, LUND VJ, BROWNE JP. 2009. Psychometric validity of the 22-item Sinonasal Outcome Test. *Clinical Otolaryngology,* 34(5), pp. 447-454.

HOX V, DELRUE S, SCHEERS H, ADAMS E, KEIRSBILCK S, JORISSEN M, HOET PH, VANOIRBEEK JA, NEMERY B, HELLINGS PW. 2012. Negative impact of occupational exposure on surgical outcome in patients with rhinosinusitis. *Allergy,* 67(4), pp. 560-565.

HULSE KE., NORTON JE, SUH L, ZHONG Q, MAHDAVINIA M, SIMON P, KERN RC, CONLEY DB, CHANDRA RK, TAN BK, PETERS AT, GRAMMER LC, HARRIS KE, CARTER RG, KATO A, SCHLEIMER RP. 2013. Chronic rhinosinusitis with nasal polyps is characterized by B-cell inflammation and EBV-induced protein 2 expression. *The Journal of Allergy and Clinical Immunology,* 131(4), pp. 1075-1083.e7.

HUMBERT M, BUSSE W, HANANIA NA, LOWE PJ, CANVIN J, ERPENBECK VJ, HOLGATE S. 2014. Omalizumab in asthma: an update on recent developments. *The Journal of Allergy and Clinical Immunology. In Practice,* 2(5), pp. 525–536.e1.

HYTÖNEN M, HAMMAREN-MALMI S, MYLLER J, MÄKELÄ M, PENTTILÄ E, PESSI T, PUHAKKA T, RAAPPANA A, TAULU R, TOPPILA-SALMI S, VIRKKULA P. 2020. Translation, cross-cultural adaptation, and validation of the sino-nasal outcome test

(snot)-22 for Finnish patients. Eur Arch Otorhinolaryngol, doi: 10.1007/s00405-020-06297-w. Online ahead of print.

ILLING EA, WOODWORTH BA. 2014. Management of the upper airway in cystic fibrosis. *Current Opinion in Pulmonary Medicine,* 20(6), pp. 623-631.

JARVIS D, NEWSON R, LOTVALL J, HASTAN D, TOMASSEN P, KEIL T, GJOMARKAJ M, FORSBERG B, GUNNBJORNSDOTTIR M, MINOV J, BROZEK G, DAHLEN SE, TOSKALA E, KOWALSKI ML, OLZE H, HOWARTH P, KRÄMER U, BAELUM J, LOUREIRO C, KASPER L, BOUSQUET J., BOUSQUET J, BACHERT C, FOKKENS W, BURNEY P. 2012. Asthma in adults and its association with chronic rhinosinusitis: the GA2LEN survey in Europe. *Allergy,* 67(1), pp. 91-98.

JOHANSSON L, AKERLUND A, HOLMBERG K, MELÉN I, BENDE M. 2003. Prevalence of nasal polyps in adults: the Skövde population-based study. *The Annals of Otology, Rhinology, and Laryngology,* 112(7), pp. 625-629.

JONES N. 2001. The nose and paranasal sinuses physiology and anatomy. *Advanced Drug Delivery Reviews,* 51(1-3), pp. 5-19.

KALISH L, SNIDVONGS K, SIVASUBRAMANIAM R, COPE D, HARVEY RJ. 2012. Topical steroids for nasal polyps. *The Cochrane database of systematic reviews,* 12, pp. CD006549.

KANJANAWASEE D, SERESIRIKACHORN K, CHITSUTHIPAKORN W, SNIDVONGS K. 2018. Hypertonic Saline Versus Isotonic Saline Nasal Irrigation: Systematic Review and Meta-analysis. *American Journal of Rhinology & Allergy,* 32(4), pp. 269-279.

KATO A, PETERS A, SUH L, CARTER R, HARRIS, KE, CHANDRA R, CONLEY D, GRAMMER LC, KERN R, SCHLEIMER RP. 2008. Evidence of a role for B cell–activating factor of the TNF family in the pathogenesis of chronic rhinosinusitis with nasal polyps. *The Journal of Allergy and Clinical Immunology,* 121(6), pp. 1385-1392.e2.

KATOTOMICHELAKIS M, SIMOPOULO, E, TRIPSIANIS G, ZHANG N, DANIELIDES G, GOUMA P, BACHERT C, DANIELIDES V. 2014. The effects of smoking on quality of life recovery after surgery for chronic rhinosinusitis. *Rhinology,* 52(4), pp. 341-347.

KEIR J. 2009. Why do we have paranasal sinuses? *The Journal of Laryngology and Otology,* 123(1), pp. 4-8.

KENNEDY DW, KUHN FA, HAMILOS DL, ZINREICH SJ, BUTLER D, WARSI G, PFISTER PJ, TAVAKKOL A. 2005. Treatment of chronic rhinosinusitis with high-dose oral terbinafine: a double blind, placebo-controlled study. *The Laryngoscope,* 115(10), pp. 1793-1799.

KERN RC, CONLEY DB, WALSH W, CHANDRA R, KATO A, TRIPATHI-PETERS A, GRAMMER LC, SCHLEIMER RP. 2008. Perspectives on the etiology of chronic rhinosinusitis: an immune barrier hypothesis. *American Journal of Rhinology,* 22(6), pp. 549-559.

KERN RC, STOLOVITZKY JP, SILVERS SL, SINGH A, LEE JT, YEN DM, ILORETA AMC, LANGFORD FPJ, KARANFILOV B, MATHENY KE, STAMBAUGH JW, GAWLICKA AK. 2018. A phase 3 trial of mometasone furoate sinus implants for chronic sinusitis with recurrent nasal polyps. *International Forum of Allergy & Rhinology,* 8(4), pp. 471-481.

KHALIL, H.S. and NUNEZ, D.A., 2006. Functional endoscopic sinus surgery for chronic rhinosinusitis. *The Cochrane Database of Systematic Reviews,* (3), pp. CD004458.

KIM DW, CHO SH. 2017. Emerging Endotypes of Chronic Rhinosinusitis and Its Application to Precision Medicine. *Allergy, Asthma & Immunology Research,* 9(4), pp. 299-306.

KIM JH, CHO C, LEE E., SUH YS, CHOI BI, KIM KS. 2016. Prevalence and risk factors of chronic rhinosinusitis in South Korea according to diagnostic criteria. *Rhinology,* 54(4), pp. 329-335.

KIRTSREESAKUL V, RUTTANAPHOL S. 2008. The relationship between allergy and rhinosinusitis. *Rhinology,* 46(3), pp. 204-208.

KLIMEK L, BERGMANN K, BIEDERMANN T, BOUSQUET J, HELLINGS P, JUNG K, MERK H, OLZE H, SCHLENTER W, STOCK P, RING J, WAGENMANN M, WEHRMANN W, MÖSGES R, PFAAR O. 2017. Visual analogue scales (VAS): Measuring instruments for the documentation of symptoms and therapy monitoring in cases of allergic rhinitis in everyday health care: Position Paper of the German Society of Allergology (AeDA) and the German Society of Allergy and Clinical Immunology (DGAKI), ENT Section, in collaboration with the working group on Clinical Immunology, Allergology and Environmental Medicine of the German Society of Otorhinolaryngology, Head and Neck Surgery (DGHNOKHC). *Allergo Journal International,* 26(1), pp. 16-24.

KLOSSEK JM, NEUKIRCH F, PRIBIL C, JANKOWSKI R, SERRANO E, CHANAL I, EL HASNAOUI A. 2005. Prevalence of nasal polyposis in France: a cross-sectional, case-control study. *Allergy,* 60(2), pp. 233-237.

KOWALSKI ML, AGACHE I, BAVBEK S, BAKIRTAS A, BLANCA M, BOCHENEK G, BONINI M, HEFFLER E, KLIMEK L, LAIDLAW TM, MULLOL J, NIŻANKOWSKA-MOGILNICKA E, PARK H, SANAK M, SANCHEZ-BORGES M, SANCHEZ-GARCIA S, SCADDING G, TANIGUCHI M, TORRES MJ, WHITE AA, WARDZYŃSKA A. 2019. Diagnosis and management of NSAID-Exacerbated Respiratory Disease (N-ERD)-a EAACI position paper. *Allergy,* 74(1), pp. 28-39.

KRZESKI A, GALEWICZ A. CHMIELEWSKI R, KISIEL M. 2011. Influence of cigarette smoking on endoscopic sinus surgery long-term outcomes. *Rhinology,* 49(5), pp. 577-582.

KUYKEN W, et al. 1995. The World Health Organization Quality of Life assessment (WHOQOL): position paper from the World Health Organization. *Social Science & Medicine (1982),* 41(10), pp. 1403-1409.

LAM K, SCHLEIMER R, KERN RC. 2015. The Etiology and Pathogenesis of Chronic Rhinosinusitis: a Review of Current Hypotheses. *Current Allergy and Asthma Reports,* 15(7), pp. 41.

LAM K, KERN RC, LUONG A. 2016. Is there a future for biologics in the management of chronic rhinosinusitis? *International Forum of Allergy & Rhinology,* 6(9), pp. 935-942.

LANE AP, TRUONG-TRAN QA, SCHLEIMER RP. 2006. Altered expression of genes associated with innate immunity and inflammation in recalcitrant rhinosinusitis with polyps. *American Journal of Rhinology,* 20(2), pp. 138-144.

LAVIGNE F, MILLER SK, GOULD AR, LANIER BJ, ROMETT JL. 2014. Steroid-eluting sinus implant for in-office treatment of recurrent nasal polyposis: a prospective, multicenter study. *International Forum of Allergy & Rhinology,* 4(5), pp. 381-389.

LEE RJ, COHEN NA. 2014. Bitter and sweet taste receptors in the respiratory epithelium in health and disease. *Journal of Molecular Medicine (Berlin, Germany),* 92(12), pp. 1235-1244.

LEE WH, HONG S, KIM HJ, AHN S, RHEE C, LEE CH, KIM J. 2015. Effects of cigarette smoking on rhinologic diseases: Korean National Health and Nutrition Examination Survey 2008-2011. *International Forum of Allergy & Rhinology,* 5(10), pp. 937-943.

LEOPOLD DA, ELKAYAM D, MESSINA JC, KOSIK-GONZALEZ C, DJUPESLAND PG, MAHMOUD RA. 2019. NAVIGATE II: Randomized, double-blind trial of the exhalation delivery system with fluticasone for nasal polyposis. *The Journal of Allergy and Clinical Immunology,* 143(1), pp. 126-134.e5.

LEUNG RM, DINNIE K, SMITH TL. 2014. When do the risks of repeated courses of corticosteroids exceed the risks of surgery? *International Forum of Allergy & Rhinology,* 4(11), pp. 871-876.

LEVY JM, MARINO MJ, MCCOUL ED. 2016. Paranasal Sinus Balloon Catheter Dilation for Treatment of Chronic Rhinosinusitis: A Systematic Review and Meta-analysis. *Otolaryngology--Head and Neck Surgery: Official Journal of American Academy of Otolaryngology-Head and Neck Surgery,* 154(1), pp. 33-40.

LITVACK JR, FONG K, MACE J, JAMES KE, SMITH TL. 2008. Predictors of olfactory dysfunction in patients with chronic rhinosinusitis. *The Laryngoscope,* 118(12), pp. 2225-2230.

LLEWELYN M, COHEN J. 2002. Superantigens: microbial agents that corrupt immunity. *The Lancet. Infectious Diseases,* 2(3), pp. 156-162.

LUND VJ, MACKAY IS. 1993. Staging in rhinosinusitis. *Rhinology,* 31(4), pp. 183-184.

LUND V, BLACK J, SZABÓ LZ, SCHREWELIUS C, AKERLUND A. 2004. Efficacy and tolerability of budesonide aqueous nasal spray in chronic rhinosinusitis patients. *Rhinology,* 42(2), pp. 57-62.

LUNDBERG JO, FARKAS-SZALLASI T, WEITZBERG E, RINDER J, LIDHOLM J, ANGGÅARD A, HÖKFELT T, LUNDBERG JM, ALVING K. 1995. High nitric oxide production in human paranasal sinuses. *Nature Medicine,* 1(4), pp. 370-373.

LUONG A, OW RA, SINGH A, WEISS RL, HAN JK, GERENCER R, STOLOVITZKY JP, STAMBAUGH JW, RAMAN A. 2018. Safety and Effectiveness of a Bioabsorbable Steroid-Releasing Implant for the Paranasal Sinus Ostia. *JAMA Otolaryngology-- Head & Neck Surgery,* 144(1), pp. 28-35.

MAFEE M, TRAN B, CHAPA A. 2006. Imaging of rhinosinusitis and its complications. *Clinical Reviews in Allergy & Immunology,* 30(3), pp. 165-185.

MAHAKIT P, PUMHIRUN P. 1995. A preliminary study of nasal mucociliary clearance in smokers, sinusitis and allergic rhinitis patients. *Asian Pacific Journal of Allergy and Immunology,* 13(2), pp. 119-121.

MALIK Z, ROSCIOLI E, MURPHY J, OU J, BASSIOUNI A, WORMALD P, VREUGDE S. 2015. Staphylococcus aureus impairs the airway epithelial barrier in vitro. *International Forum of Allergy & Rhinology,* 5(6), pp. 551-556.

MANZEY D, RÖTTGER S, BAHNER-HEYNE JE, SCHULZE-KISSING D, DIETZ A, MEIXENSBERGER J, STRAUSS G. 2009. Image-guided navigation: the surgeon's perspective on performance consequences and human factors issues. *The international journal of medical robotics + computer assisted surgery: MRCAS,* 5(3), pp. 297-308.

MARPLE BF, SMITH TL, HAN JK, GOULD AR, JAMPEL HD, STAMBAUGH JW, MUGGLIN AS. 2012. Advance II: a prospective, randomized study assessing safety and efficacy of bioabsorbable steroid-releasing sinus implants. *Otolaryngology--Head and Neck Surgery: Official Journal of American Academy of Otolaryngology-Head and Neck Surgery,* 146(6), pp. 1004-1011.

MASCIA K, HASELKORN T, DENIZ YM, MILLER DP, BLEECKER ER, BORISH L. 2005. Aspirin sensitivity and severity of asthma: evidence for irreversible airway obstruction in patients with severe or difficult-to-treat asthma. *The Journal of Allergy and Clinical Immunology,* 116(5), pp. 970-975.

MAZZA JM, LIN SY. 2016. Primary immunodeficiency and recalcitrant chronic sinusitis: a systematic review. *International Forum of Allergy & Rhinology,* 6(10), pp. 1029-1033.

MCCUSKER C, UPTON J, WARRINGTON R. 2018. Primary immunodeficiency. *Allergy, Asthma, and Clinical Immunology: Official Journal of the Canadian Society of Allergy and Clinical Immunology,* 14(Suppl 2), pp. 61.

MCMAINS KC.,2008. Safety in endoscopic sinus surgery. *Current Opinion in Otolaryngology & Head and Neck Surgery,* 16(3), pp. 247-251.

MELROY CT, KUHN FA. 2009. Safety of Ethmoid Sinus Drug-Eluting Catheter Insertion. *Annals of Otology, Rhinology & Laryngology,* 118(10), pp. 708-713.

MENG J, ZHOU P, LIU Y, LIU F, YI X, LIU S, HOLTAPPELS G, BACHERT C, ZHANGN. 2013. The Development of Nasal Polyp Disease Involves Early Nasal Mucosal Inflammation and Remodelling. *PloS one,* 8(12), e82373.

MILJKOVIC D, PSALTIS A, WORMALD P, VREUGDE S. 2016. T regulatory and Th17 cells in chronic rhinosinusitis with polyps. *International Forum of Allergy & Rhinology,* 6(8), pp. 826-834.

MIN J, NAYAK JV, HULSE KE, STEVENS WW, RAJU PA, HUANG JH, SUH LA, VAN ROEY GA, NORTON JE, CARTER RG, PRICE CPE, WEIBMAN AR, RASHAN AR, GHOSN EE, PATEL ZM, HOMMA T, CONLEY DB, WELCH KC, SHINTANI-SMITH S, PETERS AT, GRAMMER LC, HARRIS KE, KATO A, HWANG PH, KERN RC, HERZENBERG LA, SCHLEIMER RP, TAN BK. 2017. Evidence for altered levels of IgD in the nasal airway mucosa of patients with chronic rhinosinusitis. *The Journal of Allergy and Clinical Immunology,* 140(6), pp. 1562-1571.e5.

MINNI A, DRAGONETTI A, SCIUTO A, CAVALIERE C, ROSATI D, AZIMONTI D, FRANZETTI A. 2018a. Use of balloon catheter dilation vs. traditional endoscopic sinus surgery in management of light and severe chronic rhinosinusitis of the frontal sinus: a multicenter prospective randomized study. *European Review for Medical and Pharmacological Sciences,* 22(2), pp. 285-293.

MINNI A, DRAGONETTI A, SCIUTO A, ROSATI D, CAVALIERE C, RALLI M, AZIMONTI D, FRANZETTI A, DE VINCENTIIS M. 2018b. Use of balloon catheter dilation and steroid-eluting stent in light and severe rhinosinusitis of frontal sinus: a multicenter retrospective randomized study. *European review for medical and pharmacological sciences,* 22(21), pp. 7482-7491.

MOZZO P, PROCACCI C, TACCONI A, TINAZZI MARTINI P, BERGAMO ANDREIS IA. 1998. A new volumetric CT machine for dental imaging based on the cone-beam technique: preliminary results. *European Radiology,* 8(9), pp. 1558-1564.

MURR AH, SMITH TL, HWANG PH, BHATTACHARYYA N, LANIER BJ, STAMBAUGH JW, MUGGLIN AS. 2011. Safety and efficacy of a novel bioabsorbable, steroid-eluting sinus stent. *International Forum of Allergy & Rhinology,* 1(1), pp. 23-32.

NAGARKAR DR, POPOSKI JA, TAN BK, COMEAU MR, PETERS AT, HULSE KE, SUH LA, NORTON J, HARRIS KE, GRAMMER LC, CHANDRA RK, CONLEY DB, KERN RC, SCHLEIMER RP, KATO A. 2013. Thymic stromal lymphopoietin activity is increased in nasal polyps of patients with chronic rhinosinusitis. *The Journal of Allergy and Clinical Immunology,* 132(3), pp. 593-600.e12.

NGOC HA T, VALENTINE R, MORATTI S, ROBINSON S, HANTON L, WORMALD P. 2013. A blinded randomized controlled trial evaluating the efficacy of chitosan gel on ostial stenosis following endoscopic sinus surgery. *International Forum of Allergy & Rhinology,* 3(7), pp. 573-580.

NOMURA K, OBATA K, KEIRA T, MIYATA R, HIRAKAWA S, TAKANO K, KOHNO T, SAWADA N, HIMI T, KOJIMA T. 2014. Pseudomonas aeruginosa elastase causes transient disruption of tight junctions and downregulation of PAR-2 in human nasal epithelial cells. *Respiratory Research,* 15, pp. 21.

NOON E, HOPKINS C. 2016. Review article: outcomes in endoscopic sinus surgery. *BMC Ear, Nose and Throat Disorders,* 16(1), pp. 1-10.

NUMMINEN J, DASTIDAR P, HEINONEN T, KARHUKETO T, RAUTIAINEN M. 2003. Reliability of acoustic rhinometry. *Respiratory Medicine,* 97(4), pp. 421-427.

OKUSHI T, NAKAYAMA T, MORIMOTO S, ARAI C, OMURA K, ASAKA D, MATSUWAKI Y, YOSHIKAWA M, MORIYAMA H, OTORI N. 2013. A modified Lund-Mackay system for radiological evaluation of chronic rhinosinusitis. *Auris, Nasus, Larynx,* 40(6), pp. 548-553.

OLUWOLE M, RUSSELL N, TAN L, GARDINER Q, WHITE P. 1996. A comparison of computerized tomographic staging systems in chronic sinusitis. *Clinical Otolaryngology and Allied Sciences,* 21(1), pp. 91-95.

ORLANDI RR, KINGDOM TT, HWANG PH, SMITH TL, ALT JA, BAROODY FM, BATRA PS, BERNAL-SPREKELSEN M, BHATTACHARYYA N, CHANDRA RK, CHIU A. CITARDI MJ, COHEN NA, DELGAUDIO J, DESROSIERS M, DHONG H, DOUGLAS R, FERGUSON B, FOKKENS WJ, GEORGALAS C, GOLDBERG A, GOSEPATH J, HAMILOS DL, HAN K., HARVEY R, HELLINGS P, HOPKINS C, JANKOWSKI R, JAVER AR, KERN R, KOUNTAKIS S, KOWALSKI ML, LANE A, LANZA DC, LEBOWITZ R, LEE H, LIN SY, LUND V, LUONG A, MANN W, MARPLE BF, MCMAINS KC, METSON R, NACLERIO R, NAYAK JV, OTORI N, PALMER JN, PARIKH SR, PASSALI D, PETERS A, PICCIRILLO J, POETKER DM, PSALTIS AJ, RAMADAN HH, RAMAKRISHNAN VR, RIECHELMANN H, ROH H, RUDMIK L, SACKS R, SCHLOSSER RJ, SENIOR BA, SINDWANI R, STANKIEWICZ JA, STEWART M, TAN BK, TOSKALA E, VOEGELS R, WANG DY, WEITZEL EK, WISE S, WOODWORTH BA, WORMALD P, WRIGHT ED, ZHOU B , KENNEDY DW. 2016. International Consensus Statement on Allergy and Rhinology: Rhinosinusitis. *International Forum of Allergy & Rhinology,* 6 Suppl 1, pp. 22-209.

ORLANDI RR, TERRELL J.E. 2002. Analysis of the adult chronic rhinosinusitis working definition. *American Journal of Rhinology,* 16(1), pp. 7-10.

OTTAVIANO G, FOKKENS W.J. 2016. Measurements of nasal airflow and patency: a critical review with emphasis on the use of peak nasal inspiratory flow in daily practice. *Allergy,* 71(2), pp. 162-174.

OTTO KJ, DELGAUDIO JM. 2010. Operative findings in the frontal recess at time of revision surgery. *American Journal of Otolaryngology,* 31(3), pp. 175-180.

OU J, WANG J, XU Y, TAO Z, KONG Y, CHEN S, SHI W. 2014. Staphylococcus aureus superantigens are associated with chronic rhinosinusitis with nasal polyps: a meta-analysis. *European Archives of Oto-Rhino-Laryngology,* 271(10), pp. 2729-2736.

PARIKH A, ANAND U, UGWU MC, FERIDOONI T, MASSOUD E , AGU RU. 2014. Drug-eluting nasal implants: formulation, characterization, clinical applications and challenges. *Pharmaceutics,* 6(2), pp. 249–267.

PENTTILÄ M, RAUTIAINEN M, KOSKINEN M. TURJANMAA V, LARANNE J, PUKANDER J. 1994. Mucociliary Clearance of the Maxillary Sinuses in Patients with Recurrent or Chronic Sinusitis. *American Journal of Rhinology,* 8(6), pp. 285-290.

PHILPOTT C, ERSKINE S, SMITH R, HOPKINS C, KARA,N, FARBOUD A, SALAM M, ROBERTSON A, ALMEYDA R, KUMAR BN, ANARI S, RAY J, CATHCART R, CARRIE S, AHMED S, KHALIL,H, CLARK A, THOMAS M. 2018. Current use of baseline medical treatment in chronic rhinosinusitis: Data from the National Chronic Rhinosinusitis Epidemiology Study (CRES). *Clinical otolaryngology: official journal of ENT-UK; official journal of Netherlands Society for Oto-Rhino-Laryngology & Cervico-Facial Surgery,* 43(2), pp. 509-524.

PINTO JM, MEHTA N, DITINEO M, WANG J, BAROODY FM, NACLERIO RM. 2010. A randomized, double-blind, placebo-controlled trial of anti-IgE for chronic rhinosinusitis. *Rhinology,* 48(3), pp. 318-324.

PIRILÄ T, TIKANTO J. 2009. Acoustic rhinometry and rhinomanometry in the preoperative screening of septal surgery patients. *American Journal of Rhinology & Allergy,* 23(6), pp. 605-609.

PONIKAU JU, SHERRIS DA, KERN EB, HOMBURGER HA, FRIGAS E, GAFFEY TA, ROBERTS GD. 1999. The diagnosis and incidence of allergic fungal sinusitis. *Mayo Clinic Proceedings,* 74(9), pp. 877-884.

POTHOVEN KL, NORTON JE, HULSE KE, SUH LA, CARTER RG, ROCCI E, HARRIS KE, SHINTANI-SMITH S, CONLEY DB, CHANDRA RK, LIU MC, KATO A, GONSALVES N, GRAMMER LC, PETERS AT, KERN RC, BRYCE PJ, TAN BK, SCHLEIMER R.P. 2015. Oncostatin M promotes mucosal epithelial barrier dysfunction, and its expression is increased in patients with eosinophilic mucosal disease. *The Journal of Allergy and Clinical Immunology,* 136(3), pp. 737-746.e4.

RAGAB SM, LUND VJ, SCADDING G, SALEH HA, KHALIFA MA. 2010. Impact of chronic rhinosinusitis therapy on quality of life: a prospective randomized controlled trial. *Rhinology,* 48(3), pp. 305-311.

RAJAN JP, WINEINGER NE, STEVENSON DD, WHITE AA. 2015. Prevalence of aspirin-exacerbated respiratory disease among asthmatic patients: A meta-analysis of the literature. *The Journal of Allergy and Clinical Immunology,* 135(3), pp. 676-681.e1.

REH DD, HIGGINS TS, SMITH TL. 2012. Impact of tobacco smoke on chronic rhinosinusitis: a review of the literature. *International Forum of Allergy & Rhinology,* 2(5), pp. 362-369.

RICHER SL, TRUONG-TRAN AQ, CONLEY DB, CARTER R, VERMYLEN D, GRAMMER LC, PETERS AT, CHANDRA RK, HARRIS KE, KERN RC, SCHLEIMER RP. 2008. Epithelial genes in chronic rhinosinusitis with and without nasal polyps. *American Journal of Rhinology,* 22(3), pp. 228-234.

RUDMIK L, MACE JC, SMITH TL. 2011a. Smoking and endoscopic sinus surgery: does smoking volume contribute to clinical outcome. *International Forum of Allergy & Rhinology,* 1(3), pp. 145-152.

RUDMIK L, SOLER ZM, ORLANDI RR, STEWART MG, BHATTACHARYYA N, KENNEDY DW, SMITH TL. 2011b. Early postoperative care following endoscopic sinus surgery: an evidence-based review with recommendations. *International Forum of Allergy & Rhinology,* 1(6), pp. 417-430.

RUDMIK L, SMITH TL, SCHLOSSER RJ, HWANG PH, MACE JC, SOLER ZM. 2014a. Productivity costs in patients with refractory chronic rhinosinusitis. *The Laryngoscope,* 124(9), pp. 2007-2012.

RUDMIK L, SMITH TL. 2014b. Economic Evaluation of a Steroid-Eluting Sinus Implant following Endoscopic Sinus Surgery for Chronic Rhinosinusitis. *Otolaryngology--Head and Neck Surgery: Official Journal of American Academy of Otolaryngology-Head and Neck Surgery,* 151(2), pp. 359-366.

RUDMIK L. 2017. Economics of Chronic Rhinosinusitis. *Current Allergy and Asthma Reports,* 17(4), pp. 1-10.

SABINO HAC, VALERA FCP, ARAGON DC, FANTUCCI MZ, TITONELI CC, MARTINEZ R, ANSELMO-LIMA WT, TAMASHIRO E. 2017. Amoxicillin-clavulanate for patients with acute exacerbation of chronic rhinosinusitis: a prospective, double-blinded, placebo-controlled trial. *International Forum of Allergy & Rhinology,* 7(2), pp. 135-142.

SAMTER M, BEERS R.F. 1968. Intolerance to aspirin. Clinical studies and consideration of its pathogenesis. *Annals of Internal Medicine,* 68(5), pp. 975-983.

SASAMA J, SHERRIS DA, SHIN S, KEPHART GM, KERN EB, PONIKAU JU. 2005. New paradigm for the roles of fungi and eosinophils in chronic rhinosinusitis. *Current opinion in otolaryngology & head and neck surgery,* 13(1), pp. 2-8.

SCHLEIMER RP. 2017. Immunopathogenesis of Chronic Rhinosinusitis and Nasal Polyposis. *Annual Review of Pathology,* 12, pp. 331-357.

SCHWITZGUÉBEL AJ, JANDUS P, LACROIX J, SEEBACH JD, HARR T. 2015. Immunoglobulin deficiency in patients with chronic rhinosinusitis: Systematic review of the literature and meta-analysis. *The Journal of Allergy and Clinical Immunology,* 136(6), pp. 1523-1531.

SEIBERLING KA, GRAMMER L, KERN RC. 2005. Chronic rhinosinusitis and superantigens. *Otolaryngologic Clinics of North America,* 38(6), pp. 1215-1236, ix.

SESHADRI S, ROSATI M, LIN DC, CARTER RG, NORTON JE, CHOI AW, SUH L, KATO A, CHANDRA RK, HARRIS KE, CHU HW, PETERS AT, TAN BK, CONLEY DB, GRAMMER LC, KERN RC, SCHLEIMER RP. 2013. Regional differences in the expression of innate host defense molecules in sinonasal mucosa. *The Journal of Allergy and Clinical Immunology,* 132(5), pp. 1227-1230.e5.

SESHADRI S, LU X, PURKEY MR, HOMMA T, CHOI AW, CARTER R, SUH L, NORTON J, HARRIS KE, CONLEY DB, KATO A, AVILA PC, CZARNOCKA B, KOPP PA, PETERS AT, GRAMMER LC, CHANDRA RK, TAN BK, LIU Z, KERN RC, SCHLEIMER RP. 2015. Increased expression of the epithelial anion transporter pendrin/SLC26A4 in nasal polyps of patients with chronic rhinosinusitis. *The Journal of Allergy and Clinical Immunology,* 136(6), pp. 1548-1558.e7.

SEYBT MW, MCMAINS KC, KOUNTAKIS SE. 2007. The prevalence and effect of asthma on adults with chronic rhinosinusitis. *Ear, Nose, & Throat Journal,* 86(7), pp. 409-411.

SHEN JC, COPE E, CHEN B, LEID JG, COHEN NA. 2012. Regulation of murine sinonasal cilia function by microbial secreted factors. *International Forum of Allergy & Rhinology,* 2(2), pp. 104-110.

SHEN K, WANG Y, HSU T, HSIEH L, SUN F, WANG Y. 2019. Differential effects of postoperative oral corticosteroid on eosinophilic vs. non-eosinophilic CRSwNP subtypes. *American Journal of Otolaryngology,* 40(1), pp. 22-29.

SHEPPARD DN, WELSH MJ. 1999. Structure and function of the CFTR chloride channel. *Physiological Reviews,* 79(1 Suppl), pp. 23-45.

SIVASUBRAMANIAM R, DOUGLAS R. 2018. The microbiome and chronic rhinosinusitis. *World Journal of Otorhinolaryngology - Head and Neck Surgery,* 4(3), pp. 216-221.

SJOGREN PP, PARKER NP, BOYER HC. 2013. Retained drug-eluting stents and recalcitrant chronic rhinosinusitis: A case report. *Allergy & Rhinology (Providence, R.I.),* 4(1), pp. 45-48.

SMITH KA, RUDMIK L. 2013. Cost Collection and Analysis for Health Economic Evaluation. *Otolaryngology–Head and Neck Surgery,* 149(2), pp. 192-199.

SMITH KA, PULSIPHER A, GABRIELSEN DA, ALT JA. 2018. Biologics in Chronic Rhinosinusitis: An Update and Thoughts for Future Directions. *American Journal of Rhinology & Allergy,* 32(5), pp. 412-423.

SMITH TL, KERN R, PALMER JN, SCHLOSSER R, CHANDRA RK, CHIU AG, CONLEY D, MACE JC, FU RF, STANKIEWICZ J. 2013. Medical therapy vs surgery for chronic rhinosinusitis: a prospective, multi-institutional study with 1-year follow-up. *International Forum of Allergy & Rhinology,* 3(1), pp. 4-9.

SMITH TL, SAUTTER NB. 2014. Is montelukast indicated for treatment of chronic rhinosinusitis with polyposis? *The Laryngoscope,* 124(8), pp. 1735-1736.

SNIDVONGS K, CHAOWANAPANJA P, AEUMJATURAPAT S, CHUSAKUL S, PRAWESWARARAT P. 2008. Does nasal irrigation enter paranasal sinuses in chronic rhinosinusitis? *American Journal of Rhinology,* 22(5), pp. 483-486.

SNIDVONGS K, KALISH L, SACKS R, CRAIG JC, HARVEY RJ. 2011. Topical steroid for chronic rhinosinusitis without polyps. *The Cochrane database of systematic reviews,* (8), pp. CD009274.

SOBOL SE, WRIGHT ED, FRENKIEL S. 1998. One-year outcome analysis of functional endoscopic sinus surgery for chronic sinusitis. *The Journal of Otolaryngology,* 27(5), pp. 252-257.

SOLER ZM, MACE J, SMITH TL. 2008. Symptom-based presentation of chronic rhinosinusitis and symptom-specific outcomes after endoscopic sinus surgery. *American Journal of Rhinology,* 22(3), pp. 297-301.

SOLER ZM, JONES R, LE P, RUDMIK L, MATTOS JL, NGUYEN SA, SCHLOSSER RJ. 2018. Sino-Nasal outcome test-22 outcomes after sinus surgery: A systematic review and meta-analysis. *The Laryngoscope,* 128(3), pp. 581.

STEINKE JW, WOODARD CR, BORISH L. 2008. Role of hypoxia in inflammatory upper airway disease. *Current Opinion in Allergy and Clinical Immunology,* 8(1), pp. 16-20.

STEVENS WW, OCAMPO CJ, BERDNIKOVS S, SAKASHITA M, MAHDAVINIA M, SUH L, TAKABAYASHI T, NORTON JE, HULSE KE, CONLEY DB, CHANDRA RK, TAN BK, PETERS AT, GRAMMER LC, KATO A, HARRIS KE, CARTER RG, FUJIEDA S, KERN RC, SCHLEIMER RP. 2015. Cytokines in Chronic Rhinosinusitis. Role in Eosinophilia and Aspirin-exacerbated Respiratory Disease. *American Journal of Respiratory and Critical Care Medicine,* 192(6), pp. 682-694.

STEVENS WW, PETERS AT, HIRSCH AG, NORDBERG CM, SCHWARTZ BS, MERCER DG, MAHDAVINIA M, GRAMMER LC, HULSE KE, KERN RC, AVILA P, SCHLEIMER RP. 2017. Clinical Characteristics of Patients with Chronic Rhinosinusitis with Nasal Polyps, Asthma, and Aspirin-Exacerbated Respiratory Disease. *The Journal of Allergy and Clinical Immunology. In Practice,* 5(4), pp. 1061-1070.e3.

STRASZEK SP, SCHLÜNSSEN V, SIGSGAARD T, PEDERSEN OF. 2007. Reference values for acoustic rhinometry in decongested school children and adults: the most sensitive measurement for change in nasal patency. *Rhinology,* 45(1), pp. 36-39.

TAKABAYASHI T, KATO A, PETERS AT, HULSE KE, SUH LA, CARTER R, NORTON J, GRAMMER LC, CHO SH, TAN BK, CHANDRA RK, CONLEY DB, KERN RC, FUJIEDA S, SCHLEIMER RP. 2013. Excessive Fibrin Deposition in Nasal Polyps Caused by Fibrinolytic Impairment through Reduction of Tissue Plasminogen Activator Expression. *American journal of respiratory and critical care medicine,* 187(1), pp. 49-57.

TAMASHIRO E, COHEN NA, PALMER JN, ANSELMO LIMA WT. 2009. Effects of cigarette smoking on the respiratory epithelium and its role in the pathogenesis of chronic rhinosinusitis. *Brazilian Journal of Otorhinolaryngology,* 75(6), pp. 903-907.

TAN BK, SCHLEIMER RP, KERN RC. 2010. Perspectives on the etiology of chronic rhinosinusitis. *Current Opinion in Otolaryngology & Head and Neck Surgery,* 18(1), pp. 21-26.

TAN BK, ZIRKLE W, CHANDRA RK, LIN D, CONLEY DB, PETERS AT, GRAMMER LC, SCHLEIMER RP, KERN RC. 2011. Atopic profile of patients failing medical therapy for chronic rhinosinusitis. *International Forum of Allergy & Rhinology,* 1(2), pp. 88-94.

THEODORAKI MN, LEDDEROSE GJ, BECKER S, LEUNIG A, ARPE S, LUZ M, STELTER K. 2015. Mental distress and effort to engage an image-guided navigation system in the surgical training of endoscopic sinus surgery: a prospective, randomised clinical trial. *European archives of oto-rhino-laryngology: official journal of the European Federation of Oto-Rhino-Laryngological Societies (EUFOS): affiliated with the German Society for Oto-Rhino-Laryngology - Head and Neck Surgery,* 272(4), pp. 905-913.

THULESIUS HL, CERVIN A, JESSEN M. 2014. Treatment with a topical glucocorticoid, budesonide, reduced the variability of rhinomanometric nasal airway resistance. *Rhinology,* 52(1), pp. 19-24.

TIEU DD, KERN RC, SCHLEIMER RP. 2009. Alterations in epithelial barrier function and host defense responses in chronic rhinosinusitis. *The Journal of Allergy and Clinical Immunology,* 124(1), pp. 37-42.

U.S. FOOD AND DRUG ADMINISTRATION, 26 May 2010-last update, MAUDE Adverse Event Report: Acclarent, INC. Relieva Stratus deployment guide. Available: http://www.accessdata.fda.gov/scripts/cdrh/cfdocs/cfMAUDE/detail.cfm?mdrfoi__id=2647842 [Accessed 22 February 2020].

VALENTINE R, ATHANASIADIS T, MORATTI S, HANTON L, ROBINSON S, WORMALD P. 2010. The efficacy of a novel chitosan gel on hemostasis and wound

healing after endoscopic sinus surgery. *American Journal of Rhinology & Allergy,* 24(1), pp. 70-75.

VALTONEN O, BIZAKI A, KIVEKÄS I, RAUTIAINEN M. 2018. Three-Dimensional Volumetric Evaluation of the Maxillary Sinuses in Chronic Rhinosinusitis Surgery. *Annals of Otology, Rhinology & Laryngology,* 127(12), pp. 931-936.

VAN BRUAENE N, PÉREZ-NOVO CA, BASINSKI TM, VAN ZELE T, HOLTAPPELS G, DE RUYCK N, SCHMIDT-WEBER C, AKDIS C, VAN CAUWENBERGE P, BACHERT C, GEVAERT P. 2008. T-cell regulation in chronic paranasal sinus disease. *The Journal of Allergy and Clinical Immunology,* 121(6), pp. 1435-1441.e3.

VAN BRUAENE N, DERYCKE L, PEREZ-NOVO CA, GEVAERT P, HOLTAPPELS G, DE RUYCK N, CUVELIER C, VAN CAUWENBERGE P BACHERT C. 2009. TGF-β signaling and collagen deposition in chronic rhinosinusitis. *The Journal of Allergy and Clinical Immunology,* 124(2), pp. 253-259.e2.

VAN DER VEEN J, SEYS SF, TIMMERMANS M, LEVIE P, JORISSEN M, FOKKENS WJ, HELLINGS PW. 2017. Real-life study showing uncontrolled rhinosinusitis after sinus surgery in a tertiary referral centre. *Allergy,* 72(2), pp. 282-290.

VAN ZELE T, CLAEYS S, GEVAERT P, VAN MAELE G, HOLTAPPELS G, VAN CAUWENBERGE P, BACHERT C. 2006. Differentiation of chronic sinus diseases by measurement of inflammatory mediators. *Allergy,* 61(11), pp. 1280-1289.

VAN ZELE T, GEVAERT P, HOLTAPPELS G, BEULE A, WORMALD PJ, MAYR S, HENS G, HELLINGS P, EBBENS FA, FOKKENS W, VAN CAUWENBERGE P, BACHERT C. 2010. Oral steroids and doxycycline: two different approaches to treat nasal polyps. *The Journal of Allergy and Clinical Immunology,* 125(5), pp. 1069-1076.e4.

VASHISHTA R, SOLER ZM, NGUYEN SA, SCHLOSSER RJ. 2013. A systematic review and meta-analysis of asthma outcomes following endoscopic sinus surgery for chronic rhinosinusitis. *International Forum of Allergy & Rhinology,* 3(10), pp. 788-794.

VERIM A, SENELDIR L, NAIBOĞLU B, KARACA ÇT, KÜLEKÇI S, TOROS SZ, OYSU Ç. 2014. Role of nasal packing in surgical outcome for chronic rhinosinusitis with polyposis. *The Laryngoscope,* 124(7), pp. 1529-1535.

VICAUT E, BERTRAND B, BETTON J, BIZON A, BRICHE D, CASTILLO L, LECANU J, LINDAS P, LOMBARD B, MALARD O, MEROL J, MONTEYROL P, NASSER T, NAVAILLES B, PRULIÈRE-ESCABASSE V, STRINGINI R., VERILLAUD B. 2019. Use of a navigation system in endonasal surgery: Impact on surgical strategy and surgeon satisfaction. A prospective multicenter study. *European Annals of Otorhinolaryngology, Head and Neck Diseases,* 136(6), pp. 461-464.

VIDELER WJM, VAN DRUNEN CM, REITSMA JB, FOKKENS, WJ. 2008. Nebulized bacitracin/colimycin: a treatment option in recalcitrant chronic rhinosinusitis with Staphylococcus aureus? A double-blind, randomized, placebo-controlled, cross-over pilot study. *Rhinology,* 46(2), pp. 92-98.

VIDELER WJ, BADIA L, HARVEY RJ, GANE S, GEORGALAS C, VAN DER MEULEN FW, MENGER DJ, LEHTONEN MT, TOPPILA-SALMI SK, VENTO SI, HYTÖNEN M, HELLINGS PW, KALOGJERA L, LUND VJ, SCADDING G, MULLOL J, FOKKENS WJ. 2011. Lack of efficacy of long-term, low-dose azithromycin in chronic rhinosinusitis: a randomized controlled trial. *Allergy,* 66(11), pp. 1457-1468.

VILLARI CR, WOJNO TJ, DELGAUDIO JM. 2012. Case report of orbital violation with placement of ethmoid drug-eluting stent. *International Forum of Allergy & Rhinology,* 2(1), pp. 89-92.

VREUGDENBURG TD, LAMBERT RS, ATUKORALE YN, CAMERON AL. 2016. Stereotactic anatomical localization in complex sinus surgery: A systematic review and meta-analysis. *The Laryngoscope,* 126(1), pp. 51-59.

WAGNER MACKENZIE B, WAITE DW, HOGGARD M, DOUGLAS RG, TAYLOR MW, BISWAS K. 2017. Bacterial community collapse: a meta-analysis of the sinonasal microbiota in chronic rhinosinusitis. *Environmental Microbiology,* 19(1), pp. 381-392.

WALFORD HH, LUND SJ, BAUM RE, WHITE AA, BERGERON CM, HUSSEMAN J, BETHEL KJ, SCOTT DR, KHORRAM N, MILLER M, BROIDE DH, DOHERTY TA. 2014. Increased ILC2s in the eosinophilic nasal polyp endotype are associated with corticosteroid responsiveness. *Clinical Immunology (Orlando, Fla.),* 155(1), pp. 126-135.

WALLWORK B, COMAN W, MACKAY-SIM A, GREIFF L, CERVIN A. 2006. A double-blind, randomized, placebo-controlled trial of macrolide in the treatment of chronic rhinosinusitis. *The Laryngoscope,* 116(2), pp. 189-193.

WANG M, SHI P, YUE Z, CHEN B, ZHANG H, ZHANG D, WANG H. 2008. Superantigens and the expression of T-cell receptor repertoire in chronic rhinosinusitis with nasal polyps. *Acta Oto-Laryngologica,* 128(8), pp. 901-908.

WANG X, ZHANG N, BO M, HOLTAPPELS G, ZHENG M, LOU H, WANG H, ZHANG L, BACHERT C. 2016. Diversity of TH cytokine profiles in patients with chronic rhinosinusitis: A multicenter study in Europe, Asia, and Oceania. *The Journal of Allergy and Clinical Immunology,* 138(5), pp. 1344-1353.

WATELET JB, VAN CAUWENBERGE P. 1999. Applied anatomy and physiology of the nose and paranasal sinuses. *Allergy,* 54 Suppl 57, pp. 14-25.

WENTZEL JL, SOLER ZM, DEYOUNG K, NGUYEN SA, LOHIA S, SCHLOSSER RJ. 2013. Leukotriene antagonists in nasal polyposis: a meta-analysis and systematic review. *American Journal of Rhinology & Allergy,* 27(6), pp. 482-489.

WENZEL S, FORD L, PEARLMAN D, SPECTOR S, SHER L, SKOBIERANDA F, WANG L, KIRKESSELI S, ROCKLIN R, BOCK B, HAMILTON J, MING JE, RADIN A, STAHL N, YANCOPOULOS GD, GRAHAM N, PIROZZI G. 2013. Dupilumab in persistent asthma with elevated eosinophil levels. *The New England Journal of Medicine,* 368(26), pp. 2455-2466.

WILSON KF, MCMAINS KC, ORLANDI RR. 2014. The association between allergy and chronic rhinosinusitis with and without nasal polyps: an evidence-based review with recommendations. *International Forum of Allergy & Rhinology,* 4(2), pp. 93-103.

WOLF G, ANDERHUBER W, KUHN F. 1993. Development of the paranasal sinuses in children: implications for paranasal sinus surgery. *The Annals of Otology, Rhinology, and Laryngology,* 102(9), pp. 705-711.

WORMALD P, CAIN T, OATES L, HAWKE L, WONG I. 2004. A comparative study of three methods of nasal irrigation. *The Laryngoscope,* 114(12), pp. 2224-2227.

WUISTER AMH, GOTO NA, OOSTVEEN EJ, DE JONG WU, VAN DER VALK ES, KAPER NM, AARTS MCJ, GROLMAN W, VAN DER HEIJDEN G. 2014. Nasal endoscopy is recommended for diagnosing adults with chronic rhinosinusitis. *Otolaryngology--Head and Neck Surgery: Official Journal of American Academy of Otolaryngology-Head and Neck Surgery,* 150(3), pp. 359-364.

XU J, PARK SJ, PARK HS, HAN R, RHA K, KIM YM. 2016. Effects of triamcinolone-impregnated nasal dressing on subjective and objective outcomes following endoscopic sinus surgery. *European archives of oto-rhino-laryngology: official journal of the European Federation of Oto-Rhino-Laryngological Societies (EUFOS): affiliated with the German Society for Oto-Rhino-Laryngology - Head and Neck Surgery,* 273(12), pp. 4351-4357.

XU Y, QUAN H, FARIS P, GARIES S, LIU M, BIRD C, KUKEC E, DEAN S, RUDMIK L. 2016. Prevalence and Incidence of Diagnosed Chronic Rhinosinusitis in Alberta, Canada. *JAMA otolaryngology-- head & neck surgery,* 142(11), pp. 1063-1069.

YIKE I. 2011. Fungal Proteases and Their Pathophysiological Effects. *Mycopathologia,* 171(5), pp. 299-323.

YOUNG LC, STOW NW, ZHOU L, DOUGLAS RG. 2012. Efficacy of medical therapy in treatment of chronic rhinosinusitis. *Allergy & Rhinology (Providence, R.I.),* 3(1), pp. e8-e12.

ZENG M, LONG X, CUI Y, LIU Z. 2011. Comparison of efficacy of mometasone furoate versus clarithromycin in the treatment of chronic rhinosinusitis without nasal polyps in Chinese adults. *American Journal of Rhinology & Allergy,* 25(6), pp. 203.

ZHANG N, VAN ZELE T, PEREZ-NOVO C, VAN BRUAENE N, HOLTAPPELS G, DERUYCK N, VAN CAUWENBERGE P, BACHERT C. 2008. Different types of T-effector cells orchestrate mucosal inflammation in chronic sinus disease. *The Journal of Allergy and Clinical Immunology,* 122(5), pp. 961-968.

ZHOU B, HE G, LIANG J, CHENG L, MEHTA A, LIU S, YU W, WANG Z, HAN D. 2016. Mometasone furoate nasal spray in the treatment of nasal polyposis in Chinese patients: a double-blind, randomized, placebo-controlled trial. *International Forum of Allergy & Rhinology,* 6(1), pp. 88-94.

ZINREICH SJ. 2004. Imaging for staging of rhinosinusitis. *The Annals of Otology, Rhinology & Laryngology. Supplement,* 193, pp. 19-23.

ZOJAJI R, NAGHIBZADEH M, MAZLOUM FARSI BAF M, NEKOOEI S, BATAGHVA B, NOORBAKHSH S. 2015. Diagnostic Accuracy of Cone-Beam Computed Tomography in the Evaluation of Chronic Rhinosinusitis. *ORL,* 77(1), pp. 55-60.

ZUCKERMAN JD, LEE WY, DELGAUDIO JM, MOORE CE, NAVA P, NUSRAT A, PARKOS CA. 2008. Pathophysiology of nasal polyposis: The role of desmosomal junctions. *American Journal of Rhinology,* 22(6), pp. 589-597.

APPENDIX

NENÄOIREKYSELY SINO-NASAL OUTCOME TEST (SNOT-22) PVM:_____

Allaolevassa luettelossa näet listan rinosinuiittiisi liittyvistä oireista ja taloudellis/emotionaalisista seuraamuksista. Haluaisimme selvittää tarkemmin näitä ongelmia ja toivoisimme sinun vastaavan seuraaviin kysymyksiin parhaan kykysi mukaan. Ei ole olemassa oikeita tai vääriä vastauksia, vain sinä voit antaa meille nämä tiedot. Arvioi oireesi ja ongelmasi sen mukaan kuin ne ovat olleet viimeiset kaksi viikkoa. Kiitämme osallistumisestasi. Älä arkaile pyytää apua tarvitessasi.

1. Ottaen huomioon kokemasi vaivan tai ongelman vakavuus ja esiintymistiheys, arvioi seuraavat kohdat k.o asteikolla ympyröimällä tuntemustasi vastaava numero.	Ei ongelmia	Hyvin lievä ongelma	Lievä, vähäinen ongelma	Kohtuullinen ongelma	Vakava ongelma	Pahin mahdollinen	5. Tärkeimmät ongelmat
1. Niistämisen tarve	0	1	2	3	4	5	□
2. Aivastelu	0	1	2	3	4	5	□
3. Nenän vuotaminen	0	1	2	3	4	5	□
4. Nenän tukkoisuus	0	1	2	3	4	5	□
5. Haju- ja makuaistin häiriö	0	1	2	3	4	5	□
6. Yskä	0	1	2	3	4	5	□
7. Liman valuminen kurkkuun	0	1	2	3	4	5	□
8. Paksun nenäeritteen määrä.	0	1	2	3	4	5	□
9. Korvien täyteläisyyden tunne	0	1	2	3	4	5	□
10. Pyörrytyksen tai epävarmuuden tunne	0	1	2	3	4	5	□
11. Korvakipu	0	1	2	3	4	5	□
12. Kasvoalueen kipu/paine	0	1	2	3	4	5	□
13. Nukahtamisvaikeudet	0	1	2	3	4	5	□
14. Yölliset heräämiset	0	1	2	3	4	5	□
15. Unen puute	0	1	2	3	4	5	□
16. Aamuväsymys	0	1	2	3	4	5	□
17. Väsyneisyys	0	1	2	3	4	5	□
18. Alentunut suorituskyky	0	1	2	3	4	5	□
19. Alentunut keskittymiskyky	0	1	2	3	4	5	□
20. Turhautunut / levoton / ärtynyt	0	1	2	3	4	5	□
21. Surullinen	0	1	2	3	4	5	□
22. Hämmentynyt	0	1	2	3	4	5	□

2. Merkitse eniten hyvinvointiisi/terveyteesi vaikuttavat kohdat (enintään 5 kohtaa) _____↑

ORIGINAL PUBLICATIONS

PUBLICATION
I

Image-guided, navigation-assisted Relieva Stratus MicroFlow Spacer insertion into the ethmoid sinus

Taulu R, Numminen J, Bizaki A, Rautiainen M

Eur Arch Otorhinolaryngology (2015) 272(9):2335–40

Image-guided, navigation-assisted Relieva Stratus MicroFlow Spacer insertion into the ethmoid sinus

Rami Taulu MD1,2, Jura Numminen MD, PhD1, Markus Rautiainen MD, PhD1, 2

1Department of Ear and Oral Diseases, Tampere University Hospital, Tampere, Finland

2Tampere University, Medical School, Tampere, Finland

Author contribution list:

R. Taulu: Provision of study material, collection and assembly of data, manuscript writing, final approval of manuscript.

J. Numminen: Conception and design, manuscript writing, final approval of manuscript.

M. Rautiainen: Conseption and design, manuscript writing, final approval of manuscript

Corresponding author:

Rami Taulu,

Tampere University Hospital,

Department of Ear and Oral Diseases,

P.O. Box 2000, 33 521 Tampere, Finland

Tel. +358331164956

E-mail: rami.taulu@pshp.fi

Keywords: Endoscopic Sinus Surgery, Ethmoid Sinus, Drug- Eluting Stent, Relieva Stratus MicroFlow Spacer

Abstract

Anatomical complexity presents the main challenge in the administration of topical corticosteroid therapy to the paranasal sinus mucosa. This often leads to suboptimal drug delivery due to low concentrations of the therapeutic agent to the intended target area. The Relieva Stratus™ MicroFlow Spacer (Relieva Stratus) is a drug-eluting stent that is temporarily implanted into the ethmoid sinus. The reservoir of the stent is filled with triamcinolone acetonide, which is then slowly released from the device into the ethmoid sinus mucosa. The Relieva Stratus provides local and targeted delivery of the anti-inflammatory agent to the diseased mucosa. This minimally invasive implant is an option when treating ethmoid sinusitis.

From January 2011 to November 2013, a total of 52 Relieva Stratus implantations into the ethmoidal cells were performed at the Department of Ear and Oral Diseases at Tampere University Hospital, Finland. C-arm fluoroscopy guidance was employed for 26 sinuses (13 patients) and optical image guided surgery (IGS) -assisted insertions were performed on another 26 sinuses (13 patients).

The accuracy of fluoroscopic insertion is not optimal, but this method is accurate enough to prevent the violation of the skull base and lamina papyracea. IGS enables the precise treatment of the diseased cells. From a technical perspective, IGS-guided insertion is a faster, safer and more exact procedure that guarantees the optimal positioning and efficacy of the implant. Moreover, IGS guidance does not entail the use of ionizing radiation.

Introduction

The first-line treatment of chronic rhinosinusitis (CRS) is local and systemic drug therapy. There is increasing evidence of the inflammatory character of CRS and the favorable effect of topically administered glucocorticoid therapy [1,2]. The topical administration route is safe and only minor side effects have been reported, such as mucosal irritation, crusting and minor nose bleeds. The major problem in drug delivery to the affected paranasal sinus mucosa is the complexity of the sinus anatomy [1,2].

Several large prospective studies have shown that endoscopic sinus surgery (ESS) is an effective and safe method of treatment for patients with CRS when drug therapy has failed [3,4]. The goal of ESS is to ensure the ventilation of the diseased paranasal sinuses and the restoration of the mucociliary function. One of the advantages of ESS is that delivery of the topical glucocorticoids to the paranasal sinuses is easier than preoperatively [5].

Recently published clinical trials have demonstrated that a bioabsorbable mometasone-eluting stent (the Propel® Intersect ENT) is a safe and effective way to treat patients with CRS following ESS; it improves surgical results by minimizing the occurrence of inflammation, adhesions and polypoid tissue formation [6-8].

The Relieva Stratus™ Micro-flow Spacer (Relieva Stratus; Acclarent Inc. California, US) is a novel method for delivering glucocorticoids directly to affected paranasal sinuses. It has been used to treat frontal, ethmoidal and sphenoidal sinuses in a preoperative setting. It is an interesting idea to use this drug-eluting stent, which is introduced with a trocar-based delivery system, as a monotherapeutic anti-inflammatory treatment to avoid surgery and preserve normal ethmoid sinus anatomy. Cadaveric studies have demonstrated that insertion of the Relieva Stratus into the ethmoidal sinus using fluoroscopy is relatively safe and easy [9].

In an initial report, Catalano et al. [10] evaluated the short-term outcomes and safety of the Relieva Stratus infused with triamcinolone acetonide. They followed 23 patients for six months and reported that the Relieva Stratus was a safe and effective method of treatment for chronic ethmoid sinus disease. Outcomes were evaluated by observing changes in the 20-item Sino-Nasal Outcome Test (SNOT-20) and Lund-MacKay computed tomography (CT) scores.

There is only one published complication involving the Relieva Stratus in the literature; the Relieva Stratus had been wrongly placed through the lamina papyracea into the orbit. Despite the removal of the device, the pupil of patient's affected eye remained dilated [11].

In the present study, we describe a safer and more accurate technique for inserting the Relieva Stratus precisely into the involved ethmoidal sinuses with the aid of image-guided navigation. With this technique, the implantation of the Relieva Stratus proved to be a fast, safe and exact procedure. This guarantees the optimal positioning and efficacy of the implant.

The Relieva Stratus device

The Relieva Stratus (Figure 1) is a temporarily implanted drug-eluting stent. The Relieva Stratus device was introduced in 2009 as a minimally invasive surgical tool to treat chronic ethmoidal sinusitis [12]. The stent is inserted into the ethmoidal sinus complex using an endoscopic view with the aid of fluoroscopy. The length of the MicroFlow Spacer is 17 mm and the maximum width is 10 mm when the retention wings are opened. Because the device is currently available in only one length, it is utmost important to ensure that the distance between anterior wall of ethmoid bulla and anterior face of sphenoid must be more than 20 mm on preoperative sinus computed tomography. The reservoir section of the device contains several hundreds of micropores that slowly release a therapeutic agent into the ethmoidal complex. This local and targeted method of drug delivery ensures a high concentration of the anti-inflammatory agent directly into the diseased mucosa. The Food and Drug Administration (FDA) has currently approved the Relieva Stratus

loaded only with sterile saline. In Europe, the device has a CE Mark approval that also covers the use of triamcinolone acetonide (40 mg/ml). When both sides are implanted the total amount of the solution will be 24 mg leaking out of the spores in four weeks. The effect of the corticosteroid will be topical so systemic effects are not expected. There are people who experience side effects from the topical corticosteroids like patients with diabetes or glaucoma, so caution must be taken when treating these patients. Triamcinolone acetonide is widely used in different kind of drugs and its potential side effects are very well known.

With the aid of a trocar-based instrument supplied with the stent, the insertion of the Relieva Stratus device into the ethmoid sinus can be performed relatively safely and reproducibly without injuring the skull base, lamina papyracea or the face of the sphenoid sinus [9]. However, solid evidence on the safety and efficacy of the Relieva Stratus is still lacking.

Stent implantation using fluoroscopic guidance

The insertion of the Relieva Stratus with the aid of fluoroscopy is performed under general anesthesia. The anterior face of the ethmoid bulla is exposed under direct endoscopic view (Figure 2). During the insertion of the stent, the access probe (trocar) and a delivery sheath are positioned in the inferomedial part of the bulla ethmoidalis to avoid the possibility of penetrating the skull base or lamina papyracea. C-arm fluoroscopy and a so-called “shark-fin” handle are used to ensure that the correct angle and trajectory are established (Figure 3). This is followed by insertion of the delivery sheath-containing access probe into the ethmoidal cavities. The access probe is then withdrawn and the delivery sheath is left inside the ethmoidal sinus. The Relieva Stratus and a catheter are inserted through the delivery sheath into the ethmoidal cells, and then the delivery sheath is completely withdrawn. Correct positioning of the Relieva Stratus is confirmed by direct endoscopic visualization and fluoroscopy (Figure 4). The manufacturer of the device recommends that 0.31 ml of sterile saline or triamcinolone acetonide injectable solution (40 mg/ml) is injected into the catheter [13]. The shaft of the catheter is then cut and the MicroFlow Spacer is left in the ethmoid sinus (Figure 5). After four weeks, the MicroFlow Spacer is extracted at an outpatient clinic under local anesthesia by simply removing it with Blakesley forceps, for example [12].

Stent implantation with the aid of image-guided navigation

Image-guided surgery (IGS) systems have been developed to help surgeons localize anatomical structures intraoperatively. These systems enable the tracking of surgical instruments and the calculation of the position of the instrument’s tip inside a preoperatively generated imaging volume in relation to live patient anatomy in real time. The position of the instrument is displayed on the screen of a 3D imaging workstation. Different kinds of tracking

techniques can be employed; the two most common are optical and electromagnetic tracking systems. The major advance of an optical IGS is its ability to register almost any rigid instrument as a tracker instrument. This is not possible when using an electromagnetic tracking system because the system requires special instruments made by manufacturer. With optical IGS, simply by attaching a wireless universal instrument adapter to the access probe and calibrating it, one has a new, ready-to-use, navigation-enabled instrument. Patient registration is fast and takes around two minutes to set up. In the case of the Relieva Stratus device, the wireless universal instrument adapter is attached to the trocar; this new navigation-enabled instrument is then registered and calibrated (Figure 3). Before use, the accuracy of the IGS should be confirmed. Under endoscopic view, the tip of the trocar is placed in the anterior of the bulla ethmoidalis. With the aid of IGS, one can precisely pinpoint the tip of the instrument (Figure 6). The Relieva Stratus insertion can thus be performed more cranially and laterally in the bulla ethmoidalis without any risk of perforation of the skull base or other sensitive structures (Figures 7,8). During this procedure, one can follow where the tip of trocar is placed in real time, and the Relieva Stratus device can be navigated more precisely to the ethmoidal cells worst affected by CRS, based on the preoperative CT scans. The rest of the procedure is performed as described in the previous paragraph.

Our experience of image-guided, navigation-assisted Relieva Stratus insertion

Between January 2011 and November 2013, a total of 52 Relieva Stratus implantations into the ethmoidal cells have been performed at the Department of Ear and Oral Diseases at Tampere University Hospital, Finland. All patients that received the device had clear symptoms of chronic rhinosinusitis for over 12 weeks and findings of ethmoidal rhinosinusitis in a CT scan. The mean Lund-MacKay CT score (LM-score) was 10.8. The first 26 Relieva Stratus implantations (13 patients) were performed using only C-arm fluoroscopy. The latter 26 Relieva Stratus implantations (13 patients) were performed with the aid of an optical IGS system. After the insertion of the stent, the final position was ensured with fluoroscopy.

We found the procedure very easy to perform. Thus far, there have been no immediate or delayed complications, and no implant has required premature removal before the end of the four-week treatment period. After the operation, patients have experienced only minor feelings of local irritation and the majority of them have been totally pain-free. Most of the patients expressed that they could not sense anything out of the ordinarny after the implantation. There were no remarkable adverse effects in either of the study groups.

One of the major benefits of using IGS is operator confidence in knowing exactly where the tip of the trocar is. This speeds up the procedure and enables the insertion of the Relieva Stratus device much more cranially, thus avoiding an

implant placement that is too caudal. The Relieva Stratus had been inserted too low into the superior meatus and outside the ethmoidal cavities in three cases in the fluoroscopy group. In two of these cases, the catheter was cut before this was noticed and the stent was lost. This erroneous placement was practically impossible to recognize from the fluoroscopic images without confirming the position under endoscopic view.

Discussion

The Relieva Stratus™ MicroFlow Spacer (Relieva Stratus) is a new mini-invasive option for treating chronic rhinosinusitis. The implantation of the device is quick, easy and safe to perform. The complication rates ought to be very low based on previous literature [9]. There is only one published clinical trial involving the Relieva Stratus; there were no significant complications in that study [10], and only one orbital complication has been reported in the literature [11]. We encountered no significant adverse events in our study.

In our study the LM-score is quite low, because we have excluded from the study those patients, who have LM-score more than 1 in maxillary, frontal or sphenoidal sinuses. Because the targeted area of the Relieva Stratus is inside of the ethmoidal cells, we found that, it is unethical to treat the patients with totally blocked sinuses (LM-score 2), if you know that drug wont penetrate for example inside of the frontal sinus. Therefore, in our study the maximum LM-score was 18 instead of normal maximum 24.

In general, the use of C-arm fluoroscopy is quite laborious in the setting of paranasal sinus surgery. In the case of Relieva Stratus stent placements, fluoroscopic guidance accuracy is suboptimal; it is only adequate to prevent major complications, such as violations of the lamina papyracea and the skull base. Under fluoroscopic guidance, the insertion point in the anterior part of the bulla ethmoidalis is often too caudal and medial, which may lead to penetration of the superior meatus through the ethmoidal sinus. This problem was not observed in the case of IGS-assisted operations. In comparison to IGS, which enables real time guidance during the procedure and the negotiation of specific predetermined ethmoidal cells, only the final position of the Relieva Stratus can be seen after insertion when fluoroscopy is used. Thus, an IGS-assisted approach improves the accuracy of the insertion and makes it possible to treat precisely the diseased cells identified by preoperative CT imaging. This is especially useful when only part of the ethmoidal cavities are diseased. IGS also decreases the duration of the operation and thus saves operating room time.

Another major disadvantage of the fluoroscopic approach is the radiation dose acquired by the patients and the surgical staff. Especially during the learning phase, longer screening times and several expositions are required to ensure correct positioning of the device. To minimize the dose of radiation in our patients, we used only separate expositions; thus, we managed to cut radiation doses to as low as 0.4–0.5 mSv per patient. The use of the screening mode might enhance the

accuracy of the implantation, but the radiation dose is also much higher. In our study, we used fluoroscopy to check the final position of the Relieva Stratus after IGS-guided implantation. Normally, this is not necessary when IGS is used and the accuracy of the system has been confirmed.

Conclusion

Due to radiation protection concerns, and because of the complexity and variability of ethmoidal cavity anatomy and the vital anatomical structures surrounding the ethmoidal cells, we recommend the use of optical IGS in the insertion of the Relieva Stratus stent.

Conflicts of interest and source of funding: The authors have no conflicts of interest to disclose.

References

1. Lund VJ, Black JH, Szabo LZ, Schrewelius C, Akerlund A (2004) Efficacy and tolerability of budesonide aqueous nasal spray in chronic rhinosinusitis patients. Rhinology 42(2):57-62.
2. Small CB, Hernandez J, Reyes A, Schenkel E, Damiano A, Stryszak P, et al. (2005) Efficacy and safety of mometasone furoate nasal spray in nasal polyposis. J Allergy Clin Immunol. 116(6):1275-81.
3. Hopkins C, Browne JP, Slack R, Lund V, Topham J, Reeves B, et al. (2006) The national comparative audit of surgery for nasal polyposis and chronic rhinosinusitis. Clin Otolaryngol. 31(5):390-8.
4. Ragab SM, Lund VJ, Scadding G. (2004) Evaluation of the medical and surgical treatment of chronic rhinosinusitis: a prospective, randomised, controlled trial. Laryngoscope 114(5):923-30.
5. Harvey RJ, Goddard JC, Wise SK, Schlosser RJ. (2008) Effects of endoscopic sinus surgery and delivery device on cadaver sinus irrigation. Otolaryngol Head Neck Surg. 139(1):137-42.
6. Murr AH, Smith TL, Hwang PH, et al. (2011) Safety and efficacy of a novel bioabsorbable, steroid-eluting sinus stent. Int Forum Allergy Rhinol. 1(1):23–32.
7. Forwith KD, Chandra RK, Yun PT, Miller SK, Jampel HD. (2011) ADVANCE: a multi-site trial of bioabsorbable steroid-eluting sinus implants. Laryngoscope 121(11):2473–2480.
8. Marple BF, Smith TL, Han JK, et al. (2012) ADVANCE II: a prospective, randomized study assessing safety and efficacy of bioabsorbable steroid-releasing sinus implants. Otolaryngol Head Neck Surg. 146(6): 1004–1011.

9. Melroy CT, Kuhn FA. (2009) Safety of Ethmoid Sinus Drug-Eluting Catheter Insertion. Ann Otol Rhinol Laryngol. 118(10):708-713.
10. Catalano PJ, Thong M, Rimash T. (2011) The MicroFlow Spacer: A Drug-Eluting Stent for the Ethmoid Sinus. Indian J Otolaryngol Head Neck Surg. 63(3):279-84.
11. Sjogren PP, Parker NP, Boyer HC. (2013) Retained drug-eluting stents and recalcitrant chronic rhinosinusitis: A case report. Allergy Rhinol (Providence). Spring;4(1):e45-8. doi: 10.2500/ar.2013.4.0042.
12. Catalano PJ, Thong M, Garg V. (2009) The MicroFlow Spacer: A drug-eluting stent for the ethmoid sinus. Operat Tech Otolaryngol Head Neck Surg. 20:108-113.
13. Instructions for use of Relieva Stratus Microflow Spacer. Menlo Park, CA. Available online at https://www.jnjgatewayifu.com/eLabelingContent/Acc/USENG/IFU005013_Rev_F_Stratus_81590.pdf. Accessed 17 June 2014

PUBLICATION
II

A prospective, randomized clinical study comparing drug eluting stent therapy and intranasal corticoid steroid therapy in the treatment of patients with chronic rhinosinusitis

Taulu R, Numminen J, Bizaki A, Rautiainen M

Rhinology (2017) 55(3):218–226

A prospective, randomized clinical study comparing drug eluting stent therapy and intranasal corticoid steroid therapy in the treatment of patients with chronic rhinosinusitis*

Rami Taulu, Argyro J. Bizaki, Jura Numminen, Markus Rautiainen

Department of Otorhinolaryngology, Tampere University and Tampere University Hospital, Tampere, Finland

Rhinology 55: 218-226, 2017
https://doi.org/10.4193/Rhino16.070

***Received for publication:** February 17, 2016
Accepted: June 26, 2016

Abstract

Objectives: To conduct the first prospective, randomized controlled clinical trial comparing the efficacy of a drug-eluting stent (DES) (the Relieva Stratus™ MicroFlow Spacer) and topical intranasal corticosteroid therapy in patients with chronic rhinosinusitis (CRS).

Methods: Sixty-three adult patients with ethmoiditis were randomized into either the DES group (n=34) or nasal spray group (n=29). The main outcome variable was the Sinonasal Outcome Test 22, Visual Analogue Scale, nasal endoscopy, rhinometric measurements were performed at the beginning of the study, after three months and six months of follow-up.

Results: Both treatments significantly improved quality of the life with no significant difference being found between the two groups. The VAS score decreased in both groups: improvements were significant at three and six months in the nasal spray group, but in the DES group a significant difference was noted only at three months. There was a statistically significant increase in total nasal cavity volumes in the corticosteroid spray group, but not in the DES group.

Conclusion: We found that patients benefitted from DES and the corticosteroid nasal spray. We could not find any significant difference between the treatments, except the greater increase in the total nasal cavity volumes favouring the nasal spray group. Because of the very good results for the nasal spray and the much higher material and operating room costs associated with DES, we cannot recommend the use of DES over nasal spray as a monotherapeutic treatment for CRS.

Key words: chronic rhinosinusitis, ethmoiditis, drug eluting stent, Relieva Stratus Micro Flow Spacer, nasal corticosteroids

Introduction

Chronic rhinosinusitis (CRS) is a common health problem that affects 5-15% of the Western population [1-3]. CRS has a major impact on quality of life, comparable to chronic diseases such as ischemic heart disease, congestive heart failure, and back pain [4]. It causes a substantial economic burden to society and health care systems [5]. CRS is a wide general term describing a group of disorders characterized by chronic inflammation of the mucosa of the nose and paranasal sinuses that share the same symptomology. The goals of the treatment include reduction of mucosal oedema, re-establishment of sinus ventilation, and eradication of infecting pathogens. Multiple therapies are available for the management of CRS, including topical and systemic glucocorticoids, long- and short-term antibiotics, nasal saline irrigations or sprays, antileukotriens, anti-interleukin therapy, and endoscopic sinus surgery (ESS).

Intranasal glucocorticoid therapy is the first-line treatment for CRS. There is good evidence for the efficacy of topically adminis-

tered glucocorticoid therapy when treating CRS with or without nasal polyps [6-8]. The topical administration route is safe and poses only minor side effects, such as mucosal irritation, crusting, and minor nose bleeds [7]. The complexity of the sinus anatomy and the mucosal oedema of CRS patients are major problems in drug delivery to the affected paranasal sinus mucosa [9].

Several large prospective studies have shown that ESS is an effective and safe method of treatment for patients with CRS when drug therapy has failed [10,11]. The goal of ESS is to ensure the ventilation of the diseased paranasal sinuses and the restoration of the mucociliary function. One of the advantages of ESS is that delivery of the topical glucocorticoids to the paranasal sinuses is easier postoperatively [12,13].

Recently published clinical trials have demonstrated that the application of a bioabsorbable mometasone eluting stent (the Propel® Intersect ENT) in patients that have been undergone ESS is safe and improves surgical results by minimizing the occurrence of inflammation, adhesions, and polypoid tissue formation[14-16]. The Relieva Stratus™ Micro-flow Spacer (Relieva Stratus; Acclarent Inc., CA, USA) is a method for delivering glucocorticoids directly to affected paranasal sinuses. It has been used to treat frontal, ethmoidal, and sphenoidal sinuses in a preoperative setting. It is an interesting idea to use this drug eluting stent (DES), which is introduced with a trocar-based delivery system, as a monotherapeutic anti-inflammatory treatment to avoid surgery and preserve normal ethmoid sinus anatomy. Cadaveric studies have demonstrated that insertion of the Relieva Stratus into the ethmoidal sinus using fluoroscopy is relatively safe and easy [17]. An image guided surgery system (IGS) should be used for the guided insertion instead of fluoroscopic insertion, because the former is a faster, safer, and more exact procedure, and it does not use ionizing radiation [18].

In an initial report, Catalano et al. [19] evaluated the short-term outcomes and safety of the Relieva Stratus infused with triamcinolone acetonide. They followed 23 patients for six months and reported that the Relieva Stratus was a safe and effective method of treatment for chronic ethmoid sinus disease. Outcomes were evaluated by observing changes in the 20-item Sino-Nasal Outcome Test (SNOT-20) and Lund-Mackay (LM) scores.

This study is a prospective, randomized controlled clinical trial on patients diagnosed with CRS with ethmoidal involvement verified by CBCT scan findings. Our objectives were to compare the efficacy of the DES to the standard non-invasive treatment with corticosteroid nasal spray and to study the safety and potential side effects of the Relieva Stratus.

Materials and methods

Subjects

A total of 63 patients were prospectively recruited to a randomized controlled clinical trial at the Department of Otorhinolaryngology at Tampere University Hospital, Finland over a 42-month period starting from December 2010 and ending in June 2014. All the recruited patients were referred from outpatient clinics. Patients did not receive any financial compensation for their participation in this study. Informed consent was obtained from all patients in advance. The trial protocol was approved by the Ethics Committee of Pirkanmaa Hospital District, Tampere University Hospital.

Inclusion criteria were: 1) CRS diagnosed as outlined by the European position paper on rhinosinusitis and nasal polyps 2007 (20), 2) adequate medical treatment of the CRS for at least three months without a satisfactory result, 3) age over 18 years and less than 65 years, 4) CRS of ethmoid sinuses, confirmed with a CBCT scan and an LM score of at least 2 for ethmoid sinuses, and 5) fulfilment of the indications for sinus surgery according to Finnish guidelines and indications for surgical treatment [21].

Exclusion criteria were as follows: 1) previous sinus operations, 2) ASA hypersensitivity, 3) diabetes or any other severe systemic disease, 4) glaucoma, 5) pregnancy upon enrolment to the study, 6) an LM score of more than 1 in the maxillary, frontal or sphenoidal sinus, 7) distance from the face of the ethmoid bulla to the face of the sphenoid sinus less than 20mm, and 8) nasal polyposis if the polyps were growing beyond the medial meatus according to an endoscopic view.

The study protocol included four to five study visits. The first visit was an enrolment and randomization visit, during which the informed consent and history were obtained, direct nasal endoscopy was performed, and the CBCT scans were evaluated. From this point began a four week wash-out period. The patients were forbidden from using any medication containing corticosteroids. Any other medication to treat the symptoms of the CRS was allowed (no-one used long term, low-dose macrolide antibiotic drugs). At the next visit, both groups were evaluated using SNOT22, VAS, RMM, AR, and direct nasal endoscopy. In the DES group, all of the patients had bilateral stent placement under general anaesthesia. Patients in the nasal spray group were instructed as to the ideal way to administer the nasal spray. Any other drugs containing corticosteroids were forbidden in both groups for the duration of the trial. The DES was removed after four weeks at an outpatient clinic under local anaesthesia. Follow up was scheduled at three and six months after treatment; the patients were again evaluated using SNOT22, VAS, RMM, AR, and direct nasal endoscopy. Usage of antibiotics was documented and an additional sinus CBCT scan was taken at six months after treatment. Patients were regularly followed up for any adverse effects.

Study groups

Patients were randomized into the DES or the intranasal corticosteroid spray group using the MINIM MS DOS program (a program for randomization in clinical trials) [22]. It does allocation by minimisation and runs interactively through the study.

Groups were randomized with the following parameters: age, sex, asthma, nasal polyposis, and use of tobacco. The sample size was calculated based on paired t-test. The value for average SNOT22 change was set to 12.6, 20.0 was used as standard deviation [23]. With alpha of 0.05 and power of 0.8 the calculation suggests that approximately 22 study patients are needed to see the SNOT22 change as statistically significant. A drop-out of patients in follow-up had to be taken into account, so approximately 30 patients in both groups (a total of 60) were required.

Sino Nasal Outcome Test-22 Quality of Life Questionnaire

The SNOT22 is a validated, rhinosinusitis-specific quality of life instrument that contains 22 individual questions about nasal symptoms and quality of life [23]. Patients completed the questionnaire after the wash out period, at three months, and at six months. According to a previous validation study, we considered the minimally important difference – the smallest change in the SNOT22 score that can be detected in a patient – to be 8.9 points [23].

Visual Analogue Scale

Patients were asked to score using the visual analogue scale (0-10cm) the question "How troublesome are your CRS symptoms?" (0cm = not troublesome at all to 10cm = worst thinkable). VAS scoring was performed at every visit.

Acoustic rhinometry and rhinomanometry

AR evaluates nasal obstruction by analysing reflected sound waves introduced through the nostrils. It produces an image that reflects variations in the cross-sectional dimensions of the nasal cavity and closely approximates nasal cavity volume and minimal cross-sectional area. It is easy to perform, non invasive, and does not require significant patient co-operation. It can be used to demonstrate the reduction of the inflammation as a result of medical and surgical intervention [24]. We analysed the change in the total volume (between 2 to 5 cm from the nostril) of the nasal cavity [25].

RMM, a measurement of nasal airway resistance, was performed at every study visit. It is a tool to determine the degree of airflow obstruction before and after surgical procedures and pharmacological interventions. In CRS, this method can be used to confirm if the improvement in nasal congestion is the result of a reduction in inflammation [26]. In this study, we examined the change in the total inspiratory nasal resistance as a sign of the extent of mucosal inflammation.

Direct nasal endoscopy

In the study, we used the EPOS guideline for endoscopy scoring (0 = absence of polyps, 1 = polyps in middle meatus only, 2 = polyps beyond middle meatus but not blocking the nose completely, 3 = polyps completely obstructing the nose), oedema (0 = absent, 1 = mild, 2 = severe), discharge (0 =no discharge, 1 = clear, thin discharge, 2 = thick, purulent discharge), scarring (0 =absent, 1 = mild, 2 =severe), and crusting (0 = absent, 1 = mild, 2 = severe) [20]. The patient's nasal cavities were examined with an endoscope and graded by the same operator at every visit.



Figure 1. The Relieva Stratus™ MicroFlowSpacer filled with triamcinolone acetonide.

Cone beam computed tomography of paranasal sinuses

In recent years, CBCT scanning has become a competitor to traditional multi-row computed tomography. The major advantage is the lower radiation exposure, which can be as low as one half to one quarter of a standard multi-row CT scanner, and cost is also much lower.

An LM score was used to evaluate the CBCT scans. Each group of sinuses (maxillary, anterior ethmoids, posterior ethmoids, frontal, and sphenoidal) were analysed in cross-sectional images and scored as either completely clear (0), partly opaque (1), or completely opaque (2), and the opacity of the ostiomeatal complex was scored (0 or 2). The scores were added together, resulting in a maximum complete score of 12 per side. The LM score was analysed by the same doctor.

The drug eluting stent

The Relieva Stratus is a temporarily implanted drug-eluting stent. The Relieva Stratus device was introduced in 2009 as a minimally invasive surgical tool to treat chronic ethmoidal sinusitis [27]. The stent is inserted into the ethmoidal sinus complex using an endoscopic view with the aid of fluoroscopy or IGS. The reservoir section of the device contains hundreds of micropores that slowly release a therapeutic agent into the ethmoidal complex (Figure 1). This local and targeted method of drug delivery ensures a high concentration of the anti-inflammatory agent directly into the diseased mucosa. In the US, the FDA has currently approved the Relieva Stratus loaded only with sterile saline. In Europe, the device has a CE Mark approval that also covers the use of triamcinolone acetonide (40 mg/ml). If both sides are implanted, a total amount of 24mg triamcinolone will leak from the pores over a period of four weeks. Triamcinolone acetonide is widely used and thus its potential side effects are well known [28].

The manufacturer of the device recommends that 0.31 ml of sterile saline or triamcinolone acetonide injectable solution (40

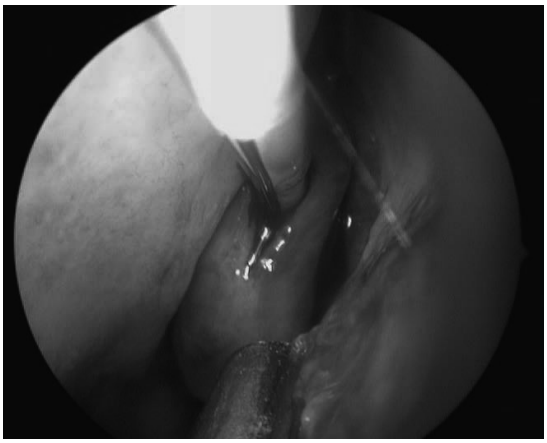

Figure 2. Endoscopic view of the right bulla ethmoidalis. With the help of the IGS insertion, the insertion point can safely be more cranial.

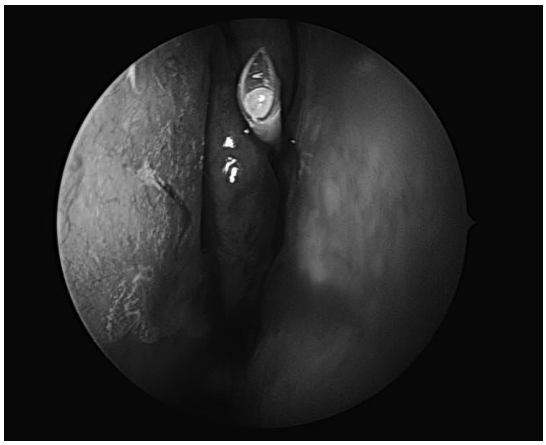

Figure 3. Endoscopic view of the final position of the Relieva Stratus™, MicroFlow Spacer. Only the cut end of the catheter shaft is visible in the picture (left side).

mg/ml) is injected into the catheter [29]. The shaft of the catheter is then cut and the MicroFlow Spacer is left in the ethmoid sinus (Figures 2 and 3). After four weeks, the stent is extracted at an outpatient clinic under local anaesthesia by simply removing it with Blakesley forceps or a similar instrument.
In our hospital the cost of the MicroFlow Spacer is €399 and the cost of the deployment guide is €175. When treating both ethmoidal sinuses the total cost of the devices is €975.
C-arm fluoroscopy guidance was employed for eleven patients and optical IGS-assisted (BrainLAB Kolibri image-guided surgery system) insertions were performed on the other 17 patients. All the insertions of the DES were performed by the same surgeon.

Intranasal corticosteroid spray

Triamcinolone acetonide is extensively used in different kind of drugs and its potential side effects are very well known [28]. The control group using the triamcinolone acetonide nasal spray (Nasacort® 55ug/dose) applied two doses/day for six months. The use of nasal corticosteroid sprays predisposes to minor side effects, with epistaxis being the most common. Patients were instructed how to apply the nasal spray inside the nose and they were also informed that the weight of the spray bottle would be controlled at the end of the study. The drugs (Kenalog40® and Nasacort®) used in this trial were bought from Tampere University Hospital's pharmacy.

Statistical analyses

Statistical analysis and graphical representation of the results were performed using the SPSS 21 software (SPSS Inc., Chicago, IL, USA). The primary variable was the SNOT22 score. Improvement in quality of life was analysed with Wilcoxon Signed Rank test. Differences between the groups were analysed with the Mann–Whitney U test. P values smaller than 0.05 were considered significant.

Results

Subjects

A total 63 patients were enrolled in the study and were randomized into the DES group (n = 34) and nasal spray group (n = 29). The first two DES patients were excluded, because there was too little of the corticosteroid solution inside the reservoir of the stent. Four patients in the DES group were lost to the follow-up (one patient had severe CRS symptoms and was operated on immediately after the removal of the stent, one patient was obliged to use another corticosteroid drug because of another unrelated disease, one patient dropped out having been diagnosed with an unrelated serious disease, and one patient dropped out for personal reasons). Finally, 57 patients (18 males and 39 females) were included in the analysis, 28 to the DES group and 29 to the control group treated with the nasal corticosteroid spray.
No significant differences were identified between the groups when comparing the baseline demographic characteristics (Table 1). The main symptoms were nasal blockage/obstruction/congestion (96.5%), nasal discharge (anterior/posterior drip; 86.0%), facial pain/pressure (80.7%), and reduction or loss of the sense of smell (50.9%) (Table 2). The use of saline nasal irrigation varied greatly; some of the patients used it daily and others only when they had many symptoms.
No statistically significant difference was found between the groups at baseline in the SNOT22 scores, VAS scores, endoscopic scores, LM scores, total nasal volumes, or the measurements of

Table 1. Patient demographic characteristics.

	DES (n=28)	Nasal spray (n=29)	Both groups (n=57)
Mean age ±SD (years)	42.9±11.6	41.1±12.6	42.0±12.1
Sex (M/F)	8/20	10/19	18/39 (31.6%/68.4%)
Smokers	9	10	19 (33.3%)
Mean duration of symptoms (months)	59.4±63.5	55.3±63.3	58.3±62.3
Polyps	5	4	9 (15.8%)
Allergy	8	13	21 (36.8%)
Asthma	4	5	9 (15.8%)
Usage of saline nasal irrigation	19	14	33 (57.9%)
Mean duration of use of steroid spray (months) before the study	20.9±35.8	14.1±26.0	17.4±31.1
Number of courses of antibiotics/patient (six months before the study)	2.1±2.1	2.2±2.1	2.2±2.1

Table 2. Main symptoms.

	DES (n=28)	Nasal spray (n=29)	Both groups (n=57)
Nasal blockage/ obstruction/congestion	27 (96.4%)	28 (96.6%)	55 (96.5%)
Nasal discharge	24 (85.7%)	25 (86.2%)	49 (86.0%)
Facial pain/pressure	23 (82.1%)	23 (79.3%)	46 (80.7%)
Reduction or loss of smell	11 (39.3%)	18 (62.1%)	29 (50.9%)

Table 3. Baseline data.

	DES		Nasal spray		Both groups	
	Mean	SD	Mean	SD	Mean	SD
SNOT22	43.9	±16.9	42.8	±14.2	43.3	±15.5
VAS	5.3	±2.3	5.7	±2.6	5.5	±2.5
AR, total volume (cm^3)	7.7	±2.3	6.8	±2.0	7.3	±2.2
RMM, total inspiratory nasal resistance ($Pa/cm^3/s$)	0.23	±0.25	0.36	±0.35	0.30	±0.31
Endoscopic score	2.0	±1.7	1.9	±2.0	2.0	±1.8
LM score (before the trial)	10.6	±3.2	11.1	±2.6	10.9	±2.9

the total mean airway resistance (Table 3).

SNOT22

At the three- and six-month follow-up visits, the total SNOT22 score showed a significant improvement in both groups, with no significant difference between the two groups. In the DES group, the mean change from the baseline score was -17.0 ± 16.7 ($p<0.001$) after three months and -12.0 ± 13.9 ($p<0.001$) after six months. The same values in the nasal spray group were -10.1 ± 13.8 ($p=0.001$) and -10.2 ± 15.9 ($p=0.002$), respectively. There was a tendency for patients in the DES group to benefit more from the treatment after three months compared to the nasal spray group, but the difference was not statistically significant ($p=0.078$) (Figure 4).

VAS

The average VAS score decreased in both groups. The mean changes were significant at three months (1.4 ± 2.5, $p=0.006$) and at six months (-1.4 ± 3.1, $p=0.026$) in nasal spray group, but in the DES group a significant difference was noted only at three months (-1.9 ± 2.4, $p=0.001$). There were no significant differences between the groups.

Acoustic rhinometry

The total nasal volumes in the nasal spray group increased significantly at three months (1.2 cm^3 ± 2.3 cm^3, $p=0.001$) and six months (1.4 cm^3 ± 2.0 cm^3, $p=0.002$). Total nasal volumes in the stent group did not show any significant changes from the baseline measurements. The differences between the groups were

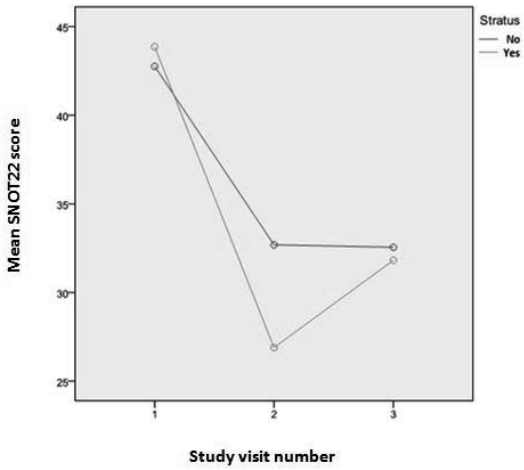

Figure 4. After three months, the SNOT22 scores were lower in the stent group compared to the nasal spray group. However, the difference was not statistically significant (p=0.078).

significant at three months (p=0.025) and six months (p=0.016).

Rhinomanometry and the endoscopic score

There were no (significant) changes in measurements by RMM or the endoscopic score either at three months or six months. No statistically significant difference was found between the groups either.

LM score

In the DES group, the change in LM score was almost statistically significant (-1.9 ± 4.4, p=0.056) when comparing the values before the study to the values at the end of the study. There were no significant differences between the groups.

Use of antibiotics

The use of the antibiotics was significantly reduced in both groups (in the DES group -1.4 ± 2.6, p=0.013 and in the nasal spray group -1.8 ± 2.1, p<0.001) when comparing the mean number of courses of antibiotics to the six-month period before the beginning of the study and the trial period. No difference was found between the groups.

Adverse events

There were no significant immediate or delayed complications in either group. No DES needed to be removed before the end of the four-week treatment period. After the insertion of the stent, some patients experienced minor sensations of local irritation. When the implant was removed, there was minor crusting (n=2) and a small amount of purulent discharge (n=3) around the cut end of the shaft of the catheter in the endoscopy in some patients. One patient needed antibiotics to treat these symptoms. Four patients had minor nose bleeds, which lasted one to two days, after the insertion of the implant; however no interventions were needed to treat them. Two patients from the nasal spray group complained of dryness of the nose.

Discussion

Current standard surgical treatment for chronic inflammatory disease of the ethmoid sinus is endoscopic ethmoidectomy performed with a microdebrider, through-cutting forceps, or a combination of the two. However, the widespread use of these tools has been known to cause adverse effects such as postoperative inflammation, middle meatal scarring, and very rarely complications as severe as cerebrospinal fluid leak, orbital emphysema, and potential visual change or loss of vision. A topical steroid is a beneficial treatment for CRS with and without polyps, but the main disadvantage with the use of the nasal sprays and drops is suboptimal drug delivery to the paranasal sinuses. Other problems with use of nasal sprays include the wrong dosing technique and a lack of motivation to use the medication as regularly and long-lastingly as recommended. The Relieva Stratus is an interesting mini-invasive option to deliver strong corticosteroid medication directly to the diseased paranasal sinus mucosa. Cadaveric studies have demonstrated that insertion of the Relieva Stratus into the ethmoidal sinus using fluoroscopy is relatively safe and easy [17]. There is only one published complication involving the Relieva Stratus in the literature; the DES had been wrongly placed through the lamina papyracea into the orbit. Despite the removal of the device, the pupil of patient's affected eye remained dilated [30]. The U.S. Food and Drug Administration (FDA) has reported one skull base injury caused by the insertion of the Relieva Stratus deployment guide through the posterior ethmoidal roof. The cerebrospinal fluid leak was detected and treated without further complications [31]. There are no prospective, randomized controlled trials addressing the efficacy of the Relieva Stratus or other corticosteroid eluting stents in patients being considered for endoscopic surgery. In our prospective, randomized clinical study, we compared the efficacy of the Relieva Stratus to ideally dosed, regular, long-term use of nasal corticosteroid spray in patients with CRS.

We found that the quality of life measured by SNOT22 score improved significantly in both treatment groups at three and six months of observation. In addition, the VAS score decreased in both groups. The observed benefits of the nasal corticosteroid spray treatment measured by VAS were evident at three months and six months, but in the DES group a significant improvement was noted only at the three month time point. There was a statistically significant increase in the total nasal cavity volumes measured with AR in the corticosteroid spray group at three months and six months, but not in the stent group. The most surprising result was the significant increase of the quality of life

Table 4. Three-month change in measurements of the DES and nasal spray group.

Parameter group	DES change from baseline		Nasal spray change from baseline		Statistical difference between the groups
	Mean	SD	Mean	SD	
SNOT22	-17.0 (p<0.001*)	±16.7	-10.1 (p=0.001*)	±13.8	p=0.078**
VAS	-1.9 (p=0.001*)	±2.4	-1.4 (p=0.006*)	±2.5	NS
AR, total nasal volume (cm^3)	-0.33 (NS)	±2.8	1.2 (p=0.001*)	±2.3	p=0.025**
RMM, total inspiratory nasal resistance ($Pa/cm^3/s$)	0.03 (NS)	±0.29	-0.05 (NS)	±0.34	NS
Endoscopic score	-0.1 (NS)	±1.9	0.4 (NS)	±1.8	NS

*Wilcoxon signed ranks test, **Mann–Whitney U test.

Table 5. Six-month change in measurements of the DES and nasal spray group.

Parameter group	DES change from baseline		Nasal spray change from baseline		Statistical difference between the groups
	Mean	SD	Mean	SD	
SNOT22	-12.0 (p<0.001*)	±13.9	-10.2 (p=0.002*)	±15.9	NS
VAS	-0.7 (NS)	±2.8	-1.4 (p=0.026*)	±3.1	NS
AR total nasal volume (cm^3)	-0.11 (NS)	±2.6	1.4 (p=0.002*)	±2.0	p=0.016**
RMM, total inspiratory nasal resistance ($Pa/cm^3/s$)	0.12 (NS)	±0.58	-0.08 (NS)	±0.25	NS
Endoscopic score	0.1 (NS)	±1.5	-0.2 (NS)	±2.2	NS
LM score	-1.9 (p=0.056*)	±4.4	-0.7 (NS)	2.7	NS
Course of antibiotics/patient six months before trial vs follow-up time	-1.4 (p=0.013*)	±2.6	-1.8 (p<0.001*)	±2.1	NS

*Wilcoxon signed ranks test, **Mann–Whitney U test.

in the nasal spray group, although these patients had already used corticosteroid nasal spray before the study without notable relief of symptoms. The use of the nasal spray increased the total volume of the nasal cavities, most likely by decreasing the mucosal swelling. These results emphasize the importance of the ideal dosing technique, motivation, and regular, long-term administration of the topical corticosteroid medication.

Our hypothesis was that the patients in the DES group would experience better relief of symptoms compared to patients in the nasal corticosteroid group. We found no support for this hypothesis. Instead, when we analysed nasal volumes in AR, we found that patients in the nasal spray group had significantly better results compared to patients in the stent group. The SNOT22 scores between the groups were similar at the beginning and at the end of the study. However, we found that at three months, the SNOT22 scores were lower in the stent group compared to the nasal spray group. The difference was not statistically significant (p=0.078). The fat-soluble triamcinolone acetonide continues to have an effect on the mucosa after the Relieva Stratus has been removed from ethmoid sinuses. It is likely that when reaching the six-month time point, the effect of the corticosteroid of the Relieva Stratus has already diminished and the difference between the groups disappears. This notion is also supported by the finding that there was no statistically significant improvement in VAS score at six months in the stent group. Like asthma, CRS is a chronic disease and corticosteroid medication simply reduces the inflammation caused by various aetiologies and relieves the symptoms; it does not provide a definitive cure for the disease.

There was no placebo group in our study. We wanted to compare the efficacy of the Relieva Stratus to a proven conservative treatment. The national comparative audit of surgery for nasal polyposis and chronic rhinosinusitis was a prospective cohort study of 3,128 adult patients that underwent sinonasal surgery in England and Wales [23]. Hopkins et al. evaluated 2,284 preoperative and postoperative SNOT22 scores for psychometric validation. SNOT22 was able to discriminate between patients known to suffer from CRS and a group of healthy controls. They found that the minimum difference detectable with the SNOT22 scoring scheme was 8.9 points [23]. In that study, the mean preoperative SNOT22 score of patients undergoing primary surgery was 39.6, which is similar to our results (43.3). Furthermore, in the present study, the mean change in SNOT22 scores after the treatment period was >10 in both groups.

In our study, the baseline LM scores were quite low (10.6 ± 3.2 in the DES group and 11.1 ± 2.6 in the nasal spray group), because we excluded from the study those patients that had an LM score of more than 1 in the maxillary, frontal, or sphenoidal sinuses. Because the target area of the Relieva Stratus is the ethmoidal cells, we found it unethical to treat patients with severe sinus pathology in maxillary, frontal, and sphenoidal sinuses (LM score 2) only with the DES. Therefore, in our study the maximum LM score was 18 instead of the normal maximum of 24.

In the operating instructions [29] provided by Acclarent Inc. and also in previous studies, it was recommended that 0.31 ml of the therapeutic agent should be injected into the catheter. We found this amount to be too small because of the dead space of the catheter shaft. To ensure that the Spacer reservoir is filled one must inject at least 0.6 ml of the solution into the catheter. Any excess solution leeches out into the ethmoidal cavities. This technical detail was the reason why we excluded the first two patients in the Relieva Stratus group.

The six month follow-up time might be too short to evaluate the long-term effect of the DES. All the patients who participated in the study had severe symptoms and were candidates for surgery, so a six month follow-up period was considered feasible and we considered a longer follow-up to be unethical.

When comparing antibiotic use six months before the study and then during the study, we found a significant decrease in both groups. It is most likely that before the study CRS symptoms were treated as acute bacterial rhinosinusitis. At the beginning of the study, the patients were educated about the inflammatory nature of CRS and the poor efficacy of short term antibiotic treatment. After this, the use of the antibiotics decreased dramatically.

In our study, the mean SNOT22 score change after three months in the patients treated with DES was 17.0, which is quite similar to the results of the national comparative audit of surgery for nasal polyposis and chronic rhinosinusitis study [23], where the mean SNOT22 score was 16.2 points lower after the ESS surgery than preoperatively. Of course, the results of these two studies cannot be compared completely because of the methodological differences between the study designs, but our results give an indication that Relieva Stratus is an effective therapy in treating patients with CRS.

The postoperative treatment of CRS after ESS includes local corticosteroid therapy [20]. In our study, the DES has been investigated as a monotherapeutic treatment. It is possible that combined therapy with the DES and the nasal corticosteroid spray therapy could be even more efficient.

Targeted administration of corticosteroids using the DES might be a considerable tool for the treatment of chronic ethmoiditis instead of ESS in cases where we want to avoid systemic corticosteroids or surgery, or where the diseased area in the ethmoidal sinuses is highly localized.

Conclusion

Patients benefitted from the Relieva Status as well as from the corticosteroid nasal spray, and quality of life improved for both groups. With the exception of a greater improvement in nasal volumes in the nasal spray group, no significant difference was observed between the treatment methods. The insertion of the Relieva Stratus requires an operation room involving fluoroscopy or the IGS system, and the material costs of the device is considerably higher compared to the use of the corticosteroid spray. Overall, compared to the corticosteroid nasal spray therapy, there was no remarkable advantage in using the Relieva Stratus stent technique as a monotherapy that would justify its increased costs and potential side effects.

The surprising result was the significant increase of the quality of the life also in the nasal spray group, since patients had already used corticosteroid nasal spray before the study without any significant results. This result emphasizes the importance of the ideal dosing technique, motivation, and the regular, long-term administration of the topical corticosteroid therapy.

Acknowledgements

To research nurse Piitu Oksanen for ensuring patients´smooth coordination and support throughout the study and to Niko Sillanpää MD, PhD for scientific and linguistic help.

Authorship contribution

RT: Principal researcher of the study, study design, recruitment of new patients, clinical examination of patients before and after the intervention, insertions of the drug eluting stents, collection and analysis of data, writing of the manuscript. AB: Manuscript review. JN: Study design, manuscript review. MR: Study design, manuscript review.

Conflict of interest

None of the authors had any conflict of interest with any finan¬cial organization. This study was not sponsored by Acclarent Inc. or any other pharmaceutical companies or any other personal or institutional funds.

References

1. Blackwell DL, Collins JG, Coles R. Summary health statistics for U.S. adults: National Health Interview Survey, 1997. Vital Health Stat 10 2002; 205: 1-109.
2. Hastan D, Fokkens WJ, Bachert C, et al. Chronic rhinosinusitis in Europe—an underestimated disease. A GA(2)LEN study. Allergy 2011; 66(9): 1216-23.
3. Pilan RR, Pinna FR, Bezerra TF, et al. Prevalence of chronic rhinosinusitis in Sao Paulo. Rhinology 2012; 50(2): 129-38.
4. Gliklich RE, Metson R. The health impact of chronic sinusitis in patients seeking otolaryngologic care. Otolaryngol Head Neck

Surg. 1995; 113: 104-9.
5. Murphy MP, Fishman P, Short SO, et al. Health care utilization and cost among adults with chronic rhinosinusitis enrolled in a health maintenance organization. Otolaryngol Head Neck Surg. 2002; 127(5):
6. Lund VJ, Black JH, Szabo LZ, et al. A Efficacy and tolerability of budesonide aqueous nasal spray in chronic rhinosinusitis patients. Rhinology 2004; 42(2): 57-62.
7. Snidvongs K, Kalish L, Sacks R, et al. Topical steroid for chronic rhinosinusitis without polyps. Cochrane Database Syst Rev. 2011: CD009274.
8. Kalish L, Snidvongs K, Sivasubramaniam R, et al. Topical steroids for nasal polyps. Cochrane Database Syst Rev. 2012 Dec 12; 12:CD006549.
9. Snidvongs K, Chaowanapanja P, Aeumjaturapat S, et al. Does nasal irrigation enter paranasal sinuses in chronic rhinosinusitis? Am J Rhinol 2008; 22(5): 483-6.
10. Hopkins C, Browne JP, Slack R, et al. The national comparative audit of surgery for nasal polyposis and chronic rhinosinusitis. Clin Otolaryngol. 2006; 31(5): 390-8.
11. Ragab SM, Lund VJ, Scadding G. Evaluation of the medical and surgical treatment of chronic rhinosinusitis: a prospective, randomised, controlled trial. Laryngoscope 2004; 114(5): 923-30.
12. Harvey RJ, Goddard JC, Wise SK, et al. Effects of endoscopic sinus surgery and delivery device on cadaver sinus irrigation. Otolaryngol Head Neck Surg. 2008; 139(1): 137-42.
13. Grobler A, Weitzel EK, Buele A, et al. Pre- and postoperative sinus penetration of nasal irrigation. Laryngoscope 2008; 118(11): 2078-81.
14. Murr AH, Smith TL, Hwang PH, et al. Safety and efficacy of a novel bioabsorbable, steroid-eluting sinus stent. Int Forum Allergy Rhinol. 2011; 1(1): 23–32.
15. Forwith KD, Chandra RK, Yun PT, et al. ADVANCE: a multi-site trial of bioabsorbable steroid-eluting sinus implants. Laryngoscope 2011; 121(11): 2473–2480.
16. Marple BF, Smith TL, Han JK, et al. ADVANCE II: a prospective, randomized study assessing safety and efficacy of bioabsorbable steroid-releasing sinus implants. Otolaryngol Head Neck Surg. 2012; 146(6): 1004–1011.
17. Melroy CT, Kuhn FA. Safety of Ethmoid Sinus Drug-Eluting Catheter Insertion. Ann Otol Rhinol Laryngol. 2009; 118(10): 708-713.
18. Taulu R, Numminen J, Bizaki A, et al. Image-guided, navigation-assisted Relieva Stratus MicroFlow Spacer insertion into the ethmoid sinus. Eur Arch Otorhinolaryngol. 2015; 272(9): 2335-40.
19. Catalano PJ, Thong M, Weiss R, et al. The MicroFlow Spacer: A Drug-Eluting Stent for the Ethmoid Sinus. Indian J Otolaryngol Head Neck Surg. 2011; 63(3): 279-84.
20. Fokkens W, Lund V, Mullol J, et al. European position paper on rhinosinusitis and nasal polyps 2007. Rhinology Suppl. 2007; (20): 1-136
21. Finnish current care guideline for sinusitis. Published 26 September 2013. Available from: http://www.kaypahoito.fi/web/english/guidelineabstracts/guideline?id=ccs00022 Accessed 17 January 2016
22. Minim: Allocation by minimisation in clinical trials. Available from: https://www-users.york.ac.uk/~mb55/guide/minim.htm Accessed 17 January 2016
23. Hopkins C, Gillet S, Slack R, et al. Psychometric validity of the 22-item Sinonasal Outcome Test. Clin Otolaryngol. 2009 Oct; 34(5): 447-54.
24. Numminen J, Dastidar P, Heinonen T, et al. Reliability of acoustic rhinometry. Respir Med. 2003; 97(4): 421-7.
25. Straszek SP, Schlüssen V, Sigsgaard T , et al. Reference values for acoustic rhinometry in decongested school children and adults: the most sensitive measurement for change in nasal patency. Rhinology 2007; 45(1): 36-9.
26. Lund VJ, Scadding GK. Objective assessment of endoscopic sinus surgery in the management of chronic rhinosinusitis: an update. J Laryngol Otol. 1994; 108(9): 749-53.
27. Catalano PJ, Thong M, Garg V. The MicroFlow Spacer: a drug-eluting stent for the ethmoid sinus. Operat Tech Otolaryngol Head Neck Surg. 2009; 20: 108–113
28. Derendorf H, Meltzer EO. Molecular and clinical pharmacology of intranasal corticosteroids: clinical and therapeutic implications. Allergy 2008; 63(10): 1292–1300
29. Instructions for use of Relieva Stratus MicroFlow Spacer, MenloPark. Available from: http://acclarent.ru/sites/default/files/speyser_i_buzh_relieva_stratus_dlya_reshetchatogo_labirinta.pdfAccessed 17 January 2016
30. Sjogren PP, Parker NP, Boyer HC. Retained drug-eluting stents and recalcitrant chronic rhinosinusitis: A case report. Allergy Rhinol (Providence) 2013; 4(1): 45-8.
31. MAUDE Adverse Event Report: Acclarent, INC. Relieva Stratus deployment guide. U.S. Food and Drug Administration. Available from: http://www.accessdata.fda.gov/scripts/cdrh/cfdocs/cfMAUDE/detail.cfm?mdrfoi__id=2647842 Accessed 17 January 2016

Rami Taulu
Department of Otorhinolaryngology
Tampere University Hospital
Teiskontie 35, Box 2000
33521 Tampere
Finland

Tel: +358331169456
E-mail: rami.taulu@pshp.fi

PUBLICATION III

Ethmoidal drug-eluting stent therapy is not superior to nasal corticosteroid spray in the prevention of endoscopic sinus surgery: results from a randomised, clinical trial

Taulu R, Sillanpää N, Numminen J, Rautiainen M

Clinical Otolaryngology (2020) 45(3):402–408

Ethmoidal drug-eluting stent therapy is not superior to nasal corticosteroid spray in the prevention of endoscopic sinus surgery: results from a randomized, clinical trial

Authors:

Rami Taulu, MD, Principal investigator

Niko Sillanpää, MD, PhD

Jura Numminen, MD, PhD

Markus Rautiainen, MD, PhD

Affiliation:

Department of Otorhinolaryngology, Head and Neck Surgery, Faculty of Medicine and Health Technology, Tampere University and Tampere University Hospital

Corresponding Author:

Rami Taulu

ORCID ID: 0000-0002-0529-9561

Full postal address:

Department of Otorhinolaryngology, Tampere University Hospital, Teiskontie 35, Box 2000, 33521 Tampere, Finland

Telephone: +358 331169456

E-mail address: rami.taulu(at)pshp.fi

Acknowledgements:

We thank Piitu Oksanen for ensuring the smooth coordination and support of patients throughout the study.

Funding and Conflict of Interest:

The authors report no conflicts of interest.

ABSTRACT

Objectives: To evaluate whether an ethmoidal drug-eluting stent (DES) (the Relieva Stratus™ MicroFlow Spacer) could better prevent endoscopic sinus surgery (ESS) than standard non-invasive therapy using corticosteroid nasal spray in patients suffering from chronic rhinosinusitis (CRS).

Design: Prospective, randomised clinical trial.

Setting: Tertiary referral centre.

Participants: Sixty-three adult patients with ethmoidal involvement in cone beam computed tomography (CBCT) whose first-line medical treatment with topical corticosteroids had failed and who were candidates for ESS were randomised either to a DES group, which received triamcinolone acetonide stents (n=34), or to a topical intranasal corticosteroid group (n=29) that used optimally dosed triamcinolone acetonide nasal spray.

Outcome measures: Patients were followed up prospectively for six months and at 36 months. Freedom from ESS was the primary endpoint. Further, we identified those factors predicting ESS.

Results: At 6 months, ESS could be prevented in almost half of the patients in both groups (DES 13/28, 46.4%, nasal spray 14/29, 48.3%). At 36 months, 20/28 (71.4%) patients in the DES group and 18/29 (62.1%) in the nasal spray group had been operated. The differences were not statistically significant at either timepoint. Patients who smoked (14/19, 73.7% vs 16/38, 42.1%) were more likely to be operated at 6 months.

Conclusion: ESS can be prevented using both therapies in the medium term in almost half of cases with neither therapy being statistically superior. This effect was somewhat diminished in the long term with a trend towards more patients being operated in the DES group. Considering the additional costs, the need for general anesthesia and the potential side effects associated with DES, its potential clinical role appears to be limited. Smoking was significantly associated with ESS.

Key points

- Drug eluting stent is a novel application route for nasal topical medication.
- Our results show that the Relieva Stratus device and optimally dosed and regularly used nasal corticosteroid spray seem to be effective and equal monotherapies in the treatment of CRS.
- However, considering the additional costs, the need for general anesthesia and the potential side effects associated with DES, the potential clinical role of the therapy appears to be limited in this indication.
- Almost half of the patients in both groups did not need ESS at six months of follow-up.
- Smoking seems to be a significant risk for failed medical treatment of CRS leading to ESS.

KEYWORDS

Chronic rhinosinusitis, ethmoiditis, drug-eluting stent, steroid-eluting stent, Relieva Stratus Micro Flow Spacer, nasal corticosteroids, endoscopic sinus surgery, smoking

INTRODUCTION

Chronic rhinosinusitis (CRS) is a general term describing a group of disorders characterised by chronic inflammation of the mucosa of the nose and paranasal sinuses with symptoms that have persisted for more than 12 weeks [1]. CRS is a common problem that causes a substantial economic burden on society and healthcare systems [2]. The aims of the treatment of CRS include reduction of mucosal oedema and inflammation, the re-establishment of sinus ventilation and the eradication of infecting pathogens.

Intranasal glucocorticoid therapy is the first-line treatment of CRS. There is robust evidence on the efficacy of topically administered glucocorticoid therapy in the treatment of CRS with or without nasal polyps [3-5]. The topical administration route is safe and only minor side effects, such as mucosal irritation, crusting and minor nose bleeds, have been reported [4]. The complexity of the sinus anatomy

and the mucosal oedema of CRS patients can, however, cause major problems in the delivery of the drug to the affected paranasal sinus mucosa [6].

Several large prospective studies have shown that endoscopic sinus surgery (ESS) is an effective and safe method of treatment for patients with CRS when drug therapy has failed [7,8]. One of the advantages of ESS is that the delivery of topical glucocorticoids to the paranasal sinuses is easier postoperatively [9,10].

Steroid-eluting sinus stents are devices that are inserted into the nose or paranasal sinuses to achieve local, controlled release of a known dose of corticosteroid drug directly into the sinus mucosa. Stents are mostly used in the postoperative management of ESS to dampen inflammation and to prevent postoperative complications, such as adhesions, scarring or polyp formation [11,12].

The Propel® steroid-releasing implant (Intersect ENT, Palo Alto, California, USA) is a bioabsorbable mometasone furoate-eluting stent. This spring-like implant, which dissolves in approximately 30 days, maintains the surgical opening after ethmoidectomy and delivers corticosteroid directly to the sinus mucosa. Sinuband FP® (BioInspire Technologies, Palo Alto California, USA) is a bioabsorbable, fluticasone propionate-eluting stent placed directly into the sinus post-surgery to accelerate recovery.

Unlike other drug-eluting stents (DES), the Relieva Stratus™ Micro-flow Spacer (Relieva Stratus; Acclarent Inc. California, US) is inserted into the affected paranasal sinuses in order to avoid surgery and to preserve normal ethmoid sinus anatomy. Previously, it has been used to treat frontal, ethmoidal and sphenoidal disease. A prospective randomised trial showed the Relieva Stratus to be efficient and safe to use when treating patients with chronic rhinosinusitis [13]. To evaluate the clinical implications of the DES, we wanted to find out whether we could prevent ESS by using the Relieva Stratus.

In this paper, we report the results of a randomised, controlled clinical trial on patients diagnosed with CRS with ethmoidal involvement based on cone beam computed tomography (CBCT) scan findings. Our primary objective was to find out whether the ethmoidal DES could better prevent ESS in the medium term in comparison with standard non-invasive therapy with corticosteroid nasal spray. A

secondary objective was to retrospectively evaluate whether the DES could prevent ESS in the long term and/or provide other benefits.

MATERIAL AND METHODS

Subjects

A total of 63 patients suffering from chronic ethmoiditis were prospectively recruited into a randomised, controlled clinical trial in the Department of Otorhinolaryngology of Tampere University Hospital, Finland over a 42-month period. The patients were randomised to receive either ethmoidal DES or optimal drug therapy with nasal corticosteroid spray. All the recruited patients were referred from outpatient clinics. A flowchart of Study Enrollment and Participation is provided in Figure 1.

Details of the inclusion and exclusion criteria have been published earlier in our previous report [13] and are also provided in the supplementary material.

All patients included in the study were eligible for ESS as per the guidelines at the time of randomisation. At the beginning of the study, patients were informed that participation in the study did not rule out surgery and that the decision to operate later on would be taken based on the level of subjective relief of their symptoms and findings in CBCT images, which were evaluated at 6 months. Only one doctor (RT) conducted the follow-up visits to ensure that the evaluation of the severity of the symptoms was as uniform as possible. The extent of the surgery was based on the CBCT findings and the symptoms of the patients.

The first patient visit was an enrollment and randomisation visit during which time informed consent and patient histories were obtained and CBCT scans were evaluated. From this point began a four-week wash-out period. During this period, patients were forbidden to use any medication containing corticosteroids. Other medication used to treat the symptoms of CRS was allowed (no patients used prolonged-course low-dose macrolide antibiotic drugs). After the four-week wash-out period, all the patients in the DES group underwent bilateral stent placement under general anaesthesia. Patients in the nasal spray group were instructed on the optimal way to administer the drug, and they were informed

that the nasal spray dosers would be weighed at every visit to verify that the drug was being used as instructed. Any other drugs containing corticosteroids were forbidden in both groups for as long as the prospective part of the trial continued. All patients completed the SNOT22 questionnaire. The DES was removed after four weeks at an outpatient clinic under local anaesthesia. After six months, the SNOT22 scores were re-evaluated.

After the prospective part of the study, all patients, including those who underwent ESS or who were randomised to the DES group, were instructed in the optimal way to administer the nasal corticosteroid spray. In addition, they were also encouraged to use the nasal spray regularly to treat their CRS.

Finally, information on provisional ESS within 36 months of randomisation was gathered from patient records and by contacting the patients.

Study groups

The randomisation was performed using the MINIM MS-DOS program [14] that allocates by minimisation and runs interactively throughout the study. The groups were randomised using the following parameters: age, sex, asthma, nasal polyposis and use of tobacco. The power analysis was performed as described in our previous report [13].

Sino Nasal Outcome Test-22 Quality of Life Questionnaire

The SNOT22 is a validated, rhinosinusitis-specific quality of life instrument that contains 22 individual questions about nasal symptoms and quality of life [15].

The drug-eluting stent

The Relieva Stratus device was introduced in 2009 as a minimally invasive surgical tool to treat chronic ethmoidal sinusitis [16]. The stent is inserted into the ethmoidal sinus complex using an endoscopic view with the aid of fluoroscopy or image-guided surgery (IGS). The anterior face of the ethmoid bulla is exposed under direct endoscopic view. During the insertion of the stent, the access probe (trocar) and a delivery sheath are positioned in the inferomedial part of the bulla ethmoidalis to avoid the possibility

of penetrating the skull base or lamina papyracea (Supplementary figure 2). C-arm fluoroscopy or IGS and a so-called "shark-fin" handle are used to ensure that the correct angle and trajectory are established (Supplementary figure 3). This is followed by insertion of the delivery sheath-containing access probe into the ethmoidal cavities. The access probe is then withdrawn and the delivery sheath is left inside the ethmoidal sinus. The Relieva Stratus and a catheter are inserted through the delivery sheath into the ethmoidal cells and the delivery sheath is then completely withdrawn. Correct positioning of the Relieva Stratus is confirmed by direct endoscopic visualisation and fluoroscopy or IGS (Supplementary figure 4). The shaft of the catheter is then cut, and the MicroFlow Spacer is left in the ethmoid sinus (Supplementary figure 5). The reservoir section of the device contains many hundreds of micropores that slowly release a therapeutic agent into the ethmoidal complex. This local and targeted method of drug delivery ensures a high concentration of the anti-inflammatory agent directly into the diseased mucosa. If both sides are implanted, a total dose of 24 mg of triamcinolone will be released from the pores over a period of four weeks. Triamcinolone acetonide is widely used, and therefore the potential side effects are well known [17].

The manufacturer of the device recommends that 0.3 ml of sterile saline or triamcinolone acetonide injectable solution (40 mg/ml) is injected into the catheter [16]. We found this amount to be too small because of the dead space in the catheter shaft. Therefore, to ensure that the Spacer reservoir is full, at least 0.6 ml of the solution should be injected into the catheter. Any excess solution leeches out into the ethmoidal cavities. The shaft of the catheter is then cut and the MicroFlow Spacer is left in the ethmoid sinus. After four weeks, the stent is extracted at an outpatient clinic under local anaesthesia by simply removing it with Blakesley forceps or similar instrument.

C-arm fluoroscopy guidance was employed for eleven patients and optical IGS-assisted (BrainLAB Kolibri image-guided surgery system) insertions were performed on the remaining 17 patients. All the insertions of the DES were performed by the same surgeon (RT) with no intraoperative complications.

Intranasal corticosteroid spray

Triamcinolone acetonide is extensively used in different kinds of drugs, and its potential side effects are very well known [17]. The nasal spray control group (Nasacort® triamcinolone acetonide, 55 ug/dose) used 2 doses/nostril /day for 6 months. The use of nasal corticosteroid sprays predisposes to minor side effects with epistaxis being the most common. Patients were instructed on how to correctly apply the nasal spray, and they were also informed that the weight of the spray bottles would be checked at the end of the study. The drugs (Kenalog40®, 40 mg/ml, Bristol-Myers-Squibb Company) and Nasacort®, 55 ug/dose, Sanofi) used in this trial were purchased from the pharmacy of Tampere University Hospital.

Statistical analyses

Statistical analyses of the results were performed and composed using SPSS 21 software (SPSS Inc., Chicago, IL, USA). The differences between the groups were analysed with Mann-Whitney U test and chi-squared test. P-values smaller than 0.05 were considered significant.

Ethical considerations

The trial protocol was approved by the Institutional Review Board of Pirkanmaa Hospital District, Tampere University Hospital (ETL code R10098M, EudraCT 2010-022188-37). Patients received no financial compensation for their participation in this study. For ethical reasons, at the time of enrollment, all patients were added to the surgery queue to make sure that participation in the study would not further delay surgery should it be needed at the end of the study.

Data availability statement

'The data that support the findings of this study are available on request from the corresponding author. The data are not publicly available due to privacy or ethical restrictions.'

RESULTS

A total of 63 patients were enrolled in the study and were randomised into the DES group (n = 34) and the nasal spray group (n = 29). Two patients in the DES group were excluded because the amount of corticosteroid solution injected into the reservoir of the stent was too small. A further four patients in the DES group were lost to follow-up - one patient had severe CRS symptoms and was operated right after the removal of the stent one month after the insertion; one patient needed to use other corticosteroid drugs because of an unrelated condition; one patient dropped out having been diagnosed with an unrelated serious illness, and one dropped out for personal reasons. Finally, 57 patients (18 male and 39 female) were included in the analysis, 28 in the DES group and 29 in the control group.

No significant differences were found between the groups in baseline demographic characteristics (Table 1), and the main symptoms were similar in both groups (Table 2). The use of saline nasal irrigation varied a lot; some of the patients used it daily and others just when they had more symptoms.

The patients included in the study could have had partial opafication of sinuses (LM of 1) other than ethmoids. At the time of randomisation, partial opafication of at least one of the the maxillary sinuses was found in 55 (96.5%), one of the sphenoid sinuses in 35 (61.4%) and one of the frontal sinuses in 33 patients (57.9%). After six months, the results were similar with the numbers being 55 (96.5%), 36 (63.1%) and 36 (56.1%), respectively. The mucosal disease was predominantly localised in the ethmoidal cavities and the partial opafication of the other sinuses was usually minor in severity and caused by the thickening of the mucosa on the walls of the sinuses.

The patients who underwent surgery had non-significantly higher baseline mean LM-scores (11.2 ± 2.7 vs 10.5 ± 3.1, p=0.53). After the six-month study period, this difference was somewhat larger (10.7 ± 3.0 vs 8.3 ± 4.7, p=0.073), but still non-significant.

After six-month follow-up, 15/28 (53.6%) of the patients in the DES group and 15/29 (51.7%) in the nasal spray group underwent ESS. During the 6 to 36 months extended follow-up period, five more patients in the DES group 20/28 (71.4%) and three more in the nasal spray group 18/29 (62.1%) underwent ESS. There were no statistical differences between the groups.

In total, after the six-month follow-up, 30/57 (52.6%) patients underwent ESS and a further 38/57 (66.7%) during the full 36-month follow-up period.

Uncinectomy or middle meatal antrostomy was performed for all of the operated patients. Four patients underwent only middle meatal antrostomy or uncinectomy because there were only minor changes remaining in the ethmoids in the control CBCT. Partial or total ethmoidectomies were performed in 89.5% (34/38) of the patients, sphenotomies in 2 patients and minimal frontal ostium sinotomy (draf IIa) in 2 patients.

The patients who were operated after 6 months had significantly higher baseline mean SNOT-22 scores (48.0 ± 14.8 vs 38.0 ± 14.8, p=0.011) and they also benefited less from the treatments than those patients who were not operated (mean change in SNOT-22 score from baseline to 6 months, -6.3 ± 12.5 vs -16.4 ± 15.7, p= 0.006). There was no significant difference in the mean change in SNOT-22 score between the DES group and the nasal spray group among those patients who were operated right after the 6-month follow-up period (-6.1 ± 10.4 vs -6.5 ± 14.6) or those patients who were not operated (-18.8 ± 14.7 vs -14.2 ±16.8).

The use of tobacco was the only variable that was significantly associated with ESS at 6 months. At this time point, 14 of the 19 (73.7%) smokers and 16 of the 38 (42.1%) non-smokers were operated (p=0.024).

DISCUSSION

Topical steroids are beneficial in the treatment of CRS with and without polyps. However, the main disadvantage with the use of the nasal sprays and drops is suboptimal drug delivery to the paranasal sinuses. Another problem with the use of nasal sprays is wrong dosing technique and lack of motivation to use the medication as regularly and for as long as recommended [18]. The Relieva Stratus device enables local and targeted delivery of corticosteroids to the affected ethmoid mucosa while at the same time preserving the normal ethmoid sinus anatomy. The efficacy and safety of the Relieva Stratus in

comparison with ESS and nasal corticosteroid therapy have been established in two previous randomised studies with follow-up periods of up to 12-month [13,19].

We compared the Relieva Stratus with the optimally dosed, regular, long-term use of nasal corticosteroid spray in patients with severely symptomatic CRS to find out whether these treatments could prevent ESS in the medium and/or long term. To the best of our knowledge, no previous studies have compared different treatment modalities in preventing ESS in patients with CRS when first-line medical treatment had failed. In standard clinical workup, most or perhaps all of these patients would have been operated. Moreover, the spontaneous relief of symptoms would have been very unlikely considering the long duration of the symptoms (mean: 58 months).

At the end of the prospective follow-up at 6 months, nearly equal proportions of patients in both groups chose not to be operated, although at the beginning of the study all patients were guaranteed an operation should they still need it. Thus, these treatments may prevent ESS in almost half of the cases in the medium term. This emphasises the importance of properly instructing CRS patients on the optimal dosing technique and motivating the patients to ensure regular, long-term administration of the topical corticosteroid therapy. Further, the effect of the Relieva Stratus, removed after one month, was sustained for six months. It is possible therefore that this kind of high-dose, targeted drug delivery can better heal the sinus mucosa and provide a prolonged anti-inflammatory effect and/or the long-acting, fat-soluble triamcinolone acetonide continues to have an effect on the mucosa even after the DES has been removed.

Three years after the initiation of the treatments, five more patients in the DES group and three in the nasal spray group had been operated with no statistically significant difference between the groups. The results suggest that ESS can be prevented in the long term with properly supervised corticosteroid therapy in close to one third of all surgical candidates referred to a tertiary centre.

The imaging findings in the non-ethmoidal sinuses were less severe and in only four patients were sinuses other than the ethmoids or maxillaries operated in addition to ethmoidectomy. The ethmoidectomy procedure also included middle meatal antrostomies or uncinectomies as per our local

clinical guideline. Four patients received only widening of the maxillary sinus opening because their findings in the ethmoids in the control CBCT were none or minimal. Thus, in these patients, it is plausible that sinus disease other than ethmoidal contributed to the need for surgery. However, we chose to include these patients because they did have ethmoidal disease in the enrollment CBCT, still had CRS symptoms and it was possible that surgery of the infundibular area could also have had a positive effect on the mucosal disease of the anterior ethmoidal sinuses.

The sensitivity of the LM-scoring system in the evaluation of the extent of the mucosal disease in the sinonasal cavities is suboptimal. The scoring system allocates the same score to both minimal mucosal swelling and subtotal opafication of the sinus. Hence, we did not find a significant difference in pre- or post-treatment LM scores between those patients who underwent surgery and those who did not.

There was a correlation between the baseline SNOT-22 values, the mean change from the baseline at 6 months and whether patients were operated or not, with those patients with more severe symptoms and who were less responsive to therapy having higher odds of operation. This highlights the validity and usefulness of the SNOT-22 scoring system.

We have previously reported the pre- and post-treatment SNOT-22 scores for both DES and nasal spray groups [13]. The baseline SNOT-22 scores were 43.9±16.9 in the DES group and 42.8±14.2 in the nasal spray group. In the DES group, the mean change from the baseline score was -17.0 ± 16.7 ($p<0.001$) after three months and -12.0 ± 13.9 ($p<0.001$) after six months. In the nasal spray group, the results were -10.1 ± 13.8 ($p=0.001$) and -10.2 ± 15.9 ($p=0.002$), respectively. There was no significant difference between the groups.

Based on the findings of this study in combination with the results of our previous report [13], we could find no therapeutic advantage for the use of the Relieva Stratus stent as monotherapy compared with the nasal corticoid spray therapy that would justify the increased costs, the need for general anesthesia and the risk of procedure-related complications associated with this technique. Targeted administration of corticosteroids with a DES might be a potential tool for the treatment of chronic ethmoiditis in cases

where we want to boost the efficacy of the corticosteroid nasal spray therapy while avoiding systemic corticosteroids or surgery or when the diseased area in the ethmoidal sinuses is limited.

We also found that tobacco use significantly predicted ESS (74% of smokers vs 42% of non-smokers). There have been no previous studies, as far as we know, that directly address whether tobacco use predicts operative treatment of CRS among patients receiving topical corticosteroids. A recent systematic review of the association between cigarette smoke exposure and CRS reports that active smoking increases the risk of CRS with a dose-response pattern and that former smoker status and passive exposure may also increase the risk [20]. The data indicate that the association between smoking and CRS outcomes is not benign, but the strength and magnitude of the effect of smoking are not fully characterised. The authors of the review concluded that there is not enough data to support smoking as a contraindication to surgical treatment of CRS because both smokers and non-smokers experience subjective improvements in symptoms after ESS. Our results suggest that smoking cessation in combination with topical corticosteroids might yield better prevention of ESS than corticosteroid treatment alone.

Limitations

The main limitation of this study was the lack of a placebo group. It is possible and even probable that some of the positive effects, especially in the DES group, when treating patients with a novel surgical treatment were placebo. Lacking the placebo-controlled study-design, we chose to compare the efficacy of the Relieva Stratus to a proven conservative treatment. Further, the differing dropout rates in the two treatment groups warrant caution in the interpretation of the results. The long-term data were obtained retrospectively, but the study groups had been prospectively randomised as described above. Direct inference about the efficacy of DES and nasal spray is not possible in this period because of confounding factors, such as the use of other corticosteroids and recall bias. However, the general preventive effect of the previous interventions can be evaluated. Symptoms caused by involvement of sinuses other than the ethmoids may have influenced the decision to proceed to ESS. However, all patients had CBCT-

verified involvement of the ethmoid sinuses at enrolment and received therapy that potentially had a treatment effect on all sinuses.

CONCLUSION

The Relieva Stratus device and nasal corticosteroid spray seem to be effective and equal monotherapies in the treatment of CRS that can prevent almost half of ESS in the medium term (6 months) among patients whose previous medical therapy had failed and who were candidates to undergo ESS. This effect was somewhat diminished, however, in the long term (36 months) with close to one third of patients avoiding ESS in both groups. Conversely, the Relieva Stratus stent technique was non-superior to nasal corticosteroid therapy and thus the added costs, need for general anesthesia and the potential side effects are difficult to justify. This result emphasises the importance of optimal dosing technique, motivation and the regular, long-term administration of topical corticosteroid therapy in the primary treatment of CRS. Tobacco use was significantly associated with ESS.

AUTHORSHIP CONTRIBUTION

RT: Principal researcher of the study was responsible for study design, recruitment of new patients, the clinical examination of patients before and after the intervention, the insertions of the drug eluting stents, the collection and analysis of data, and the writing of the manuscript. NS: was responsible for study design and manuscript review. JN: was responsible for study design and manuscript review. MR: was responsible for study design and manuscript review.

REFERENCES

1. Fokkens WJ, Lund VJ, Mullol J, et al. European position paper on rhinosinusitis and nasal polyps 2012. Rhinol Suppl 2012;23:298.

2. Rudmik L. Economics of chronic rhinosinusitis. Curr Allergy Asthma Rep 2017;17(4):1-10.

3. Kalish L, Snidvongs K, Sivasubramaniam R, Cope D, Harvey RJ. Topical steroids for nasal polyps. The Cochrane database of systematic reviews 2012;12:CD006549.

4. Snidvongs K, Kalish L, Sacks R, Craig JC, Harvey RJ. Topical steroid for chronic rhinosinusitis without polyps. The Cochrane database of systematic reviews 2011;8:CD009274.

5. Valerie J Lund, John H Black, László Z Szabó, Camilla Schrewelius, Anders Akerlund. Efficacy and tolerability of budesonide aqueous nasal spray in chronic rhinosinusitis patients. Rhinology 2004;42(2):57-62 .

6. Snidvongs K, Chaowanapanja P, Aeumjaturapat S, Chusakul S, Praweswararat P. Does nasal irrigation enter paranasal sinuses in chronic rhinosinusitis? American Journal of Rhinology 2008;22(5):483-486.

7. Noon E, Hopkins C. Review article: Outcomes in endoscopic sinus surgery. BMC Ear, Nose and Throat Disorders 2016;16(1):1-10.

8. Georgalas C, Cornet M, Adriaensen G, et al. Evidence-based surgery for chronic rhinosinusitis with and without nasal polyps. Curr Allergy Asthma Rep 2014;14(4):1-7.

9. Harvey RJ, Goddard JC, Wise SK, Schlosser RJ. Effects of endoscopic sinus surgery and delivery device on cadaver sinus irrigation. Otolaryngol Head Neck Surg 2008;139(1):137-142.

10. Grobler A, Weitzel EK, Buele A, et al. Pre- and postoperative sinus penetration of nasal irrigation. Laryngoscope 2008;118(11):2078-2081.

11. Campbell RG, Kennedy DW. What is new and promising with drug-eluting stents in sinus surgery? Current opinion in otolaryngology & head and neck surgery 2014;22(1):2.

12. Rizan C, Elhassan HA. Post-sinus surgery insertion of steroid-eluting bioabsorbable intranasal devices: A systematic review. The Laryngoscope 2016;126(1):86-92.

13. Taulu R, Bizaki AJ, Numminen J, Rautiainen M. A prospective, randomized clinical study comparing drug eluting stent therapy and intranasal corticoid steroid therapy in the treatment of patients with chronic rhinosinusitis. Rhinology 2017;55(3):218-226.

14. Minim: Allocation by minimisation in clinical trials. https://www-users.york.ac.uk/~mb55/guide/minim.htm. Accessed August 14, 2019.

15. Hopkins C, Gillett S, Slack R, Lund VJ, Browne JP. Psychometric validity of the 22-item sinonasal outcome test. Clinical Otolaryngology 2009;34(5):447-454.

16. Catalano PJ, Thong M, Garg V. The MicroFlow spacer: A drug-eluting stent for the ethmoid sinus. Operative Techniques in Otolaryngology-Head and Neck Surgery 2009;20(2):108-113.

17. Derendorf H, Meltzer EO. Molecular and clinical pharmacology of intranasal corticosteroids: Clinical and therapeutic implications. Allergy 2008;63(10):1292-1300.

18. Philpott C, Erskine S, Smith R, et al. Current use of baseline medical treatment in chronic rhinosinusitis: Data from the National Chronic Rhinosinusitis Epidemiology Study (CRES). Clinical Otolaryngology 2018;43(2):509-524.

19. Businco LDR, Mattei A, Laurino S, et al. Steroid-eluting ethmoidal stent versus antero-posterior ethmoidectomy: Comparison Of efficacy and safety in allergic patients. Otolaryngol Pol 2016;70(2):6-12.

20. Christensen DN, Franks HC, McCrary HC, et al. A Systematic Review of the Association between Cigarette Smoke Exposure and Chronic Rhinosinusitis. Otolaryngology– Head and Neck Surgery 2018;158(5):801-816.