

HEIKKI TUOMINEN

# FDG-PET Imaging in Cardiac Sarcoidosis

Importance of the pathological findings  
in the right ventricle



HEIKKI TUOMINEN

FDG-PET Imaging in  
Cardiac Sarcoidosis

*Importance of the pathological findings  
in the right ventricle*

ACADEMIC DISSERTATION

To be presented, with the permission of  
the Faculty of Medicine and Health Technology  
of Tampere University,  
for public discussion in the A210-201  
of the Arvo building, Arvo Ylpön katu 34, Tampere,  
on 14 February, at 12 o'clock.

ACADEMIC DISSERTATION

Tampere University, Faculty of Medicine and Health Technology  
Finland

<i>Responsible supervisor and Custos</i>	Professor Mika Kähönen Tampere University Finland	
<i>Supervisor</i>	Professor Mika Kähönen Tampere University Finland	
<i>Pre-examiners</i>	Docent Tuula Janatuinen University of Turku Finland	Docent Jukka Lehtonen University of Helsinki Finland
<i>Opponent</i>	Docent Jukka Kemppainen University of Turku Finland	

The originality of this thesis has been checked using the Turnitin OriginalityCheck service.

Copyright ©2020 author

Cover design: Roihu Inc.

ISBN 978-952-03-1426-2 (print)  
ISBN 978-952-03-1427-9 (pdf)  
ISSN 2489-9860 (print)  
ISSN 2490-0028 (pdf)  
<http://urn.fi/URN:ISBN:978-952-03-1427-9>

PunaMusta Oy – Yliopistopaino  
Tampere 2020

# ABSTRACT

Sarcoidosis is a granulomatous inflammatory disease that can affect any organ system. It most often manifests in lungs and hilar lymph nodes. It is often asymptomatic and has a benign prognosis. With a quarter of the patients, sarcoid inflammation affects the heart and this cardiac involvement accounts for the majority of sarcoidosis-related morbidity and mortality.

FDG-PET is a nuclear medicine imaging study with an ability to visualize inflammatory foci. Lately, it has gained importance in the workup of cardiac sarcoidosis.

One hundred thirty-seven PET studies performed in Tampere University Hospital between August 2012 and September 2015 for patients suspected with cardiac sarcoidosis were retrospectively analysed. With an aim to study the role of FDG-PET in the workup of cardiac sarcoidosis, we examined the associations of PET-findings and patient characteristics, PET-findings and ECG-parameters and the association of PET-findings in the heart and metabolically active foci elsewhere in the body. In addition, we assessed the prognostic role of PET.

Pathological cardiac PET-findings were found to be more frequent in female patients and with those with a history of atrioventricular block. Right ventricular uptake was also associated with a history of ventricular tachycardia. Pathological cardiac PET findings also correlated to novel ECG parameters septal remodelling and inferolateral remodelling in addition to widespread QRS fragmentation and left anterior hemiblock. A biopsy sample indicating sarcoidosis was obtained more frequently from patients with metabolically active foci outside of the heart. Additionally, an association between right ventricular uptake and uptake in mediastinal and hilar lymph nodes was observed. In our population, right ventricular uptake and high total cardiac metabolic activity predicted adverse cardiac events during follow-up.

Our study identified a group of patients, defined according to sex, medical history and certain ECG parameters, who have a higher frequency of positive cardiac findings in FDG-PET. The imaging study can be a useful tool in the workup of

cardiac sarcoidosis as it can aid in the diagnosis by pointing targets for tissue biopsy. Furthermore, certain findings could be considered as indicators for high risk of cardiac events.

# TIIVISTELMÄ

Sarkoidoosi on tulehdussairaus joka voi esiintyä missä elimessä tahansa. Yleisimmin se ilmenee keuhkoissa ja välikarsinan imusolmukkeissa. Sarkoidoosi on usein oireeton sattumalöydös ja sen ennuste on suotuisa.

Sarkoidoosi voi kutienkin esiintyä sydänlihaksessa jopa neljänneksessä tapauksista. Sydämessä esiintyvään tautimuotoon liittyy merkittävää sairastavuutta ja kuolleisuutta.

FDG-PET on isotooppitutkimus, jolla voidaan kuvata elimistön metabolista aktiivisuutta ja osoittaa muun muassa tulehdusprosessiin liittyvää korostunutta sokeriaineenvaihduntaa.

Tätä väitöskirjatutkimusta varten uudelleenanalysoitiin 137 tehtyä FDG-PET tutkimusta, jotka oli tehty elokuun Tampereen yliopistosairaalassa elokuun 2012 ja syyskuun 2015 välillä sydänsarkoidoosiepäilyn vuoksi. Halusimme tutkia PET-kuvauksen merkitystä potilailla, joilla epäiltiin sydämen sarkoidoosia. Vertasimme PET-löydöksiä potilaiden perustietoihin, sairaushistoriaan ja EKG-löydöksiin. Lisäksi tutkimme sydämen ja sydämen ulkopuolisten poikkeavien aineenvaihduntafokusten suhdetta ja selvitimme PET-löydösten kykyä ennustaa sydäntapahtumia.

Havaitsimme, että poikkeavia sydänlöydöksiä oli enemmän naisilla ja niillä joilla oli sairaushistoriassa merkintä eteis-kammiokatkoksesta. Oikean kammion poikkeavia muutoksia oli useammin potilailla, joilla oli ollut kammiooperäisiä rytmihäiriöitä. Poikkeavat sydänlöydökset olivat yleisempiä potilailla, joiden EKG:ssa oli nähtävissä QRS-kompleksin fragmentaatiota useissa kytkennöissä, oikean etuhaarakkeen katkos. Poikkeavat sydämen PET-löydökset liittyivät myös väliseinän uudelleenmuovautumiseksi ja alaseinän uudelleenmuovautumiseksi nimettyihin, hiljattain määriteltyihin EKG-muuttujiin. Sarkoidoosiin sopiva kudoksenäyte saatiin useammin potilailta, joilla nähtiin aineenvaihduntafokuksia sydämen ulkopuolella. Sydämen ulkopuolisilla ja oikean kammion poikkeavilla PET-löydöksillä havaittiin olevan yhteys. Oikean kammion poikkeavat löydökset ja korkea sydämen kokonaisaineenvaihdunta-aktiivisuus ennustivat sydäntapahtumia.

Tulosten perusteella FDG-PET on käyttökelpoinen tutkimus sydänsarkoidoosiepäilyssä. Tunnistimme potilasryhmiä, joilla poikkeavan PET-löydöksen todennäköisyys on korkea. Havaitimme, että PET-tutkimus voi osoittaa kohteita kudosaäytteen ottoon ja auttaa siten diagnoosiin pääsyssä. Lisäksi havaitimme tiettyjen PET-löydösten liittyvän suureen sydäntapahtumien riskiin, mikä tulee ottaa huomioon potilaan hoidossa.



# CONTENTS

1	Introduction.....	15
2	literary review .....	16
2.1	Pathology of sarcoidosis .....	16
2.1.1	Pathophysiology and clinical presentation of cardiac sarcoidosis .....	17
2.2	Epidemiology of sarcoidosis and cardiac involvement.....	17
2.3	Diagnosis of cardiac sarcoidosis .....	18
2.4	Prognosis and management of sarcoidosis .....	24
2.4.1	Prognosis of sarcoidosis is largely dependent on cardiac involvement.....	24
2.4.2	Prognosis of CS .....	24
2.4.3	Treatment of cardiac sarcoidosis.....	25
2.4.3.1	Immunosuppression.....	25
2.4.3.2	Antiarrhythmic treatment and catheter ablation for VTs .....	25
2.4.3.3	Pacemaker and ICD-implantation.....	26
2.5	Use of electrocardiography and imaging modalities in the diagnostics of CS.....	27
2.5.1	Echocardiography.....	27
2.5.2	Magnetic resonance imaging.....	28
2.5.3	Positron emission tomography.....	29
2.5.3.1	Basic concept of FDG-PET .....	30
2.5.3.2	Strategies to reduce physiological FDG-uptake in the myocardium.....	30
2.5.3.3	Interpretation of FDG-PET images .....	33
2.5.3.4	Whole-body imaging.....	34
2.5.3.5	Diagnostic performance of FDG-PET in cardiac sarcoidosis .....	36
2.5.3.6	Prognostic performance of FDG-PET.....	38
2.5.4	Imaging of CS with somatostatin receptor binding PET-tracers .....	39
2.5.5	Focus on the right ventricle.....	40
3	Aims of the study.....	41
4	Materials and methods.....	42
4.1	Study population .....	42

4.2	PET-imaging.....	43
4.3	Analysis of the PET-images .....	44
4.4	Analysis of the ECG recordings .....	46
4.5	Collection of clinical data .....	48
4.6	Statistical methods.....	48
5	Results.....	50
5.1	The inter-observer agreement in interpreting the PET-images .....	50
5.2	Myocardial PET-findings.....	50
5.3	Pathological cardiac PET-findings in relation to patient characteristics .....	54
5.4	Pathological extracardiac FDG-uptake .....	57
5.5	Association of ECG- and PET-finding.....	60
5.6	Biopsy findings confirming sarcoidosis and their association with PET results .....	62
5.7	The ability of FDG-PET to predict adverse cardiac events.....	63
6	Discussion.....	67
6.1	Methodological considerations .....	67
6.2	The results in reflection to existing literature .....	68
6.2.1	Success in reducing physiological myocardial uptake.....	68
6.2.2	Inter-observer agreement.....	69
6.2.3	Frequency of positive PET findings.....	69
6.2.4	Patient demographics, history and PET findings .....	71
6.2.5	Association of ECG and PET findings.....	72
6.2.6	Extracardiac uptake foci are important in the diagnostic process.....	74
6.2.7	PET as a predictor of adverse cardiovascular events.....	75
7	Conclusion.....	77
	References .....	79

## *List of Figures*

Figure 1 Different stages of CS by combination of FDG-PET and perfusion imaging

Figure 2 Flow chart on the patient selection process

Figure 3 Different types of cardiac uptake

Figure 4 An example of ECG with both septal and inferolateral remodeling

Figure 5 Uptake pattern frequencies in left and right ventricle

Figure 6 Quantitative PET-parameters in patients with no pathological uptake, uptake in the left ventricle only and in patients with uptake in both ventricles

Figure 7 Patients with LV, RV and extracardiac uptake:

Figure 8 Patients divided into groups according to PET-findings and the number of tissue biopsies (EMB or other) positive for sarcoidosis

Figure 9 Survival free of cardiac events in patients with no right ventricular uptake and in those with pathological right ventricular uptake

Figure 10 Survival free of cardiac events in patients with tCMA below or above 900 MBq

### *List of Tables*

Table 1 JCS 2017 General Criteria for diagnosing cardiac sarcoidosis

Table 2 Criteria for cardiac involvement in sarcoidosis (JCS 2017)

Table 3 Characteristic imaging and laboratory findings of sarcoidosis. (Japan Society of Sarcoidosis and other Granulomatous Disorders. 2015)

Table 4 Diagnostic criteria for isolated cardiac sarcoidosis (JCS 2017)

Table 5 Heart Rhythm Society expert consensus recommendation on criteria for the diagnosis of cardiac sarcoidosis

Table 6 Qualitative (a) and quantitative (b) PET-findings for the whole population (n=137)

Table 7 Baseline variables in patients with pathological or normal left ventricle FDG-PET-finding

Table 7 Baseline variables in patients with or without pathological right ventricular  
FDG-PET-finding

Table 8 Frequency of extracardiac uptake at different sites

Table 9 Baseline variables and FDG-PET-findings in patient with and without  
pathological extracardiac FDG-uptake

Table 10 ECG parameters in patients with or without pathological cardiac FDG  
uptake

Table 11 Baseline characteristics, PET-findings and treatment during follow up in  
patients with and without events during follow up

Table 12 Proportions of positive myocardial PET-findings in other studies on  
FDG-PET in suspected CS

# ABBREVIATIONS

AV - Atrio-ventricular  
BAL Bronchoalveolar lavage  
BBB - Bundle branch block  
BMI - Body mass index  
CAD - Coronary artery disease  
CMR - Cardiac magnetic resonance (imaging)  
CS - Cardiac sarcoidosis  
CT - Computed tomography  
CV - Cardiovascular  
DNA - Deoxyribonucleic acid  
ECG - Electrocardiography  
EKG - Elektrokardiografia  
EMB - Endomyocardial Biopsy  
FDG - Fluorodeoxyglucose  
FOV - Field of view  
fQRS - Fractioned QRS complex  
FWMH - Full width at half maximum  
Ga - Gallium  
HLA - Human leukocyte antigen  
HR - Hazard ratio  
HRS - Heart Rhythm Society  
HU - Hounsfield unit  
ICD - Implantable cardioverter defibrillator  
IL - Interleukine  
IU - International unit  
JCS - Japanese Circulation Society  
JMHW - Japanese Ministry of Health and Welfare  
LAFB - Left anterior fascicular block  
LBBB - Left bundle branch bloc  
LGE - Late gadolinium Enhancement

LMA - Lesion metabolic activity  
LPFB - Left posterior fascicular block  
LV - Left ventricle  
LVEDD - Left ventricular end-diastolic diameter  
LVEF - Left ventricular ejection fraction  
LVH - Left ventricular hypertrophy  
MBq - Megabecquerel  
MCH - Major Histocompatibility complex  
MPI - Myocardial perfusion imaging  
MRI - Magnetic resonance imaging  
NSIVCD - Non-specific intraventricular conduction defect  
O - Oxygen  
PET - Positron emission tomography  
Rb - Rubidium  
RBBB - Right bundle branch bloc  
RV - Right ventricle  
SD - Standard deviation  
SPECT - Single photon emission tomography  
SSTR - Somatostatin receptor  
SUV - Standardized uptake value  
tCMA - Total cardiac metabolic activity  
TNF - Tumor necrosis factor  
VT - Ventricular tachycardia

# ORIGINAL PUBLICATIONS

- I Tuominen H, Haarala A, Tikkakoski A, Korkola P, Kähönen M, Nikus K, Sipilä K. 18F-FDG-PET in Finnish patients with clinical suspicion of cardiac sarcoidosis: Female sex and history of atrioventricular block increase the prevalence of positive PET findings. *Nucl Cardiol.* 2019 Apr;26(2):394-400. doi: 10.1007/s12350-017-0940-x. Epub 2017 Jun 5
- II Sipilä K, Tuominen H, Haarala A, Tikkakoski A, Kähönen M, Nikus K. Novel ECG parameters are strongly associated with inflammatory 18F-FDG PET findings in patients with suspected cardiac sarcoidosis. *Int J Cardiol.* 2017 Dec 15;249:454-460. doi: 10.1016/j.ijcard.2017.07.027.
- III Tuominen H, Haarala A, Tikkakoski A, Kähönen M, Nikus K, Sipilä K. 18-FDG-PET in a patient cohort suspected for cardiac sarcoidosis: Right ventricular uptake is associated with pathological uptake in mediastinal lymph nodes. *J Nucl Cardiol.* 2018 May 2. doi: 10.1007/s12350-018-1291-y. [Epub ahead of print]
- IV Tuominen H, Haarala A, Tikkakoski A, Kähönen M, Nikus K, Sipilä K. FDG-PET in possible cardiac sarcoidosis: Right ventricular uptake and high total cardiac metabolic activity predict cardiovascular events. *J Nucl Cardiol.* 2019 Feb 27. doi: 10.1007/s12350-019-01659-2. [Epub ahead of print]





# 1 INTRODUCTION

Cardiac involvement accounts for the majority of mortality and morbidity associated with sarcoidosis.<sup>1</sup> Besides cardiac involvement in systemic sarcoidosis, sarcoid inflammation confined to heart has been recently recognized.<sup>2-6</sup> Timely diagnosis of cardiac sarcoidosis is important for appropriate medical treatment, but diagnosing cardiac sarcoidosis remains difficult. The gold standard of diagnosis is verification of granulomatous inflammation by endomyocardial biopsy, which has low sensitivity.<sup>7-9</sup>

FDG-PET is a nuclear imaging modality that is able to demonstrate inflammation by tracer accumulation in cells with high glucose metabolism. Activated inflammatory cells in sarcoid granulomas have elevated glucose metabolism, demonstrated by FDG accumulation in PET-imaging.<sup>10-12</sup>

Multiple studies on the diagnostic performance of FDG-PET have been published during the last decades and the latest meta-analysis was published in 2019. The imaging and patient preparation protocols have been variable. Sarcoidosis is known to have different disease course in different ethnic populations, making it uncertain whether results on certain population are generalizable to other populations.<sup>13-15</sup> A major difficulty in all studies is the lack of reliable diagnostic gold standard.

Previous study on the epidemiology of cardiac sarcoidosis in Finland has demonstrated the important role of FDG-PET in the diagnostic process. However, the diagnostic and prognostic significance of different PET findings have not been studied among Finnish population. The aim of my study was to investigate the associations and clinical significance of different PET findings.

## 2 LITERARY REVIEW

### 2.1 Pathology of sarcoidosis

Sarcoidosis is a multisystem inflammatory disease characterized by formation of immunological granulomas in various organ systems.<sup>16</sup>

The cause of the disease is unknown. Immunologically, sarcoidosis is an exaggerated response to an external antigen. Genetic predisposition is thought to account for a major part of disease susceptibility.<sup>17</sup> Numerous gene loci have been linked to sarcoidosis predisposition, each conferring a 1.1 to 1.8 times increased risk compared to non-carriers.<sup>18-21</sup>

Several environmental pathogens and other antigens have been linked to sarcoidosis. In addition, exposure to metal industry and insecticides have been linked to elevated risk of sarcoidosis.<sup>22,23</sup> Besides inorganic antigens, bacteria may trigger sarcoid inflammation. There is evidence that mycobacteria and propionibacteria may cause granuloma formation.<sup>24</sup> These bacteria have features that allow them to reside inside macrophages without being completely degraded. Signs of mycobacteria have been identified in half of tissue biopsies obtained from sarcoid granulomas.<sup>25</sup> Similarly, propionibacter DNA has been found.<sup>26</sup>

Immunologically, macrophages start the cascade that leads to the formation of a granuloma. In patients with sarcoidosis, alveolar macrophages have the ability to function as antigen presenting cells and triggering T-cell proliferation. Interestingly, macrophages from healthy individuals down-regulate T-cell proliferation.<sup>27</sup> Antigen presenting ability of macrophages is linked to MCH-expression which in turn is linked to genetic HLA-DR-subtypes that are known to affect the clinical course of sarcoidosis.<sup>19</sup> Activated macrophages secrete cytokines, notably TNF- $\alpha$ , triggering the influx of TH1-cells. These in turn produce TNF- $\alpha$ , IL-1 and interferon that further activate macrophages. Immune response is exaggerated because regulatory T-cells are low in number and act ineffectively in patients with sarcoidosis.<sup>28</sup> Epithelioid granuloma formation is a mean to insulate the undegradable parts of antigen that triggered the inflammation. In some patients, the inflammation is later

downregulated by the formation of immunosuppressive cytokines.<sup>29</sup> In others, the persisting antigen leads to a chronic inflammation.

### 2.1.1 Pathophysiology and clinical presentation of cardiac sarcoidosis

When the heart is affected by sarcoidosis, noncaseating granulomas form in the heart. Granulomas may form in any part of the heart but left ventricle is most often affected. Histologically, cardiac sarcoidosis has three successive stages. The process begins with edema followed by active granulomatous inflammation. These then lead to fibrosis and cause scarring.<sup>30</sup> Clinically, cardiac sarcoidosis most often causes conduction abnormalities, tachyarrhythmias and cardiomyopathy. Less frequently encountered manifestations include pericarditis, valvular pathologies due to direct granuloma infiltration and ischemic presentation due to coronary arterial granulomas.<sup>31</sup> High-degree atrio-ventricular (AV) conduction block is the most common clinical manifestation. In a population of young patients with advanced AV block 25-34 % of the patients were later diagnosed with cardiac sarcoidosis.<sup>32,33</sup> Ventricular tachycardias (VTs) may be the first manifestation of cardiac sarcoidosis.<sup>34,35</sup> In certain populations of patients with unexplained VT, 29 % of patients have had cardiac sarcoidosis.<sup>4</sup> Cardiomyopathy with degraded left ventricular function and clinical decompensation has been shown to indicate poor prognosis.<sup>14</sup>

## 2.2 Epidemiology of sarcoidosis and cardiac involvement

Sarcoidosis generally has a widely varying prevalence of 4.7-64 in 100,000 and incidence of 1.0 to 35.5 in 100,000 per annum in different populations. According to an American study, women seem to be more affected, as the study suggests that females were twice as likely as males to have sarcoidosis.<sup>13</sup> Prevalence and incidence figures are highest among populations in Northern Europe and lowest in Japan.<sup>15,36</sup> Sarcoidosis presents most commonly in patients between 20-39 years of age and the incidence peaks at a different age in different populations. In African American population, the disease often occurs later than in other populations and the disease course is more often chronic.<sup>36</sup> With Scandinavian and Japanese women the

incidence curve has two peaks, the first one at 20 to 29 years and the second one at 65 to 69 years.<sup>37</sup>

Epidemiology of cardiac sarcoidosis is more uncertain. In autopsy studies, the prevalence of cardiac involvement in patients with systemic sarcoidosis has been 25 %.<sup>38</sup> Studying the epidemiology of cardiac sarcoidosis is complicated by difficulties in diagnosing the disease. In post-mortem studies of patients with cardiac sarcoidosis, less than half of the patients had signs of cardiac involvement during their lifetime.<sup>39</sup> In a nationwide Finnish study, the prevalence of biopsy-confirmed cardiac sarcoidosis was 2.2 in 100,000.<sup>3</sup> The prevalence has mostly been studied with patients with systemic sarcoidosis. Prevalence figures of 1% to 26% have been described, depending on diagnostic method and population.<sup>40,41</sup> In a large American cohort study, cardiac manifestation accounted for 31 % of hospitalizations due to sarcoidosis.<sup>42</sup>

Lately, an isolated form of cardiac sarcoidosis has been recognized.<sup>2-6</sup> The frequency of isolated cardiac sarcoidosis is inadequately established due to insensitivity of diagnostic criteria (discussed in the following chapter) to recognize this form of the disease. The proportion of isolated form among sarcoidosis patients has been reported to vary from 27 to 54 %.<sup>43</sup> Kandolin et al found that isolated cardiac sarcoidosis more often presented with decreased left ventricular ejection fraction (LVEF) and was associated with poorer prognosis than cardiac involvement in systemic sarcoidosis.<sup>3</sup>

## 2.3 Diagnosis of cardiac sarcoidosis

Currently, the diagnosis of cardiac sarcoidosis is based on two sets of criteria. The most established criteria have been published by Japanese Ministry of Health and Welfare first in 1993 and revised in 2006 and 2017 by Japanese circulatory society (JCS).<sup>44-46</sup> (tables 1-4). The other set of diagnostic criteria commonly used was published by Heart Rhythm Society (HRS) in 2014 (table 5).<sup>47</sup> According to both criteria, there are two ways to diagnose cardiac sarcoidosis. The most robust diagnosis is established by detecting non-caseating granulomas in endomyocardial biopsy (EMB). Due to the patchy distribution of granulomatous inflammation in the heart, the sensitivity of EMB has been reported to be as low as 19-30 %<sup>7-9</sup>. The diagnosis of “probable cardiac sarcoidosis” can be established in patients with biopsy-proven systemic sarcoidosis when a certain set of clinical and imaging criteria

are met. These criteria differ slightly between JMHW/JCS and HRS. The latest JCS guidelines also include diagnostic criteria for isolated cardiac sarcoidosis (table 4).

**Table 1.** JCS 2017 General Criteria for diagnosing cardiac sarcoidosis <sup>46</sup>

<p>1) Histological diagnosis group (those with positive myocardial biopsy findings) Cardiac sarcoidosis is diagnosed histologically when endomyocardial biopsy or surgical specimens demonstrate non-caseating epithelioid granuloma</p>
<p>2) Clinical diagnosis group (those with negative myocardial biopsy findings or those not undergoing myocardial biopsy)</p> <p>The patient is clinically diagnosed as having sarcoidosis when epithelioid granulomas are found in organs other than the heart, and clinical findings strongly suggestive of the above-mentioned cardiac involvement (Table 2) are present;</p> <p>or when the patient shows clinical findings strongly suggestive of pulmonary or ophthalmic sarcoidosis; at least two of the five characteristic laboratory findings of sarcoidosis (Table 3); and clinical findings strongly suggest the above-mentioned cardiac involvement (Table 2)</p>

**Table 2.** Criteria for cardiac involvement in sarcoidosis (JCS 2017)<sup>46</sup>

<p>Major criteria:</p> <ul style="list-style-type: none"><li>a) High-grade atrioventricular block (including complete atrioventricular block) or fatal ventricular arrhythmia (e. g., sustained ventricular tachycardia and ventricular fibrillation)</li><li>b) Basal thinning of the ventricular septum or abnormal ventricular wall anatomy (ventricular aneurysm, thinning of the middle or upper ventricular septum, regional ventricular wall thickening)</li><li>c) Left ventricular contractile dysfunction (left ventricular ejection fraction less than 50%)</li><li>d) <sup>67</sup>Ga citrate scintigraphy or <sup>18</sup>F-FDG PET reveals abnormally high tracer accumulation</li><li>e) Gadolinium-enhanced MRI reveals delayed contrast enhancement of the myocardium</li></ul>
<p>Minor criteria:</p> <ul style="list-style-type: none"><li>f) Abnormal ECG findings: Ventricular arrhythmias (non-sustained ventricular tachycardia, multifocal or frequent premature ventricular contractions), bundle branch block, axis deviation, or abnormal Q waves</li><li>g) Perfusion defects on myocardial perfusion scintigraphy (SPECT)</li><li>h) Endomyocardial biopsy: Monocyte infiltration and moderate or severe myocardial interstitial fibrosis</li></ul>
<p>Clinical findings that satisfy the following 1) or 2) strongly suggest the presence of cardiac involvement.</p> <ul style="list-style-type: none"><li>1) Two or more of the five major criteria (a) to (e) are satisfied</li><li>2) One of the five major criteria (a) to (e) and two or more of the three minor criteria (f) to (h) are satisfied.</li></ul>

**Table 3.** Characteristic imaging and laboratory findings of sarcoidosis. (Japan Society of Sarcoidosis and other Granulomatous Disorders. 2015)<sup>46</sup>

1) Bilateral hilar lymphadenopathy

2) High serum angiotensin-converting enzyme (ACE) activity or elevated serum lysozyme levels

3) High serum soluble interleukin-2 receptor (sIL-2R) levels

4) Significant tracer accumulation in <sup>67</sup>Ga citrate scintigraphy or <sup>18</sup>F-FDG PET

5) A high percentage of lymphocytes with a CD4/CD8 ratio of >3.5 in BAL fluid

Clinical diagnosis of sarcoidosis is supported when at least two of the above five characteristic findings are observed

**Table 4.** Diagnostic criteria for isolated cardiac sarcoidosis (JCS 2017)<sup>46</sup>

<p>1. No clinical findings characteristic of sarcoidosis are observed in any organs other than the heart. (The patient should be examined in detail for respiratory, ophthalmic, and skin involvements of sarcoidosis. When the patient is symptomatic, other etiologies that can affect the corresponding organs must be ruled out.)</p> <p>2. <sup>67</sup>Ga scintigraphy or <sup>18</sup>F-FDG PET reveals no abnormal tracer accumulation in any organs other than the heart.</p> <p>3. A chest CT scan reveals no shadow along the lymphatic tracts in the lungs or no hilar and mediastinal lymphadenopathy (minor axis &gt; 10 mm).</p> <p>1) Histological diagnosis group Isolated cardiac sarcoidosis is diagnosed histologically when endomyocardial biopsy or surgical specimens demonstrate non-caseating epithelioid granulomas.</p> <p>2) Clinical diagnosis group Isolated cardiac sarcoidosis is diagnosed clinically when the criterion (d) and at least three other criteria of the major criteria (a)-(e) are satisfied (Table 2)</p>
---



**Table 5.** Heart Rhythm Society expert consensus recommendation on criteria for the diagnosis of cardiac sarcoidosis<sup>47</sup>

There are 2 pathways to a diagnosis of Cardiac Sarcoidosis:

1. Histological Diagnosis from Myocardial Tissue CS is diagnosed in the presence of non-caseating granuloma on histological examination of myocardial tissue with no alternative cause identified (including negative organismal stains if applicable).

2. Clinical Diagnosis from Invasive and Non-Invasive Studies: It is probable\* that there is CS if:

a) There is a histological diagnosis of extra-cardiac sarcoidosis and

b) One or more of following is present

Steroid +/- immunosuppressant responsive cardiomyopathy or heart block

Unexplained reduced LVEF (40%)

Unexplained sustained (spontaneous or induced) VT

Mobitz type II 2nd degree heart block or 3rd degree heart block

Patchy uptake on dedicated cardiac PET (in a pattern consistent with CS)

Late Gadolinium Enhancement on CMR (in a pattern consistent with CS) Positive gallium uptake (in a pattern consistent with CS)

c) Other causes for the cardiac manifestation(s) have been reasonably excluded

\*In general, 'probable involvement' is considered adequate to establish a clinical diagnosis of CS.<sup>33</sup>

## 2.4 Prognosis and management of sarcoidosis

### 2.4.1 Prognosis of sarcoidosis is largely dependent on cardiac involvement

Sarcoidosis without cardiac involvement has a benign prognosis and often the inflammatory process resolves without treatment. In case of cardiac involvement, however, the prognosis is less favorable. Cardiac involvement accounts for the largest proportion of sarcoidosis-related deaths.<sup>1</sup>

### 2.4.2 Prognosis of CS

In the early prognostic studies from the 1970's, CS resulted in death in two years.<sup>48</sup> In the era of modern diagnostic tools, such as effective anti-inflammatory treatment, implantable cardioverter-defibrillators and cardiac transplantation surgery, the prognosis is far better. In a nationwide Finnish study of 110 patients, the mortality rate was 9 % during follow up of 79 months (1.4 annually).<sup>3</sup> Another Finnish study compared the clinical outcome in patients with EMB-verified cardiac sarcoidosis to that of patients with extracardiac sarcoidosis and imaging findings suggesting cardiac involvement. Of the 149 patients, 34 suffered sudden cardiac death, aborted cardiac death or underwent heart transplantation. There was no significant prognostic difference between EMB-verified and other patients.<sup>49</sup>

Decreased left ventricular ejection fraction has been shown to indicate poor prognosis.<sup>14</sup> Chiu et al found that all patients with normal LVEF were alive at 10 years compared to only 19 % of those with LVEF < 35 %.<sup>50</sup> In the study of Yazaki et al, history of ventricular tachycardia, in addition to LVEF, New York Heart Association class, left ventricular end diastolic diameter indicated high risk of cardiac events. In addition, Low LVEF predicted appropriate implantable cardioverter-defibrillator (ICD) therapies in three studies.<sup>51-53</sup>

## 2.4.3 Treatment of cardiac sarcoidosis

Treatment of CS is based on immunosuppressive medication intended to prevent further damage to myocardium caused by persisting active inflammation. Other components of the treatment are aimed to specific manifestations: antiarrhythmic medications, VT-ablation and ICD implantation for ventricular arrhythmias and pacemaker therapy for conduction abnormalities. Guidelines on the treatment of CS have been published by the heart rhythm society in 2014.<sup>47</sup>

### 2.4.3.1 Immunosuppression

Immunosuppression is widely used to treat CS but the scientific literature on its efficacy is scarce and somewhat mixed. In a Canadian literary review, corticosteroid treatment improved LVEF in patients who had moderately decreased left ventricular end-diastolic diameter (LVEDD) but not in those with severely decreased left ventricular function.<sup>54</sup> However, Kandolin et al found that LVEF improved with corticosteroid treatment in those with LVEF < 35 % but not in those with less severely depressed left ventricular function.<sup>3</sup> Padala et al showed in their study that early initiation of corticosteroid therapy results in recovery of LVEF, AV conduction and resolution of VTs more often than delayed corticosteroid treatment.<sup>55</sup> In a Canadian review, Sadek et al summarize six studies on the effect of corticosteroid treatment on AV- conduction. High-degree AV-block resolved in 47 % of the 57 patients treated with corticosteroids compared to none of the 16 untreated patients.

<sup>54</sup>

### 2.4.3.2 Antiarrhythmic treatment and catheter ablation for VTs

Amiodarone and sotalol are the antiarrhythmic drugs most often used to treat VTs in CS. However, there is no evidence for benefit on long-term outcome.<sup>56</sup> There are few studies on the benefit of catheter ablation on VTs in patients with CS. The populations in the studies have been small and results mixed as other study found a favorable effect on VT burden whereas in the other study VTs recurred in majority of patients.<sup>57,58</sup>

### 2.4.3.3 Pacemaker and ICD-implantation

Heart rhythm society recommends implantation of pacemaker in CS patients with 2<sup>nd</sup> or 3<sup>rd</sup> degree AV block. Even if AV-conduction may recover with corticosteroid treatment as described earlier, the recovery is unpredictable and AV-conduction may degrade again after the initial recovery. Furthermore, it is recommended that ICD should be implanted to patients with indication for permanent pacing as patients with CS have an elevated risk of life-threatening ventricular arrhythmias. ICD-implantation is also recommended in patients with spontaneous sustained ventricular tachycardias and in those with LVEF<35 %. It is also considered useful with patients who have experienced a syncope of > 30 seconds which is believed to be of arrhythmic origin or who have inducible ventricular tachycardias of > 30 seconds in electrophysiological study.<sup>47</sup>

## 2.5 Use of electrocardiography and imaging modalities in the diagnostics of CS

### 2.5.1 Electrocardiography

Electrocardiographic abnormalities are detected in up to 50 % of patients with systemic sarcoidosis.<sup>14</sup> These abnormalities include disturbances in rhythm, conduction and repolarization.<sup>59</sup> These findings are often asymptomatic.<sup>60</sup> Even though standard ECG is recommended in the routine evaluation of patients with sarcoidosis, the abnormalities mentioned previously are nonspecific. It has been shown that standard ECG has low accuracy in detecting CS.<sup>61</sup> Ambulatory Holter-recording improves accuracy as it was found to have sensitivity and specificity of 67% and 62%, respectively, when more than 100 ventricular beats in 24 hour recording was considered pathological.<sup>62</sup> Lately, new parameters based on QRS fragmentation have been developed for ECG analysis and these have been shown to associate with different structural heart diseases, including cardiac sarcoidosis.<sup>63-66</sup> These results are considered preliminary and remain to be confirmed in future studies.

### 2.5.2 Echocardiography

Echocardiography is usually the first imaging study for patients suspected of having cardiac sarcoidosis. Echocardiography is easily available and involves no ionizing radiation. Common clinical presentations of cardiac sarcoidosis (conduction abnormalities, tachyarrhythmias and cardiomyopathy) can be caused by multitude of cardiovascular pathologies, many of which are detected in echocardiography.

Echocardiographic findings in CS are variable and often unspecific. The echocardiographic abnormalities in CS include regional wall motion abnormalities, dilated left ventricle, ventricular aneurysms, systolic or diastolic dysfunction, septal thinning or thickening, valvular dysfunction and pericardial effusion. Studies on the prevalence of these findings have been conducted on relatively small patient populations. The most frequent abnormal findings have been left ventricular (LV)

dysfunction, wall motion abnormalities and septal thinning. Of these, septal thinning has been recognized as the most specific for CS.<sup>67-70</sup> If there is clinical suspicion of CS based on findings described above, further studies with other imaging modalities (discussed below) are warranted.

If the diagnosis of CS has been established, LVEF determined by echocardiography is a strong prognostic factor alongside left ventricle end-diastolic diameter.<sup>14,50</sup> As CS is a possibly progressive condition, the patients should be followed up to detect possible deterioration of LV function that warrants for escalation of immunosuppressive treatment. Resolution of echocardiographic abnormalities by treatment with corticosteroids has been described.<sup>71</sup>

### 2.5.3 Magnetic resonance imaging

There is strong evidence for the utility of cardiac magnetic resonance (CMR) imaging in diagnosing CS. MRI imaging is based on magnetic resonance in tissue. CMR can be used to assess possible edema and myocardial fibrosis and to determine ventricular function. Edema is a hallmark of acute inflammation, whereas fibrosis due to scarring is a later manifestation in cardiac sarcoid disease. Ventricular function is a strong prognostic factor as already discussed in the previous chapter.

Acute inflammation in myocardial tissue causes edema e.g. increases the amount of extracellular fluid. In CMR, T1 and T2 will increase in proportion to the amount of extracellular water.<sup>72</sup> Edema can also cause focal myocardial thickening and early gadolinium enhancement.<sup>73,74</sup> In the case of extensive infiltration by sarcoid, confluent granulomas can be visualized in T2-images as signal-intense ring-shaped areas in myocardium. The central portion with low signal intensity represents scar that is surrounded by edematous inflammatory tissue.

Late gadolinium enhancement (to be discussed later) is considered the most specific diagnostic sign in suspected CS. However, Crouser et al found that assessing T2-weighted images improved the detection rate of cardiac involvement in patients with proven sarcoidosis.<sup>75</sup> In a follow up study, they found a reduction in T2 signal in patients successfully treated with anti-inflammatory medication.<sup>76</sup> The population in the studies was small and the results have to be confirmed in larger populations. However, a non-ionizing imaging modality that could be used in assessing the efficacy of anti-inflammatory medication would be desirable.

The role of late gadolinium enhancement (LGE) as diagnostic marker has been studied extensively. The most typical site for LGE in cardiac sarcoidosis is mid-myocardial and subepicardial spaces in basal septum and inferolateral wall.<sup>77</sup> LGE is considered to represent fibrotic scar tissue but it can also result from the increase of extracellular space in edema. Thus in some cases, LGE can subside with anti-inflammatory treatment.<sup>78</sup> Smedma et al studied the accuracy of LGE compared to JMHW criteria in 58 patients with systemic sarcoidosis. In this population, sensitivity was 100 % and specificity 78 %.<sup>79</sup> In later studies, it has been shown that LGE predicts adverse cardiac events twice better than fulfillment of JMHW criteria. In sarcoidosis patients with suspected cardiac involvement, LGE signified nine-fold risk of adverse cardiac events and 11.5 fold risk of cardiac death.<sup>113</sup> Greulich et al later found even higher figures of hazard ratio (HR) for cardiac events and death (31.6 and 33.9, respectively) in a population of 155 consecutive sarcoidosis patients with suspected cardiac involvement.<sup>80</sup> In 2016, a meta-analysis on prognostic value of LGE was published by Coleman et al. in which 10 studies involving 760 patients were included. The investigators used composite arrhythmic outcome (ventricular arrhythmia, implantable cardioverter-defibrillator shock and cardiac death) and all-cause mortality as endpoints. Odds ratio for all-cause mortality was 3.06 ( $p=0.03$ ) and 10.74 ( $p<0.001$ ) for composite outcome. In a recently published study, Smedema et al showed that LGE in right ventricle or in both ventricles signifies especially high risk of cardiac events.<sup>81</sup> However, several studies have shown that LGE can be found in sarcoidosis patients without any signs or symptoms of cardiac involvement. In these patients, there is no elevated risk of adverse cardiac events.<sup>82,83</sup> This highlights the importance of interpreting different imaging findings as a part of the clinical context.

## 2.5.4 Myocardial perfusion imaging

Granulomatous inflammation in CS may in some patients lead to myocardial fibrosis. This in turn causes perfusion defects that can be detected in myocardial perfusion imaging. There are few studies on the utility of myocardial perfusion imaging (without combined FDG-PET) in CS. Le Guludec et al studied the utility of Thallium and Tc 99m sestamibi SPECT in 37 patients with known CS.<sup>84</sup> Sestamibi was found to be more sensitive as 24 of the 37 patients showed perfusion defects compared to only 17 in thallium imaging. Reduction in the size of the defects in

dipyridamole images was correlated with improvement in follow up imaging after corticosteroid therapy. A Japanese group studied sestamibi/tetrofosmin SPECT in cardiac (n=6) and non-cardiac (n=10) patients.<sup>85</sup> LV and RV defects were found in 5/16 and 14/16 patients, respectively. Patients with CS had more defects than those with non-cardiac sarcoidosis. LV defects were linked to AV block and heart failure and RV defects with arrhythmias of RV origin. There is also an interesting study on the ability of the washout of <sup>99m</sup>Tc-tetrofosmin to predict treatment response to corticosteroids.<sup>86</sup> Early (30 min) and delayed (3 h) tetrofosmin perfusion imaging was performed in ten patients with CS before and after steroid therapy. Washout was defined as difference between defect scores in early and delayed images, and it was considered a marker of tracer redistribution. Washout was detected in six out of ten patients. Washout was found to be correlated to LVEF recovery with corticosteroid therapy.

## 2.5.5 Positron emission tomography

### 2.5.5.1 Basic concept of FDG-PET

Positron emission tomography (PET) is an imaging modality utilizing tracers labelled with positron-emitting isotopes. The most commonly used tracer is <sup>18</sup>F-fluorodeoxyglucose (<sup>18</sup>F-FDG), a glucose analogue. FDG uptake is regulated by glucose transporters.<sup>10</sup> FDG imaging is widely utilized in oncology to demonstrate metabolically active malignant tissue with increased number of glucose transporters. Similarly, activated inflammatory cells have increased number of active glucose transporters.<sup>11,12</sup> FDG-PET has been successfully utilized in variety of infectious and inflammatory conditions, e.g. vasculitis, infections of joint or vascular prostheses, fever of unknown origin, suspected postoperative infections and sarcoidosis.

### 2.5.5.2 Suggested indications for FDG-PET in suspected cardiac sarcoidosis

In 2017 a joint consensus statement on the role of FDG-PET in the detection and monitoring of CS was published by Society of nuclear medicine and American



society of nuclear cardiology.<sup>87</sup> This document provides suggested indications for FDG-PET in four different clinical situations.

- 1) In patients with known systemic sarcoidosis, FDG-PET is indicated if there are findings suggestive of CS in ECG (LBBB, RBBB, Q-waves in >1 leads), ambulatory Holter monitoring (VT or NSVT), echocardiography (wall motion abnormality, aneurysm, basal septum thinning or LVEF <50%) or cardiac MRI. FDG-PET is also indicated in patients with palpitations or syncope.
- 2) Young (<60 y) patients with unexplained II or III degree AV-conduction block.
- 3) Patients with idiopathic sustained VT that does not fulfill the criteria for typical outflow tract or fascicular VT and that is not secondary to other known heart disease.
- 4) as a follow treatment response or identify reactivation in patients with known CS

### 2.5.5.3 Strategies to reduce physiological FDG-uptake in the myocardium

In the case of cardiac sarcoidosis, PET-imaging is complicated by variable and unpredictable physiological FDG-uptake in the myocardium. In the fasting state, free fatty acids are the primary energy source in the myocardium.<sup>88</sup> As a meal triggers the secretion of insulin, myocardial tissue switches to utilizing glucose as an energy source.<sup>89</sup> However, even after fasting for 4 to 6 hours myocardium may demonstrate physiological uptake due to activity of certain glucose transporter subtypes.<sup>90</sup>

This physiological uptake can vary in location and over time even in the same patient.<sup>91</sup> It has been shown that this physiological uptake is not dependent on fasting blood level glucose, fasting time or the age of the patient.<sup>92,93</sup>

Several strategies have been developed to minimize the physiological myocardial FDG uptake. These strategies are based on prolonged fasting, carbohydrate-restricted diet prior to imaging and inducing hepatic lipases with non-fractionated heparin.

Prolonged fasting >18 h has been shown to result in reduced myocardial uptake compared to standard fast of up to 6 hours.<sup>94</sup> However, even after prolonged fast

up to 38 % of patients show myocardial FDG uptake.<sup>95</sup> Besides, patient adherence to long fasting could be questionable.

Several studies have proven the effectiveness of carbohydrate-restricted, high-fat diet. Williams et al found that patient who consumed high fat low carbohydrate diets prior to imaging had lower myocardial maximum standardized uptake values (SUVmax) compared to those who fasted according to standard protocols.<sup>96</sup> The results have been verified by later studies.<sup>97,98</sup> Despite optimal dietary preparation up to 20 % of patients show physiological myocardial FDG-uptake.<sup>94</sup>

Administration of unfractionated heparin in low doses triggers lipolysis and increases the level of free fatty acids in circulation.<sup>99</sup> This will theoretically aid in switching myocardial cells to utilize fatty acids instead of glucose, thus reducing FDG uptake. Indeed, Masuda et al show in a relatively large population the additional effect of administering 50 IU/kg unfractionated heparin 15 minutes prior to FDG compared with prolonged fasting alone.<sup>95</sup>

Combining different strategies has been shown to be effective by Manabe et al: low-carbohydrate meal prior to 18 h fast and injection of unfractionated heparin prior to FDG resulted in complete reduction of myocardial FDG-uptake in 100 % of 24 patients.<sup>100</sup>

An effective strategy to reduce physiological myocardial uptake is essential when imaging patients with suspected CS. In some cases, physiological uptake may cause a false positive finding. Even when the physician interpreting the images is aware of physiological uptake phenomenon, it may mask pathological uptake and cause false negative findings. Furthermore, calculating quantitative parameters is unreliable if there is extensive physiological uptake. An expert consensus by Society of nuclear medicine and molecular imaging and American society of nuclear cardiology recommends high-fat-low-carbohydrate diet for the day preceding FDG-PET combined to a 4-12 h fast prior to FDG-injection. Intravenous heparin (50 IU/kg 15 minutes before FDG-injection) may be used although its role in suppressing physiological myocardial uptake is considered uncertain.<sup>87</sup>

#### 2.5.5.4 Interpretation of FDG-PET images













To achieve accurate diagnosis FDG-PET imaging is usually performed in combination with myocardial perfusion imaging. This strategy allows detecting both active inflammation (FDG-PET) and myocardial scars (perfusion defects).<sup>101</sup> FDG-uptake pattern has been described in different ways but the most commonly used classification of uptake pattern was introduced by Ishimaru et al.<sup>102</sup> His group describe four different FDG-uptake patterns in the myocardium: no uptake, diffuse uptake, focal uptake and focal on diffuse pattern. The first two patterns are considered physiological and the two latter patterns are considered to represent sarcoid inflammation.

FDG accumulates only in active inflammatory process whereas fibrous scar caused by spontaneously subdued sarcoid inflammation is metabolically inactive. As mentioned previously, FDG-PET is often performed in combination with perfusion imaging.<sup>101</sup> Perfusion imaging can be performed using sestamibi-scintigraphy or PET-based imaging with <sup>13</sup>N-NH<sub>3</sub>, <sup>82</sup>Rb or O<sub>2</sub> water. The prevalence of perfusion defects in sarcoidosis patients suspected for cardiac involvement has ranged from 44 % to 76 %.<sup>103-105</sup> Populations in the studies have been relatively small and different perfusion imaging modalities have been used. The highest frequency for perfusion defects was found in a population of patients fulfilling the JMHW criteria and imaged with <sup>13</sup>N-NH<sub>3</sub>-PET.

Combining the results of FDG-PET and perfusion imaging allows recognizing different stages of CS. In a normal case, there is no FDG-accumulation in myocardium and the resting perfusion is normal. As a physiological variation, diffuse low-grade FDG-uptake may be seen and in combination with normal resting perfusion, this is considered a normal finding.<sup>102</sup> In the early stage, there is active focal uptake of FDG representing active inflammation in granulomas. At this stage, resting perfusion may be normal or there may be defects due to compression of vascular structures by the inflammatory granulomas. The latter case is called a mismatch pattern. Coronary artery disease (CAD) has been ruled out in most patients referred to PET-imaging for suspected cardiac sarcoidosis but it has to be kept in mind that hibernating myocardium in CAD could present a similar finding.<sup>106</sup> A scar without active inflammation can be seen in a later stage. Okamura et al proposed a pathological classification in to five categories based on FDG and perfusion findings. “Normal” has normal perfusion and no pathological FDG

uptake, “Early Stage” has no perfusion defect but has pathological FDG uptake, “Progressive Inflammatory Stage” has mild perfusion defect(s) and pathological FDG uptake, “Peak Active Stage with moderate perfusion defect and increased FDG uptake, “Progressive Myocardial Impairment Stage” that has severe perfusion defects combined to pathological FDG uptake, and finally “Fibrosis Stage” of severe perfusion defect with minimal or no FDG uptake. The different findings are depicted in figure 1, reproduced with permission from a review by Blankstein et al.<sup>107</sup>

**Figure 1.** Different stages of CS by combination of FDG-PET and perfusion imaging (Reproduced from Blankstein et al)

Spectrum of disease by PET/CT to evaluate rest perfusion and metabolism						
	Normal perfusion and metabolism		Abnormal metabolism		Abnormal perfusion and/or metabolism	
<b>Perfusion</b>						
	Normal	Normal	Normal	Abnormal	Abnormal	Abnormal
<b>FDG</b>						
	Normal (Negative)	Diffuse (non-specific)	Focal increase	Focal increase	Focal increase (different areas)	Normal (Negative)
<b>Interpretation</b>	Normal	Non-specific*	Early Disease	Mismatch Pattern	Scar and Inflammation	Scar

### 2.5.5.5 Whole-body imaging

In addition to demonstrating active inflammation in the heart, FDG-PET may show active foci elsewhere in the body. As discussed above, sarcoidosis may manifest in any organ or in different organs simultaneously.<sup>108</sup> When FDG-PET imaging is

performed for suspicion of CS, the imaging usually covers the area of thorax from the level of clavicles to below the diaphragm. According to an American consensus statement, the imaging should cover thorax, liver and spleen to detect possible extracardiac uptake indicating systemic sarcoidosis.<sup>87</sup> Diagnosis of CS warrants for histological verification of sarcoidosis and EMB is known to be insensitive. Pointing out active inflammation in extracardiac sites is thus valuable. In a Finnish study involving 110 patients with CS, 50 % were diagnosed by EMB and the other half by positive biopsy from an extracardiac site.<sup>3</sup> To note, 65 % of the 110 patients had no signs or symptoms of extracardiac disease but 71 % of these patients had active mediastinal lymph nodes. In another study, Ishiyama et al detected extracardiac FDG-foci in 81 % of patients with active CS. The most common sites were lymph nodes (38 %), liver (25 %), lung (19 %) and bone marrow (19 %).<sup>109</sup> It has also been shown that in large proportion of CS-patients the FDG accumulation in mediastinal lymph nodes is due to sarcoid inflammation.<sup>110</sup>

On the other hand, Blankstein et al found no association between pathological cardiac findings and active extracardiac disease in 118 patients suspected for CS. In this study, only 27 % of patients with pathological cardiac finding had extracardiac foci.<sup>111</sup> However, cases considered to have pathological cardiac finding also included patients with perfusion defect only. These cases possibly represent late-stage cardiac sarcoidosis in which the inflammatory process is subdued and this may explain the lack of association demonstrated in other studies.

In 2017, Patel et al investigated whether there is an association between extrathoracic and cardiac findings in 191 FDG-PET-studies performed to sarcoidosis patients to evaluate possible cardiac involvement. Ten percent of the patients showed pathological cardiac FDG-uptake and 40 % these showed extrathoracic foci. The frequency of extrathoracic active sites was similar in the 171 patients with normal cardiac finding as 34 % of them had pathological FDG-uptake outside thorax. The most common sites for active inflammation were lymph nodes, liver, spleen and bone.<sup>112</sup> These findings suggest that when performing FDG-PET patients with known sarcoidosis it might be advisable to cover the whole body instead of only thorax and upper abdomen to show all active disease.

### 2.5.5.6 Diagnostic performance of FDG-PET in cardiac sarcoidosis

FDG-PET was first recognized as a potential tool in diagnosing cardiac sarcoidosis in the early 2000's. Mainly Japanese groups were inspired by studies that had shown FDG-uptake in hilar and mediastinal lymph nodes in patients with sarcoidosis.<sup>113,114</sup> The first known study was published by Yamagishi et al in 2003. They compared FDG-PET + PET-perfusion study to Tl perfusion study + Ga-scintigraphy in 17 patients fulfilling the diagnostic criteria for CS. They showed the superior sensitivity of the PET-studies and the reduction of FDG-uptake with anti-inflammatory medication in a follow-up imaging.<sup>103</sup> Other studies have later confirmed the results, which were summarized in a meta-analysis on diagnostic performance of FDG-PET.<sup>115</sup> Seven studies involving 164 patients were included in the meta-analysis. The inclusion criteria for patients was a prior diagnosis of sarcoidosis and fulfillment of JMHW diagnostic criteria for CS or a strong clinical suspicion in some studies. Reported sensitivity in the studies ranged 79–100 % and specificity ranged 38–89 %. The overall pooled sensitivity and specificity were 89 % and 78 %, respectively. However, studies reporting significantly lower sensitivity figures down to 34 % have been published.<sup>116–119</sup>

Using quantitative methods to improve diagnostic accuracy has been studied. Yokoyama has reported sensitivity and specificity of 97 % and 84 %, respectively, using a SUVmax cut-off value 4.0.<sup>120</sup> A recent study used dynamic FDG-PET and coefficient of variation in myocardial glucose influx reaching sensitivity and specificity of 100 % and 91 %, respectively, against JMHW criteria.

However, determining the true sensitivity and specificity of any imaging study is complicated by lack of good gold standard for diagnosis: Patel et al investigated the sensitivity of CMR and JMHW using follow up data as gold standard. They concluded that CMR identified cardiac involvement more often than JMHW criteria and follow up EMB data support the idea that the identified cases represent true sarcoid involvement in the myocardium.<sup>121</sup>

There are only few studies comparing the diagnostic accuracy of FDG-PET and CMR. In 2008, Ohira et al found slightly better sensitivity for FDG-PET compared to CMR (88 % and 75 %, respectively). However, FDG-PET had significantly lower specificity.<sup>122</sup> In another study, the imaging modalities were compared in patients with conduction system disease due to sarcoidosis. The results showed that CMR more often identified myocardial damage in patients with mild chronic conduction system disease whereas PET was more sensitive in patients with acute high-degree

AV-block.<sup>123</sup> This finding demonstrates the difference in the rationale of the imaging methods: LGE in MRI detects scars left by the inflammatory process whereas PET shows acute inflammation.

PET has also been studied in patients presenting with common symptoms of cardiac sarcoidosis, namely AV-block and ventricular tachycardia. Manabe et al found an association between advanced AV-block and pathological septal FDG-uptake.<sup>124</sup> In another study of cardiomyopathy patients with ventricular arrhythmias, 49 % of the patients had pathological myocardial FDG-uptake and 36 % of those were later diagnosed to have CS.<sup>125</sup> Nery et al studied a small population of patients with monomorphic VT. They found that 6 out of 15 patients had pathological myocardial FDG-uptake and four were later diagnosed to have CS. Drawing from the findings discussed above, the SNMMI-ASNC consensus statement recommends cardiac PET/CT imaging in case of unexplained AV-block in patients under 60 years of age and in patients with idiopathic sustained VT.<sup>87</sup>

After the publication of previous meta-analysis in 2012, more studies have been published. A new meta-analysis including 17 studies and 891 patients was published in the beginning of 2019.<sup>121,126</sup> All studies used JMHW criteria as a gold standard. Sensitivity and specificity were 84 % and 83 %, respectively. The patient preparation protocols ranged from none to high-fat-low-carb diet and unfractionated heparin. As a slight surprise, in the included studies the patient preparation protocol did not significantly affect the diagnostic accuracy. The addition of myocardial perfusion imaging (MPI) tended to increase accuracy although the difference was not statistically significant.

To summarize, studying the accuracy of FDG-PET in sarcoidosis is complicated by lack of definite gold standard for diagnosis. JMHW criteria are most commonly used but the shortcoming of the criteria is. During the last 10 years FDG-PET has become an important imaging modality in suspected CS. It may directly demonstrate inflammatory findings in myocardium to guide EMB, which is the only definite mean to diagnose truly isolated CS. On the other hand, EMB and the risks involved can be avoided in some cases by obtaining the biopsy from an extracardiac inflammatory site if there is enough support for the diagnosis of CS from imaging and other cardiac studies. The adequacy of the latter strategy finds support in a recently published study by Simonen et al. The prognosis of EMB-verified absolute CS was compared to probable CS diagnosed by combining sarcoidosis verification from an extracardiac biopsy to cardiac findings fulfilling the diagnostic criteria discussed in chapter 1.3. The results show that the 5-year survival was comparable in the different diagnosis groups.<sup>49</sup> However, the authors point out that EMB is still necessary to diagnose

truly isolated CS and to differentiate CS from other inflammatory cardiomyopathies such as giant cell myocarditis.

#### 2.5.5.7 Prognostic performance of FDG-PET

During the last 10 years, the data supporting important prognostic role of PET in suspected CS has been increasing. One of the most often cited article was published in 2014 by Blankstein et al. They studied the prognostic role of FDG-PET in 118 patients with suspected CS. They found that the patients with pathological FDG-uptake and/or perfusion defects had annual rate of tachycardia or death more than four times higher than in those with no pathological imaging findings, even after adjusting for diagnosis of CS according to JMHW criteria. Pathological uptake in the right ventricle increased the risk even further.<sup>111</sup> In a relatively small population of 36 patients, Ahmadian et al quantified metabolic volume intensity (total cardiac metabolic activity tCMA) from average SUVmax in the heart and the volume of pathological metabolic activity. They found that tCMA was an independent predictor of adverse cardiac events.<sup>127</sup>

Prognostic potential of FDG-PET and CMR have been compared in a couple of studies. Bravo et al concluded that pathological findings in PET did not predict events when adjusted for LGE in CMR<sup>128</sup>. In another recent study investigating prognostic performance of combined cardiac PET/MR, LGE was found to be the best predictor of adverse events. However, pathological metabolic findings significantly increased the event rate during follow-up. Pathological right ventricular FDG-uptake was also found to be predictive of events after adjusting for baseline left ventricular ejection fraction.<sup>129</sup>

A recent study investigated the prognostic value of quantitative PET and perfusion imaging in 203 patients. They used 17-segment model to assess perfusion and metabolism and quantified the heterogeneity of metabolism using coefficient of variation. During the follow-up of 1.8 years, 63 patients developed adverse cardiac event defined as defibrillation due to arrhythmia, heart transplant or death. In a multivariate model coefficient of variation in metabolism and summed score of mismatch defects predicted adverse events.<sup>130</sup> Flores et al investigated whether quantitative metabolic activity and its localization could predict adverse events. The results in 67 patients show that SUVmax and SUVmean especially in the basal segments of left ventricle were predictive of adverse cardiac events.<sup>131</sup> It has also



been shown that SUVmax over all sarcoidosis-involved organs (not only heart) predict response to oral corticosteroids.<sup>109</sup> Muser et al studied the prognostic value of serial FDG-imaging during anti-inflammatory treatment. They calculated the volume-intensity product in cardiac lesion (lesion metabolic activity LMA) and used it to assess treatment response. Adverse cardiac events were significantly more common in the patient with no reduction in LMA.<sup>132</sup>

## 2.5.6 Imaging of CS with somatostatin receptor binding PET-tracers

Sarcoid granulomas have an abundance of inflammatory cells expressing somatostatin receptors (SSTRs) on their surface. Macrophages, giant cells and epithelioid cells found in sarcoid granulomas express SSTR subtype II.<sup>133</sup> This receptor can be targeted by Ga68-labelled PET tracers DOTANOC (Ga-DOTA-NaI-octreotide), DOTATATE (DOTA-DPhe-Tyr3-octreotate) and DOTATOC (DOTA-D-Phe-Tyr-octreotide).

Ga-DOTA-tracers have been used for oncological indications for years. Lately, they have been shown to be promising in the imaging of cardiac sarcoidosis.<sup>134</sup> Compared to FDG-PET, Ga-DOTA tracers benefit from the absence of physiological uptake in the myocardium as SSTRs are not expressed on the cells of healthy myocardium.

The scientific evidence thus far is based on a few relatively small studies but is promising. Nobashi et al found that Ga68-Dotatoc-PET was positive in 19/20 patients with systemic sarcoidosis and showed more active lesions than Ga-Scintigraphy.<sup>135</sup> Lapa et al compared Ga-Dotatoc and CMR in 15 patients with systemic CS and a suspicion of cardiac involvement. SSTR-PET was positive in seven patients and CMR in ten patients. Two of the PET-/CMR+ patients were considered by the investigators as probable false positives as they showed no clinical signs of active cardiac inflammation in the follow up. The authors conclude that detecting CS by SSTR-PET is feasible.<sup>136</sup> Gromsen et al have compared FDG-PET and Ga-DOTANOC-PET in 19 patients with suspected CS. Only three were finally diagnosed with CS but the results highlighted the unspecific nature of FDG-PET imaging as 11/19 of the FDG-PET studies were inconclusive compared to none of SSTR-PET studies. FDG-PET had a diagnostic accuracy of 79 % compared to 100 % of SSTR-PET. The authors conclude that FDG-PET has relatively low diagnostic accuracy and SSTR-PET is a promising alternative.<sup>134</sup>

## 2.5.7 Focus on the right ventricle

Right ventricular LGE or FDG-uptake has been the focus only in few studies. However, the evidence exists for the importance of right ventricular findings on diagnosis and prognosis of CS.

On the diagnostic aspect, Omote et al studied the association of EMB findings and right ventricular (RV) uptake in FDG-PET. Of the 28 patients twelve (43 %) had pathological RV-uptake. EMB was positive in 42 % of the patients with RV-uptake but only in 6 % of those with no RV-uptake. They also followed the patients for 42 months on average and found that those with RV-uptake had more adverse cardiac events.<sup>137</sup> Earlier Blankstein et al had shown that 80 % of EMBs obtained from patients with RV-uptake were positive. As discussed previously, in that study RV uptake was also associated with poor prognosis.<sup>111</sup> The importance of RV-uptake as prognostic factor was also shown by Wicks et al. When adjusted for LVEF, hazard ratio in patients with RV-uptake was 5.84. Even higher hazard ratio of 25.0 was found for RV LGE.<sup>129</sup> Smedema et al found similar results in 84 patients with pulmonary sarcoidosis suspected of having cardiac involvement. In CMR, 12 patients had LGE in the right ventricle and the finding was associated with a hazard ratio of 8.71<sup>81</sup>

### 3 AIMS OF THE STUDY

The overarching aim of the studies I-IV was to assess the role of FDG-PET in the workup of patients with a clinical suspicion of cardiac sarcoidosis. More specifically the aims were:

I to study the association of pathological PET findings, patient characteristics and presenting symptoms to identify the patients that are most likely to benefit from the PET-study.

II to study the association of PET findings and novel ECG-parameters

III to study the association of pathological cardiac and extracardiac PET findings

I and III to study the association of PET and biopsy findings

IV to study the prognostic value of visual and quantitative PET parameters

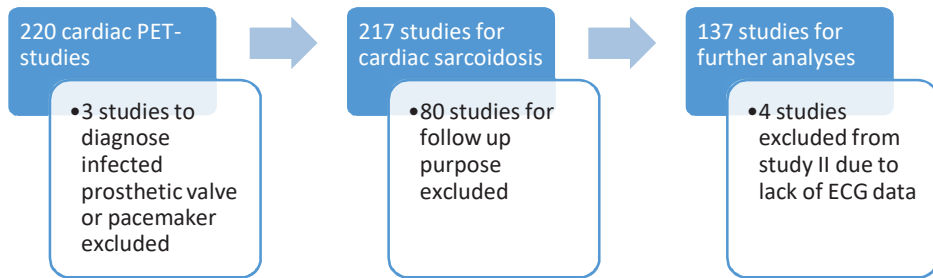
## 4 MATERIALS AND METHODS

### 4.1 Study population

For this study, all cardiac PET studies performed in the Tampere University Hospital from August 2012 to September 2015 were screened. We excluded studies in which the clinical indication was not CS suspicion, if the patient's clinical data could not be obtained or PET study was performed to follow up previously diagnosed CS. Imaging studies were also excluded if the dedicated imaging protocol described below was not followed precisely. Altogether, 137 PET examinations were analyzed. The whole population of 137 patients was analyzed in studies I, III and IV. In study II, further four patients were excluded due to lack of ECG data.

In our hospital, PET is routinely performed in the diagnostic workup of possible CS. The reason for a clinical suspicion of CS was one or more of the following: unexplained atrio-ventricular (AV) block (n=61), ventricular (n=39) or supraventricular (n=13) arrhythmia, unexplained dilated cardiomyopathy (n=27), or unexplained low ejection fraction on echocardiography (n=46), other echocardiographic findings suggestive of CS (n=53), or syncope (n=27). The referring cardiologist considered the symptoms and clinical findings as inconclusive after routine evaluation, including clinical examination, electrocardiography (ECG) and echocardiography. Coronary angiography was performed in cases with a clinical suspicion of coronary artery disease.

**Figure 2.** Flow chart on the patient selection process



## 4.2 PET-imaging

All patients underwent an integrated PET/CT (Discovery STE 16, GE Healthcare, Milwaukee, WI, USA) examination. To minimize the physiological myocardial FDG uptake, the patients were instructed not to consume any carbohydrates during the day before the imaging and were fasting for 12 h before the FDG injection. The patients kept a food diary during the diet. The patients were also instructed to avoid heavy physical exercise to minimize FDG uptake in skeletal muscle. The patient's height and weight were measured before the administration of the radiopharmaceutical, and their blood glucose level was tested to be  $<7$  mmol/l. The PET/CT images were acquired approximately 60 min after the intravenous injection of FDG using the Medrad® Intego PET infusion system (Bayer Medical Care Inc., Indianola, PA, USA). The activity injected is currently based on the patient's weight (3-3.2 MBq/kg). However, the protocol was changed in 2013. Previously, patients were given a fixed dose of 370 MBq. The mean injected activity in our study population was 320 MBq (range 219-460 MBq). The imaging covered a volume of two bed positions around the myocardium approximately from the level of shoulders to the level of the gallbladder. The acquisition of the images was performed in the

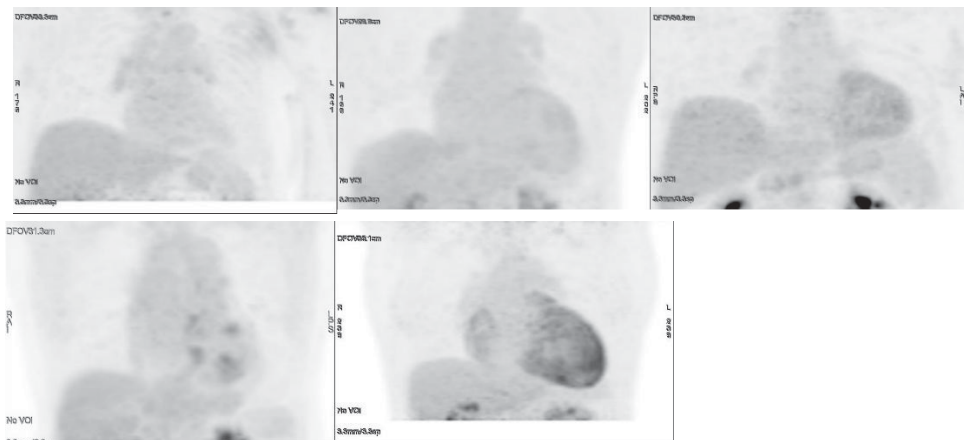
three-dimensional (3D) mode with a 128\*128 matrix, 70 cm field of view (FOV) and 5 min per bed position. The PET images were reconstructed using the 3D VUE Point reconstruction algorithm (GE Healthcare) with 2 iterations and 28 subsets. Gaussian 6.0 mm FWHM was used as the post-filter. The acquisition parameters of the CT scanner were as follows: tube voltage, 120 kV; tube current automatic exposure control range, 30 – 80 mA; noise index, 33 HU; rotation speed, 35 mm/rot; and pitch, 1.75:1. The CT images were reconstructed to slice thicknesses of 2.50 mm, with 1.25-mm intervals. The total examination time for the PET/CT was approximately 15 min. CT was used for attenuation correction and the accurate localization of uptake

### 4.3 Analysis of the PET-images

Cardiac uptake pattern in the left and right ventricular myocardium was classified separately along lines recommended by the Japanese Society of Nuclear Cardiology as ‘none’ (no activity exceeding normal blood pool activity), ‘global diffuse’ (uniform activity over the entire myocardium), ‘focal’ (focally increased spot(s) of activity, other regions inactive), ‘focal on diffuse’ (intense focal spot(s) of activity overlapping global myocardial activity). We also used an uptake pattern described as ‘diffuse non-global’ (faint activity on at least two LV walls, but at least some areas of myocardium with no activity over normal blood pool activity). This pattern is not mentioned in the recommendations issued by Japanese Society of Nuclear Cardiology but was considered to be a similar physiological phenomenon as diffuse uptake. Different patterns are presented in figure 2. The uptake was considered to be physiological when classified as none, global diffuse or diffuse non-global. Myocardial uptake pattern was considered pathological if it was classified as focal or focal on diffuse. Myocardial maximum standardized uptake value (SUVmax) was measured and its location determined. Uptake in the lymph nodes outside heart was considered pathological when exceeding that of the mediastinal blood pool. The areas inspected for possible pathological extracardiac uptake included axillary, subclavicular, mediastinal, hilar and epigastric lymph nodes. We also inspected lung parenchyma, liver, spleen and bone marrow for possible pathological FDG uptake: FDG-uptake in the spleen, liver, and lung parenchyma was considered pathological if there were spots of metabolic activity exceeding the physiological uptake of the surrounding parenchyma. Uptake was considered pathological in the bone marrow

if there was focal uptake exceeding that of the liver. Image interpretation was performed after patient anonymization and randomization by two experienced nuclear medicine physicians (HT, 10 years of experience and KS, 15 years of experience). The physicians interpreted the images separately, blinded to all clinical data. In cases where the interpretation of LV uptake differed between the observers, a consensus was reached and that was used in further analyses. After the initial analysis, quantitative parameters were measured by HT using PETVCAR software on GE Advantage workstation (GE Healthcare, Milwaukee, WI, USA). First, blood pool mean standardized uptake value (SUVmean) was measured from the ascending aorta. Descending aorta was used if there were active lymph nodes near to the ascending aorta. A lower limit of SUV for abnormal cardiac uptake was defined as blood pool SUVmean x 1.5. Using this value, pathological metabolic volume was defined as volume where SUV-value exceeded the threshold. The volume did not have to be continuous. Then SUVmean over the pathological metabolic volume was measured and used to calculate total cardiac metabolic activity (tCMA) by multiplying the metabolic volume by SUVmean.

**Figure 3.** Different types of cardiac uptake: No cardiac uptake (upper left), diffuse non global uptake (upper middle), diffuse uptake (upper right), focal uptake (lower left) and focal on diffuse uptake



## 4.4 Analysis of the ECG recordings

One standard 12 lead ECG recorded with a 50 mm/s speed of each patient was analyzed manually in a systematic manner. The analysis was performed blinded to the clinical data by an experienced cardiologist member of the investigation group.

The ECG closest to the PET/CT study was used, but in the case it was a pacemaker ECG, a previous ECG without pacing was chosen.

For the PQ interval and QRS duration, computer analysis measurements were used.

Sokolow-Lyon criteria<sup>138</sup> or Cornell voltage duration product [QRS-duration (ms)  $\times$  (RaVL in mm + SV3 in mm with 6 mm added for women)  $\geq 2440$ ].<sup>139,140</sup> were used to define left ventricular hypertrophy (LVH).

The criteria used for ST segment depression was  $\geq 0.5$  mm if the pattern was horizontal or descending and  $\geq 1$  mm if ascending in  $\geq 2$  adjacent leads measured at the J point+60 ms.<sup>141</sup> T-wave inversion was defined as  $\geq 1$  mm in  $\geq 2$  adjacent leads, except for leads aVR and V1.<sup>142</sup>

For fQRS in  $\geq 2$  adjacent leads, we used the definitions by Das et al.<sup>64</sup> Septal fragmentation was considered present if there was fQRS in  $\geq 2$  septal leads (V1-V3). We considered fragmentation of  $> 5$  ECG leads as widespread fQRS.

For fascicular and BBB, standard criteria were used. Non-specific intraventricular conduction defect (NSIVCD) was defined as a QRS duration  $\geq 120$  ms, not fulfilling criteria for right (RBBB) or left BBB.

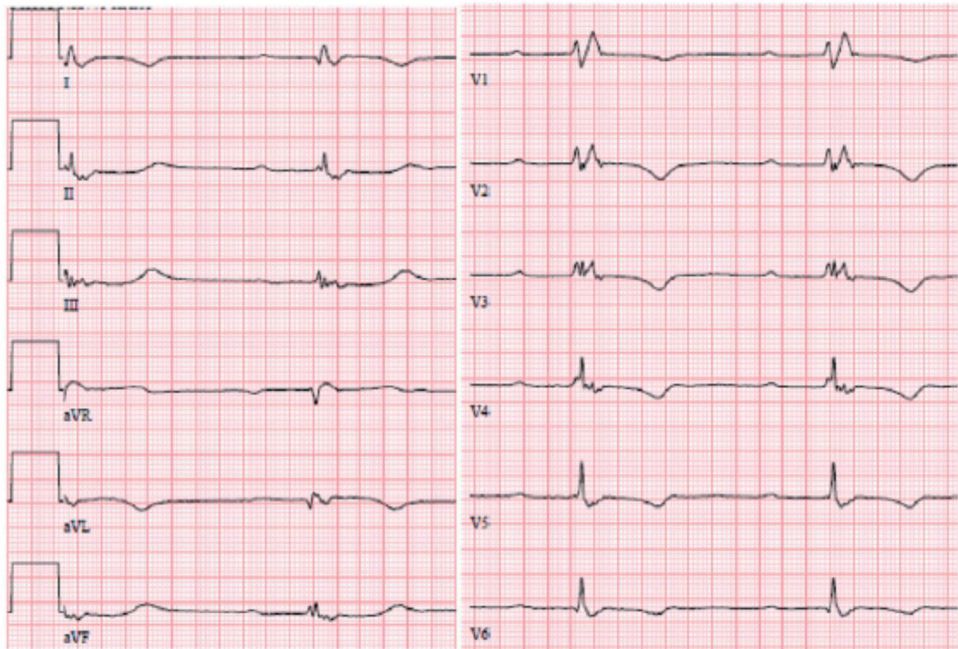
For II or III degree AV block, we used data from the patient history in addition to the ECG analysis data.

In addition to the established ECG changes, we used a recently introduced ECG parameter “Septal remodelling”,<sup>143</sup> which was defined as one of the following present in leads V1-V3:

- 1) Pathological Q waves in  $\geq 2$  parallel leads, and/or
- 2) Septal fQRS as defined above, and/or
- 3) Poor R-wave progression (R wave  $< 3$  mm) in leads V1-V3 accompanied by fQRS, or disorderly distributed R-wave amplitudes, either  $RV2 > RV3$  or  $RV1 > V2$ .<sup>144</sup>



**Figure 4.** An example of ECG with both septal and inferolateral remodeling. Reproduced from [1]



There is QRS fragmentation present in V2-V3 and there is also poor R-wave progression as  $RV2 > RV3$  fulfilling the criteria for septal remodeling. QRS is fractionated also in leads II, III, aVF and aVL which fulfills the criteria for inferolateral remodeling. The criteria for widespread QRS fractionation is also fulfilled.

In addition, we introduced a novel ECG parameter “Inferolateral remodelling”, which was defined as follows:

- 1) fQRS in  $\geq 1$  inferior (II, III, aVF) and lateral (V4-V6) lead, and/or
- 2) Q wave (as defined below) in  $\geq 2$  of the leads II, aVF, V4-V6, and/or
- 3) Low voltage (R-wave amplitude  $\leq 3.5$  mm) in II, III, aVF and V4-V6.

The possibility of a lead switch was considered by assessing the morphology of the P and S waves in the precordial leads, and no suspicious cases were observed. Any Q wave  $\geq 40$  ms in duration, or  $\geq 3$  mm deep, or qR-ratio  $\geq 0.25$ , in  $\geq 2$  parallel leads except lead aVR was considered pathological.<sup>145</sup>

## 4.5 Collection of clinical data

Clinical data were retrospectively collected from the electronic medical record system of Tampere University Hospital, which contains information from 2008 onward. The initial data collection was performed between January and May 2016. At that time, we collected demographic information, echocardiography findings, MRI-findings, relevant diagnoses, symptoms and endomyocardial biopsy (EMB) findings, deaths, healthcare visits and hospitalizations for ventricular tachyarrhythmia. Systolic function evaluated by echocardiography was categorized as normal ( $> 50\%$ ), decreased (35-50 %) or (poor  $< 35\%$ ). Echocardiography findings were collected from studies performed nearest to PET-study and the last echocardiography study of the follow-up period. Diagnosis of CS by cardiologists was based on EMB or a combination of other biopsy verification of sarcoidosis and clinical and/or imaging findings indicating cardiac involvement. Electronic health record data for follow-up was available from the Tampere University Hospital.

For follow-up purposes, a new round of data collection was performed in November 2017. At that time, we collected data for cardiac events after the initial PET-study. Cardiac events of interest were reduction in LVEF, hospitalization due to cardiac arrhythmia, and death. Change in LVEF was determined by comparing the findings between echocardiography studies performed nearest to the PET study and the last study of the follow-up period. Decrease in LVEF was defined as a negative change in LVEF category defined above. We used hospital admission as a definition of severe ventricular arrhythmia as the number of other detected ventricular arrhythmias was highly dependent on whether or not the patient had a pacemaker or implanted cardioverter-defibrillator (ICD).

## 4.6 Statistical methods

IBM SPSS version 22.0 (Armonk, NY,USA) and R Software version 3.2.2 were used for data analysis in original articles I-IV.

In the article I on the association of patient characteristics, symptoms and clinical findings to PET imaging findings, chi-square test was used to compare dichotomous variables between groups. For continuous variables, T-test was used. In this study, inter-observer agreement in PET-interpretation was tested using kappa statistics.

In article II on the association of ECG parameters and PET-findings, Chi-square and T-tests were used to compare dichotomous and continuous variable between patients with and without pathological cardiac FDG-uptake. A logistic linear regression analysis was used to test the independent relations between different ECG parameters and pathological myocardial FDG-uptake in PET. The regression model was adjusted for age, sex, body mass index (BMI), cardiovascular disease and cardiac medication.

In article III on the association of pathological extracardiac and myocardial FDG-uptake, results were compared using chi-square for dichotomous and T-test for continuous variables. A logistic linear regression was used to assess the independent associations of age, sex, pathological left- and right ventricular FDG-uptake and pathological extracardiac FDG-uptake to biopsy findings confirming sarcoidosis.

In article IV on the ability of PET-findings to predict adverse cardiovascular events, T-test was used to compare quantitative PET-parameters between patients with and without cardiovascular events during follow up. Chi-square test was used to compare dichotomous variables between these groups. For survival analysis, log-rank was used to test the ability of pathological LV-, RV- and extracardiac FDG-uptake and LVEF to independently predict cardiovascular events during follow up.

## 5 RESULTS

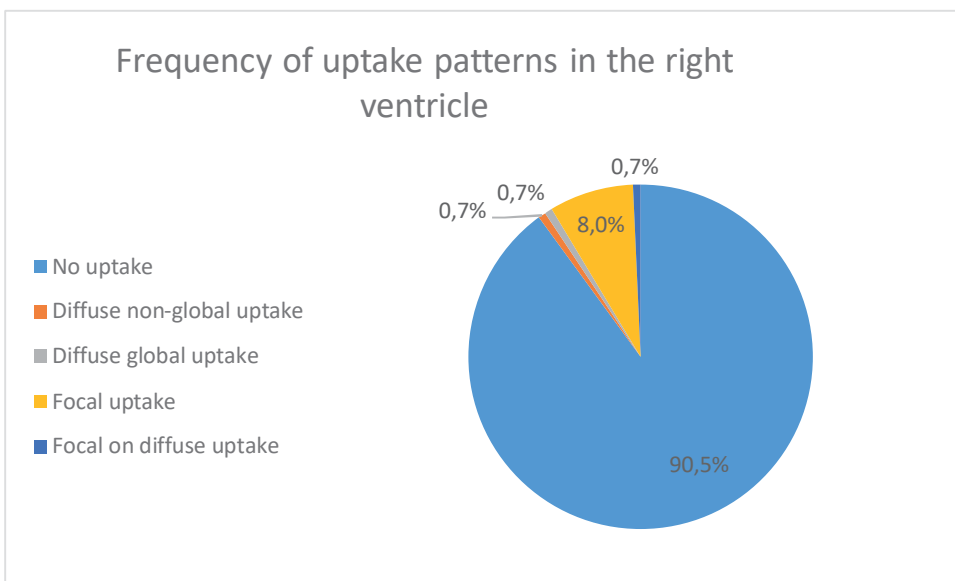
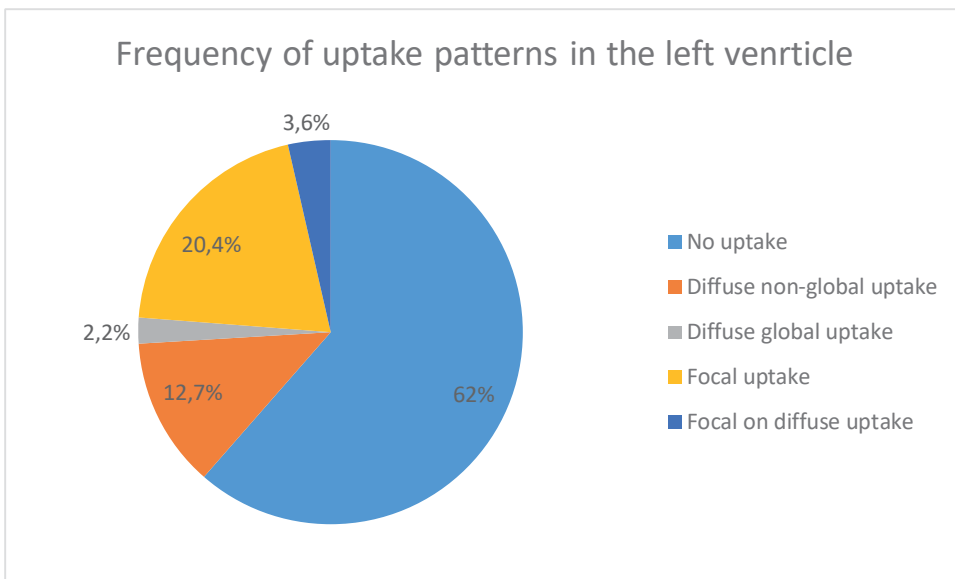
### 5.1 The inter-observer agreement in interpreting the PET-images

The inter-observer agreement for pathological left ventricular FDG-uptake between two interpreters was found to be good as the kappa-value was 0.762.

### 5.2 Myocardial PET-findings

There were 104 patients with no pathological myocardial FDG-uptake: 85 had no uptake exceeding blood-pool activity, three had diffuse uptake and 16 patients had diffuse non-global uptake pattern. Thirty-three patients had pathological myocardial FDG-uptake in the left ventricle: Of those, 28 had focal uptake and five had focal-on-diffuse pattern. Different uptake patterns are presented in figure 5. Cardiac SUVmax was higher in patients with pathological uptake pattern compared to those with no pathological FDG-uptake 8.5 (SD 4.1) and 3.4 (SD 1.3), respectively (p-value <0.001) Qualitative and quantitative PET-findings for the whole population are presented in table 6.

**Figure 5.** Uptake pattern frequencies in left and right ventricle



**Table 6.** Qualitative (a) and quantitative (b) PET-findings for the whole population (n=137)

a)

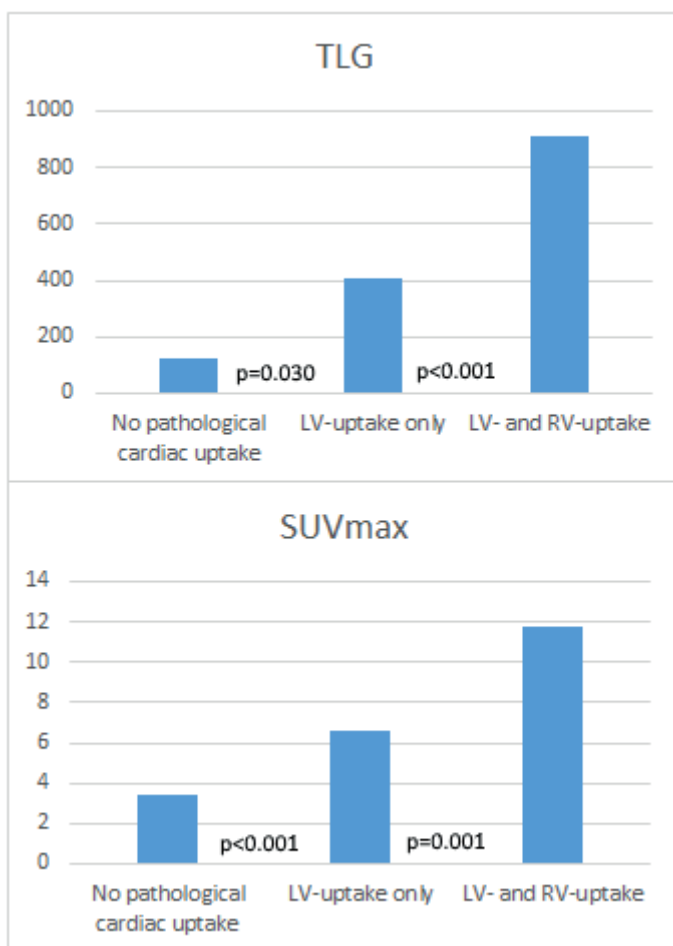
<b>Qualitative PET-findings</b>	<b>n</b>	<b>%</b>
LV-uptake	33	24
LV- and RV-uptake	12	9
extracardiac uptake	29	21

b)

<b>Quantitative PET-findings</b>	<b>mean</b>	<b>SD</b>
SUVmax	4,6	3,1
Pathological metabolic volume (cm <sup>3</sup> )	50	104
SUVmean	2,6	1,3
tCMA (MBq)	193	454

Of the 33 patients with pathological FDG-uptake in left ventricular myocardium, twelve had pathological uptake in the right ventricular free wall also. There were no patients with pathological uptake in the right ventricular wall without left ventricular uptake. Patients with uptake in both ventricles had higher cardiac SUVmax than patients with uptake in the LV only: 11.8 (3,8) and 6.6 (2.8), respectively (p-value 0.001). Quantitative parameter total cardiac metabolic activity was highest in patients with uptake in both ventricles: 914 (SD.706) compared to 404 (567) in those with LV uptake only and 123 (SD 356) MBq in those with no pathological cardiac uptake. (p-value <0.030 between both ventricles and LV-only and <0.001 between LV-only and no pathological uptake). (Unpublished data). (Figure 6)

**Figure 6.** Quantitative PET-parameters in patients with no pathological uptake, uptake in the left ventricle only and in patients with uptake in both ventricles



LV = left ventricle; RV = right ventricle. P-values represented between those with no pathological uptake and LV-uptake only and between those with LV-uptake only and uptake in both LV and RV.

### 5.3 Pathological cardiac PET-findings in relation to patient characteristics

Patient demographics in those with and without pathological LV- and RV-uptake are presented in tables 1 and 2. There were 80 male and 57 female patients in the study population. Thirteen (16 %) male and 20 (35 %) female patients had abnormal LV uptake. The frequency of pathological myocardial FDG-uptake was significantly higher in women. Of the 12 patients with pathological RV-uptake, 10 were female (p-value 0.002).

In our population, 56 patients had a history of 2<sup>nd</sup> or 3<sup>rd</sup> degree AV-block. Of these patients 41 % had pathological FDG-uptake compared to 12 % of those without advanced AV-block (p-value <0.001). The frequency of pathological FDG-uptake was 56 % in female patients with advanced AV-block (n=27). In male patients with no or mild AV-conduction abnormality (n=46), the frequency of pathological myocardial FDG-uptake was only 6 %.

Seventy-five patients had a history of ventricular tachyarrhythmia. Of those, 23 (31 %) had pathological left ventricular FDG-uptake and 11 (15 %) had pathological right ventricular FDG-uptake. Of the 12 patients with pathological RV-uptake, 92 % had a history of VT. The association was statistically significant between history of VT and RV-uptake (p-value 0.006) but did not reach significance for LV-uptake (p-value 0.053). Patient characteristics and reasons for referral in patients with and without pathological LV and RV uptake are presented in tables 7 and 8, respectively.



**Table 7.** Baseline variables in patients with pathological or normal left ventricle FDG-PET-finding. (reproduction from I)

Variable	Abnormal LV-uptake (n =33)	Normal LV-uptake (n=104)	p-value
Gender, female/male	20/13 (61/39%)	37/67 (36/64%)	0.002*
Age, years	45.8 ±12.1	43.7 ±13.2	0.401
Body mass index	26.2 ±3.9	28.3 ±5.9	0.053
History of:			
II or III degree AV-block	23 (70%)	33 (32%)	<0.001
Ventricular tachycardia	23 (70%)	52 (50%)	0.053
Atrial fibrillation	16 (49%)	37 (36%)	0.185
Heart failure	14 (42%)	53 (51%)	0.393
Pulmonary sarcoidosis	10 (30%)	17 (16%)	0.208
Any heart disease	22 (67%)	64 (62%)	0.595
Reasons for referral:			
AV-block	25 (76%)	35 (34%)	<0.001*
Supraventricular arrhythmia	3 (9%)	10 (10%)	0.541
Ventricular arrhythmia	5 (15%)	34 (33%)	0.052
Dilated cardiomyopathy	6 (18%)	22 (21%)	0.712
Abnormal echo findings	14 (43%)	39 (38%)	0.613
Syncope	6 (18%)	22 (21%)	0.712
CS-positive EMB§	6 (18%)	1 (1%)	0.190

Figures are n (%) for dichotomous and mean (+/- SD) for continuous variables. Abbreviations: CS=cardiac sarcoidosis; EMB=endomyocardial biopsy; FDG-PET=

<sup>18</sup>Fluorodeoxyglucose positron emission tomography; LV= left ventricle; AV=atrio-ventricular. § EMB was obtained from 21 patients.

**Table 8.** Baseline variables in patients with or without pathological right ventricular FDG-PET-finding. (reproduction from I)

Variable	Abnormal RV-uptake (n =12)	Normal RV-uptake (n=125)	p
Gender, female/male	10/2	49/76	0.004*
Age, years	44.7 ±8.2	44.1 ±13.3	0.878
Body mass index	28.0 ±5.7	25.8 ±4.1	0.188
History of:			
Ventricular tachycardia	11 (92%)	64 (52%)	0.006*
Atrial fibrillation	8 (67%)	45 (36%)	0.040*
Heart failure	5 (42%)	62 (50%)	0.413
Pulmonary sarcoidosis	4 (33%)	23 (18%)	0.249
Any heart disease	10 (83%)	76 (61%)	0.106
Reasons for referral:			
AV-block	10 (83%)	50 (40%)	0.004*
Supraventricular	1 (8%)	12 (10%)	0.682
Ventricular arrhythmia	4 (33%)	35 (28%)	0.461
Dilated cardiomyopathy	1 (8%)	27 (22%)	0.250
Abnormal echo findings	5 (43%)	48 (38%)	0.527
Syncope	4 (33%)	24 (19%)	0.209
CS-positive EMB§	4 (33%)	3 (2%)	0.537

Figures are n (%) for dichotomous and mean (+/- SD) for continuous variables. Abbreviations: CS=cardiac sarcoidosis; EMB=endomyocardial biopsy; FDG-PET= <sup>18</sup>Fluorodeoxyglucose positron emission tomography; RV= right ventricle; AV=atrio-ventricular. § EMB was obtained from 21 patients

## 5.4 Pathological extracardiac FDG-uptake

Of the 137 patients, 29 had pathological FDG-foci outside myocardium. Extracardiac uptake foci were most often found in mediastinal and/or hilar lymph nodes (n= 24) and lung parenchyma (n=14). Metabolically active foci were also found in spleen (n=5), axillary (n=5), subclavicular (n=5) and epigastric (n=6) lymph nodes.

**Table 9.** Frequency of extracardiac uptake at different sites

Extracardiac uptake site	n	%
any extracardiac uptake	29	21
Lung	14	10
Spleen	5	4
Mediastinal lymph nodes	23	17
Hilar lymph nodes	24	18
axillary lymph nodes	5	4
Subclavicular lymph nodes	5	4
Epigastric lymph nodes	6	4
Bone marrow	1	1

The frequency of extracardiac uptake was higher in female patients (33 % in female and 13 % in male patients, p-value 0.006). The patients with pathological extracardiac uptake more often had history of ventricular tachyarrhythmias than patients with no pathological extracardiac uptake (p-value 0.035). They also had history of cardiac

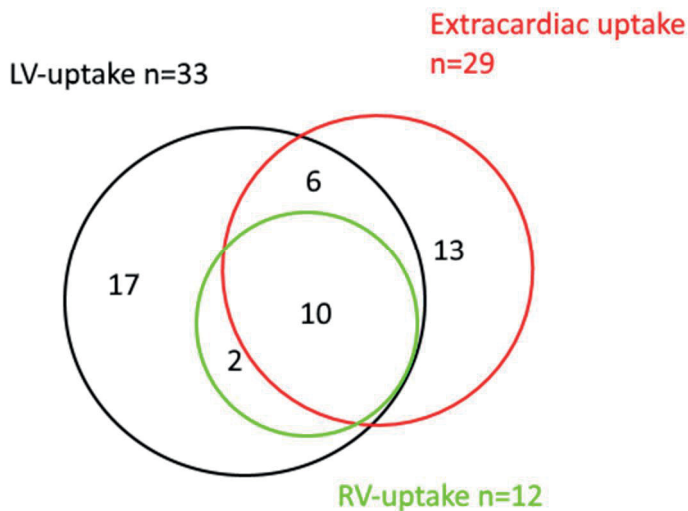
insufficiency less often than those with no abnormal extracardiac uptake (p-value 0.010). (Table 10)

There was a significant association of pathological cardiac and extracardiac uptake: Of the 33 patients with pathological cardiac uptake 16 (48 %) had pathological extracardiac FDG-uptake compared to 13 (13 %) of the 104 patients with no pathological cardiac uptake (p-value <0.001). The association was even more pronounced for those with pathological right ventricular uptake as 10/12 (83 %) compared to 19/125 (15 %) in those with no pathological RV-uptake had extracardiac uptake (p-value <0.001). Patient characteristics and PET-findings in patients with and without extracardiac uptake are presented in table 10.

The analysis of associations between different extracardiac uptake sites and pathological cardiac uptake revealed that there was association only between mediastinal and hilar lymph node uptake and pathological myocardial uptake (p<0.001 for both). There was no significant difference in the frequency of extracardiac fdg-uptake sites other than mediastinal/hilar between those with and without pathological cardiac uptake (p-values for different sites ranging from 0.085-0.652).

Fourteen patients had pathological cardiac uptake but had no prior known sarcoidosis or extracardiac uptake. Two of them had CS verified by EMB.

**Figure 7.** Patients with LV, RV and extracardiac uptake: Each circle represent the number of patients with uptake in left ventricle (black), right ventricle (green) and outside heart (red). Overlap of specific circles represents the combination of uptakes, for example, there is 10 patients with uptake in LV, RV and outside heart.



**Table 10.** Baseline variables and FDG-PET-findings in patient with and without pathological extracardiac FDG-uptake (representation from III)

Variable	Pathological extracardiac FDG-uptake (n=29)	No pathological extracardiac FDG-uptake (n=108)	p-value
Female gender	19 (66 %)	40 (37 %)	0.006*
BMI	27.3 (4.2)	28.0 (5.9)	0.525
Age, years	44.1 (12.3)	44.2 (13.2)	0.97
History of:			
Ventricular tachycardia	21 (72 %)	54 (50 %)	0.035*
II or III degree AV-block	14 (48 %)	42 (39 %)	0.241
Cardiac insufficiency	8 (28 %)	59 (55 %)	0.01*
LV-uptake	16 (55 %)	13 (12 %)	<0.001*
RV-uptake	10 (34 %)	2 (1,9 %)	<0.001*
Extracardiac biopsy positive for sarcoidosis	11 (38 %)	4 (4 %)	<0.001*
EMB or extracardiac biopsy positive for sarcoidosis	15 (52 %)	7 (7 %)	<0.001*

Figures are n (%) for dichotomous and mean (+/- SD) for continuous variables. Abbreviations: BMI=Body mass index; EMB=endomyocardial biopsy; FDG-PET=<sup>18</sup>Fluorodeoxyglucose positron emission tomography; AV=atrio-ventricular; RV=right ventricle; LV left ventricle

## 5.5 Association of ECG- and PET-finding

The association of different ECG parameters and pathological cardiac PET-findings were analyzed in 133 patients who had ECG data available. Thirty-two of these patients had pathological myocardial FDG-uptake.

Pathological LV-uptake was associated with septal remodeling, inferolateral remodeling, widespread QRS fractioning and ventricular conduction abnormalities (defined as any bundle branch block). The association of bundle branch block and pathological LV-uptake was explained by left anterior fascicular block that was the only ventricular conduction defect that was significantly more frequent in patients with pathological LV-uptake. The frequencies of different ECG parameters with regard to cardiac PET finding are presented in table 11.

There were no significant associations between pathological myocardial FDG-uptake and PQ-interval length or the presence of advanced (II or III degree) AV-block. Neither was there significant difference between those with and without pathological cardiac uptake with respect to Q-waves, LVH, T-inversion, ST-segment depression, poor R-wave progression or fractioned QRS in at least 2 adjacent leads.

The association of pathological cardiac FDG-uptake and septal remodeling, inferolateral remodeling and widespread fQRS remained significant when adjusted for sex, age, BMI, cardiac medication, presence of underlying cardiac disease and history of II or III degree AV-block ( $p$ -value  $<0.05$  for all).

The number of patients diagnosed by EMB was low in our population. Of the seven patients with EMB findings indicating CS, five had a finding of septal remodeling in their ECG.

**Table 11.** ECG parameters in patients with or without pathological cardiac FDG uptake. Modified from 11

ECG parameter	Physiological cardiac uptake (n=101)	Pathological cardiac uptake (n=32)	p-value
PQ interval (ms)	191.7 ± 56.0	222.3 ± 79.7	0.069
Poor R wave progression (%)	20	29	0.493
Left ventricular hypertrophy (%)	25	14	0.387
ST segment depression (%)	22	21	0.959
T wave inversion (%)	37	43	0.669
QRS fragmentation (%)	60	69	0.395
Septal remodelling (%)	15	44	0.001*
Inferolateral remodelling (%)	9	28	0.006*
RBBB (%)	14	22	0.279
LBBB (%)	7	9	0.648
LAFB (%)	10	28	0.010*
Any intra-ventricular conduction defect (%)	35	56	0.030*
AV block (II or III degree) (%)	9	13	0.532
Widespread (N5 leads) fQRS (%)	22	50	0.002*

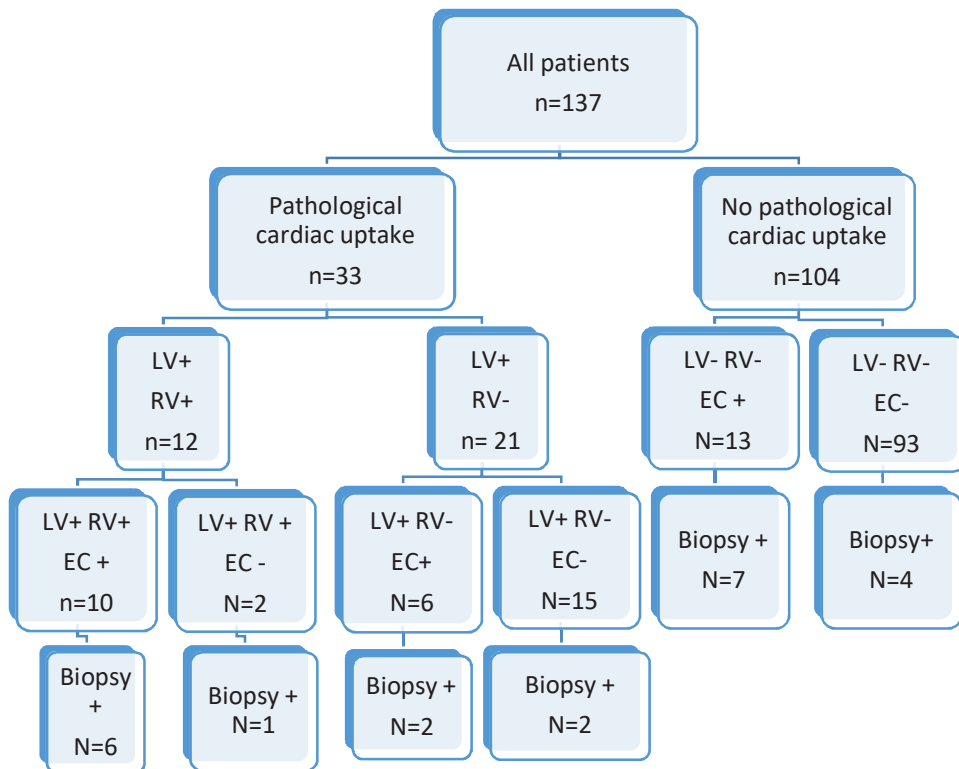
Values are means ± SD in continuous variables and % in dichotomous variables. RBBB = right ventricular bundle branch block, LBBB = left bundle branch block, LAFB = left anterior fascicular block; LPFB = left posterior fascicular block; AV= atrioventricular, fQRS = QRS fragmentation. \*p-value < 0.05

## 5.6 Biopsy findings confirming sarcoidosis and their association with PET results

In our population, endomyocardial biopsy was obtained from 21 patients. The histology was suggestive of cardiac sarcoidosis in seven patients. Six of the seven patients had pathological LV uptake and four had uptake in both ventricles. However, due to the low number of biopsies the association between cardiac FDG-uptake and positive EMB did not reach significance (p-value 0.190).

A biopsy from an extracardiac site was obtained in 25 patients and in 15 it was indicative of sarcoidosis. There was a significant association of pathological extracardiac FDG-uptake and sarcoidosis-positive biopsy finding (p-value<0.001). In a logistic regression model including LV uptake, RV uptake and extracardiac uptake, only the last was associated to positive biopsy finding (extracardiac or endomyocardial).

**Figure 8.** Patients divided into groups according to PET-findings and the number of tissue biopsies (EMB or other) positive for sarcoidosis





## 5.7 The ability of FDG-PET to predict adverse cardiac events

During the average follow-up of 55 months, eleven patients had one or more adverse cardiovascular (CV) event. Seven patients were hospitalized for ventricular tachyarrhythmia, LVEF decreased in five patients and three died. No significant difference in any baseline characteristics, including LVEF, were observed between patients who had CV events and those who had no events.

Out of 33 patients with pathological LV-uptake, five had an adverse cardiac event during follow up. All those also had uptake in the right ventricle. RV uptake but not LV-uptake was significantly associated to CV events ( $p$ -values  $<0.001$  and  $0.091$ , respectively). Baseline characteristics and PET findings in patients with and without events are presented in table 12.

Quantitative metabolic PET parameters, specifically cardiac SUVmax and total cardiac metabolic activity (tCMA) were higher in patients with events compared to those with no events:  $7.1$  vs  $4.4$  and  $530$  MBq vs  $163$  MBq, respectively ( $p < 0.001$  for both).

A cut-off value of  $>900$  MBq was used to define high tCMA. There were 8 patients with tCMA exceeding that and three (38 %) of them had an event during follow up compared to 6 % of those with tCMA  $<900$  MBq. All three patients with events and high tCMA also had pathological uptake in the RV.

In a multivariate survival analysis, high tCMA and RV uptake were significant predictors for events ( $p$ -values  $0.032$  and  $<0.001$ , respectively). Decreased baseline LVEF, pathological LV-uptake or extracardiac FDG-uptake did not significantly predict CV events during follow up ( $p = 0.094, 0.217$  and  $0.489$ , respectively).

Cardiac sarcoidosis was diagnosed in 18 patients according to diagnostic criteria. There was no significant difference in the frequency of CV events between patients who were diagnosed with CS and those who were not ( $p$ -value  $0.148$ ).

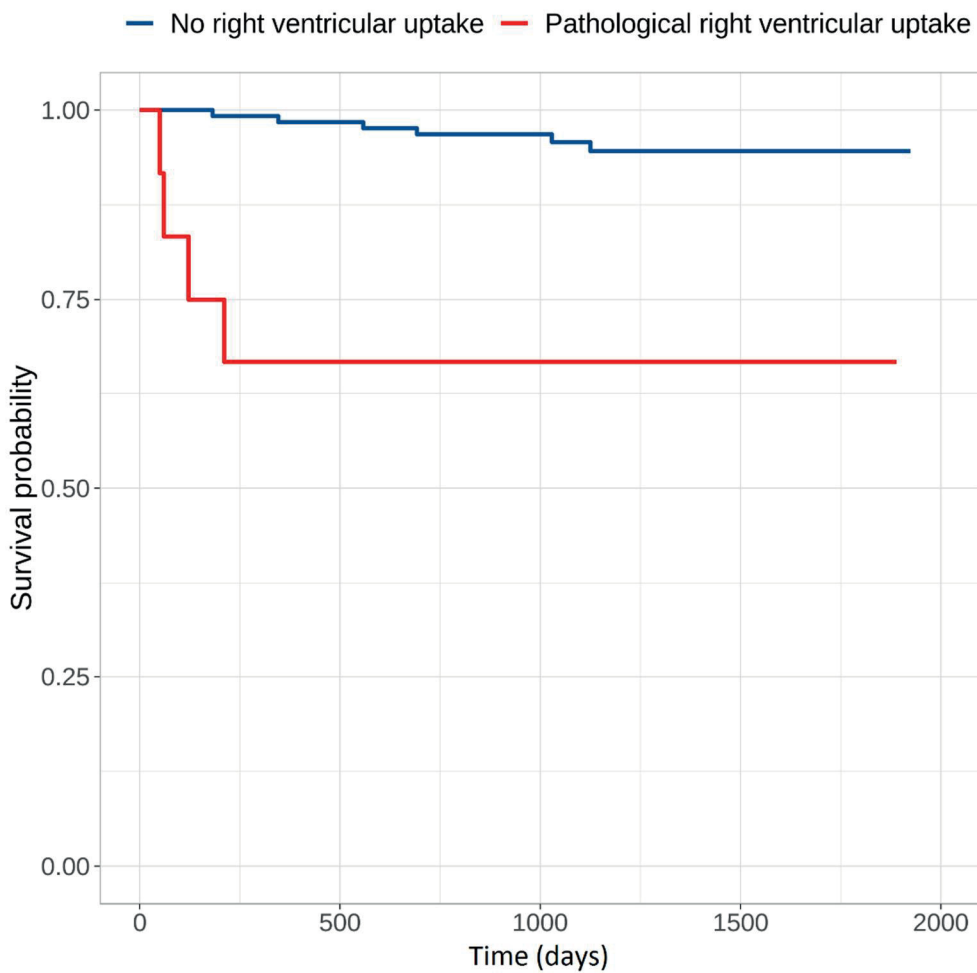
Survival curves for patients with and without pathological RV uptake are presented in figure 9 and survival curves for patients with low and high tCMA are presented in figure 10

**Table 12.** Baseline characteristics, PET-findings and treatment during follow up in patients with and without events during follow up

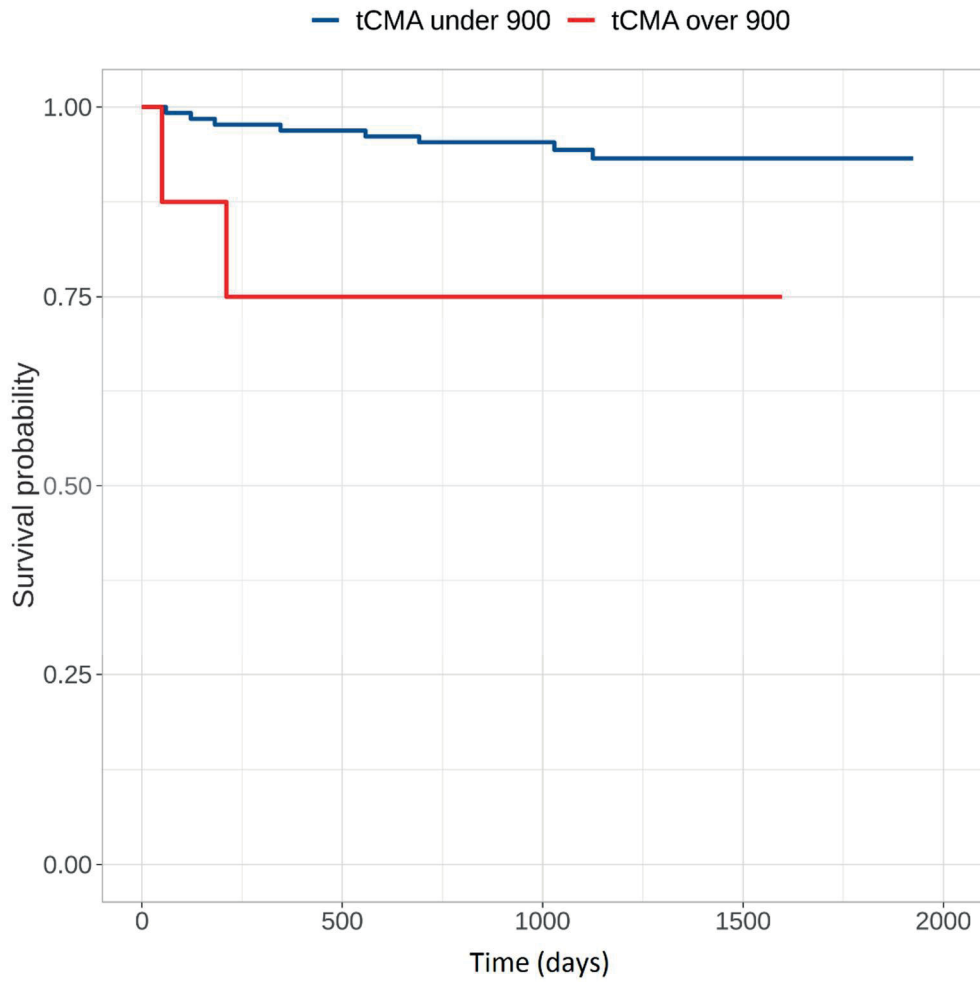
	Patients with events n=11	Patients with no events n=126	p-value
<b>Baseline characteristics</b>			
Female sex	45% (5)	43% (54)	0.556
Age, y (SD)	37 (8)	45 (13)	0.062
Follow-up, mo (SD)	50 (8)	44 (11)	0.059
Reduced LVEF at baseline	73% (8)	54% (68)	0.190
<b>PET findings</b>			
Pathological LV-uptake	46% (5)	22% (28)	0.091
Pathological RV-uptake	46% (5)	6% (7)	<0.001*
tCMA>900 MBq	27% (3)	4% (5)	0.018*
Extracardiac uptake	36% (4)	20% (25)	0.180
SUVmax	7.1 (5.6)	4.4 (2.8)	<0.001*
Metabolic volume (cm <sup>3</sup> )	105 (167)	44 (96)	0.050
tCMA (MBq)	530 (886)	163 (388)	<0.001*

Values are % (n) for dichotomous and mean (SD) for continuous variables. LVEF=Left Ventricular Ejection Fraction; LV=Left Ventricle; RV=Right Ventricle SUV=standardized uptake value; Metabolic volume =Volume of myocardium with SUV>1.5 x aortic reference SUV; tCMA=total cardiac metabolic activity calculated as SUVmean x Metabolic volume \*p-value < 0.05

**Figure 9.** Survival free of cardiac events in patients with no right ventricular uptake and in those with pathological right ventricular uptake. Between groups the p-value is 0.001.



**Figure 10.** Survival free of cardiac events in patients with tCMA below or above 900 MBq. Between groups the p-value is 0.032



## 6 DISCUSSION

### 6.1 Methodological considerations

This is a retrospective study on a clinical cohort of patients with suspected cardiac sarcoidosis referred to cardiac FDG-PET study. Our selection criteria were relatively loose: patients were included if the referring cardiologist had suspicion of CS based on symptoms and findings after other possible causes for the symptoms were ruled out by clinical examination, ECG and echocardiography and coronary angiography when considered necessary. For this reason, our population is representative of a true clinical situation faced by physicians interpreting the images and clinicians considering the significance of imaging results.

The loose inclusion criteria also lead to the fact that a majority of the subjects do not have CS, but some other yet unrecognized cardiac disease. This resulted in the relatively low frequency of pathological cardiac PET findings compared to other studies (discussed later). The frequency of CS diagnosed according to the criteria was also low and CS verified by EMB even lower.

In the nuclear medicine department of Tampere University Hospital, it is not common to perform myocardial perfusion imaging (MPI) study in combination with FDG-PET in suspicion of myocardial inflammation. This is somewhat contrary to international practice.<sup>101</sup> MPI data might have increased the sensitivity as non-active late phase sarcoidosis might have been detected. However, of the seven patients who were diagnosed to have CS by EMB only one was PET-negative. Anyhow, including MPI must be considered in possible prospective trials in the future.

Our study population was 137 patients, which is in scale with populations in other larger studies on CS. However, the relatively low number of positive cardiac PET-findings hindered the use of robust multivariate logistic regression analysis to determine the independent role of different pre-test variables in predicting positive PET-results in studies I and III. The same problem was encountered in IV when trying to determine the independent prognostic role of PET-related and other variables.

We encountered the common problem concerning most studies on CS, namely the lack of diagnostic gold standard. Verification by EMB is specific but its low sensitivity and risk of complications especially in left ventricular biopsies limits its usefulness. For this reason, we did not make conclusions on the accuracy of FDG-PET in diagnosing CS. To draw a reliable conclusion on accuracy figures would demand a prospective study with rigorous diagnostic scheme optimally including multiple endomyocardial biopsies when necessary.

The clinical presentation and prognosis of CS is known to vary between different ethnic populations. Our study population consists of patients of Caucasian origin and thus our findings should be interpreted with caution in relation to other ethnic populations.

The number of adverse events in IV remained low because we only included ventricular tachycardias that had led to hospital admission. Including all VTs was considered but was later discarded as the initial analyses indicated that the amount of registered VTs was highly dependent on whether or not the subject had a pacemaker or ICD. This could have led to falsely high number of events in patients with positive PET findings as ICD was often implanted in such patients as the cardiologists considered them to be in risk of serious rhythm disturbances (even as PET is not included in risk stratification in the 2014 HRS consensus statement).<sup>47</sup>

## 6.2 The results in reflection to existing literature

### 6.2.1 Success in reducing physiological myocardial uptake

Physiological myocardial uptake was observed in 18.5 % of patients: 2.2 % had global diffuse uptake, 12.7 had diffuse non-global uptake and 3.6 had diffuse uptake under focal pathological spots. This is in line with the figures of up to 20 % in of studies applying the same patient preparation procedures (non-carbohydrate diet combined to fast).<sup>94</sup> On this basis, our patient preparation protocol and resulting image quality is up to international standards.

## 6.2.2 Inter-observer agreement

The inter-observer agreement on whether the cardiac uptake pattern was pathological or not was found to be good between two experienced nuclear medicine physicians (kappa value 0.76). This is somewhat better compared to 0.72 found by Gromsen et al.<sup>146</sup> The difference might be explained by the fact that in their study, there were four interpreters and that in their population complete suppression of myocardial FDG-uptake was achieved in only 11 % of patients compared to our 62 %. Assumedly, the low proportion of patients with complete suppression complicates the interpretation of images.

## 6.2.3 Frequency of positive PET findings

In our population, 24 % of patients had pathological myocardial uptake. In previous studies on FDG-PET in suspected CS the proportions of patients with pathological myocardial uptake has varied widely. In the 17 studies included in a recent meta-analysis, the average proportion of positive PET findings was 31 %. The range was wide, from 6 % up to over 60 % depending on the patient population. Some recent studies are listed in table 13. Considering the relatively loose inclusion criteria in our population, the results are well in line with other existing literature.

**Table 13.** Proportions of positive myocardial PET-findings in other studies on FDG-PET in suspected CS.

Study	Population	imaging methods	Positive findings
Ohira 2008 <sup>122</sup>	21 patients with pulmonary sarcoidosis	CMR + PET	FDG uptake 71 % LGE 38 %
Manabe 2013 <sup>124</sup>	59 patients with biopsy-proven extracardiac sarcoidosis	PET	FDG uptake 59 %
Blankstein 2013 <sup>111</sup>	118 patients evaluated for suspected or known CS	PET+ perfusion imaging	FDG uptake or perfusion defect 60 %
Soussan 2013 <sup>147</sup>	58 sarcoidosis patients with suspected CS	PET	FDG uptake 34 %
Ahmadian 2014 <sup>127</sup>	38 suspected CS	PET	FDG uptake 61 %
Yokoyama 2015 <sup>148</sup>	92 suspected CS	PET	FDG uptake 60 %
Momose 2015 <sup>149</sup>	52 suspected CS	PET	FDG uptake 65 %
Wicks 2018 <sup>129</sup>	51 suspected CS	PET + MR	FDG uptake 55 % LGE 63 %
Schidt 2018 <sup>150</sup>	231 suspected CS	PET + PERF	Pathological pattern 20 %
Sgard 2019 <sup>151</sup>	80 with sarcoidosis and suspected CS	PET+ MRI	FDG uptake 14 % LGE 43%



Pathological right ventricular uptake was found in 12 of our 137 patients. There are few studies mentioning right ventricular uptake. In the 2008 study on 21 patients with pulmonary sarcoidosis and suspicion of CS by Ohira, 1 patient (5 %) had RV-uptake.<sup>122</sup> Manabe et al studied 59 patients with biopsy-proven sarcoidosis and found RV-uptake in 13 patients (22 %).<sup>124</sup> In the much-cited study by Blankstein et al on prognostic role of FDG-PET, there were 11 out of 118 patients (9 %) with RV-uptake.<sup>111</sup> Wicks found RV-uptake in 4/51 (8 %) patients with suspected CS and Omote found a high proportion of 12/28 (43 %) in patients with diagnosed CS.<sup>129,137</sup> Our results on the frequency of RV-uptake fall in line with studies on FDG-PET in suspected (but not diagnosed) CS.

There were no patients with RV uptake without LV uptake. This situation seems to be very rare as only one mention of such uptake pattern on one patient can be found in the literature.<sup>124</sup>

## 6.2.4 Patient demographics, history and PET findings

We found that pathological myocardial FDG-uptake was more frequent in females and in those with a history of II or III degree AV-block. In addition, there was an association of RV uptake and history of ventricular tachyarrhythmias.

The association of AV-block and inflammatory myocardial disease is relatively well established. In our population, there were 56 patients with a history of AV block and 12 (21 %) of them showed pathological myocardial FDG-uptake in PET. Previously, Kandolin et al found CS in 22/76 patients with advanced AV-block.<sup>33</sup> Nery et al found similar results in 33 patients with advanced AV-block with 11 (34 %) patients subsequently diagnosed with CS.<sup>32</sup> The association of pathological FDG-PET results and AV-block was also observed on another study by Nery et al on patients with unexplained VT tendency.<sup>4</sup> Furthermore, There is evidence of association between uptake in basal septum and AV-block.<sup>124</sup>

Our results on association of AV-conduction block and pathological cardiac PET findings may seem somewhat confusing, as there was association between history of AV block and PET findings and no association of AV-block in the ECG nearest to PET and pathological myocardial FDG-uptake. This may be explained by the tendency of AV conduction block in CS to be variable. This is acknowledged in HRS consensus statement on treatment of conduction disturbances as pacemaker implantation is recommended even if advanced AV-block has receded.<sup>47</sup> Thus, a

notion of advanced AV-block in patient history can be considered to be more sensitive sign than AV-block in a single ECG recording.

Right ventricular uptake was more frequent in patients with a history of ventricular tachycardias. Nery et al have shown the association of VTs and myocardial FDG-uptake in a small population.<sup>4</sup> Tung et al have also shown the association as 49 % of patients with cardiomyopathy and VTs had pathological cardiac FDG-uptake on PET.<sup>125</sup>

The studies above do not mention the site of pathological cardiac FDG uptake. There is scarce evidence for the association of RV uptake and ventricular tachycardias. However, it has been shown that patients with RV scarring shown by LGE in CMR have a higher risk of VT among other cardiac events.<sup>81</sup> The association of RV involvement in CS and ventricular tachycardias have also been shown in electrophysiological studies.<sup>58,152</sup>

The higher frequency of pathological FDG-uptake in female patients has not been reported previously. Our population had more male than female patients, although a majority of diagnosed Finnish CS patients are female.<sup>3</sup> This may indicate that female patients who were referred to PET study had signs and/or symptoms more specific to CS. Indeed, male patients were referred to PET more often than females for unexplained cardiac insufficiency, which has a multitude of underlying causes. In this manner, the higher frequency of pathological PET findings can be explained by patient selection, but it also gives valuable information for clinicians as it indicates that the suspicion of CS is more often accurate in female patients.

As another proof of unspecific nature of cardiac insufficiency as a symptom of CS is our finding that the frequency of pathological extracardiac FDG-uptake was significantly lower in patients with cardiac insufficiency. In patients suspected for CS, extracardiac foci are considered to represent active systemic sarcoidosis. We found that the presence of extracardiac uptake was the only independent predictor of a biopsy verification of sarcoidosis.

## 6.2.5 Association of ECG and PET findings

Association was observed between pathological PET findings and newly developed ECG parameters septal remodeling and inferolateral remodeling. They combine different signs of myocardial damage, namely Q-waves, poor R –wave progression and QRS fragmentation (fQRS).

Previously, it has been shown that standard ECG has low accuracy in detecting CS.<sup>61</sup> Lately, new parameters based on QRS fragmentation have been developed for ECG analysis and these have been shown to associate with different structural heart diseases, including cardiac sarcoidosis.<sup>63-66</sup>

The existing literature on association of PET- and ECG findings in suspected CS is scarce. Manabe et al found an association between ECG abnormality, defined as RBBB, AV-block, frequent ventricular extrasystolia, VT or left axis deviation, and number of pathological LV-segments in FDG-PET. They found AV-block to be the only ECG parameter significantly correlating with myocardial inflammation.<sup>124</sup>

We found no association between pathological myocardial FDG-uptake and QRS fragmentation, a result seemingly in contradiction with the association of CS and fQRS mentioned previously. However, QRS fragmentation is considered to represent myocardial scarring so it could be considered natural that there was no association of active myocardial lesion shown by FDG-PET and fQRS. However, the association was positive for widespread fQRS (>5 leads). One could speculate that in these cases the granulomatous inflammation in the myocardium is extensive and lesions in different stages coexist.

RBBB has been shown to associate with pathological myocardial FDG uptake, although less strongly than AV-block.<sup>123</sup> We also found an association between ventricular conduction defects and pathological LV-uptake but that was dependent on LAHB. RBBB was not significantly associated with myocardial uptake. This could be explained by the hypothesis that RBBB is a sign of more advanced disease. It is possible that with heightened awareness of CS our patients were referred for imaging at an earlier phase.

The novel ECG parameters of septal and inferolateral remodeling were significantly associated with pathological FDG uptake, even after adjusting with sex, BMI, age, cardiac medication, coexisting cardiac disease and history of advanced AV-block. Our results are preliminary but the ability of septal remodeling to predict positive PET-finding better than AV-block in the same ECG (odds ratio 5.9 and 4.5, respectively) may prove clinically significant if it can be verified in future studies.

## 6.2.6 Extracardiac uptake foci are important in the diagnostic process

We found an association between pathological FDG uptake in right ventricular myocardium and mediastinal/hilar lymph nodes. Furthermore, biopsy verification of sarcoidosis was more common in patients with inflammatory extracardiac foci.

Kandolin et al found FDG-uptake in mediastinal lymph nodes in majority of Finnish patients diagnosed with CS. This also held true for patients without previously known systemic sarcoidosis.<sup>3</sup> Although Blankstein et al found no association between cardiac and extracardiac FDG-uptake, this has been observed in many other studies on FDG-PET in suspected CS.<sup>109,111,153</sup> Lately, Schildt et al have shown similar high frequency of extracardiac foci in patients with CS. They also observed a more pronounced heterogeneity of myocardial FDG-uptake in patients who had extracardiac foci.<sup>150</sup> Heterogeneity of FDG-uptake could be interpreted as a sign of more widespread inflammatory process in a similar manner to RV-uptake.

Diagnosis of CS warrants biopsy verification of sarcoid inflammation either directly from myocardium (EMB) or from an extracardiac site if there is clinical and imaging data indicating cardiac involvement. Obtaining an EMB carries a risk and it has poor sensitivity. For this reason, a biopsy from an extracardiac site is often more viable option. Whole body PET/CT has an important role in demonstrating possible sites for tissue sample collection. This explains our finding that a biopsy indicative of sarcoidosis was obtained more often in patients who had pathological uptake foci outside heart. In the study population of Kandolin et al comprising of all diagnosed cases of CS in Finland, the diagnosis was based on extracardiac biopsy on 50 % of patients.<sup>3</sup> In our population, the situation is more complicated as only a minority of patients have CS. There were seven patients with extracardiac biopsy indicating sarcoidosis but no cardiac FDG-uptake. These patients have no active myocardial inflammation but late-phase inactive CS can't be excluded by PET only. In these cases, perfusion imaging data would have been valuable to diagnose possible inactive disease.

Our results show the importance of extracardiac PET-findings in the diagnostic process of CS in patients who have signs of myocardial disease in PET or other diagnostic modalities.

## 6.2.7 PET as a predictor of adverse cardiovascular events

One of the central findings of the study has been the important role of pathological FDG-uptake in the right ventricle. In our population, RV uptake predicted adverse cardiac events defined as hospital admission due to ventricular tachyarrhythmia, degradation of LVEF, or death. As a slight surprise, the association of pathological cardiac uptake and events was not significant. However, there was a clear association between RV uptake and events. Along with tCMA it was the only independent predictor of events in survival analysis. RV uptake predicted events similarly in patients with diagnosed CS and in those without a firm diagnosis of CS.

The role of RV involvement was described by Blankstein et al, who observed a five-fold risk of cardiac events was associated to RV uptake.<sup>111</sup> Wicks et al found similar figures for FDG-uptake in the RV with OR of 5.84 and even higher risk (OR 25.0) associated with LGE in the right ventricle.<sup>129</sup> In addition, the association of right ventricular LGE and poor prognosis was observed by Smedema et al.<sup>81</sup>

We also measured cardiac SUVmax and calculated total cardiac metabolic activity (tCMA) that is a product of metabolic volume and mean SUV (calculation of tCMA has been described in more detail previously). SUVmax can be understood as measure of intensity of inflammatory activity. In theory, there could be one small spot with very intense accumulation of inflammatory cells producing high SUVmax. In such case, tCMA would not be very high as metabolic volume would be small. However, this is not the case in the reality as PET has suboptimal spatial sensitivity and a very small focus is observed less intense than it really is due to partial volume effect. For this reason, the differences of tCMA and SUVmax are attenuated.

In our population, high tCMA was associated to CV events. Similar results were reported previously by Ahmadian et al, and tCMA has been shown to be useful in follow up as its decline has been associated with better prognosis.<sup>127,132</sup> SUVmax was also significantly higher in patients with CV events during follow up. Anyhow, its independent predictive role is questionable as SUVmax was higher with patients with RV-uptake.

The role of RV uptake as a predictor of adverse event is logical. As all patients with uptake in the right ventricle also had left ventricular uptake, they had a more widespread myocardial inflammation. This in turn can cause extensive damage with perilous consequences. The situation could be compared to coronary artery disease: blockade of a distal branch of a coronary artery may produce a small infarct but is normally not lethal. However, when there is a proximal blockade of a coronary artery

the infarcted area will be large and is likely to cause cardiac insufficiency and severe arrhythmias. Similarly, extensive inflammation is likely to cause extensive scarring followed by contractile dysfunction and a tendency to arrhythmias.

Few of the studies mentioned previously report that LGE is a stronger predictor of events compared to active inflammation shown by FDG-uptake. One could speculate the following logical explanation: Sarcoid inflammation is known to have different possible courses. In some patients, the inflammatory process is downregulated by anti-inflammatory cytokines whereas in others the inflammation persists. When we observe an active inflammation in PET, the patient may be on either of those paths. When we see LGE as a marker of scarring in CMR, we know that in that patient the inflammation has persisted long enough to cause damage and scarring. LGE can be seen as a marker of damage, whereas FDG-uptake is (at least in patients studied early in the course of their disease) a marker of possible future damage.

## 7 CONCLUSION

Our results add to the growing base of evidence for the important role of FDG-PET in the workup of suspected cardiac sarcoidosis.

We identified a group of patients - females with advanced AV-block - that has a high frequency of pathological PET-findings. In this group, FDG-PET is likely to affect treatment decisions by demonstrating active myocardial inflammation. Patients with a history of ventricular tachyarrhythmias had high frequency of right ventricular FDG-uptake that was linked to adverse cardiovascular event. In these patients, FDG-PET may be useful in deciding whether to implant an ICD to the patient.

Recently developed ECG parameters such as septal remodeling and inferolateral remodeling were linked to pathological PET-findings. Our results are preliminary but these ECG parameters may prove valuable in the initial workup of patients with suspected cardiac sarcoidosis.

Right ventricular involvement was more frequent in patients with systemic sarcoidosis defined by presence of pathological FDG uptake foci outside of the heart. Endomyocardial biopsy verifying sarcoidosis was obtained from seven patients. Six of these patients had pathological myocardial uptake, but due to small amount of these patients the association between pathological myocardial PET-findings and positive EMB was not significant. However, biopsy verification of sarcoidosis was obtained more often from a tissue sample obtained from sites other than the heart. Extracardiac FDG uptake foci in PET were significantly linked to tissue biopsy indicating sarcoidosis.

Finally, right ventricular FDG-uptake and high total cardiac metabolic activity were linked to high risk of adverse cardiovascular event during follow-up. These findings have valuable use in the risk stratification of patients suspected of having CS.

American consensus statement on the use of FDG-PET in CS suggests performing FDG-PET in patients with unexplained AV-block and VT, and our findings provide further proof for the utility of FDG-PET in these patient groups. Furthermore, our results add to a growing base of evidence on the prognostic value of FDG-PET in suspected CS.





## REFERENCES

1. Gideon NM, Mannino DM. Sarcoidosis mortality in the united states 1979-1991: An analysis of multiple-cause mortality data. *Am J Med.* 1996;100(4):423-427.
2. Kandolin R, Lehtonen J, Graner M, et al. Diagnosing isolated cardiac sarcoidosis. *J Intern Med.* 2011;270(5):461-468.
3. Kandolin R, Lehtonen J, Airaksinen J, et al. Cardiac sarcoidosis: Epidemiology, characteristics, and outcome over 25 years in a nationwide study. *Circulation.* 2015;131(7):624-632.
4. Nery PB, Mc Ardle BA, Redpath CJ, et al. Prevalence of cardiac sarcoidosis in patients presenting with monomorphic ventricular tachycardia. *Pacing Clin Electrophysiol.* 2014;37(3):364-374.
5. White J, Sutton T, Kerr A. Isolated primary cardiac sarcoidosis: MRI diagnosis and monitoring of treatment response with cardiac enzymes. *Circ Heart Fail.* 2010;3(6):e28-9.
6. Galati G, Leone O, Rapezzi C. The difficult diagnosis of isolated cardiac sarcoidosis: Usefulness of an integrated MRI and PET approach. *Heart.* 2014;100(1):89-90.

7. Yazaki Y, Isobe M, Hiroe M, et al. Prognostic determinants of long-term survival in Japanese patients with cardiac sarcoidosis treated with prednisone. *Am J Cardiol.* 2001;88(9):1006-1010.
8. Ratner S, Fenoglio J, Ursell P. Utility of endomyocardial biopsy in the diagnosis of cardiac sarcoidosis. *Chest.* 1986(90):528.
9. Ardehali H, Howard DL, Hariri A, et al. A positive endomyocardial biopsy result for sarcoid is associated with poor prognosis in patients with initially unexplained cardiomyopathy. *Am Heart J.* 2005;150(3):459-463.
10. Pauwels EK, Ribeiro MJ, Stoot JH, McCready VR, Bourguignon M, Maziere B. FDG accumulation and tumor biology. *Nucl Med Biol.* 1998;25(4):317-322.
11. Mochizuki T, Tsukamoto E, Kuge Y, et al. FDG uptake and glucose transporter subtype expressions in experimental tumor and inflammation models. *J Nucl Med.* 2001;42(10):1551-1555.
12. Kubota R, Yamada S, Kubota K, Ishiwata K, Tamahashi N, Ido T. Intratumoral distribution of fluorine-18-fluorodeoxyglucose in vivo: High accumulation in macrophages and granulation tissues studied by microautoradiography. *J Nucl Med.* 1992;33(11):1972-1980.
13. Baughman RP, Field S, Costabel U, et al. Sarcoidosis in America. analysis based on health care use. *Ann Am Thorac Soc.* 2016;13(8):1244-1252.

14. Yazaki Y, Isobe M, Hiroe M, et al. Prognostic determinants of long-term survival in japanese patients with cardiac sarcoidosis treated with prednisone. *Am J Cardiol.* 2001;88(9):1006-1010.
15. Pietinalho A, Hiraga Y, Hosoda Y, Lofroos AB, Yamaguchi M, Selroos O. The frequency of sarcoidosis in finland and hokkaido, japan. A comparative epidemiological study. *Sarcoidosis.* 1995;12(1):61-67.
16. Valeyre D, Prasse A, Nunes H, Uzunhan Y, Brillet PY, Muller-Quernheim J. Sarcoidosis. *Lancet.* 2014;383(9923):1155-1167.
17. Sverrild A, Backer V, Kyvik KO, et al. Heredity in sarcoidosis: A registry-based twin study. *Thorax.* 2008;63(10):894-896.
18. Valentonyte R, Hampe J, Huse K, et al. Sarcoidosis is associated with a truncating splice site mutation in BTNL2. *Nat Genet.* 2005;37(4):357-364.
19. Berlin M, Fogdell-Hahn A, Olerup O, Eklund A, Grunewald J. HLA-DR predicts the prognosis in scandinavian patients with pulmonary sarcoidosis. *Am J Respir Crit Care Med.* 1997;156(5):1601-1605.
20. Rossman MD, Thompson B, Frederick M, et al. HLA-DRB1\*1101: A significant risk factor for sarcoidosis in blacks and whites. *Am J Hum Genet.* 2003;73(4):720-735.

21. Veltkamp M, van Moorsel CH, Rijkers GT, Ruven HJ, Grutters JC. Genetic variation in the toll-like receptor gene cluster (TLR10-TLR1-TLR6) influences disease course in sarcoidosis. *Tissue Antigens*. 2012;79(1):25-32.
22. Deubelbeiss U, Gemperli A, Schindler C, Baty F, Brutsche MH. Prevalence of sarcoidosis in switzerland is associated with environmental factors. *Eur Respir J*. 2010;35(5):1088-1097.
23. Newman LS, Rose CS, Bresnitz EA, et al. A case control etiologic study of sarcoidosis: Environmental and occupational risk factors. *Am J Respir Crit Care Med*. 2004;170(12):1324-1330.
24. Chen ES, Moller DR. Etiology of sarcoidosis. *Clin Chest Med*. 2008;29(3):365-77, vii.
25. Chen ES, Song Z, Willett MH, et al. Serum amyloid A regulates granulomatous inflammation in sarcoidosis through toll-like receptor-2. *Am J Respir Crit Care Med*. 2010;181(4):360-373.
26. Ishige I, Usui Y, Takemura T, Eishi Y. Quantitative PCR of mycobacterial and propionibacterial DNA in lymph nodes of japanese patients with sarcoidosis. *Lancet*. 1999;354(9173):120-123.
27. Zissel G, Prasse A, Muller-Quernheim J. Immunologic response of sarcoidosis. *Semin Respir Crit Care Med*. 2010;31(4):390-403.

28. Miyara M, Amoura Z, Parizot C, et al. The immune paradox of sarcoidosis and regulatory T cells. *J Exp Med.* 2006;203(2):359-370.
29. Zissel G, Homolka J, Schlaak J, Schlaak M, Muller-Quernheim J. Anti-inflammatory cytokine release by alveolar macrophages in pulmonary sarcoidosis. *Am J Respir Crit Care Med.* 1996;154(3 Pt 1):713-719.
30. Hulten E, Aslam S, Osborne M, Abbasi S, Bittencourt MS, Blankstein R. Cardiac sarcoidosis-state of the art review. *Cardiovasc Diagn Ther.* 2016;6(1):50-63.
31. Houston BA, Mukherjee M. Cardiac sarcoidosis: Clinical manifestations, imaging characteristics, and therapeutic approach. *Clin Med Insights Cardiol.* 2014;8(Suppl 1):31-37.
32. Nery PB, Beanlands RS, Nair GM, et al. Atrioventricular block as the initial manifestation of cardiac sarcoidosis in middle-aged adults. *J Cardiovasc Electrophysiol.* 2014;25(8):875-881.
33. Kandolin R, Lehtonen J, Kupari M. Cardiac sarcoidosis and giant cell myocarditis as causes of atrioventricular block in young and middle-aged adults. *Circ Arrhythm Electrophysiol.* 2011;4(3):303-309.
34. Uusimaa P, Ylitalo K, Anttonen O, et al. Ventricular tachyarrhythmia as a primary presentation of sarcoidosis. *Europace.* 2008;10(6):760-766.

35. Koplan BA, Soejima K, Baughman K, Epstein LM, Stevenson WG. Refractory ventricular tachycardia secondary to cardiac sarcoid: Electrophysiologic characteristics, mapping, and ablation. *Heart Rhythm*. 2006;3(8):924-929.
36. Rybicki BA, Major M, Popovich J, Jr, Maliarik MJ, Iannuzzi MC. Racial differences in sarcoidosis incidence: A 5-year study in a health maintenance organization. *Am J Epidemiol*. 1997;145(3):234-241.
37. Milman N, Selroos O. Pulmonary sarcoidosis in the nordic countries 1950-1982. epidemiology and clinical picture. *Sarcoidosis*. 1990;7(1):50-57.
38. Perry A, Vuitch F. Causes of death in patients with sarcoidosis. A morphologic study of 38 autopsies with clinicopathologic correlations. *Arch Pathol Lab Med*. 1995;119(2):167-172.
39. Silverman KJ, Hutchins GM, Bulkley BH. Cardiac sarcoid: A clinicopathologic study of 84 unselected patients with systemic sarcoidosis. *Circulation*. 1978;58(6):1204-1211.
40. Martusewicz-Boros MM, Boros PW, Wiatr E, Zych J, Piotrowska-Kownacka D, Roszkowski-Sliz K. Prevalence of cardiac sarcoidosis in white population: A case-control study: Proposal for a novel risk index based on commonly available tests. *Medicine (Baltimore)*. 2016;95(32):e4518.

41. Ungprasert P, Carmona EM, Utz JP, Ryu JH, Crowson CS, Matteson EL. Epidemiology of sarcoidosis 1946-2013: A population-based study. *Mayo Clin Proc.* 2016;91(2):183-188.
42. Patel N, Kalra R, Doshi R, et al. Hospitalization rates, prevalence of cardiovascular manifestations, and outcomes associated with sarcoidosis in the united states. *J Am Heart Assoc.* 2018;7(2):10.1161/JAHA.117.007844.
43. Okada DR, Bravo PE, Vita T, et al. Isolated cardiac sarcoidosis: A focused review of an under-recognized entity. *J Nucl Cardiol.* 2018;25(4):1136-1146.
44. Diagnostic standard and guidelines for sarcoidosis. *Jpn J Sarcoidosis and Granulomatous Disorders.* 2007;27:89.
45. Hiraga H, Iwai K. Guidelines for diagnosis of cardiac sarcoidosis: Study report on diffuse pulmonary disease (in japanese). . 1993.
46. The Japanese Circulation Society. Guidelines for the diagnosis and treatment of cardiac sarcoidosis. . 2017.
47. Birnie DH, Sauer WH, Bogun F, et al. HRS expert consensus statement on the diagnosis and management of arrhythmias associated with cardiac sarcoidosis. *Heart Rhythm.* 2014;11(7):1305-1323.

48. Roberts WC, McAllister HA, Jr, Ferrans VJ. Sarcoidosis of the heart. A clinicopathologic study of 35 necropsy patients (group 1) and review of 78 previously described necropsy patients (group 11). *Am J Med.* 1977;63(1):86-108.
49. Simonen P, Lehtonen J, Kupari M. Long-term outcome in probable versus absolute cardiac sarcoidosis. *Am J Cardiol.* 2019;123(4):674-678.
50. Chiu CZ, Nakatani S, Zhang G, et al. Prevention of left ventricular remodeling by long-term corticosteroid therapy in patients with cardiac sarcoidosis. *Am J Cardiol.* 2005;95(1):143-146.
51. Betensky BP, Tschabrunn CM, Zado ES, et al. Long-term follow-up of patients with cardiac sarcoidosis and implantable cardioverter-defibrillators. *Heart Rhythm.* 2012;9(6):884-891.
52. Kron J, Sauer W, Schuller J, et al. Efficacy and safety of implantable cardiac defibrillators for treatment of ventricular arrhythmias in patients with cardiac sarcoidosis. *Europace.* 2013;15(3):347-354.
53. Schuller JL, Zipse M, Crawford T, et al. Implantable cardioverter defibrillator therapy in patients with cardiac sarcoidosis. *J Cardiovasc Electrophysiol.* 2012;23(9):925-929.



54. Sadek MM, Yung D, Birnie DH, Beanlands RS, Nery PB. Corticosteroid therapy for cardiac sarcoidosis: A systematic review. *Can J Cardiol.* 2013;29(9):1034-1041.
55. Padala SK, Peaslee S, Sidhu MS, Steckman DA, Judson MA. Impact of early initiation of corticosteroid therapy on cardiac function and rhythm in patients with cardiac sarcoidosis. *Int J Cardiol.* 2017;227:565-570.
56. Winters SL, Cohen M, Greenberg S, et al. Sustained ventricular tachycardia associated with sarcoidosis: Assessment of the underlying cardiac anatomy and the prospective utility of programmed ventricular stimulation, drug therapy and an implantable antitachycardia device. *J Am Coll Cardiol.* 1991;18(4):937-943.
57. Jelic D, Joel B, Good E, et al. Role of radiofrequency catheter ablation of ventricular tachycardia in cardiac sarcoidosis: Report from a multicenter registry. *Heart Rhythm.* 2009;6(2):189-195.
58. Koplan BA, Soejima K, Baughman K, Epstein LM, Stevenson WG. Refractory ventricular tachycardia secondary to cardiac sarcoid: Electrophysiologic characteristics, mapping, and ablation. *Heart Rhythm.* 2006;3(8):924-929.
59. Schuster EH, Conrad G, Morris F, et al. Systemic sarcoidosis and electrocardiographic conduction abnormalities. electrophysiologic evaluation of two patients. *Chest.* 1980;78(4):601-604.

60. Stein E, Jackler I, Stimmel B, Stein W, Siltzbach LE. Asymptomatic electrocardiographic alterations in sarcoidosis. *Am Heart J*. 1973;86(4):474-477.
61. Chapelon-Abric C, de Zuttere D, Duhaut P, et al. Cardiac sarcoidosis: A retrospective study of 41 cases. *Medicine (Baltimore)*. 2004;83(6):315-334.
62. Suzuki T, Kanda T, Kubota S, Imai S, Murata K. Holter monitoring as a noninvasive indicator of cardiac involvement in sarcoidosis. *Chest*. 1994;106(4):1021-1024.
63. Homsy M, Alsayed L, Safadi B, Mahenthiran J, Das MK. Fragmented QRS complexes on 12-lead ECG: A marker of cardiac sarcoidosis as detected by gadolinium cardiac magnetic resonance imaging. *Ann Noninvasive Electrocardiol*. 2009;14(4):319-326.
64. Das MK, Khan B, Jacob S, Kumar A, Mahenthiran J. Significance of a fragmented QRS complex versus a Q wave in patients with coronary artery disease. *Circulation*. 2006;113(21):2495-2501.
65. Roukoz H, Shah M, Masilamani LJ, et al. fQRS as a marker of granulomatous disease in patients presenting with ventricular tachycardia and normal left ventricular ejection fraction. *Indian Heart J*. 2015;67(3):222-226.

66. Schuller JL, Olson MD, Zipse MM, et al. Electrocardiographic characteristics in patients with pulmonary sarcoidosis indicating cardiac involvement. *J Cardiovasc Electrophysiol.* 2011;22(11):1243-1248.
67. Kim JS, Judson MA, Donnino R, et al. Cardiac sarcoidosis. *Am Heart J.* 2009;157(1):9-21.
68. Angomachalelis N, Hourzamanis A, Vamvalis C, Gavrielides A. Doppler echocardiographic evaluation of left ventricular diastolic function in patients with systemic sarcoidosis. *Postgrad Med J.* 1992;68 Suppl 1:S52-6.
69. Burstow DJ, Tajik AJ, Bailey KR, DeRemee RA, Taliercio CP. Two-dimensional echocardiographic findings in systemic sarcoidosis. *Am J Cardiol.* 1989;63(7):478-482.
70. Chiu CZ, Nakatani S, Yamagishi M, Miyatake K, Cheng J. Echocardiographic manifestations in patients with cardiac sarcoidosis. *J Med Ultrasound.* 2002;10:135.
71. Ishikawa T, Kondoh H, Nakagawa S, Koiwaya Y, Tanaka K. Steroid therapy in cardiac sarcoidosis. increased left ventricular contractility concomitant with electrocardiographic improvement after prednisolone. *Chest.* 1984;85(3):445-447.
72. Ferreira VM, Piechnik SK, Dall'Armellina E, et al. T(1) mapping for the diagnosis of acute myocarditis using CMR: Comparison to T2-weighted and late gadolinium enhanced imaging. *JACC Cardiovasc Imaging.* 2013;6(10):1048-1058.

73. Ferreira VM, Piechnik SK, Robson MD, Neubauer S, Karamitsos TD. Myocardial tissue characterization by magnetic resonance imaging: Novel applications of T1 and T2 mapping. *J Thorac Imaging*. 2014;29(3):147-154.
74. Vignaux O. Cardiac sarcoidosis: Spectrum of MRI features. *AJR Am J Roentgenol*. 2005;184(1):249-254.
75. Crouser ED, Ono C, Tran T, He X, Raman SV. Improved detection of cardiac sarcoidosis using magnetic resonance with myocardial T2 mapping. *Am J Respir Crit Care Med*. 2014;189(1):109-112.
76. Crouser ED, Ruden E, Julian MW, Raman SV. Resolution of abnormal cardiac MRI T2 signal following immune suppression for cardiac sarcoidosis. *J Investig Med*. 2016;64(6):1148-1150.
77. Komada T, Suzuki K, Ishiguchi H, et al. Magnetic resonance imaging of cardiac sarcoidosis: An evaluation of the cardiac segments and layers that exhibit late gadolinium enhancement. *Nagoya J Med Sci*. 2016;78(4):437-446.
78. Shimada T, Shimada K, Sakane T, et al. Diagnosis of cardiac sarcoidosis and evaluation of the effects of steroid therapy by gadolinium-DTPA-enhanced magnetic resonance imaging. *Am J Med*. 2001;110(7):520-527.

79. Smedema JP, Snoep G, van Kroonenburgh MP, et al. Evaluation of the accuracy of gadolinium-enhanced cardiovascular magnetic resonance in the diagnosis of cardiac sarcoidosis. *J Am Coll Cardiol*. 2005;45(10):1683-1690.
80. Greulich S, Deluigi CC, Gloekler S, et al. CMR imaging predicts death and other adverse events in suspected cardiac sarcoidosis. *JACC Cardiovasc Imaging*. 2013;6(4):501-511.
81. Smedema JP, van Geuns RJ, Ector J, Heidbuchel H, Ainslie G, Crijns HJGM. Right ventricular involvement and the extent of left ventricular enhancement with magnetic resonance predict adverse outcome in pulmonary sarcoidosis. *ESC Heart Fail*. 2018;5(1):157-171.
82. Nagai T, Kohsaka S, Okuda S, Anzai T, Asano K, Fukuda K. Incidence and prognostic significance of myocardial late gadolinium enhancement in patients with sarcoidosis without cardiac manifestation. *Chest*. 2014;146(4):1064-1072.
83. Kouranos V, Tzelepis GE, Rapti A, et al. Complementary role of CMR to conventional screening in the diagnosis and prognosis of cardiac sarcoidosis. *JACC Cardiovasc Imaging*. 2017;10(12):1437-1447.
84. Le Guludec D, Menad F, Faraggi M, Weinmann P, Battesti JP, Valeyre D. Myocardial sarcoidosis. clinical value of technetium-99m sestamibi tomoscintigraphy. *Chest*. 1994;106(6):1675-1682.

85. Eguchi M, Tsuchihashi K, Hotta D, et al. Technetium-99m sestamibi/tetrofosmin myocardial perfusion scanning in cardiac and noncardiac sarcoidosis. *Cardiology*. 2000;94(3):193-199.
86. Kudoh H, Fujiwara S, Shiotani H, Kawai H, Hirata K. Myocardial washout of 99mTc-tetrofosmin and response to steroid therapy in patients with cardiac sarcoidosis. *Ann Nucl Med*. 2010;24(5):379-385.
87. Chareonthaitawee P, Beanlands RS, Chen W, et al. Joint SNMMI-ASNC expert consensus document on the role of 18F-FDG PET/CT in cardiac sarcoid detection and therapy monitoring. *J Nucl Cardiol*. 2017.
88. Bengel FM, Higuchi T, Javadi MS, Lautamaki R. Cardiac positron emission tomography. *J Am Coll Cardiol*. 2009;54(1):1-15.
89. Lalonde L, Ziadi MC, Beanlands R. Cardiac positron emission tomography: Current clinical practice. *Cardiol Clin*. 2009;27(2):237-55, Table of Contents.
90. Lopaschuk GD, Stanley WC. Glucose metabolism in the ischemic heart. *Circulation*. 1997;95(2):313-315.
91. Inglese E, Leva L, Matheoud R, et al. Spatial and temporal heterogeneity of regional myocardial uptake in patients without heart disease under fasting conditions on repeated whole-body 18F-FDG PET/CT. *J Nucl Med*. 2007;48(10):1662-1669.

92. Tiwari BP, Kand P. Myocardial uptake of F-18-fluorodeoxyglucose in whole body positron emission tomography studies. *Indian J Nucl Med.* 2012;27(2):69-72.
93. de Groot M, Meeuwis AP, Kok PJ, Corstens FH, Oyen WJ. Influence of blood glucose level, age and fasting period on non-pathological FDG uptake in heart and gut. *Eur J Nucl Med Mol Imaging.* 2005;32(1):98-101.
94. Osborne MT, Hulten EA, Murthy VL, et al. Patient preparation for cardiac fluorine-18 fluorodeoxyglucose positron emission tomography imaging of inflammation. *J Nucl Cardiol.* 2017;24(1):86-99.
95. Masuda A, Naya M, Manabe O, et al. Administration of unfractionated heparin with prolonged fasting could reduce physiological 18F-fluorodeoxyglucose uptake in the heart. *Acta Radiol.* 2016;57(6):661-668.
96. Williams G, Kolodny GM. Suppression of myocardial 18F-FDG uptake by preparing patients with a high-fat, low-carbohydrate diet. *AJR Am J Roentgenol.* 2008;190(2):W151-6.
97. Harisankar CN, Mittal BR, Agrawal KL, Abrar ML, Bhattacharya A. Utility of high fat and low carbohydrate diet in suppressing myocardial FDG uptake. *J Nucl Cardiol.* 2011;18(5):926-936.
98. Cheng VY, Slomka PJ, Ahlen M, Thomson LE, Waxman AD, Berman DS. Impact of carbohydrate restriction with and without fatty acid loading on

myocardial 18F-FDG uptake during PET: A randomized controlled trial. *J Nucl Cardiol.* 2010;17(2):286-291.

99. Asmal AC, Leary WP, Thandroyen F, Botha J, Wattrus S. A dose-response study of the anticoagulant and lipolytic activities of heparin in normal subjects. *Br J Clin Pharmacol.* 1979;7(5):531-533.

100. Manabe O, Yoshinaga K, Ohira H, et al. The effects of 18-h fasting with low-carbohydrate diet preparation on suppressed physiological myocardial (18)F-fluorodeoxyglucose (FDG) uptake and possible minimal effects of unfractionated heparin use in patients with suspected cardiac involvement sarcoidosis. *J Nucl Cardiol.* 2016;23(2):244-252.

101. Skali H, Schulman AR, Dorbala S. 18F-FDG PET/CT for the assessment of myocardial sarcoidosis. *Curr Cardiol Rep.* 2013;15(4):352.

102. Ishimaru S, Tsujino I, Takei T, et al. Focal uptake on 18F-fluoro-2-deoxyglucose positron emission tomography images indicates cardiac involvement of sarcoidosis. *Eur Heart J.* 2005;26(15):1538-1543.

103. Yamagishi H, Shirai N, Takagi M, et al. Identification of cardiac sarcoidosis with (13)N-NH(3)/(18)F-FDG PET. *J Nucl Med.* 2003;44(7):1030-1036.



104. Mehta D, Lubitz SA, Frankel Z, et al. Cardiac involvement in patients with sarcoidosis: Diagnostic and prognostic value of outpatient testing. *Chest*. 2008;133(6):1426-1435.
105. Okumura W, Iwasaki T, Toyama T, et al. Usefulness of fasting 18F-FDG PET in identification of cardiac sarcoidosis. *J Nucl Med*. 2004;45(12):1989-1998.
106. Partington SL, Kwong RY, Dorbala S. Multimodality imaging in the assessment of myocardial viability. *Heart Fail Rev*. 2011;16(4):381-395.
107. Blankstein R, Waller AH. Evaluation of known or suspected cardiac sarcoidosis. *Circ Cardiovasc Imaging*. 2016;9(3):e000867.
108. Sobic-Saranovic D, Artiko V, Obradovic V. FDG PET imaging in sarcoidosis. *Semin Nucl Med*. 2013;43(6):404-411.
109. Ishiyama M, Soine LA, Vesselle HJ. Semi-quantitative metabolic values on FDG PET/CT including extracardiac sites of disease as a predictor of treatment course in patients with cardiac sarcoidosis. *EJNMMI Res*. 2017;7(1):67-017-0315-y.
110. Simonen P, Lehtonen J, Kandolin R, et al. F-18-fluorodeoxyglucose positron emission tomography-guided sampling of mediastinal lymph nodes in the diagnosis of cardiac sarcoidosis. *Am J Cardiol*. 2015;116(10):1581-1585.

111. Blankstein R, Osborne M, Naya M, et al. Cardiac positron emission tomography enhances prognostic assessments of patients with suspected cardiac sarcoidosis. *J Am Coll Cardiol.* 2014;63(4):329-336.
112. Patel DC, Gunasekaran SS, Goettl C, Sweiss NJ, Lu Y. FDG PET-CT findings of extra-thoracic sarcoid are associated with cardiac sarcoid: A rationale for using FGD PET-CT for cardiac sarcoid evaluation. *J Nucl Cardiol.* 2017.
113. Brudin LH, Valind SO, Rhodes CG, et al. Fluorine-18 deoxyglucose uptake in sarcoidosis measured with positron emission tomography. *Eur J Nucl Med.* 1994;21(4):297-305.
114. Lewis PJ, Salama A. Uptake of fluorine-18-fluorodeoxyglucose in sarcoidosis. *J Nucl Med.* 1994;35(10):1647-1649.
115. Youssef G, Leung E, Mylonas I, et al. The use of 18F-FDG PET in the diagnosis of cardiac sarcoidosis: A systematic review and metaanalysis including the ontario experience. *J Nucl Med.* 2012;53(2):241-248.
116. Ambrosini V, Zompatori M, Fasano L, et al. (18)F-FDG PET/CT for the assessment of disease extension and activity in patients with sarcoidosis: Results of a preliminary prospective study. *Clin Nucl Med.* 2013;38(4):e171-7.

117. Blankstein R, Osborne M, Naya M, et al. Cardiac positron emission tomography enhances prognostic assessments of patients with suspected cardiac sarcoidosis. *J Am Coll Cardiol*. 2014;63(4):329-336.
118. Gormsen LC, Haraldsen A, Kramer S, Dias AH, Kim WY, Borghammer P. A dual tracer (68)ga-DOTANOC PET/CT and (18)F-FDG PET/CT pilot study for detection of cardiac sarcoidosis. *EJNMMI Res*. 2016;6(1):52-016-0207-6. Epub 2016 Jun 17.
119. Tahara N, Tahara A, Nitta Y, et al. Heterogeneous myocardial FDG uptake and the disease activity in cardiac sarcoidosis. *JACC Cardiovasc Imaging*. 2010;3(12):1219-1228.
120. Yokoyama R, Miyagawa M, Okayama H, et al. Quantitative analysis of myocardial 18F-fluorodeoxyglucose uptake by PET/CT for detection of cardiac sarcoidosis. *Int J Cardiol*. 2015;195:180-187.
121. Patel MR, Cawley PJ, Heitner JF, et al. Detection of myocardial damage in patients with sarcoidosis. *Circulation*. 2009;120(20):1969-1977.
122. Ohira H, Tsujino I, Ishimaru S, et al. Myocardial imaging with 18F-fluoro-2-deoxyglucose positron emission tomography and magnetic resonance imaging in sarcoidosis. *Eur J Nucl Med Mol Imaging*. 2008;35(5):933-941.

123. Ohira H, Birnie DH, Pena E, et al. Comparison of (18)F-fluorodeoxyglucose positron emission tomography (FDG PET) and cardiac magnetic resonance (CMR) in corticosteroid-naive patients with conduction system disease due to cardiac sarcoidosis. *Eur J Nucl Med Mol Imaging*. 2016;43(2):259-269.
124. Manabe O, Ohira H, Yoshinaga K, et al. Elevated (18)F-fluorodeoxyglucose uptake in the interventricular septum is associated with atrioventricular block in patients with suspected cardiac involvement sarcoidosis. *Eur J Nucl Med Mol Imaging*. 2013;40(10):1558-1566.
125. Tung R, Bauer B, Schelbert H, et al. Incidence of abnormal positron emission tomography in patients with unexplained cardiomyopathy and ventricular arrhythmias: The potential role of occult inflammation in arrhythmogenesis. *Heart Rhythm*. 2015;12(12):2488-2498.
126. Kim SJ, Pak K, Kim K. Diagnostic performance of F-18 FDG PET for detection of cardiac sarcoidosis; A systematic review and meta-analysis. *J Nucl Cardiol*. 2019.
127. Ahmadian A, Brogan A, Berman J, et al. Quantitative interpretation of FDG PET/CT with myocardial perfusion imaging increases diagnostic information in the evaluation of cardiac sarcoidosis. *J Nucl Cardiol*. 2014;21(5):925-939.

128. Bravo PE, Raghu G, Rosenthal DG, et al. Risk assessment of patients with clinical manifestations of cardiac sarcoidosis with positron emission tomography and magnetic resonance imaging. *International Journal of Cardiology*. 2017;241:457-462. doi: <https://doi.org/10.1016/j.ijcard.2017.03.033>.
129. Wicks EC, Menezes LJ, Barnes A, et al. Diagnostic accuracy and prognostic value of simultaneous hybrid 18F-fluorodeoxyglucose positron emission tomography/magnetic resonance imaging in cardiac sarcoidosis. *Eur Heart J Cardiovasc Imaging*. 2018;19(7):757-767.
130. Sperry BW, Tamarappoo BK, Oldan JD, et al. Prognostic impact of extent, severity, and heterogeneity of abnormalities on (18)F-FDG PET scans for suspected cardiac sarcoidosis. *JACC Cardiovasc Imaging*. 2018;11(2 Pt 2):336-345.
131. Flores RJ, Flaherty KR, Jin Z, Bokhari S. The prognostic value of quantitating and localizing F-18 FDG uptake in cardiac sarcoidosis. *J Nucl Cardiol*. 2018.
132. Muser D, Santangeli P, Castro SA, et al. Prognostic role of serial quantitative evaluation of (18)F-fluorodeoxyglucose uptake by PET/CT in patients with cardiac sarcoidosis presenting with ventricular tachycardia. *Eur J Nucl Med Mol Imaging*. 2018;45(8):1394-1404.

133. ten Bokum AM, Hofland LJ, de Jong G, et al. Immunohistochemical localization of somatostatin receptor sst2A in sarcoid granulomas. *Eur J Clin Invest.* 1999;29(7):630-636.
134. Gormsen LC, Haraldsen A, Kramer S, Dias AH, Kim WY, Borghammer P. A dual tracer (68)ga-DOTANOC PET/CT and (18)F-FDG PET/CT pilot study for detection of cardiac sarcoidosis. *EJNMMI Res.* 2016;6(1):52-016-0207-6. Epub 2016 Jun 17.
135. Nobashi T, Nakamoto Y, Kubo T, et al. The utility of PET/CT with (68)ga-DOTATOC in sarcoidosis: Comparison with (67)ga-scintigraphy. *Ann Nucl Med.* 2016;30(8):544-552.
136. Lapa C, Reiter T, Kircher M, et al. Somatostatin receptor based PET/CT in patients with the suspicion of cardiac sarcoidosis: An initial comparison to cardiac MRI. *Oncotarget.* 2016;7(47):77807-77814.
137. Omote K, Naya M, Koyanagawa K, et al. (18)F-FDG uptake of the right ventricle is an important predictor of histopathologic diagnosis by endomyocardial biopsy in patients with cardiac sarcoidosis. *J Nucl Cardiol.* 2019.
138. SOKOLOW M, LYON TP. The ventricular complex in left ventricular hypertrophy as obtained by unipolar precordial and limb leads. *Am Heart J.* 1949;37(2):161-186.

139. Okin PM, Roman MJ, Devereux RB, Kligfield P. Electrocardiographic identification of increased left ventricular mass by simple voltage-duration products. *J Am Coll Cardiol.* 1995;25(2):417-423.
140. Okin PM, Devereux RB, Nieminen MS, et al. Relationship of the electrocardiographic strain pattern to left ventricular structure and function in hypertensive patients: The LIFE study. losartan intervention for end point. *J Am Coll Cardiol.* 2001;38(2):514-520.
141. Lakdawala NK, Thune JJ, Maron BJ, et al. Electrocardiographic features of sarcomere mutation carriers with and without clinically overt hypertrophic cardiomyopathy. *Am J Cardiol.* 2011;108(11):1606-1613.
142. Konno T, Fujino N, Hayashi K, et al. Differences in the diagnostic value of various criteria of negative T waves for hypertrophic cardiomyopathy based on a molecular genetic diagnosis. *Clin Sci (Lond).* 2007;112(11):577-582.
143. Ollila L, Nikus K, Holmstrom M, et al. Clinical disease presentation and ECG characteristics of LMNA mutation carriers. *Open Heart.* 2017;4(1):e000474-2016-000474. eCollection 2017.
144. Zema MJ, Kligfield P. Electrocardiographic poor R wave progression. I: Correlation with the frank vectorcardiogram. *J Electrocardiol.* 1979;12(1):3-10.

145. Dumont CA, Monserrat L, Soler R, et al. Interpretation of electrocardiographic abnormalities in hypertrophic cardiomyopathy with cardiac magnetic resonance. *Eur Heart J*. 2006;27(14):1725-1731.
146. Gromsen L, Haraldsen A, Kramer S, Dias A, Kim W, Borghammer P. A dual tracer (68)ga-DOTANOC PET/CT and (18)F-FDG PET/CT pilot study for detection of cardiac sarcoidosis. *European journal of nuclear medicine and molecular imaging research*. 2016;6(1):52.
147. Soussan M, Brillet PY, Nunes H, et al. Clinical value of a high-fat and low-carbohydrate diet before FDG-PET/CT for evaluation of patients with suspected cardiac sarcoidosis. *J Nucl Cardiol*. 2013;20(1):120-127.
148. Yokoyama R, Miyagawa M, Okayama H, et al. Quantitative analysis of myocardial 18F-fluorodeoxyglucose uptake by PET/CT for detection of cardiac sarcoidosis. *Int J Cardiol*. 2015;195:180-187.
149. Momose M, Fukushima K, Kondo C, et al. Diagnosis and detection of myocardial injury in active cardiac sarcoidosis--significance of myocardial fatty acid metabolism and myocardial perfusion mismatch. *Circ J*. 2015;79(12):2669-2676.
150. Schildt JV, Loimaala AJ, Hippelainen ET, Ahonen AA. Heterogeneity of myocardial 2-[18F]fluoro-2-deoxy-D-glucose uptake is a typical feature in cardiac



sarcoidosis: A study of 231 patients. *Eur Heart J Cardiovasc Imaging*. 2018;19(3):293-298.

151. Sgard B, Brillet PY, Bouvry D, et al. Evaluation of FDG PET combined with cardiac MRI for the diagnosis and therapeutic monitoring of cardiac sarcoidosis. *Clin Radiol*. 2019;74(1):81.e9-81.e18.

152. Kumar S, Barbhaiya C, Nagashima K, et al. Ventricular tachycardia in cardiac sarcoidosis: Characterization of ventricular substrate and outcomes of catheter ablation. *Circ Arrhythm Electrophysiol*. 2015;8(1):87-93.

153. Patel DC, Gunasekaran SS, Goettl C, Sweiss NJ, Lu Y. FDG PET-CT findings of extra-thoracic sarcoid are associated with cardiac sarcoid: A rationale for using FGD PET-CT for cardiac sarcoid evaluation. *J Nucl Cardiol*. 2017.



# $^{18}\text{F}$ -FDG-PET in Finnish patients with clinical suspicion of cardiac sarcoidosis: Female sex and history of atrioventricular block increase the prevalence of positive PET findings

Heikki Tuominen, MD,<sup>a</sup> Atte Haarala, MD, PhD,<sup>a</sup> Antti Tikkakoski, MD,<sup>a</sup> Pasi Korkola, Lic.Tech,<sup>a</sup> Mika Kähönen, MD, PhD,<sup>b</sup> Kjell Nikus, MD, PhD,<sup>b,c</sup> and Kalle Sipilä, MD, PhD<sup>a</sup>

<sup>a</sup> Department of Clinical Physiology and Nuclear Medicine, Tampere University Hospital, Tampere, Finland

<sup>b</sup> Faculty of Medicine and Life Sciences, University of Tampere, Tampere, Finland

<sup>c</sup> Heart Center, Tampere University Hospital, Tampere, Finland

Received Feb 27, 2017; accepted Apr 30, 2017

doi:10.1007/s12350-017-0940-x

**Introduction.** Fluorodeoxyglucose positron emission tomography (FDG-PET) is a non-invasive imaging modality that has been shown to be a feasible method to demonstrate myocardial inflammation. The aim of this study was to identify the patients suspected of having cardiac sarcoidosis (CS), who are most likely to benefit from PET imaging.

**Materials and methods.** 137 patients suspected of having CS underwent a dedicated cardiac FDG-PET examination at Tampere University Hospital between August 2012 and September 2015. These examinations were retrospectively analyzed.

**Results.** 33 and 12 of the 137 patients had abnormal left and right ventricular (LV and RV) FDG-uptake, respectively. Abnormal LV-uptake and RV-uptake were significantly associated with female sex and a history of advanced AV-block ( $P < 0.05$ ). Abnormal RV-uptake was also associated with ventricular tachycardia and atrial fibrillation ( $P < 0.05$ ). 56% of the 27 female patients with a history of AV-block had a pathological PET finding compared to only 6% of the 49 male patients without a history of AV-block. There were 17 female patients with history of both AV-block and ventricular tachycardia, 71% of them had abnormal PET finding.

**Conclusions.** Abnormal FDG-PET findings were associated with female sex, AV-block, and arrhythmias in this clinical cohort. (J Nucl Cardiol 2019;26:394–400.)

**Key Words:**  $^{18}\text{F}$ -FDG-PET • Cardiac sarcoidosis • AV-block

Abbreviations		LV	Left ventricle
CS	Cardiac sarcoidosis	AV	Atrioventricular
EMB	Endomyocardial biopsy	VT	Ventricular tachycardia
FDG-	$^{18}\text{F}$ Fluorodeoxyglucose positron	MPI	Myocardial perfusion imaging
PET	emission tomography		
RV	Right ventricle		

**Electronic supplementary material** The online version of this article (doi:10.1007/s12350-017-0940-x) contains supplementary material, which is available to authorized users.

The authors of this article have provided a PowerPoint file, available for download at SpringerLink, which summarizes the contents of the paper and is free for re-use at meetings and presentations. Search for the article DOI on SpringerLink.com.

**Funding** This study was funded by Finska Läkaresällskapet.

Reprint requests: Heikki Tuominen, MD, Department of Clinical Physiology and Nuclear Medicine, Tampere University Hospital, 33520, Tampere, Finland; [heikki.tuominen@pshp.fi](mailto:heikki.tuominen@pshp.fi), [heikki.p.tuominen@gmail.com](mailto:heikki.p.tuominen@gmail.com)  
1071-3581/\$34.00

Copyright © 2017 American Society of Nuclear Cardiology.

---

**See related editorial, pp. 401–404**

---

## INTRODUCTION

Sarcoidosis is a multisystem granulomatous inflammatory disorder that can affect any organ system. The disease most commonly manifests in the lungs, typically as an asymptomatic hilar lymph node enlargement. The incidence of sarcoidosis differs between populations according to their genetic background.<sup>1</sup> In Europe, Scandinavians have the highest prevalence.<sup>2</sup> At autopsy, 27% of sarcoidosis patients showed cardiac involvement, which is the most frequent cause of sarcoidosis-related death.<sup>3–6</sup> In 40–50% of patients, cardiac sarcoidosis (CS) is diagnosed pre-mortem.<sup>7</sup> Due to the difficulty of diagnosing CS, epidemiological literature on the topic is sparse. In Finland, the prevalence of biopsy-confirmed CS is 2.2/100,000. In 65% of such cases, sarcoidosis is confined to the heart without clinical manifestations in other organs. The true incidence of CS is probably higher because all clinically diagnosed cases without biopsy verification were excluded.<sup>8</sup>

According to the guidelines issued in 2006 by the Japanese Ministry of Health and Welfare (JMHW) and revised by the Japan Society of Sarcoidosis and Other Granulomatous Disorders, CS can be diagnosed directly by verifying cardiac involvement on biopsy or indirectly via histologically proven extracardiac sarcoidosis combined with electrocardiographic and imaging findings.<sup>9</sup> The revised criteria were proposed by the Heart Rhythm Society in 2014.<sup>10</sup> According to both guidelines, CS can only be diagnosed if there is direct proof by endomyocardial biopsy (EMB) or previously diagnosed systemic sarcoidosis combined with clinical and imaging findings indicating cardiac involvement. Given that the sensitivity of EMB is low, a large share of patients with probable CS does not fulfill the current diagnostic criteria.<sup>11</sup> Thus, imaging is also needed in the diagnostic workup for CS. Criteria for diagnosing isolated CS relying partly on imaging were proposed by Isobe in 2015.<sup>12</sup>

Cardiac <sup>18</sup>fluorodeoxyglucose positron emission tomography/computerized tomography (<sup>18</sup>F-FDG-PET/CT) (later referred to as PET) has been used to identify active cardiac inflammation, with a sensitivity and specificity of 89% and 78%, respectively.<sup>13</sup> PET is not included in the JMHW guidelines. The demand for cardiac imaging has increased because it has been suggested that CS should be excluded in patients under the age of 55 with unexplained dilated cardiomyopathy, II or III degree atrioventricular (AV-) block, or persistent ventricular tachycardia (VT).<sup>10,11</sup> The aim of the present study was to evaluate the use of PET in the diagnostic workup of patients with symptoms suggestive

of CS in a clinical setting. Because PET imaging is relatively expensive and involves radiation, it is clinically relevant to identify the patients who are most likely to benefit from the diagnostic method and to recognize the factors that predict a diagnosis of CS.

## MATERIALS AND METHODS

### Study Population

We retrospectively screened all cardiac PET studies performed in the Tampere University Hospital from August 2012 to September 2015. We excluded PET studies if clinical indication was not CS suspicion, where the patient's clinical data could not be obtained or if the PET study was performed to follow up on previously diagnosed CS. Imaging studies were also excluded if the dedicated imaging protocol, as described below, was not followed precisely. Altogether, 137 PET examinations were analyzed for the present study. It is routine in our hospital to perform PET in the diagnostic workup of possible CS. The reason for a clinical suspicion of CS was one or more of the following: unexplained AV-block (N = 61), ventricular (N = 39), or supraventricular (N = 13) arrhythmia, unexplained dilated cardiomyopathy (N = 27), unexplained low ejection fraction in echocardiography (N = 46), other echocardiographic findings suggestive of CS (N = 53), or syncope (N = 27). Symptoms and clinical findings were considered unexplained by the cardiologist after routine studies including clinical examination, ECG, and echocardiography. Coronary angiography was performed in case of clinical suspicion of coronary artery disease.

### PET Imaging

All patients underwent an integrated PET/CT (Discovery STE 16, GE Healthcare, Milwaukee, WI, USA) examination. To minimize the physiological myocardial FDG-uptake, the patients were instructed not to consume any carbohydrates during the day before the imaging and were fasting for 12 hour before the FDG injection. The patients kept a food diary during the diet. The patients were also instructed to avoid heavy physical exercise to minimize FDG-uptake in skeletal muscle. The patient's height and weight were measured before the administration of the radiopharmaceutical, and their blood glucose level was tested to be <7 mmol/L. The PET/CT images were acquired approximately 60 minutes after the intravenous injection of FDG using the Medrad® Intego PET infusion system (Bayer Medical Care Inc., Indianola, PA, USA). The activity injected is currently based on the patient's weight (3–3.2 MBq/kg). However, the protocol was changed in 2013. Previously, patients were given a fixed dose of 370 MBq. The mean injected activity in our study population was 320 MBq (range 219–460 MBq). The imaging covered a volume of two bed positions around the myocardium approximately from the level of shoulders to the level of the gallbladder. The acquisition of the images was made in the three dimensional (3D) mode with a 128 × 128 matrix, 70 cm field of view (FOV), and 5 min per bed position. The PET

images were reconstructed using the 3D VUE Point reconstruction algorithm (GE Healthcare) with 2 iterations and 28 subsets. Gaussian 6.0 mm FWHM was used as the post-filter. The acquisition parameters of the CT scanner were as follows: tube voltage, 120 kV; tube current automatic exposure control range, 30–80 mA; noise index, 33 HU; rotation speed, 35 mm/rot; and pitch, 1.75:1. The CT images were reconstructed to slice thicknesses of 2.50 mm, with 1.25-mm intervals. The total examination time for the PET/CT was approximately 15 min. CT was used for attenuation correction and the accurate localization of uptake.

### Analysis of the PET Images

We classified the uptake pattern in the left ventricular (LV) myocardium according to the recommendations of the Japanese Society of Nuclear Cardiology<sup>10</sup> as ‘none’ (no activity exceeding normal blood pool activity), ‘global diffuse’ (even activity over the whole myocardium) ‘focal’ (focally increased spot(s) of activity, other regions inactive), ‘focal on diffuse’ (intense focal spot(s) of activity overlaid on global myocardial activity), or ‘diffuse non-global’ (faint activity on at least two LV walls but at least some areas of myocardium with no activity over normal blood pool activity). Diffuse non-global uptake is not mentioned in the Japanese Society of Nuclear Cardiology recommendations, but it was considered to be a similar physiological phenomenon as diffuse uptake. The uptake was called physiological if it was classified as none, global diffuse, or diffuse non-global and pathological if it was classified as focal or focal on diffuse. We also classified the uptake in the right ventricle (RV) in a similar manner. The maximum standardized uptake value (SUV<sub>max</sub>) in the heart was measured, and its location was determined. The images were interpreted after patient anonymization and randomization. The images were separately interpreted by two experienced nuclear medicine physicians (HT, KS) blinded to all clinical data. In cases where the interpretation of LV-uptake differed between the observers, a consensus was formed and used in the further analyses.

### Collection of Clinical Data

We aimed to study the diagnostic yield of PET in relation to different patient characteristics (demographics, clinical history, and reason for referral). The clinical data were retrospectively collected from the electronic medical records of Tampere University Hospital, containing information from 2008 onwards. We collected demographic information, echocardiography findings, relevant diagnoses, symptoms, and EMB findings.

### Statistical Methods

Statistical analyses were performed using IBM SPSS statistics version 22.0 (Armonk, NY, USA) and R software version 3.2.2. Chi-square and *t* tests were used to compare the results. Data are expressed as the mean (±SD) for the continuous variables and percentages for the dichotomous

variables. Inter-observer agreement was calculated using kappa statistics.

## RESULTS

The inter-observer agreement in analyzing the LV-uptake in the PET studies was good (kappa 0.762). The mean follow-up time (interval between PET imaging and data collection) was 692.8 days (1 year, 10.8 months) (SD 347 days).

104 patients had no pathological LV-uptake: 85 had no visible uptake, three had diffuse uptake and 16 had diffuse non-global uptake pattern. Pathological LV-uptake was observed in 33 patients: 28 had focal uptake and five had focal on diffuse uptake pattern. The mean SUV<sub>max</sub> in the heart was 8.5 (SD 4.1) in those with pathological uptake compared to 3.4 (SD 1.3) in those with no pathological uptake (*P* < 0.001).

Altogether 29 (21%) patients had focal uptake outside myocardium. Uptake foci were encountered in hilar, mediastinal, axillary, subclavicular and abdominal lymph nodes, lung parenchyma, spleen, and skeleton. 16 of the 33 patients with pathological myocardial uptake had pathological extracardiac foci compared to 13 of those 104 who had no pathological myocardial uptake (*P* < 0.001).

The proportions of patients with pathological PET findings according to the demographic information and patient history are presented in Tables 1 and 2. 13 (16%) of the male and 20 (35%) of the female patients had abnormal LV-uptake. Twelve patients had uptake in the RV free wall, ten of them were female. All patients with abnormal RV-uptake also had pathological LV-uptake. The patients with pathological PET findings were more often female and had more frequently a history of 2nd or 3rd degree AV-block than the patients with normal PET findings (Tables 1, 2; Figure 1). Of the 137 patients 56 (41%) had a history of 2nd or 3rd degree AV-block and 41% of them had a pathological PET finding. 27 of the patients with advanced AV-block were female and 56% of them had pathological LV-uptake. Of the 49 male patients without AV-block only 6% had pathological LV-uptake. In our population, there were 75 patients with a history of VT. 31% of them had abnormal LV-uptake and 15% had abnormal RV-uptake. Abnormal RV-uptake was significantly associated with ventricular tachycardia (Table 2). There was also a borderline significant (*P* = 0.053) association between abnormal LV-uptake and ventricular tachycardia (Table 1). There was a subgroup of 17 female patients who had a history of both advanced AV-block and VT. 71% of them had a pathological PET finding. Abnormal RV-uptake was also significantly associated with the history of atrial fibrillation (Table 2). AV-block was the only reason for

**Table 1.** Baseline variables in patients with pathological or normal left ventricle FDG-PET finding

Variable	Abnormal LV-uptake (N = 33)	Normal LV-uptake (N = 104)	P
Gender, female/male	20/13 (61/39%)	37/67 (36/64%)	0.002*
Age (years)	45.8 ± 12.1	43.7 ± 13.2	0.401
Body mass index	26.2 ± 3.9	28.3 ± 5.9	0.053
History of			
II or III degree AV-block	23 (70%)	33 (32%)	<0.001
Ventricular tachycardia	23 (70%)	52 (50%)	0.053
Atrial fibrillation	16 (49%)	37 (36%)	0.185
Heart failure	14 (42%)	53 (51%)	0.393
Pulmonary sarcoidosis	10 (30%)	17 (16%)	0.208
Any heart disease	22 (67%)	64 (62%)	0.595
Reasons for referral			
AV-block	25 (76%)	35 (34%)	<0.001*
Supraventricular arrhythmia	3 (9%)	10 (10%)	0.541
Ventricular arrhythmia	5 (15%)	34 (33%)	0.052
Dilated cardiomyopathy	6 (18%)	22 (21%)	0.712
Abnormal echo findings	14 (43%)	39 (38%)	0.613
Syncope	6 (18%)	22 (21%)	0.712
EMB (N = 21) positive for CS	6 (18%)	1 (1%)	0.190

Figures are N (%) for dichotomous and mean (±SD) for continuous variables  
CS, cardiac sarcoidosis; EMB, endomyocardial biopsy; FDG-PET, <sup>18</sup>Fluorodeoxyglucose positron emission tomography; LV, left ventricle; AV, atrioventricular  
\* P < 0.05

referral significantly associated with abnormal PET findings (Tables 1, 2).

EBM was obtained from 21 patients. Histology was suggestive of CS in seven patients. Six of those had pathological LV-uptake and four also had pathological RV-uptake. However, the association between abnormal FDG-uptake and positive EMB finding was not statistically significant.

## DISCUSSION

Few studies have dealt with the utilization of PET in the diagnostic workup of CS in a clinical setting. A prospective study by Yokoyama et al. described the characteristics of a population of 92 patients with a suspicion of CS.<sup>14</sup> In that population, 40% of patients were diagnosed with CS. Pathological PET findings were observed in 36/37 of the patients diagnosed with CS compared with 16/55 non-CS patients, resulting in a sensitivity of 97% and specificity of 71%. Blankstein et al.<sup>15</sup> studied 118 patients with suspected CS. They found pathological LV-uptake or perfusion defects in 60% of the patients, but only 40% of those fulfilled the

JMWH criteria, which resulted in low specificity. The authors speculated that these findings were a result of low sensitivity of the JMWH criteria because PET was a better predictor of future adverse events. In our population of 137 patients, 33 had pathological LV-uptake. The lower proportion of abnormal PET findings compared with the previously mentioned studies probably reflects our relatively unselected population; we included all PET studies in which there was a suspicion of CS based on patients symptoms. The awareness of CS as a possible cause of otherwise unexplained cardiac symptoms has resulted in an increased demand for cardiac PET studies at our institution during the last few years.

AV-block was significantly associated with pathological PET findings in the present study. In our population, 56 patients had a history of 2nd or 3rd degree AV-block; 41% of them had pathological LV-uptake. Unexplained AV-block has previously been shown to indicate possible CS. In a study by Kandolin et al. inflammatory myocardial disease was diagnosed in 22 of 76 patients (<55 years old) with advanced AV-block.<sup>16</sup> Correlation between AV-block and FDG-uptake in the interventricular septum has also been

**Table 2.** Baseline variables in patients with or without pathological right ventricular FDG-PET finding

Variable	Abnormal RV-uptake (N = 12)	Normal RV-uptake (N = 125)	P
Gender, female/male	10/2 (83/17%)	49/76 (39/61%)	0.004*
Age, years	44.7 ± 8.2	44.1 ± 13.3	0.878
Body mass index	28.0 ± 5.7	25.8 ± 4.1	0.188
History of			
II or III degree AV-block	9 (75%)	47 (37%)	0.014*
Ventricular tachycardia	11 (92%)	64 (52%)	0.006*
Atrial fibrillation	8 (67%)	45 (36%)	0.040*
Heart failure	5 (42%)	62 (50%)	0.413
Pulmonary sarcoidosis	4 (33%)	23 (18%)	0.249
Any heart disease	10 (83%)	76 (61%)	0.106
Reasons for referral			
AV-block	10 (83%)	50 (40%)	0.004*
Supraventricular arrhythmia	1 (8%)	12 (10%)	0.682
Ventricular arrhythmia	4 (33%)	35 (28%)	0.461
Dilated cardiomyopathy	1 (8%)	27 (22%)	0.250
Abnormal echo findings	5 (43%)	48 (38%)	0.527
Syncope	4 (33%)	24 (19%)	0.209
EMB (N = 21) positive for CS	4 (33%)	3 (2%)	0.537

Figures are N (%) for dichotomous and mean (±SD) for continuous variables  
 CS, cardiac sarcoidosis; EMB, endomyocardial biopsy; FDG-PET, <sup>18</sup>Fluorodeoxyglucose positron emission tomography; RV, right ventricle; AV, atrioventricular  
 \* P < 0.05

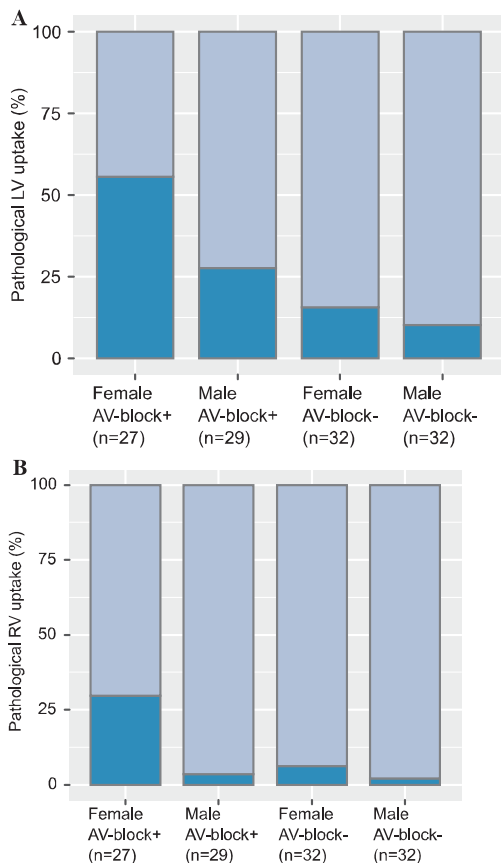
reported previously.<sup>17</sup> AV-block often causes symptoms resulting in referral for imaging studies in the active phase of the disease. This may in part explain why advanced AV-block is the most specific symptom predicting abnormal PET finding. PET findings are pathological only in the active phase of myocardial inflammation but may be normal in the chronic fibrotic phase.

In a previous study by Tung et al. 103 cardiomyopathy patients with ventricular arrhythmias underwent FDG-PET.<sup>18</sup> In that cohort 49% of the patients had abnormal LV-uptake. Nery et al. studied 15 patients with unexplained monomorphic VT and found that 42% had pathological LV-uptake.<sup>19</sup> The authors also found that CS was most often diagnosed in patients with a history of AV-block in combination with VT. In our population there was an association between the history of VT and pathological PET findings, which is in line with the previous literature. Interestingly, 71% of the female patients with a history of both VT and AV-block had a pathological PET finding in our study.

9% of patients in the present study showed pathological uptake in the RV free wall in addition to

pathological LV-uptake. Ten of those patients were female and nine had a history of AV-block. Interestingly, one third of patients with abnormal RV-uptake were later diagnosed with EMB-verified CS. This percentage is rather high considering the low diagnostic yield of the EMB. In a study by Blankstein et al.<sup>15</sup> pathological RV-uptake was encountered in 11 of the 118 patients, which is a similar proportion as that found in our study. Blankstein et al. also observed an elevated risk of VT and death in patients with abnormal RV-uptake, regardless of whether they fulfilled the JMWH criteria for CS or not. In another study, which included 59 patients with systemic sarcoidosis, the proportion of patients with pathological RV-uptake was 22%, and 85% of them fulfilled the JMWH criteria for CS.<sup>20</sup>

There are limitations related to this study. In some cases, the conclusion was different between the two image interpreters. Cardiac FDG-PET has previously been shown to be difficult to interpret.<sup>21</sup> In this study, a consensus was formed in cases where the interpretation differed between the readers. This is common practice when interpreting borderline studies in clinical situations. Because of the cross-sectional nature of this study,



**Figure 1.** Abnormal FDG-uptake in left ventricular (A) and right ventricular (B) wall in different groups..

causality could not be assessed. Reflecting the ethnic background of the majority of the Finnish population, our study group consisted of mainly white Caucasians; therefore, these results cannot be directly generalized in other populations. One major limitation concerning all studies investigating CS is the lack of accurate diagnostic gold standard. As the diagnosis of CS was biopsy-proven in only seven of the patients, one cannot be certain of the underlying cause of all abnormal PET findings. In the case of pathological PET findings, perfusion imaging might improve diagnostic accuracy.<sup>10</sup> However, in our institution, it is not routinely performed in combination with cardiac PET. Furthermore, this particular study dealt with PET only; perfusion imaging would not have changed the categorization of the findings.

## CONCLUSION

Abnormal LV-uptake and RV-uptake were associated with female sex and a history of advanced AV-block. Especially abnormal RV-uptake was predominantly encountered in female patients. Abnormal RV-uptake was also associated with ventricular tachycardia and atrial fibrillation. One third of the patients with abnormal RV-uptake were later diagnosed with EMB-verified cardiac sarcoidosis. These results can be utilized in diagnostic workup of cardiac sarcoidosis.

## NEW KNOWLEDGE GAINED

Highest frequency of pathological cardiac PET findings was encountered in female patients with history of both advanced AV-block and VT.

## Acknowledgements

We want to thank Tiit Kööbi, MD, PhD, for his invaluable contributions to PET-CT imaging in Tampere University Hospital. Additionally, we want to thank all the technicians in the Nuclear Medicine and Radiology departments of Tampere University Hospital. This study was financially supported by Grants from Finska Läkaresällskapet and the Tampere University Hospital Medical Fund.

## Disclosure

All authors declare that they have no conflicts of interest.

## Compliance with ethical standards

## Ethical approval

This article does not contain any studies with human participants performed by any of the authors.

## References

- Rybicki BA, Major M, Popovich J Jr, Malariak MJ, Iannuzzi MC. Racial differences in sarcoidosis incidence: A 5-year study in a health maintenance organization. *Am J Epidemiol* 1997;145:234-41.
- Newman LS, Rose CS, Maier LA. Sarcoidosis. *N Engl J Med* 1997;336:1224-34.
- Silverman KJ, Hutchins GM, Bulkley BH. Cardiac sarcoid: A clinicopathologic study of 84 unselected patients with systemic sarcoidosis. *Circulation* 1978;58:1204-11.
- Okura Y, Dec GW, Hare JM, Kodama M, Berry GJ, Tazelaar HD, et al. A clinical and histopathologic comparison of cardiac sarcoidosis and idiopathic giant cell myocarditis. *J Am Coll Cardiol* 2003;41:322-9.
- Schatka I, Bengel FM. Advanced imaging of cardiac sarcoidosis. *J Nucl Med* 2014;55:99-106.



6. Gideon NM, Mannino DM. Sarcoidosis mortality in the United States 1979–1991: An analysis of multiple-cause mortality data. *Am J Med* 1996;100:423-7.
7. Perry A, Vuitch F. Causes of death in patients with sarcoidosis. A morphologic study of 38 autopsies with clinicopathologic correlations. *Arch Pathol Lab Med* 1995;119:167-72.
8. Kandolin R, Lehtonen J, Airaksinen J, Vihinen T, Miettinen H, Ylitalo K, et al. Cardiac sarcoidosis: Epidemiology, characteristics, and outcome over 25 years in a nationwide study. *Circulation* 2015;131:624-32.
9. Guideline for diagnosis of cardiac sarcoidosis: study report on diffuse pulmonary diseases. Tokyo Japan: Ministry of Health, Labour and Welfare; 1993:23-4.
10. Birnie DH, Sauer WH, Bogun F, Cooper JM, Culver DA, Duvernoy CS, et al. HRS expert consensus statement on the diagnosis and management of arrhythmias associated with cardiac sarcoidosis. *Heart Rhythm* 2014;11:1305-23.
11. Kandolin R, Lehtonen J, Graner M, Schildt J, Salmenkivi K, Kivisto SM, et al. Diagnosing isolated cardiac sarcoidosis. *J Intern Med* 2011;270:461-8.
12. Isobe M, Tezuka D. Isolated cardiac sarcoidosis: Clinical characteristics, diagnosis and treatment. *Int J Cardiol* 2015;182:132-40.
13. Youssef G, Leung E, Mylonas I, Nery P, Williams K, Wisenberg G, et al. The use of 18F-FDG PET in the diagnosis of cardiac sarcoidosis: A systematic review and meta-analysis including the Ontario experience. *J Nucl Med* 2012;53:241-8.
14. Yokoyama R, Miyagawa M, Okayama H, Inoue T, Miki H, Ogi-moto A, et al. Quantitative analysis of myocardial 18F-fluorodeoxyglucose uptake by PET/CT for detection of cardiac sarcoidosis. *Int J Cardiol* 2015;195:180-7.
15. Blankstein R, Osborne M, Naya M, Waller A, Kim CK, Murthy VL, et al. Cardiac positron emission tomography enhances prognostic assessments of patients with suspected cardiac sarcoidosis. *J Am Coll Cardiol* 2014;63:329-36.
16. Kandolin R, Lehtonen J, Kupari M. Cardiac sarcoidosis and giant cell myocarditis as causes of atrioventricular block in young and middle-aged adults. *Circ Arrhythm Electrophysiol* 2011;4:303-9.
17. Manabe O, Ohira H, Yoshinaga K, Sato T, Klaipecth A, Oyama-Manabe N, et al. Elevated (18)F-fluorodeoxyglucose uptake in the interventricular septum is associated with atrioventricular block in patients with suspected cardiac involvement sarcoidosis. *Eur J Nucl Med Mol Imaging* 2013;40:1558-66.
18. Tung R, Bauer B, Schelbert H, Lynch JP 3rd, Auerbach M, Gupta P, et al. Incidence of abnormal positron emission tomography in patients with unexplained cardiomyopathy and ventricular arrhythmias: The potential role of occult inflammation in arrhythmogenesis. *Heart Rhythm* 2015;12:2488-98.
19. Nery PB, Mc Ardle BA, Redpath CJ, Leung E, Lemery R, Dekemp R, et al. Prevalence of cardiac sarcoidosis in patients presenting with monomorphic ventricular tachycardia. *Pacing Clin Electrophysiol* 2014;37:364-74.
20. Manabe O, Yoshinaga K, Ohira H, Sato T, Tsujino I, Yamada A, et al. Right ventricular (18)F-FDG uptake is an important indicator for cardiac involvement in patients with suspected cardiac sarcoidosis. *Ann Nucl Med* 2014;28:656-63.
21. Gormsen LC, Haraldsen A, Kramer S, Dias AH, Kim WY, Borghammer P. A dual tracer <sup>68</sup>Ga-DOTANOC PET/CT and <sup>18</sup>F-FDG PET/CT pilot study for detection of cardiac sarcoidosis. *EJNMMI Res* 2016;6:52.





## Novel ECG parameters are strongly associated with inflammatory $^{18}\text{F}$ -FDG PET findings in patients with suspected cardiac sarcoidosis $\star$



Kalle Sipilä <sup>a,\*</sup>, Heikki Tuominen <sup>a,1</sup>, Atte Haarala <sup>a,1</sup>, Antti Tikkakoski <sup>a,1</sup>, Mika Kähönen <sup>a,b,1</sup>, Kjell Nikus <sup>b,c,1</sup>

<sup>a</sup> Department of Clinical Physiology and Nuclear Medicine, Tampere University Hospital, Finland

<sup>b</sup> Faculty of Medicine and Life Sciences, University of Tampere, Finland

<sup>c</sup> Heart Centre, Tampere University Hospital, Finland

### ARTICLE INFO

#### Article history:

Received 9 February 2017

Received in revised form 30 May 2017

Accepted 6 July 2017

#### Keywords:

Cardiac sarcoidosis

FDG-pet

Electrocardiogram

### ABSTRACT

**Background:**  $^{18}\text{F}$ -Fluorodeoxyglucose (FDG) positron emission tomography (PET) is a feasible method to investigate the inflammatory activity of the myocardium in cardiac sarcoidosis. However, PET is costly and not as widely available as standard electrocardiogram (ECG). Current ECG findings related to cardiac sarcoidosis are highly non-specific. In this study, our aim was to determine whether novel ECG parameters are associated with pathological PET findings in patients with suspected cardiac sarcoidosis.

**Methods:** A total of 133 patients underwent cardiac FDG PET examination in Tampere University Hospital between August 2012 and September 2015. The left ventricular FDG uptake was categorized as either normal or pathological. Additionally, in-depth analyses of resting ECG were performed. Among other parameters, the presence of septal and inferolateral remodelling was assessed. These are novel ECG parameters related to local structural changes in the myocardium.

**Results:** In the ECG, septal and inferolateral remodelling, as well as widespread QRS fragmentation were significantly associated with pathological left ventricular FDG uptake even if adjusted for age, sex, body mass index, underlying cardiovascular disease and cardiac medication ( $p < 0.05$  for all). When all these ECG parameters were combined in a logistic regression model, only septal remodelling remained independently associated with abnormal left ventricular uptake ( $p < 0.05$ ).

**Conclusions:** Our findings show that novel ECG parameters septal and inferolateral remodelling, as well as diffuse QRS fragmentation, are strongly associated with pathological cardiac findings in FDG PET. Thus, the presence of these ECG findings may warrant the clinician to consider the possibility of cardiac sarcoidosis.

© 2017 Elsevier B.V. All rights reserved.

### 1. Introduction

Sarcoidosis is a systematic, multi-organ granulomatous disease. Cardiac manifestation is detected in up to 10% of sarcoidosis patients. However, in post-mortem studies, cardiac sarcoidosis (CS) has been found in 27–40% of sarcoidosis patients [1,2]. CS is associated with poor prognosis and may lead to life-threatening events [3,4]. Early diagnosis is required to lower the risk of atrioventricular (AV)

block, ventricular arrhythmias, heart failure and sudden death [5].  $^{18}\text{F}$ -Fluorodeoxyglucose (FDG) positron emission tomography (PET) is a feasible method to investigate the inflammatory activity of the myocardium in CS with a sensitivity and specificity of 89% and 78%, respectively [6]. Cardiac magnetic resonance imaging (MRI) with late gadolinium enhancement can detect even tiny scars caused by CS [7]. However, PET and cardiac MRI are costly and not as widely available as the standard electrocardiogram (ECG).

Structural heart disease can result in general and non-localizing ECG changes, such as left ventricular hypertrophy (LVH), ST depression, widening of the QRS complex, and P terminal force [8,9]. ECG changes in leads overlying affected regions can reflect regional disease processes. For instance, narrow and deep Q waves are typical in localized wall thickening in hypertrophic cardiomyopathy [10]. A resting ECG is commonly accepted as a screening test for CS [11–13]. It can detect CS with a sensitivity of 33–58% and a specificity of 22–71% [14,15].

Generally, the pathological findings related to CS in a stand-alone ECG are non-specific, but in conjunction with cardiac symptoms, findings such as bundle branch block (BBB), ventricular arrhythmias, II or III degree AV block, may contain clinically important information

$\star$  **Acknowledgements:** We want to thank physicist Pasi Korkola, Lic.Sc. for his valuable comments in regard to all technical aspects of PET/CT imaging. We also want to thank Tiit Kööbi, MD, PhD, for his invaluable contributions to PET/CT imaging in Tampere University Hospital. Additionally, we want to thank all the technicians in the Nuclear Medicine and Radiology departments of Tampere University Hospital. This study was financially supported by grants from Finska Läkaresällskapet (Z60066) and the Tampere University Hospital Medical Fund.

**Conflicts of interest:** No conflicts of interest.

\* Corresponding author at: Department of Clinical Physiology and Nuclear Medicine, Tampere University Hospital, FI-33520 Tampere, Finland.

E-mail address: [kalle.sipila@pshp.fi](mailto:kalle.sipila@pshp.fi) (K. Sipilä).

<sup>1</sup> This author takes responsibility for all aspects of the reliability and freedom from bias of the data presented and their discussed interpretation.

[3,16]. Conduction disturbances, arrhythmias and ST/T changes have been described as typical ECG findings in CS [2,17–19]. CS can affect virtually any location of the conduction system, leading to left or right BBB (complete or incomplete), AV block of any degree, and even sinus arrest. The reported prevalence of conduction abnormalities has been in the range of 12–62% [20–22]. Sustained or non-sustained ventricular tachycardia may persist despite medical treatment and can result in sudden death, which is the most feared cardiac manifestation of CS [23,24]. The role of in-depth ECG analyses, such as a fragmented QRS complex, in the diagnosis of CS is not well established [25–28].

The data in regard to abnormal ECG and its association with cardiac PET findings in sarcoidosis are very limited. Manabe et al. studied abnormal ECG findings and their relationship to myocardial FDG uptake in 50 patients with sarcoidosis and suspected cardiac involvement. Their ECG analysis concentrated mainly on conventional parameters. Abnormal ECG was associated with pathological FDG uptake in that study [29]. Roukoz et al. investigated the association of fragmented QRS (fQRS) and granulomatous myocarditis. There were only seven patients (of 58) with CS and fQRS in whom FDG PET was available. The location of FDG uptake did not correlate with the location of fQRS [30].

In our institution, FDG PET is routinely utilized as part of the diagnostic work-up in patients with suspected CS. The objective of this study was to determine whether abnormal ECG findings in patients with suspected CS are associated with pathological findings in cardiac FDG PET. Furthermore, we explored whether in-depth ECG analysis can predict abnormal FDG PET uptake.

## 2. Materials and methods

### 2.1. Study population

We retrospectively screened all cardiac PET examinations performed in Tampere University Hospital from August 2012 to September 2015. All cases in which the cardiologist suspected CS were selected. We excluded those examinations in which the patient's clinical data could not be obtained or if the study was performed to follow up on previously diagnosed CS. PET examinations were also excluded if the dedicated imaging protocol, as described below, was not followed precisely. At least one of the following symptoms or conditions raised the clinical suspicion of CS in our population: unexplained AV block ( $n = 61$ ), ventricular ( $n = 39$ ) or supraventricular ( $n = 13$ ) arrhythmia, unexplained dilated cardiomyopathy ( $n = 27$ ), unexplained low ejection fraction in echocardiography ( $n = 46$ ), other echocardiographic findings suggestive of CS ( $n = 53$ ), or syncope ( $n = 27$ ). Finally four patients were excluded as they did not have any available ECG examination. Altogether, there were 133 PET examinations analysed for this present study. All data were collected retrospectively.

### 2.2. PET imaging

All patients underwent an integrated PET/CT (Discovery STE 16, GE Healthcare, Milwaukee, WI, USA) examination. To minimize the physiological myocardial FDG uptake, patients did not consume any carbohydrates during the day before the imaging and fasted for 12 h before the FDG injection. Patients maintained a food diary during the diet. Patients were also instructed to avoid heavy physical exercise to minimize the FDG uptake in skeletal muscle. Patients' height and weight were measured before the administration of the radiopharmaceutical, and their blood glucose level was tested to be  $< 7$  mmol/l. The PET/CT images were acquired approximately 60 min after intravenous injection of FDG using the Medrad® Intego PET infusion system (Bayer Medical Care Inc., Indianapolis, PA, USA). The amount injected is currently based on the patient's weight (3–3.2 MBq/kg). However, the protocol was changed in 2013. Previously, patients were given a fixed dose of 370 MBq. The mean injected activity in our study population was 320 MBq (range 219–460 MBq). The imaging covered a volume of two bed positions around the myocardium. The total examination time for PET/CT was approximately 15 min. CT was used for attenuation correction and accurate localization of uptake.

### 2.3. Analysis of PET images

PET/CT images were evaluated visually using the AW Volume Share™ workstation, version 4.6 (GE Healthcare). AW Volume Share™ allows automatic registration and fusion between two volumetric acquisitions. The image fusion provided added value to the side-by-side interpretation. The images were analysed blinded to all clinical data after the patients were anonymized and randomized. The image analysis was performed independently by two nuclear medicine specialists (KS and HT). Myocardial FDG uptake pattern in the left ventricle (LV) was categorized visually as follows: 'none' (no uptake exceeding blood pool), 'global diffuse' (even uptake over the whole myocardium), 'focal' (focal areas of uptake, other regions inactive), 'focal on diffuse' (focal spot/spots of uptake overlaid on

less intense global myocardial uptake) or 'diffuse non-global' (faint diffuse activity on at least two LV walls but at least some areas of myocardium inactive, intensity of the uptake less than that of the liver). The uptake was considered physiological if the pattern was none, global diffuse or diffuse non-global and pathological if the pattern was focal or focal on diffuse. There were 12 cases in which the two readers initially disagreed on whether PET was normal or pathological. In these cases, the readers performed re-evaluation of the images together. The consensus achieved in the re-evaluation between the two readers was used in the statistical analyses.

### 2.4. ECG analysis

One standard 12 lead ECG recorded with a 50 mm/s speed of each patient was analysed manually in a systematic manner by one investigator (KN) blinded to the clinical data. The ECG closest to the PET/CT study was used, but if this was a pacemaker ECG, a previous ECG without pacing was chosen.

Computer analysis measurements were used for the PQ interval and QRS duration. LVH was defined according to the Sokolow-Lyon criteria [31] or Cornell voltage duration product [QRS-duration (ms)  $\times$  (RaVL in mm + SV3 in mm with 6 mm added for women)  $\geq 2440$ ] [32,33]. For ST segment depression, we used  $\geq 0.5$  mm if the pattern was horizontal or descending and  $\geq 1$  mm if ascending in  $\geq 2$  adjacent leads measured at the J point + 60 ms [34]. T-wave inversion was defined as  $\geq 1$  mm in  $\geq 2$  adjacent leads, except for leads aVR and V1 [35].

For fQRS in  $\geq 2$  adjacent leads, we used the definitions by Das et al. [36]. Septal fragmentation was considered present if there was fQRS in  $\geq 2$  septal leads (V1–V3). We considered fragmentation of  $> 5$  ECG leads as widespread fQRS.

For fascicular and BBB, standard criteria were used. Non-specific intraventricular conduction defect (NSIVCD) was defined as a QRS duration  $\geq 120$  ms, not fulfilling criteria for right (RBBB) or left BBB. For II or III degree AV block, we used data from the patient history in addition to the ECG analysis data.

In addition to the established ECG changes, we used a recently introduced ECG parameter "Septal remodelling" [37], which was defined as one of the following present in V1–V3: 1) pathological Q waves in  $\geq 2$  parallel leads, and/or 2) septal fQRS as defined above, and/or 3) poor R-wave progression (R wave  $< 3$  mm) in leads V1–V3 accompanied by fQRS, or disorderly distributed R-wave amplitudes, either  $RV2 > RV3$  or  $RV1 > RV2$  [38].

In addition, we introduced a novel ECG parameter "Inferolateral remodelling", which was defined as follows: 1) fQRS in  $\geq 1$  inferior (II, III, aVF) and lateral (V4–V6) lead, and/or 2) Q wave (as defined below) in  $\geq 2$  of the leads II, aVF, V4–V6, and/or 3) low voltage (R-wave amplitude  $\leq 3.5$  mm) in II, III, aVF and V4–V6. An example of ECG with both septal- and inferolateral remodelling is shown in Fig. 1a.

The possibility of a lead switch was considered by assessing the morphology of the P and S waves in the precordial leads, and no suspicious cases were observed. Any Q wave  $\geq 40$  ms in duration, or  $\geq 3$  mm deep, or  $qR$ -ratio  $\geq 0.25$ , in  $\geq 2$  parallel leads except lead aVR was considered pathological [39].

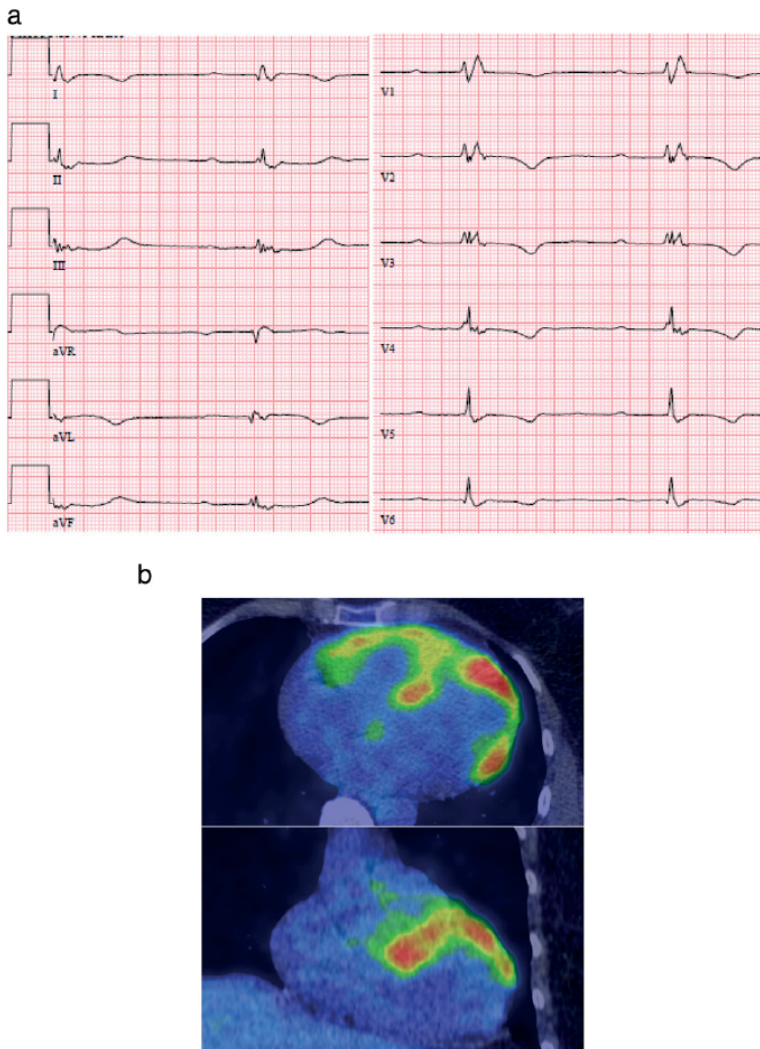
### 2.5. Statistical analyses

Chi-square and *t*-test analyses were performed to compare categorical and continuous variables between the patients with and without pathological LV uptake, respectively. A logistic linear regression analysis was performed to examine the independent relationships between the ECG parameters and pathological PET findings. Adjustments for age, sex, BMI, underlying cardiovascular disease and cardiac medication were performed. Statistical analyses were performed using R software version 2.14.1.

## 3. Results

LV uptake was considered physiological in 101 (76%) patients; 83 (62%) had no detectable LV uptake, two (2%) had global diffuse uptake and 16 (12%) had diffuse non-global uptake. In 32 (24%) patients LV uptake was pathological. Of those patients, 27 (20%) had focal myocardial uptake and five (4%) had focal spots on diffuse myocardial background uptake. Examples of pathological focal myocardial uptake and normal PET with no detectable uptake are shown in Figs. 1b and 2, respectively.

The clinical characteristics and ECG parameters in patients with or without abnormal left ventricular FDG uptake are shown in Table 1. A pathological PET finding was more common in female patients ( $p = 0.018$ ). Patients with pathological FDG uptake had lower BMI than patients with a normal PET study ( $p = 0.022$ ). The two groups did not significantly differ by age ( $p = 0.308$ ) or presence of underlying cardiac diseases ( $p = 0.513$ ). Ventricular conduction defects (defined as any BBB), septal remodelling, inferolateral remodelling and widespread fQRS were more frequent in patients with abnormal LV uptake than in patients with normal LV uptake ( $p < 0.05$  for all). The associations of inferolateral remodelling, widespread fQRS and septal remodelling with LV uptake are illustrated in Fig. 3. Left anterior fascicular block



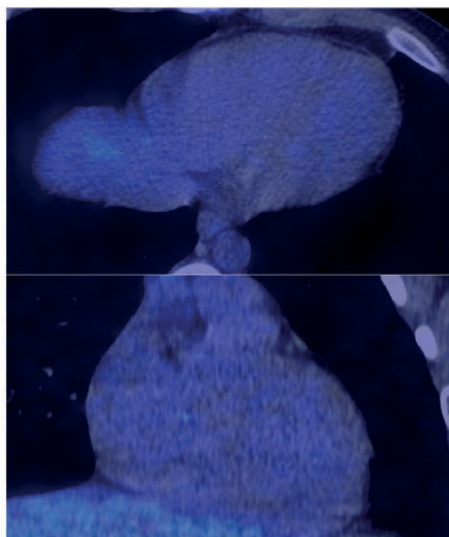
**Fig. 1.** a. A 54-year old female patient was evaluated for dyspnoea and arrhythmias. In echocardiography, the left ventricular diastolic diameter was normal and the ejection fraction was slightly decreased (45%) with septal hypokinesia. Endomyocardial biopsy findings were compatible with sarcoidosis. The ECG (50 mm/s) shows first degree atrioventricular block and right bundle branch block. Septal remodelling is evident from QRS fragmentation in leads V2–V3. In addition, QRS fragmentation is also present in leads I, III, aVL and aVF, which fulfills the criteria for inferolateral remodelling. Pathological Q waves are present in leads I and aVL. T-wave inversions in I, aVL and V1–V6 can't be fully explained by the bundle branch block. b. PET/CT fusion images in axial (above) and coronal (below) views of a 54-year old female patient. ECG of the same patient is shown in Fig. 1a. Pathological patchy uptake is seen in anterior and lateral walls of the left ventricle as well as the ventricular septum and the free wall of the right ventricle.

(LAFB) was the only ventricular conduction defect, in which the difference between the groups was significant. The two groups did not differ significantly with respect to PQ interval ( $p = 0.069$ ) or QRS width ( $p = 0.105$ ). Neither did the groups differ with regard to the presence of AV block (II or III degree), Q waves, poor R-wave progression, LVH, ST-segment depression, T-wave inversions or fQRS in at least two adjacent leads. If data regarding AV block were derived from the patient history, patients with abnormal FDG uptake had significantly more II or III degree AV block compared to those with normal LV uptake ( $p < 0.001$ ). Two patients had a pacemaker rhythm in the analysed ECG.

Of the patients, 83 used ACE inhibitors, 87 beta blockers, 54 diuretics, 17 calcium channel blockers, 9 amiodarone and 13 immunosuppressive medications. Neither the patients with or without abnormal FDG uptake

nor with or without novel ECG parameters septal- or inferolateral remodelling did significantly differ by usage of cardiac or immunosuppressive medication ( $p > 0.05$  for both).

Septal remodelling, inferolateral remodelling and widespread fQRS remained significantly associated with pathological LV uptake when adjusted for age, sex and BMI ( $p < 0.05$  for all, Table 2). These associations remained significant even if further adjusted for the usage of cardiac medication, presence of underlying cardiac disease and the history of II or III degree AV block ( $p < 0.05$  for all, Supplemental Table 1). When the presence of any BBB, septal remodelling, inferolateral remodelling and widespread fQRS were entered into a logistic regression model as independent variables, septal remodelling was the only variable significantly associated with abnormal LV uptake ( $p = 0.030$ , Table 2).



**Fig. 2.** PET/CT fusion images in axial (above) and coronal (below) views of a 19-year-old male patient. This is a normal PET finding as the myocardium does not accumulate FDG.

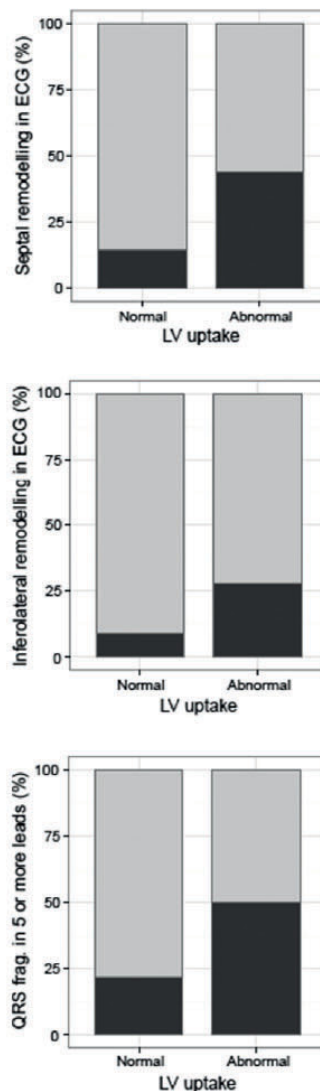
PET findings with diffuse LV uptake patterns may sometimes be considered indeterminate in regard to CS. Therefore, we reanalyzed the data of the Table 2 using only patients with focal or no detectable uptake in PET. All patients with global diffuse, non-global diffuse or focal on diffuse activity patterns were excluded from this reanalysis. The results of the Table 2 remained essentially similar (data not shown). The only

**Table 1**

Clinical characteristics and ECG parameters in patients with or without abnormal left ventricular FDG uptake.

	Normal uptake (n = 101)	Pathological uptake (n = 32)	p value
Age (years)	43.4 ± 19.9	46.0 ± 12.2	0.308
Body mass index (kg/m <sup>2</sup> )	28.2 ± 5.8	26.1 ± 3.9	0.022
Female sex (%)	36	59	0.018
Underlying cardiac disease (%)	62	69	0.513
Cardiac medication (%)	82	72	0.207
Immunosuppressive medication (%)	7.9	15.6	0.201
PQ interval (ms)	191.7 ± 56.0	222.3 ± 79.7	0.069
QRS length (ms)	113.9 ± 27.7	124.4 ± 32.5	0.105
Q wave present (%)	1	0	0.650
Poor R wave progression (%)	20	29	0.493
Left ventricular hypertrophy (%)	25	14	0.387
ST segment depression (%)	22	21	0.959
T wave inversion (%)	37	43	0.669
QRS fragmentation (%)	60	69	0.395
Septal remodelling (%)	15	44	0.001
Inferolateral remodelling (%)	9	28	0.006
RBBB (%)	14	22	0.279
LBBB (%)	7	9	0.648
LAFB (%)	10	28	0.010
LPFB (%)	4	0	0.253
NSIVCD (%)	11	21	0.113
Any intra-ventricular conduction defect (%)	35	56	0.030
AV block (II or III degree) (%)	9	13	0.532
Widespread (>5 leads) fQRS (%)	22	50	0.002
AV block (II or III degree, data from patient history) (%)	31	69	<0.001

Values are means ± SD in continuous variables and % in dichotomous variables. RBBB = right ventricular bundle branch block, LBBB = left bundle branch block, LAFB = left anterior fascicular block; LPFB = left posterior fascicular block; NSIVCD = non-specific intra-ventricular conduction defect, AV = atrioventricular, fQRS = QRS fragmentation.



**Fig. 3.** The associations of septal remodelling, inferolateral remodelling and widespread fragmented QRS with left ventricular uptake. ECG = electrocardiogram, LV = left ventricular.

exception was that none of the ECG findings alone remained significantly associated with pathological PET findings when septal remodelling, inferolateral remodelling and widespread QRS fragmentation were all entered into a logistic regression model as independent variables.

In our population there were seven patients with endomyocardial biopsy (EMB) confirmed CS, six of them had pathological PET findings. Three of the patients with positive EMB had septal remodelling and two had inferolateral remodelling in the ECG. Hence, five patients with sarcoidosis in EMB had either septal or inferolateral remodelling.

#### 4. Discussion

Diagnosing CS is often challenging. Due to the inhomogeneous involvement of the myocardium, the diagnostic yield of EMB is low [22], and there is a need for more sensitive diagnostic methods. Dedicated

**Table 2**

Logistic regression models for the associations between left ventricular FDG uptake and age, sex, body mass index and selected ECG parameters.

A)				
Left ventricular uptake	OR	2.5%	97.5%	p value
Septal remodelling	6.2453	2.3028	16.9377	<0.001
Sex	2.443	1.0047	5.9402	0.0488
Body mass index	0.9203	0.8393	1.0091	0.0771
Age	1.0241	0.9891	1.0603	0.1789
Intercept OR = 0.4165				
B)				
Left ventricular uptake	OR	2.5%	97.5%	p value
Inferolateral remodelling	3.7699	1.2905	11.0129	0.0153
Sex	2.3134	0.9834	5.442	0.0547
Body mass index	0.9269	0.8482	1.0129	0.0935
Age	1.0121	0.9791	1.0461	0.4773
Intercept OR = 0.7819				
C)				
Left ventricular uptake	OR	2.5%	97.5%	p value
Widespread (>5 leads) QRS fragmentation	5.0885	1.9496	13.2807	<0.001
Sex	2.9015	1.1906	7.0709	0.0191
Body mass index	0.922	0.844	1.0071	0.0714
Age	1.0273	0.9918	1.064	0.1333
Intercept OR = 0.2976				
D)				
Left ventricular uptake	OR	2.5%	97.5%	p value
Inferolateral remodelling	1.8956	0.5904	6.0864	0.2826
Widespread (>5 leads) QRS fragmentation	2.0591	0.7961	5.3259	0.1363
Septal remodelling	2.8971	1.1132	7.5395	0.0293
Any ventricular conduction defect	0.6223	0.2569	1.5075	0.2934
Intercept OR = 0.2151				

The selected ECG parameters were septal remodelling (A), inferolateral remodelling (B) and widespread QRS fragmentation (C). Model D included all the above-mentioned parameters as well as the presence of any ventricular conduction defect as independent variables. OR = odds ratio.

cardiac FDG PET is a feasible method to investigate the inflammatory activity of the myocardium [6]. However, PET is costly and not as widely available as standard ECG. In this study pathological PET findings were observed in all but one EMB positive CS patients. The reason for negative PET in one patient with biopsy confirmed CS is probably related to the fact that FDG uptake can only be seen in an active phase of the disease.

A standard resting ECG has been used to screen for CS [11–13], but the sensitivity and specificity have been reported to be low [14,15]. Recently, several new parameters from in-depth ECG analyses have been described, and their associations with various structural heart diseases have been reported. However, these parameters have not been extensively studied in the diagnosis of CS [25–28]. No firm data on the relationship between ECG parameters and FDG PET in a population with CS suspicion exists. In a study by Manabe et al., patients with an abnormal ECG, defined as RBBB, AV block, left axis deviation, non-sustained ventricular tachycardia, premature ventricular contractions, abnormal Q wave or ST-T abnormalities, had a higher number of LV segments with abnormal FDG uptake than patients with a normal ECG [29]. The authors concluded that AV block was the only specific ECG parameter significantly correlating with pathological PET findings. To the best of our knowledge, our study is the first to include the novel ECG parameters septal remodelling and inferolateral remodelling and to compare ECG and cardiac PET findings.

We did not detect significant differences in QRS width or in the presence of poor R-wave progression, LVH, ST-segment depression or T-inversions between the patients with or without abnormal LV uptake. This finding is probably related to the fact that these parameters are non-specific and may be associated with various cardiac conditions. fQRS has previously been associated with CS [26,30,40]. Interestingly

the presence of fQRS in at least two adjacent leads was not significantly associated with pathological LV uptake in our study. However, fQRS is considered to be a marker of myocardial scarring [41] and not of inflammation, whereas FDG is a marker of metabolic activity. For example, FDG accumulation is not observed in areas of myocardial infarction [42]. In fact, in a study by Roukoz et al., six out of seven patients had no spatial correlation between FDG uptake and fQRS [30]. In our study, fQRS in five or more ECG leads was significantly associated with abnormal LV uptake. We may postulate that in patients with highly abnormal ECG, active inflammatory lesions and more advanced myocardial damage may co-exist.

CS has been associated with ventricular conduction defects, especially RBBB [22,40,43], but only a few studies have investigated the association of myocardial FDG uptake and ventricular conduction abnormalities. Ohira et al. studied FDG PET and cardiac MRI in patients with CS and either RBBB or AV block. In their population, 72% of the patients with RBBB had pathological PET findings. However, PET was more likely pathological in patients with AV block (92%). The authors hypothesized that compared with AV block, RBBB is a sign of more advanced myocardial damage with scar formation [44]. Our finding that patients with pathological LV FDG uptake had significantly more ventricular conduction abnormalities than patients with normal LV uptake is consistent with the literature. However, in this study, LAFB was the only ventricular conduction defect, which was significantly associated with abnormal PET findings. In our population, only 32% of the patients with RBBB had abnormal FDG uptake. The reason for the lack of association between RBBB and abnormal LV uptake in our study, which is in contrast to the findings by Ohira et al., could be that our patients generally underwent cardiac imaging at an earlier stage of the disease process with less scar formation. This assumption seems to gain some support from the description of biological mechanisms in CS described by Ohira et al.

AV block is considered a frequent complication of CS [22]; in the study by Ohira et al., most of the patients (92%) with AV block (Mobitz type II or grade III AV-block) had pathological PET findings [44]. Also in the present study, II or III-degree AV block was associated with a pathological PET finding, if data from patient history was used. The presence of AV block in the ECG closest to the PET/CT study was not significantly associated with PET findings. This is most likely due to the poor sensitivity of a single ECG to detect II degree AV block.

Contrary to established ECG parameters, such as LVH and ST/T changes, the novel ECG parameters septal and inferolateral remodelling were strongly related to pathological PET findings in the present study. The association remained even after adjustment for age, sex, BMI, cardiac medication, other cardiac disease and patient history of II or III degree AV block. The results did not essentially change even if the possible indeterminate cases with diffuse LV uptake patterns were excluded from the analyses. The amount of EMB-confirmed CS was low in our population. Nevertheless, five out of seven patients (71%) with CS-positive EMB had either septal- or inferolateral remodelling in their ECG. The odds ratio to predict pathological FDG uptake was 5.9 for septal remodelling and 4.5 for the presence of II or III degree AV block in the same ECG. The fact that AV block has been strongly related to pathological PET findings in previous studies underscores the clinical importance of the ECG parameter septal remodelling [44]. Septal remodelling was also significantly associated with abnormal LV uptake, independently of the ECG parameters inferolateral remodelling and widespread fQRS.

LV remodelling is a well-established pathophysiological phenomenon in diseases such as hypertensive heart disease, valvular disease and cardiomyopathies, and it has been associated with non-specific ECG changes such as LVH and ST/T abnormalities [45]. However, the association between ECG markers of regional disease processes and structural heart disease are less well established. Our results suggest that these parameters might be related to active inflammation. Although these ECG findings by themselves are not an indication for PET and cannot be considered diagnostic for CS, our results emphasize the potential role of simple low cost methods in the diagnostic work-up for CS.

There are clear limitations with our study. This study was cross-sectional, and causality could not be assessed. Corresponding to the majority of the Finnish population, our study group consisted of mainly white Caucasians, and these results cannot be directly generalized to other populations. A major limitation concerning all studies investigating CS is the lack of a sensitive and specific diagnostic gold standard. Therefore, one cannot be certain of the underlying cause of the pathological findings. In our institution, myocardial perfusion imaging is not performed routinely. In the case of a pathological FDG PET finding, perfusion imaging might improve diagnostic accuracy [6]. However, in this particular study, we only explored the PET findings; perfusion imaging would not have changed their categorization. In a recent study, 72 h of very low carbohydrate diet was reported to be more efficient in minimizing the physiologic FDG uptake of the myocardium in comparison to 24 h of diet [46]. On the other hand, if a prolonged diet had been used in this study, some of the patients would probably have been excluded due to the failure in following the protocol precisely. There were 12 cases in which the initial conclusion differed between the two PET interpreters. However, in such cases, consensus between the readers was achieved and used in statistical analyses. Suboptimal inter-reader variability has been reported previously [47].

In conclusion, our findings show that novel ECG parameters of ventricular remodelling and diffuse QRS fragmentation are strongly associated with pathological myocardial FDG uptake in a Finnish population with clinical suspicion of CS. Although the relationships of these novel ECG parameters with CS and their clinical significance needs to be further studied in other populations, the presence of these ECG findings may warrant the clinician to consider the possibility of cardiac sarcoidosis.

Supplementary data to this article can be found online at <http://dx.doi.org/10.1016/j.ijcard.2017.07.027>.

## References

- W.C. Roberts, H.A. McAllister Jr., V.J. Ferrans, Sarcoidosis of the heart. A clinicopathologic study of 35 necropsy patients (group 1) and review of 78 previously described necropsy patients (group 11), *Am. J. Med.* 63 (1) (1977 Jul) 86–108.
- K.J. Silverman, G.M. Hutchins, B.H. Bulkley, Cardiac sarcoid: a clinicopathologic study of 84 unselected patients with systemic sarcoidosis, *Circulation* 58 (6) (1978 Dec) 1204–1211.
- S.W. Dubrey, R. Sharma, R. Underwood, T. Mittal, Cardiac sarcoidosis: diagnosis and management, *Postgrad. Med. J.* 91 (1077) (2015 Jul) 384–394.
- E. Ipek, S. Demirelli, E. Ermiş, S. İnci, Sarcoidosis and the heart: a review of the literature, *Intractable Rare Dis. Res.* 4 (4) (2015 Nov) 170–180.
- Y. Sobue, M. Harada, M. Koshikawa, T. Ichikawa, M. Yamamoto, K. Okuda, et al., QRS-based assessment of myocardial damage and adverse events associated with cardiac sarcoidosis, *Heart Rhythm* 12 (12) (2015 Dec) 2499–2507.
- G. Youssef, E. Leung, I. Mylonas, P. Nery, K. Williams, G. Wisenberg, et al., The use of 18F-FDG PET in the diagnosis of cardiac sarcoidosis: a systematic review and metaanalysis including the Ontario experience, *J. Nucl. Med.* 53 (2) (2012 Feb) 241–248.
- M.R. Patel, P.J. Cawley, J.F. Heitner, I. Klem, M.A. Parker, W.A. Jaroudi, et al., Detection of myocardial damage in patients with sarcoidosis, *Circulation* 120 (20) (2009 Nov 17) 1969–1977.
- I. Kasser, J.W. Kennedy, The relationship of increased left atrial volume and pressure to abnormal P waves on the electrocardiogram, *Circulation* 39 (3) (1969 Mar) 339–343.
- Y. Momiya, H. Mitamura, M. Kimura, ECG characteristics of dilated cardiomyopathy, *J. Electrocardiol.* 27 (4) (1994 Oct) 323–328.
- P. Charron, O. Dubourg, M. Desnos, R. Isnard, A. Hagege, A. Millaire, et al., Diagnostic value of electrocardiography and echocardiography for familial hypertrophic cardiomyopathy in a genotyped adult population, *Circulation* 96 (1) (1997 Jul 1) 214–219.
- D. Mehta, S.A. Lubitz, Z. Frankel, J.P. Wisnivesky, A.J. Einstein, M. Goldman, et al., Cardiac involvement in patients with sarcoidosis: diagnostic and prognostic value of outpatient testing, *Chest* 133 (6) (2008 Jun) 1426–1435.
- Statement on sarcoidosis, Joint statement of the American Thoracic Society (ATS), the European Respiratory Society (ERS) and the world Association of Sarcoidosis and Other Granulomatous Disorders (WASOG) adopted by the ATS Board of directors and by the ERS executive committee, February 1999, *Am. J. Respir. Crit. Care Med.* 160 (2) (1999 Aug) 736–755.
- M. Sekiguchi, Y. Yazaki, M. Isobe, M. Hiroe, Cardiac sarcoidosis: diagnostic, prognostic, and therapeutic considerations, *Cardiovasc. Drugs Ther.* 10 (5) (1996 Nov) 495–510.
- C. Chapelon-Abric, D. de Zuttere, P. Duhaut, P. Veysier, B. Wechsler, D.L. Huong, et al., Cardiac sarcoidosis: a retrospective study of 41 cases, *Medicine (Baltimore)* 83 (6) (2004 Nov) 315–334.
- K. Okayama, C. Kurata, K. Tawaraha, Y. Wakabayashi, K. Chida, A. Sato, Diagnostic and prognostic value of myocardial scintigraphy with thallium-201 and gallium-67 in cardiac sarcoidosis, *Chest* 107 (2) (1995 Feb) 330–334.
- A.R. Doughan, B.R. Williams, Cardiac sarcoidosis, *Heart* 92 (2) (2006 Feb) 282–288.
- M. Thunell, P. Bjerle, N. Stjernberg, ECG abnormalities in patients with sarcoidosis, *Acta Med. Scand.* 213 (2) (1983) 115–118.
- G.J. Fahy, T. Marwick, C.J. McCreery, P.J. Quigley, B.J. Maurer, Doppler echocardiographic detection of left ventricular diastolic dysfunction in patients with pulmonary sarcoidosis, *Chest* 109 (1) (1996 Jan) 62–66.
- W.J. Gibbons, R.D. Levy, S. Nava, I. Malcolm, J.M. Marin, C. Tardif, et al., Subclinical cardiac dysfunction in sarcoidosis, *Chest* 100 (1) (1991 Jul) 44–50.
- J.P. Smedema, G. Snoep, M.P. van Kroonenburgh, R.J. van Geuns, W.R. Dassen, A.P. Gorgels, et al., Cardiac involvement in patients with pulmonary sarcoidosis assessed at two university medical centres in the Netherlands, *Chest* 128 (1) (2005 Jul) 30–35.
- Y. Yazaki, M. Isobe, M. Hiroe, S. Morimoto, S. Hiramitsu, T. Nakano, et al., Prognostic determinants of long-term survival in Japanese patients with cardiac sarcoidosis treated with prednisone, *Am. J. Cardiol.* 88 (9) (2001 Nov 1) 1006–1010.
- J.S. Kim, M.A. Judson, R. Donnino, M. Gold, L.T. Cooper Jr., E.N. Prystowsky, et al., Cardiac sarcoidosis, *Am. Heart J.* 157 (1) (2009 Jan) 9–21.
- A. Aizer, E.H. Stern, J.A. Gomes, A.S. Teirstein, R.E. Eckart, D. Mehta, Usefulness of programmed ventricular stimulation in predicting future arrhythmic events in patients with cardiac sarcoidosis, *Am. J. Cardiol.* 96 (2) (2005 Jul 15) 276–282.
- S.L. Winters, M. Cohen, S. Greenberg, B. Stein, J. Curwin, E. Pe, et al., Sustained ventricular tachycardia associated with sarcoidosis: assessment of the underlying cardiac anatomy and the prospective utility of programmed ventricular stimulation, drug therapy and an implantable antiarrhythmia device, *J. Am. Coll. Cardiol.* 18 (4) (1991 Oct) 937–943.
- M.K. Das, H. Suradi, W. Maskoun, M.A. Michael, C. Shen, J. Peng, et al., Fragmented wide QRS on a 12-lead ECG: a sign of myocardial scar and poor prognosis, *Circ. Arrhythm. Electrophysiol.* 1 (4) (2008 Oct) 258–268.
- M. Homs, I. Alsayed, B. Safadi, J. Mahenthiran, M.K. Das, Fragmented QRS complexes on 12-lead ECG: a marker of cardiac sarcoidosis as detected by gadolinium cardiac magnetic resonance imaging, *Ann. Noninvasive Electrocardiol.* 14 (4) (2009 Oct) 319–326.
- S. Maheshwari, A. Acharyya, P.E. Puddu, E.B. Mazomenos, G. Leekha, K. Maharata, et al., An automated algorithm for online detection of fragmented QRS and identification of its various morphologies, *J. R. Soc. Interface* 10 (89) (2013 Oct 16) 20130761.
- S. Nagao, H. Watanabe, M. Kodama, J. Tanaka, E. Suzuki, I. Narita, et al., Fragmented QRS complexes, conduction disorder, and ST segment abnormality on twelve-lead electrocardiography predict severe cardiac manifestation in sarcoidosis, *Circulation* 124 (2011) A9485.
- O. Manabe, H. Ohira, K. Yoshinaga, T. Sato, A. Klaietch, N. Oyama-Manabe, et al., Elevated (18)F-fluorodeoxyglucose uptake in the interventricular septum is associated with atrioventricular block in patients with suspected cardiac involvement sarcoidosis, *Eur. J. Nucl. Med. Mol. Imaging* 40 (10) (2013 Oct) 1558–1566.
- H. Roukoz, M. Shah, L.J. Masilamani, A. Thachil, P.K. Jayakumar, D.G. Benditt, et al., QRS as a marker of granulomatous disease in patients presenting with ventricular tachycardia and normal left ventricular ejection fraction, *Indian Heart J.* 67 (3) (2015 May-Jun) 222–226.
- M. Sokolow, T.P. Lyon, The ventricular complex in left ventricular hypertrophy as obtained by unipolar precordial and limb leads, *Am. Heart J.* 37 (2) (1949 Feb) 161–186.
- P.M. Okin, R.B. Devereux, M.S. Nieminen, S. Jern, L. Oikarinen, M. Viitasalo, et al., Relationship of the electrocardiographic strain pattern to left ventricular structure and function in hypertensive patients: the LIFE study, Losartan intervention for endpoint, *J. Am. Coll. Cardiol.* 38 (2) (2001 Aug) 514–520.
- P.M. Okin, M.J. Roman, R.B. Devereux, P. Kligfield, Electrocardiographic identification of increased left ventricular mass by simple voltage-duration products, *J. Am. Coll. Cardiol.* 25 (2) (1995 Feb) 417–423.
- N.K. Lakdawala, J.J. Thune, B.J. Maron, A.L. Cirino, O. Havndrup, B. Bundgaard, et al., Electrocardiographic features of sarcomere mutation carriers with and without clinically overt hypertrophic cardiomyopathy, *Am. J. Cardiol.* 108 (11) (2011 Dec 1) 1606–1613.
- T. Konno, N. Fujino, K. Hayashi, K. Uchiyama, E. Masuta, H. Katoh, et al., Differences in the diagnostic value of various criteria of negative T waves for hypertrophic cardiomyopathy based on a molecular genetic diagnosis, *Clin. Sci. (Lond.)* 112 (11) (2007 Jun) 577–582.
- M.K. Das, B. Khan, S. Jacob, A. Kumar, J. Mahenthiran, Significance of a fragmented QRS complex versus a Q wave in patients with coronary artery disease, *Circulation* 113 (21) (2006 May 30) 2495–2501.
- L. Ollila, K. Nikus, M. Holmstrom, M. Jalanko, R. Jurkko, M. Kaartinen, et al., Clinical disease presentation and ECG characteristics of LMNA mutation carriers, *Open Heart* 4 (1) (2017 Jan 9), e000474–2016-000474. (eCollection 2017).
- M.J. Zema, P. Kligfield, Electrocardiographic poor R wave progression. I: correlation with the frank vectorcardiogram, *J. Electrocardiol.* 12 (1) (1979 Jan) 3–10.
- C.A. Dumont, L. Monserrat, R. Soler, E. Rodriguez, X. Fernandez, J. Peteiro, et al., Interpretation of electrocardiographic abnormalities in hypertrophic cardiomyopathy with cardiac magnetic resonance, *Eur. Heart J.* 27 (14) (2006 Jul) 1725–1731.
- J.L. Schuller, M.D. Olson, M.M. Zipse, P.M. Schneider, R.G. Aleong, H.D. Wiemberger, et al., Electrocardiographic characteristics in patients with pulmonary sarcoidosis indicating cardiac involvement, *J. Cardiovasc. Electrophysiol.* 22 (11) (2011 Nov) 1243–1248.



- [41] M.K. Das, D.P. Zipes, Fragmented QRS: a predictor of mortality and sudden cardiac death, *Heart Rhythm*. 6 (3 Suppl) (2009 Mar) S8–14.
- [42] A. Crean, S.N. Khan, L.C. Davies, R. Coulden, D.P. Dutka, Assessment of myocardial scar; comparison between F-FDG PET, CMR and Tc-Sestamibi, *Clin. Med. Cardiol.* 3 (2009 Jun 8) 69–76.
- [43] S. Nagao, H. Watanabe, Y. Sobue, M. Kodama, J. Tanaka, N. Tanabe, et al., Electrocardiographic abnormalities and risk of developing cardiac events in extracardiac sarcoidosis, *Int. J. Cardiol.* 189 (2015) 1–5.
- [44] H. Ohira, D.H. Birnie, E. Pena, J. Bernick, B. Mc Ardle, E. Leung, et al., Comparison of (18)F-fluorodeoxyglucose positron emission tomography (FDG PET) and cardiac magnetic resonance (CMR) in corticosteroid-naive patients with conduction system disease due to cardiac sarcoidosis, *Eur. J. Nucl. Med. Mol. Imaging* 43 (2) (2016 Feb) 259–269.
- [45] E.W. Hancock, B.J. Deal, D.M. Mirvis, P. Okin, P. Klugfield, L.S. Gettes, et al., AHA/ACCF/HRS recommendations for the standardization and interpretation of the electrocardiogram: part V: electrocardiogram changes associated with cardiac chamber hypertrophy: a scientific statement from the American Heart Association Electrocardiography and Arrhythmias Committee, Council on Clinical Cardiology; the American College of Cardiology Foundation; and the Heart Rhythm Society. Endorsed by the International Society for Computerized Electrocardiology, *J. Am. Coll. Cardiol.* 53 (11) (2009 Mar 17) 992–1002.
- [46] Y. Lu, C. Grant, K. Xie, N.J. Sweiss, Suppression of myocardial 18F-FDG uptake through prolonged high-fat, high protein, and very-low-carbohydrate diet before FDG-PET/CT for evaluation of patients with suspected cardiac sarcoidosis, *Clin. Nucl. Med.* 42 (2) (2017 Feb) 88–94.
- [47] L.C. Gormsen, A. Haraldsen, S. Kramer, A.H. Dias, W.Y. Kim, P. Borghammer, A dual tracer (68)Ga-DOTANOC PET/CT and (18)F-FDG PET/CT pilot study for detection of cardiac sarcoidosis, *EJNMMI Res.* 6 (1) (2016 Dec), 52-016-0207-6.



# 18-FDG-PET in a patient cohort suspected for cardiac sarcoidosis: Right ventricular uptake is associated with pathological uptake in mediastinal lymph nodes

Heikki Tuominen, MD,<sup>a</sup> Atte Haarala, MD, PhD,<sup>a</sup> Antti Tikkakoski, MD,<sup>a</sup>  
Mika Kähönen, MD, PhD,<sup>a,b</sup> Kjell Nikus, MD, PhD,<sup>b,c</sup> and Kalle Sipilä, MD, PhD<sup>a</sup>

<sup>a</sup> Department of Clinical Physiology and Nuclear Medicine, Tampere University Hospital, Tampere, Finland

<sup>b</sup> Faculty of Medicine and Life Sciences, University of Tampere, Tampere, Finland

<sup>c</sup> Heart Center, Tampere University Hospital, Tampere, Finland

Received Mar 2, 2018; accepted Apr 17, 2018  
doi:10.1007/s12350-018-1291-y

**Introduction.** In up to 65% of cardiac sarcoidosis patients, the disease is confined to the heart. Diagnosing isolated cardiac sarcoidosis is challenging due to the low sensitivity of endomyocardial biopsy. If cardiac sarcoidosis is part of biopsy-confirmed systemic sarcoidosis, the diagnosis can be based on cardiac imaging studies. We compared the imaging features of patients with isolated cardiac FDG uptake on positron emission tomography with those who had findings indicative of systemic sarcoidosis.

**Materials and methods.** 137 consecutive cardiac FDG-PET/CT studies performed on subjects suspected of having cardiac sarcoidosis were retrospectively analyzed.

**Results.** 33 patients had pathological left ventricular FDG uptake, and 12 of these also had pathological right ventricular uptake. 16/33 patients with pathological cardiac uptake had pathological extracardiac uptake. 10/12 patients with both LV- and RV-uptake patterns had extracardiac uptake compared to 6/21 of those with pathological LV uptake without RV uptake. SUVmax values in the myocardium were higher among patients with abnormal extracardiac uptake. The presence of extracardiac uptake was the only imaging-related factor that could predict a biopsy indicative of sarcoidosis.

**Conclusion.** Right ventricular involvement seems to be more common in patients who also have findings suggestive of suspected systemic sarcoidosis, compared with patients with PET findings indicative of isolated cardiac disease. (J Nucl Cardiol 2018)

**Key Words:** Inflammation • PET • Diagnostic and prognostic application

**Electronic supplementary material** The online version of this article (<https://doi.org/10.1007/s12350-018-1291-y>) contains supplementary material, which is available to authorized users.

The authors of this article have provided a PowerPoint file, available for download at SpringerLink, which summarises the contents of the paper and is free for re-use at meetings and presentations. Search for the article DOI on SpringerLink.com.

**Funding** The study was funded by Finska Läkaresällskapet.

Reprint requests: Heikki Tuominen, MD, Department of Clinical Physiology and Nuclear Medicine, Tampere University Hospital, Teiskontie 35, 33520, Tampere, Finland; [heikki.p.tuominen@gmail.com](mailto:heikki.p.tuominen@gmail.com)

1071-3581/\$34.00

Copyright © 2018 American Society of Nuclear Cardiology.

### Abbreviations

CS	Cardiac sarcoidosis
FDG	Fluorodeoxyglucose
PET	Positron emission tomography
SUVmax	Maximum standardized uptake
LV	Left ventricle
RV	Right ventricle
EMB	Endomyocardial biopsy
LVEF	Left ventricular ejection fraction

## INTRODUCTION

Sarcoidosis is a multisystem granulomatous inflammatory disorder that can affect any organ system. The disease typically manifests in the lungs, often as asymptomatic hilar lymph node enlargement. The most common presentation is symmetric hilar adenopathy, which is encountered in approximately 95% of patients with lung sarcoidosis.<sup>1</sup> Middle mediastinal or prevascular lymph nodes are involved in approximately 50% of patients with pulmonary sarcoidosis.<sup>2</sup> Unilateral hilar lymph node enlargement or mediastinal node enlargement without hilar adenopathy indicates an alternative etiology.<sup>3</sup> Pulmonary sarcoidosis is often an incidental finding when imaging is performed to investigate other symptoms or diseases. Sarcoidosis patients should be screened for cardiac involvement because of the potential life-threatening consequences of the disease. Sudden cardiac death has been shown to be a potential initial manifestation of CS.<sup>4-6</sup> The recommended initial screening evaluations include patient medical history, ECG, and echocardiography. However, only from 40 to 50% of patients with cardiac involvement at autopsy had clinically evident cardiac disease during their lifetimes.<sup>7</sup>

Due to the difficulty of diagnosing CS, the epidemiological literature on the topic is limited. CS has traditionally been diagnosed using the guidelines issued in 2006 by the Japanese Ministry of Health and Welfare (JMHW) and revised by the Japan Society of Sarcoidosis and Other Granulomatous Disorders. The revised criteria were proposed by the Heart Rhythm Society in 2014.<sup>8</sup> According to both guidelines, CS can only be diagnosed via direct confirmation by endomyocardial biopsy (EMB) or based on a previous diagnosis of systemic sarcoidosis combined with clinical and imaging findings indicating cardiac involvement. Given that the sensitivity of EMB is low, many patients with probable CS do not fulfill the current diagnostic criteria.<sup>9</sup>

Cardiac <sup>18</sup>fluorodeoxyglucose positron emission tomography/computerized tomography (18FDG PET/CT) (later referred to as PET) has been used to identify

active cardiac inflammation, with a sensitivity and specificity of 89% and 78%, respectively.<sup>10</sup> In the revised JMHW guidelines, gallium-scintigraphy was included as a major criterion to demonstrate myocardial inflammation. Due to the low sensitivity of Ga-scintigraphy, the JMHW has since approved substituting it with FDG-PET. The demand for cardiac imaging has increased because it has been suggested that CS should be excluded in patients under the age of 55 years with unexplained dilated cardiomyopathy, second- or third-degree atrioventricular (AV) block or persistent ventricular tachycardia (VT).<sup>8,11</sup>

In a previous study of 110 Finnish CS patients, CS was diagnosed by direct EMB in 50% of the patients and by biopsy from another affected site combined with cardiac imaging findings suggesting sarcoid involvement in the other 50% of the patients.<sup>12</sup> Seventy-one of the 110 patients had clinically isolated cardiac sarcoidosis, e.g., no clinical signs or history suggesting extracardiac disease. However, PET showed metabolically active mediastinal lymph nodes in 71% of these patients. In a study by Simonen *et al.*, it was found that confirmed CS FDG-avidity of mediastinal lymph nodes was caused by granulomatous inflammation in all patients from whom a biopsy was obtained.<sup>13</sup> Mediastinal lymph node biopsy serves as an alternative to histologically diagnosed sarcoidosis when an EMB is negative despite a strong clinical suspicion of CS. This fact may increase the true clinical sensitivity of PET compared to the figures reported previously, many of which are based on cardiac uptake patterns only.<sup>10</sup>

Our aim was to study the association between pathological extracardiac and cardiac FDG uptake.

## MATERIALS AND METHODS

### Study Population

We retrospectively screened all cardiac PET studies performed in the Tampere University Hospital from August 2012 to September 2015. We excluded PET studies in which the clinical indication was not CS suspicion, the patient's clinical data could not be obtained or the PET study was performed to followup on previously diagnosed CS. Imaging studies were also excluded if the dedicated imaging protocol, as described below, was not followed precisely. Altogether, 137 PET examinations were analyzed for the present study. In our hospital, PET is routinely performed in the diagnostic workup of possible CS. The reason for a clinical suspicion of CS was one or more of the following: unexplained AV block ( $n = 61$ ), ventricular ( $n = 39$ ) or supraventricular ( $n = 13$ ) arrhythmia, unexplained dilated cardiomyopathy ( $n = 27$ ), an unexplained low ejection fraction on echocardiography ( $n = 46$ ), other echocardiographic findings suggestive of CS ( $n = 53$ ), or syncope ( $n = 27$ ). Symptoms and clinical findings

were considered unexplained by the cardiologist after inconclusive routine studies, including clinical examination, ECG and echocardiography. Coronary angiography was performed in cases of clinical suspicion of coronary artery disease.

## PET Imaging

All patients underwent an integrated PET/CT (Discovery STE 16, GE Healthcare, Milwaukee, WI, USA) examination. To minimize physiological myocardial FDG uptake, the patients were instructed not to consume any carbohydrates during the day before the imaging exam and to fast for 12 hours before the FDG injection. The patients maintained a food diary during the prescribed diet. The patients were also instructed to avoid heavy physical exercise to minimize FDG uptake in skeletal muscle. Patient height and weight were measured before the administration of the radiopharmaceutical, and blood glucose levels were tested to confirm level of  $< 7$  mmol/L. The PET/CT images were acquired approximately 60 min after the intravenous injection of FDG using the Medrad® Intego PET infusion system (Bayer Medical Care Inc., Indianola, PA, USA). In our hospital, the activity injected is based on a patient's weight (3 to 3.2 MBq/kg). The imaging protocol has been described in more detail previously.<sup>14</sup>

## Analysis of PET Images

We classified the uptake pattern in the left ventricular (LV) myocardium according to the recommendations of the Japanese Society of Nuclear Cardiology (10) as 'none' (no activity exceeding normal blood pool activity), 'global diffuse' (uniform activity over the entire myocardium), 'focal' (focally increased spot(s) of activity, other regions inactive), 'focal on diffuse' (intense focal spot(s) of activity overlapping global myocardial activity) or 'diffuse non-global' (faint activity on at least two LV walls, but at least some areas of myocardium with no activity over normal blood pool activity). Diffuse non-global uptake is not mentioned in the Japanese Society of Nuclear Cardiology recommendations but was considered to be a similar physiological phenomenon to diffuse uptake. The uptake was called physiological if it was classified as none, global diffuse or diffuse non-global. Uptake was called pathological if it was classified as focal or focal on diffuse. We also classified the uptake in the right ventricle (RV) in a similar manner. The maximum standardized uptake value (SUVmax) in the heart was measured, and its location was determined. Extracardiac uptake in the lymph nodes was considered pathological if it exceeded that of the mediastinal blood pool. The areas inspected for possible pathological extracardiac uptake included lymph nodes in axillary, subclavicular, mediastinal, hilar, and epigastric sites. Pathological FDG uptakes in the lung parenchyma, liver, spleen, and bone were also noted. Uptakes in the liver, spleen, and lung parenchyma were considered pathological if there were spots of metabolic activity exceeding the physiological uptake of the surrounding parenchyma. Bone marrow uptake was considered pathological if focal uptake exceeding that of the liver was noted. The images were interpreted after patient

anonymization and randomization. The images were separately interpreted by two experienced nuclear medicine physicians (HT, KS) blinded to all clinical data. In cases where the interpretation of LV uptake differed between the observers, a consensus was reached and used in further analyses.

## Collection of Clinical Data

Clinical data were retrospectively collected from the electronic medical record system of Tampere University Hospital, which contains information from the year 2008 onward. We collected demographic information, echocardiography findings, relevant diagnoses, symptoms, and EMB findings.

## Statistical Methods

Statistical analyses were performed using IBM SPSS statistics version 22.0 (Armonk, NY, USA) and R software version 3.2.2. The Chi-squared test was used for dichotomous variables, and a *t* test was used for continuous variables to compare the results. Linear regression was used to assess independent predictors of positive biopsy findings in a multivariate model, including age, sex, and pathological LV, RV, and extracardiac uptakes.

## RESULTS

Thirty-three of 137 (24%) patients had pathological cardiac uptake. Of these 12 (36%) had pathological uptake in both the left and right ventricles. There were 29 of 137 (21%) patients with pathological extracardiac uptake foci. Extracardiac uptake was significantly associated with pathological LV and RV uptakes (Table 1, Figure 1). Patients with both pathological cardiac and extracardiac uptakes had significantly higher SUVmax values in the myocardium compared to the patients with abnormal myocardial uptake but physiological extracardiac uptake (SUVmax 10.4 (S.D. 4.7) and 6.6 (S.D. 2.3), respectively, *P*-value .001). The difference remained significant using SUVmax values normalized for mediastinal bloodpool: relative SUVmax 6.4 (SD 3.3) and 4.0 (SD 1.4), respectively, *P*-value .008) (Figure 2; Table 2).

Patients with uptakes in both ventricles had pathological extracardiac uptake significantly more often than patients with physiological RV uptake (*P* < .001). Ten of the 12 patients with pathological RV uptake also had pathological extracardiac foci. Patients with pathological RV uptake also had pathological extracardiac uptake more often than those with pathological uptake in the LV but not in RV (*P*-value .003, Table 3, Figure 1). Pathological myocardial uptake was associated with uptake in mediastinal and hilar lymph nodes but not with pathological uptake at other extracardiac sites (Table 2).

**Table 1.** Baseline variables and FDG-PET findings in patients with and without pathological extracardiac FDG uptake

Variable	Pathological extracardiac FDG uptake (n = 29)	No pathological extracardiac FDG uptake (n = 108)	P-value
Female gender	19 (66%)	40 (37%)	.006*
BMI	27.3 (4.2)	28.0 (5.9)	.525
Age, years	44.1 (12.3)	44.2 (13.2)	.97
History of			
Ventricular tachycardia	21 (72%)	54 (50%)	.035*
2nd or 3rd degree AV-block	14 (48%)	42 (39%)	.241
Heart failure	8 (28%)	59 (55%)	.01*
Pathological LV uptake	16 (55%)	13 (12%)	< .001*
Pathological RV uptake	10 (34%)	2 (1.9%)	< .001*
Extracardiac biopsy positive for sarcoidosis	11 (38%)	4 (4%)	< .001*
EMB or extracardiac biopsy positive for sarcoidosis	15 (52%)	7 (7%)	< .001*

The values represent n (%) for dichotomous variables and the mean (± SD) for continuous variables

BMI, Body mass index; EMB, endomyocardial biopsy; FDG-PET, <sup>18</sup>Fluorodeoxyglucose positron emission tomography; AV, atrioventricular; RV, right ventricle; LV, left ventricle

\*p < 0.05

Patients with pathological extracardiac uptake were predominantly female, more often had a history of ventricular tachycardia and less often had a history of heart failure compared to the patients without pathological extracardiac uptake. Patients with pathological extracardiac uptake had lower brain natriuretic peptide (BNP)-values than those with no pathological extracardiac uptake (751 and 1698 ng/L, respectively,  $P = .014$ ).

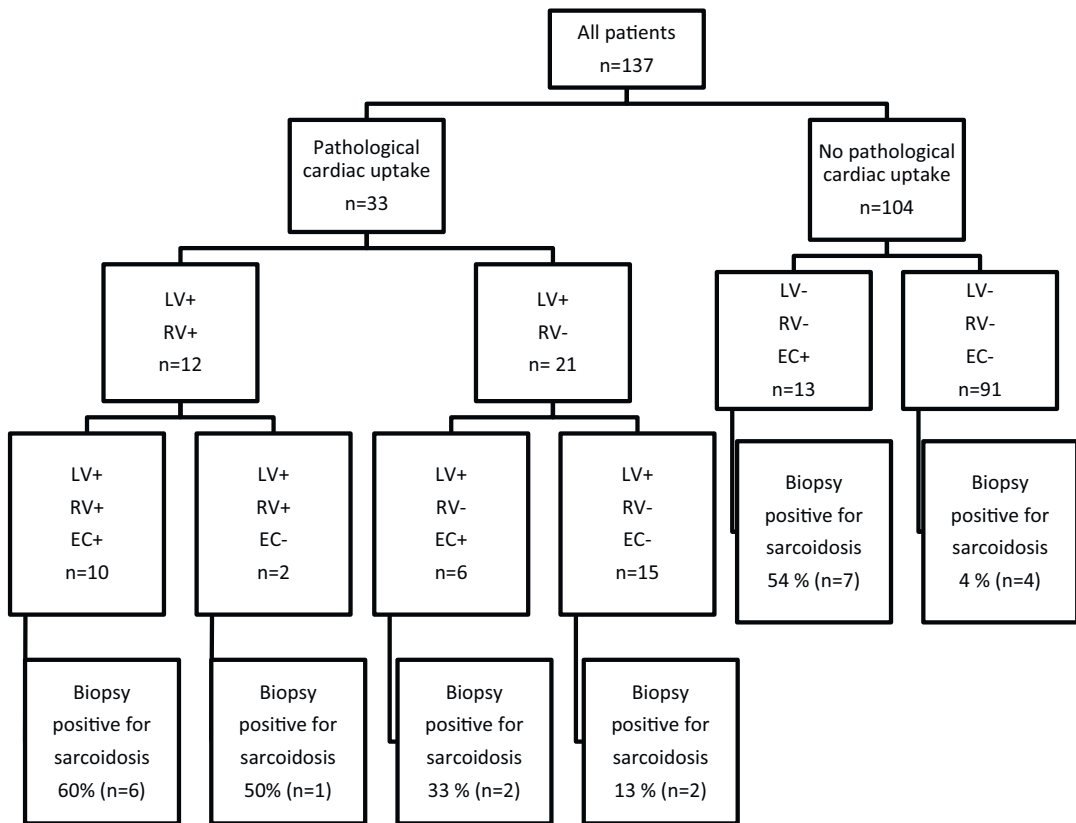
Biopsies from an extracardiac focus were obtained from 25 patients, which was indicative of sarcoidosis in 15 patients. In addition, 7 patients had a positive EMB. Patients with a positive biopsy (EMB or extracardiac) had more often pathological LV uptake, RV and extracardiac uptake than those with no biopsy-proven sarcoidosis (48% and 20%,  $P$ -value .009, 29% and 5%,  $P$ -value .003, 67 and 13%,  $P$ -value < .001, respectively). However, in a multiple regression model, only extracardiac uptake, but not LV or RV uptake, predicted a positive biopsy overall (EMB or extracardiac). Out of ten patients with both abnormal LV uptake and extracardiac uptake, six had biopsy-confirmed sarcoidosis: three by EMB and three by extracardiac tissue biopsy.

## DISCUSSION

We found a significant association between pathological myocardial FDG uptake and pathological uptake

in hilar and mediastinal lymph nodes. The association was especially strong in patients with pathological uptake in the RV free wall. Pathological myocardial uptake was stronger in patients who also had pathological extracardiac uptake. Extracardiac uptake was the only factor that could predict a positive biopsy finding for sarcoidosis.

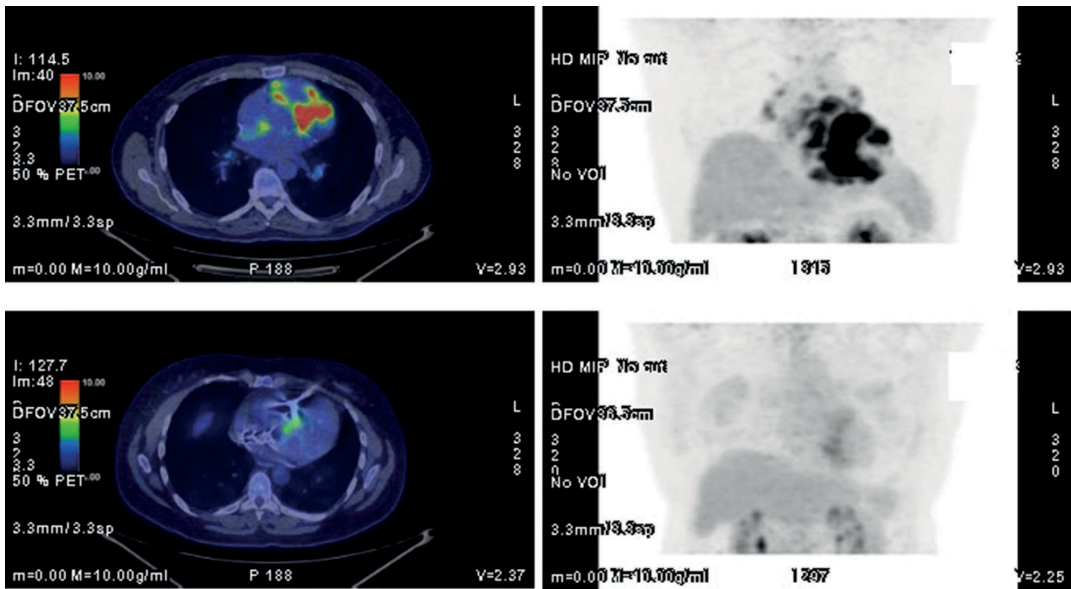
A few studies have examined the association between cardiac and extracardiac FDG uptakes in patients suspected for CS, but the results are somewhat contradictory. In a study by Kandolin *et al.*, 71% of patients with histologically verified CS had positive mediastinal lymph nodes on whole-body FDG-PET.<sup>12</sup> The percentage was the same even in patients without clinical or anamnestic extracardiac sarcoidosis. In our clinical population consisting of patients, who were suspected of having CS, 29 of 137 patients (21%) had abnormal extracardiac FDG uptake. The low number of patients with pathological extracardiac uptake is due to the fact that only a small proportion of our population had sarcoidosis. In the study of Yokoyama *et al.*, abnormal extracardiac uptake was observed in 54% of the 92 FDG-PET studies performed on patients suspected of having CS.<sup>15</sup> In their population, there was a significantly higher proportion of biopsy-confirmed CS patients compared to our study cohort. Therefore, this discrepancy could simply indicate selective differences between the cohorts. In our study, a total of 33 patients



**Figure 1.** Patients divided into groups according to PET findings and the number of tissue biopsies positive for sarcoidosis. *LV*, left ventricle; *RV*, right ventricle; *EC*, extracardiac; +, pathological FDG uptake; -, no pathological FDG uptake.

had pathological cardiac uptake, and among these patients, 48% had abnormal extracardiac FDG uptake. In the study of Patel *et al.*, similar results were found. In their study, among patients with pathological myocardial uptake, 40% also had pathological extracardiac FDG-positive foci.<sup>16</sup> On the other hand, Blankstein *et al.* reported that extracardiac FDG uptake was not significantly associated with pathological cardiac findings.<sup>17</sup> In that study, 118 PET studies were performed to assess myocardial inflammation or perfusion defects in patients suspected of having CS, and 27% of 71 patients with pathological uptake or perfusion defects had abnormal extracardiac uptake. However, the authors did not specifically report the number of patients with abnormal cardiac uptake who also had extracardiac uptake. Perfusion defects may be due to previously active inflammation that has since become inactive, which may possibly explain these differing results.

There may be some alternative explanations for the association between abnormal FDG uptakes in the RV and in mediastinal lymph nodes in addition to their vulnerability to sarcoid inflammation. Pulmonary hypertension has been shown to increase FDG uptake in the right ventricular free wall.<sup>18</sup> Hilar adenopathy in sarcoidosis has been associated with elevated pulmonary pressure.<sup>19</sup> Therefore, pulmonary hypertension and the consequent right-ventricular workload could theoretically explain the association between abnormal FDG uptake in mediastinal lymph nodes and in the RV. However, pulmonary hypertension has been shown to occur in less than 10% of patients with sarcoidosis.<sup>20</sup> Moreover, in the context of an increased workload, the uptake should be uniform rather than patchy as in our patients. Also, patients with pathological RV uptake did not have decreased LV uptake significantly more often than patients with no RV uptake (58% vs 55%,



**Figure 2.** Fusion and MIP images of patients with pathological FDG uptake in left ventricle, right ventricular free wall, and mediastinal lymph nodes (above) and with uptake only in ventricular septum (below).

**Table 2.** Pathological uptakes at different extracardiac sites in patients with myocardial uptake in both ventricles and in the left ventricle only

Extracardiac uptake site	Pathological LV uptake with no RV uptake (n = 21)	Pathological uptake in both ventricles (n = 12)	P-value
Lung	3 (14%)	3 (25%)	.374
Spleen	0 (0%)	1 (8%)	.364
Hilar ln	6 (29%)	8 (67%)	.039*
Mediastinal ln	6 (29%)	8 (67%)	.039*
Axillary ln	0 (0%)	0 (0%)	
Subclavicular ln	0 (0%)	1 (8%)	.364
Abdominal ln	1 (5%)	0 (0%)	.636

The values are n (%)

RV, right ventricle; LV, left ventricle; ln, lymph node

\*p < 0.05

respectively, P-value .542). In our cohort, 8 of 12 patients with abnormal RV uptake also had abnormal FDG uptake in hilar lymph nodes. Interestingly, in our study population, no patients had abnormal RV uptake without accompanying LV uptake. There are only a few case reports of isolated right ventricular CS, and only one patient showed this pattern in the study of Manabe *et al.*<sup>21-23</sup> One could also speculate that cardiac sarcoidosis typically begins in the LV, which has the

greatest myocardial mass of the heart chambers, and the right ventricle and mediastinal lymph nodes would then become involved later if inflammation starts to spread. This speculation could explain why the association was especially strong between abnormal extracardiac and RV uptakes in our study.

Previously, Manabe *et al.* showed that patients with pathological RV uptake fulfill the JMWH criteria more often than those with uptake only in the LV.<sup>22</sup> This is



**Table 3.** Pathological extracardiac uptakes at different sites in patients with and without pathological LV uptake, RV uptake, and LV uptake without RV uptake (a, b, and c, respectively)

<b>Extracardiac uptake site</b>	<b>Pathological LV uptake (n = 33)</b>	<b>Physiological cardiac uptake (n = 104)</b>	<b>P-value</b>
<b>3a</b>			
Lung	6 (18%)	8 (7.7%)	.085
Spleen	1 (3%)	4 (4%)	.652
Hilar ln	14 (42%)	10 (10%)	< .001*
Mediastinal ln	14 (42%)	9 (9%)	< .001*
Axillary ln	0 (0%)	5 (5%)	.246
Subclavicular ln	1 (3%)	4 (4%)	.652
Abdominal ln	1 (3%)	5 (5%)	.554
<b>Extracardiac uptake site</b>	<b>Pathological RV uptake (n = 12)</b>	<b>Physiological RV uptake (n = 125)</b>	<b>P-value</b>
<b>3b</b>			
Lung	3 (25%)	11 (9%)	.108
Spleen	1 (8%)	4 (3%)	.372
Hilar ln	8 (67%)	16 (13%)	< .001*
Mediastinal ln	8 (67%)	15 (12%)	< .001*
Axillary ln	0 (0%)	5 (4%)	.628
Subclavicular ln	1 (8%)	4 (3%)	.372
Abdominal ln	0 (0%)	6 (5%)	.571
<b>Extracardiac uptake site</b>	<b>Pathological LV uptake with no RV uptake (n = 21)</b>	<b>Physiological cardiac uptake (n = 104)</b>	<b>P-value</b>
<b>3c</b>			
Lung	3 (14%)	8 (8%)	.273
Spleen	0 (0%)	4 (4%)	.474
Hilar ln	6 (29%)	10 (10%)	.029*
Mediastinal ln	6 (29%)	9 (9%)	.020*
Axillary ln	0 (0%)	5 (5%)	.628
Subclavicular ln	0 (0%)	4 (4%)	.372
Abdominal ln	1 (5%)	5 (5%)	.735

The values are n (%)

RV, right ventricle; LV, left ventricle; ln, lymph node

\* $p < 0.05$ 

consistent with our findings: 6 of 12 patients with RV uptake had biopsy-confirmed sarcoidosis compared to only 4 of 21 patients with LV uptake alone. As the diagnostic yield of EMB is low, extracardiac uptake foci provide an alternative site for biopsy. Manabe *et al.* also showed that patients with RV uptake had more widespread pathological uptake in the LV, suggesting more widespread disease. All these findings seem to suggest that the inflammatory process is more widespread in

patients with RV involvement, and one may speculate that sarcoidosis of the heart originates in the LV.

We did not find a statistically significant association between abnormal cardiac FDG uptake and non-hilar/mediastinal extracardiac uptake. The low statistical power due to the low number of extrathoracic FDG-avid foci may explain this result. On the other hand, PET results indicated lung sarcoidosis in 14 patients. Abnormal FDG uptake in the lung parenchyma was not

associated with abnormal LV or RV uptake. Patients with known lung sarcoidosis may be promptly referred for PET when presenting with unspecific symptoms considered potentially cardiac in origin. This could lead to a selection bias toward imaging patients with less-severe symptoms/findings if they have known lung sarcoidosis.

In our population, a positive tissue biopsy for sarcoidosis was obtained significantly more often from patients with extracardiac uptake than from those who had physiological extracardiac uptake. This finding was expected, as a tissue biopsy is easier to obtain from extracardiac sites compared to EMB. Seven patients had biopsy confirmation of sarcoidosis but physiological cardiac uptake on PET, which is most likely due to the inactive state of their sarcoid disease. As shown in our previous study, one patient with EMB-confirmed CS did not have any myocardial uptake on PET.<sup>14</sup> Such a finding may represent a patient with myocardial inflammation that has caused myopathy that has since become inactive and accordingly PET-negative.

Our results and the previous literature seem to suggest that truly isolated CS is often confined to the LV myocardium. According to the present diagnostic criteria, EMB is the only method to verify isolated CS. However, EMB is rarely obtained from the LV. Therefore, if the patients in our population with pathological, isolated LV uptake truly have CS, then the present diagnostic criteria are insensitive for the diagnosis of isolated CS.

There are limitations in our study. Guidelines to select patients with suspected CS for PET imaging did not exist until very recently.<sup>24</sup> Our study population is relatively unselected, with most cases showing PET- or biopsy-negative results. However, this represents the true clinical situation. Perfusion imaging might improve diagnostic accuracy in the case of pathological PET findings. However, in our institution, it is not routinely performed in combination with cardiac PET. Furthermore, our study dealt with PET only, and perfusion imaging would not have changed the categorization of the findings. Our study population consists of Finnish patients representing Caucasians. Since the epidemiology of sarcoidosis is known to differ between populations, our findings may not be directly generalizable to other populations. In addition, the number of patients with biopsy-confirmed cardiac sarcoidosis in our population was relatively low. This limitation in statistical power is evident in many of the available CS studies.

### NEW KNOWLEDGE GAINED

Right ventricular involvement seems to be more common in patients who have FDG-PET findings

suggestive of systemic sarcoidosis compared to those with pathological findings confined to the heart.

### CONCLUSION

Patients with pathological myocardial FDG uptake had abnormal FDG uptake in mediastinal and hilar lymph nodes more often than patients with physiological cardiac uptake. Patients with both LV and RV uptakes had FDG uptake in mediastinal and hilar lymph nodes more often than those with isolated LV uptake. SUVmax values in the myocardium were higher in the patients with abnormal extracardiac FDG uptake, suggesting that sarcoid inflammation in the heart is stronger and more widespread in patients with findings suggestive of systemic sarcoidosis.

### Disclosures

*Heikki Tuominen, Atte Haarala, Antti Tikkaoski, Mika Kähönen, Kjell Nikus, Kalle Sipilä declare that they have no conflict of interest.*

### References

1. Henke CE, Henke G, Elveback LR, Beard CM, Ballard DJ, Kurland LT. The epidemiology of sarcoidosis in Rochester, Minnesota: A population-based study of incidence and survival. *Am J Epidemiol* 1986;123:840-5.
2. Brauner MW, Grenier P, Mompot D, Lenoir S, de Cremoux H. Pulmonary sarcoidosis: Evaluation with high-resolution CT. *Radiology* 1989;172:467-71.
3. Iannuzzi MC, Fontana JR. Sarcoidosis: Clinical presentation, immunopathogenesis, and therapeutics. *JAMA* 2011;305:391-9.
4. Kim JS, Judson MA, Donnino R, et al. Cardiac sarcoidosis. *Am Heart J* 2009;157:9-21.
5. Fleming HA, Bailey SM. The prognosis of sarcoid heart disease in the united kingdom. *Ann N Y Acad Sci* 1986;465:543-50.
6. Yazaki Y, Isobe M, Hiroe M, et al. Prognostic determinants of long-term survival in Japanese patients with cardiac sarcoidosis treated with prednisone. *Am J Cardiol* 2001;88:1006-10.
7. Perry A, Vuitch F. Causes of death in patients with sarcoidosis. A morphologic study of 38 autopsies with clinicopathologic correlations. *Arch Pathol Lab Med* 1995;119:167-72.
8. Birnie DH, Sauer WH, Bogun F, et al. HRS expert consensus statement on the diagnosis and management of arrhythmias associated with cardiac sarcoidosis. *Heart Rhythm* 2014;11:1305-23.
9. Kandolin R, Lehtonen J, Graner M, et al. Diagnosing isolated cardiac sarcoidosis. *J Intern Med* 2011;270:461-8.
10. Youssef G, Leung E, Mylonas I, et al. The use of 18F-FDG PET in the diagnosis of cardiac sarcoidosis: A systematic review and metaanalysis including the Ontario experience. *J Nucl Med* 2012;53:241-8.
11. Kandolin R, Lehtonen J, Kupari M. Cardiac sarcoidosis and giant cell myocarditis as causes of atrioventricular block in young and middle-aged adults. *Circ Arrhythm Electrophysiol* 2011;4:303-9.
12. Kandolin R, Lehtonen J, Airaksinen J, et al. Cardiac sarcoidosis: Epidemiology, characteristics, and outcome over 25 years in a nationwide study. *Circulation* 2015;131:624-32.

13. Simonen P, Lehtonen J, Kandolin R, et al. F-18-fluorodeoxyglucose positron emission tomography-guided sampling of mediastinal lymph nodes in the diagnosis of cardiac sarcoidosis. *Am J Cardiol* 2015;116:1581-5.
14. Tuominen H, Haarala A, Tikkakoski A, et al. 18F-FDG-PET in Finnish patients with clinical suspicion of cardiac sarcoidosis: Female sex and history of atrioventricular block increase the prevalence of positive PET findings. *J Nucl Cardiol* 2017. <https://doi.org/10.1007/s12350-017-0940>.
15. Yokoyama R, Miyagawa M, Okayama H, et al. Quantitative analysis of myocardial 18F-fluorodeoxyglucose uptake by PET/CT for detection of cardiac sarcoidosis. *Int J Cardiol* 2015;195:180-7.
16. Patel DC, Gunasekaran SS, Goettl C, Sweiss NJ, Lu Y. FDG PET-CT findings of extra-thoracic sarcoid are associated with cardiac sarcoid: A rationale for using FDG PET-CT for cardiac sarcoid evaluation. *J Nucl Cardiol* 2017. <https://doi.org/10.1007/s12350-017-0962-4>.
17. Blankstein R, Osborne M, Naya M, et al. Cardiac positron emission tomography enhances prognostic assessments of patients with suspected cardiac sarcoidosis. *J Am Coll Cardiol* 2014;63:329-36.
18. Oikawa M, Kagaya Y, Otani H, et al. Increased [18F]fluorodeoxyglucose accumulation in right ventricular free wall in patients with pulmonary hypertension and the effect of epoprostenol. *J Am Coll Cardiol* 2005;45:1849-55.
19. Preston IR, Klinger JR, Landzberg MJ, Houtchens J, Nelson D, Hill NS. Vasoresponsiveness of sarcoidosis-associated pulmonary hypertension. *Chest* 2001;120:866-72.
20. Handa T, Nagai S, Miki S, et al. Incidence of pulmonary hypertension and its clinical relevance in patients with sarcoidosis. *Chest* 2006;129:1246-52.
21. Mohsen A, Panday M, Wetherold S, Jimenez A. Cardiac sarcoidosis mimicking arrhythmogenic right ventricular dysplasia with high defibrillation threshold requiring subcutaneous shocking coil implantation. *Heart Lung Circ* 2012;21:46-9.
22. Manabe O, Yoshinaga K, Ohira H, et al. Right ventricular (18)F-FDG uptake is an important indicator for cardiac involvement in patients with suspected cardiac sarcoidosis. *Ann Nucl Med* 2014;28:656-63.
23. Hernandez Pampaloni M, Nazer B, Botvinick E. Isolated right ventricular cardiac sarcoidosis demonstrated by (1)(8)FDG positron emission tomography. *J Nucl Cardiol* 2014;21:652-4.
24. Chareonthaitawee P, Beanlands RS, Chen W, et al. Joint SNMMI-ASNC expert consensus document on the role of 18F-FDG PET/CT in cardiac sarcoid detection and therapy monitoring. *J Nucl Cardiol* 2017;58:1341-53.





# FDG-PET in possible cardiac sarcoidosis: Right ventricular uptake and high total cardiac metabolic activity predict cardiovascular events

Heikki Tuominen, MD,<sup>a</sup> Atte Haarala, MD, PhD,<sup>a</sup> Antti Tikkakoski, MD,<sup>a</sup> Mika Kähönen, MD, PhD,<sup>a,b</sup> Kjell Nikus, MD, PhD,<sup>b,c</sup> and Kalle Sipilä, MD, PhD<sup>a</sup>

<sup>a</sup> Department of Clinical Physiology and Nuclear Medicine, Tampere University Hospital, Tampere, Finland

<sup>b</sup> Faculty of Medicine and Health Technology, Tampere University, Tampere, Finland

<sup>c</sup> Department of Cardiology, Heart Center, Tampere University Hospital, Tampere, Finland

Received Dec 7, 2018; accepted Feb 1, 2019

doi:10.1007/s12350-019-01659-2

**Background.** Cardiac involvement accounts for the majority of morbidity and mortality in sarcoidosis. Pathological myocardial fluorodeoxyglucose (FDG)-uptake in positron emission tomography (PET) has been associated with cardiovascular events and quantitative metabolic parameters have been shown to add prognostic value. Our aim was to study whether the pattern of pathological cardiac FDG-uptake and quantitative parameters are able to predict cardiovascular events in patients with suspected cardiac sarcoidosis (CS).

**Methods.** 137 FDG-PET examinations performed in Tampere University Hospital were retrospectively analyzed visually and quantitatively. Location of pathological uptake was noted and pathological metabolic volume, average standardized uptake value (SUV), and total cardiac metabolic activity (tCMA) were calculated. Patients were followed for ventricular tachycardia, decrease in left ventricular ejection fraction, and death.

**Results.** Eleven patients had one or more cardiovascular events during the follow-up. Five patients out of 12 with uptake in both ventricles had an event during follow-up. Eight patients had high tCMA (> 900 MBq) and three of them had a cardiovascular event. Right ventricular uptake and tCMA were significantly associated with cardiovascular events during follow-up (*P*-value .001 and .018, respectively).

**Conclusions.** High tCMA and right ventricular uptake were significant risk markers for cardiac events among patient with suspected CS. (J Nucl Cardiol 2019)

**Key Words:** Sarcoid heart disease inflammation • PET • metabolism imaging agents

## Abbreviations

PET	Positron emission tomography
FDG	Fluorodeoxyglucose
CS	Cardiac sarcoidosis
LV	Left ventricle
RV	Right ventricle

CV	Cardiovascular
LVEF	Left ventricular ejection fraction
tCMA	Total cardiac metabolic activity
SUV	Standardized uptake value
AV	Atrio-ventricular

**Electronic supplementary material** The online version of this article (<https://doi.org/10.1007/s12350-019-01659-2>) contains supplementary material, which is available to authorized users.

The authors of this article have provided a PowerPoint file, available for download at SpringerLink, which summarises the contents of the paper and is free for re-use at meetings and presentations. Search for the article DOI on SpringerLink.com.

**Funding** Suomen Lääketieteen säätiö Suomen Klinisen fysiologian yhdistys Finska Läkaresällskapet.

Reprint requests: Heikki Tuominen, MD, Department of Clinical Physiology and Nuclear Medicine, Tampere University Hospital, 33520, Tampere, Finland; [heikki.p.tuominen@gmail.com](mailto:heikki.p.tuominen@gmail.com)  
1071-3581/\$34.00

Copyright © 2019 The Author(s)

## INTRODUCTION

Detecting cardiac involvement in sarcoidosis is essential, as it accounts for the majority of sarcoidosis-related deaths.<sup>1–3</sup> Cardiac <sup>18</sup>fluorodeoxyglucose positron emission tomography/computerized tomography (18FDG PET/CT) (later referred to as PET) has been used to identify active cardiac inflammation with a sensitivity and specificity of 89% and 78%, respectively.<sup>4</sup>

In early studies, the prognosis of cardiac sarcoidosis (CS) was poor and resulted in death within 2 years.<sup>5</sup> Later studies showed an overall improvement of prognosis. In a nationwide Finnish study of 110 CS patients, 9% died during a median follow-up of 79 months.<sup>6</sup> Left ventricular ejection fraction (LVEF) was the most powerful prognostic factor in CS patients treated with corticosteroids.<sup>7</sup> It is essential to start corticosteroid treatment early, as recovery of left ventricular function is more pronounced in patients with only moderately decreased LVEF. In patients with LVEF < 30%, corticosteroid therapy did not improve cardiac function.<sup>8</sup> In addition to degrading function, CS may also cause ventricular arrhythmias, sometimes with fatal consequences.<sup>9–11</sup>

Existing literature on the prognostic value of PET is relatively scarce, but it has been shown to enhance the prognostic assessment of CS beyond the Japanese Ministry of Health and Welfare (JMWH) criteria.<sup>12,13</sup> According to Ahmadian et al., total cardiac metabolic activity (tCMA) independently predicted cardiac events in patients with previously diagnosed sarcoidosis.<sup>14</sup> On the other hand, a study comparing findings in consecutive PET- and cardiac magnetic resonance imaging (CMR) studies reported no prognostic value of PET-findings among patients with late gadolinium enhancement (LGE) in CMR.<sup>15</sup>

Our aim was to study how visual and quantitative PET-imaging parameters performed in predicting cardiovascular (CV) events in a clinical cohort of patients referred to PET-imaging for suspected CS.

## METHODS

### Study Population

We retrospectively screened all cardiac PET studies performed in the Tampere University Hospital from August 2012 to September 2015. We excluded studies, in which the clinical indication was not CS suspicion, if the patient's clinical data could not be obtained or PET-study was performed for follow-up of previously diagnosed CS. Imaging studies were also excluded if the dedicated imaging protocol described below was not followed precisely. Altogether, 137 PET examinations were analyzed for the present study. In our

hospital, PET is routinely performed in the diagnostic workup of possible CS. The reason for the clinical suspicion of CS was one or more of the following: unexplained atrio-ventricular (AV) block ( $n = 61$ ), ventricular ( $n = 39$ ), or supraventricular ( $n = 13$ ) arrhythmia, unexplained dilated cardiomyopathy ( $n = 27$ ), or unexplained low ejection fraction on echocardiography ( $n = 46$ ), other echocardiographic findings suggestive of CS ( $n = 53$ ), or syncope ( $n = 27$ ). The referring cardiologist considered the symptoms and clinical findings as inconclusive after routine evaluation, including clinical examination, ECG, and echocardiography. Coronary angiography was performed in cases with a clinical suspicion of coronary artery disease.

### PET-Imaging

All patients underwent an integrated PET/CT (Discovery STE 16, GE Healthcare, Milwaukee, WI, USA) examination. To minimize physiological myocardial FDG-uptake, the patients were instructed not to consume any carbohydrates during the day before the imaging exam and to fast for 12 h before the FDG injection. The patients maintained a food diary during the prescribed diet. The patients were also instructed to avoid heavy physical exercise to minimize FDG-uptake in skeletal muscle. Patient height and weight were measured before the administration of the radiopharmaceutical, and blood glucose levels were tested to confirm a level of < 7 mmol/l. The PET/CT images were acquired approximately 60 min after the intravenous injection of FDG using the Medrad® Intego PET infusion system (Bayer Medical Care Inc., Indianola, PA, USA). In our hospital, the activity injected is based on the patient's weight (3–3.2 MBq/kg). The imaging protocol has been described in more detail previously.<sup>16</sup>

### Analysis of PET Images

We classified the uptake pattern in the left ventricular (LV) myocardium according to the recommendations of the Japanese Society of Nuclear Cardiology as 'none' (no activity exceeding normal blood pool activity), 'global diffuse' (uniform activity over the entire myocardium), 'focal' (focally increased spot(s) of activity, other regions inactive), 'focal on diffuse' (intense focal spot(s) of activity overlapping global myocardial activity), or 'diffuse non-global' (faint activity on at least two LV walls, but at least some areas of myocardium with no activity over normal blood pool activity). Diffuse non-global uptake is not mentioned in the Japanese Society of Nuclear Cardiology recommendations but was considered to be a similar physiological phenomenon as diffuse uptake. The uptake was considered physiological if it was classified as none, global diffuse, or diffuse non-global. Uptake was considered pathological if it was classified as focal or focal on diffuse. We also classified the uptake in the right ventricle (RV) in a similar manner. The maximum standardized uptake value (SUV<sub>max</sub>) in the heart was measured and its location was determined. Extracardiac uptake in the lymph nodes was considered pathological if it exceeded that of the mediastinal blood pool. The areas inspected for possible pathological extracardiac uptake included lymph nodes in axillary,

subclavicular, mediastinal, hilar, and epigastric sites. Pathological FDG-uptake in the lung parenchyma, liver, spleen, and bone marrow were also noted. Uptake in the liver, spleen and lung parenchyma was considered pathological if there were spots of metabolic activity exceeding the physiological uptake of the surrounding parenchyma. Bone marrow uptake was considered pathological if focal uptake exceeding that of the liver was noted. The images were interpreted after patient anonymization and randomization. The images were separately interpreted by two experienced nuclear medicine physicians (HT, 10 years of experience and KS, 15 years of experience) blinded to all clinical data. In cases where the interpretation of LV-uptake differed between the observers, a consensus was reached and used in further analyses. After this initial analysis, the quantitative parameters were measured using PETVCAR software on GE Advantage workstation (GE Healthcare, Milwaukee, WI, USA). Blood pool SUV<sub>mean</sub> was first measured from ascending aorta. A threshold for abnormal cardiac uptake was defined as blood pool SUV<sub>mean</sub> × 1.5. This value was used to delineate metabolic volume. SUV<sub>mean</sub> over metabolic volume was measured and used to calculate tCMA by multiplying the metabolic volume by SUV<sub>mean</sub>.<sup>14</sup> Cut-off for high tCMA was defined as 900 MBq that is approximately tCMA + 2SD in the group with no events.

### Collection of Clinical Data

Clinical data were retrospectively collected from the electronic medical record system of Tampere University Hospital, which contains information from 2008 onward. We collected demographic information, echocardiography findings, MRI-findings, relevant diagnoses, symptoms and endomyocardial biopsy (EMB) findings, deaths, healthcare visits, and hospitalizations for ventricular tachyarrhythmia. Systolic function evaluated by echocardiography was categorized as normal (>50%), decreased (35-50%) or (poor < 35%). Echocardiography findings were collected from studies performed nearest to PET-study and the last echocardiography study of the follow-up period. Diagnosis of CS by cardiologists was based on EMB or a combination of other biopsy verification of sarcoidosis and clinical and/or imaging findings indicating cardiac involvement. Electronic health record data for follow-up were available from the Tampere University Hospital.

### Cardiovascular Events

Cardiac events of interest were reduction in LVEF, hospitalization due to cardiac arrhythmia, and death. Change in LVEF was determined by comparing the findings between echocardiography studies performed nearest to the PET-study and the last study of the follow-up period. Decrease in LVEF was defined as a negative change in LVEF category defined above. We used hospital admission as a definition of severe ventricular arrhythmia as the number of other detected ventricular arrhythmias was highly dependent on whether or not the patient had a pacemaker or implanted cardioverter-defibrillator (ICD).

### Statistical Methods

Statistical analyses were performed using IBM SPSS statistics version 22.0 (Armonk, NY, USA) and R software version 3.2.2. *T* test was used to compare quantitative metabolic parameters between patients, who had CV events and those with no events. Comparison of quantitative parameters also included patients with physiological FDG-uptake. Chi square test was used to test the statistical difference in dichotomous variables between groups. Survival analysis was performed with log-rank test.

### RESULTS

Baseline characteristics, PET-findings and treatment during follow-up for patients with and without CV events are presented in Table 1. 35 (26%) patients had a diagnosed sarcoidosis prior to imaging or during follow-up. Cardiac sarcoidosis was diagnosed in 18 (13%) patients and in 7 patients (5%) it was confirmed by EMB.

33 (24%) patients had pathological myocardial FDG-uptake: 28 patients had a focal and 5 had a focal on diffuse pattern. 12 patients (9%) had pathological FDG-uptake in RV. All the patients with RV-uptake also had LV-uptake. Of the 104 (76%) patients without pathological uptake 85 (82%) had no visible uptake, three (3%) had diffuse uptake over LV and 16 (15%) had diffuse non-global uptake pattern. One patient had diffuse and one had diffuse non-global uptake in RV myocardium.

The follow-up time varied between 25.2 to 62.6 months (2.1-5.2 year), mean 54.7 months (3.74 years). Altogether, 11 patients had at least one event during follow-up: seven were hospitalized because of ventricular tachycardia, five had worsening of systolic LV function and three patients died. There was no significant difference in baseline characteristics between patients, who had events, and those who did not. Also, cardiac events were not significantly more common in patients who were diagnosed with CS according to diagnostic criteria.

CMR had been performed in 37 patients, of whom 19 (51%) had LGE. Of those 19 patients four (21%) had a CV event during follow-up. In the subset of patients with CMR data, all those subjects who had a CV event also had LGE.

Cardiac SUV<sub>max</sub> and tCMA were higher in patients who had CV events compared to those with no events: 7.1 vs 4.4 and 530 MBq vs 163 MBq, respectively (*P* < .001 for both). There were 33 patients with abnormal LV-uptake on PET and 12 of them had abnormal uptake also in the RV. Five (15%) out of 33 patients with pathological cardiac uptake on PET had a CV event on follow-up. All five had pathological uptake

**Table 1.** Baseline characteristics, PET-findings and treatment during follow-up in patients with and without events during follow-up

	Patients with events <i>n</i> = 11	Patients with no events <i>n</i> = 126	<i>P</i> -value
<b>Baseline characteristics</b>			
Female sex	45% (5)	43% (54)	.556
Age, years (SD)	37 (8)	45 (13)	.062
Follow-up, mo (SD)	50 (8)	44 (11)	.059
Reduced LVEF at baseline	73% (8)	54% (68)	.190
<b>PET</b>			
Pathological LV-uptake	46% (5)	22% (28)	.091
Pathological RV-uptake	46% (5)	6% (7)	< .001
tCMA > 900 MBq	27% (3)	4% (5)	.018
Extracardiac uptake	36% (4)	20% (25)	.180
SUVmax	7.1 (5.6)	4.4 (2.8)	< .001
Metabolic volume (cm <sup>3</sup> )	105 (167)	44 (96)	.050
tCMA (MBq)	530 (886)	163 (388)	< .001
<b>Treatment</b>			
ICD	100% (11)	18% (12)	< .001
Anti-inflammatory medication	46% (5)	18% (22)	.041
CS-diagnosis by the end of follow-up	27% (3)	20% (15)	.148

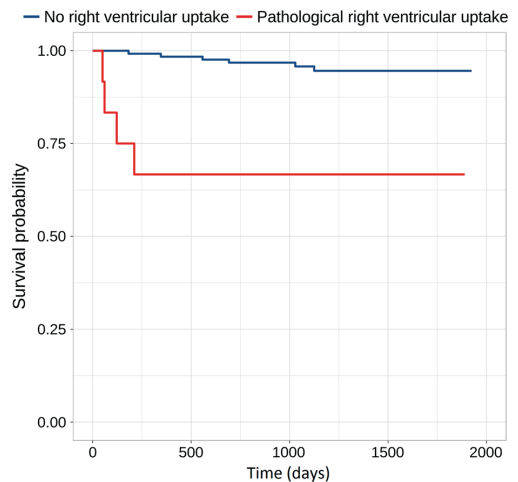
Values are % (*n*) for dichotomous and mean (SD) for continuous variables

LVEF, left ventricular ejection fraction; LV, left ventricle; RV, right ventricle, SUV, standardized uptake value; metabolic volume, volume of myocardium with SUV > 1.5 × aortic reference SUV; SUV<sub>mean</sub>, mean SUV over pathological metabolic volume; tCMA, total cardiac metabolic activity calculated as SUV<sub>mean</sub> × metabolic volume; ICD, implantable cardioverter-defibrillator; CS, cardiac sarcoidosis

also in the RV. Pathological RV-uptake was significantly more common in patients with CV events compared to those without events (*P* = .001). Event-free survival curves in patients with and without pathological RV-uptake are shown in Figure 1.

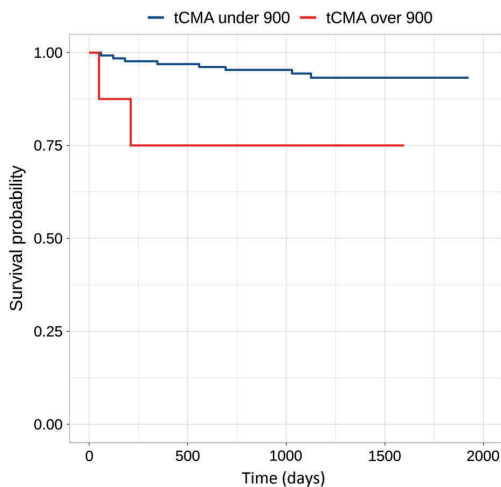
Eight patients had tCMA > 900 MBq and three (38%) of them had a CV event compared to only 6% of those with tCMA < 900 MBq. All these three patients also had pathological RV-uptake. Patients with pathological RV-uptake had significantly higher tCMA compared to those without RV-uptake: 914 (SD.706) vs. 123 (SD 356) MBq (*P* < .001). There were only 5 patients who had both high tCMA and RV-uptake, and 3 (60%) of them had a CV event. Event-free survival curves in patients with high and low tCMA are shown in Figure 2.

In survival analysis, pathological RV-uptake was a significant predictor of cardiac events (*P* = .001). Also high tCMA > 900 MBq significantly predicted events (*P* = .032). Decreased baseline LVEF, pathological LV-uptake or extracardiac FDG-uptake did not significantly



**Figure 1.** Survival free of cardiac events in patients with no right ventricular uptake and in those with pathological right ventricular uptake. Between groups the *P*-value is .001.





**Figure 2.** Survival free of cardiac events in patients with tCMA below or above 900 MBq. Between groups the *P*-value is .032.

predict CV events during follow-up ( $P = .094, .217$  and  $.489$ , respectively).

## DISCUSSION

We examined the value of cardiac FDG-PET in predicting CV events in patients with a suspicion of CS. Pathological RV-uptake was the strongest imaging-related predictor of future CV events defined as a decrease in LVEF, hospitalization for ventricular tachycardia (VT), or death. Also, the quantitative parameter tCMA was a significant predictor of events.

Decreased LVEF has been recognized as an important predictor of long-term outcome in CS patients treated with corticosteroids.<sup>7</sup> In our population, the majority of the patients who suffered for cardiac events had decreased LVEF at baseline. However, decreased LVEF had poor predictive value, as the majority of the patients in our population were referred for imaging because of unexplained cardiac failure. In fact, pathological cardiac FDG-uptake was more common among patients with normal LVEF than in those with cardiac failure.<sup>16</sup> This reflects the problem of recognizing the patients with cardiac findings with increased risk for major cardiac events.

Previously Blankstein et al. have reported that pathological cardiac PET-findings predict VT and mortality better than a CS-diagnosis by JMWH criteria and independently of LVEF.<sup>12</sup> FDG-uptake in the RV indicated a fivefold risk of cardiac events compared to those with normal PET and myocardial perfusion in

their study. In another study, myocardial perfusion-metabolism mismatch (metabolism assessed by PET) was related to cardiac events in patients assessed for possible cardiac sarcoidosis.<sup>13</sup> PET has also been shown to predict major cardiac events in patients with unexplained atrio-ventricular block, a common manifestation of sarcoidosis.<sup>17</sup>

Furthermore, quantitative evaluation of myocardial metabolic activity in PET has been shown to predict cardiac events in some studies. Muser et al. showed that a temporal decrease in tCMA indicated a lower risk of events.<sup>18</sup> Ishiyama et al. reported that SUVmax over all sarcoidosis-involved organs better predicted response to oral corticosteroids than tCMA in patients with CS.<sup>19</sup>

LGE in CMR has been shown to be a strong predictor of cardiac events in patients with proven systemic sarcoidosis even in patients with preserved LVEF.<sup>20,21</sup> Bravo et al. studied PET and CMR in patients with clinical manifestations of CS and found that LGE predicted cardiac events similarly in PET-positive and PET-negative patients. They concluded that the risk of sustained VT and death were associated with myocardial scarring but not to active inflammation.<sup>15</sup> However, they did not analyze PET-findings beyond negative/positive. Indeed, PET positivity per se was not predictive of cardiac events in our population either. The predictive value in our study was particularly associated with pathological RV-uptake. Interestingly, Murtagh et al. showed that ventricular dysfunction in addition to the large burden of cardiac LGE denoted a high risk of cardiac events.<sup>21</sup> In another recent study, it was shown that RV LGE predicted cardiac events.<sup>22</sup> Both MRI and PET studies confirm the prognostic importance of abnormal RV imaging findings. Moreover, electrophysiological studies have shown that RV scarring is a common finding in CS patients with VT.<sup>23</sup> RV scarring was often found to be confluent in comparison to patchy scarring in the left ventricle, providing large amount of substrate for re-entry circuits.<sup>24</sup>

In our population CMR was performed only in a subset of 39 patients of whom 19 (51%) had LGE. There was an association between reported LGE and CV events ( $P$ -value .039). Significantly, in this subset of available CMR data, there were no CV events in patients without LGE. Thus, negative CMR seems to have very good negative predictive value. As the number of events was low we could not perform further analyses for independent role of PET-findings in this subgroup. However, a significant proportion of patients suspected for CS had a pacemaker or ICD, and in those patients CMR may not be feasible and for this reason we consider our results on the prognostic role of PET-findings relevant.

We also found that the quantitative parameter tCMA predicts cardiac events. This is in line with the results reported by Ahmadian et al., that high tCMA predicts ventricular tachyarrhythmias and death.<sup>14</sup> However, they did not report the possible pathological uptake in RV. Sixty-three percent of our 8 patients in high tCMA group had RV-uptake, and all the high tCMA patients who had events also had pathological RV-uptake. The combination of RV-uptake and high tCMA signified 60% risk for events and should always be communicated clearly to the clinician. Right ventricular uptake is easily recognized while interpreting PET studies making it a useful sign of high risk in every day practice.

In our population, only a minority (13%) of patients had sarcoidosis confirmed by biopsy. Other diseases like viral or giant cell myocarditis can cause pathological myocardial uptake. Interestingly, patients with diagnosed CS did not have more cardiac events than those without CS-diagnosis (Table 1). We consider this finding to be clinically significant as cardiologists should consider patients with a high burden of cardiac glycolysis and/or right ventricular RV-uptake to be a high-risk group whether or not they fulfill the diagnostic criteria for CS.

We had access only to the information in the patient record of Tampere University Hospital. Possible contacts to other health care facilities were not recorded and some endpoint events may have been missed. The number of recorded cardiac events during follow-up was relatively low. Due to the small number of events, multivariable analysis was not feasible. Also, CMR data were available only in a small proportion of the patients. This prevented us from analyzing the effect of myocardial scarring on the predictive value of PET-findings. This, however, is often the clinical reality in patients with a suspicion of CS due to conduction disturbances or VT requiring a pacemaker or ICD. Our population is heterogeneous and majority of the patients do not fulfill diagnostic criteria for CS. However, the population is representative of the true clinical situation and the results can be applied to everyday clinical decision making. Regrettably, we have no data on follow-up PET studies. Changes in tCMA and RV-uptake status by treatment and impact of these changes on prognosis will be an interesting topic for future research. Our population consists of white Caucasians and, as sarcoidosis is known to have different representations in different populations our results may not be generalizable to other populations.

## CONCLUSION

Among patients referred for FDG-PET imaging to assess possible cardiac sarcoidosis, pathological right ventricular uptake and a high burden of cardiac glycolysis predict adverse cardiac events during follow-up. A combination of pathological RV-uptake and high tCMA signified very high risk for future CV events. Nuclear medicine physicians should be aware of this and communicate such findings clearly to the clinician.

## NEW KNOWLEDGE GAINED

Pathological FDG-uptake in right ventricle is easy to observe and should be considered as a significant risk marker in patients with suspected cardiac sarcoidosis especially if present in combination with high total cardiac metabolic activity.

## Disclosures

*Heikki Tuominen, Atte Haarala, Antti Tikkakoski, Mika Kähönen, Kjøll Nikus and Kalle Sipilä declares that they have no nothing to disclose.*

## Open Access

*This article is distributed under the terms of the Creative Commons Attribution 4.0 International License (<http://creativecommons.org/licenses/by/4.0/>), which permits unrestricted use, distribution, and reproduction in any medium, provided you give appropriate credit to the original author(s) and the source, provide a link to the Creative Commons license, and indicate if changes were made.*

## References

1. Okura Y, Dec GW, Hare JM, et al. A clinical and histopathologic comparison of cardiac sarcoidosis and idiopathic giant cell myocarditis. *J Am Coll Cardiol* 2003;41:322-9.
2. Schatka I, Bengel FM. Advanced imaging of cardiac sarcoidosis. *J Nucl Med* 2014;55:99-106.
3. Gideon NM, Mannino DM. Sarcoidosis mortality in the united states 1979-1991: An analysis of multiple-cause mortality data. *Am J Med* 1996;100:423-7.
4. Youssef G, Leung E, Mylonas I, et al. The use of 18F-FDG PET in the diagnosis of cardiac sarcoidosis: A systematic review and metaanalysis including the ontario experience. *J Nucl Med* 2012;53:241-8.
5. Roberts WC, McAllister HA, Jr, Ferrans VJ. Sarcoidosis of the heart. A clinicopathologic study of 35 necropsy patients (group 1) and review of 78 previously described necropsy patients (group 11). *Am J Med* 1977;63(1):86-108.
6. Kandolin R, Lehtonen J, Airaksinen J, et al. Cardiac sarcoidosis: Epidemiology, characteristics, and outcome over 25 years in a nationwide study. *Circulation* 2015;131:624-32.

7. Yazaki Y, Isobe M, Hiroe M, et al. Prognostic determinants of long-term survival in Japanese patients with cardiac sarcoidosis treated with prednisone. *Am J Cardiol* 2001;88:1006-10.
8. Chiu CZ, Nakatani S, Zhang G, et al. Prevention of left ventricular remodeling by long-term corticosteroid therapy in patients with cardiac sarcoidosis. *Am J Cardiol* 2005;95:143-6.
9. Nery PB, Leung E, Birnie DH. Arrhythmias in cardiac sarcoidosis: Diagnosis and treatment. *Curr Opin Cardiol* 2012;27:181-9.
10. Uusimaa P, Ylitalo K, Anttonen O, et al. Ventricular tachyarrhythmia as a primary presentation of sarcoidosis. *Europace* 2008;10:760-6.
11. Nery PB, Mc Ardle BA, Redpath CJ, et al. Prevalence of cardiac sarcoidosis in patients presenting with monomorphic ventricular tachycardia. *Pacing Clin Electrophysiol* 2014;37:364-74.
12. Blankstein R, Osborne M, Naya M, et al. Cardiac positron emission tomography enhances prognostic assessments of patients with suspected cardiac sarcoidosis. *J Am Coll Cardiol* 2014;63:329-36.
13. Sperry BW, Tamarappoo BK, Oldan JD, et al. Prognostic impact of extent, severity, and heterogeneity of abnormalities on (18)F-FDG PET scans for suspected cardiac sarcoidosis. *JACC Cardiovasc Imaging* 2018;11:336-45.
14. Ahmadian A, Brogan A, Berman J, et al. Quantitative interpretation of FDG PET/CT with myocardial perfusion imaging increases diagnostic information in the evaluation of cardiac sarcoidosis. *J Nucl Cardiol* 2014;21:925-39.
15. Bravo PE, Raghu G, Rosenthal DG, et al. Risk assessment of patients with clinical manifestations of cardiac sarcoidosis with positron emission tomography and magnetic resonance imaging. *Int J Cardiol* 2017;241:457-62. <https://doi.org/10.1016/j.ijcard.2017.03.033>.
16. Tuominen H, Haarala A, Tikkakoski A, et al. 18F-FDG-PET in Finnish patients with clinical suspicion of cardiac sarcoidosis: Female sex and history of atrioventricular block increase the prevalence of positive PET findings. *J Nucl Cardiol* 2017. <https://doi.org/10.1007/s12350-017-0940-x>
17. Danwade TA, Devidutta S, Shelke AB, et al. Prognostic value of fluorine-18 fluoro-2-deoxyglucose positron emission computed tomography in patients with unexplained atrioventricular block. *Heart Rhythm* 2018;15:234-9.
18. Muser D, Santangeli P, Castro SA, et al. Prognostic role of serial quantitative evaluation of (18)F-fluorodeoxyglucose uptake by PET/CT in patients with cardiac sarcoidosis presenting with ventricular tachycardia. *Eur J Nucl Med Mol Imaging* 2018;45:1394-404.
19. Ishiyama M, Soine LA, Vesselle HJ. Semi-quantitative metabolic values on FDG PET/CT including extracardiac sites of disease as a predictor of treatment course in patients with cardiac sarcoidosis. *EJNMMI Res* 2017;7(1):67-017-0315-y.
20. Greulich S, Deluigi CC, Gloekler S, et al. CMR imaging predicts death and other adverse events in suspected cardiac sarcoidosis. *JACC Cardiovasc Imaging* 2013;6:501-11.
21. Murtagh G, Laffin LJ, Beshai JF, et al. Prognosis of myocardial damage in sarcoidosis patients with preserved left ventricular ejection fraction: Risk stratification using cardiovascular magnetic resonance. *Circ Cardiovasc Imaging* 2016;9:e003738.
22. Smedema JP, van Geuns RJ, Ector J, Heidbuchel H, Ainslie G, Crijns HJGM. Right ventricular involvement and the extent of left ventricular enhancement with magnetic resonance predict adverse outcome in pulmonary sarcoidosis. *ESC Heart Fail* 2018;5:157-71.
23. Koplán BA, Soejima K, Baughman K, Epstein LM, Stevenson WG. Refractory ventricular tachycardia secondary to cardiac sarcoid: Electrophysiologic characteristics, mapping, and ablation. *Heart Rhythm* 2006;3:924-9.
24. Kumar S, Barbhuiya C, Nagashima K, et al. Ventricular tachycardia in cardiac sarcoidosis: Characterization of ventricular substrate and outcomes of catheter ablation. *Circ Arrhythm Electrophysiol* 2015;8:87-93.

**Publisher's Note** Springer Nature remains neutral with regard to jurisdictional claims in published maps and institutional affiliations.





