

This is the accepted manuscript of the article, which has been published in **Journal of Electrocardiology**. 2019 vol 55, 107-110.
<https://doi.org/10.1016/j.jelectrocard.2019.05.012>

**Electrocardiographic findings of acute total occlusion associated with a sub-occlusion
involving the left anterior descending and the right coronary artery**

Zhong-Qun Zhan MD¹, Yang-Hua Li MS¹, Yang Li MS¹, Jian-Ping Li MS¹, Kjell C. Nikus MD²

¹Department of Cardiology, Shenzhen Hospital-University of Chinese Academy of Sciences, Guangming district, Shenzhen City, P.R. China

²Department of Cardiology, Heart Center, Tampere University Hospital, Tampere and Faculty of Medicine and Health Technology, Tampere University Hospital, Finland

Zhong-Qun Zhan: zzqun21@126.com

Yang-Hua Li: 983696282@qq.com

Yang Li: 115363847@qq.com

Kjell C. Nikus: Kjell.Nikus@sydankeskus.fi

Jian-Ping Li: ljplshg@163.com

Address for correspondence: Zhong-Qun Zhan MD, Department of Cardiology, Shenzhen Hospital-University of Chinese Academy of Sciences, Guangming district, Shenzhen, P.R. China.

E-mail: zzqun21@126.com

Running Head: ECG findings of two-vessel occlusion

Word count: 150 for the abstract and 2250 for the text

Abstract page:

Background: The ECG characteristics of simultaneous acute occlusion/sub-occlusion of two coronary arteries involving the left anterior descending (LAD) and right (RCA) coronary artery have been rarely described in the literature. **Methods:** We present two patient cases, where one of the arteries was totally occluded and the other one had a sub-occlusion with severely limited flow to demonstrate the ECG characteristics of this severe presentation of acute coronary syndrome.

Results: Two ECG patterns suggested simultaneous occlusions of the RCA and LAD. One pattern was ST-segment elevation (STE) in lead III higher than in lead II with concomitant STE in leads V3-V4. The other pattern was STE in lead III higher than in lead II with the concomitant Dressler - de Winter ECG pattern in leads V2-V4. **Conclusions:** We present two ECG presentations of simultaneous RCA and LAD occlusion/sub-occlusion. We consider these ECG features as high-risk markers in acute ST-elevation myocardial infarction.

Key words: acute myocardial infarction, electrocardiogram, the Dressler - de Winter ECG pattern, acute coronary occlusion, percutaneous coronary intervention

Introduction

The 12-lead ECG continues to play a crucial role in the decision making about treatment strategies and culprit artery prediction in ST-segment elevation myocardial infarction (STEMI). The ECG characteristics of acute simultaneous occlusion of two coronary arteries have been rarely described in the literature ^[1]. Here we present two patient cases to illustrate ECG manifestations indicative of acute simultaneous occlusion/sub-occlusion of the left anterior descending (LAD) and right (RCA) coronary artery. One of the coronary arteries was totally occluded, the other one had a sub-occlusion with severely impaired flow, and this combination resulted in two very rare ECG manifestations of STEMI.

Case presentations

Case 1

A 50-year old male was transferred to the Emergency Department due to persistent chest pain, sweating and dizziness for three hours. The patient was given urokinase 1.5-million-unit thrombolytic therapy two hours earlier in a local hospital. The blood pressure (BP) was 60/40 mmHg. Cardiac auscultation revealed soft heart sounds without murmurs. Wet rales could be heard over both lower lung fields. Risk factors included smoking, hypertension and obesity. ECG on admission (Fig. 1A) showed extensive STE in leads II, III, aVF, V1, V3-V9 and V3R-V5R (Fig. 1A). Troponin I was 50 ng/ml (normal value <50 ng/ml) and NT-proBNP 2578 pg/ml (normal value <300 pg/ml). With dopamine infusion, the BP rose to 90/60 mmHg. STEMI was diagnosed, and the patient was directly transferred to the catheterization room for rescue percutaneous coronary intervention. The angiography revealed a very tight stenosis with thrombus (99% obstruction with Thrombolysis In Myocardial Infarction (TIMI) 1 flow) of the proximal RCA and a total occlusion of the distal LAD (Fig. 1B and 1C). The BP continued to drop before the intervention and noradrenaline was added to maintain hemodynamic stability. The RCA (Fig. 1B) was quickly opened after the guidewire was easily passed through the occlusion site and a stent was implanted in the proximal RCA; TIMI 3 blood flow was restored (Fig. 1E). The patient's BP was elevated to 110-120/60-70mmHg, sweating stopped and chest pain was alleviated. Based on the ECG showing STE also in leads V3-V4, the LAD was considered as a second culprit artery. Hence, the intervention was continued. Thrombus was aspirated from the occlusion site in the distal LAD. The LAD was also quickly opened and a stent was implanted with restored TIMI 3 blood (Fig. 1F). The ECG after reperfusion showed

negative T waves in leads II, III, aVF, V5, V6, and V3R-V5R, and there was almost complete ST resolution. The patient recovered well and was discharged home on the fourth day of hospital stay.

Case 2

A 55-year old male was transferred to the Emergency Department due to oppressive chest pain, diaphoresis and vomiting for two hours. He had no history of cardiopulmonary disease. Risk factors included heavy smoking and hypertension. His BP was 95/55 mmHg. Troponin I was 150 ng/ml (normal value <50 ng/ml) and NT-proBNP 2130 pg/ml (normal value <300 pg/ml). ECG on admission (Fig.2A) showed STE in leads II, III, aVF, V4R-V5R and V7, poor progression of precordial R-waves with upsloping ST-segment depression followed by tall positive symmetrical T waves in V2-V4 (Fig. 2A). STEMI was diagnosed and the patient was quickly transferred to the catheterization laboratory for primary percutaneous coronary intervention, which revealed total occlusion of the proximal RCA and critical sub-occlusion of the mid LAD with (99% obstruction with TIMI 1 flow) (Fig.2C). The RCA was quickly opened and TIMI 3 blood flow was restored after thrombus aspiration from the occlusion site and stent implantation was performed (Fig.2E). Based on the ECG showing poor progression of R-wave with concomitant upsloping ST-segment depression followed by tall positive symmetrical T waves in V2-V4 and total occlusion of the LAD (Fig.2C), the LAD was considered as a second culprit artery. Therefore, the LAD was easily and quickly opened and after stent implantation TIMI 3 blood flow was restored in the LAD, which terminated before the left ventricular apex (Fig.2F). The ECG (Fig.2D) after reperfusion showed resolution of the ST-segment deviations, and disappearance of prominent T-waves in leads V2-V4. The patient recovered well and was discharged home on the eighth day of hospital stay. **Discussion**

Here we present two types of ECG patterns indicative of acute simultaneous total/sub-total occlusions of the RCA and LAD. One ECG manifestation was STE in lead III higher than in lead II with concomitant STE in leads V3-V4. The other type was STE in lead III higher than in lead II with concomitant ST-segment depression followed by tall positive symmetrical T waves in V2-V4.

Case 1 presents an exceptional ECG manifestation of extensive STE in the 14/18 leads caused by acute total occlusion of the proximal RCA and distal LAD. The abnormal ECG findings include prominent STE in the inferior leads (3 mm in lead II, 5 mm in lead III, 4 mm in lead aVF), intermediate STE in the right ventricular precordial leads (2.5 mm in lead V3R, 3 mm in lead V4R,

2.5 mm in lead V5R, and 1.5 mm in lead V1) and mild STE in the precordial leads (about 2 mm in leads V3-V4 and about 1mm in leads V5-V9). Prominent STE in the inferior leads and intermediate STE in the right ventricular precordial leads indicate a culprit lesion in the proximal RCA. Mild STE in the precordial leads from V5 to V9 indicates that the culprit RCA was dominant. However, STE in leads V3 and V4 is unusual in patients with dominant RCA occlusion. Acute dominant RCA occlusion is usually responsible for STE in the inferior and posterior leads, and even leads V5-V6, but leads V3-V4 are usually spared [2, 3]. In patients with acute LAD occlusion, maximum STE is usually found in leads V3-V4 [2], although anatomical variation of the coronary arteries in acute coronary occlusion can result in this ECG pattern. An isolated acute occlusion of a right posterior descending branch of the RCA extending distal to the ventricular apex to supply part of the left ventricular anterior wall, can result in STE in the inferior leads and in leads V3-V4 [4, 5]. This ECG pattern was reported in a patient with acute LAD occlusion with an anomalous RCA originating from the mid-LAD [6]. An alternative explanation is that the RCA was chronically sub-occluded and received collateral circulation from the LAD. When LAD occluded, transmural ischemia occurred in the two coronary territories and possibly the manifestations were more evident in the territory of the dominant RCA. However, we think that the fact that thrombus could be seen in the sub-occluded RCA and the guidewire was easily crossed through the lesion makes this possibility unlikely.

Case 2 presents an exceptional ECG manifestation of STE in lead III higher than in lead II with concomitant ST-segment depression following by tall positive symmetrical T waves in V2-V4 caused by acute simultaneous total occlusion/sub-occlusion of the proximal RCA and distal LAD. STE in leads II, III, aVF (STE in III higher than in II), V4R-V5R and V7 indicate RCA as the culprit

artery. However, an interesting ECG pattern namely the Dressler - de Winter sign^[9, 10] simultaneously occurred in the same case. The Dressler - de Winter sign manifests as upsloping ST-segment depression at the J point in leads V1/V2-V4/V6 that continues into tall, positive symmetrical T waves^[11]. This sign is often combined with poor progression of the precordial R-wave. In the Dressler - de Winter sign of acute LAD occlusion, the maximum ST-segment depression is found in leads V2-V4^[10]. The ECG presentations in leads V2-V4 in case 2 are typical for the Dressler - de Winter sign of acute LAD occlusion. Therefore, we had predicted that both the RCA and LAD were occluded. In both patients, we decided to use the definition “sub-occlusion” of the artery with TIMI 1 flow. Some authors^[12] prefer the term total occlusion also for this angiographic manifestation (TIMI 1 flow and sub-total occlusion). In addition to the ECG findings, the angiographic presentation and the behavior of the lesion during the invasive procedure indicated acute lesions in the culprit arteries.

ST-segment depression or junctional ST-segment depression continuing into tall, positive symmetrical T waves have been considered as an indication of subendocardial ischemia or myocardial protection through collateral circulation or ischemic preconditioning but not as an expression of transmural ischemia^[2, 13-15]. We think that the angiography findings in case 2 support the hypothesis that the Dressler - de Winter sign represents subendocardial ischemia. An alternative explanation is that the LAD had a chronic sub-occlusion and received collateral circulation from the RCA. When RCA occluded, there was transmural ischemia in the territory of the RCA and subendocardial ischemia in the territory of the LAD with a Dressler-Winter pattern because the area was partially protected due to the sub-occluded LAD. However, there was no visible collateral circulation from the patent RCA with TIMI 3 blood flow, the patient had no history of chest discomfort and LAD was easily opened. We think that these facts together make this possibility less likely. We hypothesize that STE in lead III higher than in lead II with a concomitant Dressler - de Winter sign in V2-V4 is highly indicative of acute total/sub-total RCA and LAD occlusion. It is very important for physicians to utilize all the diagnostic information present in the ECG leads with ischemic changes to tailor the interventional therapeutic strategy. ECG patterns suggestive of simultaneous acute occlusion/sub-occlusion of the RCA and LAD. One pattern was STE in lead III higher than in lead II with concomitant STE in leads V3-V4. The other pattern was STE in lead III higher than in lead II with

a concomitant Dressler - de Winter sign in leads V2-V4. It is very important for treating physicians to recognize these two ECG patterns to tailor interventional therapeutic strategy.

References

- [1] Afzal A, Patel B, Patel N, Sattur S, Patel V. Simultaneous Two-Vessel Subacute Stent Thrombosis Caused by Clopidogrel Resistance from CYP2C19 Polymorphism. *Case Rep Med*. 2016. 2016: 2312078.
- [2] Sclarovsky S. *The Electrocardiogram in the Acute Ischemic Syndrome*. London: Martin Dunitz Publishers, 1999.
- [3] Sclarovsky S. Physiological and pathological remodeling in acute inferior wall myocardial infarction. *Isr Med Assoc J*. 2013. 15(4): 143-6.
- [4] Tamura A, Hazuku T, Kadota J. ST-segment elevation in leads V3 and V4 during balloon angioplasty of the "wrapped" posterior descending artery in the right coronary artery. *Int J Cardiol*. 2006. 113(1): E24-5.
- [5] Shan P, Li S, Huang Z, Huang W. A case of simultaneous anterior and inferior ST-segment elevation myocardial infarction due to isolated occlusion of a wrapped right posterior descending artery. *J Electrocardiol*. 2013. 46(1): 13-5.
- [6] Kaplan Ö, Demircan S. Case Image: Inferior and anterior ST-segment elevation and successful percutaneous coronary intervention in a patient with anomalous right coronary artery originating from the mid-left anterior descending artery. *Turk Kardiyol Dern Ars*. 2017. 45(6): 573.
- [7] Birnbaum Y. Combined anterior and inferior ST-segment elevation. Electrocardiographic differentiation between right coronary artery occlusion with predominant right ventricular infarction and distal left anterior descending branch occlusion. *J Electrocardiol*. 2011. 44(4): 487-9.
- [8] Alzand BS, Gorgels AP. Combined anterior and inferior ST-segment elevation Electrocardiographic differentiation between right coronary artery occlusion with predominant right ventricular infarction and distal left anterior descending branch occlusion. *J Electrocardiol*. 2011. 44(3): 383-8.
- [9] Littmann L. The Dressler - de Winter sign of acute proximal LAD occlusion. *J Electrocardiol*. 2018. 51(1): 138-139.
- [10] Morris NP, Body R. The De Winter ECG pattern: morphology and accuracy for diagnosing acute coronary occlusion: systematic review. *Eur J Emerg Med*. 2017. 24(4): 236-242.
- [11] de Winter RJ, Verouden NJ, Wellens HJ, Wilde AA, Interventional Cardiology Group of the Academic Medical Center. A new ECG sign of proximal LAD occlusion. *N Engl J Med*. 2008. 359(19): 2071-3.
- [12] Khan AR, Golwala H, Tripathi A, et al. Impact of total occlusion of culprit artery in acute non-ST elevation myocardial infarction: a systematic review and meta-analysis. *Eur Heart J*. 2017. 38(41): 3082-3089.
- [13] Sclarovsky S, Birnbaum Y, Solodky A, Zafir N, Wurzel M, Rechavia E. Isolated mid-anterior myocardial infarction: a special electrocardiographic sub-type of acute myocardial infarction consisting of ST-elevation in non-consecutive leads and two different morphologic types of ST-depression. *Int J Cardiol*. 1994. 46(1): 37-47.
- [14] Gorgels AP. Explanation for the electrocardiogram in subendocardial ischemia of the anterior wall of the left ventricle. *J Electrocardiol*. 2009. 42(3): 248-9.
- [15] Zhong-qun Z, Nikus KC, Sclarovsky S. Prominent precordial T waves as a sign of acute anterior myocardial

Figure legends

Figure 1A: The ECG on admission shows extensive ST-segment elevation in leads II, III, aVF, V1, V3-V9 and V3R-V5R. **1B and 1C:** Angiography before reperfusion shows sub-total occlusion of the proximal right coronary artery (TIMI 1 flow) and total occlusion of the distal left anterior descending coronary artery. **1D:** The ECG after reperfusion shows negative T waves in leads II, III, aVF, V5, V6, and V3R-V5R, and almost complete ST resolution. **1E:** Angiography after stenting shows a patent right coronary artery with TIMI 3 flow. **1F:** Angiography after stenting shows a patent left anterior descending coronary artery with TIMI 3 flow.

Figure 2A: The ECG on admission shows ST-segment elevation in leads II, III, aVF, V4R-V5R and V7, poor progression of precordial R-waves with concomitant upsloping ST-segment depression following by tall positive symmetrical T waves in V2-V4. **2B and 2C:** Angiography before reperfusion shows total occlusion of the middle right coronary artery and sub-total occlusion of the mid-part of the left anterior descending coronary artery with TIMI 1 flow. **2D:** The ECG after reperfusion shows resolution of ST-segment deviation, and disappearance of prominent T-waves in leads V2-V4. **2E:** Angiography post-stenting shows a patent right coronary artery with TIMI 3 flow. **2F:** Angiography after stenting shows a patent left anterior descending coronary artery with TIMI 3 flow.

Figure 1

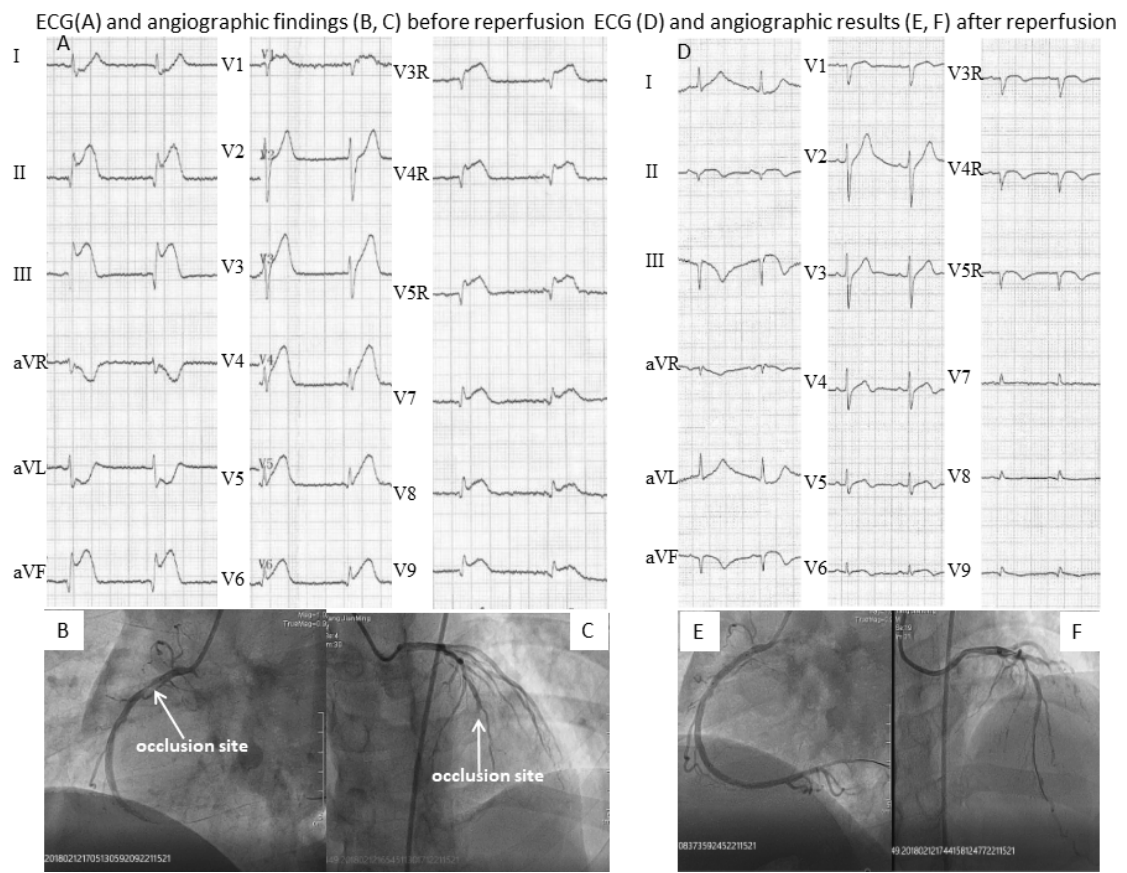


Figure 2

