

Rational and design of the European randomized Optical Coherence Tomography Optimized Bifurcation Event Reduction Trial (OCTOBER)



Niels Ramsing Holm^a Lene Nyhus Andreassen^a Simon Walsh^b Olli A. Kajander^c Nils Witt^d Christian Eek^e Paul Knaapen^f Lukasz Koltowski^g Juan Luis Gutiérrez-Chico^h Francesco Burzottaⁱ Janusz Kockman^g John Ormiston^j Irene Santos-Pardo^d Peep Laanmets^k Darren Mylotte^l Morten Madsen^m Jakob Hjortⁿ Indulis Kumsars^o Truls Råmunddal^a and Evald Høj Christiansen^a *Skejby, Denmark; Belfast, Northern Ireland; Tampere, Finland; Stockholm, Sweden; Oslo, Norway; Amsterdam, the Netherlands; Warsaw, Poland; Berlin, Germany; Rome, Italy; Auckland, New Zealand; Tallinn, Estonia; Galway, Ireland; Aarhus, Denmark; and Riga, Latvia*

Background Percutaneous coronary intervention in complex bifurcation lesions is prone to suboptimal implantation results and is associated with increased risk of subsequent clinical events. Angiographic ambiguity is high during bifurcation stenting, but it is unknown if procedural guidance by intravascular optical coherence tomography (OCT) improves clinical outcome.

Methods and design OCTOBER is a randomized, investigator-initiated, multicenter trial aimed to show superiority of OCT-guided stent implantation compared to standard angiographic-guided implantation in bifurcation lesions. The primary outcome measure is a 2-year composite end point of cardiac death, target lesion myocardial infarction, and ischemia-driven target lesion revascularization. The calculated sample size is 1,200 patients in total, and allocation is 1:1. Eligible patients have stable or unstable angina pectoris or stabilized non-ST elevation myocardial infarction, and a coronary bifurcation lesion with significant main vessel stenosis and more than 50 % stenosis in a side branch with a reference diameter ≥ 2.5 mm. Treatment is performed by the provisional side branch stenting technique or 2-stent techniques, and the systematic OCT guiding protocol is aimed to evaluate (1) plaque preparation, (2) lesion length, (3) segmental reference sizes, (4) lesion coverage, (5) stent expansion, (6) malapposition, (7) wire positions, and (8) ostial results.

Implications A positive outcome of the OCTOBER trial may establish OCT as a routine tool for optimization of complex percutaneous coronary intervention, whereas a negative result would indicate that OCT remains a tool for ad hoc evaluation in selected cases. (Am Heart J 2018;205:97-109.)

Background

Complex treatment of bifurcation lesions is associated with worse outcome than simple treatment.^{1,2} Guiding of complex bifurcation stenting by angiography is limited by

high angiographic ambiguity in visualization of lesions,³ the side branch ostium,⁴ stent expansion,⁵ stent apposition,⁶ and wire positions critical for correct delivery of balloons and stents.⁷ The lack of adequate procedural

From the ^aDepartment of Cardiology, Aarhus University Hospital, Skejby, Denmark, ^bDepartment of Cardiology, Belfast Health and Social Care Trust, Belfast, Northern Ireland, ^cHeart Centre, Department of Cardiology, Tampere University Hospital, Tampere, Finland and Faculty of Medicine and Life Sciences, University of Tampere, Tampere, Finland, ^dDepartment of Clinical Science and Education, Karolinska Institute, Unit of Cardiology, Södersjukhuset, Stockholm, Sweden, ^eDepartment of Cardiology, Oslo University Hospital, Oslo, Norway, ^fDepartment of Cardiology, VU University Medical Center, Amsterdam, the Netherlands, ^gDepartment of Cardiology, Medical University of Warsaw, Warsaw, Poland, ^hDepartment of Cardiology, Punta de Europa University Hospital, Algeciras, Spain, ⁱInstitute of Cardiology, F.Policlinico Gemelli IRCCS, Catholic University of the Sacred Heart, Rome, Italy, ^jIntra - Image Guided Healthcare, Auckland, New Zealand, ^kCardiology Center, North Estonia Medical Center, Tallinn, Estonia, ^lDepartment of Cardiology, Galway University Hospital, Galway, Ireland, ^mDepartment of Clinical

Epidemiology, Aarhus University Hospital, Skejby, Denmark, ⁿDepartment of Clinical Medicine, Aarhus University, Aarhus, Denmark, and ^oLatvian Centre of Cardiology, Pauls Stradins Clinical University Hospital, University of Latvia, Riga, Latvia.

RCT# NCT03171311

Submitted February 9, 2018; accepted August 9, 2018.

Reprint requests: Niels R. Holm, Department of Cardiology, Aarhus University Hospital, Skejby, 8200, Aarhus N, Denmark.

E-mail: niels.holm@clin.au.dk

0002-8703

© 2018 The Authors. Published by Elsevier Inc. This is an open access article under the CC BY-NC-ND license (<http://creativecommons.org/licenses/by-nc-nd/4.0/>).
<https://doi.org/10.1016/j.ahj.2018.08.003>

guidance can lead to unpredictable and suboptimal treatment results associated with higher risk of clinical events during and after treatment.⁸⁻¹⁰ Intravascular optical coherence tomography (OCT) provides visualization of the vessel wall, vessel lumen, plaque components, dissections, stents, and wires at a very high resolution, enabling precise measurements and stepwise verification and optimization during complex percutaneous coronary intervention (PCI).^{7,11-13} It is unknown if routine structured use of OCT during complex bifurcation stenting improves clinical outcome as compared to standard practice with angiographic guiding and optional use of intravascular ultrasound. The OCTOBER trial aims to demonstrate that OCT-guided PCI improves clinical outcome as compared to standard practice.

Methods

Study design

The OCTOBER trial is an investigator-initiated, randomized (1:1), controlled, prospective, superiority, multicenter trial with planned enrolment of 1,200 patients in 60 centers in Europe. By August 1, 2018, a total of 156 patients have been randomized. Estimated final enrolment day is December 31, 2019, with reporting of primary end point in the second half of 2021.

Notifications

The study is notified to the local or national ethics committees as appropriate and to the Danish Data Protection Agency covering all sites within the European Union. The trial is registered with [Clinicaltrials.gov](https://clinicaltrials.gov) NCT03171311. Only CE-marked equipment is used and only for approved indications. The principles in the Declaration of Helsinki are followed, and all patients provide written informed consent for participation in the trial.

Patient population

Patients with stable angina pectoris, or stabilized non-ST elevation myocardial infarction (NSTEMI) and a significant bifurcation lesion involving a large side branch are eligible for participation. The side branch should have an estimated proximal reference size of at least 2.5 mm and more than 50% diameter stenosis in the ostium by visual estimation. All lesion lengths are allowed, and distal segments requiring treatment are allowed to have smaller reference size than 2.5 mm.

Complete clinical and angiographic inclusion and exclusion criteria are listed in [Figure 1](#).

Primary end point

The composite end point of major adverse cardiac events (MACE) includes cardiac death, target lesion myocardial infarction (MI), and ischemia-driven target lesion revascularization (TLR) at 2 years.

Secondary composite end points

The study bifurcation-oriented composite end point includes cardiac death, target bifurcation MI, and ischemia-driven target bifurcation revascularization. The patient-oriented composite end point is all-cause mortality, MI, any revascularization, and stroke. Individual secondary end points are listed in [Table I](#).

Treatment allocation. Patients are randomized 1:1 to either OCT-guided revascularization or standard angiography-guided revascularization after diagnostic coronary angiography and the ability to wire both branches ([Figure 1](#)). The randomization is stratified (1) for operators' intention to perform either the provisional side branch stenting technique or a planned 2-stent technique and (2) for bifurcation lesion location (left main coronary artery [LMCA] or non-LMCA). In patients allocated to OCT guiding, all lesions for treatment should be guided by OCT at least until the last follow-up time point for the primary end point.

Consort patient flow documentation

Patients are enrolled according to clinical inclusion and exclusion criteria ([Figure 1](#)), and only fully eligible patients are randomized.

Study procedure

PCI technique, both allocations. Access route and wires are selected at the operator's discretion. Guiding catheters should be at least 6F, and in cases with very large vessels and in LMCA stenting, 7F and 8F catheters are recommended for optimal support and improved flushing in OCT-guided cases. Recommended stent techniques are the provisional side branch stenting technique with mandatory kissing balloon inflation and the 2-stent techniques: double kissing (DK) crush, culotte, T and protrude technique, and T-stenting. Classic crush, inverted crush, mini crush, and simultaneous kissing stent techniques are not allowed. For all stents implanted across a bifurcation whether from the main vessel or the side branch, postdilatation of the stent from the carina to the proximal stent edge according to the reference size is mandatory and should be performed as the first step after implantation. Kissing balloon inflation is performed using noncompliant balloons sized 1:1 to the SB and distal MV segments, respectively, and with (1) sequential high-pressure balloon inflations (20 atm) before (2) simultaneous inflation at 8-12 atm and exact simultaneous deflation. Proximal optimization technique (POT) after kissing balloon inflation is optional, and if performed, it is critical that the distal balloon marker is positioned 1-2 mm proximal to the proximal side branch take-off spring to avoid distorting the core bifurcation segment. Recommendations are detailed in the study protocol, and treatment in both arms follows the sequence and structure shown in the OCT guiding manual (supplement).

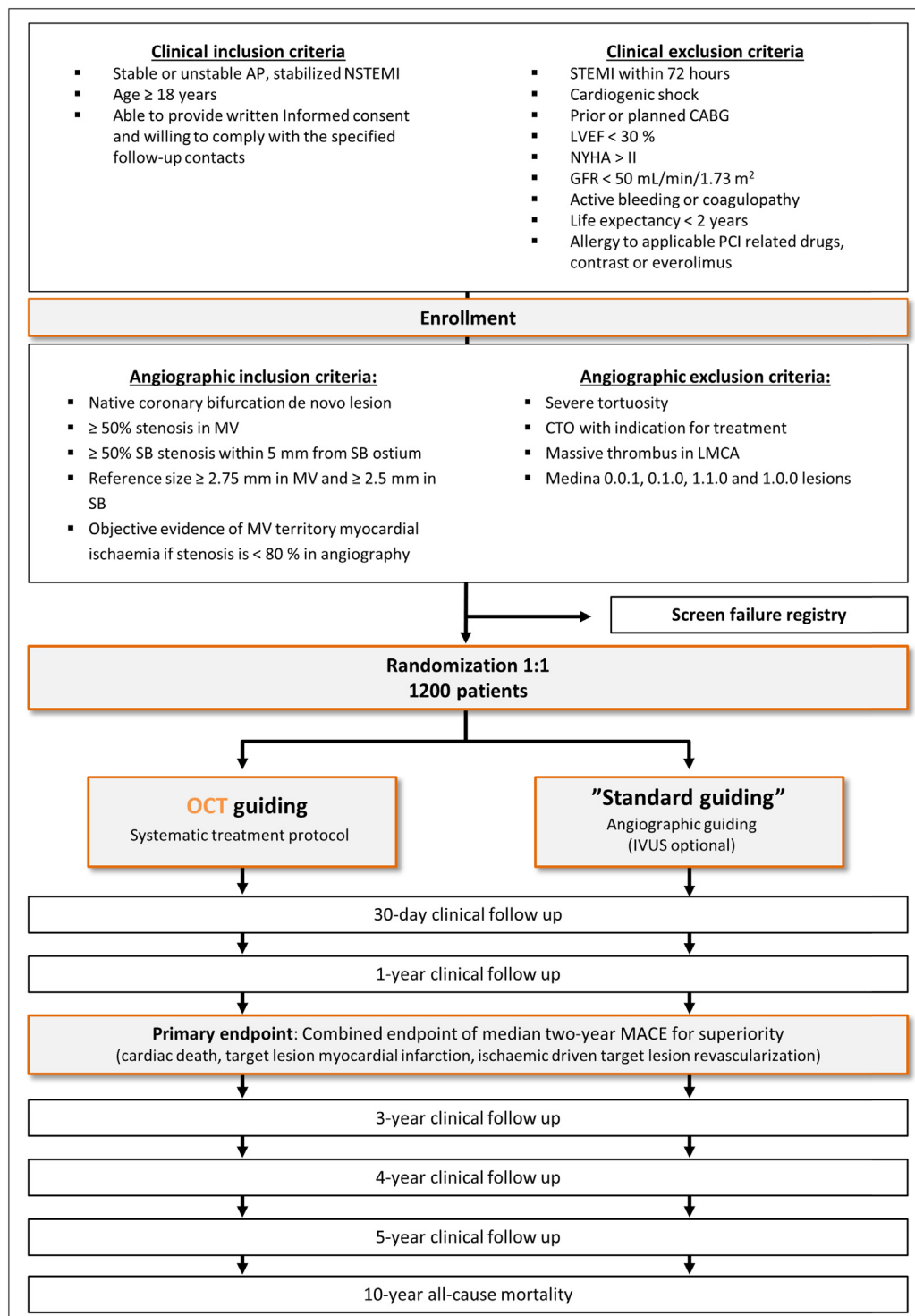


Figure 1

Patient flowchart. AP, angina pectoris; CABG, coronary artery bypass grafting; CTO, chronic total occlusion; GFR, glomerular filtration rate; IVUS, intravascular ultrasound; LVEF, left ventricular ejection fraction; MACE, major adverse cardiac events; MV, main vessel; SB, side branch; STEMI, ST-elevation myocardial infarction.

Table. Primary and secondary end points

Primary end point

- Combined end point of 2-y MACE (cardiac death, target lesion MI, ischemia-driven TLR)

Secondary end points, clinical

- Study bifurcation-oriented end point: composite of cardiac death, target bifurcation MI, target bifurcation revascularization
- Patient-oriented composite end point: all-cause mortality, MI, any revascularization, stroke
- Clinical end points at 1, 12, 24, 36, 48, and 60, m:
 - All-cause mortality (including 120 m)
 - Cardiac death
 - MI
 - Stent thrombosis (definite, possible, probable)
 - Target lesion MI
 - TLR
 - Target bifurcation MI
 - Target bifurcation revascularization
 - Target vessel revascularization
 - Any revascularization
 - CCS angina class

Secondary end points, procedural

- Contrast volume
- Procedure time
- Fluoroscopy time
- Number of stents implanted in target lesion
- Number of stents implanted in nontarget lesions
- Total stent length in target lesion
- Total stent length in total
- Procedural success (TIMI III flow and <30% diameter stenosis in target segments by QCA)

OCT-guided group:

- Successful treatment-specific OCT acquisitions (study procedure)
- Successful final OCT acquisition in main vessel (success defined as analyzable stented segment)
- Successful final OCT acquisition in stented side branch

Secondary end points, angiographic (3D QCA)

Target bifurcation

- Minimal luminal diameter and diameter stenosis post-PCI
 - In-segment
 - Segmental: proximal edge, proximal MV, bifurcation core segment, distal MV ostium, distal MV, distal edge, SB ostium, SB, SB edge

Nontarget lesions

- Luminal diameter and diameter stenosis post-PCI
 - In-segment
 - Segmental: proximal edge, in-stent, distal edge

QCA, quantitative coronary angiography; MV, main vessel; SB, side branch.; TLR, target lesion revascularization; CCS, canadian cardiovascular society grading of angina; TIMI, thrombolysis in myocardial infarction

OCT guiding strategy. The systematic OCT guiding strategy is designed to achieve 3 aims: (1) adequate vessel and stent expansion, (2) full stent apposition, and (3) optimal lesion coverage. As OCT scans require additional instrumentation and contrast use, balancing the number of scans and the potential benefit has been a main focus to ensure clinical feasibility. Of utmost importance for feasibility is the timing of scans at specific time points during the procedure where the chance of a successful scan is high and where OCT may provide most useful and clinically important information to guide the stent implantation. As OCT provides a wealth of information,

checklists for the specific scans are provided to give priority to extraction of most important information balanced against time consumption of in-procedure OCT analysis. The OCT guiding protocol is detailed in the protocol, and a short illustrated version is available for training and in-procedure instructions (supplement). The checklist-based guiding protocol is detailed for the provisional side branch stenting strategy with mandatory kissing balloon inflation and the 4 recommended 2-stent techniques. The general structure is shown in [Figure 2](#). The guiding principles are as follows: (1) predilatation of lesion segments to be stented according to angiographic findings; (2) OCT of predilated segments for evaluation of lesion preparation, planning stent length, and estimation of reference diameter in segments to be stented; (3) stent implantation, postdilatation at high pressure of all stented segments with noncompliant (NC) balloons sized 1:1 to the reference diameter, and rewiring of the side branch; (4) OCT evaluation of stent expansion and apposition, exclusion of geographical miss with residual edge stenosis, evaluation of wire position in recrossing into the side branch, and ruling out accidental abluminal rewiring of proximal main vessel segments; after correcting accordingly, (5) sequential kissing balloon inflation followed by simultaneous kissing balloon inflation; final POT is optional; (6) final OCT of all stented segments for evaluation of stent expansion and apposition, and assessment of the side branch ostium; and (7) removal of wires and final angiography in 2 projections and high frame rate enabling core laboratory 3D QCA analysis. The differences in sequence of steps between the 5 stent techniques necessitate a customized approach for each technique as outlined in the manual, but the timing of OCT scans is the same for all techniques: (A) after predilatation but before stent implantation, (B) after each rewiring, and (C) the final result of all stented segments.

Crossover and use of IVUS. Use of OCT scans in the control arm is not allowed. Use of IVUS is not encouraged and may not be used routinely in the control arm, but if an operator finds it necessary to evaluate with intravascular imaging, IVUS may be used.

Multivessel treatment. Indication for treatment of other lesions follows present guidelines regarding documentation for ischemia producing potential. Full revascularization is recommended. Treatment of other lesions should also follow the allocation for type of guiding. Staged procedures are allowed as long as the study bifurcation is treated in the first index procedure. The study allocation also applies to staged procedures.

Study stent and medical treatment (both arms). The Xience drug-eluting stent (DES) (Chicago, Illinois, Abbott) is the study stent and is used in all cases, including nonstudy lesions. Before implantation, patients are loaded with clopidogrel (300-600 mg), prasugrel (60 mg), or ticagrelor (180 mg) and aspirin (300 mg)

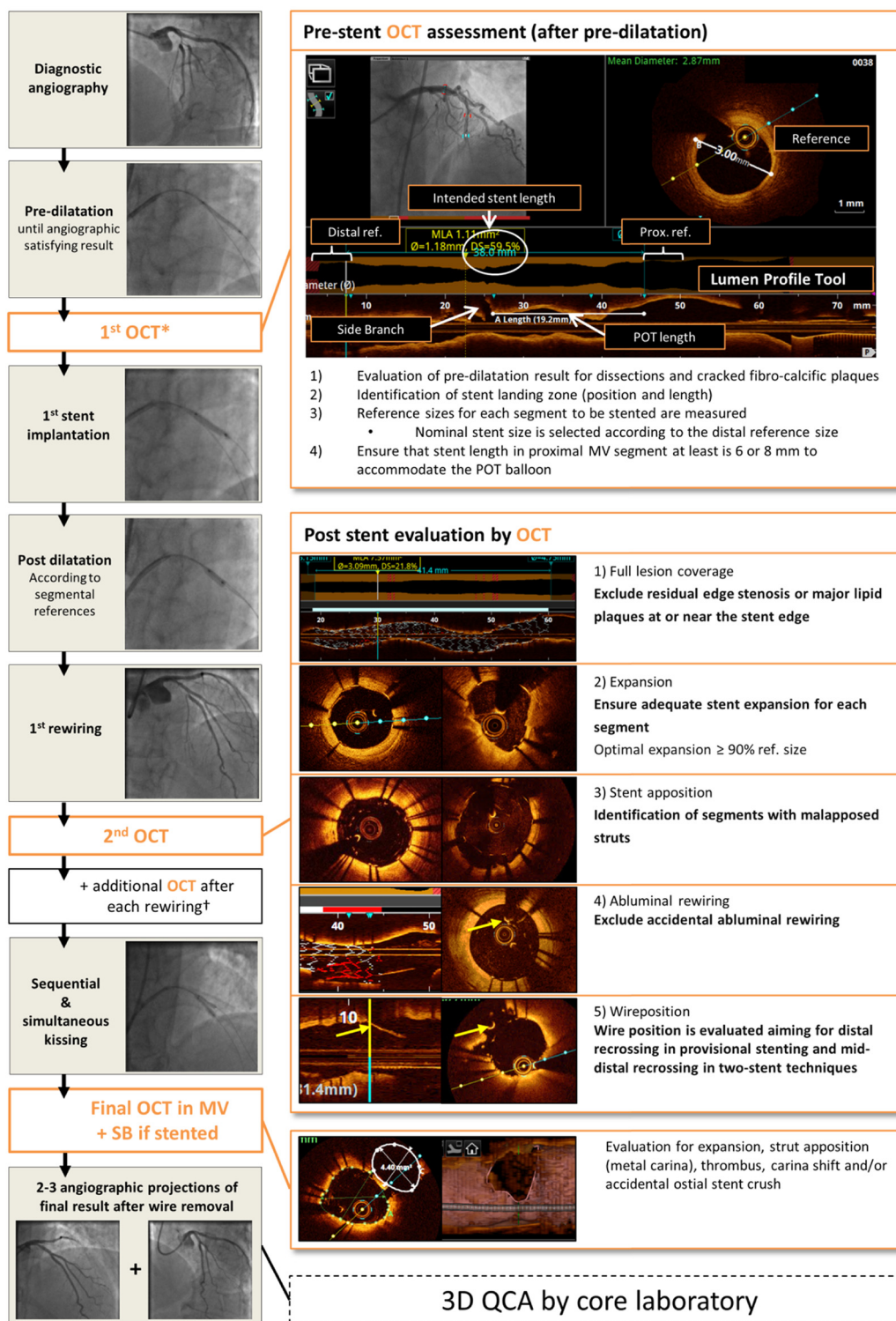
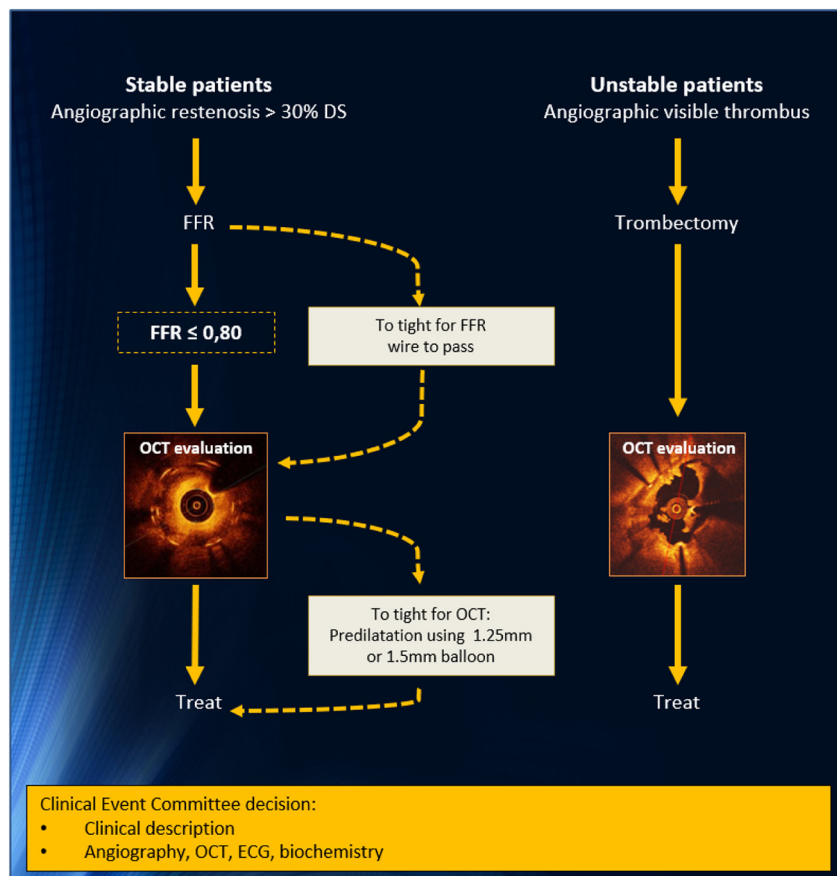


Figure 2

Principal structure of OCTOBER OCT guiding protocol. See supplemental information for specific OCT guiding protocols for provisional stenting and for DK crush, T and protrude technique, T-stenting, and culotte 2-stent techniques. *Mandatory in the MV and encouraged in the SB in 2-stent techniques, †for DK crush and culotte techniques. OCT imaging is performed using Abbott OCT-systems (Ilumien, Ilumien Optis, or Optis integrated).

**Figure 3**

Strategy for evaluation of patients with potential or manifest event. Objective evidence for lesion-specific ischemic potential is mandatory before treatment of in-stent restenosis in patients with stable angina pectoris. OCT evaluation before treatment of stent failure is performed in patients with possible or manifest events with both trial allocations. *DS*, diameter stenosis; *ECG*, electrocardiogram; *FFR*, fractional flow reserve.

according to European Society of Cardiology guidelines or local instructions. During the procedure, patients are treated with heparin (activated clotting time (ACT) >250 checked every 30-60 minutes). After procedures indicated by stable angina pectoris, clopidogrel 75 mg/d is indicated for 6 months, and after procedures indicated by UAP or Non-ST-elevation MI (NSTEMI), prasugrel 10 mg/d (5 mg/d if age >75 years or weight <60 kg) or ticagrelor 90 mg ×2/d is indicated for 12 months. All patients are prescribed lifelong aspirin at 75 mg/d.

Evaluation of patients with potential or manifest events. Figure 3 describes the algorithm for evaluation of patients with potential or manifest events.

Study training and feed back

Training and lead-in-cases. All study sites will receive on-site training before inclusion start and are required to have successfully performed at least 2 cases of OCT-guided complex bifurcation treatment cases before

entering the study. Study material, descriptive posters with key OCT findings, and image-based study flowcharts are provided (Figure 4 and supplement).

OCT guiding continuous feedback. Investigators receive confidential “next day” case-by-case core laboratory feedback of all OCT-guided procedures throughout the study for continuous optimization of physicians’ skills. The feedback covers the quality and procedural timing of OCT acquisitions, measurements, and adequate decisions but also comments on regular procedural aspects in bifurcation stenting. An important aspect is to increase physicians’ confidence in relying on OCT for treatment decisions, in particular when there is mismatch between OCT and angiographic findings.

Angiographic core laboratory analysis

Angiographic analysis is performed for all patients in both treatment arms. The target bifurcation is analyzed by applying a 7-segment model for bifurcations and a 3-segment model for straight vessel analysis. Balloon-treated segments are analyzed

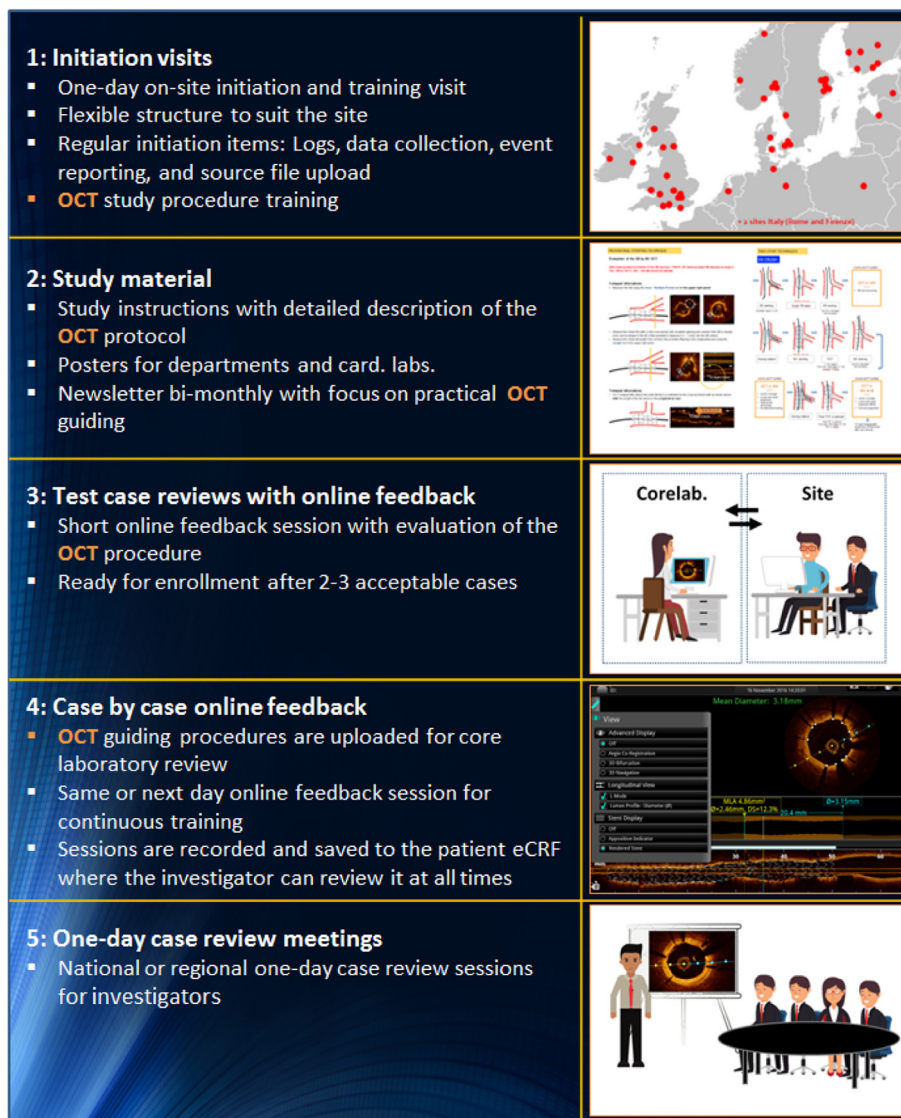

Figure 4

Setup for initiation and training of sites, and continuous OCT case feedback during enrolment.

as stented segments. Analysis of pre-PCI includes reference size, diameter stenosis %, minimal lumen diameter, lesion length, and angulations. The pre- and post-PCI angiograms are analyzed by observers blinded to the allocation. Analysis is performed at the Interventional Imaging Core Laboratory, Aarhus University Hospital, Denmark, using the Medis QAngio3DXA bifurcation analysis application (Medis Medical Imaging, the Netherlands, Leiden).

OCT core laboratory analysis

OCT scans are divided into 8 subsegments: the 3 edge segments, the proximal and distal MV, the bifurcation core segment, the SB ostium, and the remaining SB.

Pre-stent analysis of target bifurcation

OCT runs are analyzed for landing zone estimation, segmental reference diameters, and minimal lumen area. The reference diameters are measured for comparison to in-procedure estimates following the same algorithm (supplement). If valid reference estimation is not possible by OCT, 3D QCA-derived reference size is used.

Poststent implantation and wire recrossing. OCT runs are analyzed for geographical miss compared to in-procedure indicated landing zone, position of cell recrossing, and accidental abluminal rewiring.

Final result. OCT runs are analyzed for mean and minimal stent and lumen area, rate of accidental crushed stent segments, malapposition, and intraluminal masses.

Fraction of cases where optimal expansion was achieved is reported.

OCT analysis is performed at the Interventional Imaging Core Laboratory, Aarhus University Hospital, Denmark.

Sample size calculation

Estimates for median 2-year MACE rates are based on the following evidence and assumptions. The 2-year MACE rate in the Syntax LMCA subgroup treated by PCI was 22.6%. This included 1.4% cerebrovascular events. This population also included isolated LMCA ostial and midshaft lesion. The DELTA registry comparing ostial/midshaft and distal LMCA bifurcation lesions reported median 3.5-year MACE rate of 19% and 28%, respectively.¹⁴ The 2-year MACE rate in the MAIN COMPARE 2-stent group was 24%,¹⁵ and MACE at mean 32 months in the meta-analysis by Karrowni et al was 20% in the single stent group versus 33% after 2-stent treatment of LMCA bifurcations.¹⁶ Patients treated for LMCA bifurcation lesions in the Nordic Bifurcation study III had a MACE rate of 25% at 3 years (in review). The DKCRUSH III comparing the DK crush technique and culotte for LMCA bifurcation treatment reported 3-year MACE of 8.2% and 23.7%, indicating that different 2-stent techniques may be associated with different clinical outcome.¹⁷ Still, the utilization of intracoronary imaging in all the studies except for MAIN COMPARE was low.¹⁵

Therefore, applying a newer-generation DES in a population where patients require 2-stent treatment or have increased complexity due to side branch stenosis and with a 60% ratio of LMCA to non-LMCA bifurcations and a 30% patient-level requirement for multivessel stenting, we expect a 2-year event rate of approximately 16% by standard guiding (population standard).

The clinical value of using OCT to detect correctable factors not visible by angiography during PCI is sparsely investigated. The CLI-OPCI matched analysis found a reduction in 1-year MACE by OCT guiding from 14.8% to 9.6% in a standard PCI population,¹⁸ and the CLI-OPCI II registry reported that suboptimal PCI result as detected by OCT was an independent predictor of worse outcome (MACE hazard ratio [HR]: 3.53; 95% CI: 2.2-5.8; $P < .001$).¹⁹ The randomized IVUS-XPL trial by Hong et al showed a 50% reduction in MACE driven by reduction in MACE in the IVUS guidance group but overall low 1-year event rates.²⁰ The randomized studies by Antonsen et al²¹ and Jun-Sung Kim et al²² both showed a significant improvement in 6-month stent strut coverage by OCT guiding compared to angiographic guiding, further indicating positive effects of OCT optimization. Complex PCI of bifurcation lesions suffers from a high degree of angiographic ambiguity. Therefore, we expect that the positive effects of OCT guiding should at least be at level with the findings reported in average PCI populations. We therefore estimated an absolute reduction in 2-year MACE from 16% to 10% by routine OCT guidance. With $\alpha = .05$ and power = 80%, a total of 984 patients ($n = 492$ in each group) are required.

To accommodate for uncertainty of estimates and lost-to-follow-up, the inclusion target is 1,200 patients total.

Statistics

Continuous variables are compared using the 2-sample t test (or Welch approximation in case of unequal variances) or the Mann-Whitney U test if data follow a nonnormal distribution. Categorical variables are analyzed with the χ^2 test or Fisher exact test if cell numbers are small. The main effect measure is the 0- to 24-month HRs estimated by adjusted and unadjusted Cox regression based on intention-to-treat principle. Per-protocol analyses are performed for the combined end points. The final follow-up date for the primary end point is when median 2 years of follow-up has been reached and the last enrolled patient has been followed for at least 1 year. Both intention-to-treat and per protocol analyses are performed for all composite end points. All end points are assessed until death or loss to follow-up. Cumulative incidence curves are plotted (treating death as nonevent). Patients treated by the standard guiding strategy are used as the reference group for the overall and subgroup analyses. HR estimates for major adverse cardiac events at 24 months of follow-up are estimated for prespecified subgroups of patients (classified by baseline demographic and clinical characteristics). Effects of baseline differences between groups are evaluated by Cox proportional-hazard regression analysis. A 2-sided P value of less than .05 indicates significance.

Subgroup analysis are prespecified for the following subgroups: 1-stent techniques, 2-stent techniques, LMCA bifurcation subgroup, single-vessel disease, multivessel disease, long and short SB disease, optimal and suboptimal angiographic results, stable angina pectoris and acute coronary syndrome (ACS), diabetes, gender, calcified lesions, and SYNTAX score above 11 and are presented in a forest plot.

Data collection and monitoring

Data collection, processing, and storage. Data are entered directly in the e-CRF in the secure Web-based trial management system, TrialPartner, Institute of Clinical Medicine, Aarhus University Hospital. Imaging data including angiographic image runs and all OCT scans are uploaded to the study database, enabling remote monitoring and procedure feedback by the central core laboratory. Data regarding readmission and source data for clinical end point committee evaluation are uploaded as well.

Monitoring of the study. The study is monitored according to the Good Clinical Practice guidelines. During the study period, monitors will ensure that the trial is conducted in compliance with the protocol, Good Clinical Practice, and applicable regulatory requirements. The monitors perform remote and on-site reviews for verification of consistency and correctness of recorded data.

Data Safety Monitoring Board. The safety of the study is monitored by an independent external safety committee (Data Safety Monitoring Board [DSMB]) headed by Juha Hartikainen, Kuopio, Finland. The DSMB receives information on rates of death, MI, stent thrombosis, and repeat revascularization. The DSMB independently makes decision on continuation, pausing, or stopping the study. Applicable ethics committees and site PI are informed immediately of any changes in the study risk assessment and study status.

Ethical aspects

OCT has a IIB recommendation by European Society of Cardiology guidelines for optimizing PCI.²³ The strategy in both treatment arms is at present clinically applicable nonstudy treatments, and it is unknown if one is beneficial over the other. Optimization by OCT follows established technical treatment goals, and the implantation techniques allowed in the study are recommended standard techniques.²⁴ The experimental aspect is the routine use of systematic OCT guiding during invasive angiography compared to present standard practice of primarily angiographic guiding and unstructured ad hoc use of invasive imaging mostly performed using IVUS. Allocation of the guiding strategy by randomization is therefore deemed acceptable.

Funding

The Sponsor (Aarhus University Hospital, Denmark) has received an institutional research grant from Abbott, USA, to conduct the study according to the protocol and the prespecified budget and to provide participating centers a limited milestone-based per patient payment. Abbott did not have any influence on the study design or protocol in any aspect. Abbott will not be involved with the conduct of the study including training, enrolment, follow-up, data collection, analysis, interpretation of data, drafting, or final approval of the manuscript. The authors are solely responsible for the design of this study the drafting and editing of the paper and its final contents.

Discussion

The purpose of the OCTOBER trial is to evaluate if structured OCT guidance during complex bifurcation PCI improves clinical outcome compared to PCI guided by angiography with optional IVUS. Optimal performed complex bifurcation stenting has been investigated and debated intensively. The vast majority of clinical comparisons of stent implantation strategies in bifurcations have focused on 1-stent treatment with and without kissing balloon inflation, 1- versus 2-stent techniques, or comparisons of different 2-stent strategies. The goal of any technical strategy must be to alleviate downstream ischemia and ensure low complication rates both during PCI and beyond. Four principal factors may be important

in achieving this: (1) adequate lesion coverage, (2) thorough expansion of stent and vessel, (3) avoiding malapposition, and (4) use of best-in-class DES. Many bifurcation stent techniques and present-generation DES allow for fulfilment of these treatment goals. Still, acute results after complex bifurcation stenting are highly sensitive to optimal sizing of stents and balloons, as well as the sequence of implantation steps and balloon dilatations. Angiographic ambiguity is high during complex bifurcation PCI, and IVUS interpretation in this setting is nontrivial for most interventional cardiologists.

The OCT treatment protocol is based on the following:

Full lesion coverage

After introduction of first-generation DES with low late lumen loss, full lesion coverage was a widely accepted treatment strategy until it was shown that longer stented segments and overlapping stents were associated with increased risk of periprocedural MI, restenosis, and stent thrombosis.^{25,26} So-called spot stenting was advocated, aiming for treatment of most flow-limiting sections only.²⁷ This in turn led to high rates of edge restenosis.²⁸ Second-generation DES did not show the same risk associated with overlapping and implanting of longer stents.²⁹ Kang et al showed that plaque burden >55% but not lumen diameter in the stent edge after implantation of second-generation DES predicted edge restenosis.³⁰ OCT has the potential to identify the extent of the lesion before stent implantation to allow planned full lesion coverage and potentially lower the risk of geographical miss.^{11,12,31} Consequently, OCT-guided full lesion coverage is intended in the OCTOBER trial. After identifying the intended stent landing zones, OCT enables evaluation of the actual stent landing zone based on available stent lengths and PCI technical requirements before implanting the stents. Use of angio-OCT co-registration may improve precision and feasibility during stent sizing and positioning, and is recommended. When the stent is implanted, the OCT evaluation of edge segments may reveal if the intended landing zone was covered and if residual stenosis, major plaques, dissection, or plaque rupture is present. The principles for lesion coverage are further based on the CLI-OPCI trial that identified residual edge stenosis as a strong predictor of MACE and on the IVUS edge dissection trials showing that edge dissections visible by angiography was associated with increased MACE.^{18,32,33}

Stent expansion

Underexpansion of stented segments is associated with in-stent restenosis^{34,35} and is a frequent finding after otherwise apparent successful angiographic-guided stent implantation.^{36,37} Kang et al (2011) showed that segmental cutoff values for minimal luminal area in the distal left main bifurcation predicted TLR.³⁸ These values may become the standard of care but are only used sporadically, and the assessment of the circumflex (Cx)

ostium has so far required direct interrogation by the IVUS catheter for valid assessment.³⁹ Current clinical OCT systems provide efficient tools to check for under-expanded lumen and stent.⁴⁰ The occurrence of stent and vessel underexpansion may be reduced by post-dilatation, but modifying fibrocalcified plaques sufficiently *before* implanting the stents may be as important.³⁷ The cutoff values for minimal stent area proposed by Kang et al were derived by IVUS and may not directly apply to OCT. In OCTOBER, a minimal stent diameter larger than 90% of the segmental reference size is required and is in line with expansion limits of the ILUMIEN III trial. The POT⁴¹ is of particular importance to ensure tapering of the vessel and to improve stent apposition and opening the SB ostium for facilitated rewiring. Downsides to POT may relate to (1) cases where the lesion is uncovered proximally and a POT balloon extends into the lesion (“geographical miss”) and (2) the final POT. In performing POT after SB treatment (balloon inflation or stent implantation), a position of the POT balloon across the SB takeoff may push the carina and carinal struts toward the SB ostium, and in Y-shaped bifurcation, the area of the SB ostium might be reduced. Thus, final POT is optional in OCTOBER, and if performed, the balloon should not cross the SB takeoff. The rePOT technique (or POT-side-POT) could have similar disadvantages in distorting the bifurcation core segment and is not allowed in OCTOBER because of limited documentation for its clinical benefit. The OCT guiding strategy applied in the present study includes OCT sizing of length and diameter of both the stent and the POT balloon. The stent landing zone is extended proximally to accommodate the full POT balloon length if possible.

Tu et al (2013) reported that, in 40% of cases, it was not possible to achieve the optimal angiographic projection angle for the ostium of the Cx due to the restraints of the C-arm of the angiographic equipment.⁴ In these cases, a short Cx stenosis or a tight ostial part of a longer Cx stenosis is not visualized, and by that, a systematic intravascular imaging evaluation is needed. Still, Mintz and colleagues (2011) showed that IVUS was not reliable for assessment of the Cx ostium from a main vessel pullback.³⁹ The side branch OCT study by Karanasos et al⁴² proved that OCT was capable of providing accurate assessments of the SB ostium from both MV and SB pullbacks.

Malapposition

Malapposition is a frequent finding in case-control studies of stent thrombosis,^{43,44} but in the published observational trials, it has not been possible to identify acute malapposition as a predictor of clinical events.^{18,45,46} This might relate to the rather low patient numbers and a low- to medium-risk population. Despite the lack of robust evidence, it is still reasonable to aim for full stent apposition for the following reasons: (1) stent strut coverage is delayed

on malapposed struts,⁴⁷ and uncovered struts are associated to stent thrombosis⁴⁴; (2) malapposed struts may directly increase the risk of ST,⁴⁴ as malapposition results in high shear stress rate on the strut surface, known to activate platelets and coagulation cascade³⁶; and (3) accidental abluminal rewiring occurs only in the presence of malapposition and is a prominent risk in bifurcation treatment when rewiring through already implanted stents (see below).⁷ Malapposition at 6-month follow-up can be reduced by index procedure OCT guiding,²¹ so an active approach may be feasible and effective.

Wire position

Modeling studies by Foin et al⁴⁸ and clinical studies by Alegría-Barrero et al⁴⁹ showed that wire positions in recrossing side branches critically affected scaffolding of the side branch ostium and the extent of stent strut malapposition at the bifurcation. Risk of stent malapposition was also increased with complex stenting techniques.^{50,51} Wire positions can be evaluated and optimized by OCT guiding^{52,53}; thus, in the OCTOBER trial, we aim for optimal wire position in stent cell recrossing. This means recrossing near the carina point but in 2-stent techniques with the provision that rewiring in extreme positions may increase the risk of abluminal rewiring of the stent in the jailed branch and should be avoided in such cases.^{54,55} Bench studies by Murasato et al (2009) showed examples of accidentally crushed stents due to abluminal rewiring during complex treatment.⁵⁴ This risk was later confirmed by Zhang et al and Würtz et al.^{8,56} The latter reported clinical events where accidental crushed segments were identified by OCT but were not visible during the index procedure by angiography. Similar findings by Abdou et al⁵⁷ showed that angiography is ambiguous in guiding complex stenting in the left main bifurcation. In the OCTOBER trial, we aim for early full stent apposition to reduce the risk of abluminal rewiring, and an OCT acquisition after rewiring is mandatory for excluding abluminal rewiring and evaluating multiple other factors at that step.

OCT for guiding LMCA bifurcation stenting

Fujino et al reported that guiding LMCA stenting by OCT was feasible, was safe, and provided superior information on stent position compared to IVUS but was limited in ostial LMCA assessment.⁶ Burzotta et al confirmed that OCT evaluation was feasible in midshaft and distal LMCA lesions.¹³

Optimization of nonbifurcation stent implants

In cases where multiple lesion require stent implantation, the OCT guiding protocol is applied to all lesions including lesions treated in staged procedures. The degree of revascularization follows present guidelines. This patient-oriented optimization of all target lesions is

reflected in the primary composite end point which also includes nonbifurcation target lesions. It is expected that OCT guiding has a positive yet smaller effect on outcome in less complex lesions. Furthermore, as autopsy rates remain very low, cardiac death can rarely be related to target or nontarget lesions. Isolated outcomes for target bifurcations are reported in secondary end points.

Limiting use of contrast

Several aspects of the design are aimed to limit the additional use of contrast in the OCT arm. This includes (1) study training in acquisition technique to identify optimal guiding catheter positions before injection, (2) optimal timing of OCT scans for each stent technique, (3) use of fast pullback speed requiring 10 mL contrast or less per pullback, and (4) simultaneous cining during pullback for use as regular angiographic acquisition and optional OCT to angiography co-registration. Patients with severe renal disease are not enrolled in the trial.

Improve clinical outcome in complex PCI

Complex bifurcation lesions require treatment by complex stenting techniques with an elevated risk of suboptimal treatment results. OCT enables improved procedural control over correctable factors that may lead to optimized implantation results. Whether systematic use of OCT to optimize complex bifurcation stenting improves clinical outcome using best-in-class DES remains unknown but is highly likely based on the multiple reports described above.

Conclusion

OCTOBER is the first adequately powered clinical trial aimed to show if routine OCT guiding of stent implantation improves clinical outcome. A positive outcome may establish OCT as a routine tool for optimization of complex PCI, whereas a negative result would indicate that OCT remains a tool for ad hoc evaluation in select cases.

Disclosure information

N. R. H. received institutional research grants from Abbott and Boston Scientific, and received speaker fees from Abbott and Terumo. L. N. A. received an institutional research grant from Abbott. S. W. is a consultant to Abbott Vascular. O. A. K. received speaker fees from Abbott. I. K. received speaker fees from Astra Zeneca. E. H. C. received institutional research grants and speaker fees from Abbott. All other authors have reported no conflict of interest.

Acknowledgments

The authors wish to thank research secretary Helle Bargsteen and study coordinators Pia Stycke Ottosen and

Lars Joergensen from Aarhus University Hospital for their contribution throughout the design and planning phase of the trial. Abbott, USA, is thanked for offering an institutional research grant in support of the trial. We further thank Aarhus University and Aarhus University Hospital for supporting the trial.

Appendix A. Supplementary data; A) Study instructions: OCT guiding and B) Clinical end point definitions

Supplementary data to this article can be found online at <https://doi.org/10.1016/j.ahj.2018.08.003>.

References

1. Maeng M, Holm NR, Erglis A, et al. Long-term results after simple versus complex stenting of coronary artery bifurcation lesions: Nordic Bifurcation Study 5-year follow-up results. *J Am Coll Cardiol* 2013;62:30-4.
2. Behan MW, Holm NR, de Belder AJ, et al. Coronary bifurcation lesions treated with simple or complex stenting: 5-year survival from patient-level pooled analysis of the Nordic Bifurcation Study and the British Bifurcation Coronary Study. *Eur Heart J* 2016;37:1923-8.
3. Baumgart D, Haude M, Birgelen Cv CV, et al. Assessment of ambiguous coronary lesions by intravascular ultrasound. *Int J Cardiovasc Interv* 1999;2:3-12.
4. Tu S, Jing J, Holm NR, et al. In vivo assessment of bifurcation optimal viewing angles and bifurcation angles by three-dimensional (3D) quantitative coronary angiography. *Int J Cardiovasc Imaging* 2012;28:1617-25.
5. Burzotta F, Talarico GP, Trani C, et al. Frequency-domain optical coherence tomography findings in patients with bifurcated lesions undergoing provisional stenting. *Eur Heart J Cardiovasc Imaging* 2014;15:547-55.
6. Fujino Y, Bezerra HG, Attizzani GF, et al. Frequency-domain optical coherence tomography assessment of unprotected left main coronary artery disease—a comparison with intravascular ultrasound. *Catheter Cardiovasc Interv* 2013;82:E173-83.
7. Holm NR, Adriaenssens T, Motreff P, et al. OCT for bifurcation stenting: what have we learned? *EuroIntervention* 2015;11 (Suppl V):V64-70.
8. Wurtz M, Christiansen EH, Kristensen SD, et al. Accidentally crushed stent during complex bifurcation treatment. A potential cause of very late stent thrombosis. *Int J Cardiol* 2015;197:113-5.
9. Leibundgut G, Gick M, Toma A, et al. Longitudinal compression of the platinum-chromium everolimus-eluting stent during coronary implantation: predisposing mechanical properties, incidence, and predictors in a large patient cohort. *Catheter Cardiovasc Interv* 2013;81:E206-14.
10. Fujino Y, Attizzani GF, Tahara S, et al. Frequency-domain optical coherence tomography assessment of unfavorable kissing-balloon result in unprotected left main intervention. *JACC Cardiovasc Interv* 2013;6:1324-5.
11. Tearney GJ, Regar E, Akasaka T, et al. Consensus standards for acquisition, measurement, and reporting of intravascular optical coherence tomography studies: a report from the International Working Group for Intravascular Optical Coherence Tomography Standardization and Validation. *J Am Coll Cardiol* 2012;59: 1058-72.

12. Prati F, Guagliumi G, Mintz GS, et al. Expert review document part 2: methodology, terminology and clinical applications of optical coherence tomography for the assessment of interventional procedures. *Eur Heart J* 2012;33:2513-20.
13. Burzotta F, Dato I, Trani C, et al. Frequency domain optical coherence tomography to assess non-ostial left main coronary artery. *EuroIntervention* 2015;10:e1-8.
14. Naganuma T, Chieffo A, Meliga E, et al. Long-term clinical outcomes after percutaneous coronary intervention versus coronary artery bypass grafting for ostial/midshaft lesions in unprotected left main coronary artery from the DELTA registry: a multicenter registry evaluating percutaneous coronary intervention versus coronary artery bypass grafting for left main treatment. *JACC Cardiovasc Interv* 2014;7:354-61.
15. Park DW, Seung KB, Kim YH, et al. Long-term safety and efficacy of stenting versus coronary artery bypass grafting for unprotected left main coronary artery disease: 5-year results from the MAIN-COMPARE (Revascularization for Unprotected Left Main Coronary Artery Stenosis: Comparison of Percutaneous Coronary Angioplasty Versus Surgical Revascularization) registry. *J Am Coll Cardiol* 2010;56:117-24.
16. Karrowi W, Makki N, Dhaliwal AS, et al. Single versus double stenting for unprotected left main coronary artery bifurcation lesions: a systematic review and meta-analysis. *J Invasive Cardiol* 2014;26:229-33.
17. Chen SL, Xu B, Han YL, et al. Clinical outcome after DK crush versus culotte stenting of distal left main bifurcation lesions: the 3-year follow-up results of the DKCRUSH-III study. *JACC Cardiovasc Interv* 2015;8:1335-42.
18. Prati F, Di Vito L, Biondi-Zoccai G, et al. Angiography alone versus angiography plus optical coherence tomography to guide decision-making during percutaneous coronary intervention: the Centro per la Lotta contro l'Infarto-Optimisation of Percutaneous Coronary Intervention (CLI-OPCI) study. *EuroIntervention* 2012;8:823-9.
19. Prati F, Romagnoli E, Burzotta F, et al. Clinical impact of OCT findings during PCI: the CLI-OPCI II study. *JACC Cardiovasc Imaging* 2015;8:1297-305.
20. Hong SJ, Kim BK, Shin DH, et al. Effect of intravascular ultrasound-guided vs angiography-guided everolimus-eluting stent implantation: the IVUS-XPL randomized clinical trial. *JAMA* 2015;314:2155-63.
21. Antonsen L, Thayssen P, Maehara A, et al. Optical coherence tomography guided percutaneous coronary intervention with Nobori stent implantation in patients with non-ST-segment-elevation myocardial infarction (OCTACS) trial: difference in strut coverage and dynamic malapposition patterns at 6 months. *Circ Cardiovasc Interv* 2015;8, e002446.
22. Kim JS, Shin DH, Kim BK, et al. Randomized comparison of stent strut coverage following angiography- or optical coherence tomography-guided percutaneous coronary intervention. *Rev Esp Cardiol (Engl Ed)* 2015;68:190-7.
23. Windecker S, Kolh P, Alfonso F, et al. 2014 ESC/EACTS guidelines on myocardial revascularization: the Task Force on Myocardial Revascularization of the European Society of Cardiology (ESC) and the European Association for Cardio-Thoracic Surgery (EACTS) developed with the special contribution of the European Association of Percutaneous Cardiovascular Interventions (EAPCI). *Eur Heart J* 2014;35:2541-619.
24. Lassen JF, Burzotta F, Banning AP, et al. Percutaneous coronary intervention for the left main stem and other bifurcation lesions: 12th consensus document from the European Bifurcation Club. *EuroIntervention* 2018;13:1540-53.
25. Zhang QY, Li Y, Guan SY, et al. Incidence and predictors of definite stent thrombosis after coronary stent implantation. *Chin Med J* 2012;125:1547-51.
26. Raber L, Juni P, Loffel L, et al. Impact of stent overlap on angiographic and long-term clinical outcome in patients undergoing drug-eluting stent implantation. *J Am Coll Cardiol* 2010;55:1178-88.
27. Colombo A, De Gregorio J, Moussa I, et al. Intravascular ultrasound-guided percutaneous transluminal coronary angioplasty with provisional spot stenting for treatment of long coronary lesions. *J Am Coll Cardiol* 2001;38:1427-33.
28. Sakurai R, Ako J, Morino Y, et al. Predictors of edge stenosis following sirolimus-eluting stent deployment (a quantitative intravascular ultrasound analysis from the SIRIUS trial). *Am J Cardiol* 2005;96:1251-3.
29. Mori N, Okamoto N, Tanaka A, et al. Comparison of angiographic and 1-year outcomes between a long single stent and overlapping double stents in patients with newer-generation drug-eluting stents for long narrowings. *Am J Cardiol* 2016;117:1724-8.
30. Kang SJ, Cho YR, Park GM, et al. Intravascular ultrasound predictors for edge restenosis after newer generation drug-eluting stent implantation. *Am J Cardiol* 2013;111:1408-14.
31. Fedele S, Biondi-Zoccai G, Kwiatkowski P, et al. Reproducibility of coronary optical coherence tomography for lumen and length measurements in humans (The CLI-VAR [Centro per la Lotta contro l'Infarto-VARiability] study). *Am J Cardiol* 2012;110:1106-12.
32. Ellis SG, Roubin GS, King 3rd SB, et al. Angiographic and clinical predictors of acute closure after native vessel coronary angioplasty. *Circulation* 1988;77:372-9.
33. Sheris SJ, Canos MR, Weissman NJ. Natural history of intravascular ultrasound-detected edge dissections from coronary stent deployment. *Am Heart J* 2000;139:59-63.
34. Moussa I, Moses J, Di Mario C, et al. Does the specific intravascular ultrasound criterion used to optimize stent expansion have an impact on the probability of stent restenosis? *Am J Cardiol* 1999;83:1012-7.
35. Bertrand OF, De Larochelliere R, Joyal M, et al. Incidence of stent under-deployment as a cause of in-stent restenosis in long stents. *Int J Cardiovasc Imaging* 2004;20:279-84.
36. Foin N, Gutierrez-Chico JL, Nakatani S, et al. Incomplete stent apposition causes high shear flow disturbances and delay in neointimal coverage as a function of strut to wall detachment distance: implications for the management of incomplete stent apposition. *Circ Cardiovasc Interv* 2014;7:180-9.
37. Nageh T, De Belder AJ, Thomas MR, et al. Intravascular ultrasound-guided stenting in long lesions: an insight into possible mechanisms of restenosis and comparison of angiographic and intravascular ultrasound data from the MUSIC and RENEWAL trials. *J Interv Cardiol* 2001;14:397-405.
38. Kang SJ, Mintz GS, Kim WJ, et al. Effect of intravascular ultrasound findings on long-term repeat revascularization in patients undergoing drug-eluting stent implantation for severe unprotected left main bifurcation narrowing. *Am J Cardiol* 2011;107:367-73.
39. Kang SJ, Mintz GS, Oh JH, et al. Intravascular ultrasound assessment of distal left main bifurcation disease: the importance of the polygon of confluence of the left main, left anterior descending, and left circumflex arteries. *Catheter Cardiovasc Interv* 2013;82:737-45.
40. Maehara A, Ben-Yehuda O, Ali Z, et al. Comparison of stent expansion guided by optical coherence tomography versus intravascular ultrasound: the ILUMIEN II Study (Observational Study of Optical Coherence Tomography [OCT] in Patients

- Undergoing Fractional Flow Reserve [FFR] and Percutaneous Coronary Intervention). *JACC Cardiovasc Interv* 2015;8:1704-14.
41. Foin N, Secco GG, Ghilencea L, et al. Final proximal post-dilatation is necessary after kissing balloon in bifurcation stenting. *EuroIntervention* 2011;7:597-604.
 42. Karanasos A, Tu S, van Ditzhuijzen NS, et al. A novel method to assess coronary artery bifurcations by OCT: cut-plane analysis for side-branch ostial assessment from a main-vessel pullback. *Eur Heart J Cardiovasc Imaging* 2015;16:177-89.
 43. Kosonen P, Vikman S, Jensen LO, et al. Intravascular ultrasound assessed incomplete stent apposition and stent fracture in stent thrombosis after bare metal versus drug-eluting stent treatment the Nordic Intravascular Ultrasound Study (NIVUS). *Int J Cardiol* 2013;168:1010-6.
 44. Taniwaki M, Radu MD, Zaugg S, et al. Mechanisms of very late drug-eluting stent thrombosis assessed by optical coherence tomography. *circulation* 2016;133:650-60.
 45. wijns w, shite j, jones mr, et al. optical coherence tomography imaging during percutaneous coronary intervention impacts physician decision-making: ILLUMIEN I study. *Eur Heart J* 2015;36:3346-55.
 46. Soeda T, Uemura S, Park SJ, et al. Incidence and clinical significance of poststent optical coherence tomography findings: one-year follow-up study from a multicenter registry. *Circulation* 2015;132:1020-9.
 47. Gutierrez-Chico JL, Regar E, Nuesch E, et al. Delayed coverage in malapposed and side-branch struts with respect to well-apposed struts in drug-eluting stents: in vivo assessment with optical coherence tomography. *Circulation* 2011;124:612-23.
 48. Foin N, Torii R, Alegria E, et al. Location of side branch access critically affects results in bifurcation stenting: Insights from bench modeling and computational flow simulation. *Int J Cardiol* 2013;168:3623-8.
 49. Alegria-Barrero E, Foin N, Chan PH, et al. Optical coherence tomography for guidance of distal cell recrossing in bifurcation stenting: choosing the right cell matters. *EuroIntervention* 2012;8:205-13.
 50. Foin N, Alegria-Barrero E, Torii R, et al. Crush, culotte, T and protrusion: which 2-stent technique for treatment of true bifurcation lesions? Insights from in vitro experiments and micro-computed tomography. *Circ J* 2013;77:73-80.
 51. Viceconte N, Tyczynski P, Ferrante G, et al. Immediate results of bifurcational stenting assessed with optical coherence tomography. *Catheter Cardiovasc Interv* 2013;81:519-28.
 52. Holm NR, Tu S, Christiansen EH, et al. Use of three-dimensional optical coherence tomography to verify correct wire position in a jailed side branch after main vessel stent implantation. *EuroIntervention* 2011;7:528-9.
 53. Okamura T, Onuma Y, Yamada J, et al. 3D optical coherence tomography: new insights into the process of optimal rewiring of side branches during bifurcational stenting. *EuroIntervention* 2014;10:907-15.
 54. Murasato Y, Hikichi Y, Horiuchi M. Examination of stent deformation and gap formation after complex stenting of left main coronary artery bifurcations using microfocus computed tomography. *J Interv Cardiol* 2009;22:135-44.
 55. Zhang JJ, Chen SL. Classic crush and DK crush stenting techniques. *EuroIntervention* 2015;11(Suppl V):V102-5.
 56. Zhang JJ, Chen SL, Ye F, et al. Mechanisms and clinical significance of quality of final kissing balloon inflation in patients with true bifurcation lesions treated by crush stenting technique. *Chin Med J* 2009;122:2086-91.
 57. Abdou SM, Wu CJ. Stent malapposition caused by improper rewiring during left main intervention: the role of intravascular ultrasound in avoidance and management—a case report. *Catheter Cardiovasc Interv* 2011;77:785-9.