




Egyptian Society of Ear, Nose, Throat and Allied Sciences
Egyptian Journal of Ear, Nose, Throat and Allied Sciences

www.ejentas.com



CASE REPORT

Polyostotic fibrous dysplasia of the mandible and bony nasal septum with intracranial expansion



Jura Numminen *, Markus Rautiainen

Department of Ear and Oral Diseases, Tampere University Hospital, Tampere University School of Medicine, P O Box 2000, 33521 Tampere, Finland

Received 28 May 2015; accepted 4 August 2015

KEYWORDS

Fibrous dysplasia;
 Nasal cavity;
 Skull base;
 Endoscopic sinus surgery

Abstract Fibrous dysplasia is an uncommon benign tumour in the nasal cavity. Due to adjacent vital soft tissue structures surgery is often the treatment of choice. We report a rare case of polyostotic fibrous dysplasia of the mandible and the ethmoid bone including nasal bony septum with intracranial expansion, and include a review of the literature. The tumour was successfully resected using a combined transnasal and craniotomy approach. Fibrous dysplasia is a rare benign tumour in the head and neck region, which often limits its growth during the follow-up period. Careful monitoring of the patient is necessary because in some rare cases there can be severe symptoms due to the growth of the tumour, which are indications of immediate surgery in the head and neck region.

© 2015 Egyptian Society of Ear, Nose, Throat and Allied Sciences. Production and hosting by Elsevier B.V. All rights reserved.

1. Introduction

Fibrous dysplasia is a benign uncommon disorder of a bone. It accounts for about 2.5% of all bone tumours and 7.5% of benign bone tumours.^{1,2} Two forms of this disorder have been recognised. The monostotic form represents 70% of the cases and is defined as having only one focus of involvement. The most common sites affected are the femur and costae. Polyostotic fibrous dysplasia is characterised by multiple foci involving several bones. The polyostotic form is sometimes associated with McCune Albright syndrome (MAS) representing as an endocrine disorder and café-au-lait spots.

Histologically fibrous dysplasia has been described as an overgrowth of nondescript fibrotic tissue with a secondary phenomenon of bony metaplasia. More recently, it has been shown that the underlying cause could be a complex derangement in the function of the cells in the osteogenic lineage.^{3,4} A mutation in the subunit of an intracellular G-signalling protein (Gs-a) leads to a loss of guanosine triphosphatase activity of the Gs-a. This leads to increased intracellular cyclic adenosine monophosphate (cAMP) production, increased cell proliferation and inappropriate cell matrix production. It has also been reported that cultured cells from MAS patients secrete excessive interleukine-6 (IL-6) and have an increased amount of intracellular cAMP.⁵

The natural course of the disease is variable. Although the disease is usually progressive before the age of 30, some of the lesions continue growing well into adulthood.^{6,7} There are no uniformly accepted guidelines for treatment of this dis-

* Corresponding author. Tel.: +358 3 31167651.

E-mail address: jura.numminen@pshp.fi (J. Numminen).

Peer review under responsibility of Egyptian Society of Ear, Nose, Throat and Allied Sciences.

<http://dx.doi.org/10.1016/j.ejenta.2015.08.007>

2090-0740 © 2015 Egyptian Society of Ear, Nose, Throat and Allied Sciences. Production and hosting by Elsevier B.V. All rights reserved.

ease. Options include monitoring and medical and surgical treatment. There are many reports of medical treatment with bisphosphonates showing a decrease in pain from the lesions but no resolution of the growth itself.^{8,9} Timing of surgical treatment is variable depending on the location of the lesion and the symptoms it causes.

We describe a very rare case of polyostotic fibrous dysplasia involving the mandible and the base of the skull as well as the ethmoid bone without any other signs of MAS.

2. Case report

A 14 year-old boy was referred from another hospital to the Department of Otorhinolaryngology, Tampere University Hospital for biopsies. The patient had a history of three years' recurrent right-sided mandibular swelling and severe pain. Otherwise his medical history was unremarkable. In the referring unit, the symptoms were first mistaken to be of parotid origin and an ultrasound and sialography were obtained with no significant findings. The patient was treated with repeated courses of antibiotics with no relief in the symptoms. An orthopantomogram (OPTG) was obtained and it showed a lesion susceptible to chronic osteomyelitis and the patient was treated with a course of oral clindamycin and metronidazole. During the treatment the symptoms reduced somewhat. Later on, a magnetic resonance image (MRI) was obtained. It showed a lesion (size 2 cm in diameter) in the mandible and incidentally another lesion (size 3.5 × 2 cm) in the anterior cranial base continuing into the nasal bony septum and ethmoidal cells (Fig. 1). The patient was then asked about nasal symptoms and a history of nasal obstruction and discharge was given. A scintigraphy was also obtained and it showed no other lesions. Both lesions in the mandible and in the septum were biopsied. Both biopsies showed fibrous dysplasia. The patient was treated with a course of bisphosphonate (disodium clodronate – Bonafos® – 2400 mg a day for 6 months) during which the symptoms in the mandibular region resolved completely. Eighteen months after the initial referral, however, he developed blurred vision, occasional double vision and his nasal congestion worsened, and he was

referred again for consultation. Computed tomography (CT)-scan showed a slow growth in tumour size in the nasal cavity. It was measured at 5.2 × 2.2 cm in size. The surgery was now indicated because of exacerbation of the nasal symptoms and development of occasional ocular symptoms. This was presumed to be a possible symptom presentation of the intracranial growth of the tumour. Combined approaches were chosen as an operative technique. The neurosurgeon performed an anterior craniotomy through a coronal incision. During the craniotomy, a neurosurgeon completed the subtotal resection of the tumour using dissectors and curettes. The dural defect was then repaired with one piece of temporal fascia, fibrin glue and an Ethisorb™ Dura Patch. The residual tumour in the nasal cavity was then resected endoscopically through the nose by an ear, nose and throat specialist using endoscopic sinus surgery instruments and angled scopes. The patient had no immediate complications and was discharged a few days later. The follow-up CT nearly two years after the surgery showed an “egg-shell” of the bony septum filled with retention fluid but no residual tumour growth. In the control visit 10 years later, in 2014, the patient was symptom-free.

3. Discussion

Fibrous dysplasia represents a rare benign bony tumour that occurs predominantly in young adults. The most common location is the thorax and extremities, and it is very rarely seen in the head and neck region. It has been reported that 50–100% of patients with a polyostotic form of the disease have craniofacial involvement whereas in the monostotic form only 10% have a lesion in the head and neck region. In craniofacial involvement surgery is indicated if the lesion compromises vision or aesthetics or causes other significant discomfort.¹⁰ A recent report of 26 patients showed cranial involvement of the fibrous dysplasia, including the frontal, parietal, sphenoidal, and occipital bones in 13 (52%) patients. The tumour was located in the maxillary bone in 9 (33%) patients. Temporal bone involvement was found in 3 (11%) patients. One patient (4%) had mandibular involvement.¹¹ Eth-

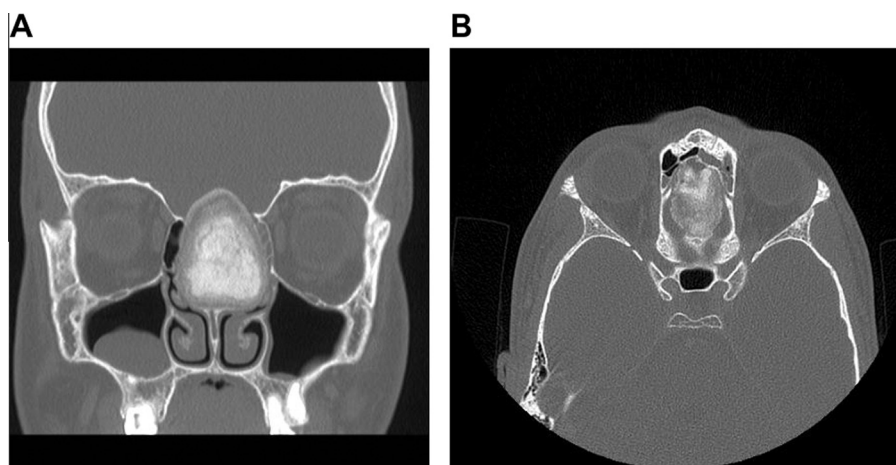


Figure 1 Pre-operative CT images. (A) Image with coronal section shows a huge fibrous dysplasia in nasal septum reaching through the skull base. (B) Axial section shows the width of the tumour, which is passing from skull base defect.

moidal involvement is a rarity. To our knowledge, a polyostotic form of the disease involving the ethmoid bone and nasal septum has not been previously reported in the literature.

We assumed that our patient's visual symptoms were caused by the optic nerve being irritated by the tumour. A review of the literature showed that the pathogenesis of the visual symptoms is not fully understood yet. It has been proposed that disturbances in the venous drainage of the optic nerve and ultimately decreased retinal perfusion could be the underlying mechanism. Other theories include traction on the optic nerve, spontaneous haemorrhage or sinus mucocele formation.¹⁰ It has generally been accepted that tumours encasing the optic nerve should be resected and a decompression of the optic nerve should be performed. Some authors have suggested that decompression should be done prophylactically in cases with optic nerve involvement. However, a recent study showed that in a series of 107 optic nerves that were 100% encased, 88% exhibited no evidence of optic neuropathy. There was no difference in age between groups with less than 50%, 50–99%, and 100% encasement, and patients with optic neuropathy were not older than those without optic neuropathy. These data support the conclusion that encasement does not progress with age and that increasing age does not necessarily bring with it the likelihood of optic neuropathy and blindness. Based on this evidence, the authors do not recommend prophylactic decompression on patients without symptoms merely as an attempt to prevent possible future optic neuropathy. The authors also show that vision loss is more often associated with either growth hormone excess related to MAS or an aneurysmal bone cyst.¹² Our patient reported intermittent blurred vision and double vision although CT showed no direct optic nerve involvement. Postoperatively all the visual symptoms were resolved, but the primary reason for the double vision and blurred vision remained unclear.

4. Conclusion

Fibrous dysplasia is a benign bone lesion characterised by progressive replacement of normal bone by fibrous tissues. The clinical picture is variable from asymptomatic patients to patients with severe symptoms presenting as pain and pathological fractures. Fibrous dysplasia and especially a polyostotic form of fibrous dysplasia is a real rarity that presents diagnostic and treatment challenges to us. As our case demonstrates, bony lesions in the mandibular region can sometimes mimic soft tissue problems. One should always strive for a histological or at

least a radiological diagnosis, especially when treatment attempts have failed. This case also demonstrates the need for careful monitoring of tumours located in areas where the tumour growth can lead to possibly devastating complications.

Conflict of Interest

None.

References

- Hoffman, Jacoway JR, Krolls SO. Fibrous dysplasias: Benign nonodontogenic tumors of the jaws *Intraosseous and Parosteal Tumors of the Jaws*. 2 ed. Bethesda, MD: AFIP; 1987.
- Edgerton, Persing JA, Jane JA. The surgical treatment of fibrous dysplasia with emphasis on recent contributions from craniomaxillo-facial surgery. *Ann Surg*. 1985;202:459–478.
- Marie, de Pollak C, Chanson P, et al. Increased proliferation of osteoblastic cells expressing the activating Gs a mutation in monostotic and polyostotic fibrous dysplasia. *Am J Pathol*. 1997; 150:1059–1069.
- Riminucci M, Fisher LW, Shenker A, et al. Fibrous dysplasia of bone in the McCune–Albright syndrome: abnormalities in bone formation. *Am J Pathol*. 1997;151:1587–1600.
- Yamamoto T, Ozono K, Kasayama S, et al. Increased IL-6 production by cells isolated from the fibrous bone dysplasia tissues in patients with McCune–Albright syndrome. *J Clin Invest*. 1996;98:30–35.
- Harris WH, Dudley Jr HR, Barry RJ. The natural history of fibrous dysplasia: an orthopedic, pathological and roentgenographic study. *J Bone Joint Surg Am*. 1962;44:207–233.
- Davies ML, MacPherson P. Fibrous dysplasia of the skull: disease activity in relation to age. *Br J Radiol*. 1991;64:576–579.
- Chapurlat RD, Delmas PD, Liens D, Meunier PJ. Long-term effects of intravenous pamidronate in fibrous dysplasia of bone. *J Bone Miner Res*. 1997;12:1746–1752.
- Liens D, Delmas PD, Meunier PJ. Long-term effects of intravenous pamidronate in fibrous dysplasia of bone. *Lancet*. 1994;343: 953–954.
- Ricalde P, Horswell BB. Craniofacial fibrous dysplasia of the fronto-orbital region: a case series and literature review. *J Oral Maxillofac Surg*. 2001;59:157–167.
- Yetiser S, Gonul E, Tosun F, et al. Monostotic craniofacial fibrous dysplasia: the Turkish experience. *J Craniofac Surg*. 2006;17: 62–67.
- Cutler C, Lee J, Butman J, et al. Long-term outcome of optic nerve encasement and optic nerve decompression in patients with fibrous dysplasia: risk factors for blindness and safety of observation. *Neurosurgery*. 2006;59(5):1011–1017.