

SHORT COMMUNICATION

Long-term Outcome of Daylight Photodynamic Therapy with Amino-5-laevulinate Nanoemulsion vs. Methyl-5-aminolaevulinate for Actinic Keratoses

Noora Neittaanmäki-Perttu^{1,2}, Mari Grönroos², Taneli Tani³ and Erna Snellman⁴

¹Department of Dermatology and Allergology, Helsinki University and Helsinki University (Central) Hospital, FIN-00029 Helsinki, Departments of ²Dermatology and Allergology and ³Pathology, Päijät-Häme Social and Health Care Group, Lahti, and ⁴Department of Dermatology, Tampere University and Tampere University Hospital, Finland. E-mail: noora.neittaanmaki@finnet.fi

Accepted Jan 21, 2016; Epub ahead of print Jan 25, 2016

Photodynamic therapy with daylight (DL-PDT) is a promising treatment modality for actinic keratoses (AK). It enables the convenient and painless treatment of large areas of photo-damaged skin, and has excellent cosmetic outcome. DL-PDT using methyl-5-aminolaevulinate (MAL) has shown equal efficacy with conventional light-emitting diodes (LED)-PDT (1–3). However, all the current studies of DL-PDT have limited follow-up periods of 3 or 6 months (1–5). As AKs tend to regress spontaneously and reoccur over time (6), it is crucial to determine the long-term efficacy of treatment. In our previously published non-sponsored, randomized, double-blinded, prospective pilot trial, amino-5-laevulinate nanoemulsion (BF-200 ALA) showed a trend towards improved efficacy compared with MAL in DL-PDT for AKs (7). We report here the long-term (12-month) clinical and histological outcomes of the same pilot trial.

MATERIALS AND METHODS

The methods have been described previously in detail (7). Patients with symmetrical actinic damage in the head area who volunteered to enter the study, were treated in August and September 2013. Prior to treatment, all lesions were photographed, counted and marked on a plastic sheet, and 2 symmetrical equally graded (8) AKs were biopsied bilaterally. A chemical sunscreen (P20[®], SPF 20 Riemann & C0. A/S, Hilleroed, Denmark) was applied and after 15 min the treatment areas were curettaged followed by application of the photosensitizers (0.25-mm thick layer). Patients were randomized to receive DL-PDT with BF-200 ALA (Ameluz, Biofrontera, Leverkusen, Germany) on one

side of the face or scalp and MAL (Metvix, Galderma, Paris) on the other with 2-h illumination outdoors. Follow-up visits, conducted by the same blinded investigator (MG), included the mapping of the residual lesions, as well as histological sampling. Histology was interpreted by a blinded pathologist (TTT). For statistical analysis the following tests were used: Wilcoxon’s signed-rank paired test: baseline characteristics, lesion clearance, area complete response, histological clearance, reduction in p53; and McNemar’s test: complete field clearance.

RESULTS

All 13 patients in the initial 3-month analyses continued to follow-up at 12 months. Between the 3- and 12-month control visits one grade I AK in the MAL group and two grade II AKs in the BF-200 ALA area were treated using cryosurgery, as requested by the patients. Of these, the lesion in the MAL group was still present at 12 months, while the lesions in the BF-200 ALA group cleared. Other lesions were treated only after the 12-month follow-up.

At 12 months in per patient half-face analysis, 9 of the 13 (69.2%, 95% confidence interval (CI) 44.1–94.3) fields treated with BF-200 ALA and 3 of 13 (23.1%, 95% CI 0.2–46.0) fields treated with MAL were completely cleared of AKs ($p=0.07$). The mean complete lesion clearance rate per patient (half-face) was 87% for BF-200 ALA and 62% for MAL ($p=0.007$) (Table I). The medians (percentiles 25 and 75) for lesion clearance were 100 (73.2, 100) for BF-200 ALA and 60 (41.7, 90.9) for MAL. The area complete response including the baseline and new lesions (preventive effect) were 83.3% for BF-200 ALA and 59.1% for MAL ($p=0.0021$).

If we assume that no lesion had been treated with cryosurgery before the 12-month follow-up (and were still present at 12 months) the clearance rates would have been as follows: mean complete lesion clearance rate per patient (half-face) 83% vs. 62% ($p=0.055$) and area complete response 81% vs. 59.1% ($p=0.0071$), for BF-200 ALA and MAL, respectively.

For histological analysis, one AK lesion on both treatment sides was biopsied before treatment, and the same area was biopsied again at 3 and 12 months. One patient who was clinically completely cleared refused histological sampling at the 12-month visit. Thus, 12 patients were biopsied bilaterally after 12 months.

Table I. Mean area and lesion clearance rates at 12 months

	Total lesions, <i>n</i>				Complete clearance ^c	Area CR ^d
	Baseline	12 mo.	Res. ^a	Rec. ^b		
BF-200 amino-5-laevulinate						
Total	84	14	8	6	87%	83.3%
Grade I	61	13	8	5		
Grade II–III	23	1	0	1		
Methyl-5-aminolaevulinate						
Total	93	38	18	16	62%	59.1%
Grade I	73	34	15	15		
Grade II–III	20	4	3	1		
<i>p</i> -values	0.496				0.007	0.0021

^aRes.: Residual. Lesions present at baseline, 3- and 12-month follow-up. ^bRec.: Recurrent. Lesions present at baseline, cleared at 3 months and reoccurred at 12 months. ^cMean complete clearance of lesions, per patient. ^dArea complete response (CR) includes the residual and new lesions.

The complete histological clearance rates were 6 of 12 (50%) for BF-200 ALA and 5 of 12 (41.6%) for MAL ($p=0.417$). Surprisingly, at 12 months, mean p53 expression was 45.4% of the baseline level in the BF-200 ALA group, while it had increased to 96% in the MAL group ($p=0.182$) (Fig. 1).

DISCUSSION

The results of this study show, for the first time, the long-term (12 months) efficacy of DL-PDT. They suggest that, in a long-term follow-up, BF-200 ALA is more effective compared with MAL in the treatment of AKs with DL-PDT. Our planned next step is to see if this result can be confirmed in a larger trial.

At 12 months, BF-200 ALA showed better maintained clearance than MAL. As we used an intra-patient study design, the per patient field response rates (69% for BF-200 ALA and 23% for MAL) are indicative of the patient complete response rates. Interestingly, the depressed p53 expression only minimally increased between 3 and 12 months after treatment in the BF-200 ALA group while in the MAL group p53 expression was increased close to the baseline level. This may indicate a better long-term reversal in the carcinogenesis with BF-200 ALA. However, the same finding of better reversal in carcinogenesis was not seen in the HE-stainings, which may be due to the small sample size. Potentially better reversal in carcinogenesis in BF-200 ALA group is also supported by the fact that the MAL group developed more new lesions after 3 and 12 months than the BF-200 ALA group. AK counts can also change spontaneously, with high regression and recurrence rates (6). Thus, it is important not only to report the clearance of the baseline lesions, but also the

preventive effect on the whole treated field. For this, we used an experimental analysis of area complete response.

A limitation of this study was the small sample size, including only 13 patients, and that a few lesions were treated between the 3- and 12-month follow-ups. However, this was taken into account when interpreting the results.

In conclusion, in 12-month follow-up, DL-PDT with BF-200 ALA shows improved efficacy compared with MAL.

ACKNOWLEDGEMENTS

The study was supported by the Foundation for Clinical Chemistry Research.

Conflicts of interest: NN-P received travel grants from Biofrontera and Galderma and was speaker honoraria for Biofrontera and Desitin Pharma. MG, TTT and ES have no conflicts of interest to declare.

REFERENCES

1. Wiegell SR, Haedersdal M, Philipsen PA, Eriksen P, Enk CD, Wulf HC. Continuous activation of PpIX by daylight is as effective as and less painful than conventional photodynamic therapy for actinic keratoses; a randomized, controlled, single-blinded study. *Br J Dermatol* 2008; 158: 740–746.
2. Rubel DM, Spelman L, Murrell DF, See JA, Hewitt D, Foley P, et al. Daylight photodynamic therapy with methyl aminolevulinate cream as a convenient, similarly effective, nearly painless alternative to conventional photodynamic therapy in actinic keratosis treatment: a randomized controlled trial. *Br J Dermatol* 2014; 171: 1164–1171.
3. Lacour JP, Ulrich C, Gilaberte Y, Von Felbert V, Basset-Seguín N, Dreno B, et al. Daylight photodynamic therapy with methyl aminolevulinate cream is effective and nearly painless in treating actinic keratoses: a randomised, investigator-blinded, controlled, phase III study throughout Europe. *J Eur Acad Dermatol Venereol* 2015; 29: 2342–2348.
4. Wiegell SR, Haedersdal M, Eriksen P, Wulf HC. Photodynamic therapy of actinic keratoses with 8% and 16% methyl aminolevulinate and home-based daylight exposure: a double-blinded randomized clinical trial. *Br J Dermatol* 2009; 160: 1308–1314.
5. Wiegell SR, Fabricius S, Stender IM, Berne B, Kroon S, Andersen BL, et al. A randomized, multicentre study of directed daylight exposure times of 1½ vs. 2½ h in daylight-mediated photodynamic therapy with methyl aminolevulinate in patients with multiple thin actinic keratoses of the face and scalp. *Br J Dermatol* 2011; 164: 1083–1090.
6. Werner RN, Sammain A, Erdmann R, Hartmann V, Stockfleth E, Nast A. The natural history of actinic keratosis: a systematic review. *Br J Dermatol* 2013; 169: 502–518.
7. Neittaanmäki-Perttu N, Karppinen TT, Grönroos M, Tani TT, Snellman E. Daylight photodynamic therapy for actinic keratoses: a randomized double-blinded nonsponsored prospective study comparing 5-aminolevulinic acid nanoemulsion (BF-200) with methyl-5-aminolevulinate. *Br J Dermatol* 2014; 171: 1172–1180.
8. Olsen EA, Abernethy ML, Kulp-Shorten C, Callen JP, Glazer SD, Huntley A, et al. A double-blind, vehicle-controlled study evaluating masoprocol cream in the treatment of actinic keratoses on the head and neck. *J Am Acad Dermatol* 1991; 24: 738–743.

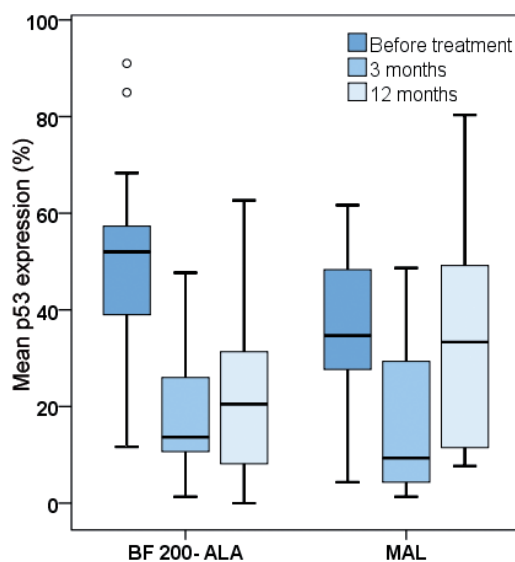


Fig. 1. Mean p53 expression (%) prior to and after photodynamic therapy with daylight for actinic keratoses, in the presence of methyl-5-aminolevulinate (MAL) or amino-5-laevulinate (BF-200 ALA) nanoemulsion.