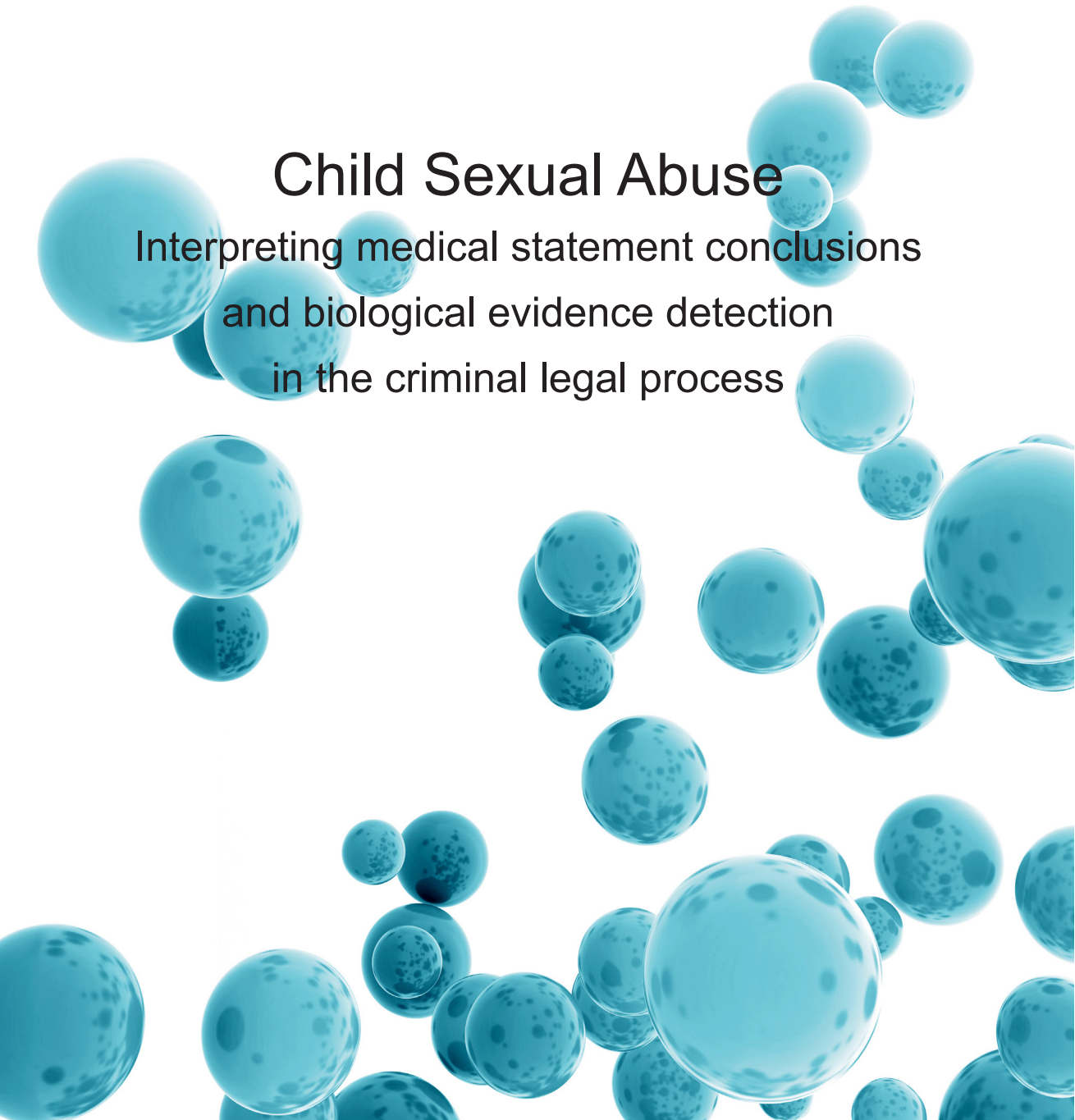


MINNA JOKI-ERKKILÄ

Child Sexual Abuse

Interpreting medical statement conclusions
and biological evidence detection
in the criminal legal process





MINNA JOKI-ERKKILÄ

Child Sexual Abuse

Interpreting medical statement conclusions
and biological evidence detection
in the criminal legal process



ACADEMIC DISSERTATION

To be presented, with the permission of
the Board of the School of Medicine of the University of Tampere,
for public discussion in the small auditorium of building M,
Pirkanmaa Hospital District, Teiskontie 35, Tampere,
on 2 October 2015, at 12 o'clock.

UNIVERSITY OF TAMPERE

MINNA JOKI-ERKKILÄ

Child Sexual Abuse

Interpreting medical statement conclusions
and biological evidence detection
in the criminal legal process

Acta Universitatis Tamperensis 2087
Tampere University Press
Tampere 2015

ACADEMIC DISSERTATION

University of Tampere, School of Medicine
Tampere University Hospital, Departments of Child Psychiatry and
Gynecology and Obstetrics
Finland

Supervised by

Professor Pekka J. Karhunen,
University of Tampere
Finland
Professor emeritus Pentti K. Heinonen
University of Tampere
Finland

Reviewed by

Docent Dan Apter
University of Helsinki
Finland
Professor Annie Vesterby Charles
University of Aarhus
Denmark

The originality of this thesis has been checked using the Turnitin OriginalityCheck service in accordance with the quality management system of the University of Tampere.

Copyright ©2015 Tampere University Press and the author

Cover design by
Mikko Reinikka

Distributor:
verkkokauppa@juvenesprint.fi
<https://verkkokauppa.juvenes.fi>

Acta Universitatis Tamperensis 2087
ISBN 978-951-44-9887-9 (print)
ISSN-L 1455-1616
ISSN 1455-1616

Acta Electronica Universitatis Tamperensis 1581
ISBN 978-951-44-9888-6 (pdf)
ISSN 1456-954X
<http://tampub.uta.fi>

Suomen Yliopistopaino Oy – Juvenes Print
Tampere 2015



ERRATA

Errors in citations and references revised as follows

- page 20, 4th paragraph, 3rd line: “White et al.2006” should be “White and McLean 2006”
- page 21, 3rd paragraph, 5th line: “Lauber et al. 1982” should be “Lauber and Souma 1982”
- page 22, chapter 2.2.1, 3rd paragraph, 2nd line: “Heger et al. 2000a” should be “Heger et al. 2002a”
- page 32, chapter 2.2.9, 3rd paragraph, 7th line: double citation. Omitted (Adams et al. 2012).
- page 36, chapter 2.3, 2nd paragraph, lines 10-11: incorrect order of citations “(Adams 2008, Adams 2011, Adams et al 2007, Royal College of Paediatrics and Child Health 2008).” should be “(Adams et al 2007, Adams 2008, Royal College of Paediatrics and Child Health 2008, Adams 2011).”
- page 36, chapter 2.3, 3rd paragraph, lines 3-4: incorrect order of citations “(Finkel and Alexander 2011, Adams 2008, Adams 2011, Adams et al. 2007, Royal College of Paediatrics and Child Health 2008).” should be “(Adams et al. 2007, Adams 2008, Royal College of Paediatrics and Child Health 2008, Finkel and Alexander 2011, Adams 2011).”
- page 37, 2nd paragraph, last line: initials were omitted from the citation “Berkowitz CD 2011” “Berkowitz 2011”
- page 66, chapter 6.3.2, 3rd paragraph, 3rd line: citation of WHO revised to “(WHO 2012)
- page 75, 5th reference: “Astrup BS, Thomsen JL, Lauritsen J, Ravn P (2012ab): Detection of spermatozoa following consensual sexual intercourse. Forensic Sci Int 221:137-141.” should be “Astrup BS, Thomsen JL, Lauritsen J, Ravn P (2012b): Detection of spermatozoa following consensual sexual intercourse. Forensic Sci Int 221:137-141.”
- page 75, 2nd reference of “Anderson S, Parker B, Bourguignon C (2008): Changes in genital injury patterns over time in women after consensual intercourse. J Forensic Leg Med. 15:306–311.” should be omitted because it is not used in the thesis.
- page 81, 1st reference: “Jones JS, Rossman L, Hartman M, Alexander CC (2003bc): Anogenital injuries in adolescents after consensual sexual intercourse. Acad Emerg Med 10: 1378-1383.” should be “Jones JS, Rossman L, Hartman M, Alexander CC (2003c): Anogenital injuries in adolescents after consensual sexual intercourse. Acad Emerg Med 10: 1378-1383.”
- page 82, 13th reference: “McCann J, Voris J (1993): Perianal injuries resulting from sexual abuse. A longitudinal study. Pediatrics 91:390-397” should be “McCann J, Voris J (1992): Perianal injuries resulting from sexual abuse. A longitudinal study. Pediatrics 91:390-397.”

Revisions in chapter 4.2.3

- page 45, 1st paragraph, 4th line: “The entire urine volume was collected.” should be “The urine volume was collected as much as possible.”
- page 45, 2nd paragraph, 3rd line: “Separate urine collection bottle(s) were given for preserving the urine in the refrigerator.” revised as “Collected urine samples were preserved in urine bottle(s) in the refrigerator.”

Errors in Table topic titles revised as follows

- page 63: Table topic “Figure 9” should be revised “Table 7.”
- page 65: Table topic “Figure 10” should be revised “Table 8.”
- In Table 7 (page 63) a space should be added to the table lines between citation lines of Anderson et al. 2006 and McLean et al 2010.

Errors in the text in

- page 64, 1st paragraph, lines 4-6: “every third participant of vaginal delivery with episiotomy healed with a regular mucosal surface, and these participants had no visible scarring under white or UV-light.” revised as “every third participant of vaginal delivery with episiotomy or rupture of vaginal outlet wall healed with a regular mucosal surface, and two of these participants had no visible scarring under white or UV-light.”
- page 64, chapter 6.3, 4th paragraph, 1st line: “The quantity of measurable male DNA (median 0.9 ng/μl)” should be “The quantity of measurable male DNA (median 0.68 ng/μl)”.
- page 65, chapter 6.3.1, 1st paragraph, 3rd line: “Table 10” revised to “Table 8”.
- page 67, chapter 6.4, 1st paragraph, last sentence: the two commas should be omitted.

*To the glory of God,
may He comfort all the victims of crime*

Contents

Contents

List of Original Communications

Abbreviations

Abstract

- 1 Introduction 17
- 2 Review of Literature 18
 - 2.1 Clinical examination techniques 19
 - 2.2 Common misconceptions interpreting child sexual abuse 21
 - 2.2.1 Integrity of hymen 22
 - 2.2.2 Hymenal findings after vaginal penetration 22
 - 2.2.3 Anogenital healing 23
 - 2.2.3.1 Hymenal healing 23
 - 2.2.3.2 Non-hymenal healing studies on anogenital findings 24
 - 2.2.3.3 Time-frame since the last suspected sexual event to medical examination; findings and healing 24
 - 2.2.4 Anogenital injury potential 26
 - 2.2.5 Consensual versus non-consensual anogenital injuries 27
 - 2.2.6 Anogenital findings and inexperienced examiner 28
 - 2.2.6.1 Some physical findings detected in both abused and non-abused children 29
 - 2.2.6.2 Hymenal findings in non-abused and in suspected sexual abuse children 29
 - 2.2.6.3 Anal findings in non-abused and in suspected sexual abuse children 30

2.2.7	Hymen and use of tampons.....	31
2.2.8	Multiple assailants.....	31
2.2.9	Significance of the physician.....	32
2.2.10	Biological evidence collection in suspected sexual abuse.....	33
2.2.10.1	Detection of biological evidence in children.....	33
2.2.10.2	Detection of spermatozoa in adolescents and /or adults	34
2.2.10.3	Detection of Y-DNA in adolescents and /or adults	35
2.3	Medical decision making.....	36
2.4	Criminal legal process.....	37
2.4.1	Physical findings and legal outcome.....	37
2.4.2	Spermatozoa, DNA and legal outcome.....	38
2.4.3	Other factors and legal outcome.....	39
2.4.4	Elements for successful prosecution.....	40
3	Aims of the Study.....	41
4	Materials and Methods	42
4.1	Data collection.....	42
4.1.1	For evaluation of medical statement conclusions in the criminal legal process (I)	42
4.1.1.1	Exclusion criteria (I)	42
4.1.1.2	Variables collected from medical records, preliminary investigation files, prosecutor’s files, District Court and Court of Appeal (I).....	43
4.1.2	Participant recruitment for the studies II-IV	43
4.1.2.1	Medical and sexual variables for studies II-IV	43
4.2	Clinical forensic documentation and sampling techniques following consensual intercourse in adult volunteers (II-IV).....	44
4.2.1	Examination and documentation techniques for UV-study (II).....	44

4.2.2	Vaginal and cervical sample collection (III)	44
4.2.3	Urine sample collection (IV)	45
4.3	Laboratory techniques (III-IV)	45
4.3.1	DNA extraction and quantification (III-IV)	45
4.3.2	Microscopic analysis (III-IV)	45
4.3.3	Contamination issues (III-IV)	46
4.3.4	Statistics	46
4.3.5	Ethical considerations	46
5	Results	47
5.1	The criminal legal process and medical statement conclusions (I)	47
5.1.1	Study population and alleged victimization (I)	47
5.1.2	Criminal investigations and medical statement conclusions (I)	48
5.1.2.1	Medical findings (I)	48
5.1.2.2	Biological traces of evidence (I)	49
5.1.2.3	Type of suspected abuse (I)	49
5.1.2.4	Cases closed during criminal investigation (I)	49
5.1.3	Prosecution and medical statement conclusions (I)	49
5.1.3.1	Decisions to dismiss charges and medical statements (I)	50
5.1.4	Court decisions and medical statements (I)	50
5.1.4.1	Acquittals (I)	50
5.1.4.2	Perpetrator's confession of CSA (I)	50
5.2	Evidence collection in volunteers (II-IV)	50
5.2.1	Detection of acute anogenital injury under white and UV-light (II)	51
5.2.1.1	Age and acute genital findings (II)	51

5.2.2	Genital scars under white and UV-light (II)	52
5.2.3	Forensic evidence specimens collected from vagina, cervical canal and urine (III-IV)	52
5.2.3.1	Cut-off limits of the possibility of identifying DNA from swab, brush and urine samples (III-IV)	53
5.2.3.2	Microscopy (III-IV)	54
5.2.4	Timing issues (II-IV)	55
5.2.4.1	Time-frame for injury detection (II)	55
5.2.4.2	Time-frame for Y-DNA detection (III-IV)	55
5.2.4.3	Time-frame for spermatozoa detection in microscopy (III-IV)	56
5.2.4.4	Possible factors affecting the detection of acute genital findings, genital scars, Y-DNA or spermatozoa (II-IV)	57
6	Discussion	59
6.1	Medical statement conclusions in the criminal legal process (I)	59
6.1.1	The Child's disclosure of alleged CSA (I)	60
6.1.2	Sexual violence and legal outcome (I)	60
6.2	The possibility of previous injury cannot be ruled out by delayed medical examination (II)	61
6.3	Forensic collection methods for spermatozoa and DNA following consensual intercourse (III-IV)	64
6.3.1	Spermatozoa and DNA collection in alleged CSA (I)	65
6.3.2	Timing of collecting biological forensic samples (III-IV)	66
6.4	Strengths, limitations and some ethical considerations	67
6.5	Future implications	69
7	Summary	70
8	Conclusions	71
9	Acknowledgements	72

10	References	74
11	Original Communications.....	89

List of Original Communications

This thesis is based on the following original articles:

- I. Joki-Erkkilä M, Niemi J, Ellonen N (2014): Child sexual abuse – Medical statement conclusions in criminal legal process. *Forensic Sci Int* 239:31-36.
- II. Joki-Erkkilä M, Rainio J, Huhtala H, Karhunen PJ (2014): Evaluation of anogenital injuries using white and UV-light among adult volunteers following consensual sexual intercourse. *Forensic Science International*. 242:293-298.
- III. Joki-Erkkilä M, Tuomisto S, Seppänen M, Huhtala H, Ahola A, Rainio J, Karhunen PJ (2014): Clinical forensic sample collection techniques following consensual intercourse in volunteers - Cervical canal brush compared to conventional swabs. *Journal of Forensic and Legal Medicine* 27:50-54.
- IV. Joki-Erkkilä M, Tuomisto S, Seppälä M, Huhtala H, Ahola A, Karhunen PJ. Urine specimen collection following consensual intercourse – a forensic evidence collection method for Y-DNA and spermatozoa. *Submitted*.

The publisher has kindly granted copyright permission to reproduce these articles in this thesis.

ABBREVIATIONS

BMI	body mass index
CSA	child sexual abuse
FN	fossa navicularis, fossa
ICD-10	International Classification of Disease and Related Health Problems, World Health Organization 2005
PCR	polymerase chain reaction
PF	posterior fourchette, posterior commissure
UV-light	ultraviolet light
WHO	World Health Organization
Y-DNA	male deoxyribonucleic acid
Y-STR	short tandem repeats on male-specific Y chromosome

DEFINITIONS

Abrasion	mucous membrane or skin excoriation caused by the removal of epidermal layer and with defined edge
Child	an individual under the age of 18 years
Fissure	superficial partial split in mucous membrane or skin, which does not extend to subcutaneous tissue
Hart's line	line between non-keratinized and keratinized squamous epithelium
Laceration	skin or mucosal wound with separation of the connective tissue elements and it may extend to subcutaneous tissue. None of the skin or mucosa is missing, but it is just separated
Petechiae	pinpoint, flat, round spot of blood under mucosa or skin, caused by intradermal or intramucosal bleeding
Residual findings	objective findings of previous trauma; anatomic changes, scars
Scar	area of fibrous tissue that replaces normal skin after injury
Submucosal hemorrhage	small hemorrhage under mucous membrane
Vestibule	area between hymen and Hart's line

ABSTRACT

Background. The majority of child sexual abuse (CSA) victims have only minor injuries or no physical findings at all in the medical examination, depending on the type of sexual abuse and the time delay. This is a complex and challenging issue to be understood in the decision making process at all stages of criminal legal interpretation. Still, there are many myths, even among professionals, regarding sexual violence, leading to over-diagnosis or under-diagnosis. The present situation calls for an increase in the knowledge of the interpretation of genital findings and timing issues as well as new methods to be applied.

Objective. The aim was to evaluate the interpretation of genital findings and timing issues in medical decision making among victims of child sexual abuse in medical statement conclusions and the importance of it in the criminal legal process. Clinical forensic evidentiary collection techniques were evaluated in adult volunteers following consensual intercourse.

Methods. The studies were conducted in two different series. The first consisted of (I) medically examined, police reported alleged victims of child sexual abuse with final legal outcomes; and the second of adult female volunteers attending a medical examination following consensual intercourse. The latter evaluated three different perspectives of forensic evidence collection; (II) the use of ultraviolet light compared to white light in documenting acute injury and scars, the clinical forensic sampling techniques of (III) a cervical brush compared to traditional sampling techniques and (IV) the value of post-coital urine samples as a source of Y-DNA and spermatozoa.

Results. In the criminal legal process, a child's clear disclosure of the sexual abuse was the most important evidence and the medical statement conclusions had a significant role in decision making (study I). In the majority of cases the medical statement conclusion neither supported nor excluded the suspicion of CSA. Even a lack of physical evidence, when consistent with alleged sexual abuse type and a child's disclosure, supported the interpretation of evidence in the criminal legal process.

Following consensual intercourse the acute genital injury rate was 14.8% under white light colposcopy and 23.0% using UV light among 88 adult volunteers within 5.5 days (study II). In the genital area submucosal hemorrhages and delivery-associated scars were documented significantly better under UV-light than white light. Furthermore, one third of women had no residual anogenital skin or mucosal surface findings, despite prior episiotomy or rupture of the vaginal outlet wall during delivery.

Combining collecting techniques of vaginal and cervical swabs and brush samples, 81.0% of the volunteers (N=84) were Y-DNA positive within 6 days (study III). By combining swab and brush techniques, 75% of the volunteers had still measurable Y-DNA within 72-144 post-coital hours. The rate of measurable Y-DNA decreased approximately 3% per hour. Despite reported consensual intercourse, 6.8% (3/44) of volunteers were Y-DNA negative within 48h. Y-DNA was no longer detected after 144 post-coital hours (6 days). Following consensual intercourse, the benefit of cervical brush sample collection for Y-DNA detection was found after 60 hours when compared to traditional swab collection.

In study IV, correctly collected urine specimens were an excellent source for Y-DNA within 24 hours. The benefit of post-coital urine samples was that it collected a high quantity of male DNA, and it was a non-invasive collection method for forensic purposes.

Conclusions. The present results highlight the fact that medical examinations cannot exclude suspicion of child sexual abuse. Negative biological evidence results do not exclude the possibility of sexual assault

even when collected within 72 hours. The timing and accurate documentation of the medical examination results need to be evaluated and interpreted case by case in the medical statements considering the disclosure of CSA and differential diagnostics of a physical finding. The enormous healing potential should be considered in the criminal legal process to avoid misunderstandings in victims of sexual violence.

Limiting the forensic biological evidence collection only to 72 hours may cause potential loss of evidence. When acute sexual assault is suspected, it is important to consider performing an acute clinical examination up to 6 days afterwards because even minor injury can still be detectable.

For the best possible genital evidence collection, high quality documentation and combining forensic evidence collection from multiple sites with different techniques is recommended. Also, urine samples may be considered as a good additional forensic evidence collection method in acute suspected child sexual abuse cases, to diminish the time delay and to improve patients' positive attitudes towards evidence collection.

TIIVISTELMÄ

Somaattisessa tutkimuksessa todetaan lapsen seksuaalisen hyväksikäytön uhreista valtaosalla vain joko vähäisiä vammoja tai ei ollenkaan fyysisiä löydöksiä riippuen hyväksikäyttötavasta ja tutkimusajankohdasta. Fyysisen löydöksen tai sen puuttumisen tulkinta on monimutkainen ja haastava tehtävä kaikilla rikosoikeudellisen prosessin päätöksenteon tasoilla. Edelleen jopa ammattilaisten parissa elää myyttejä, jotka voivat johtaa yli- tai alidiagnostiikkaan. Nykyinen tilanne fyysisten sukupuolielin löydösten tulkinnan, tutkimusajankohdan ja – menetelmien suhteen vaatii tiedon syventämistä.

Tutkimuksen tavoitteena oli arvioida lääketieteellisesti tutkittujen lapsen seksuaalisen hyväksikäyttöepäilyuhrien sukuelin alueen löydösten tulkintaa ja tutkimusajankohdan merkitystä lääkärintlausuntojen johtopäätösten päätöksenteossa ja niiden merkitystä rikosoikeudellisessa prosessissa. Kliinisen oikeuslääketieteellisen näytön eri taltiointimenetelmiä arvioitiin vapaaehtoisen yhdynnän jälkeen aikuisilla naisilla.

Tutkimus suoritettiin kahdella eri aineistolla. Ensimmäinen tutkimusaineisto koostui somaattisesti tutkituista, poliisin tutkinnassa olleista lapsen seksuaalisen hyväksikäyttöepäilyn uhreista, joilla oli tiedossa rikosoikeudellisen prosessin ratkaisu. Toinen tutkimusaineisto koostui aikuisista vapaaehtoisista naisista, jotka suostuivat tutkimukseen vapaaehtoisen yhdynnän jälkeen. Viimeksi mainittu tutkimusosuus suoritettiin kolmelta eri kannalta: ultravioletti (UV) -valoa verrattiin valkoiseen valoon tuoreiden vammojen ja arprien toteamisessa; kliinisten näytteen taltiointitekniikoiden mahdollisuutta todeta Y-DNA:ta ja siittiöitä arvioitiin sekä vertaamalla kohdunkaulakanavan harjanäytettä perinteisiin seksuaalirikostutkimusnäytteisiin että taltioimalla yhdynnän jälkeisiä virtsanäytteitä.

Lapsen kertomus seksuaalisesta väkivallasta oli merkittävin näyttö rikosoikeudellisessa prosessissa ja lääkärintlausunnon johtopäätöksillä oli merkittävä rooli päätöksenteossa. Valtaosassa lääkärintlausunnon johtopäätökset eivät tukeneet eivätkä poissulkeneet lapsen seksuaalisen hyväksikäytön epäilyä. Fyysisen löydöksen puuttuminen jopa tuki näytön tulkintaa rikosoikeudellisen prosessin päätöksenteossa, jos se oli yhdenmukainen hyväksikäyttötavan ja lapsen kertomuksen kanssa.

Vapaaehtoisen yhdynnän jälkeen aikuisilla naisilla (N=88) todettiin tuoreita vammoja 14,8 % valkoisella valolla ja 23 % UV-valolla. UV-valolla osoitti limakalvonalaiset verenvuodot ja arvet paremmin kuin valkoisella valolla ulkosynnyttimien alueella. Lisäksi alatiesynnytykseen liittyvä välilihanleikkauksen tai emätinaukon repeämän arvet olivat parantuneet täydellisesti kolmasosalla (10/31) naisista.

Yhdistämällä sekä emättimen ja kohdunkaulakanavan pumpulitikku- ja harjanäytteet todettiin mitattava määrä Y-DNA:ta 81 % naisella (N=84) vapaaehtoisen yhdynnän jälkeen. Y-DNA:ta oli edelleen mitattavissa 75 % naisista 72–144 tunnin kuluttua yhdynnästä. Mitattava määrä Y-DNA:ta laski noin 3 % tunnissa. Naisista 6,8 % (3/44) ei todettu Y-DNA:ta 48 tunnin aikana vapaaehtoisesta yhdynnästä. Y-DNA:ta ei enää todettu 144 tunnin jälkeen yhdynnästä. Kohdunkaulakanavan harjanäyte osoittautui hyödylliseksi taltiointimenetelmäksi 60 tunnin jälkeen.

Oikein taltioitu virtsanäyte osoittautui erinomaiseksi Y-DNA lähteeksi 24 tunnin sisällä vapaaehtoisesta yhdynnästä. Virtsanäytteen hyötynä voidaan pitää erityksessä todettua korkeaa DNA määrää ja sen kajoamatonta keräystapaa.

Somaattisella tutkimuksella ei voida sulkea pois lapsen seksuaalista hyväksikäyttöepäilyä. Negatiivisilla seksuaalirikosnäytetuloksilla ei voida kumota seksuaalisen väkivallan mahdollisuutta vaikka epäilty

väkivalta olisi tapahtunut 72 tunnin sisällä. Tutkimusajankohta ja tarkasti dokumentoidut löydökset tulkitaan tapauksittain lääkärinlausunnossa ottaen huomioon lapsen kertomuksen ja vaihtoehtoiset syyt löydökselle. Seksuaaliväkivallan aiheuttamien löydösten erinomainen paranemistaipumus tulisi huomioida rikosoikeudellisessa tulkinnassa väärinymmärrysten välttämiseksi.

Seksuaalirikosnäytteiden taltioinnin rajoittaminen 72 tuntiin voi johtaa potentiaalisen näytön menettämiseen. Akuutin seksuaalirikosepäilyn yhteydessä on tärkeää suorittaa somaattinen tutkimus mahdollisimman pian kuuden vuorokauden ajan, koska pienet vammat saattavat edelleen olla todettavissa.

Korkealaatuista dokumentointia ja seksuaalirikosnäytteiden taltiointia useilla eri tekniikoilla suositellaan parhaan mahdollisen näytön saamiseksi. Lisäksi virtsanäytteen taltiointia suositellaan lisätutkimuksena lapsen seksuaalisen hyväksikäyttöepäilyn yhteydessä pienentämään seksuaalirikosnäytteiden keruun viivettä sekä parantamaan tutkittavan asennetta näytteiden taltiointiin.

1 Introduction

The prevalence of child sexual abuse has varied between 4-20% among girls and 1-9% among boys among 8th and 9th grade students according to two national Finnish surveys conducted in year 2013 (Fagerlund et al. 2014, National Institute for Health and Welfare 2014). The variation may result from different questionnaire designs, sexual abuse definitions and perpetrator age related definitions. It is well documented that the majority of child sexual abuse victims remain undetected. Of sexual assault allegations reported to the police only a small proportion are false allegations.

The medical assessment has multiple purposes besides the evidence collection and documentation. The need for prevention, prophylaxis, diagnostics, screening, treatment, and psychiatric care are to be evaluated. Furthermore, medical assessment includes the urgent decisions for mandatory reporting to police and to social services to ensure the child's safety and the evaluation of all the procedures according to law. The purpose of the actual clinical forensic examination is to document the physical findings, both minor and major signs of injuries, to evaluate the time relevance to the alleged crime and the possible use of force and to collect trace evidence for the criminal investigation. The chain of custody needs to be documented. Accurate and minute documentation of the examination is a key factor for further analysis and interpretation of the findings in the light of the history given. The child's disclosure of the suspected incident is recorded in detail. When the police request a medical statement, the documented history and medical findings are interpreted into the statement using a language, which is comprehensible to all collaborative quarters. Both failure to recognize and over-diagnosing child sexual abuse can be deleterious for the child, the family and the alleged perpetrator. Specific expertise of the field is needed to avoid further maltreatment or neglect.

2 Review of Literature

The United Nations Convention on the Rights of the Children (Treaty series 60/1991) obligates Finland among others to protect children from sexual abuse and all other kinds of abuse. The United Nations Security Council Resolution 1820 (2008) declared that sexual violence violates its victims' human rights. In Finland, during the last few years there have been many legislative advancements concerning child sexual abuse (CSA). Furthermore, the Finnish Police Academy recently published a textbook on the criminal investigation of physical and sexual abuse against children (Ellonen 2013).

When a suspicion of CSA arises, there needs to be a preliminary investigation. In the Finnish legal system the investigation of suspected sexual assault crimes is led by the police in close collaboration with the prosecutor. Collaboration in the early phase of preliminary investigations has been improved between police and prosecutor (Preliminary investigation Law 5:1). The new Criminal Investigation Act (2013) requires the criminal investigation authority to take appropriate measures which precede the initiation of the criminal investigation when a suspected crime of CSA is reported. The Criminal Code of Finland was renewed in 2004, 2006 and 2011 concerning child sexual abuse.

The police request assistance from the health care system if needed. Physicians are obligated to provide executive assistance if such is requested by the police (Police Law 9§2). If a suspicion arises without a referral from the police, the new paragraph in the Child Welfare Act (417/2007, 542/2011) obligates the health care personnel among others to report a CSA suspicion directly to the police and to the child welfare agencies (Child Welfare Act 25§, Criminal Code 20§ 1889/39). The role of child welfare is to ensure the child's safety. Furthermore the Finnish CSA law (Laki lapseen kohdistuneen seksuaalirikoksen selvittämisen järjestämisestä, 1009/2008, 1570/2009, 793/2013) guides the organizing of forensic interviews and medical examinations in healthcare and their collaboration with police and the judiciary.

The clinical forensic examination consists of a medical interview, observations and documentation of physical findings and collection of forensic evidence. The medical examination is ideally performed by two physicians for better accuracy in documenting injury (Royal College of Paediatrics and Child Health 2008, Working group set up by the Finnish Medical Society Duodecim and the Finnish Society for Child and Adolescent Psychiatry 2013). Police are authorized to request a medical statement based on physical findings. The writing of a medical statement is guided by the Finnish Medical Association (2013). The statement should be well balanced, objective, unbiased and be useful to the Court (Skellern and Donald 2012). The prosecutor decides, based on the evidence, whether to press or dismiss charges. The Court decides the verdict.

This review of literature will include some physical genital and forensic laboratory findings but does not discuss a wide range of normal anatomical variety of hymen, descriptions of hymen anatomy, trans-hymenal diameter, the possibility of sexually transmitted diseases in CSA, or general bodily injuries. Non-genital body injuries are reported to be more common than anogenital injuries in sexual assault victims in most studies (Cartwright 1986, Riggs et al. 2000, Sugar et al 2004, Saint-Martin et al. 2007, Ingeman-Hansen et al. 2008, Avegno et al. 2009, Jänisch et al. 2010), but also opposing detection rates are reported (Grossin et al. 2003). Non-genital findings are reported less often or as often in alleged adolescent victims of sexual assaults (Jones et al. 2003a, White and McLean 2006). A Finnish study of

adolescent and adult alleged sexual offenses reported that in most cases the offender had used physical violence causing minor injuries to the victim (Penttilä and Karhunen 1990).

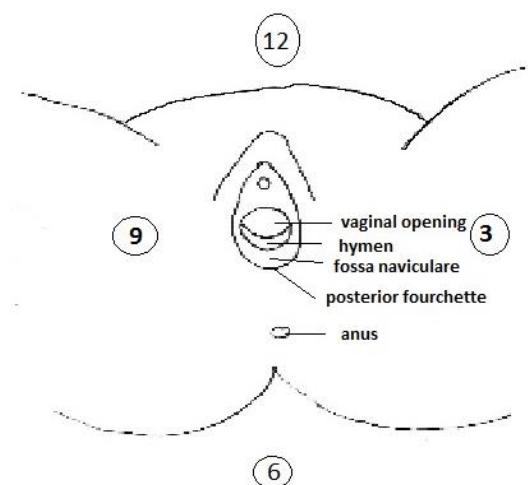
The literature included is mostly outlined and collected from European, American, Australian, and New Zealand studies because of cultural, socio-economic and legislative reasons. This thesis will mainly concentrate on females because most CSA victims are females.

2.1 Clinical examination techniques

The overall medical assessment of CSA should include the background history from the guardian without the presence of the child, the background history from the child without the presence of guardian, a physical examination and when necessary, laboratory tests (Adams et al. 2011). Different examination positions (supine labial traction, supine labial separation, prone knee chest position, left lateral position) and techniques (visual inspection, magnifying instrumentation, staining techniques, saline installation, or unfolding instrumentation) are recommended (Myhre et al. 2003, Kellogg 2005, Adams et al. 2007). Variance in the examining positions and techniques may influence the examination results and need to be discussed in medical reports. The physical findings are reported clock wise (Figure 1).

The examination position of the child is important. The co-operation and relaxation of the child has an influence on the examination findings (Berenson et al. 2002, Boyle et al. 2008 and Gavril et al. 2012). In prepubertal and pubertal girls, supine labial separation is a useful method identifying acute injury in the labia, posterior fourchette (PF) and the perineum, while the supine labial traction method is better within the vestibule, on the hymenal surface, or in the fossa navicularare (FN), and the knee chest position is the best method to identify lacerations on the hymen (Boyle et al. 2008). The prone knee-chest position and supine labial traction method are superior when evaluating prepubertal vaginal introitus (McCann et al. 1990a). Variable amounts of traction during the examination may result in different measurements. The gravity helps the hymen to unfold in the prone knee-chest position. The anal and perianal inspection is performed in all the examination positions including the left lateral position (Myhre et al. 2001). It is recommended to maintain anal observation for 30 seconds to detect possible anal dilation (Royal College of Paediatrics and Child Health 2008).

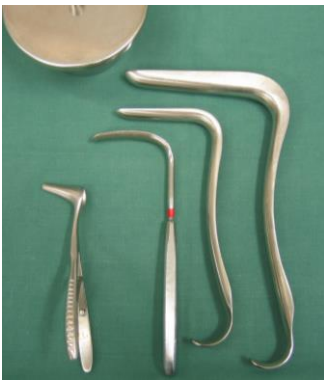Figure 1. Anatomical female anogenital structures and clock wise position.



In adolescents the hymen is estrogenized, often folded and redundant which may be confused as an injury (Starling and Jenny 1997). The use of *unfolding instrumentation*, Foley catheter (Ferrel 1995, Starling and Jenny 1997, Jones et al. 2003b), transparent round-bottomed plastic tubes (Edgardh et al. 1999), saline installation (Myhre et al. 2003), or a swab (De Jong 2011, Price 2013) are recommended to be used for documentation of hymenal findings. With the Foley catheter the inter-rater agreement indicated excellent reproducibility (Jones et al. 2003b).

In prepubertal children, usually there is no need to use *vaginal speculum* in CSA examination (Kellogg et al. 2005). Vaginal bleeding from an unidentified source is an indication to examine the vagina to exclude tumor of lower genital tract, foreign body or vaginal injury. In prepubertal children if vaginal examination is indicated this is recommended to perform under anesthesia (Merritt 1998). In adolescents the need for speculum examination is considered on a case by case basis, especially if vaginal and cervical swab collection of biological evidence is indicated (Figure 2) (De Jong 2011).

Figure 2. There are small size speculums for children but in child sexual abuse evaluations it is not needed in prepubertal children. The photo also shows a nasal speculum (on the left) and a virgo speculum (on the right).



Photograph by M. Joki-Erkkilä

The Royal College of Pediatrics and Child Health and The Faculty of Forensic and Legal Medicine (2012) recommended high quality *photo-documentation* during pediatric forensic examination, and if not obtained the reason for this must be documented. Photography is indicated in sexual assault examinations (Slaughter et al. 1997, Lenahan et al. 1998, Sugar et al. 2004, Jones et al. 2009, Maguire et al. 2009). Starling et al. (2013) highlighted the importance of photographic image quality in the peer review process. Photographic documentation is essential for the corroboration of findings and archiving must be ensured by strict protocols of evidence preservation (Laitinen et al. 2013) because it's part of the legal documentation used as evidence (Ernst 2009).

By *visual inspection* majority of suspected post-pubertal victims of any kind of sexual assault lack anogenital injuries (Tintinalli and Hoelzer 1985, Rambow et al. 1992, Gray-Eurom et al. 2002, Grossin et al. 2003, Sugar et al 2004, White et al. 2006, McLean et al. 2011). A recent prospective case-control study found genital injuries in 54% of a non-consensual sexual intercourse group and in 10% of consensual sexual intercourse adults by macroscopic inspection (Lincoln et al. 2013).

As early as 1981 Teixeira presented the use of *colposcope* in sexually assaulted females. Different magnifying techniques are used for genital injury detection. For sexual assault examinations, the colposcope is the most commonly used magnifying microscope with a good light source, and is usually attached to a camera for still or video documentation. It is effective in detecting genital injury (Slaughter et al. 1992, Lenahan et al. 1998, Riggs et al. 2000, Hilden et al. 2005, Jones et al. 2009, Laitinen et al. 2013). Teixeira (1981) observed that healing often appeared complete during inspection but colposcopy

revealed residual findings. In adults who reported penile penetration or sexual assault, colposcopy documented a significantly higher rate, 53-87% of genital findings (Slaughter et al 1992, Lenahan et al. 1998). The detection of significant injuries may not necessarily require the use of a colposcope (Adams et al. 1994), thus, major injuries are detected by inspection. A prospective study on colposcopic photographs of CSA found that diagnostic accuracy was lower for physical signs of sexual abuse with pubertal girls by photographic peer-reviewers (Muram et al. 1999).

Contrast media application has been used to identify microscopic injuries (Lauber and Souma 1982, McCauley et al. 1987, Jones et al 2003c). Toluidine blue is a nuclear staining dye which after application reveals tissue integrity. Toluidine blue increases detection rates of tears and abrasions, but decreases the detection of erythema or ecchymosis (Sommers et al. 2008, Zink et al. 2010). The positive uptake of toluidine blue is considered only as supportive evidence and not conclusive (Hochmeister et al. 1997, Laitinen et al. 2013).

In adult sexual assault cases and consensual sexual intercourse control studies comparing *different examination techniques* (inspection, colposcopy and toluidine blue) found that colposcopy was significantly better when compared to macroscopic inspection (Astrup et al 2013). In adult studies, the vast majority of injuries were detected in the external genitals by magnification and toluidine blue (Larkin et al. 2012, Anderson et al. 2006, Lauber et al. 1982, Slaughter et al. 1992, Slaughter et al 1997). Detection rates of acute external genital injury following consensual sexual intercourse from adult studies evaluating different examination methods are presented in Table 7 in the discussion section.

Ultraviolet (UV)-light is electromagnetic radiation with a shorter wavelength than visible light. UV-light is either absorbed or reflected by various biochemical compounds that are part of the healing process in skin tissue (Barsley et al. 1990, Hansell and Lunnon 1984). Under inspection with white light some bruises cannot be seen deep in the tissue, or under thick areas of skin. UV-light detects the release of blood cells and shows bruises in dark color. Reflective UV-light photography reveals injuries invisible to the naked eye (Kraus and Warlen 1985, Mackenzie and Jenny 2014).

UV-light was suggested as a part of medico-legal examinations to evaluate stains and skin trauma as long ago as 1995 (Lynnetryp and Hjalgrim 1995). It is mostly used in clinical forensic evaluation for detection of body fluids or blood stains (Christian et al. 2000, Nelson and Santucci 2002, Carter-Snell and Soltys 2005). Both acute injuries (Golden 1994, Lynnetryp and Hjalgrim 1995) and old injuries (Barsley et al. 1990) has been detected on skin under UV-light. Stene and colleagues (2010) found in over 15-year-old suspected assault victims with no visible gynecological injury a local fluorescence in 15% (11/73) of cases and vaginal foreign material in 3% of cases under UV-light.

Anoscopy is rarely reported to be used in medical examinations of alleged CSA children. Saint-Martin and colleagues (2007) reported use of anoscopy in 68% of those cases (all ages) where external anal trauma was observed and it revealed two lesions in rectal mucosa. Slaughter and colleagues (1997) reported use of anoscopy in eight cases whom all had evidence of rectal trauma. Anoscopy has been found to be a significantly better method for gathering evidence than colposcopy in male victims of anal abuse (Ernst et al. 2000).

2.2 Common misconceptions interpreting child sexual abuse

There are several misconceptions which come across in multidisciplinary collaboration as well as among physicians not familiar with the medical literature of pediatric gynecology or CSA (Wells 2006, Hornor 2009, Hornor 2010). The ten most common misconceptions are discussed below. These following issues need to be discussed with decision makers, police, lawyers and juries, so that they can base their decision

on facts and not fiction (White and McLean 2006). The risk of misinterpretation should not be neglected.

2.2.1 Integrity of hymen

“The hymen is present only in virgins” is a myth. In the majority of CSA victims the medical examination of hymen is normal (no residual findings) or non-specific (intermediate), thus there are no significant physical findings (De Jong and Rose 1991, Adams et al. 1994, Adams and Knudson 1996, Kellogg et al. 1998, Berenson et al. 2000, Heger et al. 2002a, Anderst et al. 2009, De Jong 2011).

The posterior part of the hymen is an anatomical structure which is always detected in newborns (Berenson 1993a) if no congenital anogenital malformation is detected. In the medical evaluation, it is important to be familiar with normal development, to distinguish normal congenital variety of anatomical structures from acute and healed signs of a prior injury (Pillai 2008). A follow-up examination within two weeks will differentiate a congenital finding from an acute one (Hornor 2009).

Missing part of the posterior hymen from 4-8 o'clock has been reported in CSA cases after vaginal penetration (Adams et al. 1994, Heger et al. 2000a), but the majority of girls with a disclosure of sexual abuse don't have any residual hymenal findings in non-acute gynecological examinations in CSA research reports (Heger et al. 2002a, Kellogg et al. 2004, Anderst et al. 2009). Thus, the hymen is most likely to be present after CSA, but in only some cases there are significant findings. Lack of hymenal injury may be due to several reasons: (1) the injury might have healed completely before the medical evaluation (Heppenstall-Heger et al. 2003, Finkel 1989, McCann et al. 2007a, Anderst et al. 2009), (2) the medical examination was not performed properly with different examination techniques (McCann et al. 1990a, Boyle et al. 2008), (3) the child could not relax during the examination (Berenson et al. 2002, Boyle et al. 2008, Gavril et al. 2012), (4) the tissue stretched and remained uninjured (Adams et al. 2007), (5) the type of sexual violence did not cause any injury due to the nature of the CSA, e.g. fondling, touching, oral-genital contact (Adams et al. 1994, Adams et al. 2007, Gavril et al. 2012), (6) or there was no such incidence. The medical examination of the hymen does not reveal CSA if there are no acute or residual objective findings of penetration. The type of suspected CSA, the possibility of healing of any prior injury, differential diagnostics and the child's disclosure are to be evaluated in the medical decision making process.

2.2.2 Hymenal findings after vaginal penetration

One of the myths is that *“the hymen is not anymore intact after vaginal penetration”*. After penetration has occurred the hymen often remains uninjured. Kellogg and colleagues (2004) found a definitive hymenal sign of penetration only in 5.6% (2/36) of pregnant or previously pregnant girls. In Anderst's and colleagues' study (2009) of disclosed non-consensual vaginal penetration, 18% of girls with prior consensual intercourse had definitive hymenal finding of penetration in non-acute examination. Edgardh and colleagues (1999) reported no deep clefts or scars in twenty girls with a history of consensual, non-abusive genital penetration in non-acute medical examinations.

Significant genital signs are more likely to be detected if the clinical forensic examination is conducted as soon as possible after the alleged sexual violence. Examination within seven days after alleged penile or digital vaginal penetration detected acute lacerations or hymenal bruising in 50% (46/92) girls (Watkeys et al. 2008). They reported 15% of prepubertal children having abnormal hymenal findings

(bruising of hymen/posterior vaginal wall, hymenal tear/marked swelling/adhesions) after alleged penetration in acute examination.

A history of penile-vaginal contact or penetration has not been found to correlate with the presence of abnormal genital findings (Adams et al. 1994), but contrast data is also presented (Adams et al. 1988, Muram 1989a, Kerns et al. 1992). Even so, Heppenstall-Heger and colleagues (2003) reported that the most significant genital injuries were associated with penile-vaginal penetration in preadolescent girls in a study including acute anogenital injuries due to different reasons. Heger and colleague's study (2002a) which included the child's history of genital penetration, 6% of girls had an abnormal examination. Anderst and colleagues (2009) reported definitive findings of penetrative trauma in 11% of girls with disclosure of penile penetrations and no history of consensual intercourse; all of these diagnostic hymenal findings were detected in over ten-year-old girls and none on the prepubertal girls even though they reported multiple episodes of penetration. In a retrospective chart review study almost a third of the children with disclosure of genital-genital penetration had diagnostic findings (according to Adams et al. 2007 guidelines); of which 78% were acute and 22% healed findings (Gavril et al. 2012). A Swedish study of non-acute examinations found deep clefts and/or vestibular scars in 59% of adolescents reporting penetrating abuse, and in 6% of those reporting non-penetrative abuse (Edgardh et al. 1999). Post-pubertal girls who disclosed vaginal penetration had in 70% cases normal findings when examined seven days after the incident (Watkeys et al. 2008).

Heppenstall-Heger and colleagues (2003) reported 63% of girls having PF/FN trauma after vaginal penetration or trauma, and only partial hymenal tears were associated with digital-vaginal penetration in preadolescent girls. In adults, the strongest predictors of injury were non-consent penetration and penetration of finger, which was four times more likely to result genital injury than penetration without finger involvement (Lincoln et al. 2013).

2.2.3 Anogenital healing

2.2.3.1 Hymenal healing

A common belief is that "*hymen cannot heal*". In three retrospective studies (McCann et al 2007a, McCann et al 2007b, Gavril et al. 2012), six longitudinal case studies (Berkowitz et al. 1987, Finkel 1989, Muram and Gale 1990, McCann and Voris 1992, Boos 1999, Boos et al. 2003) and one prospective study of 94 cases (Heppenstall-Heger et al. 2003) acute accidental or non-accidental genital trauma were evaluated by at least one follow-up examination to determine healing. Some other studies report acute anogenital healing but in those studies the nature of the healed wound is not clearly described (Berkowitz 2011).

In McCann's and colleague's study (2007a) in prepubertal girls 24% of the acute deep (more than 50% of the width of the hymen) hymenal lacerations healed into intermediate or superficial hymenal lacerations (notches). Of the acute hymenal transections with or without extensions 45% evolved with transections, and a further 3% healed completely or were undetected. Of acute hymenal transection with extensions 29% remained with an extension (McCann et al 2007a). On the other hand, contrary results reported hymenal transections with or without extensions to persist, even some after unsuccessful hymenal repair in surgery (Finkel 1989, Boos 1999, Heppenstall-Heger et al. 2003). Berkowitz and colleagues (1987) reported a 5-year-old girl with hymenal laceration extending all the way into the anus which later at menarche needed a hymenotomy because of imperforate hymen. Muram and Gale (1990) reported a straddle injury of vulva and vagina which healed with bridges of synechiae. Partial hymenal tears most often healed completely but some sustained a shallow notch at the site of prior injury (Boos

1999, Heppenstall-Heger et al. 2003, McCann et al. 2007a). Heppenstall-Heger and colleagues (2003) found that hymenal abrasion healed either completely or with angularity in hymen. White and McLean (2006) evaluated that 35% of hymenal findings in adolescent virgins were likely to heal in weeks or months to the non-specific category.

A basic knowledge of healing must be considered while evaluating the timing of alleged sexual assaults. Wound healing includes hemostasis (seconds to minutes), inflammation (3-5 days), proliferation (4-14 days) and remodeling (day 8 to 1 year) (Janis et al. 2010). The most superficial injuries are known to have their surface recovered with a new epithelium at a rate of 1mm per 24 hours (McCann 1998). Regeneration of damaged cells in deeper injuries is well on its way in 48-72 hours, while multiplication of new cells and differentiation of new epithelium takes from 5-7 days (McCann 1998). The complete healing of genital tissue requires 4-6 weeks. The maturation of scars may take from 60-180 days or even longer (McCann 1998).

2.2.3.2 Non-hymenal healing studies on anogenital findings

Posterior fourchette or perineum deep lacerations are reported to heal in 2-3 weeks in prepubertal girls (McCann et al. 2007b). Posterior fourchette or fossa naviculare surgery in preadolescent girls healed either with a scar or vascular changes (Heppenstall-Heger et al. 2003). In adult consensual sexual intercourse study observed that lacerations were visible for 89 hours by inspection, over 105 hours by colposcopy, and over 115 hours by use of toluidine blue (Astrup et al. 2012a).

The majority of abrasions, contusions, and submucosal hemorrhages healed within days in children (McCann et al 2007b). Heppenstall-Heger and colleagues (2003) found that abrasion may heal completely, or it healed with vascular changes in the posterior fourchette or in the fossa naviculare. Furthermore, tears healed in almost third of cases (11/35) completely and few with nonspecific labial fusions (Heppenstall-Heger et al. 2003). In the perihymenal and anal region the healing was complete.

Most anal findings (fissures, abrasions and lacerations) heal completely (Hobbs and Wynne 1989, Heppenstall-Heger et al. 2003). Perianal superficial lacerations have been reported to heal within 24 hours while deeper injuries took several days to heal (McCann and Voris 1993). Watkeys and colleagues (2008) reported in alleged anal abuse abnormal findings in 57% (13/23) of children if examined within seven days and in 18% if examined more than seven days after the incident. Anal scarring has been detected after extensive tissue damage, in this study following surgical repair (Heppenstall-Heger et al. 2003).

2.2.3.3 Time-frame since the last suspected sexual event to medical examination; findings and healing

One of the most significant predictors of abnormal genital findings is the time since the last CSA episode (Adams et al. 1994). With acute findings, the timing of the alleged incidence is more precise. When deciding the urgency of medical examination, one should take into account the child's wishes, welfare and their emotional state, but the examination should not be delayed for more than 12 hours (Watkeys et al. 2008). It should be included in the decision, that if the alleged CSA incident has occurred within 24 hours an immediate examination provides more evidence the sooner it is performed (Christian et al. 2000).

The majority of acute genital injuries heal completely leaving no signs of previous injury (Heppenstall-Heger et al. 2003, McCann et al 2007ab, Adams 2011, Gavril et al. 2012). Acute injuries, bruising, abrasions, lacerations with or without bleeding, are usually easier to recognize than healed

findings, but even with these findings, differential diagnostics are to be considered. For example, anogenital acute lacerations or extensive bruising can be the result of physical abuse, sexual abuse, or accidental trauma but acute lacerations in adolescents can also result from consensual intercourse (De Jong 2011). All acute findings should be re-evaluated to avoid misinterpretation.

In addition to injury documentation, other reasons for immediate medical examination in suspected CSA are forensic evidence collection; pregnancy evaluation or prophylaxis; identification, treatment or prophylaxis of sexually transmitted diseases; to reduce recantation due to threats or bribes; to document the history given; and to evaluate whether other victims exist; to evaluate if the child has abuse related symptoms; or parental or child anxiety (Christian 2011). According to Finnish guidelines for the evaluation of a CSA case (Working group set up by the Finnish Medical Society Duodecim and the Finnish Society for Child and Adolescent Psychiatry 2013) the urgency of a medical examination is evaluated by the possibility of obtaining biological evidence and of documenting injury or sexually transmitted infection. This guideline recommends immediate medical examination if acute injury is suspected; if bleeding is observed; if the child complains of anogenital pain; if any prophylaxis is needed; if the suspected incidence was within 72 hours, forensic evidence collection for prepubertal children is indicated (Adams et al. 2007, Christian et al. 2000), or for adolescents if the delay from the time of the suspected sexual violence is within a week for genital evidence collection (US Department of Justice 2004, Ingemann-Hansen et al. 2013). The documentation of possible injury or healing of injury is recommended for two weeks by a skilled examiner. A non-acute examination may be delayed if a qualified examiner is unavailable; or if the child's emotional or psychological state argues against the examination (Adams 2008, Christian 2011). Forensic evidence collection is discussed in chapter 2.2.10.

The likelihood of diagnosing acute or residual anatomical findings is associated with the time since the alleged CSA, the history of bleeding or pain at the time of the abuse and the examination techniques (Adams et al 1994, Adams et al. 2000, Christian et al 2000). However, even in cases with the child's disclosure of CSA with bleeding, pain or both, the possibility of a finding may depend on the time delay since the incident to the examination (Anderst et al. 2009, Adams 2011). A significantly higher incidence of abnormal findings was found in legally confirmed CSA girls when examined within 72 h of the last incidence (Adams et al. 1994).

Residual or healing injury may be difficult to detect if the initial examination is delayed (Adams et al. 1994, Cahill 2004). Any delay in a clinical forensic examination may cause loss of evidence. Cahill (2004) reported that 14% of suspected adolescent sexual assault victims underwent an acute examination and 86% a delayed examination. A study including both genders and children and adults reported a genital injury rate of 36% when the victim was examined within 72 hours of the alleged sexual assault, and 20% when examined after 72 hours (Grossin et al. 2003). The time elapsed from the assault to the examination has been reported to be longer for virgins than non-virgins (White and McLean 2006). A third (24/72) of the examinations was performed more than six months after the assault (Cahill 2004).

Adolescent girls more often have abnormal findings than prepubertal girls if examined within a week, respectively, 70% vs 15% (Watkeys et al. 2008). When the adolescent victims were examined within 24 hours, 43% of cases and within 72 hours 40% of cases had no physical findings (Cahill 2004). Some adolescents have healed hymenal findings in acute examinations with or without disclosure of consensual sexual intercourse (Gavril et al. 2012), or with an experience of painful tampons use (Adams et al. 2004).

Follow-up examinations by experienced examiners are recommended in acute cases and with non-specific findings (Finkel 2011, Gavril et al. 2012). The research of follow-up examinations has revealed a change in the interpretation of trauma likelihood in 18% of alleged CSA cases and improved the detection of sexually transmitted diseases in 7% of cases (Gavril et al. 2012). These rate changes were slightly lower in preadolescent children, respectively, 15% and 5% (Gavril et al. 2012).

2.2.4 Anogenital injury potential

“Sexually assaulted girls always have injuries” is another common misconception. Majority of CSA victims do not have significant physical findings (De Jong and Rose 1991, Adams et al. 1994, Adams and Knudson 1996, Kellogg et al. 1998, Berenson et al. 2000, Heger et al. 2002a, Anderst et al. 2009, De Jong 2011). Usually, if sexual assault results a trauma, minor genital injuries are detected. Major injuries which need treatment are reported only in 0.2-7% in study populations including both children and adults victims of suspected sexual violence (Hayman et al. 1972, Everett and Jimerson 1977, Tintinalli and Hoelzer 1985, Cartwright et al. 1986). A Danish study reported 0-2 fatal cases per year (Hilden et al. 2005).

Jones and Worthington (2008) analyzed under 21 years of age girls (N=44) who had anogenital injuries requiring surgical repair of any cause. They reported that the most common injury mechanism for anogenital trauma was straddle or implemental. The most severe injuries were caused by motor vehicle accidents. Sexual violence was identified as a cause of anogenital injury in 25% girls requiring surgery (Jones and Worthington 2008). In sexual violence the most common injury mechanism is blunt force trauma. The use of sharp objects is rarely reported.

The study population of verified CSA is extremely small. There are some studies of medical findings with more confirmed evidence of CSA and some with the perpetrator's confession with very small numbers of victims. Adams and colleagues (1994) studied legally confirmed CSA cases and reported no abnormal findings in six cases where the perpetrator confessed to digital-vaginal penetration, while abnormal findings were reported in 80% (4/5) victims where the perpetrator confessed to penile-vaginal penetration. In another study, Kerns and Ritter (1992) reported normal examination findings in 62% (8/13) patients with perpetrator confession of digital-vaginal penetration while normal findings were reported in 18% (4/22) girls with perpetrator confession of penile-vaginal penetration. Muram (1989a) reported 31 CSA cases in which the perpetrator confessed to sexual molestation, in 18 cases with vaginal penetration abnormal genital findings were found in 45% of cases. In Edgardh's and colleagues' study (1999), eight girls, who reported vaginal penetration, which was admitted by the perpetrator, had disclosure supporting genital findings.

There are some protective and risk factors of injury. The estrogen changes in pubertal development increase the elasticity and distensibility of the hymen and may protect from injury (Adams et al. 1994). In retrospective study of over 14 year-old female sexual assault victims, the risk of genital injury detected by inspection was more frequent in victims younger than 20 and older than 49 years, in those examined within 24 hours, and after anal assault (Sugar et al. 2004). On the other hand, abnormal findings were detected often at age 11-15 and in those children who were abused for more than three months (Hansen et al. 2010). First coitus was a risk factor for anogenital injuries (Jones et al. 2003c, Sugar et al. 2004). Female victims with body trauma are reported to have a higher rate of anogenital trauma (Sugar et al. 2004), and adolescents with experience of non-consensual sexual intercourse had a greater prevalence of non-genital injuries than adolescents with consensual sexual intercourse (Jones et al. 2003c). Eight percent of adolescent CSA victims reported physical abuse during sexual abuse (Cahill 2004). Furthermore, risk factors for vaginal lacerations reported in case reports were a disparity between genital organs, or penis ornamentation (Frioux et al. 2011). Etiology of severe lacerations was associated with failure of normal lubrication or dilation (Hoffman and Ganti 2001).

In Gavril's and colleagues' (2012) study 93 children disclosed only non-penetrative types of abuse, but 9% of them had positive findings (according to Adams et al. 2007 guidelines), including a case with

vaginal laceration requiring surgical operation and a case with healed hymenal transection. If a child describes only fondling or oral copulation, the examination is expected to be normal, thus many kinds of touching leave no signs (Adams et al 1994).

2.2.5 Consensual versus non-consensual anogenital injuries

Another misconception is that “*sexually assaulted girls always have worse injuries than those seen in consensual intercourse*”. The genital injury rate in adolescents is not clear. Studies evaluating consensual intercourse are mostly conducted in adults with different examination methods and injury definitions. This chapter concerning the overall prevalence of genital injuries includes case-control studies which clearly define the age of the study participant.

There are only two retrospective studies which compare acute genital injury rates after consensual and non-consensual sexual intercourse in adolescents (McCauley et al. 1986, Jones et al. 2003c). Jones’ and colleagues’ (2003c) study also included nonspecific findings (redness, swelling) and anal findings. McCauley’s and colleagues’ (1986) study population was very small. The acute genital injury rates in these adolescent case-control studies were 28-73% for consensual sexual intercourse and 28-85% for non-consensual sexual intercourse. In both non-consensual and consensual intercourse in adolescents, laceration was the most common finding (Jones et al. 2003c, McCauley et al. 1986). In acute examinations of suspected CSA cases also abrasions, ecchymosis and swelling were detected (Jones et al. 2003a). Adolescents with consensual sexual intercourse had injuries in hymen, fossa navicularis and posterior fourchette (Jones et al. 2003c), whereas those with non-consensual sexual intercourse the injuries were located in fossa navicularis, posterior fourchette, labia minora and hymen (Adams et al. 2001, Jones et al. 2003a, Jones et al. 2003c). Non-consensual sexual intercourse victims have a greater incidence of anogenital abrasions in labia minora, ecchymosis on the cervix or hymen, and edema (Jones et al. 2003c). White and McLean (2006) reported significantly more hymen injuries (lacerations, bruises, abrasions) in the virgin group (51%) compared to non-virgin group (12%). In adolescence, the child’s disclosure was the only issue distinguishing vaginal lacerations between consensual or non-consensual intercourse origins (Frioux et al. 2011).

In case-controlled studies composed of female adolescents and adults, the acute genital injury rate was 11-30% for consensual intercourse and 32-89% for non-consensual intercourse (Slaughter et al. 1997, Anderson et al. 2006). The Slaughter and colleagues study (1997) has been criticized because it included in the consensual sexual intercourse control group participants who recanted a first case of alleged non-consensual sexual intercourse (Sommers 2007). In their study another cause for prevalence bias was the inclusion of unspecific genital findings. Also in their report there is a bias in the examination time; the consensual sexual intercourse group was examined within 24 hours whereas the non-consensual sexual intercourse group was mostly examined within 72 hours. Almost a third was examined more than 72 hours after the alleged sexual assault, which makes the possibility of healing in the non-consensual group possible (Sommers 2007). Anderson’s and colleagues’ study (2006) was comprised of a small study population (N=46), heterogeneity of age and delays in the examination between the studied groups, and case background history, which makes the matching procedures inadequate (Sommers 2007).

Most of the prospective case-control studies which were only composed of adult participants found a consistent acute genital injury prevalence of 6-10% for consensual sexual intercourse (McLean et al. 2011, Lincoln et al. 2013) and 23-54% for non-consensual sexual intercourse by clinical macroscopic inspection (McLean et al. 2011, Lincoln et al. 2013, Astrup et al. 2013), whereas one study found an

overlapping result of 34% in the consensual sexual intercourse group for the non-consensual sexual intercourse group (Astrup et al. 2013). In one case-control study which evaluated the severity of genital findings within 72 hours of vaginal penetration, the examination was performed by using a colposcope and toluidine blue (Larkin et al. 2012). They found that when the minor findings which do not break the integrity of tissue were included in the injury prevalence, the figures were 58% for consensual sexual intercourse and 63% for non-consensual sexual intercourse, and in further analysis the prevalence of major injuries which disrupted the tissue integrity in the genitals was 10% for consensual sexual intercourse and 40% for non-consensual sexual intercourse (Larkin et al. 2012). Unfortunately their study may have been biased because they included redness and swelling in the category of major injuries and did not have follow-up visits to confirm these findings.

White and McLean (2006) reported a genital injury rate of 53% of virgin and 32% of non-virgin adolescents of alleged sexual assault victims. In their study it has to be noted that it took longer for the virgins to attend to the examination which may influence the injury detection rate.

There are some case reports of consensual intercourse resulting in serious intra-abdominal bleeding caused by posterior vaginal fornix rupture (Usifo et al. 2006), or without vaginal injury. A case series reported upper vaginal lacerations to be associated with consensual intercourse and one case with longitudinal vaginal laceration from non-consensual intercourse (Frioux et al. 2011).

In two recent adult studies, lacerations were the most common injury type following both consensual sexual intercourse and non-consensual sexual intercourse (Lincoln et al. 2013, Astrup et al. 2013). What is interesting in Astrup's and colleagues' (2013) adult case control study is that lacerations were detected more often by toluidine blue in consensual intercourse group than in non-consensual cases if lacerations were not found by inspection or by colposcopy. Significantly more abrasions are found in alleged sexual assault victims (Lincoln et al. 2013, Astrup et al. 2013). Concerning hematomas of any type there are inconsistent results in the literature. Overall, it is suggested that female non-consensual sexual intercourse victims have a greater number of anogenital injuries than those with consensual sexual intercourse (Jones et al. 2003c, Slaughter et al. 1997, Astrup et al. 2013) and a higher frequency of larger or more complex lesions (Astrup et al. 2013), but it is not a precondition for being a victim. Larkin and colleagues (2012) reported significantly more severe injuries in adult sexual assault victims than in consensual sexual intercourse controls. In adult non-consensual sexual intercourse cases and consensual sexual intercourse control studies, genital examination was associated with the presence of genital injury if examined within 24 hours of the incident, if the penetration involved fingers, or if the woman had symptoms prior to the incident, or signs or evidence of genital infection at the examination (Lincoln et al. 2013).

2.2.6 Anogenital findings and inexperienced examiner

One misapprehension is that "*all physicians can interpret anogenital findings*". Some of the genital findings, like erythema, gaping hymenal orifice, periurethral bands, labial adhesions, midline avascular area, failure of midline fusion, urethral prolapse, molluscum contagiosum, nevi of the hymen, Mongoloidian spots, or lichen sclerosus, may be *misinterpreted as signs of CSA* by inexperienced examiner (McCann et al 1990b, Kellogg et al. 1998, Hornor 2009). Myhre's study (2003) with non-abused children showed that the size of the hymenal orifice may be gaping so that you may even see the cervix of the uterus if the child is well relaxed during the examination. A gaping orifice cannot be used as an indicator of CSA (Berenson et al. 2002, Ingram et al. 2001). A failure of midline fusion may be mistaken as an acute laceration (Heger et al. 2002b). Mongoloidian spots (hyper-pigmented skin areas), or a hymenal nevi may be misinterpreted as

bruises caused by CSA. In these findings a follow-up examination may reveal the correct diagnosis. Lichen sclerosus can be mistaken for CSA (acute findings like hemorrhagic blisters, fissures, excoriations, bleeding or scarring-like findings) (Lagerstedt et al. 2013). In lichen sclerosus a typical symptom of vulvar itching may lead to diagnosis but also there can be symptoms which cause concern such as dysuria, soiling, or pain on defecation which are also common in CSA (DeLago et al. 2008). Overall, these aforementioned findings are not signs of CSA nor are they factors that protect from CSA. The medical interview should always include a tactfully posed question that helps to evaluate if there is any suspicion of abuse. When a genital finding raises a concern, pediatric gynecologic or dermatologic consultation is recommended (Hornor 2009).

2.2.6.1 Some physical findings detected in both abused and non-abused children

There are some physical findings which are common both in sexually abused and non-abused children and which may raise a concern of CSA. Presenting symptoms of anogenital lesions have been found to be significantly associated with diagnosis of CSA (Kellogg et al. 1998).

Redness in the genital area may be detected in non-abused girls (Myhre et al. 2003). It is common in the vulvar or in the perianal area in superficial bacterial infections and it may also result from inflammation, poor hygiene, acute trauma, dermatological disease, allergy, chemical reaction, or it can be seen after sexual abuse if the examination is performed within seven days of the incident (Royal College of Paediatrics and Child Health 2008, Hobbs and Wright 2014).

The significance of physical symptoms (*dysuria, bleeding and genital pain*) was reported in 60% of girls in suspected CSA (DeLago et al. 2008). Anogenital bleeding was reported at the time of assault in 34% of children (Adams et al. 1994). Bleeding was reported to be a significant predicting factor for abnormal genital findings (Adams et al. 1994) and this association was found in ≥ 10 -year-old children (Anderst et al. 2009). Contradictory results are also presented where probable or definitive examination findings were as likely in cases with or without bleeding (Kellogg et al. 1998). Anderst and colleagues (2009) also highlighted that only every fifth of the subjects reporting bleeding had definitive findings on examination.

Vaginal discharge is found in 2-3% of non-abused prepubertal girls (McCann et al. 1990b, Myhre et al. 2003). In suspected sexually abused children (<17 years) vaginal discharge is reported in 18% (Kellogg et al. 1998). A recent retrospective research reported vaginal discharge in 5% of prepubertal girls with suspicion of sexual abuse or physical abuse. Almost half of these had anaerobic bacteria, one case was positive for *Chlamydia trachomatis* but the rest did not reveal the cause for recurrent discharge (McGreal et al. 2013). Berenson's case-control study (2000) showed a significant association between vaginal discharge and the likelihood of sexual abuse diagnosis. Kellogg and colleagues retrospective case series (1998) did not find an association between vaginal discharge and probable or definitive examination findings of CSA. In cases with vaginal discharge or genital lesions, vulvar or vaginal specimens are indication for differential diagnosis of bacterial, viral infections or sexually transmitted diseases (Kellogg et al. 1998, Piippo et al. 2000).

2.2.6.2 Hymenal findings in non-abused and in suspected sexual abuse children

Most CSA studies are retrospective chart reviews or case reports and the study population is mainly based on alleged cases. It is rare to have objective evidence or eyewitnesses of sexual crimes.

In a systematic review (Berkoff et al. 2008), posterior hymenal findings, between 4 and 8 o'clock, transections, deep notches, and perforations were not seen in studies of prepubertal girls without a history of genital trauma from sexual abuse. "The posterior hymenal findings of *transections, deep notches, and perforations* are extremely infrequent findings among children without a history of genital trauma from sexual abuse or, other" clear explanations of the finding (Berkoff et al. 2008).

Horizontal measurements of vaginal outlets were not helpful in diagnosing or confirming previous reported penetration because there exists overlapping in the measurements between abused and non-abused children (Adams et al. 1994, Berenson et al. 2002).

Hymenal measurements are rarely useful as a diagnostic tool (Berenson et al. 2002). There is no consensus among experts whether a marked narrowing of the posterior hymen should be considered diagnostic of trauma because present data is insufficient to justify that conclusion (Adams 2011). Narrowing of the hymen is difficult to measure reliably (Berenson et al. 2002). At least one millimeter of posterior hymen tissue (at 6 o'clock) was present in 98% of prepubertal girls with no history of sexual abuse (Berensson et al. 1992), but less than 1 mm was detected in girls with a history of prior sexual abuse (Berensson et al. 2002). Furthermore, Heger and colleagues (2002b) found less than 1-2mm hymenal rims in 22% of pre- and peripubertal girls; the narrow hymenal rim was detected in those girls of BMI over 75th percentile. The hymenal measurements should not be used in isolation to confirm or rule out the diagnosis of sexual abuse, but rather consider the findings consistent with the disclosure of penetrating trauma (Berenson et al. 2002).

If there is no child's disclosure of CSA, the research data is insufficient for most of the experts to agree on the significance of a *deep notch of hymen* and it should be interpreted with caution (Adams 2011). Current guidelines suggest that a deep notch of the posterior hymen supports a suspicion of CSA if a clear disclosure of sexual abuse is given by the prepubertal child (Adams 2011), if there is no other reasonable explanation for the finding. Even if there is no disclosure, a suspicion of CSA may arise (Adams 2011), and the obligatory report to police and child protective services is indicated if a deep notch is detected (Child Welfare Law 25§). Further evaluation may give additional information to determine the significance of the medical finding.

The American Professional Society on the Abuse of Children defines *transection* as a tear or laceration through the entire width of the hymenal membrane extending to its attachment to the vaginal wall. In prepubertal girls transection between 4 and 8 o'clock of the posterior hymen suggests genital penetrating trauma and the differential diagnostics for the cause are to be considered (Adams 2011, Berkoff et al. 2008), such as accidental trauma, sexual abuse or medical procedure. The presence of a transection of the posterior hymen is not confirmatory of sexual abuse (Berkoff et al. 2008), unless there is a clear disclosure of CSA by the child. But even in the absence of a disclosure, the finding supports suspicion of CSA, unless there is a clear, timely, plausible, description of accidental trauma provided by the child or the caretaker (Adams 2011). Transections have not been found in the posterior hymen in non-abused prepubertal children (McCann et al. 1990, Berenson et al. 1992, Berenson 2000, Heger et al. 2002b, Myhre 2003).

2.2.6.3 Anal findings in non-abused and in suspected sexual abuse children

The significance of anal findings may be hard to interpret and the medical conclusions need to include differential diagnostics and the child's clear disclosure (Myhre et al. 2013).

Anal fissures are common findings in children with passing large hard stools, constipation, dermal or gastrointestinal diseases (Royal College of Paediatrics and Child Health 2008, Adams 2008, Hornor

2009), but also frequently reported in sexually abused children with a disclosure of anal penetration (Pierce 2004, Royal College of Paediatrics and Child Health 2008, Hobbs 2012, Myhre et al. 2013).

Anal lacerations are reported in 1% of legally confirmed CSA victims (Adams 1994). Myhre's and colleagues' study (2013) evaluating anal findings in children with or without probable anal penetration showed a positive association between anal penetration and anal soiling, anal fissures, anal laceration and total anal dilatation. Saint-Martin and colleagues (2007) reported recent anal lesions in 3% of less than 15-year-old children, but the type of sexual violence was not discussed. In Sugar and colleagues study (2004), after anal penetration 16% of victims had anal lacerations, but also in those cases where anal contact was not reported anal lacerations were detected in 5%.

Anal scars have been reported in 38%-84% of anally abused children (Bruni 2003, Pierce 2004) and in 1-4% of any kind of sexual abuse (Muram 1989b, Reinhart 1987). Bruni (2003) reported the highest frequency of scars in cases where there were perpetrators' confessions. Watkeys and colleagues (2008) found visible healed fissures or scars in 18% (9/50) of alleged CSA children when examination was performed more than seven days after the last episode of anal abuse. Hobbs and Wright's case-control study (2014), composed of alleged anal abuse and possible physical abuse or neglect victims, found anal scars in 5% of cases and none in the control group. The Royal College of Paediatrics and Child Health (2008) suggests that anal scars are associated with anal abuse because Myhre's study (2001) of non-abused children (n=305) did not detect any anal lacerations.

Total anal dilatation has been reported significantly more often in children with probable anal penetration (Myhre et al. 2013). *Dynamic reflex anal dilatation* has also been reported more often in CSA cases (Bruni 2003, Hobbs and Wright 2014). There is no consistency among experts of the significant measurement of dilatation or the relevance of it. Anal dilatation has also been detected in one study of non-abused children depending on the examining position; in the left lateral position in less than one per cent and more often (5%) in the knee-chest position (Myhre et al. 2001), but in another non-abuse study it was not detected in children of 18 months or younger (Berenson et al. 1993b).

Hilden and colleagues (2005) reported a higher risk of injuries (tears, ecchymosis, abrasions) after anal penetration when compared to only vaginal penetration in over 13-year-old females. Furthermore, Heppenstall-Heger and colleagues (2003) reported an anal trauma in nine girls disclosing only vaginal penetration.

2.2.7 Hymen and use of tampons

Another misconception is that *"the use of tampons will always damage the hymen"*. Adams and colleagues (2004) identified a deep notch in 3% (n=58) of adolescent girls who denied intercourse but described the painful past use of a tampon. Emans and colleagues (1994) found a deep cleft in the posterior part of the hymen which was not related to tampon use in 3% of adolescent girls who denied intercourse. White and McLean (2006) did not find in adolescent girls of non-consensual intercourse an association between genital injury in virgins and non-virgins with respect to tampon use, but they found more hymenal injuries in non-tampon users. Interpreting the relationship between tampon-use and hymenal findings must be made with caution (Goodyear-Smith et al. 1998).

2.2.8 Multiple assailants

It is assumed that *"CSA victims of multiple assailants have more genital injuries"* than in those cases of a single assailant. Genital injuries were reported in 43% (6/14) adolescent girls (12-19 years) who were acutely or

non-acutely medically examined after multiple assailant rapes (Edinburgh et al. 2014). Another study of sexual assault victims aged 6-89 years did not find an association between multiple assailants and physical injury (Avegno et al. 2009). Further studies on this subject are needed to confirm this conclusion.

2.2.9 Significance of the physician

A strong myth of even among professionals is that “*physicians are able to determine whether the child has been sexually abused or not*”. Heger’s and colleagues’ study (2002a) found normal or non-specific physical findings in 96% of 2384 children evaluated for possible CSA. There is no way for a physician to support the allegation of whether the child was abused or not, if there is no significant physical finding without other alternative explanations or the child’s disclosure. The child’s history along with differential diagnostic considerations may reveal the cause of a detected physical finding. Furthermore, injury alone is not sufficient to distinguish between consensual and non-consensual sexual intercourse (Helweg-Larsen 1985).

Gray-Eurom and colleagues (2002) concluded that a forensic examination is nothing more than a thorough physical and gynecological examination with accurate documentation of history and injuries, evidence collection and physical observations which can be performed by every emergency physician. At least, this does not include examinations of suspected child sexual abuse. Less than 40% of physicians, more often pediatricians than general practitioners, were familiar with normal genital anatomy of children from a photograph (Lentsch and Johnson 2000). A study of pattern recognition among residents and faculty at a major American teaching hospital showed a mean correct response rate of 58% for faculty from photographs of common pediatric gynecologic conditions (Muram and Simmons 2008). Urethral prolapse, labial adhesion, and uncomplicated vulvovaginitis were often incorrectly identified as signs of sexual abuse (Muram and Simmons 2008).

An online survey of Child Abuse Pediatricians, pediatricians, advanced practical nurses and sexual assault nurse examiners studied the identification and interpretation of medical cases with photographic documentation reported that those physical examiners who perform many CSA examinations on regular basis, examiners who regularly review cases with an expert and who keep up to date current research have higher knowledge and competence in interpreting medical and laboratory findings in CSA children (Adams et al. 2012). Less than 70% of the questions were answered correctly if they examined fewer than 5 children monthly for suspected CSA (Adams et al. 2012). (Adams et al. 2012). Also, in a follow-up study the likelihood of trauma decreased twice as likely if the initial examiner had performed only < 100 examinations when compared to those who had conducted >100 examinations (Gavril et al. 2012).

Inter-rater reliability in CSA among experts on photo-documentation was sufficiently high (Muram et al. 1999, Starling et al. 2013). Starling and colleagues (2013) reported on inter-rater reliability with the original diagnosis with a strong agreement of 67% for normal and abnormal physical findings, but 15% poor agreement for intermediate findings. They concluded that no agreement among experts exists for intermediate findings (Starling et al. 2013).

The Royal College of Paediatrics and Child Health and Faculty of Forensic and Legal Medicine (2012) recommend team work of two in clinical examinations of CSA and a single doctor to provide a pediatric forensic examination only if she/he has all the necessary skills. Also Finnish guidelines (2013) recommend team work among physicians performing clinical forensic examinations of CSA.

2.2.10 Biological evidence collection in suspected sexual abuse

2.2.10.1 Detection of biological evidence in children

A common expectation is that “*after penile-vaginal penetration, spermatozoa, semen or male DNA is always identified*”. Forensic evidence is found only in the minority of CSA victims (Christian et al. 2011). The possible related reasons are listed in Table 1 (Christian et al. 2011, Nesvold et al. 2011). The decision to proceed with the analysis of collected evidence in clinical forensic examination is made by the investigating police, and the question has been raised of suboptimal use of medical evidence (Nesvold et al. 2011). According to international conventions on victim’s rights, a victim is entitled to have their case fully documented even when the perpetrator is not identified (Nesvold et al. 2011). Forensic evidence if identified can be strong evidence of CSA in the criminal legal process (Gray-Eurom et al. 2002, McGregor et al. 2002).

Table 1. Possible reasons for missing forensic evidence in child sexual abuse victims (combined information from Christian et al. 2011, Nesvold et al. 2011, Hagemann 2014).

Delayed opportunity for evidence collection
Forensic evidence is not collected
Need to identify the perpetrator is assumed to be less relevant because usually he/she is familiar to the child
Minimal probability of identifying biological material leads to diminished utility of forensic analysis
Collected forensic evidence is not sent to be analyzed

In adolescents and adults, a vaginal speculum is used to improve allocative sample collection from the vaginal fornix and the cervical canal (De Jong 2011). Deep vaginal sample collection results may be related to physiological changes. Cervical mucus changes in the proliferative menstrual phase so that it correlates with receptivity to spermatozoa. Preovulatory mucus change in mucus hydration increases over a one day period occurring 3-4 days before the lutenizing hormone peak (Katz et al. 1997). This may influence the spermatozoa detection rates in the preovulatory phase. Prepubertal girls do not produce cervical mucus which may cause the vaginal environment to be more destructive of semen and sperm (Paradise 1990, Silverman and Silverman 1978, De Jong 2011).

In prepubertal children the collection techniques differ from those of adolescents and adults; a vaginal speculum is not used (De Jong 2011). The samples are mainly collected from the external genitalia, the inner thighs, the naval, abdominal or back area, between the buttocks; and blind vaginal swab-samples from visible discharge are collected avoiding contact with the sensitive hymen.

There are four retrospective (Christian et al. 2000, Thackeray et al. 2011, Girardet et al. 2011, Maquilla et al. 2011) and three prospective (Delfin et al. 2005, Young et al. 2006, Palusci et al. 2006) studies which evaluated forensic evidence exclusively in alleged CSA victims. One additional study also included adults but analyzed detection of spermatozoa separately in age categories (Dahlke et al. 1977). In prepubertal children most of the positive biological evidence was collected within 24 hours (Christian et al. 2000, Young et al. 2006, Palusci et al. 2006, Girardet et al. 2011), but positive biological evidence has also been detected beyond 24 hours up to 54-95 hours from body swabs (Thackeray et al. 2011, Girardet et al. 2011). In prepubertal children a significant proportion of evidence was found from non-body specimens, like clothing or linens (Christian et al. 2000, Young et al. 2006, Palusci et al. 2006, Girardet et al. 2011).

Unfortunately, some of these studies had a somewhat confusing way in reporting their results; all the collected specimens were not analyzed, detection rates were reported variably and the time-frame was not always reported accurately.

In prepubertal children of CSA biological evidence was found from the child's body in 3-11% of cases (Christian et al. 2000, Dahlke et al 1977, Palusci et al. 2006). The reported biological evidence prevalence was 42% in 13-16 year-old children (Young et al. 2006). Spermatozoa were detected in 19-21% in suspected CSA victims (Delfin et al. 2005, Maiquilla et al. 2011) and in 36% in 11-14 year-old adolescent victims (Dahlke et al 1977).

In suspected CSA victims Y-DNA has been detected in 41% of vagina samples (Maquilla et al. 2011) and in 20% of evidence collection kits (Girardet et al. 2011). The increased likelihood of finding forensic evidence or positive DNA was observed in over ten-year-old children (Palusci et al. 2006, Girardet et al. 2011). Among these the collection body site for the highest yield of positive DNA was found in vaginal specimens, followed by penile, anal, fingernail and combing samples (Girardet et al. 2011).

Genital findings have been found to be associated with a greater likelihood of identifying forensic evidence on a child (Palusci et al. 2006), but in other studies no such correlation between physical findings and laboratory evidence was found (Christian et al. 2000, Girardet et al 2011, Thackeray et al. 2011). Lack of injury or disclosed type of non-penetrative sexual abuse does not obviate the need to collect forensic evidence if a suspicion has risen (Christian et al. 2000). Children with normal or nonspecific anogenital findings may still have positive DNA evidence from a body swab (Palusci et al. 2006, Girardet et al. 2011).

Successful DNA typing has been reported in 22% of CSA victims (Maquilla et al. 2011) and in 65% of evidence collection kits (Thackeray et al. 2011). Factors found which are associated with successful DNA typing were the older age of the victim (Maquilla et al. 2011, Thackeray et al. 2011), the number of offenders identified by the child (Maquilla et al. 2011), and sperm detection by microscopy (Maquilla et al. 2011). Time delay, post-CSA activities, relationship to the perpetrator and history of ejaculation did not show a correlation to Y-DNA typing (Maquilla et al. 2011).

2.2.10.2 Detection of spermatozoa in adolescents and /or adults

Another fact opposing the aforementioned myth of always identifying biological evidence after penile-vaginal penetration is that evidence of sexual contact is not always identified following consensual intercourse. There is an overlap in the detection of spermatozoa in studies carried out following consensual sexual intercourse and in studies of suspected sexual assaults including adolescents and/or adults (Morrison 1972, Leppäluoto 1974, Davies and Wilson 1974, Silverman and Silverman 1978, Randall 1987, Penttilä and Karhunen 1990, McGregor et al. 2002, Cahill 2004, Astrup et al. 2012b). Different staining methods for sperm may account for some differences in these study results. There are many confusing factors in reporting the study results, e.g. study population or the age is not reported, or the terminology is not consistent. The majority of swab studies are conducted within 72 hours of consensual sexual intercourse or sexual assault.

In retrospective European studies of alleged adolescent and adult victims of sexual violence, spermatozoa was detected in 16-52 % of cases (Penttilä and Karhunen 1990, Ingemann Hansen et al. 2008, Jänisch et al. 2010, Stene et al. 2010, Hellerud et al. 2011, Hagemann et al. 2011, Hagemann 2014). In these studies the samples were collected from the body and/or garment. The sample collection time was within 96 hours. Another recent European study, which included a study population from pre-puberty to postmenopausal females and males, detected spermatozoa in 30% of cases, but the time of

sample collection was not accurately reported (Grossin et al. 2003). An older Danish study reported semen detection of 33-52% in two different time periods (Helweg-Larsen 1985).

A recent study of consensual intercourse detected spermatozoa in 88% (28/32) of women who reported ejaculation, but it also detected spermatozoa in 14% of women who did not report ejaculation (Astrup et al. 2012b). In older consensual sexual intercourse studies where the time relevance and study population are defined, the detection rate of spermatozoa varies from 25% to 80% within 48 hours of the intercourse (Silverman and Silverman 1978, Leppäluoto 1974, Randall. 1987).

The spermatozoa count reduced significantly with the time delay from intercourse to sample collection (Astrup et al. 2012b). In suspected sexual assault cases spermatozoa has been detected from vaginal samples up to seven days after the assault (Allard 1997). The longest reported post-coital time interval for spermatozoa to be present in the cervical smear is 12 days and 9 days in the vagina (Morrison 1972). Other consensual sexual intercourse studies report detection of spermatozoa for as long as 6 to 10 days since last intercourse (Leppäluoto 1974, Davies and Wilson 1974, Silverman & Silverman 1978, Randall 1987). Detection of spermatozoa was influenced by vaginal flora (Leppäluoto 1974). Oral contraception has lowered the spermatozoa detection rate in some studies (Silverman and Silverman 1978, Randall 1987) whereas in another study no such influence was detected (Astrup et al. 2012b).

The best sampling site for spermatozoa has been either the cervical canal (Morrison 1972), or vagina (Astrup et al. 2012b), or no such difference is found in the detection rates. Astrup and colleagues (2012b) discussed the vaginal fornix as a superior sampling site for there were no negative samples when the other two sampling sites (external genitals, cervical canal) were positive and the number of spermatozoa was higher in these slides. Jänisch and colleagues (2010) reported a sperm detection rate of 19% from anal samples up to 24h post-assault in adolescents and adults.

The absence of spermatozoa has been explained by the perpetrator's erectile inadequacy or impotence, premature ejaculation before penetration, ejaculatory incompetence, oligo- or azospermia, vasectomy, prolonged post-coital interval, digital penetration, use of condom, use of spermicides or oral contraceptives, victim's menstruation, by vaginal inflammation, or a loss vaginal fluids from the vagina before the evidence collection (Halbert and Jones 1978, Roa et al. 1995).

The presence of vaginal or cervical spermatozoa proves sexual contact, but not the nature of the sexual contact. The absence of spermatozoa does not support or exclude the possibility of sexual contact. Negative results of biological forensic samples present only the loss of evidence or the lack of trace evidence if a clear, reliable forensic history given supports the suspected sexual assault.

2.2.10.3 Detection of Y-DNA in adolescents and /or adults

In the criminal process, DNA analysis is performed in only a small proportion of samples from sexual violence victims (McGregor et al. 2002, Jewkes et al. 2009).

In a previous study of alleged sexual assault victims (aged 3-75) with negative cytology for spermatozoa, Y-DNA was detected in 29% of swabs collected from the body and in 44% (25/57) cases with vaginal swabs when vaginal penetration was the suspected assault type (Sibille et al. 2002).

In Scandinavian sexual assault studies on forensic evidence collected from adolescent and adult victims, DNA matches was found in 5-16% of cases (Ingemann-Hansen et al. 2008, Nesvold et al. 2011, Hagemann et al. 2011). Another Scandinavian study reported a positive male-DNA profile in 81% (104/128) samples when the sample was collected from female genitals or garments within 67 hours (Hellerud et al. 2011).

In genital samples collection, a more than 24 hour delay from the alleged sexual assault reduces the probability of positive male DNA detection (Sibille et al. 2002, Hellerud et al. 2011). After 48h, a short

tandem repeat (Y-STR) was reported evidenced in 30% of cases and the maximal time interval was 8 days (Sibille et al. 2002).

The reported sexual assault related pregnancy rate is 1-7.5% if post-coital contraception is not used (Rambow et al. 1992, Holmes et al. 1996, Cahill 2004, Sague-Castillo 2009). The possibility of sexual assault related pregnancy should be considered in every adolescent pregnancy. If a suspicion of sexual assault related pregnancy arises, the Finnish Crime Laboratory (2011) instructs to collect the specimen from induced abortion, miscarriage or fetal material. The collected specimen should be rinsed in sterile saline and stored in a sterile sample container, and send to DNA analysis by refrigerated transport. I found no studies concerning DNA analysis and pregnancy related sexual assault.

2.3 Medical decision making

Clinical decision making is a flow of decisions to decrease diagnostic uncertainty and to analyze the risks and costs (Jong-Myon 2014, McGee 2010; Kadane 2005). The Bayesian idea uses probability to describe uncertainty (Kadane 2005). Pre-test probability is the proportion of people in the population at risk who have the disease; thus the prevalence of the disease before the diagnostic test. In clinical medical decisions the first step is to analyze the patient's history, symptoms and signs, which will open a new pathway to differentiating the alternative causes of the disease by additional tests. These prospective approach decisions are led by pre-test probabilities; some getting support and some not. In clinical forensic decisions the approach is retrospective. If a physical finding is detected, one needs to analyze what is the cause of it, timing evaluations, differential diagnostics and how serious the injury is. If the physical findings are positive for the disease, this proportion of patients is the post-test probability. Uncertainty regarding the exact type of CSA by the child and healing will influence the evaluation of medical examination results.

In cases when there are more objective findings for medical decision making, the pre-test and post-test probabilities are more useful. In common situations, like in a flu epidemic, the medical decision making process for treatment has a pattern recognition which does not systematically exclude other diagnostic possibilities (McGee 2010). In these situations pre-test probabilities often lead us to correct assessments. For more complex situations a systematic approach for diagnostics is preferred for individual patients (McGee 2010). The highest quality of research consists of systematic reviews or meta-analyses of randomized controlled trials (McGee 2010). In some situations where randomized controlled trials are impossible and unethical to achieve, for example in suspected CSA, clinical guidelines give a more specified method which incorporates the principles of evidence based medicine and consensus recommendations by experts in the field (Adams 2008, Adams 2011, Adams et al 2007, Royal College of Paediatrics and Child Health 2008). In clinical decision making the principles of quantitative and analytical decisions are left to the physician in charge (McGee 2010, Rynnänen 2009).

In suspected child sexual abuse assessments, during the medical history the initial differential diagnostics consider a large variety of hypothetical possibilities, which may be supported or excluded by the physical examination findings, imaging and laboratory tests (Finkel and Alexander 2011, Adams 2008, Adams 2011, Adams et al. 2007, Royal College of Paediatrics and Child Health 2008). Through the interpretation of history, symptoms and signs, a medical decision leads to a diagnosis (conclusion). In CSA, simplified medical decision making is not possible by pretest probability because "this estimate applies only to the population at large", not to the population where a family member had expressed concern of maltreatment (Berkoff et al. 2008). No such "population data exists to estimate the probability once a parent expresses a suspicion of maltreatment" (Berkoff et al. 2008). Statistical

differences do not always correlate with clinical usefulness (Berenson et al. 2002). Physicians “must perform an objective physical examination unbiased by their pretest probability” (Berkoff et al. 2008).

In Berkoff and colleague’s (2008) systematic review, given broad 95% confidence intervals around the likelihood ratios for the presence of findings along with the low or unknown sensitivity of all physical examination findings evaluated; the physical examination cannot independently confirm or exclude non-acute sexual abuse as the cause of genital trauma in prepubertal girls. Although there have been attempts to form a genital injury severity scale currently it has no use in criminal justice because a significant number of sexual assault victims do not have detectable injuries (Kelly et al 2013). Injury alone does not predict sexual assault (Sommers et al 2012). Most sexual assault cases have only mild injuries; thus the tissue integrity stays intact (Larkin et al. 2012). Vaginal discharge, posterior hymenal transections, deep notches and perforations raise a suspicion of sexual abuse in prepubertal children, but the findings do not independently confirm the diagnosis (Berkoff et al 2008). Furthermore, also to be considered in decision making is the possibility that genital trauma often heals quickly and completely (Adams et al. 2011, Berkowitz CD 2011).

Disclosure of child sexual abuse during medical assessment was significantly associated with a positive physical examination finding (Palusci et al. 1999). If no alternative cause for the trauma exists, the presence of anogenital trauma may suggest that penetration or another type of sexual act has occurred but it does not itself imply the consent of the act (Jones et al. 2003c).

Palusci and colleagues (2006) used Bayesian analyses to calculate the predictive values of positive examination and forensic evidence; puberty and a history of ejaculation predicted for positive examination, and positive examination findings, age >10, puberty, and older alleged perpetrator for a finding of forensic evidence.

A systematic meta-analysis empirically tested the extent of the relationship between CSA and adolescent pregnancy; women who had a history of CSA were more than twice as likely to have experienced a pregnancy in adolescence as women who had not experienced abuse (Noll et al. 2009). In clinical decision making this indicates the importance of guidance of sexually abused children.

In medical research with such a delicate and complicated matter as CSA is, it is difficult to conduct studies with no confounding factors and the risk of bias is great. Most supporting medical decisions are based on the patient’s history and findings. It is, therefore, impossible to make medical decisions based solely on pretest probability concerning physical findings. The interpretation of physical findings should be made case by case based on the facts (Berkoff et al. 2008). Lack of injury does not imply that the alleged sexual violence was consent by the victim nor does it prove that a penetration did not occur (Jones et al. 2003c, Adams et al 1994, Kellogg et al. 2004). Injury is no prerequisite for a legal case (Wiley et al. 2003).

2.4 Criminal legal process

2.4.1 Physical findings and legal outcome

The role of expert statements as legal evidence is unclear (Ellonen 2010). CSA is often extremely difficult to prove in a legal sense due to a lack of (physical) evidence and challenges related to the arrangement of the child’s hearing and the varying quality of disclosures (Hirvelä 2007). Medical legal conclusions are reported to support the history of abusive genital penetration in 69% of cases (Edgarth et al. 1999).

The impact of medical examination findings and legal outcomes in adults has been reviewed earlier in a global review by DuMont and White (2007) and in a doctoral thesis by Hagemann (2014). These reviewed studies consisted of 10 North-American, seven European of which six from Scandinavia and one South-African study including both adolescents and adults (Tintinalli and Hoelzer 1985, Helweg-Larsen et al. 1985, Penttilä and Karhunen 1990, Rambow et al. 1992, Shei et al. 1995, Lindsay 1998, McGregor et al. 1999, Palusci et al. 1999, Du Mont and Parnis 2000, Gray-Eurom et al. 2002, McGregor et al. 2002, Wiley et al. 2003, Cahill 2004, Saint-Martin et al. 2007, Ingemann-Hansen et al. 2008, Jewkes et al. 2009, McLean et al. 2011, Hageman et al. 2011, Hagemann 2014). Furthermore, there are six studies evaluating medical-legal outcomes separately or exclusively on children (De Jong and Rose 1991, Palusci et al. 1999, Cahill 2004, Jewkes et al. 2009, Edelson and Joa 2010, Hansen et al. 2010) and two more CSA studies including wider age categories of 9-22 or 1-19 years (Edgardh et al. 1999, Sugue-Castillo 2009).

There are contradictory study results concerning medical evidence and *prosecution*. Medical evidence was a predictor of successful prosecutions both in children (Palusci et al. 1999, Sugue-Castillo 2009) and in adults (Rambow et al. 1992, Cross et al. 1994, Gray-Eurom et al. 2002, McGregor et al. 2002), but in some studies no such relation was found in legal outcomes of appearing in court including all ages (McGregor et al. 1999, Du Mont and Parnis 2000, Cahill 2004, Hansen et al. 2010).

McGregor and colleagues (1999, 2002) found moderate and severe physical injuries associated with laying charges and in these cases the tendency of laying charges increased according to the severity of the injury. Jewkes and colleagues (2009) found an association between detection of both non-genital and genital injury and trial commencing in children but not in adults. They reported a strong association between the accused being found guilty of a sexual offence and non-genital and/or genital injuries in adults, but not in children (Jewkes et al. 2009). A lack of documented injuries was reported in every fourth of children with a perpetrator conviction (Jewkes et al. 2009).

No relationship between abnormal anogenital findings or forensic medical evaluation and the legal outcomes of *conviction* was found in CSA cases (De Jong et al. 1991, Saint-Martin et al. 2007, Sugue-Castillo 2009, Hansen 2010). De Jong and Rose (1991) found relation between victim's age and legal outcome; there was a significantly lower conviction rate in the youngest victims despite of high rate of physical injury. In a French study, physical evidence of trauma was neither predictive nor essential for conviction (Saint-Martin et al. 2007). Predictive factors of the legal outcome were reported when convictions occurred more often when the perpetrator was an acquaintance of the victim, or when referral to the medical examination was from the justice department (Saint-Martin et al. 2007).

In Edgardh and colleagues' (1999) study, the legal outcome by injury categorization to normal/unspecific and possible/clear evidence was associated with the legal outcome of conviction in suspected adolescent sexual abuse cases. The same tendency was reported by Finnish researchers; the presence of severe injuries led more often to imprisonment, though it did not correlate with the length of sentence in adolescent and adult sexual assault victims (Penttilä and Karhunen 1990).

In Cahill's (2004) study, involving a single victim with pregnancy the assailant was convicted. No other studies reported an SA-related pregnancy legal outcome.

2.4.2 Spermatozoa, DNA and legal outcome

Helweg-Larsen (1985) did not find a correlation between juridical outcome and the presence of semen in reported adolescent and adult rape victims. In that study, even in eight cases with both evidence of violence and semen the charges were dropped due to a lack of evidence of non-consent. No association

was found between the detection of sperm and laying charges (Rambow et al. 1992, McGregor et al. 1999). The presence of spermatozoa did not correlate with imprisonment or the length of sentence in adolescent and adult sexual assault victims (Penttilä and Karhunen 1990), nor did it correlate with a guilty verdict (Tintinalli and Hoelzer 1985).

No association between DNA findings and legal outcomes has been reported (McGregor et al. 2002, Jewkes and colleagues 2009). Jewkes and colleagues (2009) reported only 10 adults and 12 children where DNA findings were available. DNA findings more often led to acquittal both in cases where the short tandem repeat (STR) profile did not match and where there was a profile match (Jewkes et al. 2009). Convictions were found in only three adult and two child cases with a DNA report (Jewkes et al. 2009).

2.4.3 Other factors and legal outcome

A significant predictor of legal outcomes has been the perpetrator's confession (Cross et al. 1994, Hansen et al. 2010). The victim being younger than 18 years (Gray-Eurom et al. 2002), or 7-10-years-old (Hansen et al. 2010), the duration of the sexual abuse, and the use of a weapon by the assailant (Gray-Eurom et al. 2002) have also been associated with successful prosecutions. On the contrary, McGregor and colleagues (1999) did not find an association between weapon use and laying charges and De Jong and Rose (1991) found a significantly lower conviction rate in the youngest victims.

Palusci and colleagues (1999) reported that a child's disclosure of CSA was not an independent predictive factor of a finding of guilt. Sugue-Castillo (2009) found a child's clear, credible disclosure as the most important determinant of the legal outcome. These results do not contradict each other; rather it is obvious that more evidence is needed for finding somebody guilty of a sexual crime against children than just a vague disclosure. Charged cases tend to have at least two types of evidence; often disclosure and corroborating evidence (Walsh et al. 2010).

In children, disclosures involving penetration were significantly associated with cases reaching court (Sugue-Castillo 2009). An association with legal outcomes was reported in those adult victims reporting oral penetration, and adults with anogenital trauma (Wiley et al. 2003). But on the other hand, Wiley and colleagues (2003) reported that neither anal, vaginal or multiple orifice penetration, nor general body trauma were related to legal outcomes.

Incorrect documentation of the case history can be devastating to a victim's credibility in the legal process (Gray-Eurom et al. 2002).

A higher association with legal outcomes was reported in those victims examined within 24h in adults and within 72 hours in children of their suspected assault (Wiley et al. 2003, Sugue-Castillo 2009). In Cahill's (2004) study this association was not found, but all their acutely examined CSA adolescent cases resulted in conviction, whereas, in delayed examinations the conviction rate fell to 70% (14/20).

In adults, amnesia was associated with negative legal outcomes (Wiley et al. 2003).

American researchers reported gender differences in CSA cases referred to the district attorney's office and legal outcomes; cases involving females had more positive legal outcomes than male victims (Edelson & Joa 2010).

No association was reported between prior sexual activity and legal outcomes in suspected adolescent victims' CSA cases (Cahill 2004). Multiple assailants were not associated with legal outcomes (Sugue-Castillo 2009). A trend towards more common prosecution of a suspect has been reported in cases evaluated in specialized centers of sexual assault care in victims over 15 years old (Stene et al. 2010).

False allegations are reported in adolescent and adult sexual assault studies in 0.8-4% of cases (Helweg-Larsen 1985, Penttilä and Karhunen 1990).

2.4.4 Elements for successful prosecution

Sugue-Castillo (2009) included qualitative data provided by professionals working with CSA, consisting of seven elements which were cited in court decisions: a clear, credible disclosure by the child, co-operation of all witnesses, the integrity and professionalism of legal personnel, the complete elements of the crime, the presence of definitive medical findings, teamwork among professionals, and timely hearings.

If the medical statement is not clearly understood or there are some questions regarding the physical findings, it may be helpful during court sessions to call the physician to interpret the meaning of both normal and abnormal medical findings as the doctor's testimony has been shown to significantly correlate with the legal outcome (Sugue-Castillo 2009). The question; "*does the injury fit the history?*" needs to be answered.

3 Aims of the Study

The purpose of the study is to increase the knowledge and evaluate the interpretation of genital findings, forensic evidence collection and timing issues in medical decision making in the criminal legal process of CSA. We studied adult volunteers because the evidentiary value of clinical forensic examination findings and forensic sampling techniques following consensual intercourse cannot be evaluated in small children. The evidentiary value of clinical forensic examinations, especially forensic sampling techniques for spermatozoa and Y-DNA from genital area are evaluated. The specific aims were to evaluate;

I the role of medical statement conclusions in the criminal legal process.

The study hypothesis was that medical statement conclusions do have value in the criminal legal process.

II the benefits of UV-light compared to white light in clinical examinations following consensual intercourse in adult volunteers.

The study hypothesis was that the UV-light improves detection of genital injury.

III forensic collection methods for a measurable quantity of Y-DNA, by comparing the traditional swab samples from the vaginal fornix and cervical canal to cervical canal brush samples following consensual intercourse in adult volunteers, and to evaluate the time frames.

The study hypothesis was that the brush samples may provide additional biological evidence from the cervical canal as the brush attaches most of the cervical canal mucus to the brush when compared to traditional genital swab samples.

IV Y-DNA and spermatozoa detection in post-coital urine specimens following consensual intercourse in adult volunteers, and to evaluate the time-frame for positive Y-DNA samples.

The study hypothesis was that the vaginal outflow will provide a measurable amount of Y-DNA from a correctly collected urine sample.

4 Materials and Methods

4.1 Data collection

4.1.1 For evaluation of medical statement conclusions in the criminal legal process (I)

1. Medical records collected by computer data search combinations of
 - a. ICD-10 diagnoses (Z04.4, T74.2, F65.4, Z61.4, Z61.5, Y05.0, Y05.10, Y05.11, Y05.2, Y05.8, Y05.9)
 - b. Medical examination units/out-patient clinics during the period 1.1.2001-31.12.2009
 - c. Age limit under 18-years at the time of medical examination

A random sample of 265/430 CSA cases collected from the Tampere University Hospital records was retrospectively reviewed. The medical records were collected from the hospital archives by the archivist. We included in the study only such medically examined CSA cases where a crime investigation case number was found in the medical records.

2. The cases were identified in the National Police Information System by the crime investigation number. Sergeants responsible for those CSA cases were identified from the Police Information System, which is a national crime register. Authorization to view the actual preliminary investigation files was provided separately from each sergeant in charge of those cases by written consent.

3. Data requests for the preliminary investigations by CSA crime case numbers were sent to the Prosecutor's office. From the Prosecutor's office we received archive numbers of those cases that proceeded to court handling as well as the documents of the Prosecutor's decision to dismiss charges.

4. We made a request for the District Court archive documents, which included the Prosecutor's application for a summons, the judicial decision and possible sentence.

5. If the district court's conviction was appealed against from the district court to the Court of Appeal, a written request was sent to the Court of Appeal for the lawful decisions in these cases.

4.1.1.1 Exclusion criteria (I)

Two hundred and sixty five randomly selected medical records were reviewed from the University Hospital medical records. Forty-five cases were excluded even though a forensic medical examination was performed; either there was no police referral or there was no written request for the medical statement in the medical files, that is, the police officer had only escorted the suspected victim to the clinical forensic examination with no further requests. A sample of 220 CSA cases with crime investigation numbers was found. Eight cases were excluded because a medical examination was not performed at all during the investigation. In seventeen cases a medical statement was not attached to the patient files. A total of 195 cases were included in the first phase of the study. In 23 cases a medical statement was not attached to the preliminary investigation material. Thirteen cases were still under criminal investigation. In five cases we did not receive documents from the prosecution service. In seven

cases we did not receive the District Court's decisions, in nine cases the files from the Court of Appeal, and in eight cases the crime was not CSA; these cases were excluded from the data.

4.1.1.2 Variables collected from medical records, preliminary investigation files, prosecutor's files, District Court and Court of Appeal (I)

Variables collected from the files: Gender and age of victim, number of victims and perpetrators, offender's relationship to victim, date of alleged CSA, continuity, alleged abuse type, date of report to law enforcement, prosecutor, and court verdict date, forensic medical examination dates, dates of acute or non-acute examination, forensic sample collection and findings, expert statement conclusions, additional examinations, other investigation procedures, status of criminal investigation, verdicts, offender's confession.

4.1.2 Participant recruitment for the studies II-IV

Female volunteers, comprising medical or laboratory students, hospital personnel or acquaintances, were invited to participate in a gynecological examination from May 2008-December 2009, following consensual intercourse, through personal invitation or collective invitation after a lecture. The inclusion criteria were; volunteers were aged 18 years or over, heterosexual intercourse took place, a willingness to complete a detailed questionnaire on their personal and sexual life, and signed consent to photography and forensic laboratory analysis.

For the UV-light study (II), 90 Caucasian women volunteered, but two declined the use of photography and were not included in the study. Finally, 88 participants were included in the study.

For the brush and swab study (III), 84 volunteers were included. Two volunteers were excluded because of pregnancy.

For the urine sample study (IV), ninety volunteers participated. Two volunteers were excluded because of misunderstandings in filling-in the study information form. 88 volunteers were included in the study.

4.1.2.1 Medical and sexual variables for studies II-IV

Each medical and sexual history was collected via a form filled-in by the volunteer. The time of the intercourse and the medical examination were recorded. Information about sexual activity in general, time of previous intercourse before the intercourse for the sample collection, the sample collection time, frequency of intercourse in the past two weeks prior to the sample collection or medical examination, post-coital activities following the intercourse (wiping, washing, showering, going to the sauna, urinating, defecating), contraception use, number of partners, last menstrual cycle and length, and the use of tampons, as well as the duration of the studied intercourse, use of different positions, lubricants, and possible discomfort in the genital or other parts of the body were all recorded. Additionally, information about parity, obstetrical procedures during delivery(-ies), past occurrences of genital-anal trauma, and medical gynecological operations were gathered. Former sexual victimization was recorded if answered in the questionnaire.

The women were instructed to record the time of their last intercourse before the studied urine collection, the urine sample collection time and post-coital voiding time. Time of the studied intercourse,

time of the collected urine sample, post-coital activities, and the numbering of post-coital voiding times were recorded on the study form.

4.2 Clinical forensic documentation and sampling techniques following consensual intercourse in adult volunteers (II-IV)

All 88 volunteers were examined in the supine position using the separation and traction technique of the external genitalia. The white light examination was performed first, next the UV-light documentation following by the vaginal and cervical samples. One gynecologist performed all the medical examinations and collected all the samples.


4.2.1 Examination and documentation techniques for UV-study (II)

For the colposcopy, an Olympus OCS 500 colposcope and white light source was used with a magnification at 3.7. In 86 volunteers a colposcope attached camera (4x Olympus high quality ED wide zoom lens, Olympus C-5060 wide zoom, 5.1 megapixels) was used for the photographic documentation. In two volunteers a Canon EOS 5D camera was used for documentation due to technical problems. A colposcopy under white light was performed, followed by a UV-light (368nm) examination. During the UV-light examination the lights in the examination room were turned off. The extra-genital area and hymen were photographed and the findings were filled-in separately on the study information form. The anogenital injuries detected were categorized into submucosal hemorrhages, petechiae, ecchymosis, bruises, abrasions, fissures, lacerations, and scars.

4.2.2 Vaginal and cervical sample collection (III)

Three samples were collected; cotton swabs (Invasive sterile Eurotubo® collection swab, Deltalab, Rubi, Spain) first from the vaginal fornix, following a cervical canal swab sample and a third sample from the cervical canal with a Papanicolaou (PAP) smear cervical brush (Gynobrush® Plus, Heinz Herenz, Hamburg, Germany) (Fig. 3). A cervical brush was spun in the cervical canal so that it would collect as much cervical mucus as possible. The swab was also spun in the cervical canal.

Figure 3. Swab and cervical brush (cm).



Photograph by M. Joki-Erkkilä

4.2.3 Urine sample collection (IV)

Following consensual intercourse, volunteers were advised to void into a collection cup so that the rim of the collection cup would lie tightly onto the perineum. The purpose was to collect as much as possible of the outflow of vaginal secretions into the collection cup when physiologically relaxing the pelvic floor muscles while urinating. The entire urine volume was collected. The first post-coital voiding urine sample was instructed to be collected without washing or without any other possible post-coital activities. Post-coital activities were allowed for the following collected urine samples.

The volunteer labelled the collection cup by (1) the study number given to her earlier during invitation and (2) numbered the post-coital voiding time and marked it on the side of the collection cup. Separate urine collection bottle(s) were given for preserving the urine in the refrigerator. The collection bottle was returned to the examiner as soon as possible but not later than 5 days.

4.3 Laboratory techniques (III-IV)

4.3.1 DNA extraction and quantification (III-IV)

The cervical mucus was first mechanically removed from the brush by rubbing the brush against the wall of the microcentrifuge tube which contained 400 μ l of Phosphate-Buffered Saline (PBS). DNA from the swab and brush samples was extracted using QIAamp DNA Mini Kit[®] (Qiagen, Germany) with Buccal Swab Spin Protocol.

The amount of urine and the pH of the urine were measured. Urine samples were centrifuged for 10 minutes at 3,000 rpm and the supernatant was decanted. After centrifugation the supernatant (urine) was poured out and the cellular deposit at the base of the centrifuge tube was collected. From 200 μ l of cell pellet, DNA was extracted using QIAamp DNA Mini Kit[®] (Qiagen, Germany). Centrifugation steps were carried out at room temperature according to the protocol.

For all the samples, Quantifiler Y Human Male DNA Quantification Kit[®] (Applied Biosystems, USA) was used to quantify the total amount of amplifiable male DNA. Analysis was done with AbiPrism[®] 7000 HT Sequence Detection System (Applied Biosystems, USA) according to instructions provided.

A sample was considered positive if a measurable amount of DNA was detected. The cut-off limit for possible DNA identification of the male was considered to be 0.01ng/ μ l (oral communication with Finnish Crime Laboratory) and according to the recommended cut-off limit of 0.023ng/ μ l for Quantifiler Y.

4.3.2 Microscopic analysis (III-IV)

From the vaginal and cervical swab and brush samples, microscopic examinations were altogether performed in 62 (73.8%) volunteers. Immediate microscopy of vaginal and cervical sample was performed on 39 out of 84 (46.4%) volunteers in a forensic laboratory, and in a subset of 111(54.1%) urine samples from 47 volunteers in a forensic laboratory.

The immediate microscopy consisted of the following parameters: density, motility and sperm density. The density was categorized as follows; no sperm, a few sperm (1-10/slide), a moderate amount (10-50/slide), and many (>50/slide). The examination was performed according to the laboratory

manual WHO 1999 (WHO Laboratory manual for the examination of human semen and sperm-cervical mucus interaction 1999). Each sample was suspended on a slide by mixing the sample with a small amount of a culture medium (5 µl). The covered preparation was examined under the microscope. All samples were examined by phase-contrast microscope (magnification of 10x20).

In 23 (27.4%) volunteers samples from swabs and from brushes were collected onto slides which were dried and dyed with semen stain identification (Kernechrot Picoindigocarmine Stain®). Spermatozoa were verified at 1000x magnification microscopy.

4.3.3 Contamination issues (III-IV)

The possibility of contamination has to be considered. All the sample collection, the urine sample processing, extraction and amplification steps were performed by the same female experimenters to avoid secondary Y-DNA contamination. Disposable powder free gloves were used and changed frequently to minimize the contamination risk. During the vaginal and cervical sample collection, the paper cover on the examination table was changed and the table with surrounding area was wiped with disposable disinfecting cloths between volunteers.

4.3.4 Statistics

SPSS was used for data analysis; in studies I-III SPSS 18 (SPSS Inc. released 2009 and PASW Statistics for Windows, Version 18.0, Chicago: SPSS Inc.), and in study IV, SPSS 21 (IBM Corp. Released 2012. IBM SPSS Statistics for Windows, Version 21.0. Armonk, NY: IBM Corp.). Tests applied for data were Pearson's χ^2 -test and Fisher's exact test, and statistical significance was assumed if $p < 0.05$.

The results were summarized by descriptive statistics; medians with a range or frequencies (n) and percentages (%). Categorical associations were assessed using Fisher's exact test.

In studies II-IV, differences in the ability to detect scars with UV-light and white light after combining responses of "no" and "unspecified findings"; between different collection methods and between detection of Y-DNA and spermatozoa were analyzed using the McNemar test.

In study III the positivity of different collection methods was analyzed by binary logistic regression using the time from intercourse to medical examination, parity, contraception and post-coital activities as predictor variables. The results are shown as odds ratios (OR) with 95% confidence intervals (CI).

In study IV the Chi-square test was used to compare our microscopy results on the detected spermatozoa rate in first void urine to results from the study by Smith et al (2014).

4.3.5 Ethical considerations

All the studies were approved by the Pirkanmaa District Hospital's Ethics Committee. Written consent was required for attendance in the clinical forensic studies in volunteers, for photography and the use of photographs for teaching, for publication purposes, and for forensic laboratory analysis. No data from patients' medical records were collected in studies II-IV. Written consent was not required in study I because the children or the parents were not contacted personally.

5 Results

5.1 The criminal legal process and medical statement conclusions (I)

5.1.1 Study population and alleged victimization (I)

The research data consists of the analysis of 130 under 18-year-old children with suspicion of being sexually abused (Table 2).

Table 2. Characteristics of medically examined, police reported suspected CSA victims, N=130.

Variable	N	(%)
<i>Age of the victim, years</i>		
0-6	81	(62)
7-9	20	(15)
10-17	29	(22)
<i>Gender of the victim</i>		
Female	104	(80)
Male	26	(20)
<i>Single or continuous CSA</i>		
Single event	50	(39)
Multiple events	80	(61)
<i>Number of suspected perpetrators</i>		
One	121	(93)
Several	9	(7)
<i>Number of victims per suspected crime</i>		
One	87	(67)
Several	43	(33)
<i>Perpetrator</i>		
Biological parent	60	(47)
Stepfather	4	(3)
Other relative	12	(9)
Other	44	(33)
Unknown	10	(8)

The median age was 5.3 years (range 11 months–17.3 years) at the time of the offence and 6.5 years at the time of the crime being reported to law enforcement. The majority of victims (78%) were under 10-years-old. In most cases there was a suspicion of repetitive sexual abuse, which continued from several months to years. In every third allegation there were multiple victims per crime; two victims in 18%, three victims in 10% and four to five victims in 5.4% per crime. In nine cases there were two to three offenders per child.

5.1.2 Criminal investigations and medical statement conclusions (I)

The medical statement conclusion was “not supporting nor excluding” in 99 (76.2%) of suspected CSA cases. Medical statement conclusions supported the alleged sexual abuse in 21 (16.2%) of cases, and ten (7.7%) medical statements were considered as not-supporting or excluding conclusions (Table 3).

In three supportive medical conclusion cases medical examinations with normal hymen finding according to Adams’ guidelines (2007) were stated incorrectly in the conclusions as being a sign of penetration. These cases had photographic documentation available.

Table 3. The progress of medical statement conclusions in the criminal legal process.

Medical Statement's conclusion	Criminal legal process, (n)				
	Preliminary investigation	Case closed	Charges filed	Final Conviction	Not guilty
Not supported nor excluded	99	21	41	28	13
Supportive	21	2	12	11	1
Non-supportive	10	3	1	1	0
Total	130	26	54	40	14

5.1.2.1 Medical findings (I)

Of those 99 cases with medical statement conclusions “not supporting nor excluding”, 93 (94%) had normal or no residual physical findings, three cases had acute genital findings, and three cases had residual physical findings.

Acute (<72 h) examinations were performed in 28/117 cases. Ten acutely examined children had supportive medical statement conclusions; seven of them had acute anogenital findings, and a further two cases had healing findings when examined 7 and 8 days after suspected CSA.

5.1.2.2 Biological traces of evidence (I)

In the group of medical statement conclusions “not supporting nor excluding”, biological traces of forensic evidence were collected in 12 cases and two cases were positive for semen; one collected from the body and the other one from the underwear.

In the group of medical statement conclusions supporting the alleged CSA, biological traces of forensic evidence were collected in 10 cases and two of them were positive for semen. DNA typing in the one of them did not match the DNA of the suspected perpetrator.

In the non-supporting medical statement group, biological traces of forensic evidence were collected in one acute case and semen was found by the crime laboratory.

Altogether 15.2% of cases were semen or spermatozoa positive when clinical forensic samples were collected from the child’s body or underwear.

5.1.2.3 Type of suspected abuse (I)

Of the supporting medical conclusions, the type of suspected abuse was penetration in 46% cases. When the most severe alleged type of sexual abuse was fondling, 8.2% had supportive medical statement conclusions. When the sexual act happened without physical contact with the victim’s genital area, none of the medical statement conclusions supported nor excluded the abuse. None in the non-supporting medical statement conclusion group disclosed any kind of sexual abuse.

5.1.2.4 Cases closed during criminal investigation (I)

In every fifth of the suspected CSA cases the criminal investigation was closed by the police due to either not having enough evidence of the alleged crime, the suspected perpetrator was unknown, the suspected perpetrator had died or was a minor.

5.1.3 Prosecution and medical statement conclusions (I)

Of the medically examined suspected CSA cases 100 (76.9%) proceeded to prosecution.

Prosecutors filed charges in 54 (41.5%) of cases; where medical statements were mentioned as a piece of evidence in 18 (33.3%) of cases. Of the indicated cases 75.9% had the “not supporting nor excluding” medical conclusions, 22.2% “supportive” conclusions and 1.9% “non-supportive” medical statement conclusions.

Three cases were charged without the child’s disclosure of sexual abuse. One of the charged cases without a disclosure was a 14-year old disabled girl with a hymen transection at 6 o’clock and an eyewitness. The other two cases did not have any physical findings.

5.1.3.1 Decisions to dismiss charges and medical statements (I)

Charges were dismissed in 46 (35.4%) of cases with not enough evidence supporting the crime. Five cases had “not supporting” and five cases had supporting medical statement conclusions and 36 cases had “not supporting nor excluding” conclusions.

Altogether, medical statements were mentioned as one of the reasons to dismiss charges in 18 cases.

5.1.4 Court decisions and medical statements (I)

In the final legal endpoint the conviction rate from the whole study population was 30.8% (40/130), and in charged cases 74.0% (40/54).

When medical statements were analyzed according to final convictions as the ending point; of the “supportive” conclusions the conviction rate was 91.7% of charged cases and in 52.4% of the whole study population, whereas the figures of “not supporting nor excluding” conclusions were 68.3% and 28.3%, and ten percent of “non-supportive” medical conclusions (Table 3).

Medical statement conclusions ($p = 0.037$) and the clear child’s disclosure of CSA ($p < 0.001$) had a significant role in decision making on convictions.

Overall, medical statements were mentioned as a piece of evidence in 15 (36%) verdicts. The medical statement conclusions, which neither supported nor excluded the allegation, were considered as evidence that supported the child’s disclosure when the type of sexual abuse was considered. In all but one sentenced case there was a clear disclosure from the child. The child’s disclosure was mentioned as a piece of evidence in 30/40 (75%) verdicts.

5.1.4.1 Acquittals (I)

Of the charged cases, twelve (22.2%) of cases were found not guilty in the District Court and fourteen cases in the Court of Appeal.

The Court’s “not guilty”-decisions were mainly based on the child’s disclosure not being clear enough to emphasize what actually had happened or the interview was criticized because of using too many leading questions, or the principle of contradiction was not fulfilled.

5.1.4.2 Perpetrator’s confession of CSA (I)

During the legal process 10/130 (7.7%) of convicted perpetrators confessed to the alleged crime.

5.2 Evidence collection in volunteers (II-IV)

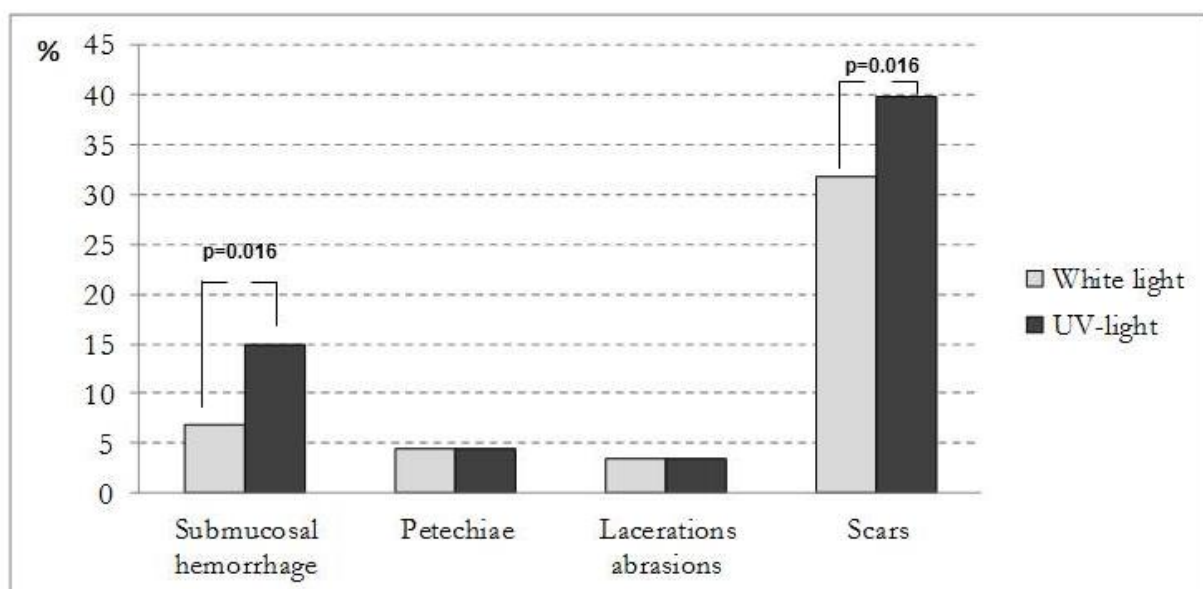
For study III 84 and for studies II and IV 88 Caucasian volunteers were included. The median age of the volunteers was 26.5 years (range 20-52). All reported penile-vaginal penetration.

5.2.1 Detection of acute anogenital injury under white and UV-light (II)

The acute genital injury rate was 14.8% (13/88) under white light colposcopy and 23.0% (20/87) using UV light. One volunteer could not be evaluated by UV light, due to vulval erythrasma, which caused excessive coral red fluorescence.

Submucosal hemorrhages were documented under white light in 6.8% (6/88) of cases, and 14.9% (13/87) under UV-light (Fig. 4). Seven out of thirteen (53.8%) submucosal hemorrhages would have been missed without the UV-light ($p = 0.016$). Petechiae were detected in four (4.5%) volunteers using both white and UV-light. Four participants had non-specific mucosal redness. UV-light showed no advantages over white light in detecting the two abrasions or the small superficial acute laceration (4 mm). Condyloma acuminatum was not highlighted or illuminated under UV-light. No bruises, ecchymosis or deep lacerations in the genital area, nor acute or residual injuries in the anal area were documented.

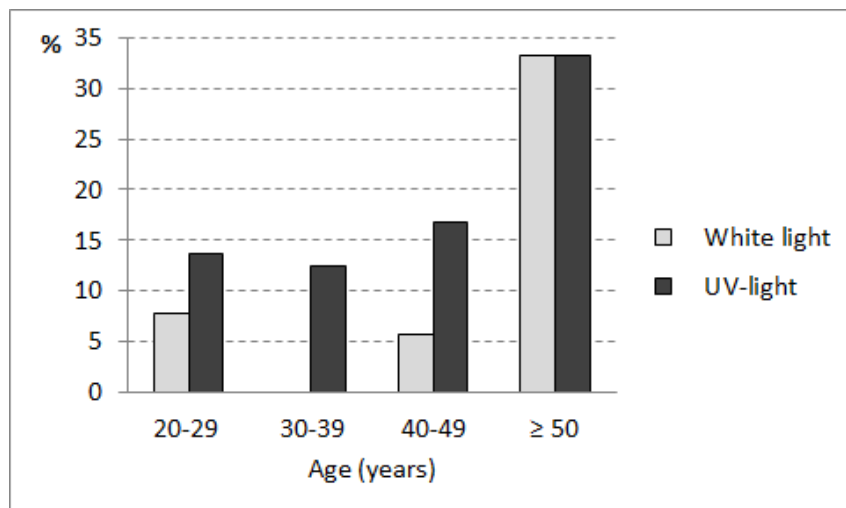
Figure 4. Genital acute injuries and scars detected by white and UV-light following consensual intercourse in adult volunteers.



5.2.1.1 Age and acute genital findings (II)

No submucosal hemorrhages were identified in the 30–39 age category following consensual intercourse under white light. Submucosal hemorrhages were more prevalent in over 49 year old women after consensual intercourse under white light (Fig. 5). Due to a small number of cases in older age groups these differences were no association.

Figure 5. Percentages of genital submucosal hemorrhages detected under white and UV-light following consensual intercourse according to age.



5.2.2 Genital scars under white and UV-light (II)

Scars in the genital area were visible in 28 (31.8%) under white light and 35 (39.8%) volunteers under UV-light ($p = 0.016$) (Fig 4). Of the scars, 7 (20%) would have been missed without the use of UV-light. Six of these seven scars had an even, regular mucosal surface and no residual anatomical changes detected under white light.

Genital scars differed in color. Under white light in mucosal tissue inside the Hart's line, scars were seen white, redder than mucosa with vascular changes or the same color as the mucosa. Outside the Hart's line, the skin tissue scars color varied from white, darker than, or the same color as the skin, to a combination of these in the genital area. Under UV-light, scars were seen as either white or darker than the mucosal or skin tissue, regardless of the Hart's line location. Of all scars, 13 (36%) were white in color, 12 (33.3%) the same color as the mucosa, and 5 (13.9%) observed with vascular changes.

5.2.3 Forensic evidence specimens collected from vagina, cervical canal and urine (III-IV)

In study III, a measurable amount of Y-DNA was detected from 56 (66.6%) vaginal fornix swabs, from 52 (61.9%) cervical canal swabs and from 50 (59.5%) cervical brush samples (Table 4). By combining all vaginal and cervical collecting techniques, 81% of the volunteers were Y-DNA positive.

Y-DNA was detected only in cervical swabs of 3/84 (3.6%) volunteers, in vaginal swabs of 9/84 (10.4%) volunteers and in brush samples of 6/84 (7.1%) volunteers. From all the collected samples 16/84 (19%) volunteers were Y-DNA negative in the vaginal and cervical swab and the cervical brush collection methods.

Table 4. Forensic collection methods of biological trace Y-chromosomal material by vaginal and cervical canal swabs and cervical canal brushes following consensual intercourse.

Collection method	Vaginal fornix swab		Cervical canal swab		Total n (%)	
	+	-	+	-		
Cervical canal brush	+	41	9	43	7	50 (59.5)
	-	15	19	9	25	34(40.5)
Total, n (%)		56(66.6)	28(33.3)	52(61.9)	32(38.1)	84

The study IV consisted of 205 urine specimens. The median urine volume was 175ml (range 2-550ml, Q1=90ml, Q3=290ml). The mean urine pH was 6.3 (range 4.8-8.2). No statistically significant relation was found between urine volume, urine pH and measurements of male DNA. Y-DNA was measurable in 173/205 (84.4%) urine specimens, median 0.68 ng/μl (range 0.0009-121.8). Of the 86 first post-coital void urine specimens available, Y-DNA was detected in 83 (96.5%) specimens (Table 5). Y-DNA was still measurable in 70 (58.8%) urine specimens of 119 volunteers with post-coital activities.

Table 5. Measurable male DNA in urine specimens collected following consensual intercourse according to the number of post-coital voiding samples.

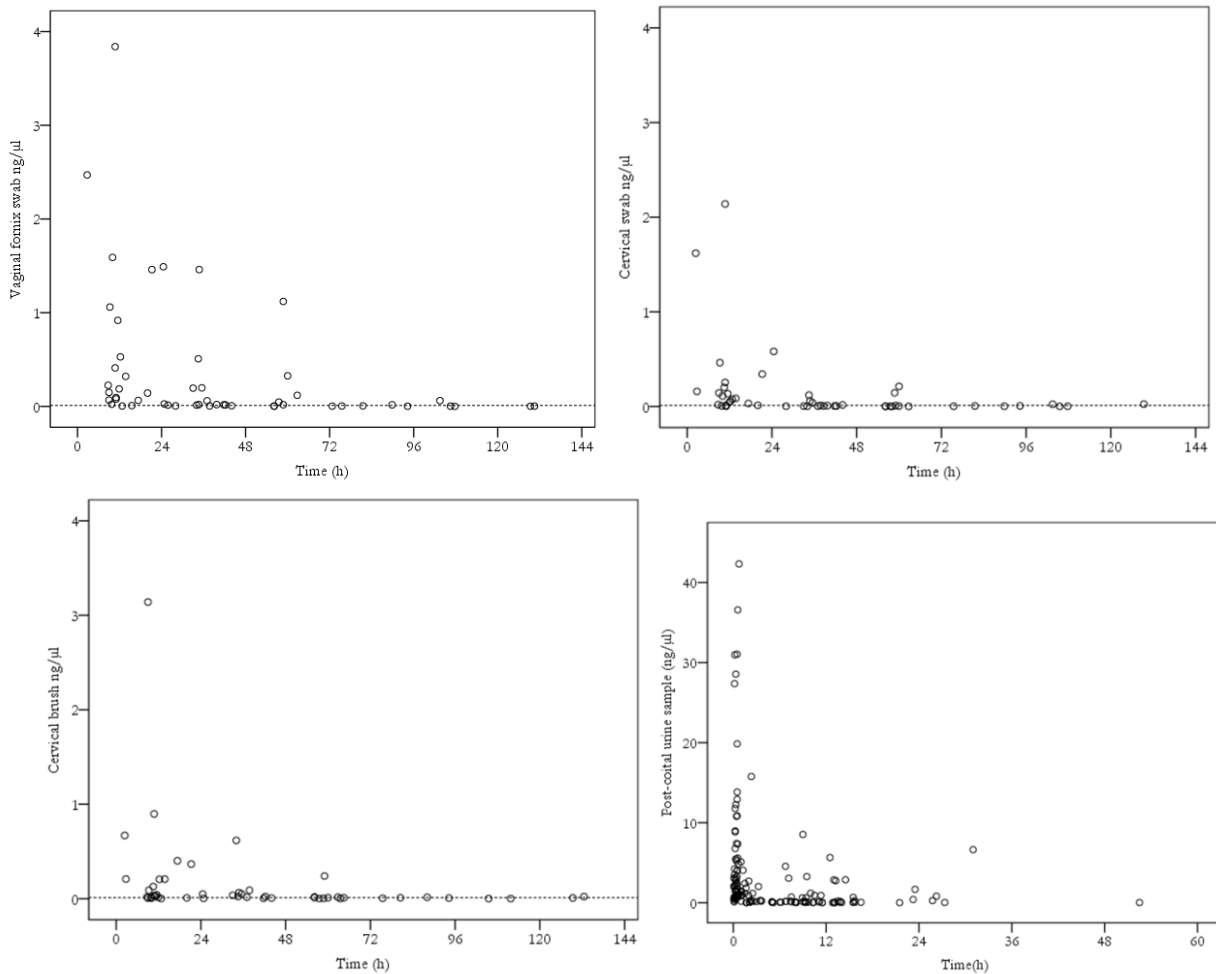
Y-DNA	Post-coital voiding samples											
	First void		Second void		Third void		Fourth void		Fifth void		Sixth to tenth void	
	n	%	n	%	n	%	n	%	n	%	n	%
	n=86		n=43		n=27		n=11		n=10		n=28	
Positive	83	96.5	31	72.1	15	55.6	8	72.7	8	80.0	8	28.6
Negative	3	3.5	12	27.9	12	44.4	3	27.3	2	20.0	20	71.4

5.2.3.1 Cut-off limits of the possibility of identifying DNA from swab, brush and urine samples (III-IV)

The cut-off limit for possible DNA identification of the male was hypothetically considered to be 0.01ng/μl. In study III, the quantification and analysis resulted in measurable amounts of male DNA from which the mean quantities were 1.10 ng/ml (median 0.06 ng/μl; range 0.0005-23.3 ng/μl) from vaginal fornix swabs; 0.34 ng/μl (median 0.01 ng/μl; range 0.0011-10.6 ng/μl) from cervical swabs; and 0.16 ng/μl (median 0.02 ng/μl; range 0.0005-3.2 ng/μl) from cervical brushes (Fig. 6). No statistically significant relations were found when comparing the collection methods by cut-off limit of 0.01ng/μl.

In study IV, Y-DNA of $\geq 0.01\text{ng}/\mu\text{l}$ was quantified in 153/205 (74.6%) urine specimens. The mean of measurable Y-DNA quantity was $4.2\text{ ng}/\mu\text{l}$ (median $0.9\text{ng}/\mu\text{l}$; range $0.01\text{-}121.8\text{ ng}/\mu\text{l}$) (Fig. 6). The hypothetical DNA identification was also estimated according to the recommended cut-off limit of $0.023\text{ng}/\mu\text{l}$ for Quantifiler Y. The male DNA amount was below $0.023\text{ ng}/\mu\text{l}$ in 28/153 (18.3%) urine samples.

Figure 6. Quantification of human male DNA according to time and $\geq 0.01\text{ ng/ml}$ cut-off limit in vaginal and cervical swabs, cervical brush and urine samples collected following consensual intercourse. One urine specimen ($121.84\text{ ng}/\mu\text{l}$, collected 50 minutes following intercourse) was omitted from the figure as an outlier. Notice the differences between the scales of vaginal/cervical and urine samples.



5.2.3.2 Microscopy (III-IV)

In study III microscopy of slides was performed in 62/84 (73.8%) of the volunteers using two different microscopy techniques. Immediate phase-contrast microscopy performed in a subgroup of 39 volunteers, by an experienced sperm microscopist, detected spermatozoa in 7/39 (17.9%) volunteers; six (7.1%) with a few sperm and one (1.2%) with many spermatozoa per slide. Using the Kernechrout dye, spermatozoa with both body and tail were detected in 5/23 (21.7%) volunteers. Altogether twelve (14.3%) volunteers had spermatozoa detected in study III.

In study IV, immediate phase-contrast microscopy was performed on a subset of 111 urine specimens from 47 volunteers. Immediate microscopy verified spermatozoa within 24 hours in 66

(59.5%) samples; a few in 29 (26.1%), a moderate amount in 15 (13.5%) and many in 22 (19.8%) samples at 10x20 magnification.

In study IV, spermatozoa was detected in 37/44 (84.1%) samples in first void specimens. A significantly higher rate of spermatozoa was detected when compared to a recent study of Smith and colleagues (2014) of first void urine specimens in alleged sexual assault cases, 84% vs. 35% ($p < 0.001$).

In study IV, a significant ($p < 0.001$) association was found between positive Y-DNA and detection of sperm in immediate phase contrast microscopy. Microscopy detected 66 (67.3%) of positive Y-DNA samples and failed to detect spermatozoa in 32 (32.7%) of Y-DNA positive samples. Compared to Y-DNA, the sensitivity of phase contrast microscopy was 67.4% (95% CI; 57.1-76.5%), but specificity was 100% (95% CI; 82.2-100%).

5.2.4 Timing issues (II-IV)

The median time from consensual vaginal intercourse to medical examination and the vaginal and cervical canal sample collection was 42.0 h (range 1.5-183.2). The median time from consensual intercourse to urine specimen collection was 5 hours (range 0.08-96.33 hours).

5.2.4.1 Time-frame for injury detection (II)

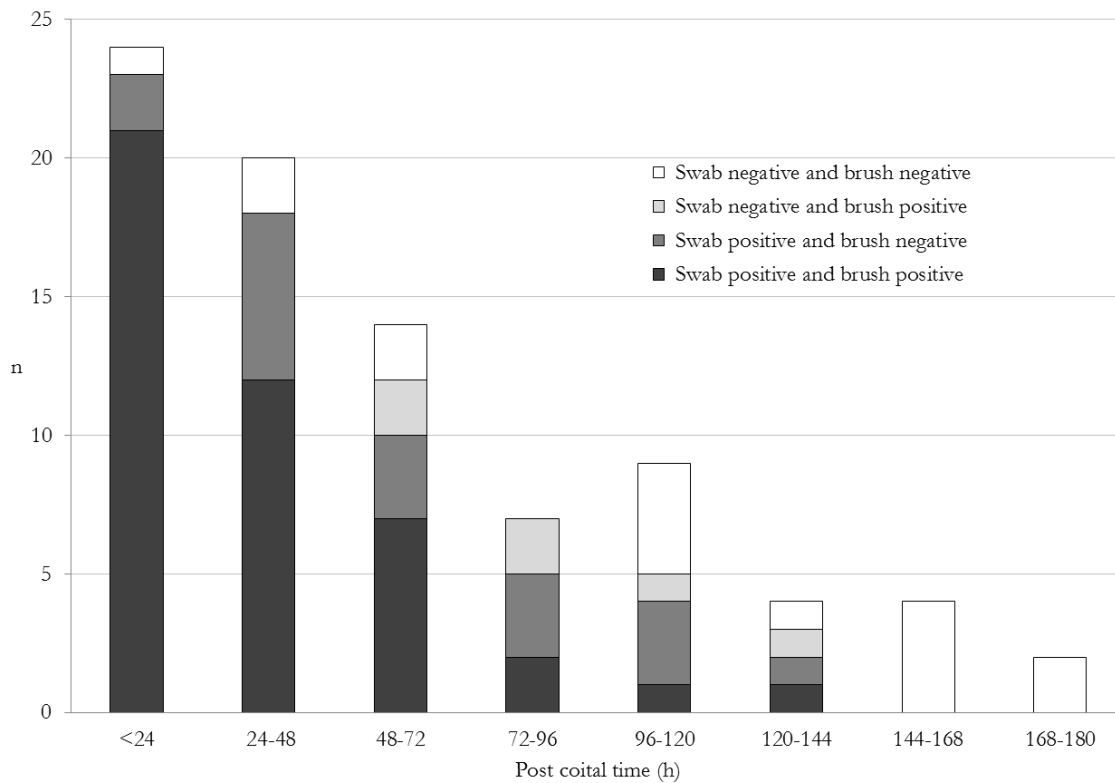
Submucosal hemorrhages were detected on average after 49.0 h (range 13.5–133.25) following intercourse under white light and 45.5 h (8.75–133.25) under UV-light, suggesting hemorrhages were seen slightly (n.s.) earlier under UV-light than under white light. UV-light did not detect petechiae earlier than white light, but confirmed their existence more definitively after several days.

Positive findings for genital hemorrhages within 24 h were 12% (3/25) in white light and 24% (6/25) in UV-light; within 24–48 h 14.3% (3/21) in white-light and 19% (4/21) in UV-light, within 48–72 h 2/16 in white light and 4/16 in UV-light, within 96–120 h 1/8 in UV-light and within 120–144 h 2/4 in both lights.

5.2.4.2 Time-frame for Y-DNA detection (III-IV)

In study III, up to 60 h, the conventional swab sampling techniques detected more Y-DNA positive samples compared to the brush technique. However, after 60 h the cervical canal brush sample technique showed its benefit by detecting 27.3% (6/22) Y-DNA positive samples, which were Y-DNA negative by both conventional swab sampling techniques (Fig.7).

Figure 7. Time interval from consensual sexual intercourse to the study examination and measurable male DNA's by forensic collection methods (swab samples from vaginal fornix and cervical canal; brush samples from cervical canal) per volunteer (N = 84).



When samples were collected in less than 72h following consensual intercourse, two (28.6%) brush samples out of seven swab-Y-DNA-negative samples were positive. When samples were collected over 72h following intercourse, four (26.7%) brush samples out of 15 swab-negative samples were positive.

By combining swab and brush techniques, 75% of volunteers were still Y-DNA positive between 72 and 144 h. The positivity of the sample was statistically significantly associated with the time from the consensual intercourse to the medical examination. The positivity rate decreased by approximately 3% per hour (vaginal swabs OR 0.97 (95% CI 0.96-0.98).

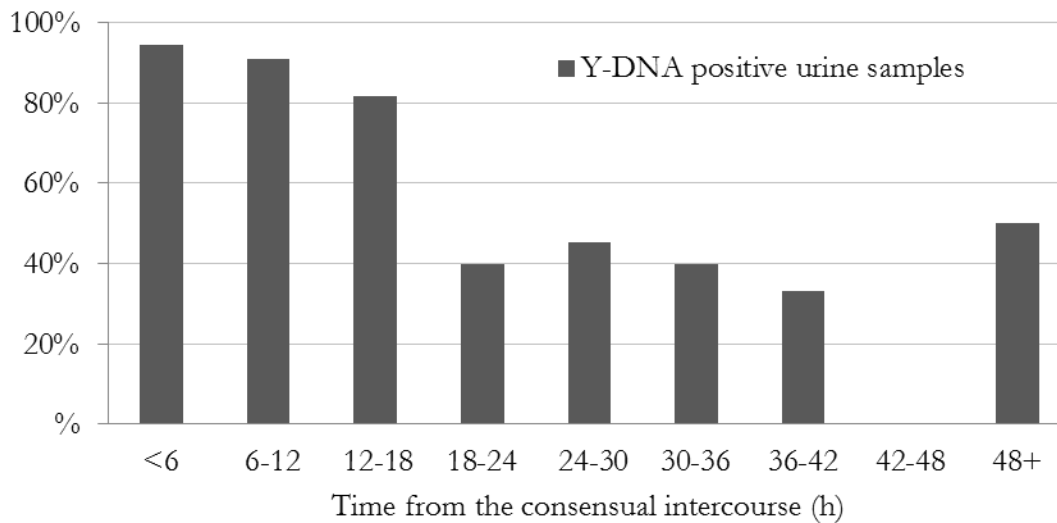
In study III, of 58 volunteers studied within 72 h, 5/58 (8.6%) were Y-DNA negative, and 3/44 (6.8%) of volunteers were Y-DNA negative within 48 h. After 144 h (6 days) Y-DNA was not detected.

In study IV, the median time for measurable Y-DNA was 9.2 hours (range 0.08-52.5 hours). Most (89.3%) of the urine specimens were collected within 24 post-coital hours. After 24 post-coital hours Y-DNA was measurable in 9/22 (40.9%; range 0.0013-6.6 ng/ μ l) urine specimens (Fig.8). In five of these measurable specimens Y-DNA was quantified over 0.01ng/ μ l after 24h.

5.2.4.3 Time-frame for spermatozoa detection in microscopy (III-IV)

Within 48 h, microscopy detected spermatozoa in 11/32 (34.3%) volunteers in study III. Within 24 hours, 66 (59.5%) of urine samples were positive for spermatozoa in immediate microscopy.

Figure 8. Proportion of positive male DNA in urine samples according to the time from consensual intercourse to urine specimen collection.



5.2.4.4 Possible factors affecting the detection of acute genital findings, genital scars, Y-DNA or spermatozoa (II-IV)

Lubricants. Eight volunteers used lubricants during the studied intercourse, and none showed acute findings in the anogenital area. No associations were found regarding the use of lubricants and Y-DNA positive samples.

Hormonal pregnancy contraception. Twenty-one volunteers did not use any hormonal products and five of them in the pre-ovulatory menstrual phase were positive in all collected samples. Submucosal hemorrhages were more commonly seen among users of progestagen contraceptives (pills or intrauterine device) compared to non-hormonal and combined oral contraceptives, but with no statistically significant difference. No associations were found regarding the contraceptive method in use and Y-DNA positive samples.

Use of condom. Four volunteers used condoms for contraception. In two of them the quantity of Y-DNA was over 0.01ng/μl. In two urine specimens spermatozoa were detected.

Coital frequency per week (mean 3.2, range 1–6; SD 1.2) did not influence the frequency of acute mucosal findings, even when age was considered. The coital frequency per two weeks prior to the study intercourse was 0-3 times in 41 (48.8%) volunteers and 4 or more times in 43 (51.2%) volunteers. No association was found between coital frequency and measurable Y-DNA.

Coital duration. The median coital duration was 15 min (range 2–60). In both studies III and IV, no statistically significant differences were found between coital duration and the Y-DNA specimen positivity. All acute physical findings under either white or UV-light were detected in cases where the intercourse lasted less than twenty minutes.

Coital and post-coital activities. In both studies III and IV, no statistically significant differences were found between coital frequency during the previous two weeks prior to the study intercourse, post-coital activities, and the Y-DNA specimen positivity. Post-coital activities were reported in 21 volunteers, of which 16 (76.2%) swab samples and 12 (57.1%) brush samples remained positive.

Parity. Delivery pathway or former episiotomy did not have an effect on acute findings. In study II, 52 volunteers were nulliparous (59.1%), 36 (40.9%) parous with one to five deliveries, of which two vaginal

deliveries without episiotomy and three Caesarean sections. Genital scars were detected in one (1.9%) nulliparous woman and 34 (94.4%) parous women. A regular or normal appearing mucosal surface was seen in all nulliparous females. Ten out of thirty-one (33.3%) women with a history of episiotomy or ruptured vaginal outlet wall during delivery had complete healing based on the presence of a regular anogenital skin and mucosal surface. In two volunteers, one with a history of a vaginal delivery without episiotomy and another with episiotomy, visible scars were undetectable under white and UV-light.

Accidental trauma. Prior accidental genital trauma with bleeding was reported by 16 (18.2%) of the 88 volunteers. Two of these were cycling traumas, one straddle injury, one coital injury and one rape, and the remaining 11 did not specify the cause of the trauma. Of these, 6/16 had a scar. Apart from delivery-associated scars, one scar was caused by a vaginal operation and one scar by a previous trauma. Residual genital findings were not detected in ten nulliparous females who reported genital accidental trauma.

Anal trauma. Prior anal trauma with bleeding was reported by six (6.9%) volunteers. Two of these were victims of sexual abuse, of which one reported violent anal penetration. None had visible scarring under white or UV-light.

Sexual assault. Prior sexual assault was reported by 7/87 (8%) volunteers. One volunteer did not answer the question. At the time of the sexual assault, five out of seven participants were under 18 years old, and two were adults (20 and 23 years). In three cases of child sexual abuse, the victimization of sexual abuse lasted over a long period of time (3–6 years). Both adult victims suffered penetrative rape. Additionally, two volunteers were unsure whether they were sexually assaulted as teenagers.

6 Discussion

6.1 Medical statement conclusions in the criminal legal process (I)

Robust decision making in the medical field is needed to minimize misunderstandings in the criminal legal process of alleged sexual violence against children. Study I found some cases where the physical findings were inadequately interpreted in medical statement conclusions, which may have led to misinterpretations in the criminal legal process. Results of study I highlight the importance of common terminology (American Professional Society on the Abuse of Children 1998, Pillai 2007) and interpretation of physical findings (Adams et al. 2007, Royal College of Paediatrics and Child Health 2008) in medical statements and reports which enables the understanding of each other in multidisciplinary collaboration (Nesvold et al. 2011). The use of guidelines (Adams et al. 2007, Royal College of Paediatrics and Child Health 2008, Finnish guidelines 2013), peer-review (Committee on Medical Liability and Risk Management 2009, Adams et al. 2012, Starling et al. 2013) and external quality control of medico-legal documents (www.justissekretariatene.no) will facilitate and improve the quality of interpreting the genital findings correctly in medical statements. Thus, the medical statement conclusion significantly supports decision making in the legal process when it is consistent with the child's disclosure, and if it is interpreted correctly.

The significance of an overall population based prevalence of anogenital injury in the medical decision making of an individual case is insignificant, because there are so few objective findings in victims of CSA. Only some genital findings used in isolation may predict non-acute sexual abuse among prepubertal girls (Berkoff et al. 2008). The attempt to narrow decision making only to the existing wide range of population based prevalence data of anogenital injury in victims after sexual violence or following consensual intercourse may be misleading. To clarify this medical interpretation, for example, let's consider a hypothetical infertility patient whose pretest probability of pregnancy is 33% if treatment of choice is in vitro fertilization. Following the embryo transfer, when we certainly know that an embryo was inserted into her uterus, the clinical prevalence of intra uterine adherence of the embryo, thus her getting pregnant, is either 100% or 0%. That is the same with victims of sexual violence, you either get an injury or you don't, but it does not make the sexual violence less relevant, if such an incident is clearly disclosed by the victim. The detected injury or residual change in anatomical architecture is a proof of a certain amount of force used against tissue, depending on the object used.

An evaluation of alternative causes of the injury needs a complex flow of decisions while forming medical conclusions and clinical forensic conclusions. If (1) time for healing (time frame from alleged sexual violence to medical examination), (2) differential diagnostics, (3) child's history of CSA, (4) other objective evidence, (5) type of violence, injury mechanism (6) the amount of force used in the incident, (7) degree of the primary injury, or (8) pubertal developmental status are not included to the evaluation of suspected sexual violence, an inadequate interpretation of the anogenital findings may lead to a serious risk of misinterpretation in the criminal legal process. These are highly important factors when analyzing the presence of anogenital injury, but also basic knowledge of normal anatomical (Berenson et al. 1992, Berenson 1993ab, Berenson 1994, Heger et al. 2002b, Myhre et al. 2003, Hobbs 2012) and hormonal variety and developmental changes (Berenson and Grady 2002, Myhre et al. 2010) in the genital area are important for the interpretation of physical findings. The absence of physical findings is more probable

than the presence of an objective anogenital finding regardless of time (De Jong and Rose 1991, Adams et al. 1994, Adams and Knudson 1996, Kellogg et al. 1998, Berenson et al. 2000, Heger et al. 2002a, Anderst et al. 2009, De Jong 2011).

6.1.1 The Child's disclosure of alleged CSA (I)

The most valuable and relevant evidence in the legal process was the child's clear disclosure of sexual abuse, which is consistent with the earlier research (De Jong and Rose 1991, Adams et al. 1994, Heger et al. 2002a, Sague-Castillo et al. 2009). Leander's study (2010) on 27 sexually abused children with objective verification (e.g. photographs and/or video films) found that children reported more neutral information from the abusive acts than from sexual acts, and only 10% of details concerned sexual information. Even though the reliability of a child's disclosure may be questioned during the evaluations, the most objective forensic interviewing research result reported that some children even with verifying evidence denied being part of sexual acts (Leander 2010). This is in line with the "golden standard" in absence of genital injury presented earlier by Adams (1994) and Kellogg (2004) and their colleagues: "it's normal to be normal, but it does not mean that nothing happened".

Study I showed that in most CSA cases a clear disclosure is needed for a verdict, which is consistent with earlier research reporting that charged cases tend to have at least two types of evidence; often disclosure and corroborating evidence (Walsh et al. 2010). Acute injury or objective residual finding may support the disclosure of CSA (Adams et al. 2007, Royal College of Paediatrics and Child Health 2008).

The result of study I show that medical statement conclusions were used to value the reliability of the disclosure. The significance of medical history is to find out if there were any physical symptoms or signs at the time of the alleged incidence which could help to validate the child's description of the abuse experience (Adams 2011). The medical history assists in the evaluation of physical symptoms and signs regarding the differential diagnostics and the time related issues concerning the suspected sexual crime. The medical provider can correlate the child's description of symptoms to the description of the acts the child experienced and can testify to that in court (Adams 2011). We found the medical statement conclusions supported the legal decision depending on disclosure, as it enhanced the reliability of the child's disclosure.

In legal decision making the "not supporting nor excluding" medical statement conclusions, "the golden standard" (Adams et al. 1994, Kellogg et al. 2004) were considered as evidence that supports the child's disclosure when the type of sexual abuse was considered. The court's decision is adjudicated by all the presented evidence in the criminal process. The presence of medical evidentiary is not essential for a conviction which is consistent with study I: medical evidence may corroborate the victim's testimony (Jewkes et al. 2009).

6.1.2 Sexual violence and legal outcome (I)

There are contradictory results concerning medical evidence and prosecution in CSA studies; it is reported to be a predictor of successful prosecution (Palusci et al. 1999, Sague-Castillo 2009, Jewkes et al. 2009) but in some studies no such relation was found in legal outcomes of appearing in court (Cahill 2004, Hansen et al. 2010) or being convicted in CSA cases (Sague-Castillo 2009, Hansen et al. 2010). Study I analyzed the medical statement conclusions role in legal outcomes; the interpreted conclusions by the physician had a significant role in legal decision making. Value of the medical conclusion is

increased when it is not solely based on the detected genital finding but also includes the child's disclosure and differential diagnostics.

Lack of consistency in the classification system used to describe genital and non-genital injury complicates the evaluation of the significance of the injury (Sommers et al. 2012). In spite of inconsistent injury definitions, the presence of injury has been reported to influence decision making throughout the criminal legal process (Penttilä and Karhunen 1990, Rambow et al 1992, Gray-Eurom et al. 2002, McGregor et al. 2002, Jewkes et al. 2009, Sommers et al. 2012), but abnormal physical findings are not necessary for conviction in legally confirmed sexual abuse cases (Tintinalli and Hoelzer 1985, De Jong and Rose 1991, Muram 1989a).

Earlier reported and present study I results of prosecution and conviction rates of medically examined alleged CSA victims are presented in Table 6. The study I CSA population charging rate of 42% was consistent with earlier Scandinavian studies, where the filing rate varied from 43% to 44% in police referred CSA allegations (Edgardh et al. 1999, Hansen et al. 2010). Earlier reported conviction rates in Scandinavia were 38–42% in the whole study populations (Edgardh et al. 1999, Hansen et al. 2010) which were slightly higher than in our study I (30.8%). It is worth noticing that the conviction rates of CSA were low in developing countries (Jewkes et al. 2009, Sugue-Castillo et al. 2009).

In studies of legal outcomes of sexual assault cases including both adolescents and adults the reported prosecution rate varies from 32% to 44% (Penttilä and Karhunen 1990, Gray-Eurom et al. 2002), and the guilty verdict or plea rate was 35-86% (Penttilä and Karhunen 1990, Wiley et al. 2003, Saint-Martin et al. 2007).

I agree with Du Mont and White (2007) that it is difficult to draw comparative conclusions because medical evidence and legal-outcome study designs often include both adults, adolescents, some men and even children. Some studies do not include the age range at all. In previous research the study variables have been drawn from various countries with various criminal justice systems, from diverse data sources, or the analyses have been performed by different procedures, which make comparison even more difficult (Du Mont and White 2007). Reporting has varied by different legal outcomes and other measured issues which complicate the comparative analysis; some measuring the prosecution charging or dismissal rates and some guilty verdicts or pleas, and the portion of pending cases influence the results. Some studies include in the medical evidentiary the criminal laboratory results and some do not. The differences in these and in scientific approaches to the research questions, in definitions of sexual violence, in criminal legal processes and laws make analyzing results problematic.

6.2 The possibility of previous injury cannot be ruled out by delayed medical examination (II)

Study II added to our knowledge of genital findings following consensual intercourse and confirmed the study hypothesis; both submucosal hemorrhages and scars were detected significantly more often under UV-light when compared to white light, with the result that more than half of submucosal hemorrhages and every fifth of genital scars (mostly delivery associated) would have been potentially missed if white light alone was used. As is the case following consensual intercourse, most sexual violence related genital findings are minor injuries which do not result in residual findings in both children and adults; thus, the majority of genital injuries heal completely (Heppenstall-Heger et al. 2003, McCann et al 2007ab, Adams 2011, Gavril et al. 2012).

Table 6. Progression of medically examined suspected CSA cases in the legal process.

Authors, referral, country	N	Age, years	Charges filed	Conviction rate, overall/ in charged cases (n)
De Jong and Rose 1991	137	1-16	NA	52% at age of ≤6 years 80-83% at age of 7- 16
Palusci et al. 1999, NA, USA	497	0-17	NA	35%
Edgardh et al. 1999, police or social service referred, Sweden	94	9-22	44%	42% (32/77)
Cahill 2004, NA, USA	72	12-17	33%	26%/ 79%
Saint-Martin et al 2007 Police referred	430	<15 ^a	54% ^b	43% ^b
Jewkes et al 2009 Police reported, South-Africa	596	0-17	48% (n=284)	7% / 16%
Sugue- Castillo 2009, Philippines	486	1-19	NA	15% 58% ^c
Hansen et al, 2010 Police referred, Denmark	482	Median ♀ 9 ♂ 6 (0-15)	43%	38% (165/440)/ 87% (165/190)
Present study I Police referred, Finland	130	Median 5,3 0-17	41.5%	30.8%/ 74%

^a The study presented data of <15 years and 15 years and older cases separately

^b calculated in <15 years age category^a

^c among resolved cases

NA data not available

The minor acute injury rate was consistent with earlier adult consensual sexual intercourse studies using magnifying instrumentation and white light (Slaughter et al. 1997, McLean et al. 2010, Lincoln et al. 2013) (Table 7). The majority of studies which used application of contrast media report higher injury prevalence (Norvell et al. 1984, Anderson et al. 2006, Zink et al. 2010, Astrup et al. 2012a, Larkin et al. 2012). The high prevalence of genital tears and lacerations in some earlier studies may be due to

insufficient differential diagnostics of extra-genital mucosal findings, or a lack of follow-up. Genital mucosal findings caused by some gynecological, gastrointestinal, or dermal diseases may be difficult to distinguish from fissures or lacerations caused by sexual intercourse. Of course, in prepubertal children consensual intercourse is not an acceptable differential diagnostic option for genital injury.

Figure 9. List of previous adult studies with acute external genital findings following consensual vaginal intercourse, compared to our study

Authors, Publication year	<i>N</i>	<i>Age range, years</i>	<i>Time frame, hours</i>	<i>Acute genital trauma rate (n)</i>	<i>Acute genital findings (n)</i>	<i>Clinical examination methods</i>
Lauber et al. 1982^a	22	women	≤48	4.5%	Laceration (1)	Toluidine blue technique
Norvell et al. 1984^a	18	23-35	1.≥72 2.≤6	11.1% (2) 61.1% (11)	Teleangiectasia (7), broken blood vessels (2), micro abrasions (2)	Colposcope and Lugol's solution
Slaughter et al 1997^b	75	18-48	≤ 24	11% (7)	Ecchymosis, tear, abrasion	Colposcopy and photography
Anderson et al. 2006^a	46	21-45	≤ 24	30%	Abrasions, tears, ecchymosis, redness	Colposcopy, toluidine blue
McLean et al. 2010^a	68	≥30	≤ 48	6% (4)	Bruises (3), Laceration (1), abrasion (1)	Wall mounted circular magnifying glass with incorporated lamp surround
Zink et al. 2010^a	120	>20	≤ 24	55%	Tears, abrasions, ecchymosis, redness	Visual inspection, colposcopy, toluidine blue
Astrup et al. 2012^a	98	29-40	<48	34%, 49% ^e , 52% ^d	Lacerations (49) ^d , abrasions (7) ^d , hematoma (3) ^c	Naked eye, colposcopy, or toluidine blue
Lincoln et al. 2013^a	81	18-45	≤ 72	9.9%	Lacerations, abrasions, bruises	Macroscopic inspection
Present study II^a	87	20-52	<184	14.8 % 23.0 % ^e	Submucosal haemorrhage (13) ^e , petechiae (4), abrasions (2), laceration (1)	Colposcopy and photography either by white or UV-light

^aProspective study

^bRetrospective study

^cColposcopy

^dToluidine blue

^eUV-light

In previous follow-up research in children, anogenital, non-hymenal scar tissue formation has been infrequently observed only after deep genital lacerations (tears) from various causes; medical procedure, accidental injury or sexual violence (Heppenstall-Heger et al. 2003, McCann et al. 2007a, Slaughter, Watkeys et al. 2008). Scars on the mucosa may heal to be undetectable, as shown in our study II; every third participant of vaginal delivery with episiotomy healed with a regular mucosal surface, and these participants had no visible scarring under white or UV-light. Even in children, the majority of acute genital findings heal to normal during follow-up (Finkel 1989, Heppenstall-Heger et al. 2003, Boos et al. 2003, Gavril et al. 2012). This enormous healing ability should be considered in the criminal legal process to avoid misunderstandings in cases of sexual violence.

6.3 Forensic collection methods for spermatozoa and DNA following consensual intercourse (III-IV)

The study hypothesis of the two forensic evidence collection methods, the cervical brush and urine specimen was confirmed; they both provided additional evidence in documenting the presence of Y-chromosomal material when compared to traditional collecting methods. When analyzing collected genital samples, the sensitivity of detection of Y-chromosomal material using Y-STR amplification methods has been higher than finding spermatozoa in cytology (Sibille et al. 2002). Study III results showed 14.3% overall positivity by microscopy compared to 81.0% by PCR.

The best sampling site to detect spermatozoa differs by studies, either being the cervix (Morrison 1972), or the posterior fornix (Astrup et al. 2012a). In study III, the brush technique from the cervical canal seems to be slightly better than the swab technique if the quantity of Y-DNA is considered. The benefits of the brush technique may be due to the collection of the remaining semen in cervical canal crypts by a brush compared with swabs as the brush attaches most of the cervical canal mucus to the brush.

A recent Australian study (Smith et al. 2014) detected spermatozoa in 35% of first void urine specimens collected following alleged penile-vaginal penetration which was a significantly lower detection rate than in our first void specimen (84%) following consensual intercourse. The difference in the detection rate may at least partly be due to a lower ejaculation rate in assault cases, or in the urine specimen collection technique.

The quantity of measurable male DNA (median 0.9 ng/ μ l) in the post-coital urine specimens seems to be higher when compared to vaginal swabs (median 0.06 ng/ μ l), cervical swabs (median 0.01 ng/ μ l), and to cervical brush (median 0.02 ng/ μ l) samples analyzed by the same quantification method. The possibility for male DNA identification was considered in 75% of urine specimens.

Study (III-IV) results show that even following consensual sexual intercourse there is not always biological evidence of sexual contact, which is in concordance with earlier research on consensual sexual intercourse (Leppäluoto et al. 1974, Silverman and Silverman 1978, Randall. 1987, Astrup et al. 2012a).

Lack of biological evidence does not support or negate the clear disclosure of sexual violence. The presence of spermatozoa proves contact of a sexual nature, or a contamination of seminal fluids in the site of the sample collection. Detecting male DNA from the vaginal fornix or uterine cervix may result from sexual assault, previous consensual intercourse, contamination by secondary transfer of male DNA, or a rare XY syndrome in a female (Joki-Erkkilä et al. 2002). Thus, evidence of spermatozoa in adolescent victim or Y-DNA detected from sample collected from child's body does not itself prove the suspected perpetrator guilty without the DNA-identification and still the relevance of child's disclosure

Previous studies show Y-DNA detection rates of 41-92% in CSA children by Y-STRs (Delfin et al. 2005, Girardet et al. 2011, Thackeray et al. 2011 and Maiquilla et al. 2011). In our study I there was only one DNA identification, which did not match the perpetrator's DNA. In the crime laboratory report it was not further interpreted. It could be a result of contamination while collecting the sample, preserving it, or in phases of laboratory analysis. The presence of Y-DNA in the child's genitalia corroborates testimonies of sexual contact but also a previous consensual sexual history is to be considered in adolescents (Delfin et al. 2005).

No single sample collection method or sampling site is solely better than the other in alleged sexual violence victims and to avoid loss of evidence a multi-method approach is of value in biological trace evidence collection.

6.3.2 Timing of collecting biological forensic samples (III-IV)

Up to 60 h, the conventional swab sampling techniques detected more Y-DNA positive samples compared to the brush technique. However, after 60 h the cervical canal brush sample technique showed its benefit by detecting 27.3% more male DNA positive samples, which were Y-DNA negative in both swab sampling techniques. Despite reported consensual intercourse, 6.8% volunteers were Y-DNA negative within 48 h. The possibility of negative sample results following consensual intercourse in volunteers is an important impact to be acknowledged in the evaluation of biological trace evidence in the criminal legal process.

The results (study IV) suggest that urine specimens for forensic purposes may be collected even up to three days in suspected sexual assaults. A high positive Y-DNA rate was detected in urine samples when collected within 18 post-coital hours. Overall, spermatozoa were detected up to 24 post-coital hours in collected urine specimens. After 24 hours, Y-DNA was identified in 40% of post-coital urine specimens. Post-coital factors, such as washing, urinating or defecation do not preclude the finding of spermatozoa or Y-DNA, which supports earlier study results (Allard 1997).

In adolescent and adult victims of sexual violence the cut-off time frame for evidence collection from the lower genital tract with swab samples varies mostly from 48h to 72h and occasionally samples are considered beyond this, up till 10 days (WHO). The WHO recommends collecting specimens as early as possible because the value of evidentiary material decreases 72 hours after the assault. Study III showed that the risk of negative genital sample results after sexual intercourse increased by approximately 3% every hour. Genital swabs and brush samples collected identifiable Y-DNA up to six days after the suspected assault. In consistency with earlier research (Sibille et al. 2002), we recommend that the cut-off time frame for vaginal and cervical forensic sample collection should be at least one week after the suspected sexual assault in adults and in adolescents in whom the samples are collected in a similar way to adults.

The delay from alleged CSA to medical examination has been reported as being longer amongst younger children than in 15 year-olds or older (Saint-Martin et al. 2007). It is well documented that the majority of positive forensic evidence is collected within 24 hours of sexual violence in prepubertal children (Christian et al. 2000, Palusci et al. 2006, Young et al. 2006, Girardet et al. 2011), but some cases with positive evidence may be lost if evidence collection is avoided (Thackeray et al. 2011, Girardet et al. 2011).

There are recommendations of limited evidence collection from a prepubertal child's body up to 24h (Christian et al. 2000) but the American Academy of Pediatrics recommends an immediate examination and forensic evidence collection when sexual abuse has occurred within 72 hours, or when there is

bleeding or acute injury. Although the amount of positive forensic findings from body swabs after 24 hours are rare, limiting the time for sample collection in prepubertal children may lead to a loss of evidence. This really emphasizes the value of immediate clinical forensic examination and sample collection.

Although DNA analysis is a reliable forensic method, as it can accurately demonstrate a connection between evidence and its specific source, the result needs to be correctly interpreted; a negative forensic sample result can only lead to the conclusion that it does not support or exclude the possibility of e.g. vaginal penetration if a history of such is given.

6.4 Strengths, limitations and some ethical considerations

Studies I-IV followed the Declaration of Geneva respecting the secrets confided in me. These ethical challenges for anonymity were considered carefully. Ethically, human rights are uplifted; the officials working with CSA children will benefit by understanding the complexity of medical examination results and the interpretation of it. The risk of misinterpretation was evaluated to avoid professional neglect. Emphasizing the value of multidisciplinary, comprehensible, language and communication are important issues.

Study I dealt with the very delicate subject of child sexual abuse, a highly vulnerable study population. In the study, delicate information and data from different systems (health care, National Police Information System, criminal investigation, Prosecutor's office, District Court Archive, and Court of Appeal) was combined so that the concealment of confidential information was secured; after collecting the patient's data from the healthcare archives, the obligation to maintain secrecy was maximized by collecting further data by criminal investigation or archive numbers. The data was reviewed by individual case records and reported in detail with ethical considerations so that it would not hurt the people involved. The social and psychological advance in study I was that it may diminish anxiety among professionals because it showed that the "not supporting nor excluding" medical conclusions, "the golden standard" (Adams et al. 1994, Kellogg et al. 2004) were considered as evidence that supports the child's disclosure when the type of CSA was considered.

The strength of study I was the completed collection of the criminal legal data from all the various official sources; healthcare, police, prosecution and court. The strength of study I's design was that it only included random sample cases with final legal conclusions and the pending cases were excluded. The new approach of also evaluating the differential diagnosis of a physical finding is also strength of study I, as a lack of including credible alternative explanations has been reported earlier to be a deficiency of forensic reports (Mian et al. 2009).

Study I certainly has some limitations. Inadequate documentation and personal variation in the whole medico-legal process may weaken the reliability of this retrospective data. If the data is not properly documented and archived, it possibly cannot be used in the court of law. Data collection may have been biased by the sample selection due to the reorganized archives since 2006, which are now separate from the actual hospital archives and the crime investigation numbers were easily found after 2006. Another possible cause for selection bias may have been that some of the medical statements from the hospital archives were destroyed after two years of archiving. Also, in the earlier years, the crime investigation numbers were not automatically documented in the medical records. In addition, the photographic archive was also destroyed before year 2004. Photographic documentation was available in 77/104 (74.0%) girls and in 1/26 (3.8%) boys. Because of the lack of photographs we could not verify diagnostic accuracy in medical reports. Thus, to archive all the medico-legal documents diligently should be a

requirement. Also the randomization method of the archivist selecting cases randomly may have caused a selection bias. Furthermore, some subjective interpretation was required during data collection and coding. Study I involved researchers from different disciplines; medical and social sciences. Therefore, there were differences in the subjective interpretation of medical conclusions. In the final data, we use the medical point of view.

Study I results may have been influenced by possible variation in interpretation of evidence by police officers, prosecutors or different courts handling CSA cases. Possibly inadequacy of evidence of CSA may have caused a bias in the ruling.

The strength of studies II-III was that all the examinations and sample collections were performed by one gynecologist. Participant reliability was considered to be excellent because studies II-IV were conducted in volunteers by personal invitation.

The research design may have influenced the results in studies II-III because there were no randomization and because in studies II-IV there were no control groups. Even so, in study II-III the research design by standard examination method answered to the research hypothesis, but it did not answer whether the vaginal or cervical canal swabs are better evidence collection methods than the cervical brush.

Alternative medical or non-medical reasons for the physical findings in study II need to be considered. The accuracy of genital finding interpretation may have improved by follow-up examination; Gavril and colleague's follow-up study (2012) showed a considerable change in genital injury likelihood. Interpretation of UV-light physical findings requires discretion, as alternative medical or non-medical causes must be considered. A physical finding such as accentuation in the mucosal or skin area can be caused by sexual abuse, trauma, medical operations, shadows, blood, moles, venous enlargements, or healed infections (e.g., Varicella). To avoid these, multiple photographs were taken during the examination. Additional considerations are that UV-light causes the skin to fluoresce a coral red color in erythrasma, and the fluorescence of pubic hair may interfere with interpretation of physical findings. In sexual assault cases, follow up examinations are also recommended to evaluate the cause(s) of acute and intermediate medical findings in UV-light investigations. Consideration of differential diagnosis is essential for any physical finding.

The risk of type II error was a limitation because of the considerably small sample sizes especially in different time-frames and age groups following consensual intercourse. Because studies II-IV were underpowered, some statistically significant differences may have remained undetected.

Limitations of study II included the quite small number of participants and the lack of a follow-up and independent peer-review. One examiner provided study consistency, but the lack of a comparative interpretation is definitively a limitation. Only one female with a submucosal hemorrhage had a control visit in a week for another reason, and the earlier identified submucosal hemorrhage had disappeared, but another one was seen in a different location. There is a need for further studies to compare UV-light on different skin pigments.

In studies III-IV the vaginal, cervical and urine sample sizes were also quite small, when divided into several post-coital time frames, especially after 72 h. There is a need for larger studies. The risk of contamination needs to be considered. To diminish the risk of contamination, female researchers performed all collecting and sampling using standard techniques, and all the laboratory work was conducted by female experimenters. This does not prevent the possibility of secondary transfer of DNA from examination premises or forensic laboratory facilities. The quantified male DNA may also result from other sources than semen such as epithelial cells. Unfortunately, the volunteers were not asked their opinion on possible ejaculation or known azoospermia, which may explain part of the negative Y-DNA results.

In studies II-IV, confounding factors such as misunderstandings in filling in the study information form are possible.

6.5 Future implications

The importance of documentation should result a national data collection form for medical examinations of CSA as it is already established in adult victims of sexual violence (RAP-guidebook by Brandt et al. 2010). Peer-review is recommended to help the evaluation. The use of UV-light on body trauma needs further evaluation. Video-documentation of anogenital examinations may enhance peer-review because changes in dynamic examination may reveal physical findings more accurately. Future research on this is indicated. Furthermore, the national auditing system for medical statement conclusions should be established to improve quality and to avoid misunderstanding in the criminal legal process.

In sexual abuse evaluations the uncertainty of perpetration disclosed by a young child will exist. There is no way to find out whether the penetration was only through labia or partially into the vagina (Adams et al. 1994), but I raise a suggestion that the penile introduction to the mucosal surfaces should be considered as penetration in cases of CSA in the criminal evaluation.

At the acute CSA examination the physician needs to make critical decisions regarding whether to collect forensic specimens or not, how to document the findings, whether a peer-review is needed, and what kind of prophylaxis or treatment is needed, or whether a follow-up is indicated. If the medical examination is not documented accurately and clearly and there is no proper follow-up, the value of it is open to question.

One problem in deciding the urgency of the CSA examination is that some physicians believe injuries are missed if the examination does not take place within 72 hours of the alleged assault (Cahill 2004), but on the other hand some believe that an urgent evaluation is not needed because the injuries will be detected even on a later examination. The course of healing systematically follows natural laws and no matter what causes the injury healing will follow.

In consensual sexual intercourse and non-consensual sexual intercourse research there are many factors causing possible bias: retrospective research frames; most studies including both adolescents and adults; studies including nonspecific findings like redness or swelling which are difficult to evaluate without a follow-up visit; different or unclear definitions of the physical findings; not defining specifically the severity of the finding; lack of follow-up; and not considering the differential diagnostics. Interpretations of research results are also complicated by different examination positions and techniques and variance in time-frames.

The need for the physician to understand the complexity of her/his role while performing a clinical forensic examination on an alleged victim; even though the majority of victims do not have physical injury and the need for medical treatment is unlikely it's the victim's right as well as the alleged perpetrator's right to get documentation in detail regarding both negative or positive findings, and biological evidence collection if indicated. Health care personnel do not need to evaluate whether there has been a crime or not, the police will investigate the case and for the judges remain the decision whether there is enough evidence to prove a crime took place or not.

7 Summary

There are four main results in this thesis.

In the criminal legal process, the child's clear disclosure of the sexual abuse is the most important evidence and the medical statement conclusions had a significant role in decision making. Medical statement conclusions were used to value the reliability of the child's disclosure. Even a lack of physical evidence, when consistent with the alleged sexual abuse type and the child's disclosure, supports the interpretation of the evidence in the criminal legal process.

The use of UV-light significantly enhanced the detection of minor acute injuries (submucosal hemorrhages) and delivery-associated scars invisible in white light. The enormous healing ability of the human body should be considered in the criminal legal process to avoid misunderstandings in cases involving sexual violence. When sexual assault is suspected, according to our results, it is important to consider an immediate clinical examination up to 6 days after the suspected assault because even a minor injury can still be present.

The benefit of cervical brush sample collection for Y-DNA detection was found after 60 hours following consensual intercourse. Traditional swab samples would have missed 27.3% of cervical canal brush Y-DNA positive samples. By combining swab and brush techniques, three quarters of volunteers were still Y-DNA positive in 72-144 post-coital hours. The rate of measurable Y-DNA decreased approximately 3% per hour.

Correctly collected urine specimens were an excellent source for Y-DNA within 24 hours. Its main benefit is that it is a non-invasive collection method for forensic purposes. Also it may be considered a good forensic evidence collection method in acute suspected child sexual abuse cases, to diminish the time delay, and to improve patients' positive attitudes towards evidence collection.

8 Conclusions

The present thesis highlights the fact that clinical forensic examination and negative biological evidence results cannot exclude suspicion of child sexual abuse even when evidence is collected within 72 hours. Limiting the forensic biological evidence collection only to 72 hours may cause potential loss of evidence.

Lack of acute or residual injury or the lack of biological evidence does not support or negate the clear disclosure of sexual consensual or non-consensual intercourse. On the other hand, evidence of spermatozoa or Y-DNA does not itself prove the suspected perpetrator guilty without the DNA-identification, because contamination of non-match male DNA from other sources needs to be considered. The presence of spermatozoa collected from the child's body most likely proves contact of a sexual nature. For the best possible biological trace evidence collection, all the collection sites and techniques are recommended.

The purpose of clinical forensic examination needs to be clearly comprehended during the medical evaluation so that it is more of value to the criminal legal process than of medical curiosity. Timing and accurate documentation of the medical examination results need to be evaluated and interpreted case by case in the medical statement taking into consideration the disclosure of CSA, the possibility of healing and differential diagnostics of a physical finding.

The attempt to evaluate genital injury prevalence in consensual sexual intercourse and non-consensual sexual intercourse or to scale the severity of the injuries only tells us the amount of the force used in the sexual contact. It is a well-documented fact that the presence or absence of injury does not reveal if the actual crime took place or not. Injuries which resulted from sexual assault or accidental trauma may look similar. The physical injury healing process follows the exact course of natural laws no matter what caused it.

Following consensual sexual intercourse or after non-consensual sexual intercourse a significant number of cases involve only minor injuries or no injuries at all, and therefore no statistical analysis of physical evidence will reveal who has been a victim of a sexual crime. The timing and accurate documentation of the medical examination results need to be evaluated and interpreted case by case in the medical statement considering the disclosure of CSA and differential diagnostics according to the physical findings.

9 Acknowledgements

This study was carried out at the Department of Forensic Medicine, University of Tampere, Departments of Obstetrics and Gynecology and Child Psychiatry, Pirkanmaa District Hospital and in close collaboration with Research Unit of Police College of Finland, Tampere, Finland. This study was financially supported by the Competitive State Research Financing of the Expert Responsibility area of Tampere University Hospital (*Grant number 9S013*), Clinical research funding of Tampere University Hospital and The Scientific Foundation of the City of Tampere.

I wish to express my sincere gratitude to my supervisors for their valuable and encouraging academic guidance. I want to thank Professor of Forensic Medicine Pekka Karhunen, my main supervisor, for his enthusiastic attitude to my suggestion to this work, for guiding me in the field of clinical forensics and challenging me in discussions. He supported me through difficult times in the work. His positive attitude enabled this work and his expertise was invaluable to me. Secondly I want to thank Professor Pentti K. Heinonen for introducing me to the scientific writing, for being straight, honest, and supportive in the feedback, and for your discreet guidance. I want to thank you for your consultations and teaching, especially on the field of pediatric and adolescent gynecologic treatment and surgery. I highly respect your expertise.

I want to express my appreciation to the official reviewers of this thesis, Professor Annie Vesterby Charles, M.D, PhD, for your positive feedback and Docent Dan Apter, for your careful review and your constructive criticism.

I sincerely thank Pauliina Hiltunen, M.D, PhD. and Katja Ahinko, M.D, PhD, for serving on the supervisory committee of this thesis.

I want to thank my co-authors for their contribution to the original articles. I want to express a special gratitude to Mervi Seppänen and Sari Tuomisto, M.Sc, PhD, for their invaluable practical help during the medical evidence collection and for your forensic laboratory expertise. I want to thank crime scene investigator Aki Salonen for introducing me the UV-light, teaching me to photograph in dark with Uv-light and your encouraging collaboration. I am truly thankful for Docent Noora Ellonen for your friendship, expertise and critical advices. I sincerely thank Jenni Niemi, MSocSc, for your active and precise collaboration. I own a gratitude to Heini Huhtala, M.Sc, for your valuable statistical advices and for helping me on the statistical analysis. I warmly thank biomedical laboratory scientist Arja Ahola for your help in this work. Also I want to thank Juha Rainio, PhD, for your input.

I want to sincerely thank former head of the Department of Child Psychiatry Pälvi Kaukonen , former head of the Department of Obstetrics and Gynecology Eija Tomas, head of the Department of Child Psychiatry Kaija Puura and former head of the Department of Obstetrics and Gynecology Kari Nieminen for your support throughout these years. I want to thank also the staff of Gynecology Outpatient Clinic for your practical help during the study material collection years. I warmly thank all my present and former colleagues at the Departments of Obstetrics and Gynecology, Pediatrics and Child Psychiatry.

I want to cordially thank all the participants in the studies. Without your contribution to attend to the evidence collection in studies II-IV it would not have been possible to do this work. Great acknowledgement is paid to all the child victims of alleged sexual crime. I warmly thank Finnish Crime Laboratory, police and juridical instanced for your collaboration.

I want to deeply thank Taina Arvola, M.D, PhD, for your careful and constructive unofficial remarks and criticism on this thesis. Thank you for taking me to the long walks in the forest and for being an understanding ear to hear the things of similar life experiences through the difficult years. You have been amazing and caring friend.

I profoundly thank Annlis Söderholm M.D, PhD, for your enthusiastic support and guidance in this difficult field of child maltreatment. I want to thank Saila Piippo, M.D, PhD, and Docent Hanna-Liisa Lenko for introducing me to the field of pediatric and adolescent gynecology. I thank Maria Sumia, M.D, Docent Laure Morin-Papunen and Docent Satu Kivitie-Kallio for being excellent colleagues in the field of child maltreatment. I want to thank Docent Pirjo Anttila and the team of Finnish Child Advocacy Center pilot for your supportive attitude.

I dearly appreciate my colleagues Elina Suikki, M.D, Erja Lagertedt, M.D and Mika Martiskainen, M.D, and my long-term, effective, trustworthy specialist nurse Liisa Perko for your warm friendship, understanding, collaboration and support. Without your help I would have not have this work done. I want to thank the whole somatic working group for the positive working environment.

I want to thank Docent Ilona Luoma along with the former and present Forensic Interviewing Working Group Kirsi Kakko, M.D, Teija Hyytiäinen, M.D, Maria Peltola, M.D, psychologists Tiina Väkiparta, Katri Tala, Miia Summanen, Johannes Huilla, and Marika Jaarto, social workers Tiina Civil and Essi Julin, nurses Mervi Sinisalo and Katri Veilamo, secretaries Marja Raitio, Tuula Vuorinen and Päivi Määttä for your support and encouragement in my work.

I want to thank Anne-Mari Borg, M.D, PhD, for supporting me with the practicalities. I enjoyed the talks with you and sharing the excitement.

I want to thank all my friends for your friendship. I want to acknowledge all my friends in faith, thank you for your prayers, and my dear old friend Marja-Leena Rinkineva for always supporting me.

My heartfelt thanks go to Tuuli Vuolteenaho and her family. I thank my great mother in law Anja Joki-Erkkilä for your positive attitude. I want to thank Tammar Al-Nassar and Reetta Airaksinen for assisting me in so many ways during these years.

I am grateful to my mother Ritva Vasama for your love and caring, and my late father for his encouragement. I want to express my gratitude to my sisters Tiina Mattila, Kaija Vasama and my brother Juha Vasama and your families. I highly appreciate your friendship, honesty and presence during the good and difficult times. Thank you.

I profoundly thank Veli-Pekka for being my dear husband of 27 years. Thank you for your everlasting love, guidance, care and support. It is so good to be with you. I love it now that subjects for communication never end. I feel a great gratitude for having four lovely children. I thank you Veikka, Saara and Venla for your altruistic love, for being there and for caring. You are so important to me. I love you all! Also I want to thank our dear daughter Laura in heaven. She guided me with the important things in life, and supported me to continue in this difficult and hard field by once saying to me “Mom, I am so proud of the work you’re doing”. I miss you so.

Finally, I want to thank our Almighty God for giving me guidance and wisdom to write the theses. I am much obliged to you for carrying me through the hard times and lifting me up from the darkness to the light. I glorify your name for giving me the hope of eternal life!

10 References

Adams JA, Ahmad M, Phillips P (1988): Anogenital findings and hymenal diameter in children referred for sexual abuse examination. *Adol Pediatr Gynecol* 1:123-127.

Adams JA, Harper K, Knudson S, Revilla J (1994): Examination findings in legally confirmed child sexual abuse. It's normal to be normal. *Pediatrics* 94:310-317.

Adams JA, Knudson S (1996): Genital findings in adolescent girls referred for suspected child abuse. *Arch Pediatr Adolesc Med* 150:850-857.

Adams JA, Girardin B, Faugno D (2000): Signs of genital trauma in adolescent rape victims examined acutely. *J Pediatr Adolesc Gynecol* 13:88.

Adams JA, Girardin B, Faugno D (2001): Adolescent sexual assault: Documentation of acute injuries using photo-colposcopy. *J Pediatr Adolesc Gynecol* 14:175-180.

Adams JA, Botash AS, Kellogg N (2004): Differences in hymenal morphology between adolescent girls with and without a history of consensual sexual intercourse. *Arch Pediatr Adolesc Med* 158:280-285.

Adams JA, Kaplan RA, Starling SP, Mehta NH, Finkel MA, Botash AS, Kellogg ND, Shapiro R.A (2007): Guidelines for medical care of children who may have been sexually abused, *J Pediatr Adolesc Gynecol* 20:163-172.

Adams JA (2008): Guidelines for medical care of children evaluated for suspected sexual abuse: an update for 2008. *Curr Opin Obstet Gynecol* 20:435-441.

Adams JA (2011): Medical evaluation of suspected child sexual abuse: 2011 update. *J Child Sex Abus* 20:588-605.

Adams JA, Starling SP, Frasier LD, Palusci VJ, Shapiro RA, Finkel MA, Botash AS (2012): Diagnostic accuracy in child sexual abuse medical evaluation: Role of experience, training, and expert case review. *Child Abuse Negl* 36:383-392.

Allard J (1997): The collection of data from findings in cases of sexual assault and the significance of spermatozoa on vaginal, anal and oral swabs. *Sci Justice* 37:99-108.

American Professional Society on the Abuse of Children (1998): Glossary of terms and the interpretations of findings for child sexual abuse evidentiary examinations. Chicago. American Professional Society on the Abuse of Children.

- Anderson S, McClain N, Riviello RJ (2006): Genital findings of women after consensual and non-consensual intercourse, *J Forensic Nurs* 2:59–65.
- Anderson S, Parker B, Bourguignon C (2008): Changes in genital injury patterns over time in women after consensual intercourse. *J Forensic Leg Med.* 15:306–311.
- Anderst J, Kellogg N, Jung I (2009): Reports of repetitive penile-genital penetration often have no definitive evidence of penetration. *Pediatrics* 124:e403-409.
- Astrup BS, Ravn P, Lauritsen J, Thomsen JL (2012ba): Nature, frequency and duration of genital lesions after consensual sexual intercourse—Implications for legal proceedings. *Forensic Sci Int* 219:50–56.
- Astrup BS, Thomsen JL, Lauritsen J, Ravn P (2012ab): Detection of spermatozoa following consensual sexual intercourse. *Forensic Sci Int* 221:137-141.
- Astrup BS, Ravn P, Thomsen JL, Lauritsen J (2013): Patterned genital injury in cases of rape - A case-control study. *J Forensic Leg Med* 20:525-529.
- Avegno J, Mills TJ, Mills LD (2009): Sexual victims in the emergency department: Analysis by demographic and event characteristics. *J Emerg Med* 37:328-334.
- Barsley RE, West MH, Fair JA (1990): Forensic photography. Ultraviolet imaging of wounds on skin. *Am J Forensic Med Pathol* 11:300–308.
- Berenson AB, Heger AH, Hayes JM, Bailey RK, Emans SJ (1992): Appearance of the hymen in prepubertal girls. *Pediatrics* 89:387-394.
- Berenson AB (1993a): Appearance of the hymen at birth and one year of age: a longitudinal study. *Pediatrics* 91:820-825.
- Berenson AB, Somma-Garcia A, Barnett S (1993b): Perianal findings in infants 18 months of age or younger. *Pediatrics* 91:838-840.
- Berenson AB (1994): The prepubertal genital exam: what is normal and abnormal. *Curr Opin Obstet Gynecol* 6:526-530.
- Berenson AB, Chacko MR, Wiemann CM, Mishaw CO, Friedrich WN, Grady JJ (2000): A case-control study of anatomic changes which resulting from sexual abuse. *Am J Obstet Gynecol* 182:820-834.
- Berenson AB, Chacko MR, Wiemann CM, Mishaw CO, Friedrich WN, Grady JJ (2002): Use of hymenal measurements in the diagnosis of previous penetration. *Pediatrics* 109:228-235.
- Berenson AB, Grady JJ (2002): A longitudinal study of hymenal development from 3 to 9 years of age. *J Pediatr* 140:600-607.

- Berkoff MC, Zolotor AJ, Makaroff KL, Thackery JD, Shapiro RA, Runyan DK (2008): Has This Prepubertal Girl Been Sexually Abused? *JAMA* 300: 2779-2792.
- Berkowitz CD, Elvik SL, Logan M (1987): A simulated “acquired” imperforate hymen following the genital trauma of sexual abuse. *Clin Pediatr* 26:307-309.
- Berkowitz CD (2011): Healing of Genital Injuries. *J Child Sex Abus* 20:537–547.
- Boyle C, McCann J, Miyamoto S, Rogers K (2008): Comparison of examination methods used in the evaluation of prepubertal and pubertal female genitalia: a descriptive study. *Child Abuse Negl* 32:229-243.
- Boos SC (1999): Accidental hymenal injury mimicking sexual trauma. *Pediatrics* 103:1287-1290.
- Boos SC, Rosas AJ, Boyle C, McCann J (2003): Anogenital injuries in child pedestrians run over by low-speed motor vehicles: Four cases with findings that mimic child sexual abuse. *Pediatrics* 112:e77-e84.
- Brandt P, Brusila P, Cacciatore R, Raijas R, Söderholm A-L, Vala U (2010): RAP—Acute help for victims of rape-guidebook: Examination and treatment of sexual assault in healthcare [Finnish]. Available at: http://www.vaestoliitto.fi/seksuaalisuus/tietoa-seksuaalisuudesta/ammattilaiset/tyokalupakki/valineita_nuoren_kohtaamiseen/rap-kasikirja/
- Bruni M (2003): Anal findings in sexual abuse of children (A descriptive study). *J Forensic Sci* 48:1343-1346.
- Bustin SA, Benes V, Garson JA, Hellemans J, Huggett J, Kubista M, Mueller R, Nolan T, Pfaffl MW, Shipley GL, Vandesompele J, Wittner CT (2009): The MIQE guidelines: Minimum information for publication of quantitative real-time PCR experiments. *Clin Chem* 55:611-622.
- Cahill LL (2004): Adolescent sexual assault: timing of physical exam, exam findings, prior sexual history, and legal outcome. Spokane, WA: Gonzaga University, US.
- Carter-Snell C, Soltys K (2005): Forensic ultraviolet lights in clinical practice: Evidence for the evidence. *Canadian Journal of Police & Security Services* 3:79-85.
- Cartwright PS, Moore RA, Anderson JR, Brown DH (1986). Genital injury and implied consent to alleged rape. *J Reprod Med* 31:1043-1344.
- Christian CW, Lavelle JM, De Jong AR, Loiselle J, Brenner L, Joffe M (2000): Forensic evidence findings in prepubertal victims of sexual assault. *Pediatrics* 106:100-104.
- Christian CW (2011): Timing of the medical examination. *J Child Sex Abus* 20:505-520.
- Committee on Medical Liability and Risk Management (2009): Expert witness participation in civil and criminal proceedings. *Pediatrics* 124:428-438.
- Cross TP, de Vos E, Whitcomb D (1994): Prosecution of child sexual abuse: which cases are accepted? *Child Abuse Negl* 19:1431-1442.

- Davies A, Wilson E (1974): Persistence of seminal constituents in human vagina. *Forensic Sci* 3:45-55.
- Dahlke MB, Cooke C, Cunnane M, Chawla J, Lau P(1977): Identification of semen in 5000 patients seen because of rape. *Am J Pathol* 68:740-746.
- De Jong AR, Rose M (1991): Legal proof of child sexual abuse in the absence of physical evidence. *Pediatrics* 88:506-511.
- De Jong AR (2011): The medical evaluation of acute sexual abuse or assault in children and adolescents. In: *Medical response to child sexual abuse. A resource for professionals working with children and families*. STM Learning, Inc, pp. 213-249. Eds. Kaplan R, Adams JA, Starling SP, Giardino AP, Saint Louis, MI, USA.
- DeLago C, Deblinger E, Schroeder C, Finkel A (2008): Girls who disclose sexual abuse: urogenital symptoms and signs after genital contact. *Pediatrics* 122:e281-e286.
- Delfin FC, Madrid BJ, Tan MP, De Ungria MC (2005): Y-STR analysis for detection and objective confirmation of child sexual abuse. *Int J Legal Med* 119:158-163.
- Du Mont J, Parnis D (2000): Sexual assault and legal resolution: Querying the medical collection of forensic evidence. *Med Law* 19:779-792.
- Du Mont J, White D (2007): *The uses and impacts of medico-legal evidence in sexual assault cases: A global review*. Geneva. World Health Organization.
- Edelson MG, Joa D (2010): Differences in legal outcomes for male and female children who have been sexually abused. *Sex Abuse* 22:427-442.
- Edgardh K, von Krogh G, Ormstad K (1999): Adolescent girls investigated for sexual abuse: history, physical findings and legal outcome. *Forensic Sci Int* 104:1-15.
- Edinburgh L, Pape-Blabolil J, Harpin SB, Saewyc E (2014): Multiple perpetrator rape among girls evaluated at a hospital-based Child Advocacy Center: Seven years of reviewed cases. *Child Abuse Negl* 38:1540-1551.
- Ellonen N (2010): Reporting violence and child sexual abuse [Finnish], in: S-M. Humppi, N. Ellonen (Eds.), *Child Abuse and Sexual Abuse. Case Recognition, Criminal Process and Multidisciplinary Collaboration*. Police College of Tampere Research 40, Juvenes Print, pp. 88–168.
- Ellonen N (2013): *Criminal investigation on physical and sexual abuse against children [Finnish]*. Police College of Tampere Textbook 20, Tampereen Yliopistopaino- Juvenes Print. Tampere.
- Emans SJ, Woods ER, Allred EN, Grace E (1994): Hymenal findings in adolescent women: Impact of tampon use and consensual sexual activity. *J Pediatr* 125:153–160.
- Ernst AA, Green E, Ferguson MT, Weiss SJ, Green WM (2000): The utility of anoscopy and colposcopy in the evaluation of male sexual assault victims. *Ann Emerg Med* 36:432-437.

Ernst E (2009): Evaluation of image quality of digital photo documentation of female genital injuries after sexual assault. Cleveland, OH: College of Nursing, Case Western Reserve University.

Everette RB, Jimerson GK (1977): The rape victim: A review of 117 consecutive cases. *Obstet Gynecol* 50:88-90.

Fagerlund M, Peltola M, Kääriäinen J, Ellonen N, Sariola H (2014): Finnish child victim survey 2013 [Finnish]. Police College of Tampere Research 110, Juvenes Print, Tampere.

Ferrel J (1995): Foley catheter balloon technique for visualizing the hymen in female adolescent sexual assault victims. *J Emerg Nurs* 21:585-586.

Finkel MA (1989): Anogenital trauma in sexually abused children. *Pediatrics* 84:317-322.

Finkel MA, Alexander RA (2011): Conducting the Medical History, *J Child Sex Abus*, 20:486-504.

Finkel MA (2011): Putting it all together. *J Child Sex Abus* 20:643-656.

Finnish Medical Association (3.12.2013). Writing medical reports. [Finnish]. <http://www.laakariliitto.fi/edunvalvonta-tyoelama/liiton-ohjeet/laakarintodistus/>

Finnish Crime Laboratory (2011): Instructions for sexual crime related pregnancy material procedure. [Finnish].

Frioux S, Blinman T, Christian CW (2011): Vaginal lacerations from consensual intercourse in adolescents. *Child Abuse Negl* 35:69-73.

Gavril AR., Kellogg ND, Nair P (2012) Value of Follow-up Examinations of Children and Adolescents Evaluated for Sexual Abuse and Assault. *Pediatrics* 129:282.

Girardet R, Bolton K, Lahoti S, Mowbray H, Giardino A, Isaac R, Arnold W, Mead B, Paes N (2011): Collection of forensic evidence from pediatric victims of sexual assault. *Pediatrics* 128:233-238.

Golden GS (1994): Use of alternative light source illumination in bite mark photography. *J Forensic Sci* 39:815-823.

Goodyear-Smith FA, Tannis M, Laidlaw TM (1998): Can tampon use cause hymen changes in girls who have not had sexual intercourse? A review of the literature. *Forensic Sci Int* 94:147-153.

Gray-Eurom K, Seaberg D, Wears R (2002): The prosecution of sexual assault cases: correlation with forensic evidence. *Ann Emerg Med* 39:39-46.

Grossin C, Sibille I, Lorin dela Maison G, Banasr A, Brion F, Durigon M (2003): Analysis of 418 cases of sexual assault. *Forensic Sci Int* 131:125-130.

- Hagemann CT, Stene LE, Myhre AK, Ormstad K, Schei B (2011): Impact of medico-legal findings on charge filing in cases of rape in adult women. *Acta Obst Gynecol Scand* 90:1218-1224.
- Hagemann CT (2014): Medical findings and legal outcome among postpubertal women attending the Sexual Assault Centre at St. Olavs Hospital, Trondheim, Norway. A record-based study. Norwegian University of Science and Technology. Trondheim, Norway.
- Halbert DR, Jones DE (1978): Medical management of the sexually assaulted woman. *J Reprod Med* 20:265-274.
- Hansell P, Lunnon RJ (1984): Ultraviolet and fluorescence recording, in: R.A. Morton (Ed.), *Photography for the Scientist*, second ed., Academic Press, London, pp. 321–354.
- Hansen LA, Mikkelsen SJ, Sabroe S, Vesterby Charles A (2010): Medical findings and legal outcome in sexually abused children. *J Forensic Sci* 55:104.
- Hayman C, Lanza C, Fuentes R, Algor K (1972): Rape in the district of Columbia. *Am J Obstet Gynecol* 113:91-97.
- Heger A, Ticson L, Velasquez O, Bernier R (2002a): Children referred for possible sexual abuse: medical findings in 2384 children. *Child Abuse Negl* 26:645-659.
- Heger AH, Ticson L, Guerra L, Lister J, Toni Zaragoza T, McConnell G, Morahan M (2002b): Appearance of the genitalia in girls selected for non-abuse: Review of hymenal morphology and nonspecific findings. *J Pediatr Adolesc Gynecol* 15:27-35.
- Hellerud BB, Bouzga M, Hoff-Olsen P, Megåv B (2011): Semen detection: A retrospective overview from 2010. *Forensic Sci Int* 3:e391.e392.
- Helweg-Larsen K (1985): The value of the medico-legal examination in sexual offences. *Forensic Sci Int* 27:145-155.
- Heppenstall-Heger A, McConnell G, Ticson L, Guerra L, Lister J, Zaragoza T (2003): Healing patterns in anogenital injuries: a longitudinal study of injuries associated with sexual abuse, accidental injuries, or genital surgery in the preadolescent child. *Pediatrics* 112:829-837.
- Hilden M, Schei B, Sidenius K (2005): Genitoanal injury in adult female victims of sexual assault. *Forensic Sci Int* 154: 200–205.
- Hirvelä P (2006): *Criminal process in sexual crimes against children* [Finnish]. WSOY, Vantaa.
- Hobbs CJ, Wynne JM (1989): Sexual abuse in English boys and girls: the importance of the anal examination. *Child Abuse Negl* 13:195-210.
- Hobbs CJ (2012): Physical evidence of child sexual abuse. *Eur J Pediatr* 171:751-757.

- Hobbs CJ, Wright CM (2014): Anal signs of child sexual abuse: a case-control study. *BMC Pediatrics* 14:128
- Hochmeister MN, Whelan M, Borer UV, et al. (1997): Effects of toluidine blue and destaining reagents used in sexual assault examinations on the ability to obtain DNA profiles from postcoital vaginal swabs. *J Forensic Sci* 42: 316–319.
- Hoffman RJ, Ganti S (2001): Vaginal laceration and perforation resulting from first coitus. *Pediatr Emerg Care* 17:113-114.
- Holmes MM, Resnick HS, Kilpatrick DG, Best CL (1996): Rape-related pregnancy: estimates and descriptive characteristics from a national sample of women. *Am J Obstet Gynecol* 175:320.325.
- Hornor G (2009): Common Conditions That Mimic Findings of Sexual Abuse. *J Pediatr Health Care* 23:283-288.
- Hornor (2010): A normal anogenital exam: sexual abuse or not? *J Pediatr Health Care* 24:145-151.
- Ingemann-Hansen O, Brink O, Sabroe S, Sorensen V, Vesterby Charles A (2008): Legal aspects of sexual violence – Does forensic evidence make a difference? *Forensic Sci Int* 180:98-104.
- Ingemann-Hansen O, Charles AV (2013): Forensic medical examination of adolescent and adult victims of sexual violence. *Best Pract Res Clin Obstet Gynaecol* 27:91-102.
- Ingram DM, Everett VD, Ingram DL (2001): The relationship between the transverse hymenal orifice diameter by the separation technique and other possible markers of sexual abuse. *Child Abuse Negl* 25:1109-1120.
- Janis JE, Kwon RK, Lalonde DH (2010): A practical guide to wound healing. *Plast Reconstr Surg* 125:230e.
- Jewkes R, Christofides N, Vetten L, Jina R, Sigsworth R, Loots L (2009): Medicolegal findings, legal case progression, and outcomes in South-African rape cases: retrospective review. *PLoS Med* 6:1-8.
- Joki-Erkkilä M, Karikoski R, Rantala I, Lenko H-L, Visakorpi T, Heinonen PK (2002): Gonadoblastoma and dysgerminoma associated with XY gonadal dysgenesis in an adolescent with chronic renal failure: a case of Frasier syndrome. *J Pediatr Adolesc Gynecol* 15:145-149.
- Jong-Myon B (2014): The clinical decision analysis using decision tree. *Epidemiol Health*. 36: e2014025.
- Jones JG, Worthington T (2008): Genital and anal injuries requiring surgical repair in females less than 21 years of age. *J Pediatr Adolesc Gynecol* 21:207-211.
- Jones JS, Rossman L, Wynn BN, Dunnuck C, Schwrtz N (2003a): Comparative analysis of adult versus adolescent sexual assault: epidemiology and patterns of anogenital injury. *Acad Emerg Med* 10:872-877.
- Jones JS, Dunnuck C, Rossman L, Wynn BN, Genco M (2003b): Adolescent Foley catheter technique for visualizing hymenal injuries in adolescent sexual assault. *Acad Emerg Med* 10:1001-1004.

Jones JS, Rossman L, Hartman M, Alexander CC (2003bc): Anogenital injuries in adolescents after consensual sexual intercourse. *Acad Emerg Med* 10: 1378-1383.

Jones JS, Alexander C, Wynn BN, Rossman L, Dunnuck C (2009): Why women don't report sexual assault to the police: the influence of psychosocial variables and traumatic injury. *J Emerg Med* 36: 417-424.

Jänish S, Meyer H, Germerott T, Albrecht U-V, Schulz Y, Debertin AS (2010): Analysis of clinical forensic examination reports on sexual assault. *Int J Legal Med* 124:227-235.

Kadane JB (2005): Bayesian methods for health-related decision making. *Statist. Med.* 24:563-567.

Katz DF, Slade DA, Nakajima ST (1997): Analysis of pre-ovulatory changes in cervical mucus hydration and sperm penetrability. *Advances in Contraception* 13:143-151.

Kellogg ND, Parra JM, Menard SM (1998): Children with anogenital symptoms and signs referred for sexual abuse evaluations. *Arch Pediatr Adolesc Med* 153:634-641.

Kellogg ND, Menard SW, Santos A (2004): Genital anatomy in pregnant adolescents: "normal" does not mean "nothing happened". *Pediatrics* 113:e67-69.

Kellogg N, the Committee on Child Abuse and Neglect (2005): The evaluation of sexual abuse in children. *Pediatrics* 116:506-512.

Kelly DL, Larkin HJ, Cosby CD, Paolinetti LA (2013): Derivation of the Genital Injury Severity Scale (GISS): A concise instrument for description and measurement of external female genital injury after sexual intercourse. *Journal of Forensic and Legal Medicine* 20:724-731.

Kerns DL, Ritter ML (1992): Medical findings in child sexual abuse cases with perpetrator confession. *Amer J Dis Child* 146:494.

Krauss TC, Warlen SC (1985): The forensic science use of reflective ultraviolet photography. *J Forensic Sci* 30:262-268.

Laitinen FA, Grundmann O, Ernst EJ (2013): Anogenital Injury in Adolescent/Adult Sexual Assault Victims. A Review of the Forensic Literature. *Am J Forensic Med Pathol* 34:286-294.

Larkin HJ, Cosby CD, Kelly D, Paolinetti LA (2012): A pilot study to test the differential validity of genital injury severity scale, in developmental for use in forensic sexual assault examinations. *J Forensic Nursing* 8:30-38.

Lagerstedt M, Karvinen K, Joki-Erkkilä M, Huotari-Orava R, Snellman E, Laasanen SL (2013): Childhood lichen sclerosus - A challenge for clinicians. *Pediatr Dermatol* 30:444-50.

Lauber AA, Souma ML (1982): Use of toluidine blue for documentation of traumatic intercourse. *Obstet Gynecol* 60:644-648.

- Leander L (2010): Police interviews with child sexual abuse victims: Patterns of reposting, avoidance and denial. *Child Abuse Negl* 34:192-205.
- Lenahan LC, Ernst A, Johnson B (1998): Colposcopy in evaluation of the adult sexual assault victim. *Am J Emerg Med* 16:183-184.
- Leppäluoto P (1974): Vaginal flora and sperm survival. *J Reprod Med* 12:99-107.
- Lentsch KA, Johnson CF (2000): Do physicians have adequate knowledge of child sexual abuse? The results of two surveys of practicing physicians, 1986 and 1996. *Child Maltreat* 5:72-78.
- Lincoln C, Perera R, Jacobs I, Ward A (2013): Macroscopically detected female genital injury after consensual and non-consensual vaginal penetration: A prospective comparison study. *J Forensic Leg Med* 20: 884–901.
- Lindsay SP (1998): An epidemiologic study of the influence of victim age and relationship to the suspect on the results of evidentiary examinations and law enforcement outcome in cases of reported sexual assault. University of California, San Diego.
- Lynnetryp N, Hjalgrim H (1995): Routine use of ultraviolet light in medicolegal examinations to evaluate stains and skin trauma. *Med Sci Law* 35:165–168.
- Mackenzie B, Jenny C (2014): The use of alternate light sources in the clinical evaluation of child abuse and sexual assault. *Pediatr Emerg Care* 30:207-210.
- Maguire W, Goodall E, Moore T (2009): Injury in adult female sexual assault complainants and related factors. *Eur J Obstet Gynecol Reprod Biol.* 142: 149–153.
- Maiquilla SMB, Salvador JM, Calacal GC, Sagum MS, Dalet MRM, Delfin FC, Tabbda KA, Franco SAE, Pergidon HB, Madrid BJ, Tan MP, De Ungria MCA (2011): Y-STR DNA analysis of 154 female child sexual abuse assault cases in the Philippines. *Int J Legal Med* 125:817-824.
- McCann J, Voris J, Simon M, Wells R (1990a): Comparison of genital examination techniques in prepubertal girls. *Pediatrics* 85:182-187.
- McCann J, Wells R, Simon M, Voris J (1990b): Genital findings in prepubertal girls selected for nonabuse: a descriptive study. *Pediatrics* 86:428-439.
- McCann J, Voris J (1993): Perianal injuries resulting from sexual abuse. A longitudinal study. *Pediatrics* 91:390-397.
- McCann J (1998): The appearance of acute, healing and healed anogenital trauma. *Child Abuse Negl* 22:605-615.
- McCann J, Miyamoto S, Boyle C, Rogers K (2007a): Healing of hymenal injuries in prepubertal and adolescent girls: a descriptive study. *Pediatrics* 119:e1094-10106.

- McCann J, Miyamoto S, Boyle C, Rogers K (2007b): Healing of nonhymenal genital injuries in prepubertal and adolescent girls: a descriptive study. *Pediatrics* 120:1000-1011.
- McCauley J, Gorman R, Gusinski G (1986): Toluidine blue in the detection of perineal lacerations in pediatric and adolescent sexual abuse victims. *Pediatrics* 78:1039-1042.
- McCauley J, Gusinski G, Welch R (1987): Toluidine blue in the corroboration of rape in the adult victim, *Am J Emerg Med* 5:105–108.
- McGee DL. (2010): Clinical decision making. *Merck Manual* 2nd Edition.
- McGreal S, Wood P (2013): Recurrent vaginal discharge in children. *J Pediatr Adolesc Gynecol* 26:205-208.
- McGregor MJ, Le G, Marion SA, Wiebe E (1999): Examination for sexual assault: Is the documentation of physical injury associated with the laying of charges? A retrospective cohort study. *CMAJ* 160:1565-1569.
- McGregor MJ, Du Mont J, Myhr TL (2002): Sexual Assault Forensic Medical Examination: Is Evidence Related to Successful Prosecution? *Ann Emerg Med* 39:639-647.
- McLean I, Roberts SA, White C, Paul S (2011): Female genital injuries resulting from consensual and non-consensual vaginal intercourse. *Forensic Sci Int* 204:27–33.
- Merritt DF (1998): Evaluation of vaginal bleeding in the preadolescent child. *Semin Pediatr Surg* 7:35-42.
- Mian M, Schryer CF, Spafford M, Joosten J, Lingard L (2009): Current practice in physical child abuse forensic reports: a preliminary exploitation. *Child Abuse Negl* 33:679-683.
- Morrison AI (1972): Persistence of spermatozoa in vagina and cervix. *Br J Vener Dis* 48:141.
- Muram D (1989a): Child sexual abuse: relationship between sexual acts and genital findings. *Child Abuse Negl* 13:211-216.
- Muram D (1989b): Anal and perianal abnormalities in prepubertal victims of sexual abuse. *Am J Obstet Gynecol* 161:273-281.
- Muram D, Gale CL (1990): Acquired vaginal occlusion. *Adolesc Pediatr Gynecol* 3:141-145.
- Muram D, Arheart KL, Jennings SG (1999): Diagnostic accuracy of colposcopic photographs in child sexual abuse evaluations. *J Pediatr Adolesc Gynecol* 12:58-61.
- Muram D, Simmons KJ (2008): Pattern recognition in pediatric and adolescent gynecology – a case for formal education. *J Pediatr Adolesc Gynecol* 21:103-108.
- Myhre AK, Bemtzen K, Bratlid D (2001): Perianal anatomy in non-abused preschool children. *Acta Paediatr* 90:1321-1328.

- Myhre AK, Berntzen K, Bratlid D. (2003): Genital anatomy in non-abused preschool girls. *Acta Paediatr* 92:1453-1462.
- Myhre AK, Myklestad K, Adams JA (2010): Changes in genital anatomy and microbiology in girls between age 6 and age 12 years: a longitudinal study. *J Pediatr Adolesc Gynecol* 23:77-85.
- Myhre AK, Adams JA, Kaufhold M, Davis JL, Suresh P, Kuelbs CL (2013): Anal findings in children with and without probable anal penetration: a retrospective study of 1115 children referred for suspected sexual abuse. *Child Abuse Negl* 37:465-474.
- National Institute for Health and Welfare (2014): School health promotion study [Finnish]. <https://www.thl.fi/fi/web/thlfi-en/research-and-expertwork/population-studies/school-health-promotion-study>.
- Nelson DG, Santucci KA (2002): An alternative light source to detect semen. *Acad Emerg Med* 9:1045-1048.
- Nesvold H, Ormstad K, Friis S (2011): To be used or not to be used, that's the question: Legal use of forensic and clinical information collected in a self-referral sexual assault centre. *J Forensic Sci* 56:1156-1162.
- Noll JG, Shenk CE, Putnam KT (2009): Childhood Sexual Abuse and Adolescent Pregnancy: A Meta-analytic Update. *J Pediatr Psychol* 34: 366–378.
- Norvell MK, Benrubi GI, Thompson RJ (1984): Investigation of microtrauma after sexual intercourse. *J Reprod Med* 29:269–271.
- Palusci VJ, Cox EO, Cyrus TA, Heartwell SW, Vandervort FE, Pott ES (1999): Medical assessment and legal outcome in child sexual abuse. *Arch Ped Adol Med* 153:388-392.
- Palusci VJ, Cox EO, Shatz EM, Schultze JM (2006): Urgent medical assessment after child sexual abuse. *Child Abuse Negl* 30:367-380.
- Paradise JE (1990): The medical evaluation of the sexually abused child. *Pediatr Clin North Am* 37:839-862.
- Penttilä A, Karhunen PJ (1990): Medicolegal findings among rape victims. *Med Law* 9:725-737.
- Pierce AM (2004): Anal fissures and anal scars in anal abuse – are they significant? *Pediatr Surg Int* 20:334-338.
- Piippo S, Lenko H, Vuento R (2000): Vulvar symptoms in paediatric and adolescent patients. *Acta Paediatr* 89:431-435.
- Pillai M (2007): An evaluation of 'confirmatory' medical opinion given to English courts in 14 cases of alleged child sexual abuse. *J Forensic Leg Med* 14:503-514.
- Pillai M (2008): Genital findings in prepubertal girls: what can be concluded from an examination? *J Pediatr Adolesc Gynecol* 21:177-185.

- Price J (2013): Injuries in prepubertal and pubertal girls. *Best Pract Res Clin Obstet Gynaecol* 27:131-139.
- Ranbow B, Adkinson C, Frost TH, Peterson GF (1992): Female sexual assault: medical and legal implications. *Ann Emerg Med* 21:727-731.
- Randall B (1987): Persistence of vaginal spermatozoa as assessed by routine cervicovaginal (PAP) smears. *J Forensic Sci* 32:678-683.
- Reinhart MA (1987): Sexually abused boys. *Child Abuse Negl* 11:229-235.
- Riggs N, Houry D, Long G, Markovchick V, Feldhaus KM (2000): Analysis of 1,076 cases of sexual assault. *Ann Emerg Med* 35:358-362.
- Roa PN, Collins KA, Geisinger KR, Parsons LH, Schnell S, Hayworth-Hodge R, Tap MP, Lantz PE, Pettenati MJ (1995): Identification of male epithelial cells in routine postcoital cervicovaginal smears using fluorescence in situ hybridization. Application in sexual assault and molestation. *Am J Clin Pathol* 104:32-35.
- Royal College of Paediatrics and Child Health (RCPCH) (2008): *The physical signs of child sexual abuse: An evidence-based review and guidance for best practice*, first ed. London, UK.
- The Royal College of Paediatrics and Child Health and Faculty of Forensic and Legal Medicine (2012). Available at: www.rcpch.ac.uk.
- Ryynänen OP (2009): Bayesian theorem while working with patients [Finnish]. *Duodecim* 125:483-485.
- Saint-Martin P, Bouyssy M, O'Byrne P (2007): Analysis of 756 cases of sexual assault in Tours (France): medico-legal findings and judicial outcomes. *Med Sci Law* 47:315-324.
- Schei B, Muus KM, Moen MH (1995): Medidinske og rettslige aspekter av voldtekt. Hendelser til voldsteksteamet ved Regionsykehuset I Trondheim I perioden 1989-92. [Norwegian]. *Tidsskr Nor Laegeforen* 115:30-33.
- Sibille I, Duverneuil C, Lorin de la Grandmaison G, Guerrouache K, Teissiere F, Durigon M, de Mazancourt P (2002): Y-STR DNA amplification as biological evidence in sexually assaulted female victims with no cytological detection of spermatozoa. *Forensic Sci Int* 125:212e6.
- Silverman EM, Silverman AG (1978): Persistence of spermatozoa in lower genital tracts of women. *J Am Med Assoc* 240:1875-1877.
- Skellern C, Donald T (2012): Defining standards for medico-legal reports in forensic evaluation of suspicious childhood injury. *J Forensic Legal Med* 19:267-271.
- Slaughter L, Brown C (1992): Colposcopy to establish physical findings in rape victims. *Am J Obstet Gynecol* 166:83-86.

Slaughter L, Brown CR, Crowley S, Peck R (1997): Patterns of genital injury in female sexual assault victims, *Am J Obstet Gynecol* 176:609–616.

Smith DA, Webb L., Fennel A, Nathan E, Bassindale C, Phillips M (2014): Early evidence kits in sexual assault: an observational study of spermatozoa detection in urine and other forensic specimen. *Forensic Sci Med Pathol* 10:336-343.

Sommers MS (2007): Defining patterns of genital injury from sexual assault: a review. *Trauma Violence Abuse* 8:270–280.

Sommers MS, Zink TM, Fargo JD, Baker RB, Buscur C, Shamley-Ebron DZ, Fisher BS (2008): Forensic sexual assault examination and genital injury: a skin colour or source of health disparity? *Am J Emerg Med* 26:857-866.

Sommers MS, Brunner LS, Brown KM, Buschur C, Everett JS, Fargo JD, Fisher BS, Hinkle C, Zink TM (2012): Injuries from intimate partner and sexual violence: Significance and classification system. *J Forensic Leg Med* 19:250-263.

Starling SP, Jenny C (1997): Forensic examination of adolescent female genitalia: The Foley catheter technique. *Arch Pediatr Adolesc Med* 151:102-103.

Starling SP, Frasier LD, Jarvis K, McDonald A (2013): Inter-rater reliability in child sexual abuse diagnosis among expert reviewers. *Child Abuse Negl* 37:456-464.

Stene LE, Ormstad K, Schei B (2010): Implementation of medical examination and forensic analyses in the investigation of sexual assaults against adult women: A retrospective study of police files and medical journals. *Forensic Sci Int* 199:79-84.

Sugar NF, Fine DN, Eckert LO (2004): Physical injury after sexual assault: Findings of a large case series. *Am J Obstet Gynecol* 190:71-76.

Sugue-Castillo M (2009): Legal outcomes of sexually abused children evaluated at the Philippine General Hospital Child Protection Unit. *Child Abuse Negl* 33:193-202.

Texeira WRG (1981): Hymenal colposcopic sexual offences. *Am J Forensic Med Pathol* 2:209-215.

Thackeray JD, Hornor G, Benzinger EA, Scribano PV (2011): Forensic evidence collection and DNA identification in acute child sexual assault. *Pediatrics* 128:227-232.

Tintinalli JE, Hoelzer (1985): Clinical findings and legal resolution in sexual assault. *Ann Emerg Med* 14:447-453.

United Nations (1989): The United Nations Convention on the rights of the child. Treaty Series 60/1991.

United Nations (2008): United Nations Security Council Resolutions 1820.

- US Department of Justice (2004): A national protocol for sexual assault medical forensic examinations: adults/adolescents. Washington, DC. Office of Violence Against Women.
- Usifo F, Sharma R, Macrae R, Hargreaves C, Swinhoe JR (2006): Posterior vaginal fornix rupture and haemoperitoneum following sexual intercourse. *J Obstet Gynecol* 26:482-483.
- Walsh WA, Jones LM, Cross TP, Lippert T (2010): Prosecuting child sexual abuse: The importance of evidence type. *Crime Delinq* 56:436-454.
- Watkeys JM, Price LD, Upton PM, Maddocks A (2008): The timing of medical examination following an allegation of sexual abuse: Is this emergency? *Arch Dis Child* 93:851-856.
- Wells DL (2006): Sexual assault practice: Myths and mistakes. *J Clin Forensic Med* 13:189-193.
- White C, McLean I (2006): Adolescent complainants of sexual assault: injury patterns in virgin and non-virgin groups. *J Clin Forensic Med* 13:172-180.
- World Health Organization (1999): WHO laboratory manual for the examination of human semen and sperm-cervical mucus interaction. 4th ed. Cambridge University Press and the World Health Organization.
- World Health Organization (2010): WHO laboratory manual for the examination and processing of human semen. 5th ed. The World Health Organization, Geneva, Switzerland.
- World Health Organization (WHO) (2012): Sexual and Reproductive Health: Sexual Violence. Available at: http://www.who.int/reproductivehealth/topics/violence/sexual_violence/en/index.html.
- Wiley J, Sugar N, Fine D, Eckert LO (2003): Legal outcomes of sexual assault. *Am J Obstet Gynecol* 188:1638-1641.
- Working group set up by the Finnish Medical Society Duodecim and the Finnish Society for Child and Adolescent Psychiatry (2013): Evaluation of a suspected child sexual abuse [Finnish]. Duodecim. Available at: http://www.terveysportti.fi/dtk/ltk/koti?p_haku=lapsen%20seksuaalisen
- www.finlex.fi
- Zink T, Fargo JD, Baker RB, Buschur C, Fisher BS, Sommers MS (2010): Comparison of methods for identifying ano-genital injury after consensual intercourse. *J Emerg Med* 39:113–118.
- Young KL, Jones JG, Worthington T, Simpson P, Casey PH (2006): Forensic laboratory evidence in sexually abused children and adolescents. *Arch Pediatr Adolesc Med* 160:585-588.

11 Original Communications

