



ANNE SALONEN

Incidence of Hospitalisation and  
Surgical Treatment of Humeral Shaft and  
Distal Humeral Fractures Among Children and  
Adolescents in Finland

Complications in Antebrachium and  
Femoral Titanium Elastic Nailing



ACADEMIC DISSERTATION

To be presented, with the permission of  
the Board of the School of Medicine of the University of Tampere,  
for public discussion in the Small Auditorium of Building M,  
Pirkanmaa Hospital District, Teiskontie 35,  
Tampere, on December 19th, 2014, at 12 o'clock.

UNIVERSITY OF TAMPERE

ANNE SALONEN

Incidence of Hospitalisation and  
Surgical Treatment of Humeral Shaft and  
Distal Humeral Fractures Among Children and  
Adolescents in Finland

Complications in Antebrachium and  
Femoral Titanium Elastic Nailing

*Acta Universitatis Tamperensis 2002*  
*Tampere University Press*  
*Tampere 2014*



TAMPEREEN  
YLIOPISTO

ACADEMIC DISSERTATION

University of Tampere, School of Medicine  
Tampere University Hospital, Pediatric surgery clinic  
Finland

*Supervised by*

Docent Olli Pajulo  
University of Turku  
Finland  
Docent Tuija Lahdes-Vasama  
University of Tampere  
Finland

*Reviewed by*

Docent Timo Hurme  
University of Turku  
Finland  
Docent Kari Vanamo  
University of Eastern Finland  
Finland

The originality of this thesis has been checked using the Turnitin OriginalityCheck service in accordance with the quality management system of the University of Tampere.

Copyright ©2014 Tampere University Press and the author

Cover design by  
Mikko Reinikka

Layout by  
Sirpa Randell

Distributor:  
kirjamynti@juvenes.fi  
<http://granum.uta.fi>

Acta Universitatis Tamperensis 2002  
ISBN 978-951-44-9650-9 (print)  
ISSN-L 1455-1616  
ISSN 1455-1616

Acta Electronica Universitatis Tamperensis 1490  
ISBN 978-951-44-9651-6 (pdf)  
ISSN 1456-954X  
<http://tampub.uta.fi>

Suomen Yliopistopaino Oy – Jjuvenes Print  
Tampere 2014



# TABLE OF CONTENTS

ABSTRACT

TIIVISTELMÄ

LIST OF ORIGINAL PUBLICATIONS

ABBREVIATIONS AND DEFINITIONS

1	INTRODUCTION .....	11
2	REVIEW OF THE LITERATURE .....	13
2.1	General aspects .....	13
2.2	Fracture healing of growing bone .....	13
2.3	Incidence and aetiology of children's fractures .....	16
2.3.1	Incidence and aetiology of humeral shaft fractures .....	18
2.3.2	Incidence and aetiology of distal humeral fractures .....	18
2.3.3	Incidence and aetiology of antebrachium shaft fractures .....	19
2.3.4	Incidence and aetiology of femoral shaft fractures .....	19
2.4	Diagnostic aspects .....	20
2.4.1	Radiographic assessment .....	20
2.4.2	Classification of long-bone diaphyseal fractures .....	20
2.4.3	Classification of distal humeral fractures .....	22
2.4.4	Classification of open fractures .....	23
2.5	Treatment modalities of extremity fractures in children and adolescents .....	24
2.5.1	Management of humeral shaft fractures .....	24
2.5.2	Management of distal humeral fractures .....	25
2.5.3	Management of diaphyseal antebrachium fractures .....	28
2.5.4	Management of femoral shaft fractures .....	30
2.6	The Finnish National Hospital Discharge Registry .....	32
3	AIMS OF THE RESEARCH .....	34

4	MATERIALS AND METHODS .....	35
4.1	Patient data .....	35
4.1.1	Study I .....	35
4.1.2	Study II .....	35
4.1.3	Study III .....	36
4.1.4	Study IV .....	36
4.2	Methods .....	36
4.2.1	Studies I and II .....	36
4.2.2	Studies III and IV .....	37
5	RESULTS .....	38
5.1	Study I .....	38
5.2	Study II .....	41
5.3	Study III .....	43
5.4	Study IV .....	44
6	DISCUSSION .....	45
6.1	Incidence of hospitalisation for humeral shaft and distal humeral fractures .....	45
6.2	Increasing incidence of operative managements in distal humeral fractures .....	46
6.3	Low incidence of operative management in humeral shaft fractures .....	47
6.4	Complications of TEN-nailing in diaphyseal antebrachium and femoral shaft fractures .....	47
7	CONCLUSIONS .....	50
8	ACKNOWLEDGEMENTS .....	51
9	REFERENCES .....	53
10	ORIGINAL PUBLICATIONS .....	65

# ABSTRACT

The incidence of upper extremity fractures in children and adolescents and the surgical management of these fractures is increasing. The first objective of this dissertation was to determine the trend of the incidence of hospitalisation and treatment performed in operating room of humeral shaft and distal humeral fractures in Finland between 1987 and 2010. In instable long-bone diaphyseal fractures, elastic stable intramedullary nailing is currently the most commonly used operative fixation method. The second aim of the study was to evaluate complications concerning both antebrachium and femoral shaft fractures treated with titanium elastic nails (TENs).

The study of humeral shaft and distal humeral fractures included the entire (paediatric and adolescent) population, aged 0–16 years and 0–18 years, respectively, in Finland. The study period covered the 24-year period between 1987 and 2010. Patients treated in outpatient-clinic or in emergency room without hospitalisation were not included. Data for hospitalised patients with humeral shaft and distal humeral fractures were obtained from the Nationwide Hospital Discharge Registry (NHDR) of Finland where information is collected from all hospital categories (private, public, and other). The main outcome variable of these studies was the number of hospitalised patients and managements performed in operation room with a primary or secondary diagnosis of humeral shaft and distal humeral fracture. The procedure codes included in these studies were reposition and casting, reposition with osteosynthesis, and external fixation. As the physicians performed the procedures in the operating room with the patient under anaesthesia, the procedures were considered surgical treatment. To calculate the incidence of hospitalisation and surgical management, the annual mid-year population census from the Official Statistic of Finland, an electronic national population register. Statistical analyses were performed using PASW ver.19.0 (SPSS, Chicago, IL). The incidence figures were thus the true results concerning the entire paediatric and adolescent population of Finland rather than cohort-based estimates during the study period; as such, 95% confidence intervals were not calculated.

During the 24-year study period, the incidence of hospitalisation or surgical management of humeral shaft fractures remained stable. The incidence of hospitalisation increased only among girls, from 3.3 per 100 000 person-years to 5.3 per 100 000 person-years. There were no significant changes in treatment in either sex. In contrast, the incidence of hospitalisation

of distal humeral fractures increased markedly between 1987 and 2010 in both sexes. In all children aged 0–12 years, the overall hospitalisation incidence increased 30%, with girls aged 0–6 years having the highest increase, almost 3-fold. The incidence of operative management, reposition with osteosynthesis, increased 5-fold in patients aged 0–6 years and 2-fold in patients aged 7–12 years. As the incidence of operative management increased in patients younger than 13 years, the incidence of reposition and casting i.e. conservative treatment did not change during the 24 study years. The incidence of hospitalisation or treatment methods did not change in patients older than 13 years.

The studies concerning complications of TENs in antebrachium and femoral shaft fractures included patients treated at the Tampere University Hospital during 5-year study periods, from 1 January 2001 through 31 December 2005, and from 1 January 2003 through 31 December 2007. The data were collected from patient charts and radiographs were obtained from the hospital archives. The study of antebrachium shaft fractures included 35 consecutive patients treated with TENs and the study of femoral shaft fractures included 32 consecutive patients treated with TENs. Patient data and complications were evaluated individually.

In femoral shaft fractures treated with TENs, all fractures united within 3 months. In antebrachium shaft fractures, two patients had delayed bone union. The final functional outcome of all fractures was eventually good. In 12 patients (34%), complications associated with TENs were recorded. The complications were mostly related to technical errors, such as skin irritation at the nail entry site when nails remained too prominent toward the skin or fracture instability after inserting nails that were too thin. Two patients had a re-fracture after both-bone fracture with the radius stabilised with TENs and the ulna stabilised with a Kirschner wire or plate. A third patient returned to participating in sports earlier than advised and sustained a re-fracture after another sport injury. In one patient, compartment syndrome was recorded after nailing and the complication was considered major, although the patient recovered without further surgical intervention. The complication rate of femoral shaft fractures was 28%. Although all fractures united within three months, nine (16%) patients complained of skin irritation and pain at the nail entry site and in four (12%) patients the fracture was considered unstable immediately after nailing. All complications, except one with too early return to sport, were related in inadequate technical performance.

In conclusion, the incidence of hospitalisation and surgical treatment of humeral shaft fractures among children and adolescents remained stable between 1987 and 2010. In contrast, both the incidence of hospitalisation and operative management with osteosynthesis of distal humeral fractures increased markedly during the same study period, especially among girls less than seven years of age. The complication rates of TENs were 34% in antebrachium fractures and 28% in femoral shaft fractures. In the antebrachium fractures, all but one complication was considered minor. In femoral shaft fractures, fracture instability after the operation in four patients was considered major. The complications associated with TENs were mostly related to technical errors because the biomechanical qualities of the method were not respected.

# TIIVISTELMÄ

Lasten ja nuorten murtumat ovat yleisiä, joka kolmas saa murtuman ennen 17 ikävuotta. Viimeisen viidentoista vuoden aikana yläraajamurtumien esiintyvyys Suomessa on kasvanut merkittävästi, vaikka murtumien kokonaisesiintyvyys on laskussa. Myös murtumien hoito on muuttumassa yhä operatiivisemmaksi. Nämä muutokset ovat nähtävissä myös muissa maissa varsinkin olkavarren alaosan murtumien osalta. Pitkien luiden murtumien hoidossa käytetään usein titaanisia taipuisia ydinnauvoja (TEN-nauloja). Leikkaustekniikka on periaatteiltaan yksinkertainen ja pitkäaikaiset hoitotulokset hyviä, vaikkakin toimenpiteeseen liittyy runsaasti komplikaatioita.

Tämän tutkimuksen ensisijaisena tavoitteena oli selvittää lasten ja nuorten olkavarren keskiosan ja alaosan sairaalahoitoon johtaneiden murtumien esiintyvyydessä tapahtuneita muutoksia vuosien 1987 ja 2010 välisenä aikana. Lisäksi selvitettiin näiden murtumien hoidossa tapahtuneita muutoksia samalla ajanjaksolla. Tutkimuksen toisena tavoitteena oli retrospektiivisesti selvittää TEN-naulaukseen liittyviä komplikaatioita kyynärvarsi- ja reisimurtumien hoidossa.

Suomalainen terveydenhuollon sekä kansallinen että kansainvälinen tilastointi perustuu 1967 perustettuun hoitoilmoitusrekisteriin (HILMO-rekisteri). Rekisteriin kerätään tietoa sekä julkisten että yksityisten terveydenhuollon laitosten hoitamista potilaista. Rekisteri on lakisääteinen, ja siihen kirjautuvat tiedot potilaiden laitoshoidosta, erikoissairaalan avohoidosta ja toimenpiteistä. Rekisteri ei kata potilaiden yksittäisiä käyntejä terveyskeskuksessa tai sairaalan ensiavussa.

Olkavarren keskiosan ja alaosan sairaalahoitoon johtaneiden murtumien esiintyvyys sekä hoidossa tapahtuneet muutokset selvitettiin HILMO-rekisteriin perustuvien sähköisten tietokantojen avulla. Tutkimusta vastaava väestön määrä ja sukupuoli selvitettiin Väestörekisterikeskuksen tilastoista.

TEN-naulaukseen liittyviä komplikaatioita selvitettiin retrospektiivisesti keräämällä potilasaineisto kaikista Tampereen Yliopistollisessa Sairaalassa hoidetuista, alle 18 vuotiaista, kyynärvarsi- ja reisimurtumapotilaista viiden vuoden ajalta, kyynärvarsimurtumien osalta vuosien 2000–2005 ja reisimurtumien osalta vuosien 2003–2007 väliseltä ajalta. Viiden tutkimusvuoden aikana 35 potilaan kyynärvarren murtuma ja 32 potilaan reisimurtuma hoidettiin TEN-naulalla. Potilaiden ikä vaihteli kyynärvarsitutkimuksessa 5 ja 17 ikävuoden välillä, reisimurtumatutkimuksessa 5 ja 16 ikävuoden välillä.



Olkavarren keskiosan murtumien kokonaisesiintyvyys (4,8 per 100 000) pysyi tasaisena koko 24 vuoden tutkimusajan. Poikien osalta murtumien esiintyvyys laski hiukan ja tyttöjen osalta lisääntyi. Muutokset olivat kuitenkin niin vähäisiä, että ne saattavat liittyä myös normaaliin vuotuisen muutokseen. Hoitomenetelmissä ei myöskään havaittu muutoksia. Olkavarren alaosan sairaalahoitoon johtavien murtumien kokonaisesiintyvyys oli 5,6 per 10 000 24 vuoden ajanjaksona. Esiintyvyys lisääntyi tutkimusajanjaksona merkittävästi siten, että alle 13-vuotiaiden sairaalaan johtaneiden murtumien esiintyvyys lisääntyi 30 %. Huomionarvoista on, että alle kouluikäisten tyttöjen murtumien osuus kolminkertaistui. Leikkaushoidon esiintyvyys viisinkertaistui alle kouluikäisten ja kaksinkertaistui alle 13-vuotiaiden lasten keskuudessa. Vanhemmassa ikäluokassa ei tapahtunut muutoksia murtumien esiintyvyyden tai hoidon suhteen.

Kyynärvarren murtumissa 34 %:lla potilaista todettiin TEN-naulaukseen liittyvä komplikaatio. Komplikaatiot vaihtelivat naulan aiheuttamasta ihoärsytyksestä murtuman leikkauksen jälkeiseen epävakauteen ja ohimenevään hermovammaan. Kahdella potilaalla todettiin pitkittynyt luutumisen ja uusintamurtuma. Näiden komplikaatioiden arvioitiin johtuvan leikkausmetodien yhdistelmästä; elastiseen naulaan oli yhdistetty joko levy tai Kirshner-piikki (k-piikki). Vakavimmaksi komplikaatioksi arvioitiin yhdellä potilaalla todettu leikkauksenjälkeinen aitiopainesyndrooma.

Kaikki tutkimuksessa olleet reisimurtumat luutuivat kolmessa kuukaudessa vaikka komplikaatio todettiin 28 %:lla potilaista. Ongelmia aiheuttivat taivuttamattomat, liian lähelle ihoa ja polviniveltä jätetyt naulat jotka ärsyttivät ihoa ja hidastivat polven liikkeen palautumista. Toisena ongelmana todettiin toimenpiteen jälkeen epävakaiksi jääneet murtumat liian ohuita nauloja käytettäessä.

Sekä kyynärvarsi- että reisi-murtumien osalta suurin osa komplikaatioista arvioitiin johtuvan sekä puutteellisesta leikkaustekniikasta että puutteellisesta TEN-naulauksen biomekaniikan tuntemuksesta.

# LIST OF ORIGINAL PUBLICATIONS

- I Salonen A, Pajulo O, Lahdes-Vasama T, Mattila VM. Stable incidence of surgical treatment and hospitalisation for humeral shaft fractures among 0- to 16-year-old patients in Finland from 1987 to 2010. *J Child Orthop* 2014;8(2):143-148.
- II Salonen A, Pajulo O, Lahdes-Vasama T, Välipakka J, Mattila VM. Increased incidence of distal humeral fractures and surgical treatment in 0- to 18-year-old patients treated in Finland from 1987 to 2010. *J Child Orthop* 2013;7(6):559-564.
- III Salonen A, Salonen H, Pajulo O. A critical analysis of postoperative complications of antebrachium TEN-nailing in 35 children. *Scand J Surg* 2012;101(39):216-221.
- IV Salonen A, Lahdes-Vasama T, Mattila VM, Välipakka J, Pajulo O. Pitfalls of femoral titanium elastic nailing. *Scand J Surg* 2014; Published online before print April 15.

These publications are reprinted by the permission of the copyright holders.

# ABBREVIATIONS AND DEFINITIONS

Antebrachium	Forearm
Bryant traction	Lower limb traction frame supported by weight
CT	Computed tomography
Dealed bone union	Fracture that has not healed in the expected time
Diaphysis	Shaft of a long bone
ESIN	Elastic Stable Inamedullary Nail
K-wire	Kirschner wire
MRI	Magnetic resonance imaging
ND/MD	Nail/Medullary canal diameter
NHDR	National Hospital Discharge Registry
OTA	Orthopaedic Trauma Association
TEN	Titanium elastic nail
Volkman's contracture	Compartment syndrome

# 1 INTRODUCTION

One of three children sustains a fracture before their 17<sup>th</sup> birthday. At least one-third of the fractures are located in the upper extremity, as forearm both-bone fractures account for 6% of all fractures while fractures of the distal humerus account for 5% and those of the humeral shaft account for 1% of all fractures in children. Lower extremity fractures are more unusual than upper extremity fractures, and femoral fractures account for less than 2% of all fractures, although these fractures have remarkable impact on patients and family life as they usually lead to hospitalisation and surgical treatment (McCartney et al. 1994, Hedström et al. 2010).

The incidence of paediatric fractures in southern Finland is currently 163 per 10 000 in both sexes (Mäyränpää et al. 2010). While the overall incidence of fractures has slightly decreased, the incidence of upper extremity fractures has increased over 20% in the past 15 years (Helenius et al. 2009, Sinikumpu et al. 2013).

Along with the increasing incidence of upper extremity fractures, the incidence of operative treatment has also increased. Improvements in instrumentation and imaging technology, as well as rapid bone healing with minimal and temporal fixation, has increased the tendency toward operative management. Social and financial pressures also contribute to minimise hospitalisation (Flynn et al. 2003, Helenius et al. 2009, Eismann et al. 2013). Still, most children's fractures can be managed by closed reduction and casting. Humeral shaft fractures are perhaps the easiest long-bone fractures to treat using conservative methods, due to the remarkable remodelling potential of the humerus (Beaty 1992, Franklin et al. 2014). Operative treatment, on the other hand, is favoured for unstable diaphyseal antebrachium fractures as the complication rates in conservative treatment are reported to be as high as 50% (Mann et al. 2003). Operative treatment is also widely accepted for distal humeral fractures, especially supracondylar fractures where precise anatomic reconstitution is demanded in the absence of significant remodelling (Buckvić et al. 2013). For children younger than school age with femoral diaphyseal fractures, traction and spica casting is the method of choice. In older children, long-term immobilisation in the hospital and home is not well tolerated and elastic stable intramedullary nailing has taken precedence over the closed method in the past 20 years (Allen 1977, Flynn et al. 2004, Baldwin et al. 2011).

Elastic stable intramedullary nailing has been applied since the 1970s and is now widely used for unstable long-bone fractures in children. The advantages of intramedullary stable, titanium nailing (TEN-nailing) include its minimal technical invasiveness and the ability to maintain joint movement and muscle tone as well as normal circulation and fracture stability. Another advantage, especially in treating diaphyseal femoral fractures, is the short-term hospitalisation, allowing for early return to school and everyday life. Although TEN-nailing has several advantages, there are also various reported complications, mainly associated with improper operative technique (Lascombes et al. 1990, Vransky et al. 2000, Barry and Paterson 2004, Jubel et al. 2005).

The aim of the present study was to determine the incidence of hospitalisation and surgical treatment of diaphyseal and distal humeral fractures in children and adolescents over the past 24 years in Finland. In addition, complications concerning antebrachium and diaphyseal femoral TEN-nailing were analysed.

## 2 REVIEW OF THE LITERATURE

### 2.1 General aspects

Injuries are common during childhood as the incidence of recorded injuries is 25 per 100 each year. Almost one-third of these injuries are fractures (Landin 1983, Grossman 2000). Thus, one out of three growing children will sustain a fracture before they reach 17 years of age (Schneidt et al. 1995, Walsh et al. 1996, Cooper et al. 2004). The fracture pattern and bone remodelling ability greatly differ between children and adults. The most important difference is the presence of the growth plate. Growing bone is also porous and contains a high amount of collagen and cartilage. Together, these qualities support rapid fracture healing and remodelling. Ligamentous injuries in children are rare compared with adults as growing bone has less tensile strength than ligaments, leading to fracture. Thirty percent of fractures occur at the growth plate, which, although uncommon, can lead to damage of the physis and subsequently to asymmetrical growth (Iannotti 1990, Mann and Rajmaira 1990, Frost et al. 2000).

The majority of fractures in children and adolescents occur in the upper extremity with relative low injury energy. The most common injury mechanism is a fall, but the injury energy increases with age. Although both girls and boys have the same kind of fracture pattern, the fracture incidence is 1.2-fold higher among boys. In general, fractures are managed without surgical intervention, and thus most patients are treated as outpatients (Kopjar and Wickizer 1998, Goulding 2007).

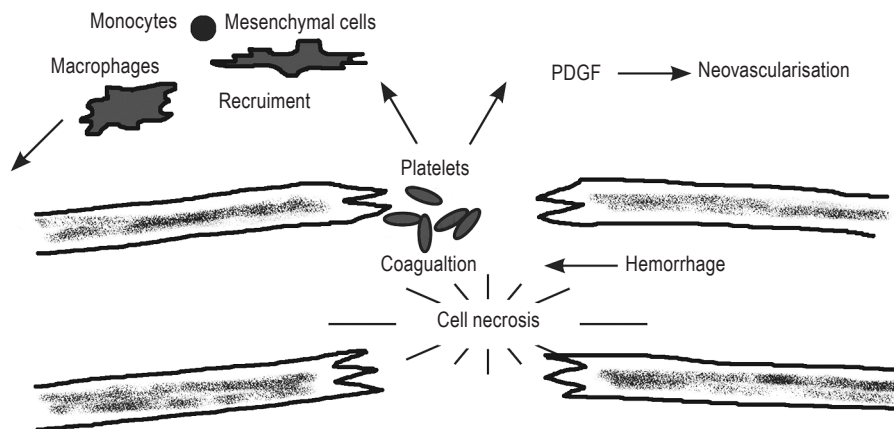
The incidence of upper extremity fractures in children and adolescents has increased by 24% in Finland during the past 15 years, although the overall incidence of fractures decreased during the same period. At the same time, the incidence of surgical management has also increased (Helenius et al. 2009, Mäyränpää et al. 2010).

### 2.2 Fracture healing of growing bone

Fractures can heal through primary or secondary bone formation mechanisms. The primary pathway is based on anatomic reduction and rigid stabilisation, without a remodelling phase. In fractures without rigid stabilisation, the bone is formed in three phases, including inflammatory, reparative, and remodelling phases. The phases are the same in children and

adults, but the remodelling phase is more extensive and physiologically active in children (Wilkins 2005, Xian et al. 2010, Marsell and Einhorn 2011).

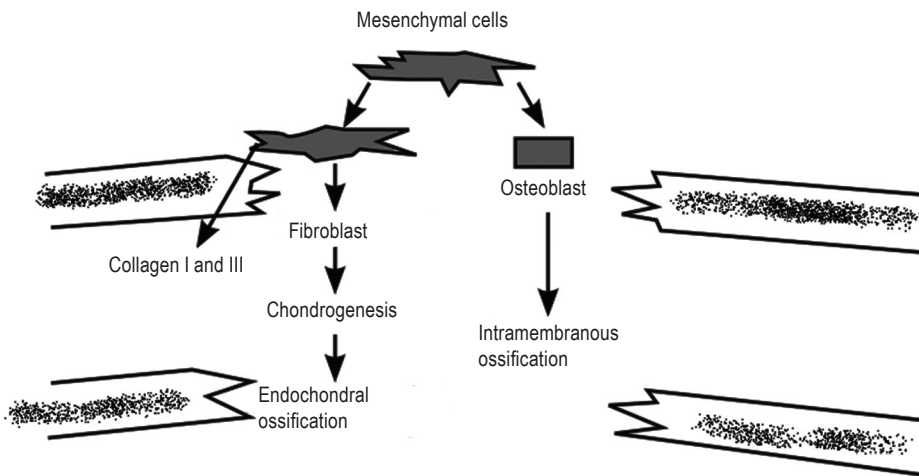
Immediately after trauma, bleeding occurs from the Haversian system in the maturing diaphysis or from the metaphyseal vascular system. A haematoma is generated within 24 hours and contains bone marrow cells. The bleeding leads to an inflammatory response as soft tissue around the fracture releases growth factors, cytokines, and prostaglandins into the haematoma. The periosteum tears relatively easily in children, allowing the haematoma to dissect along the diaphysis and metaphysis, thereby contributing new bone formation. The inflammatory phase is usually completed after 7 days (Figure 1.). Inflammatory molecules are, however, still needed later during the regeneration phase as they are involved in eliminating the debris from the fracture site, which allows for the migration and invasion of mesenchymal cells to the area (Gerstenfeld et al. 2003, Green et al. 2005 (A), Wilkins 2005, Schindeler et al. 2008, Xian et al. 2010). Avascular trabecular and cortical bone induce multipotential mesenchymal stem cells in the surrounding soft tissue and bone marrow to modulate osteogenic cells like chondrocytes and fibroblasts (Goldhaber et al. 1961).



**Figure 1.** Inflammatory phase. Inflammatory cells remove the debris from the fracture site and together with fibroblastic cells develop matrix that enables new bone formation.

The second phase, the reparative phase, includes soft callus (fibrocartilage) and hard callus formation (Figure 2.). Osteogenic cells produce a semi-rigid soft callus that provides a somewhat stable, avascular structure to the fracture. Callus formation begins 7 to 9 days after the trauma (Einhorn 1998, Wilkins 2005, Schindeler et al. 2008). Hard bone formation requires revascularisation in the fracture site. After the soft callus is formed, chondrocyte apoptosis and subsequent cartilaginous degeneration destroy and remove extracellular matrices away from the fracture site. This allows for angiopoietin-dependent

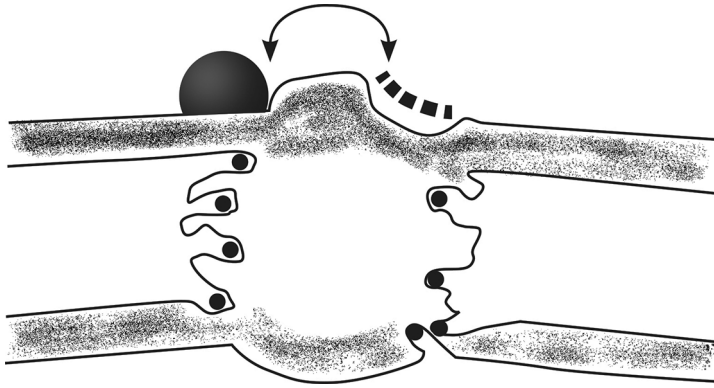
and vascular endothelial growth factor pathways to vascularise the soft callus (Tsidiris et al. 2007, Ai-Aql et al. 2008). After vascularisation, the hard callus is formed by chondrocyte proliferation and extracellular matrix calcification. Peak production of the hard callus is usually reached in 2 weeks. The reparative phase continues for up to 3 months (Einhorn 1998, Wilkins 2005).



**Figure 2.** The mesenchymal cells are needed to release growth factors. These cells may differentiate into osteoblasts that produce intramembranous bone.

Bone remodelling is the third and last phase of bone healing, and can last for years (Figure 3.). The remodelling phase is balanced between hard callus resorption by osteoclasts and lamellar bone deposition by osteoblasts (Wendeborg 1961). The rate of remodelling is dependent on patient age and fracture site. The metaphysis is an active remodelling area in normal bone growth and 75% of angular remodelling originates from the physis. Angular remodelling is based on increased growth on the concave side of the fracture. After the long axis of the long-bone shaft becomes perpendicular to the physis, growth becomes symmetrical again (Ryöppy and Karaharju 1974, Pauwels 1975, Wallace and Hoffman 1992). The diaphysis covers 25% of angulation remodelling. Remodelling requires simultaneous pressure on the concave side and tension, with reabsorption on the convex side redress the diaphysis (Wolf 1892, Wilkins 2005).





**Figure 3.** Remodelling begins with resorption of mechanically inefficient portions of the callus.

The remodelling capacity is greatly dependent on patient age, injury energy and fracture location. Remodelling is generally better in the upper extremities than in the lower extremities. Proximal and diaphyseal humeral fractures have significant remodelling ability. Anterior angulation up to 70° can remodel in children younger than 5 years (Beaty 1992, Gasco et al. 1997, Wilkins 2005). In diaphyseal antebrachial fractures, angulation up to 15° and malrotation up to 45° can remodel in children younger than 8 years. In older children and in proximal diaphyseal antebrachium fractures, the corresponding angles are 10° and 30°, respectively (Jones and Weiner 1999, Price 2010). Supracondylar fractures, on the other hand, have very poor remodelling potential and anatomic reduction is thus essential (Musgrave and Mendelson 2002, Buckvić et al. 2013). Based on a study by Kamegaya et al. (2012), the remodelling potential of diaphyseal femoral fractures is best in children younger than 5 years, as remodelling of angular deformities is more efficient in the coronal plane than in the sagittal plane. In children younger than 10 years, the angular remodelling potential is 30% in the coronal plane and 20% for those in the sagittal plane. In patients older than 10 years, the corresponding figures are less than 20%, respectively (Kamegaya et al. 2012). The rotational correction in femoral shaft fractures is minimal in all age groups (Davids 1994).

### 2.3 Incidence and aetiology of children's fractures

The majority of paediatric fractures are sustained in the upper extremities, although the incidence of single fractures varies annually and geographically (Table 1.). In a recent Swedish study by Hedström et al. (2010), upper extremity fractures accounts up to 70% of fractures while lower extremity are less common (Table 2.) (Hedström et al. 2010). Fractures are more common in boys. Nearly 50% of boys sustain a fracture before turning

17, compared with 30% of girls. The peak age for fractures is 4 years earlier in girls than boys (10 years vs 14 years) (Landin 1983, Mäyränpää et al. 2010).

In southern Finland, the overall fracture incidence in children and adolescents younger than 16 years increased from 159 per 10 000 to 196 per 10 000 between 1967 and 1983. Since then the incidence has decreased almost 20% and the current incidence rate is 163 per 10 000 in southern Finland. The decrease has been similar in boys and girls. The reported fracture pattern has changed because the incidence of hand and foot fractures has decreased 39% and 48%, respectively, whereas that of upper extremity fractures has increased up to 31% between 1983 and 2005 (Mäyränpää et al. 2010). In northern Finland, the increasing trend of upper-extremity fractures is similar, and the reported incidence of antebrachium fractures increased more than 4-fold between 2000 and 2009 (Sinikumpu et al. 2013). Also in a Finnish nationwide population-based study of children and adolescents younger than 18 years (Helenius et al. 2009), the incidence of upper-extremity fractures resulting in hospitalisation increased 23% between 1997 and 2005. The trend seems so be similar in Sweden where the incidence of children's fractures almost doubled up to 212 per 10 000 between 1950s and 1970s (Landin 1983). Since then the overall children's fracture incidence has decreased 9% between 1993 and 1994 in southern Sweden, but increased 13% between 1993 and 2007 in northern Sweden, respectively (Tiderius et al. 1999, Hedström et al. 2010).

The most common injury mechanism is a fall, accounting for up to 70% of injuries. Collisions, and school and traffic accidents are common in school-aged children and the incidence of these injury mechanisms increases with age (Kopjar and Wickizer 1998, Rennie et al. 2007).

**Table 1.** Overview of epidemiological studies describing children's fractures.

Author	Location	Study period	Age group	Incidence per 10 <sup>3</sup>
Cooper	Great Britain	1988–1998	0–17	13.3
Brudvik	Norway	1998	0–15	24.5
Kopjar	Norway	1992–1995	0–12	12.8
Lyons	Wales	1996	0–14	36.1
Rennie	Scotland	2000	0–15	20.2
Landin	Sweden	1950–1979	0–16	21.2
Tiderius	Sweden	1993–1994	0–16	19.3
Hedström	Sweden	1993–2007	0–19	20.1
Maasalu	Estonia	2006	0–14	68.9

**Table 2.** Distribution of the most common fracture site.

Fracture site	Proportion (%)
Distal forearm	26
Clavicle	11
Fingers	10
Metatarsals	5
Proximal forearm	3
Forearm shaft	3
Proximal humerus	3
Tibial/fibular shaft	3
Carpals	2
Femoral shaft	1
Humeral shaft	1

### 2.3.1 Incidence and aetiology of humeral shaft fractures

Humeral shaft fractures account for less than 2% of all children's fractures, with an incidence of 12 to 30 per 100 000 (Cheng and Shen 1993, Cheng et al. 1999). There are two incidence peaks, one in children younger than 3 years and the other in children older than 12 years. In large babies (birth weight over 4.5 kg), humeral fractures may occur as a birth trauma when special manoeuvres are needed to bring the baby down when the arm is positioned above the head (Weseley and Barenfeld 1969). In children less than 3 years of age, child abuse must also be considered as a potential cause of fracture (King et al. 1988). In children older than 12 years of age, the most common fracture mechanism is direct trauma or rotational forces upon the humeral shaft caused by sport injuries (Caviglia et al. 2005).

### 2.3.2 Incidence and aetiology of distal humeral fractures

Supracondylar fractures are the most common fractures in the elbow region, comprising up to 58% of elbow fractures and 5% of all children's fractures. In the Danish population, the annual incidence of supracondylar fractures in children younger than 15 years is 1.8 per 1000 (Houshian et al. 2001, Hedström et al. 2010). The peak incidence occurs in preschool children, 5 to 6 years of age. Fractures can be classified as extension or flexion fractures based on the injury mechanism. Extension fractures are the most common, accounting for up to 99% of supracondylar fractures. These fractures are usually caused by a fall onto an outstretched hand with the elbow in full extension. Flexion-type fractures are caused by a fall onto the flexed elbow (Weise et al. 1997, Cheng et al. 2001, Houshian et al. 2001).

Fractures of the lateral condyle account for up to 20% of distal humeral fractures and are the second most frequent fractures of the elbow region after supracondylar fractures (Beaty 2010, Tejwani et al. 2011). The peak incidence occurs in preschool-age children. Injury is caused by a varus force with the elbow in extension. Often the fracture fragment is avulsed with the lateral ligament and the extensor muscles (Jakob et al. 1975).

Fractures involving medial epicondylar epiphysis account for 14% of distal humeral fractures. Compared with supracondylar and lateral condylar fractures, medial epicondylar fractures have a later peak incidence, typically in children between 9 and 14 years of age. The fracture is often (up to 50%) associated with dislocation of the elbow. In almost 20% of fractures, the fracture fragment is incarcerated into the elbow joint (Bede et al. 1975). Injuries also occur from direct trauma to the medial side of the elbow, avulsion of the flexor muscles attaching to the medial side of elbow, or chronic stress (Smith 1950, Gottschack et al. 2012).

### 2.3.3 Incidence and aetiology of antebrachium shaft fractures

Antebrachium shaft fractures represent 4% of all fractures in children with an incidence of 6.8 per 10 000 in the south Finnish population (Mäyränpää et al. 2010). The overall risk for fracture increases up to 12 years of age. The risk decreases after age 12 among girls, but not among boys (Landin 1983). Antebrachium shaft fractures are the most common fractures requiring surgical intervention (Greenbaum et al. 2001). The fracture is usually sustained by a fall onto the outstretched upper extremity and fractures are often associated with the use of a trampoline or monkey bars. The antebrachium fracture type is defined by the injury force. The bone is more resistant to an axial force than to bending or rotation. A direct lateral force to the arm can break a single bone, usually the ulna. Rotational force is present in greenstick fractures or when the ulna and radius break at different levels. Longitudinal forces bend the growing bone resulting in a bowing fracture. Hyperpronation is associated with fractures on the dorsal side and hypersupination on the volar side (Evans 1951, Borden 1974, Carter and Spengler 1987, Crawford and Cionni 1984, Price and Mencio 2001).

### 2.3.4 Incidence and aetiology of femoral shaft fractures

Femoral shaft fractures are the most common fractures requiring hospitalisation, although they account for less than 2% of all fractures. The incidence of femoral shaft fractures reported by Heideken et al. (2011) in Sweden is 11.8 per 100 000, and it decreased by 42% between 1987 and 2005. During that time, the length of hospitalisation also decreased by 81%, from 26 days to 5 days. The fracture aetiology varies between patients of different ages. In children younger than 1 year of age, up to 80% of fractures may be caused by abuse. In walking children, the most common cause of a femoral shaft fracture is a fall from a

height of less than 1 meter. In older children, injuries leading to femoral shaft fractures are usually high-energy as sport-related accidents are the most frequent cause of fracture in children between 4 and 12 years of age and traffic accidents in adolescents older than 12 years of age (Beals and Tufts 1983, Kopjar and Wickizer 1998, Heideken et al. 2011). In low-energy femoral shaft fractures among children older than 4 years, metabolic diseases like osteogenesis imperfecta, various benign bone lesions, and neoplasms must be considered, although they are very rare. Stress fractures may be diagnosed in children older than 4 years with very active sport hobbies. These fractures, however, are very uncommon, representing only 4% of femoral shaft and neck fractures (Burks and Sutherland 1984, Krettek et al. 1991, Nafei et al. 1992, Arkader and Dormans 2010).

## 2.4 Diagnostic aspects

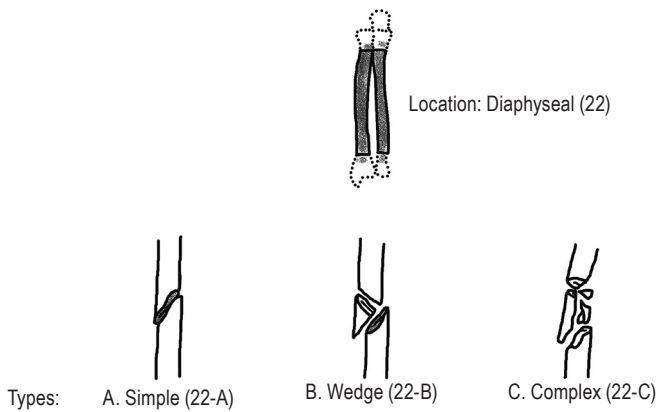
### 2.4.1 Radiographic assessment

Adequate radiographic assessment of injuries is important to clarify fully the extent of fractures and soft tissue injuries to evaluate the need for surgical intervention. Limb radiographs should include at least of two views at 90° angles to one another and usually both the proximal and distal joint of the bone of interest. In complex fractures 3-dimension computed tomography (CT) models have expanded the ability to better define fracture patterns. The disadvantage of CT is radiation dose, although in future ultra-low-dose CT may provide effective dose of radiation equal to that of radiographs. Magnetic resonance imaging (MRI) is radiation free alternative to CT. It provides diagnostic help in unclear fracture suspicion. The disadvantage of MRI can be in some places it's lesser availability and need for sedation or anesthesia in young patients. (Musgrave and Mendelson 2002, Moritz et al. 2012, Sutko and Oberc 2012, Henry 2013, Güzel et al. 2014, Schmutz et al. 2014.) Image intensifiers have greatly facilitated the reduction and internal stabilisation of fractures with percutaneous management and have also reduced radiation exposure to patients and theatre personnel (Keenan et al. 1996, Vitale 2010).

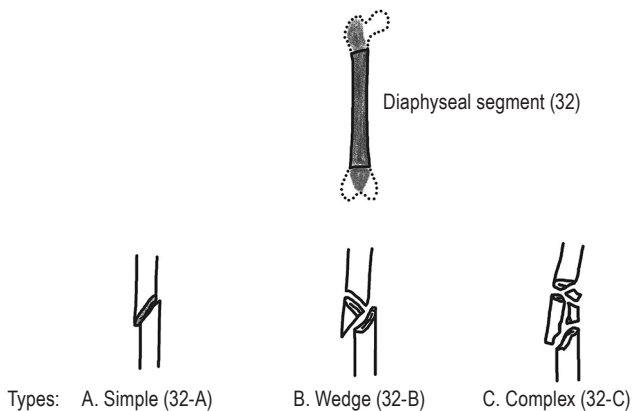
### 2.4.2 Classification of long-bone diaphyseal fractures

Diaphyseal long-bone fractures are classified by various systems. Fractures are considered stable if the fragments are in apposition and at most exhibit axial deviation, but not shortening. Greenstick fractures are an intermediate step between plastic deformity and complete fracture as they are seen only in growing children. Long oblique fractures and fractures with complete displacement and remarkable shortening are considered unstable. One common fracture classification is based on the Orthopaedic Trauma Association (OTA) committee. The different diaphyseal fractures are divided as simple, wedge, and

complex fractures (Figure 4. and 5.) (Müller 1990, Casey and Moed 1996, Orthopaedic Trauma Association 1996, Mulperi 1997).



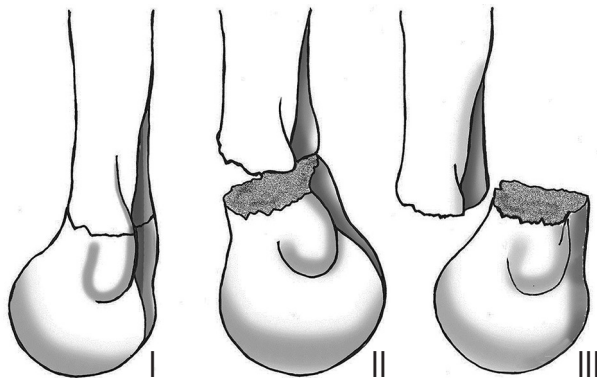
**Figure 4.** The main types of diaphyseal antebrachial fractures according to OTA classification. (Reprinted from J Pediatr Orthop vol 21 number 10, 2007 with permission of OTA.)



**Figure 5.** The main types of diaphyseal femoral fractures according to OTA classification. (Reprinted from J Pediatr Orthop vol 21 number 10, 2007 with permission of OTA.)

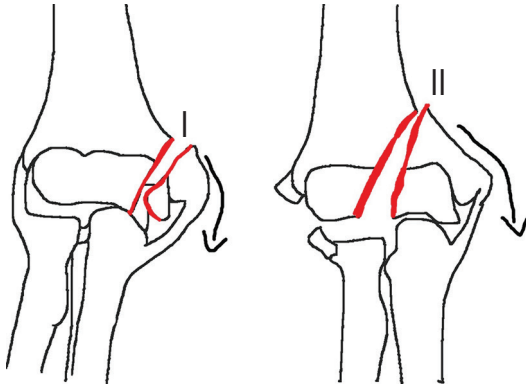
### 2.4.3 Classification of distal humeral fractures

Supracondylar fractures are often classified according to the Gartland system (Figure 6.) (Gartland 1959). The original classification is extended to include Type IV fractures, which are displaced into both extension and flexion. Type IV fractures are often diagnosed in the operating room when reducing the fracture under an image intensifier. Collapse of the medial column, i.e., the medial condyle, and loss of the Bauman angle is not a true separate fracture type but can be diagnosed also in minimally displaced supracondylar fractures. Without reduction, the collapse of the medial column can potentially lead to varus deformity (Gartland 1959, De Boeck 1995, Leitch et al. 2006).



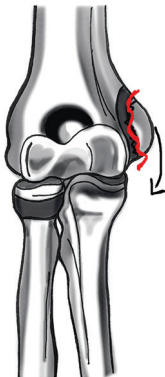**Figure 6.** Supracondylar fractures according to Gartland classification. In type I the fracture is undisplaced. In type II the posterior hinge is displaced but there is posterior continuity. In the type III there is no posterior continuity.

Lateral condyle fractures are usually classified according to Milch or Wilkins. Milch classification is based on anatomic fracture lines (Figure 7.). Wilkins classification is based on dislocation: in type I fracture is undisplaced, in type II there is angulation and in type III there is also lateral dislocation. As a modification to help deciding on the surgical treatment in Milch type I, Badelon et al. (1988) divided stage I fractures as those with less than 2 mm and those over 2 mm displacement. Surgical treatment is recommended for those displaced more than 2 mm (Rutherford 1985, Badelon 1988, Wilkins 1991).



**Figure 7.** The Milch classification. In type I, the fracture line passes through the trochleocapitellar groove. In Type II, fracture line passes through the trochlea.

There are various classifications for medial epicondyle fractures. A simple classification divides fractures into acute or chronic. Acute fractures can be undisplaced, minimally or significantly (more than 5 mm) displaced fractures, and fractures with entrapment of the epicondylar fragment into the elbow joint with or without elbow dislocation (Figure 8.) (Beaty and Kasser 2010).



**Figure 8.** The medial epicondyle fracture-line.

#### 2.4.4 Classification of open fractures

Open fractures are usually high-energy injuries. The Gustilo-Anderson classification is widely used and it has become the standard classifying system for open fractures (Table 3.). The purpose of the classification schema is to provide a prognostic framework that guides antibiotic treatment, determine appropriate timing for soft tissue débridement, internal fixation etc. interventions (Gosselin 2004, Okike and Bhattacharya 2006, Kim and Leopold 2012).



**Table 3.** The Gustilo-Anderson classification.

Classification	Description
<b>Type I</b>	Puncture wound $\leq 1$ cm with minimal soft tissue injury. Minimal wound contamination or muscle crushing.
<b>Type II</b>	Wound $> 1$ cm Moderate soft-tissue injury. Soft tissue coverage of the bone is adequate. Communication in fracture is minimal.
<b>Type III 3a</b>	Extensive soft tissue damage. Massively contaminated, severely comminuted or segmental fracture. Soft tissue coverage of the bone is adequate.
<b>Type III 3b</b>	Extensive soft tissue damage with periosteal stripping and bone exposure. Severely contaminated and comminutes fracture. Flap coverage is required to provide soft tissue coverage.
<b>Type III 3c</b>	Associated with an arterial injury requiring repair for limb salvage.

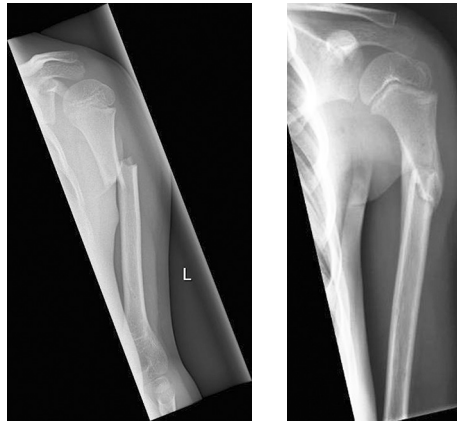## 2.5 Treatment modalities of extremity fractures in children and adolescents

The goal of fracture treatment is fracture stabilisation with non-operative or operative management performed to ensure soft tissue protection, adequate reduction, and early range of motion to prevent joint stiffness (Musgrave and Mendelson 2002). Several treatment possibilities are available when choosing the best treatment for individual patients. Non-operative management options include functional bracing, splinting, or casting as well as traction and spica cast for femoral diaphyseal fractures. Commonly applied operative management options include internal fixation with intramedullary elastic or stable nailing, K-wire pinning, external fixation, and plating among others depending the site of the fracture. Although conservative treatment has been traditionally the treatment of choice, the use of surgical intervention has increased during the past 15 years. The same trend is seen in adult upper extremity fractures. (Flynn et al. 2003, Cheng et al. 1999, Helenius et al. 2009, Mattila et al. 2011, Huttunen et al. 2012, Eismann et al. 2013.) Operative management at best gives optimal fracture alignment and stabilisation with the opportunity to establish early joint movement. On the other hand, there is iatrogenic risk of neurovascular or bone vascularity damage.

### 2.5.1 Management of humeral shaft fractures

The majority of humeral shaft fractures in children can be managed non-operatively by splinting or casting, although sometimes angulation may be difficult to control. The remodelling potential of the humerus is remarkable in patients younger than 5 years, remodelling can resolve angulation up to  $70^\circ$  and children can tolerate residual anterior angulation up to  $40^\circ$  (Beaty 1992). Thus, the functional outcome usually is good despite

residual radiographic angulation (Figure 9). Although conservative treatment has led to good results, there is growing interest in stable intramedullary nailing, especially when treating adolescents, for open or bilateral fractures or in cases of multiple traumas (Caviglia 2005, Lascombes et al. 2006, Fernandez et al. 2010 (A)).



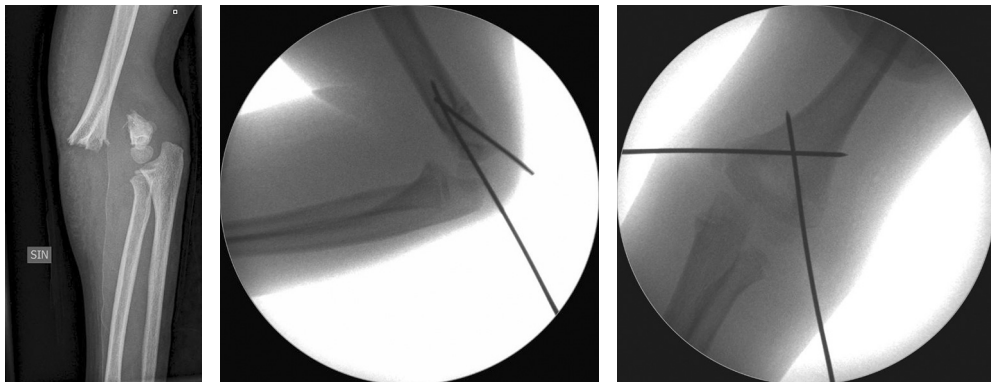
**Figure 9.** Humeral shaft fracture in a 8-year-old girl treated conservative with plastic functional brace.

### 2.5.2 Management of distal humeral fractures

Supracondylar humerus fractures account for up to 30% of all limb fractures in pre-school children, while medial epicondyle and lateral condyle fractures are very uncommon (Beekman and Sullivan 1941, Cheng and Shen 1993, Cheng et al. 2001). Anatomical reduction in distal humeral fractures, especially in supracondylar fractures is required because of limited bone remodelling potential. Type I fractures can be managed by an above-the-elbow cast with the elbow at 90° for approximately three weeks (Musgrave and Mendelson 2002). The management of type II fractures is controversial. Although Gartland II type fractures can be managed successfully with reduction, casting, and close follow-up, percutaneous pinning is a popular method to secure stability. In Gartland type III and IV fractures, as well as loss of the medial column, operative treatment with pinning is recommended (Figure 10.) (Wilkins 1990, Wilkins 1991, DeBoeck 1995, Foad et al. 2004, Mulpuri and Wilkins 2012, Spencer et al. 2012). The pinning procedure can be performed usually with two crossed pins or with two lateral entry pins. Medial/lateral pin entry proves most stable fixation (Brauer et al. 2007). Whether the pins are parallel or divergent, the best fracture stability is achieved by separating the pins as far apart as possible at the fracture site. Bloom et al. (2008) recommended intraoperative testing of fracture stability and if the fracture is considered slightly unstable, a third lateral pin is advised (Bloom et al. 2008). Open reduction is indicated in cases where closed reduction fails or when the fracture is associated with dysvascular limb (Onder et al. 2009). A long-

arm cast with elbow flexion of no more than 90° is recommended. After three weeks of immobilisation, the cast and pins are removed, usually in the outpatient department without anaesthesia (Musgrave and Mendelson 2002).

The overall complication rate in supracondylar fracture pinning is less than 10%. Iatrogenic injury to the ulnar nerve occurs in 4% of patients with medial pins. To avoid this complication, a mini-open technique is recommended. Even if the ulnar nerve is not penetrated by the pin, a medial pin placed adjacent to a nerve can cause irritation or even injury. This injury can be avoided by using two lateral pins although the fracture stabilisation with this technique is not as good as with crossed pins (Rasool 1998, Skaggs et al. 2001, Skaggs et al. 2004, Green et al. 2005, Brauer et al. 2007). Postoperative loss of reduction leading to malunion, hyperextension, and cubitus varus are even more uncommon complications, presenting in less than 2% of all complications (Pirone et al. 1988, Sankar et al. 2007). Pin track infections, myositis ossificans, and osteonecrosis have been described after supracondylar fracture pinning, but these complications are also rare (Spinner et al. 1995, Kim et al. 2002, Skaggs et al. 2004).

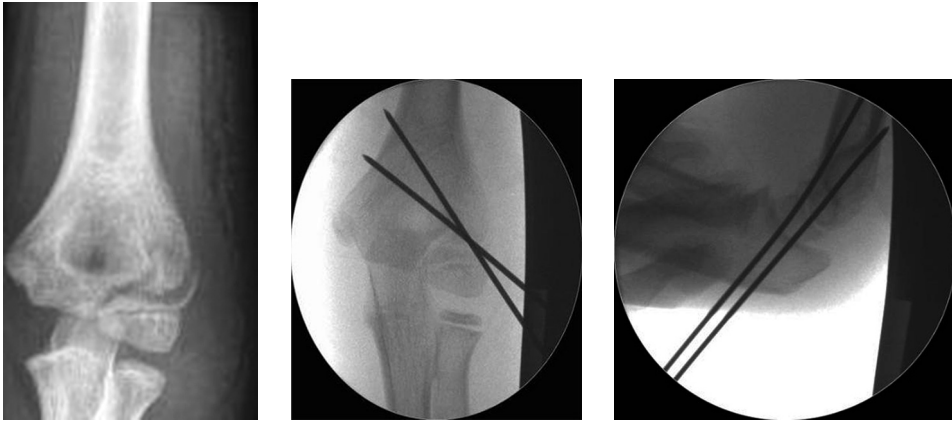


**Figure 10.** A Gartland type III supracondylar fracture in a 7-year-old boy treated with crossed K-wires.

The most common fracture locations in the distal humeral physis are the lateral condyle and medial epicondyle, although they both are very uncommon. In lateral condyle fractures, open reduction and fixation with pins or screws is recommended for Milch type II and III fractures (Figure 11.) (Rutherford 1985). In Milch type I fractures where the fracture is displaced less than 2 mm, immobilisation without reduction with a long-arm cast with the elbow in 60° to 90° flexion leads to a good functional outcome (Jakob et al. 1975).

Clinically significant complications concerning lateral condylar fractures are rare (Koh et al. 2010). Delayed union, non-union, and osteonecrosis are associated with delayed or missed diagnosis. True nonunion is rare because it is usually the result of a missed diagnosis of a displaced fracture. Osteonecrosis has been reported in fractures treated with open reduction and pinning when performed more than three weeks after the primary injury (Blount 1955). After operative reduction, the most common complications are lateral

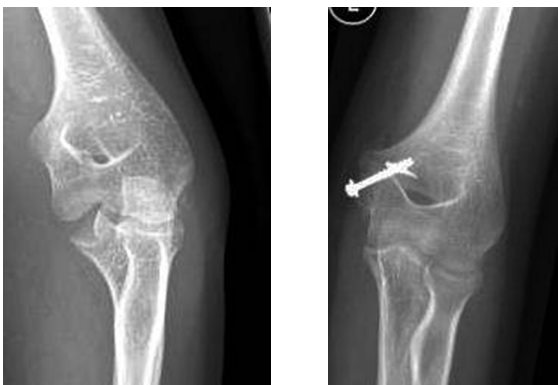condyle overgrowth and cubitus varus, but they hardly ever lead to functional abnormality or reoperation (Koh et al. 2010).



**Figure 11.** Lateral condyle fracture in a 10-year-old boy treated with open reduction and K-wire fixation.

Nearly half of medial epicondylar fractures are associated with elbow dislocation. The treatment of these fractures is controversial. In fractures with fragment incarceration within the elbow joint, the fragment must be removed with manipulation or with open reduction. Fracture displacement more than 5 mm and ulnar nerve dysfunction are accepted indications for open reduction and fixation with a Kirschner wire (K-wire) or screw (Figure 12.). Several studies, however, have reported excellent functional outcome with only long-arm cast immobilisation without reduction (Berstein 1981, Hines et al. 1987, Wilson et al. 1988, Farsetti et al. 2001, El Andalussi et al. 2006).

Complications associated with medial epicondylar fractures include failure to recognise incarcerated fracture fragment in the elbow joint. Mechanical blockade can lead to a loss of elbow motion or result in ulnar nerve dysfunction when the ulnar nerve is compressed between a bony fragment and the distal humeral cortex (Fairbanks and Buxton 1934).



**Figure 12.** A medial epicondylar fracture in a 10-year-old girl treated with open reduction and screw fixation.

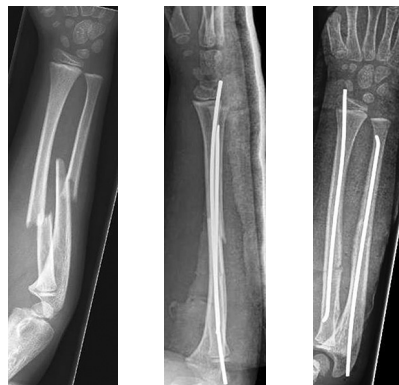### 2.5.3 Management of diaphyseal antebrachium fractures

The majority of children's diaphyseal antebrachium fractures can be treated with closed reduction and long-arm casting, although 16% of antebrachium fractures treated conservatively are converted to operative procedures (Franklin et al. 2014). Operative management is required in fractures with over 10° of angulation, loss of supination or pronation, as well as in unstable or open fractures (Garg et al. 2008). The spontaneous recovery of malunion is poor in girls older than 8 years and in boys older than 10 years old (Fuller and McCullough 1982). A variety of implants have been used for fixation of forearm fractures. Open reduction and plate fixation is a well-reported procedure in both children and adolescents. Plate fixation allows anatomic and stable correction without rotational and angular abnormalities. It also allows early mobilisation to prevent joint stiffness. Compression plates are recommended in re-fractures when in many cases the intramedullary canal is full of old callus or bone septa from the previous fracture which makes passage of intramedullary device difficult. (Creaseman et al. 1984, Price et al. 1990, Ortega et al. 1996.) The large surgical exposure required for the procedure, however, may result in disturbing scars and loss of motion when muscle fibrosis develops. Indications for external fixation are extremely rare. These include extensive comminution, segmental bone loss or grossly inadequate soft tissue coverage. (Putnam and Walsh 1993, Price 1994, Lieber and Sommerfeldt 2011.) Intramedullary fixation with elastic stable intramedullary nailing, K-wire, Rush rod, or Steinmann pins provides minimally invasive management compared to plating. Especially, elastic stable titanium nailing has become an established management option in Europe during the last three decades as both short and long-term outcomes are frequently reported to be good (Figure 13.) (Lascombes et al. 1990, Vransky et al. 2000, Barry and Paterson 2004, Jubel et al. 2005). The procedure is relatively simple and safe as the implants are inserted into the intramedullary canal far from the fracture site in order to avoid further soft tissue damage (Fernandez et al. 2009). Elastic stable nailing also provides a good cosmetic outcome as implants are inserted through a small soft tissue incision (Cullen et al. 1998). Although closed reduction and nail fixation aim for minimal scarring, according to Yuan et al. (2004) conversion from a closed to an open procedure should be considered if a closed reduction cannot be obtained with three attempts. Functional outcome is equal in open and closed procedures (Yuan et al. 2004, Yalcinkaya et al. 2010).

Elastic stable nailing is based on three-point stabilisation with opposite tension of two parallel implants. In diaphyseal antebrachium fractures, tension forms between the ulna and the radius when both bones are separately fixed (Lascombes et al. 2006, Garg et al. 2008). The flexibility of nails allows minimal movement at the fracture site, which facilitates callus formation (Huber et al. 1996). Elastic stable nails are also strong enough to maintain satisfactory alignment, although rotational stability is based on the ability of the periosteum to resist torsional stress, so there is no need to pre-bend the nails (Blaisier and Salamon 1993, Price 2010).

In antebrachium fractures, the diameter of the each inserted nail should be at least 40% of intramedullary canal (Schmittenebecher et al. 2000). The entry point of nails placed in the radius is on the anterior or lateral side of the distal radius above the distal physis while the entry point of nails placed in the ulna is in the proximal ulna (Lascombes et al. 2006). After insertion, the nails are cut and bent close to the bone, although the radial nail should be prominent enough to prevent damage of the extensor pollicis longus (Weiss and Mencio 2012). Cast immobilisation from four to six weeks after operative treatment is recommended (Garg et al. 2008, Kang et al. 2011). Intramedullary nails are usually removed under anaesthesia after complete bone union four to six months after the operation (Garg et al. 2008).

Conservative treatment for unstable diaphyseal antebrachium fractures leads to unsatisfactory outcome in up to 50% of patients (Mann et al. 2003). Elastic intramedullary nailing provides excellent functional and cosmetic outcome, although complication rates up to 25% are reported (Flynn et al. 2010, Antabak et al. 2013, Sinikumpu et al. 2013). The majority of complications are associated with technical errors made by inexperienced surgeons (Slongo 2005). Compartment syndrome might be the most severe complication associated with intramedullary nailing. The reported rate of compartment syndrome varies from 1.5% to 7% (Flynn et al. 2010, Martus et al. 2013). The rate of other severe complications, such as lesions of the superficial radial nerve, delayed union, or non-union is less than 2% (Lascombes et al. 1990, Cullen et al. 1998, Jubel et al. 2005, Fernandez et al. 2009, Fernandez et al. 2010 (B)). Re-fractures after intramedullary fixation are reported from 0.5% to 8.5% of cases (Lascombes et al. 1990, Schmittenebecher et al. 2000, Sinikumpu et al. 2013). A less severe and the most common complication is skin irritation at the nail entry site, which accounts for almost 90% of all complications. Although the complication



**Figure 13.** A displaced antebrachium fracture in 8-year-old boy treated with TENs.

is considered minor, it can potentially lead to skin infection and osteomyelitis (Lascombes et al. 1990).

#### 2.5.4 Management of femoral shaft fractures

Almost 70% of paediatric femoral fractures locate in the diaphyseal area (Blount 1955). There are multiple treatment options for femoral diaphyseal fractures depending on the patient age and individual circumstances (Table 4.) (Musgrave et al. 2002). Infants up to six months of age rarely require a formal reduction as the periosteum is thick and the remodelling potential is remarkable. The majority of infant femoral fractures are considered stable and immobilisation with a Pavlik harness or von Rosen splint is commonly used. Only in rare fractures with excessive shortening of more than 2 cm or failure to immediately align the fracture is spica casting required because traction rarely is necessary (Stannard et al. 1995, Morris et al. 2002). Deformity of up to 10° of varus or valgus, 15° of anterior or posterior angulation, as well as shortening up to 15 mm is tolerated in patients younger than six years of age because of the remarkable remodelling potential in this age group.

In children younger than six years, Bryant traction followed by delayed hip spica casting or immediate hip spica casting is usually the best treatment option. The advantages of a spica cast include low cost, although the cast is applied under anaesthesia in the operating room or sedation unit. The procedure is safe and offers an excellent outcome (Allen et al. 1977). On the other hand, the spica cast treatment requires significant parental commitment and participation for the patient care. During the six weeks immobilisation, patient hygiene, transportation and home care is depended on parents or other care-giver help (Nafei et al. 1992, Cox and Clarke 1997). Complications ontraction and hip spica casting are rare but compartment syndrome has been reported in patients with both hip and knee in 90° flexion. To avoid this complication it is advisable to avoid traction on a short leg cast, leaving the foot out of the cast as well as to decrease the hip and knee flexion (Mubarak et al. 2006).

In school-aged children, the remodelling potential is lesser than in younger children. Furthermore, long-term skeletal traction and subsequent treatment with a hip spica cast is poorly tolerated (Flynn and Schwend 2004). External fixation allows rigid fixation of the reduced fracture without physeal injury and without the need for knee immobilisation. Implant removal is also easy. The disadvantages of the method include pin-tract infections, risk for a subsequent fracture through previous pin sites, and quadriceps muscle fibrosis around the pin tracts (Musgrave and Mendelson 2002).

In diaphyseal femoral fractures in patient with head-injury, multiple injuries or with severe soft tissue injury and open fractures, external fixation can be considered. Although elastic stable nail has decreased the use of external fixation as a primary device, patients with necessitate intensive nurcing care benefits fast and stable fixation offered by external fixation (Krettek et al. 1991, Bar-On et al. 1997, Tomaszewski and Gap 2014). Complications concerning external fixation consist mostly of pin traction infections,

scarring and re-fractures. In prospective randomized study by Bar-On et al. (1997) elastic stable nail and external fixation was compared. In the study was found that early post-operative recovery was similar but patients with elastic stable nail returned to school and full activity earlier than patients treated with external fixation. Also the patient subjective satisfaction for the treatment was higher in elastic stable nails group (Bar-On et al. 1997).

Comparing traction and hip spica cast as well as external fixation to stable elastic intramedullary nailing, the nailing procedure provides many advantages (Moroz et al. 2006, Slongo et al. 2004). The elastic intramedullary nailing technique is minimally invasive. The procedure offers early knee joint mobilisation to maintain muscle tone and reduce joint stiffness. Hospitalisation duration is relatively short. In addition, psychological recovery is accelerated by early resumption of functional activity, allowing for a rapid return to school and ordinary family life (Parsch et al. 1997, Stans et al. 1999, Slongo et al. 2004, Song et al. 2004).

The most common technique for elastic stable nail insertion is retrograde through a small lateral and medial incision just above the distal femoral physis. Some orthopaedists, however, prefer an antegrade technique with entry in the subtrochanteric area (Bourdalet 1996, Fricka et al. 2004). The primary limitation of elastic intramedullary nailing is the lack of rigid fixation. To prevent fracture instability the nail/medullary canal diameter ratio of the narrowest site of the medullary canal should be up to 80%, so each nail ND/MD ratio should be 40% and both nails should be of the same size. The midportion of the nails at the level of fracture site should bend to 30° before installing to further stabilise the fracture (Ligier et al. 1988). The distal nail ends should be trimmed to 1 to 2 cm from the cortex and applied close to the surface of the bone at the level of the physis to avoid nail end irritation in the subcutis and skin (Parikh et al. 2012). Although elastic intramedullary nailing is popular, it's disadvantages are hardware removal and complication rates as high as 60% (Lascombes et al. 2006, Moroz et al. 2006, Parikh et al. 2012). The intramedullary nailing (ESIN) provides best outcome for patients younger than 12 years and lighter than 50 kg (Figure 14.). Most of the complications are due to poor patient selection and incorrect operative technique (Ho et al. 2006, Moroz et al. 2006). The most common reported complication is soft-tissue irritation at the nail entry site (Lascombes et al. 2006, Ho et al. 2006, Moroz et al. 2006). Although nail prominence is inconvenient in soft tissue, it can also result in more serious complications, such as skin breakdown and superficial or deep soft tissue infection. The infection can also spread further into the bone, leading to osteomyelitis and subsequently early implant removal with a risk of re-fracture (Flynn et al. 2001, Flynn et al. 2004). Up to 16% of reported complications concern fracture instability (Ligier et al. 1988, Ho et al. 2006).

Children older than 12 years and especially adolescents with closed physis are frequently treated as adults. Antegrade rigid intramedullary nails have the advantages of small skin incision and stable fixation without automatic hardware removal. The disadvantages of adult type intramedullary nails include a potential injury to the proximal and distal physis

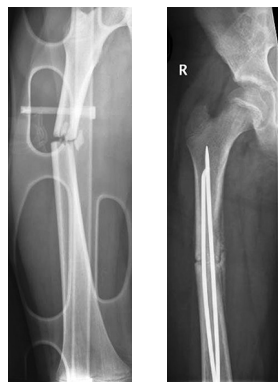

as well as to the blood supply or avascular necrosis in patients with an open physis. In order to avoid these iatrogenic complications, adolescent femoral nails are advisable for patients older than 12 as the nail entry point is on the lateral side of trochanter (Musgrave and Mendelson 2002, McNeill et al. 2011).

Standard compression plating with open reduction has only few indications while submuscular bridge plating is used for unstable or comminuted fractures and fractures with severe soft tissue injury (Ward et al. 1992, Kregor et al. 1993). The disadvantage of plating in open reduction is the extensive dissection with periosteal stripping, which may lead to overgrowth. In both open and submuscular plating, the locking screws can cold-weld to the plate turning a simple implant removal into a difficult procedure (Kregor et al. 1993, Fyodorov et al. 1999).

**Table 4.** Aligning guidelines for diaphyseal femoral fractures.

Patient age	Treatment method
0–2 years	Pavlik harness, spica-cast, traction and spica cast
2–5 years	Spica-cast, traction and spica-cast, external fixation (elastic stable intramedullary nail)
6–10 years	Elastic stable intramedullary nail, external fixation, plate fixation
10 years and older	Elastic stable intramedullary nail, lateral femoral nail, rigid intramedullary nail, external fixation, plate fixation



**Figure 14.** A femoral shaft fracture in a 10-year-old boy treated with TENs.

## 2.6 The Finnish National Hospital Discharge Registry

The Finnish National Hospital Discharge Registry (NHDR) is one of the oldest individual level hospital discharge registers in the world. It was founded in 1967 and the information is collected equally from all hospital categories (private, public, and other). All institutions in Finland are obligated to collect and submit the data to the NHDR. All hospitalised patients are included in the register. The NHDR contains data on patient age,

sex, and domicile; length of hospital stay; primary and secondary diagnosis; and surgical interventions performed during the hospital stay. It has been intensively used for research purposes as its validity is excellent regarding both coverage and accuracy of the database (Salmela and Koistinen 1987, Keskimäki and Aro 1991, Mattila et al. 2008, Sund 2012). A limitation of the registry is that it is inadequate in the recording of subsidiary diagnosis as well as secondary operations and other rarely used items (Sund 2012). This limitation does not compromise the value of the data in NHDR, however, for use in studies that are not otherwise feasible (Sund 2012).

### 3 AIMS OF THE RESEARCH

The purpose of this thesis was to study certain clinically important aspects of upper extremity fractures and elastic titanium intramedullary nailing. The specific aims of the study were as follows:

1. To assess the incidence and changes of hospitalisation as well as the incidence of surgery for humeral shaft fractures among persons 0 to 16 years of age in Finland between 1987 and 2010.
2. To assess the incidence and changes of hospitalisation as well as the incidence of surgery for distal humeral fractures among persons 0 to 18 years of age in Finland between 1987 and 2010.
3. To critically assess the complications associated with antebrachium fractures treated with TENs in Tampere University Hospital between 2001 and 2005.
4. To critically assess the complications associated with diaphyseal femoral fractures treated with TENs in Tampere University Hospital between 2003 and 2007.

## 4 MATERIALS AND METHODS

### 4.1 Patient data

This doctoral dissertation comprises four separate retrospective studies. The first two studies explored changes in the incidence of hospitalisation and treatment performed in operating room in cohorts of children and adolescents with a diaphyseal or a distal humeral fracture during the past 24 years. The third and fourth studies evaluated complications associated in antebrachium and diaphyseal femoral TEN-nailing. For this purpose, four separate studies were performed and subsequently four different patient data sets were studied.

#### 4.1.1 Study I

Study I was conducted to obtain population-based epidemiological data on humeral shaft fractures. The study covered the entire paediatric and adolescent population (aged <17 years) of Finland during a 24-year period, from 1 January 1987 through 31 December 2010. Data from 1165 patients hospitalised for humeral shaft fractures were obtained from the statutory, computer-based NHDR. A total of 585 procedures were performed in operating room on these subjects. The mean age of the hospitalised children was 10.5 years (10.8 in boys and 10.1 in girls).

#### 4.1.2 Study II

Study II was conducted to obtain population-based epidemiological data on distal humeral fractures. The study covered the entire paediatric and adolescent population (aged <19 years) of Finland during a 24-year period, from 1 January 1987 through 31 December 2010. A total of 12 585 patients were hospitalised with a main or secondary diagnosis of distal humeral fracture. The total number of primary procedures performed in operating room to treat these fractures was 5548. Boys comprised the majority of the patients (n=7487, 60%; girls n=5098, 40%). The mean age of the hospitalised children was 10.5 years (10.8 in boys and 10.1 in girls).

### 4.1.3 Study III

This retrospective series comprised 75 patients younger than 18 years of age with a main diagnosis of antebrachium fracture in Tampere University Hospital during the five-year study period, from 1 January 2001 through 31 December 2005. The data comprised patient charts and radiographs and were collected from the hospital archives. The study included 35 consecutive patients treated with TEN-nailing. The age of the patients ranged from 5.2 years to 17.4 years, with a mean age of 12.3 years. The majority of patients, 20 (75%) were boys. Sixteen (46%) of the injuries were sustained in a fall.

### 4.1.4 Study IV

This study group included patients younger than 18 years of age with a main diagnosis of diaphyseal femoral fracture collected retrospectively from the electronic hospital registry of Tampere University Hospital from 1 January 2003 through 31 December 2007. The data comprised patient charts and radiographs and were collected from the hospital archives. One hundred and two patients were treated as inpatients during the five-year study period. The study included 32 consecutive patients younger than 16 years of age treated with TEN-nailing. Of these patients, 22 (70%) were boys and 10 (30%) girls. The age of patients ranged from 5 to 16, with mean age of 9 years for both boys and girls.

## 4.2 Methods

### 4.2.1 Studies I and II

To calculate the incidence of humeral shaft and distal humeral fractures leading to hospitalisation the data were obtained from the NHDR. In study I, the main outcome variable was the number of patients hospitalised with a main or secondary diagnosis of humeral shaft fracture (ICD-9 codes 8122A and 8123A in 1987–1996 and ICD-10 code S42.3 in 1997–2010). To calculate the incidence of treatment performed in operating room, ICD-9 procedural codes 9123 (reposition and cast), 9126 (closed reposition and osteosynthesis), and 9128 (open reduction and osteosynthesis) were included in the study. During the study period the ICD-codes changed in 1997 and thereafter the corresponding ICD-10 codes were NBJ41 (reposition and cast), and NBJ60 and NBJ40 (reposition and osteosynthesis).

In study II, the main outcome variable was the number of patients hospitalised as inpatients with a main diagnosis of distal humeral fracture (ICD-9 codes 8124A and 8125A in 1987–1996 and ICD-10 code S42.4 in 1997–2010). The procedure codes were ICD-9 from 1987 to 1996 and ICD-10 from 1997 to 2010. The ICD-9 procedural codes

included in the study were 9123 (reposition and cast), 9128 (closed or open reposition and osteosynthesis), 9130 (external-fixation), and 9139 (other distal humeral fracture operation). The corresponding ICD-10 codes were NBJ41 (reposition and cast), NBJ64 (reposition or reduction and osteosynthesis), NBJ70 (external-fixation), and NBJ91 (other distal humeral fracture operation).

In both studies, the annual mid-year population was obtained from the Official Statistics of Finland, an electronic national population register. Statistical analyses were performed using PASW ver. 19.0 (SPSS, Chicago, IL). The incidence figures were thus the true results concerning the entire adolescent population in Finland rather than cohort-based estimates during the study period.

#### 4.2.2 Studies III and IV

Study III comprised 35 children and adolescents with antebrachium fractures treated with TEN-nailing at Tampere University Hospital in Finland during a five-year period from 1 January 2001 through 31 December 2005. The data were collected retrospectively by searching for patients with a main diagnosis of antebrachium fracture and two operation codes (NFJ60, NFJ64) from the electronic hospital registry. Study IV comprised 32 children younger than 18 years treated with TEN-nailing at Tampere University Hospital in Finland during a five-year period from 1 January 2001 to 31 December 2005. The data was collected from patients with a main diagnose of femoral diaphyseal fracture (S72.3) and two operative codes (NFJ60, NFJ64).

In both studies the information obtained from patient files included patient age, sex, weight, injury mechanism, and fracture type. Fractures were classified according to the Orthopaedic Trauma Association and Gustilo-Anderson classifications. The surgical technique for fixation and complications were recorded from pre- and postoperative X-rays and patient records. To evaluate discomfort caused by the TEN, in femoral fractures nail tip prominence was recorded as the maximum transverse distance measured from the surface of the femur to the distal tip of the nail on the anterior-posterior or lateral radiographs. For antebrachium fractures, patient reported discomfort at the TEN entry site was recorded as a complication. The TEN/medullary canal diameter ratio and fracture site movement between intra- and post-operative X-rays to evaluate fracture instability. The fracture was considered unstable immediately after the operation if there was any movement between intraoperative and post-operative X-rays. Fractures with later angulation were also considered unstable. Statistical analysis was not performed because of the small number of patients.

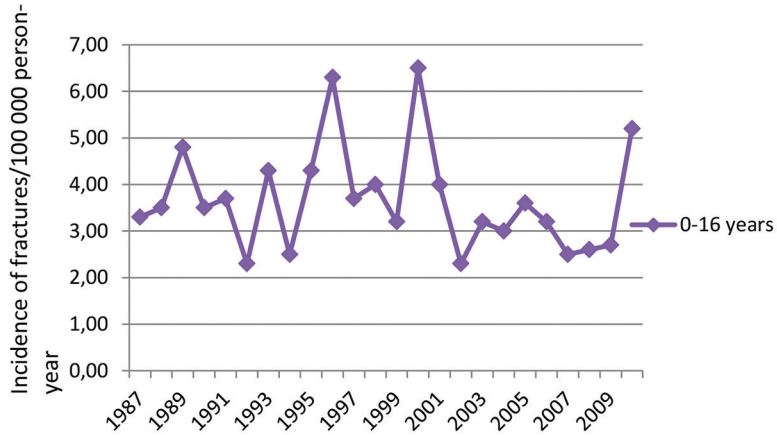
## 5 RESULTS

This section reviews the main results of the four studies included in this thesis. Further details are presented in the original articles.

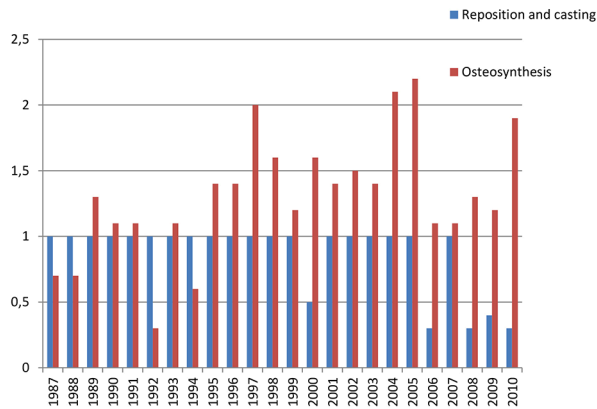
### 5.1 Study I

The main outcome of this study was the stable incidence of humeral shaft fractures and treatment performed in operating room during the 24-year study period. The overall incidence of hospitalisation was 4.8 per 100 000 person-years. The incidence increased only among girls from 3.3 per 100 000 person-years in 1987 to 5.3 per 100 000 person-years in 2010 (Figure 15.). Although the increase was significant, it must be considered that the total number of patients was small and the changes may be due to normal annual variation. The incidence of treatment including reposition and casting or osteosynthesis in the operating room remained low and stable (Figure 16.). A total of 585 procedures were performed in operating room during the study period. The number of osteosynthesis procedures was 323 and the overall incidence was 1.4 per 100 000 person-years (Figure 17.). The incidence was lowest in patients younger than 6 years, with a mean of 0.5 per 100 000 person-years, and highest in patients aged 13 to 16 years, with a mean of 2.5 per 100 000 person-years. The total number of fractures treated with intramedullary nailing was 79 and the incidence of procedure was 0.3 per 100 000 person-years.

A total of 262 patients were treated with closed reposition and casting with an overall incidence of the procedure of 1.1 per 100 000 person-years. The highest incidence of closed reposition and casting was in patients aged 7 to 12 years, with a mean 1.3 per 100 000 person-years (Figure 18.). A total of 580 (49%) patients were hospitalised without intervention in operating room.

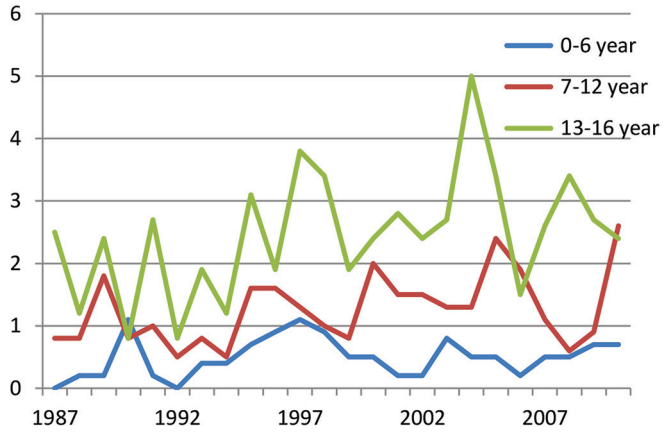


**Figure 15.** The incidence of humeral shaft fractures among girls between 1987 and 2010.

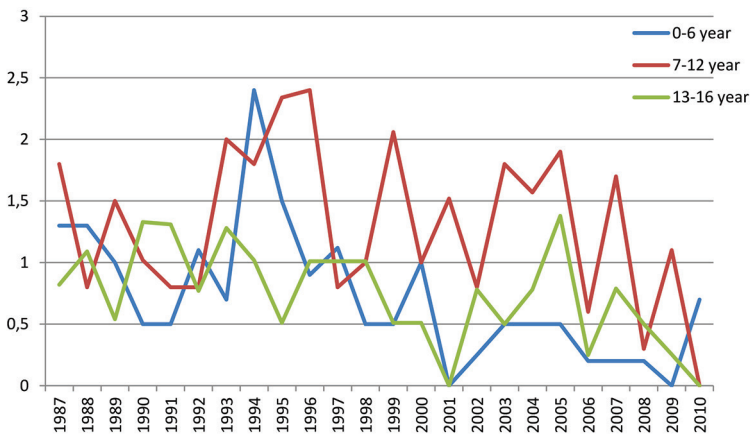


**Figure 16.** The annual incidence (1/100 000 person-years) of treatment performed in operating room among all patients between 1987 and 2010.





**Figure 17.** The annual incidence (1/100 000 person-years) of osteosynthesis in humeral shaft fractures among girls and boys between 1987 and 2010.

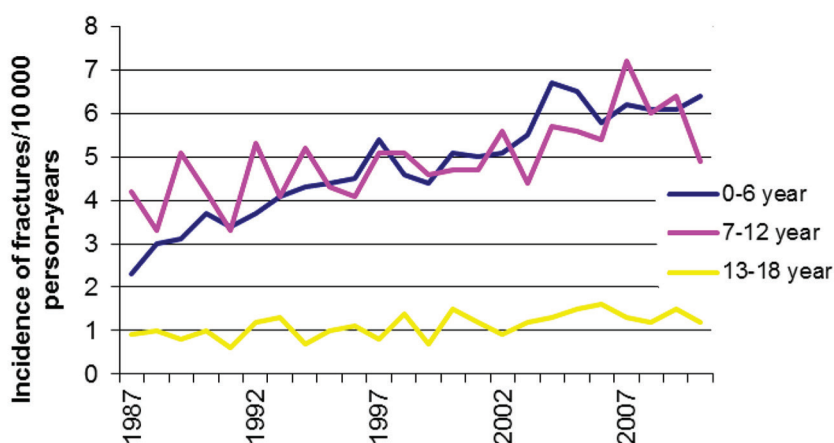


**Figure 18.** The annual incidence (1/100 000 person-years) of reposition and casting in humeral shaft fractures among girls and boys between 1987 and 2010.

## 5.2 Study II

The main outcome of this study was a significant increasing trend of hospitalisation and operative treatment in patients with distal humeral fractures. The total number of patients hospitalised due to a distal humeral fracture was 12 590 between 1987 and 2010. The overall person-based hospitalisation incidence for distal humeral shaft fractures was 5.6 per 10 000. The incidence of hospitalisation increased most in children younger than 13 years of age, up to 30%, from 4.5 per 10 000 in 1987 to 5.8 per 10 000 in 2010 (Figure 19). In girls younger than seven years, the incidence of hospitalisation significantly increased from 2.3 per 10 000 in 1987 to 6.4 per 10 000 in admissions. The same trend, although not so marked, was detected in boys younger than seven years, whose respective admissions figures increased from 3.7 per 10 000 to 6.8 per 10 000 (Figure 20.).

A total of 5548 procedures performed in operating room were recorded (Figure 21.). The most common treatment method was reduction with osteosynthesis ( $n=4703$ ) of which the incidence increased markedly during the follow up period. The incidence of osteosynthesis as a chosen treatment modality increased 5-fold in patients younger than 6 years and 2-fold in patients 7 to 12 years of age. The absolute figures being 0.6 and 1.4, respectively, in 1987 and 3.0 and 3.4 in 10 000 in 2010 (Figure 22.). The incidence of reposition and casting i.e. conservative treatment remained steady with the highest overall incidence being in children younger than 7 years, 0.9 per 10 000. In children aged 7 to 12 years the incidence of reposition and casting decreased slightly as the operative management with osteosynthesis increased. In adolescents older than 13 years of age, there were no changes in the incidence of hospitalisation or chosen treatment methods.



**Figure 19.** The annual incidence of distal humeral fractures among girls between 1987 and 2010.

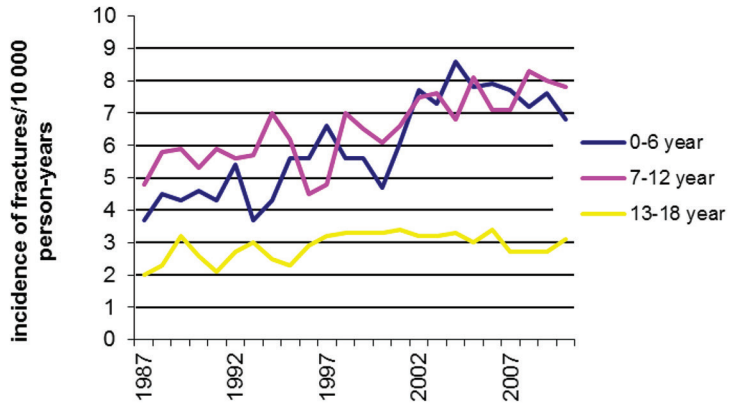


Figure 20. The annual incidence of distal humeral fractures among boys between 1987 and 2010.

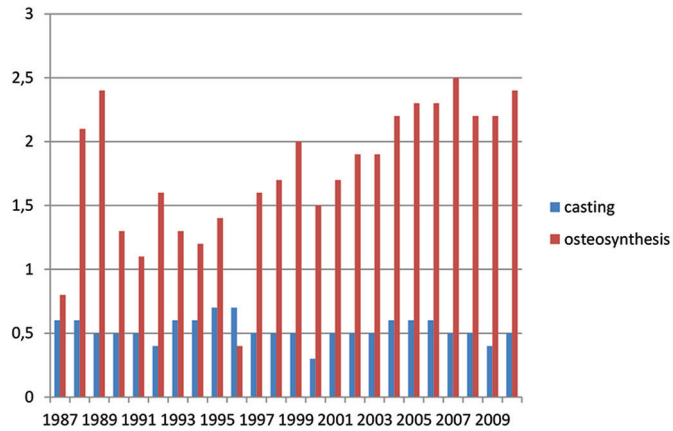
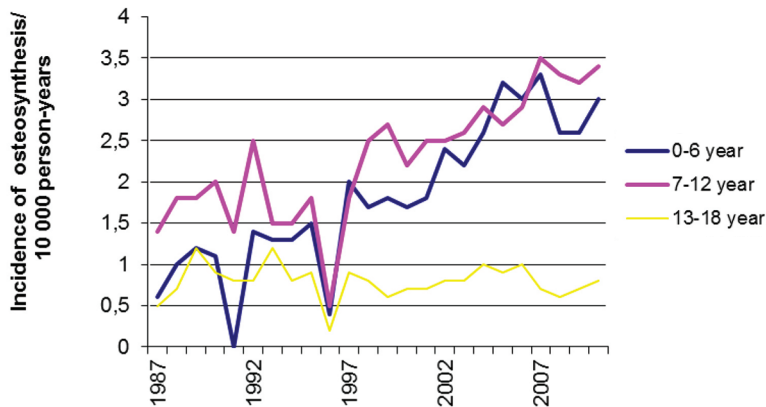


Figure 21. The annual incidence (1/10 000 person-years) of treatment in operating room among all patients between 1987 and 2010.



**Figure 22.** The annual incidence of osteosynthesis among girls and boys between 1987 and 2010.

### 5.3 Study III

In study III, we evaluated 35 consecutive patients with antebrachium fracture treated with TEN-nailing and postoperative casting. Twenty-three (66%) fractures united without any complications. Five (14%) patients had short-term and seven (20%) had long-term problems during the follow up period (Table 5.). The complication rate was higher in patients over 10 years of age. Complications were mostly associated with inadequate TEN-nail technique, such as leaving the nail prominent toward the skin. In three patients, ulnar nail prominence caused discomfort at the nail insertion site. In one case, the TEN was not inside intramedullary canal after the operation. Fracture instability immediately after operative treatment was noted in one patient and neurapraxia in three patients. In one patient, compartment syndrome was recorded after the primary operation. In addition, three re-fractures were recorded, in two cases the radius was fixed with TENs and the ulna with K-wire or a plate. In one case, the patient returned to participating in sports earlier than advised and sustained a fracture after an accident. All re-fractures were repaired with plating. Even with the various complications, the long-term outcomes were good as all fractures healed without residual functional impairment.

**Table 5.** List of individual complications and timing of the notification of the forearm fractures treated with TENs.

Patient number	Pre-op	Post-op	5 weeks	8 weeks	12 weeks	Follow-up control
1	Median nerve deficit	Median nerve neuropraxia			Supination deficit, delayed union	Re-fracture
2		Nail discomfort				
3				Supination deficit		
4	Ulnar nerve deficit		Compartment syndrome			
5		Fracture instability				
6			Nail discomfort			
7			Volar angulation, nail discomfort			
8				Nail discomfort		Infection after nail removal
9		Radial nerve deficit				
10		Ulnar nail malposition				
11				Non-union		Re-fracture
12				Re-fracture		

## 5.4 Study IV

In study IV, we retrospectively evaluated 32 consecutive patients with diaphyseal femoral fracture treated with TEN-nailing. All fractures had united within three months of injury. Nine (28%) patients reported a postoperative complication. Complications were associated with nail prominence in five (16%) patients and instability in four (12%) patients. In patients with nail prominence, the TEN-nail ends were unbent and 10 mm to 35 mm outside the cortex of the distal femur compared to patients without complications (<10 mm). In patients with recorded fracture instability, the mean TEN-nail/medullary canal diameter ratio was 46% (compared to 66% in patients without complications) and movement between intra-operative and post-operative x-rays was observed. In addition, periosteal callus formation was prolonged. In patients without complications the width of the periosteal callus seen on a radiograph taken at 5 weeks after the TEN insertion was almost twofold that of patients with complications.

## 6 DISCUSSION

### 6.1 Incidence of hospitalisation for humeral shaft and distal humeral fractures

In Studies I and II, we evaluated the incidence of hospitalisation and treatment methods performed in operating room for humeral shaft and distal humeral fractures. The reported incidence of upper extremity fractures is increasing, although the overall incidence of fractures is decreasing (Chung and Spilson 2001, Helenius et al. 2009, Mäyränpää et al. 2010, Sinikumpu et al. 2013). Most of the fractures occurred in school-aged children. Although the incidence of humeral shaft fractures has remained low during the past 24 years, the incidence of distal humeral fractures has increased markedly. The difference in injury mechanism may partly explain the divergence in incidence. All but pathological diaphyseal humeral fractures require a high-energy twisting or transverse force, as the fractures are frequently associated with multiple traumas often related to traffic accidents (Fisher 1958, Shaw et al. 1997, Tsai et al. 2009). In distal humeral fractures, the injury mechanism is often a relatively low-energy fall from a playground object onto an outstretched hand (Fransworth et al. 1998, Villarin et al. 1999, Loder 2008). In addition, leisure-time physical activities like playing on the monkey bars, swings, and slides as well as popularity of motor vehicles may lead to fractures, but especially jumping on a trampoline has markedly increased the incidence of all paediatric injuries and particularly supracondylar fractures (Smith 1998, Hurson et al. 2007, Klimek et al. 2013, Loder 2008, Barr 2014, Loder et al. 2014). Based on a nationwide report by Loder et al. (2014) in the United States, elbow region fractures caused by jumping on a trampoline most often occur in children younger than 7 years of age with male predominance. In our population-based studies, there was also male prominence, but interestingly the increase in both humeral shaft and distal humeral fractures requiring hospitalisation mostly occurred in girls. In distal humeral fractures, the increase was almost 3-fold in preschool girls. In girls younger than 17 years, there was a 1.5-fold increase in hospitalisation for humeral shaft fractures while the incidence of these fractures decreased among boys of the same age. The same trend has reported in Sweden by Tiderius et al. (1999) in forearm fractures. The increasing fracture incidence in girls may be explained by the greater equality of sexes in northern countries as girls participate in the same sports as boys with the same activity level, a trend

that may be consistent with the increase in active female role models (as seen in cinema, and toys and cartoons targeting girls).

## 6.2 Increasing incidence of operative managements in distal humeral fractures

Although most clinical studies concerning children's fractures do not support more operative management, there is an increased interest toward operative management for upper extremity fractures in children as well as in adults (Flynn et al. 2003, Helenius et al. 2009, Mattila et al. 2011, Huttunen et al. 2012, Eismann et al. 2013). In our study, operative management of distal humeral fractures had an increasing trend. During the 24-year study period, the incidence of osteosynthesis increased 5-fold in patients younger than 6 years and 2-fold in patients 7 to 12 years of age. Based on earlier studies of elbow-region fractures in children, most distal humeral fractures are supracondylar fractures and the incidence of supracondylar fractures is increasing (Beekman and Sullivan 1941, Hanlon and Estes 1954, Weise et al. 1997, Laudenhaf et al. 2014, Loder et al. 2014). In our study, we assumed that the changes in fracture treatment were related to supracondylar fractures as the diagnosis and procedural codes of all distal humeral fractures are the same. Operative management with pinning is reported to be a relatively safe procedure as complication rates after closed or open reduction with an anterior approach and pinning are less than 5%. The operative treatment is also cost and time effective method compared to conservative treatment. (Khan et al. 2005, Bashyal et al. 2009, Ersan et al. 2009, Liu et al. 2011.) The functional and cosmetic outcome in unstable (Gartland II and III) fractures is reported to be better after operative treatment than after conservative management (Ong and Low 1996, Khan et al. 2005). Although Spencer et al. (2012) reported good outcomes in Garland II type fractures treated only with reposition, very close follow-up is needed to avoid complications and the majority of authors recommend an operative approach as the remodelling potential is limited after malunited supracondylar fractures (Persiani et al. 2012, Spencer et al. 2012, Buckvić et al. 2013). The overall interest toward operative management and good functional and cosmetic outcomes of operative reduction with relative low complication rates without concern of reduction loss may explain the increasing operative rates. There is also a socioeconomical aspect, as both parents and trauma clinics with limited economical and time resources may have increased willingness to operate, as multiple follow-up visits to the clinic are not needed.

In our study, there was no change in the operative treatment of patients older than 13 years of age as it is assumed that these patients are near adult age and will be treated over time as adults.

### 6.3 Low incidence of operative management in humeral shaft fractures

In contrast to increasing operative management of distal humeral fractures, there were no changes in the fracture management of humeral shaft fractures, as the incidence of all managements performed in operating room remained low and steady level. There is increasing interest in intramedullary nailing in humeral shaft fractures as the method is reported to produce an excellent outcome with early mobilisation and rapid pain reduction without need for a cast (Zatti et al. 1998, Lascombes et al. 2006, Fernandez et al. 2010 (A), Garg et al. 2008, Gordon and Garg 2010). In the Finnish population, the incidence of TEN-nailing remained very low as only 79 humeral shaft fractures were treated with TEN-nailing during the 24-year study period. The remodelling potential of humeral shaft fractures is remarkable and the remaining residual angulation is well tolerated in all age groups (Beaty 1992). The good functional and cosmetic outcome without the risk of iatrogenic operative complications may explain the unwillingness to change conservative management to an operative approach.

### 6.4 Complications of TEN-nailing in diaphyseal antebrachium and femoral shaft fractures

In Studies III and IV, we evaluated complications of TENs diaphyseal antebrachium and femoral fractures. Elastic stable intramedullary nailing, utilizing TENs, has become a very popular method for treating long-bone fractures in children as the short- and long-term outcomes are generally good (Schmittenebecher et al. 2000, Garg et al. 2008, Fernandez et al. 2009, Lieber and Sommerfeldt 2011). Although elastic stable intramedullary nailing is a relatively simple and safe procedure, complications are reported in up to 16% of patients. In diaphyseal antebrachium nailing, the most common complications are skin irritation or infections at the nail insertion site, accounting for up to 90% of reported complications, whereas transient nerve injuries, slight loss of reduction or motion, and delayed union, as well as severe complications such as compartment syndrome and permanent nerve injuries are observed less frequently (Cullen et al. 1998, Richter et al. 1998, Schmittenebecher et al. 2000, Jubel et al. 2005, Lascombes et al. 2006, Flynn et al. 2010). In Study III, which evaluated complications of diaphyseal antebrachium fractures in a relatively small paediatric trauma centre, the total complication rate was 34%. One-half of the complications were associated with inadequate surgical technique as one nail protruded, one nail was not in the intramedullary canal, three patients suffered discomfort caused by nail prominence, and one patient's fracture was unstable after surgery. As reported by Lascombes et al. (2006) and Weinberg et al. (2008), the principles of TEN-nailing are quite simple, but the surgeon must be aware of the biomechanical aspects of the management, such as proper nail size, and symmetry of the frame and orientation of the implants (Lascombes et al. 2006, Weinberg et al. 2008). In Study III, patients with re-fracture were identified. In two cases,



delayed union occurred in patients whose radius was nailed and the ulna fixed with a K-wire or plate. These patients sustained a re-fracture, one of whom returned to participating in sports too early. In our limited series, combined semi-rigid and rigid management led to complications, probably due to the different biomechanical qualities of the devices. All but one of the complications (return to participating in sports without permission), could have been avoided by a better understanding of the TEN technique.

In Study IV, we evaluated the complications of TENs for femoral shaft fractures. According to Palmu et al. (2013) treatment of all femoral fractures in Finland has changed from non-operative to more operative (Palmu et al. 2013). The advantages of TENs include its minimal invasiveness and the ability for direct mobilisation to maintain joint movement and muscle tone as well as normal circulation. Hospitalization is usually short term and reduces the treatment cost compared to traditional treatments for traction and spica cast (Heinrich et al. 1994, Mazda et al. 1997, Parsch et al. 1997, Flynn et al. 2001, Flynn et al. 2004, Hunter 2005). Although long term results in conservative treatment are good the socioeconomical pressure (home care, parents and hospital resources etc.) leads to choose operative treatment instead of conservative treatment (Sanders et al. 2001, Palmu et al. 2010). Elastic titanium nailing is currently the most popular operative method for femoral diaphyseal fractures in school-aged children, although complication rated as high as 60% is reported (Flynn et al. 2001, Sanders et al. 2001, Palmu et al. 2010, Sink et al. 2010, Baldwin et al. 2011). The severity of complications varies from temporary skin irritation at the nail entry site to angular malalignment leading to premature knee-joint arthritis. Majority of the reported complications concern skin irritation at the nail entry site. These can potentially lead to superficial skin infection or deep subcutaneous infection. Complications such as delayed union, and angular and rotational malunion, are reported after inadequate fracture stability. If spiral fracture is evaluated instable after two nails insertion, Kaiser et al. (2014) recommends insertion of 3<sup>rd</sup> nail. Although the principal idea of TENs is tension between two nails, it seems that the 3<sup>rd</sup> nail increases significantly fracture stiffness and prevents need of re-operation (Kaiser et al. 2014). With careful preoperative planning and clinical examination during operation most of the complications are potentially avoidable. (Ligier et al. 1988, Luchmann et al. 2003, Ho et al. 2006, Lascombes et al. 2006, Wall et al. 2008.) Most problems arose from skin irritation caused by prominent nail ends at the fracture entry site as reported also Flynn et al. 2001, Lascombes et al. 2006 and Baldwin et al. 2011. The other notable complication was fracture instability due to the use of too-thin nails. The instability problem is associated especially in patients heavier than 50kg and older than 10 years. The selection of proper nails size is essential as to prevent instability. The ND/MD ratio should be 80% of the narrowest intramedullary canal diameter (Flynn and Schwend 2004). In our study there was no association of complications and surgeon experience (resident/senior), time of surgery, or mode of reduction. In retrospective evaluation most of the complications could have been avoided by more careful clinical practice. The selection of wide enough nails and inadequate TEN-nailing techniques would probably prevent

fracture instability and angular malalignment problems. At the end of the operation nail ends should have inspected by clinical examination and prominent nails should have been bend beside the bone to avoid skin irritation. To prevent long term complications, examination direct after the operation and during follow-up by careful clinical examination including skin inspection, knee mobilisation and radiographs is essential.

The most common complication, both in diaphyseal antebrachium and femoral fractures, was skin irritation at the nail entry site. These complications could have been avoided by inserting the TENs into the intramedullary canal which of course makes lateral retrieval difficult. There is an active debate concerning the removal of implants overall and especially removing TENs. While some authors still recommend routine removal of implants, there are also new controversial recommendations (Flynn et al. 2001, Korhonen et al. 2014). Based on a literature- and experience-based review by Korhonen et al. (2014), routine TENs removal in children older than 8 years is not recommended, although the decision must always be based on individual evaluation. The subject is controversial as the future risks of unremoved TEN-nails are not known due to lack of long-term follow-up studies. Removing an implant years after primary implantation requires a new surgery and can be difficult or even impossible due to bone growth.

## 7 CONCLUSIONS

The main findings of the present study can be summarised as follows:

1. The incidence of hospitalisation and management performed in operating room in children and adolescents younger than 17 years of age with humeral shaft fractures remained low between 1987 and 2010. There incidence of operative treatment was slightly higher (1.4 per 100 000 person-year) than conservative treatment (1.1 per 100 000). There were no changes in management methods during the 24 years study period. Although boys comprised the majority (62%) of patients, the incidence of hospitalisation increased among girls.
2. The incidence of hospitalisation and operative treatment of distal humeral fractures in children and adolescents aged 0–18 years of age increased between 1987 and 2010. The hospitalisation frequency increased 30% during the study period. Among girls younger than 7 years, the hospitalisation incidence increased the most. The incidence of operative reduction with osteosynthesis increased 5-fold in patients younger than 7 years and 2-fold in patients aged 7–12. The incidence of reposition and casting i.e. conservative treatment remained steady level, only among children aged 7–12 years the incidence of conservative treatment decreased slightly.
3. Postoperative complications concerning diaphyseal antebrachium and femoral TENs are mostly considered minor, as the final clinical outcome is good. Most of the complications are associated with inadequate technique.

## 8 ACKNOWLEDGEMENTS

This study was carried out at the Tampere University Hospital and University of Tampere, School of Medicine Finland.

Most of all, I owe my deepest gratitude to my official and unofficial doctoral supervisors docent Olli Pajulo, docent Tuija Lahdes-Vasama and professor Ville Mattila. No one embarking on scientific work could have hoped for a better mentors. I'm grateful to you Olli for introducing me to the world of pediatric orthopedics. The basic idea of this doctoral thesis was yours. This route has been long and rocky but you have become very close person to me as you have teach me very important things, not just about research, but also life itself.

I'm also very grateful to my chief and supervisor Tuija Lahdes-Vasama. Without any pressure you have got more than the best out of me. You helped and encouraged me when I needed it most. I appreciate your help in scientific writing and valuable comments during this process.

I don't know should I thank the intercity train from Helsinki to Tampere or colleague Liisa Pekkanen (who I deeply admire) for introducing me to professor Ville Mattila. I'm more than impressed for your professional skills in the field of research and I'm deeply honoured to work under your supervision. It has been marvellous to see your genius in drawing conclusions and expressing the core meaning of the data.

I wish to thank the official reviewers, docent Timo Hurme and docent Kari Vanamo, for your valuable comments and suggestions for improving my dissertation.

An irreplaceable role in my life belongs to my closest colleague Jarmo Välipakka. You are the one I'm always able to relay on, no matter what happens in any field of my life. You are my teacher and dear friend and I'm privileged to be the one who is always one step behind you. I wish one day I could be worth of you.

I wish to thank also my colleagues Annaleena Anttila (especially), Ritva Sihvonen, Tarja Iber, Eija Mäkelä, Arimatias Raitio for supporting me during these years.

I want to thank all my friends and relatives with whom I have been privileged to share this and many other journey during these years.

I wish to express my warmest gratitude to my parents Irma and Matti and my grandmother Martta (I'm so proud you are still going strong!) for your loving support, encouraging and believing in me through my life.

I should have dedicated this dissertation to Anu, Saimi and Niilo, my own family. I'm sorry, it was impossible as I know how much discomfort this process has caused to you. Thank you Anu for supporting and loving me, without your overall talent to take care of everything I wouldn't be able to climb this high and this dissertation would never been finished. But most of all I'm grateful of our two unbelievable treasures Saimi and Niilo, without them there is nothing.

Last but not least I want to thank my late grandmother Elma. You gave me strong family history and believe in future. You saw me and I know for sure that the light in my darkness is your love.

Kangasala, October 2014

A handwritten signature in black ink, appearing to read 'Anne', is centered on the page. The signature is written in a cursive, flowing style.

## 9 REFERENCES

- Ai-Aql ZS, Alagl AS, Graves DT. Molecular mechanisms controlling bone formation during fracture healing and distraction osteogenesis. *J Dent Res* 2008;87(2):107-118.
- Allen BL, Kant AP, Emery FE. Displaced fractures of the femoral diaphysis in children. *J Trauma* 1977;17:8-19.
- Antabak A, Luetic T, Ivo S, Karlo R, Cavar S, Bogovic M, Medacic SS. Treatment outcomes of both-bone diaphyseal paediatric forearm fractures. *Injury* 2013;44(3):S11-S15.
- Arkader A, Dormans JP. Pathologic fractures associated with tumors and unique conditions of the musculoskeletal system. In: Rockwood CA Jr, Beaty JH, Kasser JR, editors: *Fractures in Children*, 7<sup>th</sup> edition. Philadelphia, JB Lippincott, 2010:120-191.
- Badelon O, Bensahel H, Mazda K, Vie P. Lateral condylar fractures in children: a report of 47 cases. *J Pediatr Orthop* 1988;8:31-34.
- Baldwin K, Hsu J, Wenger D, Hosalkar HS. Treatment of femur fractures in school-aged children using elastic stable intramedullary nailing: a systematic review. *J Pediatr Orthop B* 2011;20(5):303-308.
- Bar-On E, Savig S, Porat S. External fixation or flexible intramedullary nailing for femoral fractures in children. A prospective, randomized study. *J Bone Joint Surg (Br)* 1997;79:975-978.
- Barr LV. Paediatric supracondylar humeral fractures: epidemiology, mechanism and incidence during school holidays. *J Child Orthop* 2014;8(2):167-170.
- Barry M, Paterson JMH. Aspects of current managements: flexible intramedullary nails for fractures in children. *J Bone Joint Surg* 2004;86(7):947-953.
- Bashyal RK, Chu JY, Schoenecker PL, Dobbs MB, Cuhmann SJ, Gordon JE. Complications after pinning supracondylar distal humerus fractures. *J Pediatr Orthop* 2009;29(7):704-708.
- Beals RK, Tufts E. Fractured femur in infancy: the role of child abuse. *J Pediatr Orthop* 1983;3:583-586.
- Beaty JH. Fracture of the proximal humerus and shaft in children. *Instr Course Lect* 1992;41:369-372.
- Beaty JH. Fractures of the lateral humeral condyle are the second most frequent elbow fractures in children. *J Orthop Trauma* 2010;24(7):438.
- Beaty JH, Kasser R. The elbow: Physeal fractures, apophyseal injuries of the distal humerus, osteonecrosis of the trochlea, and t-condylar fractures. In: Rockwood CA Jr, Beaty JH, Kasser JR, editors: *Fractures in Children*, 7<sup>th</sup> edition. Philadelphia, JB Lippincott, 2010:533-593.
- Bede WB, Lefebure AR, Rosmon MA. Fractures of the medial humeral epicondyle in children. *Can J surg* 1975;18:137-142.
- Beekman F, Sullivan JE. Some observations on fractures of long bones in children. *Am J Surg* 1941;51:722-738.

- Bernstein SM, King JD, Sanderson RA. Fractures of the medial epicondyle of the humerus. *Contemp Orthop* 1981;12:637-641.
- Blaisier RD, Salamon PB. Closed intramedullary rodding of pediatric adolescent forearm fractures. *Oper Tech Orthop*. 1993;3:128-133.
- Bloom T, Kobertson C, Mahar AT, Nexton P. Biomechanical analysis of supracondylar humerus fracture pinning for slightly malreduced fractures. *J Pediatr Orthop* 2008;28(7):766-772.
- Blount WP. Fractures in children. Baltimore: Williams & Wilkins, 1955.
- Borden S. Traumatic bowing of the forearm in children. *J Bone Joint Surg Am* 1974;56:611-616.
- Bourdalet D. Fracture of the femoral shaft in children: advantages of the descending medullary nail. *J Pediatr Orthop B* 1996;5:110-114.
- Brauer CA, Lee BM, Bae DS, Waters PM, Kocher MS. A systematic review of medial and lateral entry pinning versus lateral entry pinning for supracondylar fractures of the humerus. *J Pediatr Orthop* 2007;27(2):181-186.
- Buckvić N, Kvesić A, Brekaló Z, Bosak A, Buckvić K, Karlo R. The problem of post-traumatic varization of the distal end of the humerus remaining after the recovery of a supracondylar fracture. *J Pediatr Orthop B* 2013;22(4):273-275.
- Burks RT, Sutherland DH. Stress fracture of the femoral shaft in children: report of two cases and discussion. *J Pediatr Orthop* 1984;4(5):614-616.
- Carter DR, Spengler DM. Mechanical properties and composition of cortical bone. *Clin Orthop Res* 1987;135:192-217.
- Casey PJ, Moed BR. Greenstick fractures of the radius in adults: a report of two cases. *J Orthop Trauma* 1996;10:209-212.
- Caviglia H, Garrido CP, Palazzi FF, Meana N. Pediatric fractures of the humerus. *Clin Orthop* 2005;432:49-56.
- Cheng JC, Shen WY. Limb fracture pattern in different pediatric age groups: A study of 3,350 children. *J Orthop Trauma* 1993;7:15-22.
- Cheng JC, Shen WY, Ying SY, Lam PK. A 10-year study of the changes in the pattern and treatment of 6,493 fractures. *J Pediatr Orthop* 1999;19(3):344-350.
- Cheng JC, Lam TP, Maffulli N. Epidemiological features of supracondylar fractures of the humerus in Chinese children. *J Pediatr Orthop B*. 2001;10(1):63-67.
- Chung KC, Spilson SV. The frequency and epidemiology of hand and forearm fractures in United States. *J Hand Surg Am* 2001;26:908-915.
- Cooper C, Dennison EM, Leufkens HG, Bishop N, Van Staa TP. Epidemiology of childhood fractures in Britain: a study using the general practice research database. *J Bone Miner Res* 2004;19:1976-1981.
- Cox PJA, Clarke NMP. Improving the outcome of paediatric orthopaedic trauma: an audit of inpatient management in Southampton. *Ann R Coll Surg Engl* 1997;79:441-446.
- Crawford AH, Cionni AS. Management of pediatric orthopedic injuries by the emergency specialist. In: *Pediatric Critical Illness and Injury: Assessment and Care*. Rockville: Aspen System Publications, 1984:213-225.
- Creaseman C, Zaleske DJ, Ehrlich MG. Analyzing forearm fractures in children: the more subtle signs of impending problems. *Clin Orthop* 1984;188:40.
- Cullen MC, Roy DR, Giza E. Complications of intramedullary fixation of pediatric forearm fractures. *J Pediatr Orthop* 1998;18:14-21.
- Davids JR. Rotational deformity and remodeling after fracture of the femur in children. *Clin Orthop*. 1994;302:27-35.

- De Boeck H, De Smet P, Penders W, DeRydt D. Supracondylar elbow fractures with impaction of the medial condyle in children. *J Pediatr Orthop* 1995;15(4):444-448.
- EL Andaloussi Y, Yousri B, Aboumaarou M, EL Andaloussi M. Medial epicondylar fractures in children. *Chir Main* 2006;25(6):303-308.
- Einhorn TA. The cell and molecular biology of fracture healing. *Clin Orthop Relat Res* 1998;(355 Suppl):S7-S21.
- Eismann EA, Little KJ, Kunkel ST, Cornwall R. Clinical research fails to support more aggressive management of pediatric upper extremity fractures. *J Bone Joint Surg Am* 2013;7(15):1345-1350.
- Ersan O, Gonen E, Arik A, Dasar u, Ates Y. Treatment of supracondylar fractures of the humerus in children is a safe and effective method. *Int Orthop* 2009;33(5):1371-1375.
- Evans EM. Fractures of the radius and ulna. *J Bone Joint Surg Br* 1951;33:548-561.
- Fairbanks HAT, Buxton JD. Displacement of the internal epicondyle to the elbow joint. *Lancet* 1934;2:218.
- Farsetti P, Potenza V, Catrini R, Ippolito E. Long-term results of treatment of the medial humeral epicondyle in children. *J Bone Joint Surg Am.* 2001;83-A(9):1299-1305.
- Fernandez FF, Eberhardt O, Langendörfer M, Wirth T. Nonunion of forearm shaft fractures in children after intramedullary nailing. *J Pediatr Orthop (B)* 2009;18(6):289-295.
- Fernandez FF, Eberhardt O, Wirth T. Elastic stable intramedullary nailing as alternative therapy for the management of paediatric humeral shaft fractures. *Z Orthop Unfall* 2010 (A);148(1):49-53.
- Fernandez FF, Langendörfer M, Eberhardt O. Failures and complications in intramedullary nailing of children's forearm fractures. *J Pediatr Orthop B* 2010; 4(2):159-167.
- Fisher SH. Skeletal manifestations of parent-induced trauma in infants and children. *South Med J* 1958;51:956-960.
- Flynn JM, Luedtke L, Ganey T. Comparison of titanium elastic nails with traction and spica cast to treat femoral fractures in children. *J Bone Joint Surg Am* 2004;86:A770-777.
- Flynn JM, Hresko T, Reynolds RAK, Blasler RD, Davidson R, Kaser J. Titanium elastic nails for pediatric femur fractures: a multicenter study of early results with analysis of complications. *J Pediatr Orthop* 2001;21(1):4-8.
- Flynn JM, Sarwark JF, Waters PM, Bae DS, Lemke LP. The surgical management of pediatric fractures of the upper extremity. *Instr Course Lect.* 2003;52:635-645.
- Flynn JM, Jones KJ, Garner MR, Goebel J. Eleven years experience in the operative management of pediatric forearm fractures. *J Pediatr Orthop* 2010;(30):313-319.
- Flynn JM, Schwend R. Management of pediatric femoral shaft fractures. *J Am Acad Orthop Surg* 2004;12(5):347-359.
- Foead A, Penafort R, Saw A, Sengupta S. Comparison of two methods of percutaneous pin fixation in displaced supracondylar fractures of the humerus in children. *J Orthop Surg.* 2004; (1):76-82.
- Franklin CC, Wren T, Ferkel E, Arkader A. Predictors of conversion from conservative to operative treatment of pediatric forearm fractures. *J Pediatr Orthop B* 2014;23(2):150-154.
- Fransworth CL, Silva PD, Mubarak SJ. Etiology of supracondylar humerus fractures. *J Pediatr Orthop* 1998;18(1):38-42.
- Fricka KB, Mahar AT, Lee SS, Newton PO. Biomechanical analysis of antegrade and retrograde flexible intramedullary nail fixation of pediatric femoral fractures using synthetic bone model. *J Pediatr Orthop* 2004;24:167-171.



- Frost HM, Schonau E. The muscle bone uniting in children and adolescents: a 2000 overview. *J Pediatr Endocrinol Metab* 2000;13:571-590.
- Fuller DJ, McCullough CJ. Malunited fractures of the forearm in children. *J Bone Joint Surg Br* 1982;64(3):364-367.
- Fyodorov I, Sturm PF, Robertson WW Jr. Compression-plate fixation of femoral shaft fractures in children aged 8 to 12 years. *J Pediatr Orthop* 1999;19(5):578-581.
- Garg NK, Ballal MS, Malek IA, Webster RA, Bruce CE. Use of elastic intramedullary nailing for treating unstable forearm fractures in children. *J Trauma* 2008;65(1):109-115.
- Gartland JJ. Management of supracondylar fractures of the humerus in children. *Surg Gynecol Obstet* 1959;109:145-154.
- Gasco J, de Pablos J. Bone remodeling in malunited fractures in children. Is it reliable? *J Pediatr Orthop B* 1997;6(2):126-132.
- Caviglia H, Garrido CP, Palazzi FF, Meana NV. Pediatric fractures of the humerus. *Clin Orthop* 2005;432:49-56.
- Gerstenfeld LC, Cullinane DM, Barnes GL. Fracture healing as a post-natal developmental process: molecular, spatial, and temporal aspect of its regulation. *J Cell Biochem* 2003;88(5):873-884.
- Goldhaber P. Osteogenic induction across millipore filters in vivo. *Science* 1961;133:2065-2067.
- Gordon JE, Garg S. Pediatric humerus fractures: indications and technique for flexible titanium intramedullary nailing. *J Pediatr Orthop* 2010;30:73-76.
- Gosselin RA, Roberts I, Gillespie WJ. Antibiotics for preventing infection in open limb fractures. *Cochrane Database Syst Rev* 2004;(1).
- Gottschack HP, Eisner E, Hosalkar HS. Medial epicondylar fractures in the pediatric population. *J Am Acad Orthop Surg* 2012;20(4):223-232.
- Goulding A. Risk factors for fractures in normally active children and adolescents. *Med Sport Sci* 2007;51:102-120.
- Green E, Lubahn JD, Evans J. Risk factors, treatment, and functional outcomes associated with nonunion of the midshaft humerus fracture. *J Surg Orthop Adv* 2005 (A);14(2):64-72.
- Green DW, Widmann RF, Frank JS, Gardner MJ. Low incidence of ulnar nerve injury with crossed pin placement for pediatric supracondylar humerus fractures using a mini-open technique. *J Orthop Trauma* 2005 (B);19(3):158-163.
- Greenbaum B, Zionts LE, Ebramzadeh E. Open fractures of the forearm in children. *J Orthop Trauma* 2001;15:111-118.
- Grossman DC. Unintentional injuries in childhood. The future of children 2000, vl 10 no.1 [www.futureofchildren.org](http://www.futureofchildren.org).
- Güzel A, Atli A, Doğan E, Celik F, Tüfek A, Dusak A, Sen V, Yildirim ZB. Magnetic resonance imaging in children under anesthesia. The relationship between the degree of information provided to parents and parents' anxiety scores. *Biomed Res Int* 2014;2014:425107.
- Hanlon CR, Estes WL. Fractures in childhood: a statistical analysis. *Am J Surg* 1954;87:312-323.
- Hedström E M, Svensson O, Bergström U, Michno P. Epidemiology of fractures in children and adolescents. *Acta Orthop* 2010;81(1):148-51.
- Heideken J, Svensson T, Blomqvist P, Haglund-Åkerlind Y, Janarv PM. Incidence and trends in femur shaft fractures in Swedish children between 1987 and 2005. *J Pediatr Orthop* 2011;31(5):512-519.
- Heinrich SD, Drvaric DM, Darr K, MacEven GD. The operative stabilization of pediatric diaphyseal femur fractures with flexible intramedullary nails: a prospective analysis. *J Pediatr Orthop* 1994;14(4):501-507.

- Helenius I, Lamberg TS, Kääriäinen S, Impinen A, Pakarinen M. Operative treatment of fractures in children is increasing. A population-based study from Finland. *J Bone Joint Surg Am* 2009;91(11):2612-2616.
- Henry M, Riesenburger RI, Kryzanski J, Jea A, Hwang SW. A retrospective comparison of CT and MRI in detecting pediatric cervical spine injury. *Childs Nerv Syst.* 2013;29(8):1333-1338.
- Hines RF, Herndon WA, Evans JP. Operative treatment of medial epicondyle fractures in children. *Clin Orthop Res* 1987;221:170-174.
- Ho CA, Skaggs DL, Tang CW, et al. Use of flexible intramedullary nails in pediatric femur fractures. *J Pediatr Orthop* 2006;26(4):497-504.
- Houshian S, Mehdi B, Larsen MS. The epidemiology of elbow fracture in children: analysis of 355 fractures with special reference to supracondylar humerus fractures. *J Orthop Sci* 2001;6:312-315.
- Huber RI, Keller HW, Huber PM, Rehm KE. Flexible intramedullary nailing as fracture treatment in children. *J Pediatr Orthop.* 1996;16(5):602-605.
- Hunter J. Femoral shaft fractures in children. *Injury* 2005;36:A86–A93.
- Hurson C, Browne K, Callender O, O'Donnell T, O'Neil A, Moore DP, Fogarty EE, Dowlington FE. Pediatric trampoline injuries. *J Pediatr Orthop* 2007;27(7):729-73220.
- Huttunen TT, Kannus P, Lepola V, Pihlajamäki M, Mattila VM. Surgical treatment of humeral-shaft fractures: a register based study in Finland between 1987 and 2009. *Injury* 2012;43(10):1704-1708.
- Iannotti JP. Growth plate physiology and pathology. *Orthop Clin North Am* 1990;21:1-17.
- Jakob R, Fowles JV, Rang M, Kassab MT. Observations concerning fractures of the lateral humeral condyle in children. *J Bone joint Surg B* 1975;57(4):430-436.
- Jones K, Weiner DS. The management of forearm fractures in children: a plea for conservatism. *J Pediatr Orthop* 1999;19(6):811-815.
- Jubel A, Andermahr J, Isenberg J, Issavand A, Prokop A, Rehm KE. Outcomes and complications of elastic stable intramedullary nailing for forearm fractures in children. *J Pediatr Orthop B* 2005;14:375-80.
- Kaiser MM, Stratmann C, Zachert G, Schulze-Hessing M, Gros N, Eggert R, Rapp M. Modification of elastic intramedullary nailing with 3<sup>rd</sup> nail in a femoral spiral fracture model – results of biomechanical testing and a prospective clinical study. *BMC Musculoskelet Disord.* 2014;8:3.
- Kamegaya M, Saisu T, Segawa Y, Kakizaki J, Sakamoto Y, Hagiwara S. Remodeling of angulation deformities in diaphyseal femoral fracture in children. *J Orthop Sci.* 2012;17:763-769.
- Kang SN, Magwani J, Ramchandran M, Paterson JM, Barry M. Elastic intramedullary nailing of paediatric fractures of the forearm: a decade of experience in a teaching hospital in the United Kingdom. *J Bone Joint Surg Br* 2011;93(2):262-265.
- Keenan WNW, Woodward AF, Price D, Ecliff KD, Richards J, Powell J, Shanahan S. Manipulation under anaesthetic of children's fractures: Use of the image intensifier reduces radiation exposures to patients and theatre personnel. *J Pediatr Orthop* 1996;16(2):183-186.
- Keskimäki I, Aro S. Accuracy of data on diagnosis, procedures and accidents in the Finnish Hospital Discharge Register. *Int J Health Sci* 1991;15-21.
- Khan MS, Sultan S, Ali MA, Kahn A, Younis M. Comparison of percutaneous pinning with casting in supracondylar humeral fractures in children. *J Ayub Med Coll Abbottabad* 2005;17(2):33-36.

- Kim HT, Song MB, Conjares JN, Yoo CL. Trochlear deformity occurring after distal humeral fractures: magnetic resonance imaging and its natural progression. *J Pediatr Orthop* 2002;22(2):188-193.
- Kim PH, Leopold SS. Custilo-Anderson Classification. *Clin Orthop Relat Res* 2012;470(119):3270-3274.
- King J, Diefendorf D, Apthorp J, Negrete VF, Carlson M. Analysis of 429 fractures in 189 battered children. *J Pediatr Orthop* 1988;8:585-589.
- Klimek PM, Juen D, Stranzinger E, Wolf R, Slongo T. Trampoline related injuries in children: Risk factors and radiographic findings. *World J Pediatr* 2013;9(2):169-174.
- Koh KH, Seo SW, Kim KM, Shim JS. Clinical and radiographic results of lateral condylar fracture of distal humerus in children. *J Pediatr Orthop* 2010;30(5):425-429.
- Kopjar B, Wickizer TM. Fractures among children: incidence and impact on daily activities. *Inj Prev* 1998;4(3):194-197.
- Korhonen J, Sinikumpu JJ, Harmainen S, Ryhänen J, Kallio P, Serlo W. Osteosynteesimateriaalin poisto lapsilta ja nuorilta. *Duodecim* 2014;130(7):689-695.
- Kregor PJ, Song KM, Routt ML, Sangeorzan BJ, Liddell RM, Hansen ST Jr. Plate fixation of femoral fractures in multiple injured children. *J Bone Joint Surg (Am)* 1993;75:1774-1780.
- Krettek C, Haas N, Walker J, Tserne H. Treatment of femoral shaft fractures in children by external fixation. *Injury* 1991;22(4):263-266.
- Landin LA. Fracture patterns in children. Analysis of 8,682 fractures with special reference to incidence, etiology and secular changes in a Swedish urban population 1950–1979. *Acta Orthop Scand Suppl* 1983;202:1-109.
- Lascombes P, Prevot J, Ligier JN, Metaizeau JP, Poncelet T. Elastic stable intramedullary nailing in forearm shaft fractures in children: 85 cases. *J Pediatr Orthop* 1990;10:167-71.
- Lascombes P, Haumont T, Journeau P. Use and abuse of flexible intramedullary nailing in children and adolescents. *J Pediatr Orthop* 2006;26(6):827-834.
- Laudenhaf HN, Schaffert M, Bauer J. The displaced supracondylar humeral fracture: Indications for surgery and surgical options: a 2014 update. *Curr Opin Pediatr* 2014;26(1):64-69.
- Leitch KK, Kay RM, Femino JD, Tolo VT, Storer SK, Skaggs DL. Treatment of multidirectionally unstable supracondylar humeral fractures in children. A modified Gartland type-IV fracture. *J Bone Joint Surg Am* 2006;88:480-485.
- Lieber J, Sommerfeldt DW. Diametaphyseal forearm fracture in childhood. Pitfalls and recommendations for treatment. *Unfallchirurg* 2011;114(4):292-299.
- Ligier JN, Metaizeau JP, Prevot J, Lascombes P. Elastic stable intramedullary nailing of femoral shaft fractures in children. *J Bone Joint Surg Br* 1988;70(1):74-77.
- Liu RW, Roocroft J, Bastrom T, Yaszay B. Surgeon learning curve for pediatric supracondylar humerus fractures. *J Pediatr Orthop* 2011;31(8):818-824.
- Loder RT. The demographics of playground equipment injuries in children. *J Pediatr Surg* 2008;43(4):691-699.
- Loder RT, Schultz W, Sabatino M. Fractures from trampoline: Results from a national database, 2002 to 2011. *J Pediatr Orthop* 2014;34(7):683-690.
- Luhmann SJ, Schootman M, Schoenecker PL, Dobbs MB, Gordon JE. Complications of titanium elastic nails for pediatric femoral shaft fractures. *J Pediatr Orthop* 2003;23(4):443-447.
- Mann DC, Rajmaira S. Distribution of physeal and nonphyseal fractures in 2650 long bone fractures in children aged 0–16 years. *J Pediatr Orthop* 1990;10(6):713-716.
- Mann D, Schnabel M, Baacke M, Gretzen L. Results of elastic stable intramedullary nailing (ESIN) in forearm fractures in childhood. *Unfallchirurg* 2003;106:102-109.

- Marsell R, Einhorn T. The biology of fracture healing. *Injury, Int J. Care Injured* 2011;42:551-555.
- Martus JE, Preston RK, Schoenecker JG, Lovejoy SA, Green NE, Mencio GA. Complications and outcomes of diaphyseal antebrachium fracture intramedullary nailing: A comparison of children and adolescent groups. *J Pediatr Orthop* 2013;33(6):598-607.
- Mattila VM, Sillanpää P, Iivonen T, Parkkari J, Kannus P, Pihlajamäki H. Coverage and accuracy of diagnosis of cruciate ligament injury in the Finnish Hospital Register Discharge. *Injury* 2008;39:1373-1376.
- Mattila VM, Huttunen TT, Sillanpää P, Niemi S, Pihlajamäki H, Kannus P. Significant change in the surgical treatment of distal radius fractures: a nationwide study between 1988 and 2008 in Finland. *J Trauma* 2011;71(4):939-942.
- Mazda K, Khairouni A, Pennecot G, Bensahel H. Closed flexible intramedullary nailing of the femoral shaft fractures in children. *J Pediatr Orthop B* 1997;6(3):198-202.
- McCartney D, Hinton A, Heinrich SD. Operative stabilization of pediatric femur fractures. *Orthop Clin North Am* 1957;25(4):635-650.
- McNeill JA, Francis A, El-Hawary R. A systematic review of rigid, locked, intramedullary nail insertion sites and avascular necrosis of femoral head in the skeletally immature. *J Pediatr Orthop* 2011;31(49):377-380.
- Milch H. Fractures and fracture dislocations of humeral condyles. *J Trauma* 1964;4:592-607.
- Moritz JD, Hoffmann B, Sehr DH, Eggerking J, Keil K, Caliebe A, Dischinger J, Heller M, Bolte H. Pediatric fracture diagnosis-ultra-low-dose CT with an effective dose equal to that of radiographs. *Rofo* 2012;184(11):1026-1033.
- Moroz LA, Launay F, Kocher MS, Newton PO, Frick SL, Sponseller PD, Flynn JM. Titanium elastic nailing of fractures of the femur in children. Predictors of complications and poor outcome. *J Bone Joint Surg B* 2006;88(10):1361-1366.
- Morris S, Cassidy N, Stephens M, McCormick D, McManus F. Birth-associated femoral fractures: incidence and outcome. *J Pediatr Orthop* 2002;22(1):27-30.
- Mubarak SJ, Frick S, Sink E, Rathjen K, Noonan KJ. Volkamm contractures and compartment syndromes after femoral fractures in children treated with 90/90 spica cast. *J Pediatr Orthop* 2006;26(5):567-572.
- Mulperi ME. Classic radiologic sign: an atlas and history. New York, NY: Parthenon, 1997.
- Mulpuri K, Wilkins K. The treatment of displaced supracondylar humerus fractures: evidence-based guideline. *J Pediatr Orthop* 2012;32(2):143-152.
- Musgrave DS, Mendelson SA. Pediatric orthopaedic trauma: principles in management. *Crit Med Care* 2002;30(11):S431-443.
- Müller ME, Nazarian S, Koch P, Schatzker J, Nafei A, Hvid I. The Comprehensive Classification of Fractures of Long Bones. Berlin: Springer-Verlag, 1990.
- Mäyränpää MK, Mäkitie O, Kallio P. Decreasing incidence and changing pattern of childhood fractures: A population-based study. *J Bone Miner res.* 2010;25(12):2752-9.
- Nafei A, Teichert G, Mikkelsen S, et al. Femoral fractures in children: an epidemiological study in a Danish urban population, 1977-86. *J Pediatr Orthop* 1992;12(4):499-502.
- Okike K, Bhattacharyya T. Trends in the management of open fractures: a critical analysis. *J Bone Joint Surg Am.* 2006;88:2739-2748.
- Ong TG, Low BY. Supracondylar humeral fractures- a review of the outcome of the treatment. *Singapore Med J.* 1996;37(59):508-511.
- Onder E, Emel G, Ahmed A, Uygur D, Yalim A. Treatment of supracondylar fractures of the humerus in children through an anterior approach is a safe and effective method. *Int Ortop.* 2009;33(5):1371-1375.

- Ortega R, Loder RT, Louis DS. Open reduction and internal fixation of forearm fractures in children. *J Pediatr Orthop* 1996;16(5):651-654.
- OTA. Fracture and dislocation compendium. Orthopaedic Trauma Association Committee for Coding and Classification. *J Orthop Trauma* 1996;10(Suppl 1):154.
- Palmu S, Lohman M, Paukku R, Paltonen J, Nietosvaara Y. Childhood femoral fracture can lead to premature knee-joint arthritis. *Acta Orthop* 2013;84(1):71-75.
- Palmu S, Paukku R, Peltonen J, Nietosvaara Y. Treatment injuries are rare in children's femoral fractures. Compensation claims submitted Patients Insurance Center in Finland. *Acta Orthop* 2010;81(6):715-718.
- Parikh SN, Jain VV, Denning J, Tamai J, Mehlman CT, McCarthy JJ, Wall FJ, Crawford AH. Complications of elastic stable intramedullary nailing in pediatric fracture management: AAOS exhibit selection. *J Bone Joint Surg A* 2012;94(24):e184.
- Parsch KD. Modern trends in internal fixation of femoral shaft fractures in children. A critical review. *J Pediatr Orthop B* 1997;6:117-125.
- Pauwels F. A clinical observation as example and proof of functional adaptation of bone through longitudinal growth. *Z Orthop Ihre Grenzgeb.* 1975;113(1):1-5.
- Persiani P, Di Domenica M, Gurzi M, Martini L, Lanzone R, Villani C. Adequate of treatment, bone remodeling, and clinical outcome in pediatric supracondyle humeral fractures. *J Pediatr Orthop B* 2012;21(2):115-120.
- Pirone AM, Graham HK, Krajbich JL. Management of displaced extension-type supracondylar fractures of the humerus in children. *J Bone Joint Surg Am* 1988;70(5):641-650.
- Price CT. Fractures of the midshaft radius and ulna. In: Letts RM, ed. *Management of pediatric fractures*. New York: Churchill Livingstone, 1994:323.
- Price CT. Acceptable alignment of forearm fractures in children: open reduction indications. *J Pediatr Orthop* 2010;30(2):82-84.
- Price CT, Mencio GA. Injuries to the shaft of the radius and ulna. In: Rockwood CA Jr, Wilkins KE, King RE, editors: *Fractures in Children*, 5<sup>th</sup> edition. Philadelphia, JB Lippincott, 2001:443-482.
- Price CT, Scott DS, Kurzner ME, Flynn JC. Malunited forearm fractures in children. *J Pediatr Orthop* 1990;10:705.
- Putnam JD, Walsh TM. External fixation for open fractures of the upper extremity. *Hand Clin* 1993;4:613.
- Rasool MN. Ulnar nerve injury after K-wire fixation of supracondylar humerus fractures in children. *J Pediatr Orthop* 1998;18(5):686-690.
- Rennie L, Court-Brown CM, Mok JY, Beattie TF. The epidemiology of fractures in children. *Injury* 2007;38:913-922.
- Richter D, Ostermann PA, Ekkernkamp A. Elastic intramedullary nailing: A minimally invasive concept in the treatment of unstable forearm fractures in children. *J Pediatr Orthop* 1998;18(4):457-461.
- Rutherford AJ. Fractures of the lateral humeral condyle in children. *J Bone Joint Surg Am* 1985;67:851-856.
- Ryöppy S, Karaharju EO. Alteration of epiphyseal growth by an experimentally produced angular deformity. *Acta Orthop Scand* 1974;45(4):490-498.
- Salmela R, Koistinen V. Is the discharge register of general hospitals complete and reliable? *Sairaala* 1987;49:480-482.

- Sanders J, Browne R, Mooney J, Rney EM, Horn BD, Anderson DJ, Hennrikus WL, Robertson WW. Treatment of femoral fractures in children by pediatric cohort: results of a 1998 survey. *J Pediatr Orthop* 2001;21(4):436-441.
- Sankar WN, Hebel NM, Skaggs DL, Flynn JM. Loss of pin fixation in displaced supracondylar humeral fractures in children: cause and prevention. *J Bone Joint Surg Am* 2007;89(4):713-717.
- Scheidt PC, Harel Y, Trumble AC, Jonas Dh, Overpeck MD, Bijur PE. The epidemiology of nonfatal injuries among US children and youth. *Am J Public Health* 1995;85:932-938.
- Schindeler A, McDonald MM, Bokko P, Little DG. Bone remodeling during fracture repair: The cellular picture. *Semin Cell Dev Biol* 2008;19(5):459-466.
- Schmittenebecher PP, Dietz HG, Linhart WE, Slongo T. Complications and problems in intramedullary nailing of children's fractures. *Eur J Trauma* 2000;26:287-293.
- Schmutz B, Rahmel B, McNamara Z, Coulthard A, Schuetz M, Lynham A. Magnetic resonance imaging: an accurate, radiation-free, alternative to computed tomography for the primary imaging and three-dimensional reconstruction of the bony orbit. *J Oral Maxillofac Surg.* 2014;72(3):611-618.
- Shaw BA, Murphy KM, Shaw A, Oppenheim WC, Myracle MR. Humerus shaft fractures in young children: accident or abuse? *J Pediatr Orthop* 1997;17:293-297.
- Sinikumpu JJ, Lautamo A, Pokka T, Serlo W. Complications and radiographic outcome of children's both-bone diaphyseal forearm fractures after invasive and non-invasive treatment. *Injury* 2013;44:431-436.
- Sink EL, Faro F, Polousky J, Flynn K, Gralla J. Decreased complications for pediatric femur fractures with a change in management. *J Pediatr Orthop* 2010;30(7):633-637.
- Skaggs DL, Cluck MW, Mostofi A, Flynn JM, Kay RM. Lateral-entry pin fixation in the management of supracondylar fractures in children. *J Bone Joint Surg Am* 2004;86(4):702-707.
- Skaggs DL, Hale JM, Bassett J, Kaminsky C, Kay RM, Tolo VT. Operative treatment of supracondylar fractures of the humerus in children. The consequence of pin placement. *J Bone Joint Surg Am* 2001; 83(5):737-740.
- Slongo T, Song HR, Oh CW, Shin HD. Treatment of femoral shaft fractures in young children: comparison between conservative treatment and retrograde flexible nailing. *J Pediatr Orthop B* 2004;13:275-280.
- Slongo TF. Complications and failures of the ESIN technique. *Injury* 2005;36:S.A78-S.A85.
- Smith FM. Medial epicondyle injuries. *J Am Med Assoc* 1950;142:396-402.
- Smith GA. Injuries to children in the United States related to trampolines, 1990-1995: A national epidemic. *Pediatric* 1998;101(3):406-412.
- Song HR, Oh CW, Shin HD, Kim SJ, Kyung HS, Baek SJ, Park BC, Ihn JC. Treatment of femoral shaft fractures in young children: comparison between conservative treatment and retrograde flexible nailing. *J Pediatr Orthop B* 2004;13(4):275-280.
- Spencer HT, Dorey FJ, Zionts LE, Wong MA, Moazzaz P, Silva M. Type II supracondylar fractures: can some be treated nonoperatively? *J Pediatr Orthop* 2012;32(7):675-681.
- Spinner RJ, Jacobson SR, Nunley JA. Fracture of a supracondylar humeral myositis ossificans. *J Orthop Trauma* 1995;9(3):263-265.
- Stannard JP, Christensen KP, Wilkins KE. Femur fractures in infants: a new therapeutic approach. *J Pediatr Orthop* 1995;14(4):461-466.
- Stans AA, Morrissy RT, Renwick SE. Femoral shaft fracture treatment in patients age 6-16 years. *J Pediatr Orthop* 1999;19(2):222-228.

- Sund R. Quality of the Finnish Hospital Discharge Register: A systematic review. *Scand J Public Health* 2012;40(6):505-515.
- Sutko J, Oberc A. Stress fractures in children. *Ortop Traumatol Rehabil.* 2012;14(6):545-453.
- Tejwani N, Phillips D, Goldstein RY. Management of lateral humeral condylar fracture in children. *J Am Acad Orthop Surg* 2011;19(6):350-358.
- Tiderius CJ, Landin L, D uppe H. Decreasing incidence of fractures in children: an epidemiological analysis of 1,673 fractures in Malm , Sweden, 1993–1994. *Acta Orthop Scand.* 1999;70(6):622-627.
- Tomaszewski R, Gap A. Results of the treatment of the open femoral shaft fractures in children. *J Orthop* 2014;21;11(2):78-81.
- Tsai CH, Fong YC, Chen YH, HSU CJ, Chang CH, Hsu HC. The epidemiology of traumatic humeral shaft fractures in Taiwan. *Int Orthop* 2009;33(2):463-467.
- Tsiridis E, Upadhyay N, Giannoudis P. Molecular aspects of fracture healing: which are the important molecules? *Injury, Int. J. Care Injured.* 2007;38(1):S11-S25.
- Villarin LA, Beck KE, Freid R. Emergency department evaluation and treatment of elbow and forearm injuries. *Emerg Med Clin North Am* 1999;17:844-858.
- Vitale M. Epidemiology of fractures in children. In: Rockwood CA Jr, Beaty JH, Kasser JR, editors: *Fractures in Children*, 7<sup>th</sup> edition. Philadelphia, JB Lippincott, 2010:3-17.
- Vransky P, Bourdelat D, Al Faour A. Flexible stable intramedullary pinning technique in the treatment of pediatric fractures. *J Pediatr Orthop.* 2000;20:23-27.
- Wall EJ, Jain V, Vora V, Mehlman CT, Crawford AH. Complications of titanium and stainless steel elastic nail fixation of pediatric femoral fractures. *J Bone Joint Surg Am* 2008;90:1305–1313.
- Wallace ME, Hoffman EB. Remodeling of angular deformity after femoral shaft fractures in children. *J Bone Joint Surg Br* 1992;74(5):765-769.
- Walsh SSM, Jarvis SN, Towner EM, Aynsley-Green A. A Annual incidence of unintentional injury among 5400 children. *Int Prev* 1996;2:16-20.
- Ward WT, Levy J, Kaye A. Compressio plating for child and adolescent femur fractures. *J Pediatr Orthop* 1992;12(5):626-632.
- Wendeberg B. Mineral metabolism of fractures of the tibia in man studied with external counting of Sr85. *Acta orthop* 1961;(52):1-79.
- Weinberg AM, Castellani C, Amerstorfer F. Elastic stable intramedullary nailing (ESIN) for forearm fractures. *Oper Orthop Traumatol.* 2008;20(4-5):285-296.
- Weise K, Schwab E, Scheufele TM. Elbow injuries in childhood. *Unfallchirurg.* 1997;100(4):255-269.
- Weiss JM, Mencio GA. Forearm shaft fractures: does fixation improve outcomes? *J Pediatr Orthop* 2012;1:S22-24.
- Weseley MS, Barenfeld PA: Ball throwers' fracture of the humerus. Six case reports. *Clin Orthop Relat Res.* 1969;64:153-156.
- Wilkins KE. The operative management of supracondylar fractures. *Orthop Clin North Am* 1990;21:269-289.
- Wilkins KE. Fractures and dislocation of the elbow region. In: Rockwood CA Jr, Wilkins KE, King RE, editors: *Fractures in Children*, 3<sup>rd</sup> edition. Philadelphia, JB Lippincott, 1991:509-828.
- Wilkins KE. Principles of fracture remodeling in children. *Injury, Int. J. Care Injured.* 2005;36:S-A3-S-A11.

- Wilson NIL, Ingran R, Rymaszewski L, Miller JH. Treatment of fractures of the medial epicondyle of the humerus. *Injury* 1988;19:342-344.
- Wolf J. *Das Gesetz der Transformation der Knochen*. Verlag von August-Hirschwald, 1892.
- Xian CJ, Foster BK. The biological aspects of children's fractures. In: Rockwood CA Jr, Beaty JH, Kasser JR, editors: *Fractures in Children*, 7<sup>th</sup> edition. Philadelphia, JB Lippincott, 2010:18-43.
- Zatti G, Teli M, Ferrario A, Cherubino P. Treatment of closed humeral shaft fractures with intramedullary elastic nails. *J Trauma* 1998;45(6):1046-1050.
- Yalcinkaya M, Dogan A, Ozkaya U. Clinical results of intramedullary nailing following closed or mini open reduction in pediatric unstable diaphyseal forearm fractures. *Acta Orthop Traumatol Turc.* 2010;44(1):7-13.
- Yuan PS, Pring ME, Gaynor TP. Compartment syndrome following intramedullary fixation of pediatric forearm fractures. *J Pediatr Orthop* 2004;24:370-375.





## 10 ORIGINAL PUBLICATIONS



# Stable incidence of surgical treatment and hospitalisation for humeral shaft fractures among 0- to 16-year-old patients in Finland from 1987 to 2010

A. Salonen · O. Pajulo · T. Lahdes-Vasama ·  
V. M. Mattila

Received: 13 October 2013 / Accepted: 4 February 2014 / Published online: 20 February 2014  
© The Author(s) 2014. This article is published with open access at Springerlink.com

## Abstract

**Background** Studies among children experiencing fractures report an increasing trend toward operative management. In the present study, we examined whether the same trend has occurred for humeral shaft fractures in accordance with increasing interest toward intramedullary nailing and other operative treatments. The number, incidence and treatment of all hospitalised 0- to 16-year-old patients with humeral shaft fractures in Finland was assessed over a recent 24-year period.

**Method** The study included the entire adolescent (0–16 years) population in Finland during the 24-year period from January 1, 1987, to December 31, 2010. Data on hospitalised patients who sustained humeral shaft fractures were obtained from the nationwide National Hospital Discharge Register (NHDR) of Finland.

**Results** During the study period, there were a total of 1,165 hospitalisations with a main or secondary diagnosis of humeral shaft fracture. The incidence of hospitalisation

due to humeral shaft fractures was 4.8 per 100,000 person-years. The incidence increased only slightly among girls from 3.3 per 100,000 person-years in 1987 to 5.3 per 100,000 person-years in 2010. The incidence of reposition and casting was 1.1 per 100,000 person-years and the incidence of reposition with osteosynthesis, including intramedullary nailing, was 1.4 per 100,000 person-years. The specific incidence of intramedullary nailing remained low with no signs of increased incidence, and the incidence was 0.3 per 100,000 person-years. There were no significant changes in the incidence of surgical treatment during the 24-year study period.

**Conclusion** Despite an overall increasing trend toward operative management of fractures in children, conservative management remains the treatment of choice for humeral shaft fractures based on the low and steady incidence of surgical treatment during the 24-year study period. In addition, the incidence of hospitalisation for fractures remained low without a significant increase during the study period.

A. Salonen (✉) · T. Lahdes-Vasama  
Department of Pediatric and Adolescent Surgery, Pediatric Clinics and Pediatric Research Centre, Tampere University Hospital, Teiskontie 35, 33521 Tampere, Finland  
e-mail: anne.salonen@pp7.inet.fi

O. Pajulo  
Department of Pediatric Surgery, Pediatric Clinics, Turku University Hospital, Turku, Finland

V. M. Mattila  
Division of Orthopedics and Traumatology, Department of Trauma, Musculoskeletal Surgery and Rehabilitation, Tampere University Hospital, Tampere, Finland

V. M. Mattila  
Department of Orthopedics, Karolinska Hospital, Stockholm, Sweden

**Keywords** Adolescent · Humeral shaft fracture · Epidemiology · Incidence · Treatment

## Introduction

Although humeral shaft fractures are relatively uncommon, they occur in every age group. Two peaks in occurrence are observed: in children under 3 years of age and in adolescents over 12 years of age [1, 2]. In general, humeral shaft fractures represent <10 % of humeral fractures in children and 1–3 % of all fractures in children [1, 2]. The most common fracture mechanism is direct trauma or rotational forces upon the humeral shaft. In newborn babies (birth

weight over 4.5 kg), humeral fractures are considered to be due to birth trauma [3]. In children under 3 years of age, child abuse must be considered a potential cause of fracture [4]. In adolescents, most humeral shaft fractures are caused by sporting injuries [5].

The majority of humeral shaft fractures in children can be managed without surgery, although angulation may be difficult to control. The remodelling potential of the humerus is remarkable, and functional outcomes are still good, despite radiographic angulation [1]. A fractured humerus in children under 12 years of age can be remodelled with up to 70° of anterior angulation, and older children can tolerate anterior angulation of up to 30–40° in the upper arm [1]. The remodelling process cannot correct a malaligned rotational deformity, however, which, in severe cases, may lead to functional impairment in adolescents near adult age [6]. Surgical indications are controversial, but open fractures, bilateral fractures and fractures associated with multiple trauma, as well as arterial injuries, some nerve injuries and inadequate closed reduction, are considered indications for surgery [5]. Despite good results after conservative treatment, interest toward surgical stabilisation in adolescents with elastic titanium nails has increased [7, 8].

This study aimed to assess the incidence of surgery and hospitalisation for humeral shaft fractures among children 0–16 years of age in Finland. We also describe whether the trend toward surgical treatment changed during the study period, between 1987 and 2010.

### Materials, methods and statistical analysis

This study covered the entire paediatric and adolescent population (aged <17 years) of Finland during a 24-year period, from January 1, 1987, to December 31, 2010. Humeral shaft fracture data were obtained from the statutory, computer-based National Hospital Discharge Register (NHDR) of Finland. The Finnish NHDR was founded in 1967 and the information is collected equally from all hospital categories (private, public and other). The NHDR contains data on the age, sex and domicile of the subject; length of hospital stay; primary and secondary diagnosis; and operations performed during the hospital stay. The validity of the NHDR is excellent regarding both coverage and accuracy of the database [9–11].

The main outcome variable for this study was the number of surgically treated patients hospitalised with a main or secondary diagnosis of humeral shaft fracture (ICD-9 codes 8122A and 8123A in 1987–1996 and ICD-10 code S42.3 in 1997–2010). During the study period, the

procedural codes changed. The procedure codes were ICD-9 from 1987 through 1996 and ICD-10 from 1997 through 2010. The ICD-9 procedural codes included in the study were 9123 (reposition and cast), 9126 (closed reposition and osteosynthesis) and 9128 (open reduction and osteosynthesis). The corresponding ICD-10 codes were NBJ41 (reposition and cast), and NBJ60 and NBJ40 (reposition and osteosynthesis).

For the purpose of analysing incidence trends during the study period from 1987 to 2010, the ICD-10 procedure codes were pooled with the ICD-9 codes. Treatment in the operating room was categorised into two groups; reposition with casting and reposition with osteosynthesis. Patients were analysed in three groups according to age: 0–6 years, 7–12 years and 13–16. Due to the small number of events in specific sex and age groups, operation-specific incidence rates were pooled for boys and girls.

To calculate the incidence of humeral shaft fractures leading to surgery and inpatient hospital treatment, the annual mid-population was obtained from the Official Statistics of Finland, an electronic national population register [12]. Statistical analysis was performed using PASW 19.0 (IBM SPSS, Chicago, IL, USA). The incidence figures were, thus, the true results concerning the entire adolescent population in Finland, rather than cohort-based estimates during the study period, and, therefore, 95 % confidence intervals were not calculated.

### Results

A total of 1,165 hospitalisations for patients from 0 to 16 years of age with a main or secondary diagnosis of humeral shaft fracture were registered during the 24-year study period. Boys comprised the majority of patients (62 %,  $n = 719$ ). Surgical treatment was required in 585 (51 %) of the cases. The most common treatment method was repositioning and osteosynthesis (55 %,  $n = 323$ ), including 79 fractures treated with intramedullary nailing (eight cases in those aged 0–6 years, 28 in those aged 7–12 years and 43 in those aged 13–16 years). Closed reposition and casting in surgery included 262 patients (45 %). Pain relief and further evaluation by senior paediatric orthopaedists was the reason for hospitalisation in 580 (49 %) of the cases in which no operations were performed. The mean age of the hospitalised children was 10.5 years (10.8 in boys and 10.1 in girls,  $p = 0.003$ ).

During the study period, the incidence of surgery did not change. The incidence of repositioning and casting was 1.1 per 100,000 person-years during the 24-year study period (Table 1). The incidence of repositioning and casting was lowest in patients aged 13–16 years, with a mean of 0.9 per

**Table 1** Incidence of repositioning with casting per 100,000 person-years among girls and boys aged 0–16 years between 1987 and 2010

	0–6 years	7–12 years	13–16 years
1987	1.6	0.3	0.8
1988	0.7	0.8	1.2
1989	1.6	1.5	0.8
1990	0.9	1	1.9
1991	0.7	0.8	1.9
1992	1.1	1.3	1.1
1993	1.8	2	0.4
1994	1.5	1.8	1.2
1995	1.9	2.3	0.8
1996	2	2.4	1.5
1997	0.7	0.8	1.1
1998	0.9	1	1.5
1999	1.9	2	0.8
2000	1	1	0.8
2001	1.5	1.5	0
2002	0.7	0.8	0.8
2003	1.8	1.8	1.1
2004	1.5	1.6	0.8
2005	1.8	1.9	1.5
2006	0.5	0.6	0.4
2007	1.5	1.7	1.1
2008	0.2	0.3	0.8
2009	1	1.1	0.4
2010	0	0	0

100,000 person-years, and highest in patients aged 7–12 years, with a mean of 1.3 per 100,000 person-years. The incidence increased slightly in the youngest study group, those aged from 0 to 6 years, from 1.3 per 100,000 person-years between 1987 and 1997 to 1.7 per 100,000 person-years between 2000 and 2010. The corresponding incidence was 1.2 per 100,000 person-years between 1987 and 1997 to 0.6 per 100,000 person-years between 2000 and 2010 in the oldest study group.

The incidence of repositioning and osteosynthesis was 1.4 per 100,000 person-years (Table 2). The incidence was lowest in those aged 0–6 years, with a mean of 0.5 per 100,000 person-years, and highest in those aged 13–16 years, with a mean of 2.5 per 100,000 person-years. The incidence of repositioning and osteosynthesis increased slightly only in the oldest study group from 2.1 per 100,000 person-years between 1987 and 1997 to 2.6 per 100,000 person-years between 2000 and 2010. The total number of fractures treated with intramedullary nailing was 79. The incidence of intramedullary nailing was 0.3 per 100,000 person-years. The incidence was highest in patients aged 13–16 years ( $n = 43$ ), with a mean of 0.7 per 100,000 person-years. The highest

**Table 2** Incidence of reposition with osteosynthesis per 100,000 person-years among girls and boys aged 10–16 years between 1987 and 2010

	0–6 years	7–12 years	13–16 years
1987	0	0.8	2.5
1988	0.2	0.8	1.2
1989	0.2	1.8	2.4
1990	1.1	0.8	0.8
1991	0.2	1	2.7
1992	0	0.5	0.8
1993	0.4	0.8	1.9
1994	0.4	0.5	1.2
1995	0.7	1.6	3.1
1996	0.9	1.6	1.9
1997	1.1	1.3	3.8
1998	0.9	1	3.4
1999	0.5	0.8	1.9
2000	0.5	2	2.4
2001	0.2	1.5	2.8
2002	0.2	1.5	2.4
2003	0.8	1.3	2.7
2004	0.5	1.3	5
2005	0.5	2.4	3.4
2006	0.2	1.9	1.5
2007	0.5	1.1	2.6
2008	0.5	0.6	3.4
2009	0.7	0.9	2.7
2010	0.7	2.6	2.4

incidence, 1.4 per 100,000 person-years, occurred in 1997 in those aged 13–16 years, and after 1997, the incidence decreased to 0.6 per 100,000 person-years without any signs of an increase.

In the present study, the person-based incidence due to the hospitalisation of humeral shaft fractures was 4.8 per 100,000 person-years (6.0 per 100,000 person-years in boys and 3.7 per 100,000 person-years in girls). The incidence increased among girls, from 3.3 per 100,000 person-years in 1987 to 5.3 per 100,000 person-years in 2010 (Table 3). In boys, the incidence of humeral shaft fractures decreased slightly from 6.7 per 100,000 person-years in 1987 to 5.9 per 100,000 person-years in 2010 (Table 4). The highest incidence of fractures was 9.6 per 100,000 person-years in boys aged 13–16 years. The lowest fracture incidence was observed in girls aged 0–6 years (2.3 per 100,000 person-years).

The mean duration of hospital stay for the entire study group was 2.6 days. The mean duration of hospital stay was 2.5 days for patients with reposition and casting, and 3.4 days for patients with reposition or reduction and osteosynthesis.

**Table 3** Incidence of humeral shaft fractures per 100,000 person-years among girls aged 0–16-years from 1987 to 2010

	0–6 years	7–12 years	13–16 years
1987	1.3	5.2	3.4
1988	2.3	4.7	3.4
1989	2.3	6.3	5.7
1990	1.4	5.2	3.9
1991	2.8	5.2	3.1
1992	1.8	3.6	1.6
1993	2.3	6.8	3.9
1994	2.2	2.1	3.2
1995	2.7	6.4	3.9
1996	3.6	7.5	7.7
1997	4.6	3.4	3.1
1998	1.9	6.9	3.1
1999	2.4	3.2	3.9
2000	3.4	7.3	8.9
2001	1.5	4.7	5.7
2002	1	2	4
2003	1.5	4.2	3.9
2004	3.1	2.7	3.1
2005	1.5	3.8	5.4
2006	1	3.3	5.4
2007	1.5	2.3	4.6
2008	1.5	2.3	3.9
2009	1.5	1.8	4.7
2010	4.9	5.9	4.8

**Table 4** Incidence of humeral shaft fractures per 100,000 person-years among boys aged 0–16 years from 1987 to 2010

	0–6 years	7–12 years	13–16 years
1987	2.6	5	12.3
1988	6.2	1.5	8.8
1989	2.2	5.5	7
1990	3.6	3.5	7.5
1991	2.7	6.5	12.6
1992	1.8	5.1	7.5
1993	2.2	4.5	6.8
1994	6	5	8.3
1995	4.3	5.1	8.2
1996	4.3	6.2	11
1997	4.4	6.7	19
1998	0.9	4.6	11.7
1999	1.8	6.5	13.5
2000	2.8	3	6.9
2001	2.3	4.5	3.9
2002	0.9	6.5	5.4
2003	4.4	6.1	8.3
2004	2.5	9.2	14.2
2005	3.9	6.3	14
2006	1.9	6.4	5.1
2007	4.8	9.3	12.6
2008	1.9	2.2	7.4
2009	0.9	5.6	9.1
2010	3.2	6.2	8.5

## Discussion and conclusions

The principal aim of the present study was to describe the incidence and trends of operative treatment for humeral shaft fractures among children and adolescents aged 0–16 years in Finland between 1987 and 2010. The main finding was that, despite the overall increase in surgical treatment in children and adolescents, the incidence of surgery for humeral shaft fractures remained low during the 24-year study period. Also, the incidence of humeral shaft fractures leading to hospitalisation remained low, with no significant changes during the study period.

Based on the previous literature, approximately one-third of children sustain at least one fracture before 17 years of age and the majority of the fractures occur in the upper limbs [13–15]. Antebrachium fractures represent 35 %, while humeral diaphyseal fractures represent less than 1 % of all fractures [13–17]. According to Mäyränpää et al. [18], the incidence of all fractures other than upper-extremity fractures has decreased significantly over the past two decades. Helenius and coworkers [19] recently reported that the incidence of hospital-treated upper-extremity fractures has increased by 23 % in Finland

during the preceding 10 years. Based on our earlier study (Salonen et al. [20]) and the present study, it seems that the main reason for the increased incidence of hospital-treated upper extremity fractures is distal humeral fractures.

The incidence of surgery remained low and steady during our study period. Roughly half of the patients were treated surgically by repositioning and casting or by osteosynthesis. Despite the increasing interest toward intramedullary nailing, its role in the management of humeral shaft fractures has remained low in Finland. The highest incidence of intramedullary nailing was 1.4 per 100,000 person-years and, interestingly, it did not increase during the study period, although elastic medullary nailing was recently suggested to be a good alternative to conservative treatment [7, 8]. Fernandez et al. [8] reported 31 children with traumatic humeral shaft fractures treated with elastic stable intramedullary nailing. In their sample, five complications occurred, all concerning the indication for surgery or technical error (skin irritation, damage of the radial nerve etc.) [8]. All patients and parents were satisfied with the treatment and all children were able to return to their sporting activities after treatment [8]. Zatti et al. [21] reported 40 patients, 14 treated with elastic stable

intramedullary nailing and 16 treated with AO plates. Both groups had the same fracture healing time and functional recovery, allowing for early motion. The surgical technique of elastic nailing is simple, safe and rather atraumatic, and, therefore, valid for routine use [21]. Gordon and Garg as well as Slongo described indications and techniques for flexible titanium intramedullary nailing. They both reported optimal results of fracture treatment provided the indication is valid and the appropriate technique is used [22, 23]. Although our study did not compare the results of surgical and non-surgical treatment, conservative treatment was most often used and there was no significant trend toward an increase in surgical treatment.

The previously reported overall increasing incidence of fractures may be due to changes in children's activity patterns over time. In addition, new leisure-time physical activities, such as jumping on a trampoline, may increase the fracture incidence [24]. Hurson et al. [24] reported a dramatic increase in fractures and other trampoline-related injuries in Ireland. A similar trend was reported in the United States during the past 10–15 years [15].

In the present study, the incidence of hospitalised humeral shaft fractures was 4.8 per 100,000 person-years. To our knowledge, this is the first nationwide study to assess the incidence of hospitalisation due to humeral shaft fractures in children and adolescents. In our study, we observed a slight increase in hospitalisation due to humeral shaft fractures among girls. It must be considered, however, that humeral shaft fractures are relatively uncommon and the observed increase may have been due to annual normal variation. The low and relatively stable incidence of humeral shaft fractures can be accounted for by the injury mechanism. Shaft fractures require a rather uncommon trauma mechanism with twisting or transverse high-energy injury, which is often associated with multiple traumas [25–27].

The mean age at injury onset was 10.1 years, and the peak incidence occurred somewhat earlier in girls than in boys. The majority of patients were boys. These results correspond to those in previous reports [14]. The younger age of girls may be explained by differences in the pubertal growth of girls and boys. During the pubertal growth spurt, there is a relative decrease in bone mineral density due to bone expansion and insufficient mineralisation [28]. The greater frequency of fractures in boys, on the other hand, can be explained by differences in exposure time and in the intensity of their leisure-time sporting activities. In addition, some humeral fractures might be due to violence, which is more common among boys [29]. Boys' violent actions are connected to leisure-time activities as well as to alcohol, and increase with age [29].

A strength of this study is the Finnish NHDR, which provides an excellent database of patients treated in hospitals during the last 24 years. In addition, treatment is

equally available for all Finnish citizens and, thus, patients can be followed in the hospital discharge register by their personal identification number. The limitations of this study include the lack of separation between intramedullary nailing and plating during the time when the ICD-10 classification was used. Based on our analysis of ICD-9 coding, however, plating is rarely performed in children and adolescents. Further, the incidence reported in the present study is based on hospitalisation data on severe and unstable fractures. There may have been some patients treated as outpatients that are not included in this study.

To summarise, while the overall incidence of adolescent fractures has increased rapidly, the incidence of humeral shaft fractures has not changed markedly over the past 24 years. The incidence of surgical treatment has also remained steady, despite alternative treatment choices (e.g. elastic intramedullary nailing and plating).

**Open Access** This article is distributed under the terms of the Creative Commons Attribution License which permits any use, distribution, and reproduction in any medium, provided the original author(s) and the source are credited.

## References

1. Beaty JH (1992) Fractures of the proximal humerus and shaft in children. *Instr Course Lect* 41:369–372
2. Shrader MW (2007) Proximal humerus and humeral shaft fractures in children. *Hand Clin* 23(4):431–435
3. Weseley MS, Barenfeld P (1969) Ball throwers' fracture of the humerus. Six case reports. *Clin Orthop Relat Res* 64:153–156
4. King J, Diefendorf D, Aphorp J, Negrete VF, Carlson M (1988) Analysis of 429 fractures in 189 battered children. *J Pediatr Orthop* 8:585–589
5. Caviglia H, Garrido CP, Palazzi FF, Meana NV (2005) Pediatric fractures of the humerus. *Clin Orthop Relat Res* 432:49–56
6. Dameron TB Jr, Grubb SA (1981) Humeral shaft fractures in adults. *South Med J* 74:1461–1467
7. Lascombes P, Haumont T, Journeau P (2006) Use and abuse of flexible intramedullary nailing in children and adolescents. *J Pediatr Orthop* 26(6):827–834
8. Fernandez FF, Eberhardt O, Wirth T (2010) Elastic stable intramedullary nailing as alternative therapy for the management of paediatric humeral shaft fractures. *Z Orthop Unfall* 148(1):49–53
9. Salmela R, Koistinen V (1987) Is the discharge register of general hospitals complete and reliable? *Sairaala* 49:480–482
10. Keskimäki I, Aro S (1991) Accuracy of data on diagnoses, procedures and accidents in the Finnish Hospital Discharge Register. *Int J Health Sci* 2:15–21
11. Mattila VM, Sillanpää P, Iivonen T, Parkkari J, Kannus P, Pihlajamäki H (2008) Coverage and accuracy of diagnosis of cruciate ligament injury in the Finnish National Hospital Discharge Register. *Injury* 39:1373–1376
12. Official Statistics of Finland, Statistics Finland, Helsinki (2012) <http://stat.fi/>
13. Hedström EM, Svensson O, Bergström U, Michno P (2010) Epidemiology of fractures in children and adolescents. *Acta Orthop* 81(1):148–153
14. Cooper C, Dennison EM, Leufkens HG, Bishop N, van Staa TP (2004) Epidemiology of childhood fractures in Britain: a study



- using the general practice research database. *J Bone Miner Res* 19:1976–1981
15. Rennie L, Court-Brown CM, Mok JY, Beattie TF (2007) The epidemiology of fractures in children. *Injury* 38:913–922
  16. Larsen CF, Kiaer T, Lindequist S (1990) Fractures of the proximal humerus in children. Nine-year follow-up of 64 unoperated on cases. *Acta Orthop Scand* 61(3):255–257
  17. Landin LA (1997) Epidemiology of children's fractures. *J Pediatr Orthop B* 6:79–83
  18. Mäyränpää MK, Mäkitie O, Kallio PE (2010) Decreasing incidence and changing pattern of childhood fractures: a population-based study. *J Bone Miner Res* 25(12):2752–2759
  19. Helenius I, Lamberg TS, Kääriäinen S, Impinen A, Pakarinen MP (2009) Operative treatment of fractures in children is increasing. A population-based study from Finland. *J Bone Joint Surg Am* 91(11):2612–2616
  20. Salonen A, Pajulo O, Lahdes-Vasama T, Välipakka J, Mattila VM (2013) Increased incidence of distal humeral fractures and surgical treatment in 0- to 18-year-old patients treated in Finland from 1987 to 2010. *J Child Orthop* 7(6):559–564
  21. Zatti G, Teli M, Ferrario A, Cherubino P (1998) Treatment of closed humeral shaft fractures with intramedullary elastic nails. *J Trauma* 45(6):1046–1050
  22. Gordon JE, Garg S (2010) Pediatric humerus fractures: indications and technique for flexible titanium intramedullary nailing. *J Pediatr Orthop* 30:S73–S76
  23. Slongo TF (2008) Ante- and retrograde intramedullary nailing of humerus fractures. *Oper Orthop Traumatol* 20(4–5):373–386
  24. Hurson C, Browne K, Callender O, O'Donnell T, O'Neill A, Moore DP et al (2007) Pediatric trampoline injuries. *J Pediatr Orthop* 27(7):729–732
  25. Fisher SH (1958) Skeletal manifestations of parent-induced trauma in infants and children. *South Med J* 51:956–960
  26. Villarin LA Jr, Belk KE, Freid R (1999) Emergency department evaluation and treatment of elbow and forearm injuries. *Emerg Med Clin North Am* 17:843–858
  27. Shaw BA, Murphy KM, Shaw A, Oppenheim WL, Myracle MR (1997) Humerus shaft fractures in young children: accident or abuse? *J Pediatr Orthop* 17:293–297
  28. Faulkner RA, Davison KS, Bailey DA, Mirwald RL, Baxter-Jones AD (2006) Size-corrected BMD decreases during peak linear growth: implications for fracture incidence during adolescence. *J Bone Miner Res* 21(12):1864–1870
  29. Mattila VM, Parkkari J, Lintonen T, Kannus P, Rimpelä A (2005) Occurrence of violence and violence-related injuries among 12–18 year-old Finns. *Scand J Public Health* 33(4):307–313

# Increased incidence of distal humeral fractures and surgical treatment in 0- to 18-year-old patients treated in Finland from 1987 to 2010

A. Salonen · O. Pajulo · T. Lahdes-Vasama ·  
J. Välipakka · V. M. Mattila

Received: 28 April 2013 / Accepted: 3 September 2013 / Published online: 17 September 2013  
© EPOS 2013

## Abstract

**Background** Studies of pediatric and adolescent fractures in general report a significant increase in the incidence of upper-extremity fractures as well as in their surgical treatment. The aim of this study was to determine the trends of the incidence and treatment of distal humeral fractures in hospitalized 0- to 18-year-old patients in Finland.

**Method** The study included the entire pediatric and adolescent (<19 years) population in Finland during the 24-year period from 1 January 1987 to 31 December 2010. Data on hospitalized patients were obtained from the nationwide National Hospital Discharge Registry where information is collected from all hospital categories (private, public, and other). Surgical treatment was categorized into three groups; (1) reposition with casting; (2) reposition or reduction and osteosynthesis; (3) reposition or reduction and external-fixation and other fixation methods. Patients were classified into three groups according to age:

0–6 years, 7–13 years, and 14–18 years. Annual incidences were calculated using the annual mid-year population census obtained from the Official Statistics of Finland. **Results** During the 24-year study period, there were a total of 12,590 hospitalizations with a main or secondary diagnosis of distal humeral fracture. In children aged 0–12 years the overall incidence of hospitalization increased 30 % during the 24-year study period, from 4.5 per 10,000 person-years in 1987 to 5.8 per 10,000 person-years in 2010. There were a total of 5,548 operations. During the study period, surgical treatment by repositioning or reduction with osteosynthesis due to a distal humeral fracture increased by fivefold in patients aged <6 years and by twofold in patients aged 7–12 years of age. The incidences of fracture and treatment in children older than 13 years did not change.

**Conclusion** The incidence of distal humeral fractures and the incidence of repositioning with osteosynthesis increased remarkably in prepubertal children during the 24-year study period in Finland.

A. Salonen (✉) · T. Lahdes-Vasama · J. Välipakka  
Department of Pediatric and Adolescent Surgery, Pediatric Clinics and Pediatric Research Center, Tampere University Hospital, Teiskontie 35, 33521 Tampere, Finland  
e-mail: anne.salonen@pp7.inet.fi

O. Pajulo  
Department of Pediatric Surgery, Pediatric Clinics, Turku University Hospital, Turku, Finland

V. M. Mattila  
Division of Orthopedics and Traumatology, Department of Trauma, Musculoskeletal Surgery, and Rehabilitation, Tampere University Hospital, Tampere, Finland

V. M. Mattila  
Department of Orthopedics, Karolinska Hospital, Stockholm, Sweden

**Keywords** Distal humeral fracture · Incidence · Pediatric · Treatment

## Introduction

Distal humeral region fractures account for up to 5 % of all fractures in skeletally immature children [1–3]. Supracondylar fractures comprise up to 80 % of distal humeral region fractures [1–4], while fractures of the medial and lateral humeral condyles are much less common, representing 20 % of distal humeral fractures [1, 2]. Upper-arm fractures are often sustained during a fall as children attempt to protect themselves with an outstretched hand [1,

2]. A previous Finnish population-based study revealed a 23 % increase in the incidence of all upper-extremity fractures over the past 10 years and an increase of up to 28 % in the incidence of surgical treatment [5]. The type of upper-extremity fracture that has increased the most, however, is not known.

Unlike other anatomic areas in the growing skeleton, most distal humeral fractures are treated surgically by closed or open repositioning and osteosynthesis, usually by pinning [6–8]. Percutaneous pinning is a popular method of choice for supracondylar fractures [6–8] and has been reported to be a safe and cost-effective method that provides good functional results [7–10]. Even dislocated supracondylar fractures can be treated by repositioning and casting with an excellent functional outcome [11]. Most complex fractures require open reduction [6, 12]. An open procedure, based on a good technical understanding, has been reported to be as safe as a closed procedure [12, 13]. However, especially with an open technique, the treating physician should be aware of the potential complications, including iatrogenic neurovascular injury, elbow stiffness, malunion, and the development of cubitus varus or valgus deformity [14–16]. To reliably provide adequate functional results, it is recommended that a surgeon gain experience by operating on a minimum of 15 fractures under the supervision of an attending surgeon [17].

The aim of this study was to assess population-based changes in the incidence of hospitalization and treatment of distal humeral fractures among children aged 0–18 years in Finland between 1987 and 2010.

## Materials and methods

This study covered the entire pediatric and adolescent population (aged <19 years) in Finland during a 24-year period, from 1 January 1987 to 31 December 2010. Distal humeral fracture data were obtained from the statutory, computer-based National Hospital Discharge Register of Finland (NHDR) that was founded in 1967 and collects information from all hospital categories (i.e., private, public, and others). The NHDR contains data on the age, sex, and domicile of a patient, length of hospital stay, primary and secondary diagnosis, and operations performed during the hospital stay. The validity of the NHDR is excellent with respect to both coverage and accuracy of the database [18–20].

The main outcome variable for this study was the number of patients hospitalized as inpatients with a main diagnosis of distal humeral fracture (ICD-9 codes 8124A and 8125A from 1987 to 1996; ICD-10 code S42.4 from 1997 to 2010). The procedural codes changed during the 24-year study period. The procedures carried out for

patients with ICD-9 codes included in the study were reposition and cast (9,123 patients), closed or open reposition and osteosynthesis (9,128 patients), external-fixation (9,130 patients), and other distal humeral fracture operations (9,139 patients). The corresponding ICD-10 codes were NBJ41 (reposition and cast), NBJ64 (reposition or reduction and osteosynthesis), NBJ70 (external-fixation), and NBJ91 (other distal humeral fracture operation).

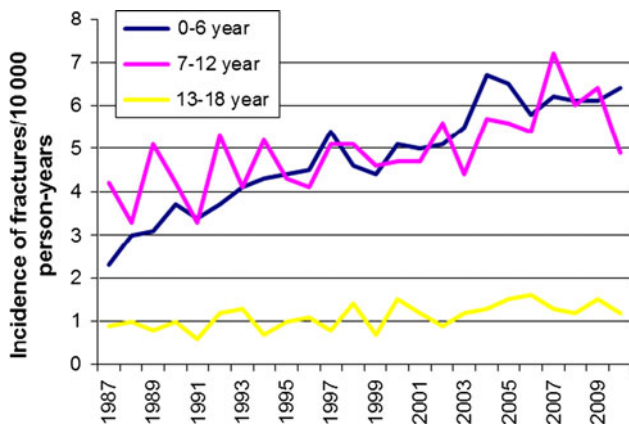
To analyze the incidence trends during the entire study period from 1987 to 2010, the ICD-10 procedures codes were pooled with the ICD-9 codes. Surgical treatment was categorized into three groups: Group 1, reposition with casting; Group 2, reposition or reduction with osteosynthesis; Group 3, external fixation and other fixation method. The patients were also stratified into three age groups: from 0 to 6 years, from 7 to 13 years, and from 14 to 18 years.

To calculate the incidence of distal humeral fractures leading to inpatient hospital treatment, we obtained the annual mid-year population census from the Official Statistics of Finland, an electronic national population register [21]. Statistical analysis was performed using PASW ver. 19.0 (SPSS, Chicago, IL). The incidence figures were thus the true results concerning the entire adolescent population in Finland rather than cohort-based estimates during the study period; as such 95 % confidence intervals were not calculated.

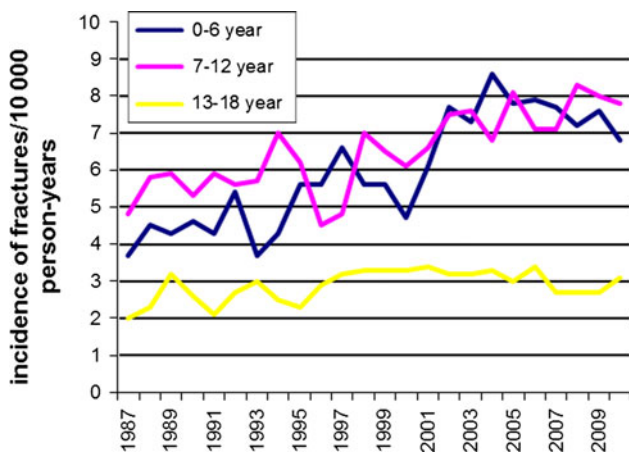
## Results

A total of 12,585 hospitalizations were registered for patients aged <19 years with a main or secondary diagnosis of distal humeral fracture during the 24-year study period. Boys comprised the majority of the patients (7,487, 60 %), with girls accounting for 40 % (5,098). There were a total of 5,548 surgical procedures (44 %). The most common surgical treatment method was reposition or reduction with osteosynthesis (4,703, 85 %), followed by closed reposition with casting (619, 11 %). Other types of surgical management, such as external-fixation (38, 1 %) and others (185, 3 %) were quite rare. Most of the patients were not treated in an operating room (7,040, 56 %). The mean age of the hospitalized children was 7.8 years (boys 8.2 years; girls 7.3 years;  $p = 0.003$ ). Mean hospital stay for the entire study population was 1.9 days; for patients with reposition or reduction and osteosynthesis, mean hospital stay was 1.9 days, and for those with reposition and casting it was 3.0 days.

In this patient cohort, the overall person-based hospitalization incidence for distal humeral shaft fractures was 5.6 per 10,000 person-years. In patients of both sexes aged 13–18 years, the incidence of fractures remained low and



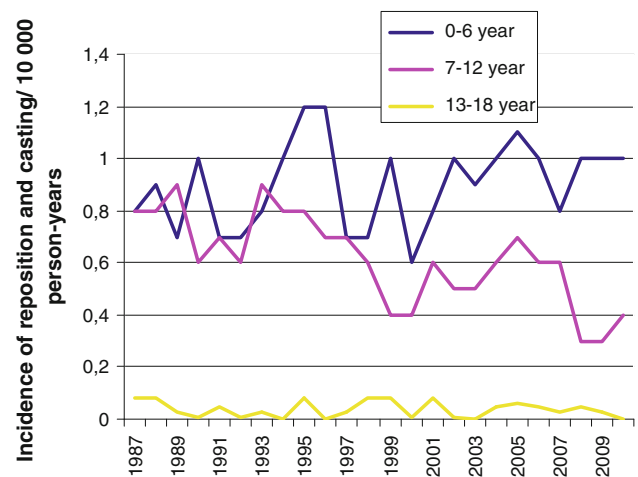
**Fig. 1** Incidence of distal humeral fractures between 1987 and 2010 among girls aged 0–18 years



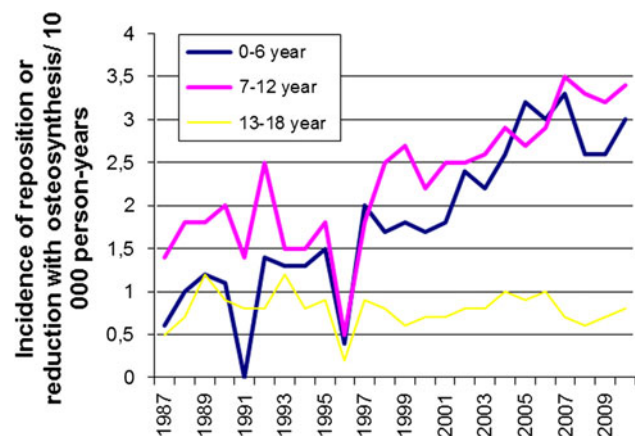
**Fig. 2** Incidence of distal humeral fractures between 1987 and 2010 among boys aged 0–18 years

did not change during the 24 years of the study. In patients aged 0–6 years and 7–12 years, however, the incidence of fractures increased markedly in both sexes after the early 1990s. Girls aged 0–6 years showed the highest increase in the incidence of fractures, from 2.3 per 10,000 person-years in 1987 to 6.4 per 10,000 person-years in 2010 (Fig. 1). The same trend was detected in boys aged 0–6 years—from 3.7 per 10,000 person-years in 1987 to 6.8 per 10,000 person-years in 2010 (Fig. 2).

The overall incidence of repositioning and casting remained steady during the study period, decreasing slightly in patients aged 7–12 years (Fig. 3). The incidence of repositioning or reduction and osteosynthesis increased markedly after 1996, especially in patients aged 0–6 years, from 0.6 per 10,000 person-years in 1987 to 3.0 per 10,000 person-years in 2010; in patients aged 7–12 years, this incidence increased from 1.4 per 10,000 person-years in 1987 to 3.4 per 10,000 person-years in 2010 (Fig. 4).



**Fig. 3** Incidence of repositioning with casting between 1987 and 2010 among girls and boys aged 0–18 years



**Fig. 4** Incidence of repositioning or reduction with osteosynthesis among girls and boys aged 0–18 years between 1987 and 2010

The incidence of external-fixation was very low, with the highest incidence being 0.09 per 10,000 person-years (6 patients) in 1997 in patients aged 0–6 years. Surgical treatment with external-fixation was not related to a longer hospitalization period (mean 1.4 vs 1.9 days in all patients).

**Discussion**

The two principal aims of this study were to describe the incidence of distal humeral fractures leading to hospitalization and the trends in the surgical management of children and adolescents aged 0–18 years in Finland between 1987 and 2010. The main findings were that the incidence of fractures and surgical treatment increased markedly in preteen children beginning towards the end of the 1990s.

The overall incidence of pediatric fractures has increased since the 1950s, but according to Mäyränpää et al.'s population-based study the trend changed during the last two decades [4, 22], with the incidence of all but upper-extremity fractures significantly decreasing [22]. In their Finnish population-based study on the incidence of hospital-treated upper-extremity fractures, Helenius and co-workers [5] reported a 23 % increase in fractures and 28 % increase in operative management during the past 10 years. These findings are supported by those of other studies, but there has been little focus on which type of fractures has increased. Cooper et al. [23] reported that approximately one-third of children sustain at least one fracture before 17 years of age, further suggesting that the overall increasing incidence of fractures may be due to changes in children's activity patterns over time. In addition, new leisure-time physical activities, such as motor vehicle activities, and the popularity of trampolines and skateboards have led to an increase in the incidence of distal humeral fracture, especially supracondylar fractures [24–27]. Distal humeral fractures, especially supracondylar fractures, are usually extension fractures sustained during a fall on an outstretched hand in a child's attempt to protect him/herself [28]. The injury mechanism is quite common and is usually related to low injury energy [28]. In children aged <3 years, the injury mechanism is often a fall from a household object, and in children aged >4 years, it is likely to be due to a fall from playground equipment, as reported by Fransworth et al. [29]. Park et al. [30] presented a playground safety score and suggested that improvements in the playground infrastructure may reduce the incidence of humerus fractures, especially supracondylar fractures. Safety precautions should be implemented in both homes and playgrounds, and the safety aspects of various sport activities should be improved.

Our analysis was based on accurate NHDR data and the annual mid-year population census in Finland. The change in the ICD-classification during the follow-up time had no impact on the collected data, and the trend of increasing incidence of fractures was linear. The collected data cover the entire Finnish population over a 24-year period, and the follow-up time was sufficiently long to estimate the trends of fracture incidence over the long term. Annual incidence rates provide precise information and can be used to detect even small changes in incidence. The findings of our study suggest that the increase in upper-extremity fractures is strongly related to increases in distal humeral fractures. The reason for the increase in these fractures, especially in younger children, may be explained by an increased activity pattern in the children's home. In their study on preschool children, Valerio et al. [31] reported that upper extremity fractures caused by a low-energy injury most often occur at home (42 %) in this age group, followed by

accidents on playgrounds and footpaths (26 %). There has been an increased participation of preschool-age children in activities associated with physical risks, such as jumping on a trampoline without a safety net and playing with motor vehicle toys, which may also contribute to the increased incidence of these types of fractures.

The incidence of repositioning and casting remained low and constant during the study period in the youngest and oldest age groups. In patients aged 7–13 years, however, the incidence of repositioning with casting decreased and at the same time the incidence of repositioning or reduction and osteosynthesis (mostly pinning) increased markedly. Based on previous studies, most distal humeral fractures are supracondylar fractures, so we assumed that changes in the incidence of fractures and treatment mostly included supracondylar fractures. Based on their evidence-based study, Mulpuri et al. [6] recommended surgical treatment for dislocated, unstable fractures (Willkins II and III). Foad et al. reported that surgical treatment with repositioning and pinning with a minimally invasive incision is a safe and effective surgical procedure, regardless of how the pinning is performed [32]. The low complication rates and several advantages, including simple operative procedures, quick recovery time, and good functional results, support surgical treatment [8–10, 12, 13, 32]. On the other hand, Spencer et al. [11] claim that some less severe, stable (Gartland type II) supracondylar fractures can be successfully treated without surgical intervention if close follow-up is possible. Based on the results of our 24-year study, it would appear that both the incidence of fractures and the incidence of surgical treatment have increased. These changes require more economical recourses in terms of planning and preparing pediatric wards and hospitals. The reason for the increased incidence of surgical treatment may be partly explained by the overall increased tendency toward operative treatment for upper extremity fractures [33]. According to Fletcher et al. [34], supracondylar fractures in patients older than 8 years of age are probably caused by higher energy injury and are more severe than those in younger age groups in which the injury energy is usually low. Supracondylar fractures with relatively poor remodeling potential require precise and stable treatment to obtain a satisfactory outcome, which may increase the willingness of the surgeon to ensure the stability of the fracture by pinning, especially in Gartland II type fractures, although such fractures could also be managed by repositioning and close follow-up. The increased concern associated with these fractures may partly explain the increase in operative treatment rather than changes in hospitalization standards.

One strength of this study is the use of data from the Finnish NHDR, which provides an excellent database of patients treated in hospitals during the last 24 years. In

addition, treatment is equally accessible at a comparable standard to all Finnish citizens, and thus patients can be followed in the hospital discharge register based on their personal identification number. The accuracy and coverage of the NHDR are reported to be excellent, and the validity of the data has confirmed in several studies [18–20]. The NHDR also covers private hospitals, which are very uncommon in Finland.

A limitation of this study includes the lack of separation between supracondylar, later-, and medial epicondylar fractures due to the fact that they were classified under the same ICD-10 code. This is a general limitation, however, that is commonly related to hospital discharge register data. Further, the incidence reported in our study is based on hospitalized patients. Patients treated by casting as outpatients were not included in this study. A child or adolescent often requires pain management in the hospital, however, and based on our experience approximately 56 % of these patients are hospitalized. In the Finnish healthcare system, there are no financial incentives that could drive to admission rather than outpatient treatment, and private hospitals do not treat pediatric fracture patients needing overnight care. In conclusion, financial benefit does not explain the increased interest towards operative treatment.

To summarize, the increase in the overall incidence of pediatric upper arm fractures seems to be partially accounted for by an increase in distal humeral fractures, especially in preteen children. Over the last two decades, young children have begun to participate in more risky activities, such as jumping on a trampoline and playing with motor vehicle toys. In the older age group, the severity of fractures may have also increased due to higher energy injuries caused by motor vehicles. This change in activities during a child's everyday life and the simple fracture mechanism by falls on an outstretched hand may explain the increased incidence in fractures. It is unlikely that changes in hospitalization policies have caused this increase in our country. The incidence of surgical treatment by pinning also increased at the same time and may be explained by the overall increased trend toward selecting operative treatment for upper extremity fractures. Distal humeral fractures with low bone remodeling potential require precise and stable reduction, which may increase the willingness of the surgeon to ensure the stability of the fracture by pinning.

**Conflict of interest** None.

## References

1. Beekman F, Sullivan JE (1941) Some observations on fractures of long bones in children. *Am J Surg* 51:722–738
2. Weise K, Schwab E, Scheufele TM (1997) Elbow injuries in childhood. *Unfallchirurg* 100(4):255–269
3. Hanlon CR, Estes WL (1954) Fractures in childhood: a statistical analysis. *Am J Surg* 87:312–323
4. Hedström EM, Svensson O, Bergström U, Michno P (2010) Epidemiology of fractures in children and adolescents. *Acta Orthop* 81(1):148–153
5. Helenius I, Lamberg TS, Kääriäinen S, Impinen A, Pakarinen M (2009) Operative treatment of fractures in children is increasing. A population-based study from Finland. *J Bone Jt Surg Am* 91(11):2612–2616
6. Mulpuri K, Wilkins K (2012) The treatment of displaced supracondylar humerus fractures: evidence-based guideline. *J Pediatr Orthop* 32(2):143–152
7. Wilkins KE (1990) The operative management of supracondylar fractures. *Ortop Clin North Am* 21:269–289
8. Green DW, Widmann RF, Frank JS, Gardner MJ (2005) Low incidence of ulnar nerve injury with crossed pin placement for pediatric supracondylar humerus fractures using a mini-open technique. *J Ortop Trauma* 19(39):158–163
9. Mazda K, Boggione C, Fitoussi F, Pennecot GF (2001) Systematic pinning of displaced extension-type supracondylar fractures of the humerus in children: a prospective study of 116 consecutive patients. *J Bone Jt Surg Br* 83:888–893
10. Zionts LE, Woodson JC, Manjra N, Zalavras C (2009) Time of return of elbow motion after percutaneous pinning of pediatric supracondylar humerus fractures. *Clin Ortop Relat Res* 469(8):2007–2010
11. Spencer HT, Dorey FJ, Zionts LE, Wong MA, Moazzaz P, Silva M (2012) Type II supracondylar fractures: can some be treated nonoperatively? *J Pediatr Orthop* 32(7):675–681
12. Onder E, Emel G, Ahmed A, Uygur D, Yalim A (2009) Treatment of supracondylar fractures of the humerus in children through an anterior approach is a safe and effective method. *Int Ortop* 33(5):1371–1375
13. Reitman RD, Waters P, Millis M (2001) Open reduction and internal fixation for supracondylar humerus fractures of the humerus in children. *J Pediatr Orthop* 21:157–161
14. Bub FR, Schulz AP, Lill H, Voigt C (2011) Supracondylar osteotomies of posttraumatic distal humeral deformities in young adults—technique and results. *Open Ortop J* 5:389–394
15. Bashyal RK, Schoenecker PL, Dobbs MB, Luhmann SJ, Gordon JE (2009) Complications after pinning of supracondylar distal humerus fractures. *J Pediatr Orthop* 29(7):704–708
16. Mehlman CT, Crawford AH, Mcmillion TL, Toy DR (1996) Operative treatment of supracondylar fractures of the humerus in children: the Cincinnati experience. *Acta Orthop Belg* 62(1):41–50
17. Liu RW, Roocroft J, Bastrom T, Yaszay B (2011) Surgeon learning curve for pediatric supracondylar humerus fractures. *J Pediatr Orthop* 31(8):818–824
18. Salmela R, Koistinen V (1987) Is the discharge register of general hospitals complete and reliable? *Sairaala* 49:480–482
19. Keskimäki I, Aro S (1991) Accuracy of data on diagnosis, procedures and accidents in the Finnish Hospital Discharge Register. *Int J Health Sci* 2:15–21
20. Mattila VM, Sillanpää P, Iivonen T, Parkkari J, Kannus P, Pihlajamäki H (2008) Coverage and accuracy of diagnosis of cruciate ligament injury in the Finnish Hospital Discharge Register. *Injury* 39:1373–1376
21. Statistics Finland (2012) Official Statistics of Finland. Statistics Finland, Helsinki
22. Mäyränpää MK, Mäkitie O, Kallio PE (2010) Decreasing incidence and changing pattern of childhood fractures: a population-based study. *J Bone Miner Res* 25(12):2752–2759

23. Cooper C, Dennison EM, Leufkens HG, Bishop N, van Staa TP (2004) Epidemiology of childhood fractures in Britain: a study using the general practice research database. *J Bone Miner Res* 19:1976–1981
24. Hurson C, Browne K, Callender O, O'Donnell T, O'Neill A, Moore DP, Fogarty EE, Dowling FE (2007) Pediatric trampoline injuries. *J Pediatr Orthop* 27(7):729–732
25. Villarin LA, Beck KE, Freid R (1999) Emergency department evaluation and treatment of elbow and forearm injuries. *Emerg Med Clin North Am* 17:844–858
26. Leksan I, Nolic V, Mrela T, Lovric I, Kristek J, Selthofer R (2007) Supracondylar fractures of the humerus in children caused by traffic. *Coll Antropol* 31(49):1009–1013
27. Nysted M, Drogset JO (2006) Trampoline injuries. *Br J Sports Med* 40(12):984–987
28. Carson S, Woolridge DP, Colletti J, Kilgore K (2006) Pediatric upper extremity injuries. *Pediatr Clin North Am* 53(1):41–67
29. Fransworth CL, Silva PD, Mubarak SJ (1998) Etiology of supracondylar humerus fractures. *J Pediatr Orthop* 18(1):38–42
30. Park MJ, Baldwin K, Weiss-Laxer N, Christian JB, Mello MJ, Ebersson C, Spiegel DA (2010) Composite playground safety measure to correlate the rate of supracondylar humerus fractures with safety. An ecologic study. *J Pediatr Orthop* 30(2):101–105
31. Foad A, Penafort R, Saw A, Sengupta S (2004) Comparison of two methods of percutaneous pin fixation in displaced supracondylar fractures of the humerus in children. *J Orthop Surg* 1:76–82
32. Valerio G, Gallè F, Mancusi C, Di Onofrio V, Colapietro M, Guida P, Liguori G (2010) Pattern of fractures across pediatric age groups: analysis of individual and lifestyle factors. *BMC Public Health* 30(10):656
33. Flynn JM, Jones KJ, Garner MR, Boebel J (2010) Eleven years experience in the operative management of pediatric forearm fractures. *J Pediatr Orthop* 30(4):313–319
34. Fletcher ND, Schiller JR, Garg S, Weller A, Larson AN, Kwon M, Browne R et al (2012) Increased severity of type III supracondylar humerus fractures in the preteen population. *Pediatr Orthop* 32(6):567–572

## A CRITICAL ANALYSIS OF POSTOPERATIVE COMPLICATIONS OF ANTEBRACHIUM TEN-NAILING IN 35 CHILDREN

A. Salonen<sup>1</sup>, H. Salonen<sup>1</sup>, O. Pajulo<sup>2</sup>

<sup>1</sup> Department of Pediatric and Adolescent Surgery, Pediatric Clinics and Pediatric Research Centre, Tampere University Hospital, Tampere, Finland

<sup>2</sup> Department of Pediatric Surgery, Pediatric Clinics, Turku University Hospital, Turku, Finland

### ABSTRACT

**Background:** Unstable antebrachium diaphyseal fractures in children are nowadays increasingly treated operatively by elastic intramedullary nailing.

**Aim:** Aim of the study was to critically assess both radiological and functional outcome of antebrachium fractures treated by titanium elastic nail (TEN) in a pediatric cohort.

**Material and Methods:** This retrospective study investigated 75 consecutive children, who were treated for antebrachium shaft fractures at Tampere University Hospital during the time period from January 2001 to December 2005. All the fractures were classified according to OTA. Thirty-five children (mean age 12.3 years) were treated by TEN-nailing. Twenty four of the forearm fractures were unstable, five were open, five were re-fractures and one had ulnar nerve deficit. In all but one patient both forearm bones were fractured. Twelve (34%) operations were managed by closed reduction, open reduction was needed in 23 (66%) patients. In 29 cases both bones were fixed with TEN-nail. In the four patients with re-fracture in both ulna and radius only the radius was TEN-nailed. In one case radius was fixed with TEN-nail and ulna with K-wire and in another case radius was fixed with TEN-nail and ulna with plate. Fracture pattern, mode of reduction, surgical approach, short- and long-term complications and outcome were recorded.

**Results:** Twenty three (66%) patients achieved healing of the fractures without any limitation in range of motion. Twelve patients with postoperative complication were followed up 31–74 (median of 54) months. Eleven (31%) patients had minor postoperative complications and one (0,3%) patient had a Volkmann's ischemic contracture. Five of complicated patients had more than one problem. Immediate post-operative problems were noted in these five patients. At follow-up visits four patients complained of ulnar nail discomfort, two had neural symptoms. Additionally, three children suffered from re-fractures.

**Discussion:** Despite various minor complications, TEN-nailing is considered suitable treatment for unstable forearm shaft fractures. Most of the problems were related to poor technical performance in nailing.

Keywords: Pediatric; adolescent; antebrachium; fracture; operative treatment; internal fixation; TEN-nailing; complication

---

Correspondence:

Anne Salonen, M.D.

Department of Pediatric and Adolescent Surgery

Tampere University Hospital

Teiskontie 35

FI - 33521 Tampere, Finland

Email: anne.salonen@pp7.inet.fi



## INTRODUCTION

Forearm shaft fractures are common injuries in children. Estimates range from 6% to 10% of all pediatric fractures (1, 2). Most of the diaphyseal angulated fractures of the radius and ulna in children are treated with closed reduction and cast immobilisation (3). Conservative treatment for unstable forearm fracture may, however, lead to poor result in up to 50% of patients (4). Malalignments, more than 10 degree deviation in any direction, displacements of the bone or rotational failures can result in severely limited of motion (5). Dislocated antebrachium shaft fractures are recommended to be treated operatively with intramedullary nailing or in some cases plating. Elastic stable intramedullary nailing (ESIN), also called as Nancy nailing was, developed in France in the late 1970s. The results of ESIN nailing have been generally good (4, 6). The titanium elastic nail (TEN Synthes Paoli, PA, USA) set was developed in USA from the ESIN nail. In Finland TEN-nails are commonly used when treating dislocated shaft fracture in children. Titanium nail allows appropriate plastic bending to gain fixation in the bone, while retaining sufficient elasticity to resist unwanted displacement. TEN-nail offers semi-stable fracture fixation with rapid, biological healing and external callus. Removal of the nail is easy and risk of re-fracture is reported to be low (7). Also occurrence of other complications such as wound infection, skin irritation, nerve deficiency and rotational limitation has been reported only in 14.6–16% of the operated children (8, 9). We wanted to review and critically analyze the results of a cohort of Finnish children treated with TEN-nailing for dislocated antebrachium and find possible risk factors leading to complications.

## MATERIAL AND METHODS

All children with antebrachium shaft fractures which were treated with TEN-nailing during the time period from January 2001 to December 2005 were included the study. This retrospective study group was collected by using two antebrachium fracture diagnoses and two operation codes. A total of 35 patients were found. Of these 20 (57%) were boys and 15 (43%) were girls. The age at inclusion of the children ranged from 5.2 years to 17.4 years with a median of 12.3. In the boys age range was from 6.5 years to 17.4 years (median 12.3 years) and the girls' age range was from 5.2 years to 15.8 years (median 10.7 years). Sixteen (46%) of the injuries resulted from a fall, other fractures were related to skateboarding in seven (20%), gymnastic injury in three (9%), football and ice hockey accident in 2 (6%) patients. Other injury mechanisms were motorcycling, riding, roller-skating and trampoline, one patient in each case, and there was one hammer accident.

All the fractures were classified according to the OTA classification (10). There were two 22-A2 type fractures (simple radius fracture), 31 type 22-A3 fractures (a simple fracture of both bones) and two type 22-B3 fractures (simple wedge fracture, or wedge fracture of other bone). Indication for operative treatment was instability in 24 cases, re-fracture after earlier conservative treatment in five cases, grade I open fracture by Gustilo-Anderson in five cases and ulnar nerve palsy with stable forearm fracture in one

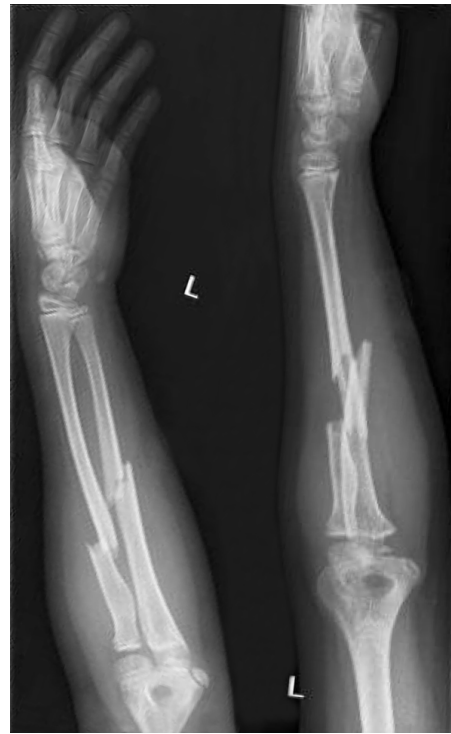

Fig 1. Dislocated antebrachium shaft fracture (22-A3) of a nine-year-old boy.

case (Fig. 1). Thirty-three fractures were intramedullary fixed entirely by TEN-nails. In one operation TEN-nail was combined with plate and in another with K-wire. In four patients only radius was fixed with TEN-nail despite both bones being fractured. Only ulnar or radial fractures were TEN-nailed in one Monteggia- and one Galeazzi-fractures, respectively. In the operation theatre the patient was always positioned supine with the affected arm placed on a radiolucent table. The radial TEN-nail was always inserted retrogradely through a small skin incision and with blunt dissection by protecting the superficial radial nerve. The entry hole on cortex was drilled in proximal to physis and TEN-nail was advanced into intramedullary canal by hand. The ulnar TEN-nail was inserted in similar technique but positioned antegradely from volar proximal medial metaphysis. Both insertion points were verified under image intensifier before skin incision. TEN-nails were buried under the skin to reduce the risk of infection and cut off close to the bone in order to avoid tenting the skin and irritation. Operator was in either a consultant of pediatric surgery or pediatric orthopedics. Twelve (34%) operations were managed by closed reduction and open reduction was needed in 23 (66%) cases. Operation times varied from 20 min to 155 min. Patients without complication median operation time was 70 min and patients with complications 126 min. Two operations took place during night time, both of the resulted complications.

All patients were immobilised up to the first control examination (Fig. 2). Immobilisation with a long arm cast was used in fourteen patients, short arm cast in eleven patients and with a collar cuff in ten patients. Sports limitation was advised from six to eight weeks after operation. The TEN-nails were removed at an average of 25.6 (range five to 53) weeks after the insertion (Fig. 3). Patients with post-operative problems were followed up from 31 to 74 months, with a median of 54 months. The follow up included radiological and clinical evaluation. Functional

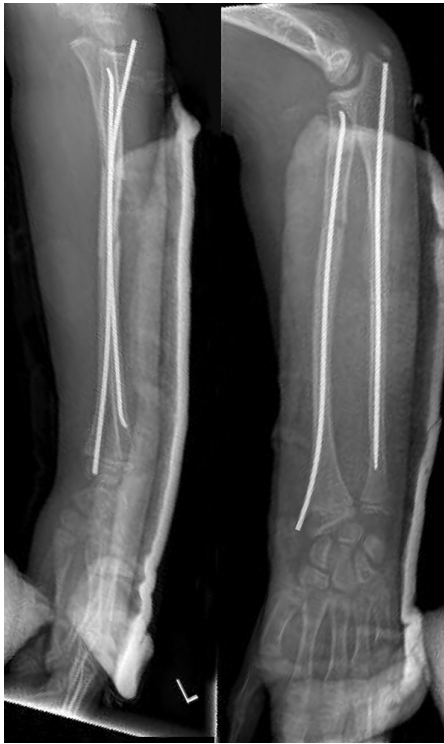

Fig 2. The antebraechium shaft fracture five weeks after the TEN-nail fixation.

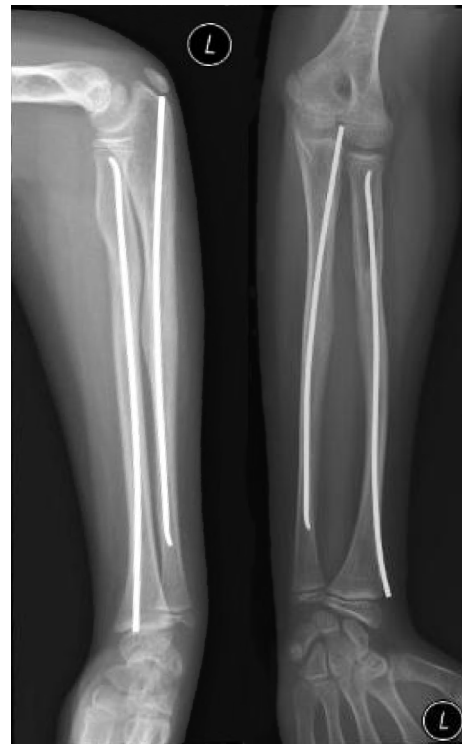

Fig 3. The antebraechium shaft fracture seven months after the TEN-nail fixation.

outcome was assessed clinically by comparing the operated side to the healthy side.

## RESULTS

During the follow up time 23 (66%) fractures united without any problems. Five (14%) patients had short-term and seven (20%) had long-term problems during the follow up time. Complication rate was higher in patients over 10 years (67%, mean age 14.1 years) than in younger ones (33%, mean age 6.9 years). Nearly all fractures were type 22-A3 (Table 1). Five patients had problems immediately after operation (Table 1). The first patient had several complications, he was found to have median nerve neuropraxia already before operation and the neural symptoms were deteriorated postoperatively. At consequent follow up the symptoms persisted and the patient developed 20 degree supination deficit and finally a re-fracture resulted from a fall before removal of TEN-nails. The second patient suffered from post-operative paraesthesia over the dorsum of the thumb. However, this disappeared before second control and the patient recovered fully. The third patient with Monteggia fracture was treated by open reduction. The ulna was fixed with a TEN-nail and the radius was fixed dorsally with a single Kirschner-wire. Before the operation a partial ulnar nerve deficit was noted and postoperatively the ongoing pain over the ulnar nerve distribution was reported by the patient. In the first control visit the flexor contracture was

noted, which led to a referral to the hand surgeons and a Volkmann's ischemic contracture was diagnosed. Consequently, the osteosynthesis material was removed by the hand surgeons concurrently with a flexor release operation ten weeks after the primary operation. During the follow up time the patient recovered fully. The fracture of the fourth patient was still unstable after the operation. The short-arm cast of the patient was changed to a long arm cast in the first post-operative day and finally the patient recovered without any additional problems. The fifth patient with complications had the ulnar TEN-nail malposition recognised on next day after the operation. However, the fracture united well without surgical intervention.

Three out of seven patients with long-term complications had pain caused by ulnar TEN-nail. Supination deficit was recognised in two patients. In one patient 12 degree volar angulation and protruding ulnar nail were noted five weeks after operation. The nail was removed and the patient wore a daytime short arm cast afterwards. Three patients had a re-fracture before removal of TEN-nails. The first patient's re-fracture occurred after first control following heavy tackling in football and the patient was operated on with new TEN-nails and casting. The second patient's fracture occurred three months after primary operation resulting from a fall. In follow up controls there was delayed fracture union. The third patient's radius was TEN-nailed and ulna was plated. During the follow-up controls ulna was poorly united. The re-fracture was treated by plating both

TABLE 1

List of the individual complications, timing of the notification and OTA classification of the forearm fractures in pediatric patients treated operatively.

Patient number	Fracture type	Complications (noted at)					
		Pre-op	Post-op (< 1 week)	1 st control (5 weeks)	2nd control (8 weeks)	3rd control (12 weeks)	follow-up control
1	22-A2	Median nerve deficit	Median nerve neuropraxia			Supination deficit, delayed fracture union	Re-fracture
2	22-A3			Ulnar nail end causing discomfort			
3	22-A3				Supination deficit		
4	22-A3	Ulnar nerve deficit	Ulnar nerve neuropraxia	Volkman's ischaemic contracture			
5	22-A3		Fracture instability				
6	22-B3			Ulnar nail end causing discomfort			
7	22-A3			12 degree volar angulation of radius and ulnar nail protruding			
8	22-A3				Ulnar nail causing discomfort		Wound infection after TEN-nail removal
9	22-A3		Radial nerve deficite				
10	22-A3		Ulnar nail malposition				
11	22-A3					Ulnar non-union	Re-fracture
12	22-A3				Re-fracture		

the radius and the ulna. The patient with ulnar TEN-nail causing pain suffered also from wound infection after removal of TEN-nail. The infection was treated by oral antibiotics.

During the follow up time all these patients recovered well and the functional outcome was good, including the patient with Volkman's contracture. Re-fractures were successfully treated by plating, casting and TEN-nailing.

## DISCUSSION

Up to 85% of unstable antebrachium fractures in children can be managed by closed reduction and long arm cast immobilisation (11). Reduction without osteofixation leads frequently to limited rotation of antebrachium (12). Tarr et al. (1984) have demonstrated in their cadaveric study the following connection between structure and function; angulation between five and ten degrees at the midsaft of the antebrachium can lead to pronation deficit of 10% to 83% of normal as well as supination deficit of 5% to 27%

of normal (13). Although residual angulation is generally well tolerated, there seems to be the consensus that angular deformity >10 degrees and rotational deformity >45 degrees are unacceptable (14, 15). Other indications for operative treatment include open, irreducible, pathologic or malunited fractures or fractures with a neurovascular compromise (6, 8, 16). Compared to plate fixation, which is widely used on adult antebrachium fractures, intramedullary nailing is considered more suitable for children (17). TEN-nailing is a minimally invasive procedure for unstable antebrachium fractures, and it offers definitive management, minimal cosmetic deformity and easy implant removal (9, 16, 18).

Although the TEN-nailing procedure is simple and widely used, minor complications are reported in up to 16 % of the patients (8, 9). Most common minor complications are skin irritation or infections at site of the nail insertion, transient nerve injuries, slight loss of reduction or motion and delayed unions (3, 9, 19). Major complications such as compartment syndrome, permanent nerve injuries and poor technical result leading to reoperation are seen less frequently (18).

During four years of the study we found 75 antebrachium fractures needing reposition under anesthesia. Half of these fractures needed operative fixation by TEN-nailing. Our practise with TEN-nailing differs from that of other centres in some respects. It seems that in our institution open reduction of dislocated shaft forearm fractures is performed significantly more frequently than in other centres. Open reduction was needed in two out of three patients. This rate was high compared with other studies, where the need for open reduction varied from 5 to 29% (1, 8, 20, 21). Open or closed reduction is, however, reported to result in equal functional outcome (22). The mean operation time on all the study patients was especially long – even double as long as the operation time on similar patient group reported by Weinberg et al (2008) (23). Our patients with complications were operated on almost one hour longer than those without complications. The need for open reduction and low experience of the operator predominantly explain the long operation times. Ninety per cent of postoperative problems reported are caused by the sharp ends of the nails and require sometimes shortening after primary operation (20). Three of our patients had skin irritation at insertion of the nails. This problem could have been avoided by paying attention to suitable length of the nails (or using synthetic caps). The rate of superficial radial nerve injury is reported to be 1.2% (20). Two patients in the present study had transient radial or ulnar nerve injury. The nails were inserted in these cases via a small incision, which increases the risk of nerve irritation. Although the nerves recovered fully, this kind of injury can be avoided by visualizing the soft tissue and bone before inserting the nail (19).

Compartment syndrome which leads to contracture is reported in 6.7% patients undergoing intramedullary nailing (8). One of our patients suffered from Volkmann's contracture. This patient had Monteggia-fracture operated by radial K-wire and ulnar TEN-nail. Patients who undergo multiple passes with nail during closed reduction are at increased risk to develop soft tissue injury and compartment syndrome leading to Volkmann's contracture. According to Yuan et al. (2004) the fracture should be opened if closed reduction cannot be reached within three passes (24).

Nails require a sufficient diameter, 40% of the smallest diameter of the medullar canal, both for radius and ulna. Tension of the two nails against one another should be appropriate so the interosseus membrane is tensioned. The three-point support has to be achieved and nails must be inserted far from the fracture line (19, 25). One fracture in our patients was unstable after TEN-nailing. The diameter of TEN-nails was not proper. Another patient's TEN-nail was not proximally in intramedullary canal. These technical problems could have been avoided by testing the fractures under X-ray.

Prevalence of supination deficit rate is reported to be low (26). In our series two patients had transient supination deficit. During the follow up time both patients gained full range of motion. Reason for the

supination deficit may be an insufficient anatomical reduction. Volar angulation problems are reported especially in patients treated only by casting. To prevent angulation, intramedullary nailing for both bones is recommended (27). In our series one patient with both forearm fractures TEN-nailed had volar angulation of radius and protruding ulnar nail. The patient recovered fully during the follow up time.

Re-fractures occur rarely after nailing, only in 0.5% of cases. In conservatively treated fractures re-fracture rate arises up to 10% (19, 20). It is generally accepted that the fracture should be consolidated before starting sports activity and nails should not be removed before four to six months and the fracture must be completely consolidated (20). In our study three patients had re-fracture. We always immobilize the operated arm with collar cuff or cast to prevent too early mobilisation. In one case, the patient started sports activity too early, before permission was given. One of the patients had unusual fixation combination of TEN-nail and plate. And the third patient with both radius and ulna TEN-nailed had delayed fracture union. Flynn et al (2010) operated two fractures of 149 with combined intramedullary nail and plate fixation without any complications (8). In our series both cases operated on with TEN-nail and plate or K-wire combination, i.e. rigid and semi rigid osteofixations led to poor outcome. We do not recommend the mixed use of different fixation methods.

In our study we found that complication rate was higher in patients older than ten years. Same results have been reported earlier (5, 8). Plate fixation might be better alternative than TEN-nailing for patients near adult age.

The question of routine elective execution of TEN-nail is controversial. Simanouvsky et al (2006) investigated retrospectively 143 children of which 11% were symptomatic before removal of TEN-nails. The execution procedure resulted minor complications in five patients (28). Raney et al (2008) reported the complication rate up to 34% for implant removal surgery in their evidence-based analysis (29). In our series all patients went through a removal of TEN-nails; no complications, however, occurred except one postoperative wound infection. In the future the need for routine elective execution of this procedure may be questioned. The problem may rise to some patients who later in adulthood need surgery for the TEN-nailed antebrachium; the implant removal is difficult or even impossible due to bone growth.

We found that the number of minor complications in forearm fracture treated operatively is higher than previously reported. In our study the problem free cases (66%) contain only fractures that did not have any postoperative radiological or functional impairment or discomfort caused by the nail. We believe that special attention to proper surgical techniques would reduce the rates of complications. Based on this study, TEN-nailing with proper technique is suitable treatment for school age children with unstable antebrachium fracture. It is a safe, minimally invasive technique which allows primary and definitive management of these fractures.

## REFERENCES

1. Mann DC, Rajmaira S: Distribution of physeal and non physeal fractures in 2.650 long-bone fractures in children aged 0–16 years. *J Pediatr Ortop* 1990;10:713–716
2. Schmittenebecher PP: Analysis of re-interventions in children's fractures and aspect of quality control. *Eur J Trauma* 2004;30 (in Press)
3. Cullen MC, Roy DR, Giza E, Crawford AH: Complications of intramedullary fixation of pediatric forearm fractures. *J Pediatr Ortop* 1998;18:14–21
4. Mann D, Schnabel M, Baacke M, Getzen L: Results of elastic stable intramedullary nail (ESIN) in forearm fractures in childhood (In German). *Unfallchirurg* 2003;106:102–109
5. Schmittenebecher PP: State-of-the-art treatment of forearm shaft fractures. *Int J Care Injured* 2005;36:S-A25–S-A34
6. Prevot J, Lascombes P, Ligier JN: The ECMES (Centro-Medullary Elastic Stabilising Wiring) osteosynthesis method in limb fractures in children. Principle, application on the femur. Apropos of 250 fractures followed-up since 1979 (in French). *Chirurgia* 1993;119:473–476
7. Hunter JB: The principles of elastic stable intramedullary nailing in children. *Injury* 2005;36:A20–4
8. Flynn JM, Jones KJ, Garner MR: Eleven years experience in the operative management of pediatric forearm fractures. *J Pediatr Ortop* 2010;30(4):313–319
9. Jubel A, Andermahr J, Isenberg J et al: Outcomes and complications of elastic stable intramedullary nailing for forearm fractures in children. *J Pediatr Ortop* 2005;14(4):375–38
10. Charles T. Price, Gregory A. Mencia: Injuries to the shaft of the radius and ulna. In: James H. Beaty, James R. Kasser. *Rockwood and Wilkins' fractures in children*. Lippincott Williams and Wilkins, Philadelphia 2001, pp. 443–482
11. Creasman C, Faleski D, Ehrlich MG: Analyzing forearm fractures in children: the more subtle signs of impending problems. *Clin Ortop* 1984;188:40–45
12. Alpar EK, Thomson K, Woen R: Midshaft fractures of forearm bones in children. *Injury* 1981;13:153–158
13. Tarr R, Garfinkel A, Sarmiento A: The effects of angular and rotational deformities of both bones of the forearm. An in vitro study. *J Bone Joint Surg (Am)*. 1984;66:65–70
14. Darawalla JS: A study of radioulnar movements following fractures of the forearm in children. *Clin Ortop* 1979;139:114–120
15. Price CT, Scott DS, Kurzner ME, Flynn JC: Malunited forearm fractures in children. *J Pediatr Ortop* 1990;10:705–712
16. Lascombes P, Haumont T, Journeau P: Use and abuse of flexible intramedullary nailing in children and adolescents. *J Pediatr Ortop* 2006;26(6):827–834
17. Van der Reijnders WL, Otsuka NY, Moroz P: Intramedullary nailing versus plate fixation for unstable forearm fractures in children. *J Pediatr Ortop* 1998;18(1):9–13
18. Richter D, Ostermann PA, Ekkernkamp A: Elastic intramedullary nailing: A minimally invasive concept in the treatment of unstable forearm fractures in children. *J Pediatr Ortop* 1998;18(4):457–461
19. Schmittenebecher PP, Dietz HG, Linhart WE, Slongo T: Complications and problems in intramedullary nailing of children's fractures. *Eur J Trauma* 2000;26:287–293
20. Lascombes P, Prevot J, Ligier JN et al: Elastic stable intramedullary nailing in forearm shaft fractures in children 88 cases. *J Pediatr Ortop* 1990;10(2):167–171
21. Stanley EA, Wilkins KE: Treatment of midshaft fractures of the radius and ulna utilizing percutaneous intramedullary pinning. *Ortho Trans* 1995;20:305
22. Yalcinkaya M, Dogan A, Ozkaya U: Clinical results of intramedullary nailing following closed or mini open reduction in pediatric unstable diaphyseal forearm fractures. *Acta Orthop Traumatol Turc*. 2010;44(1):7–13
23. Weinberg AM, Castellani C, Amerstorfer F: Elastic stable intramedullary nailing (ESIN) of forearm fractures. *Oper Ortop Traumatol* 2008;20(4–5):285–296
24. Yuan PS, Pring ME, Gaynor TP: Compartment syndrome following intramedullary fixation of pediatric forearm fractures. *J Pediatr Orthop* 2004;24:370–375
25. Slongo TF: Complications and failures of the ESIN technique. *Int J Care Injured* 2005;36:S-A78–S-A85
26. Ali AM, Abdelaziz M, El-Lakanney MD: Intramedullary nailing for diaphyseal forearm fractures in children after failed conservative treatment. *J Orthop Surg* 2010;18(3):328–331
27. Lee S, Nicol RO, Stott NS: Intramedullary fixation for pediatric unstable forearm fractures. *Clin Orthop Relat Res* 2002;402:245–250
28. Simanovsky N, Tair M, Simanovsky N: Removal of flexible titanium nails in children. *J Pediatr Ortop* 2006;26(2):188–192
29. Raney EM, Freccero DM, Dolan LA: Evidence-based analysis of removal of orthopaedic implants in the pediatric population. *J Pediatr Ortop* 2008;28(7):701–704

Received: April 20, 2011

Accepted: November 8, 2011

## PITFALLS OF FEMORAL TITANIUM ELASTIC NAILING

A. Salonen<sup>1</sup>, T. Lahdes-Vasama<sup>1</sup>, V. M. Mattila<sup>2,3</sup>, J. Välipakka<sup>1</sup>, O. Pajulo<sup>4</sup>

<sup>1</sup> Department of Pediatric and Adolescent Surgery, Pediatric Clinics and Pediatric Research Center, Tampere University Hospital, Tampere, Finland

<sup>2</sup> Division of Orthopedics and Traumatology, Department of Trauma, Musculoskeletal Surgery and Rehabilitation, Tampere University Hospital, Tampere, Finland

<sup>3</sup> Department of Orthopedics, Karolinska Hospital, Stockholm, Sweden

<sup>4</sup> Department of Pediatric Surgery, Pediatric Clinics, Turku University Hospital, Turku, Finland

### ABSTRACT

**Background and Aims:** Despite several potential complications of elastic intramedullary nailing, it is currently the treatment of choice for femoral diaphyseal fractures in school-aged children. This study aimed to critically evaluate the complications of titanium elastic nailing in pediatric femoral shaft fractures.

**Material and Methods:** This study evaluated patients with a diaphyseal femoral fracture treated with titanium elastic nailing (TEN) in Tampere University Hospital in Finland. The study group included 32 children with a mean age of 9 years during a 5-year period, from 1 January 2003 to 31 December 2007. Data were collected from medical records and x-rays. Mean follow-up time was 42 months.

**Results:** Of 32 patients, 9 (28%) reported a postoperative complication. Complications were associated with nail prominence in five (16%) patients and instability in four (12%) patients. In patients with nail prominence, the titanium elastic nailing–nail ends were unbent and 10–35 mm outside the cortex of the distal femur. The nail prominence caused pain and delayed knee mobilization until the nail was removed after a mean time of 4 months. In patients with fracture instability, the mean titanium elastic nailing–nail/medullary canal diameter ratio was 46% and periosteal callus formation was 5.4 mm at the first control. In those with stable fractures, the values were 66% and 9.2 mm, respectively.

**Conclusions:** Based on this study, two types of pitfalls in a small volume center were found. Titanium elastic nail ends were left unbent and too long. We recommend palpating the nail ends to exclude nail prominence and to verify free movement of the knee after nail cutting and bending. Fracture instability was caused by inserting titanium elastic nailing–

---

#### Correspondence:

Anne Salonen, M.D.  
Department of Pediatric and Adolescent Surgery  
Pediatric Clinics and Pediatric Research Center  
Tampere University Hospital  
Teiskontie 35  
33521 Tampere  
Finland  
Email: anne.salonen@pp7.inet.fi

**nails that were too narrow. To avoid this complication, careful preoperative planning to select the proper-size titanium elastic nailing–nails and intraoperative testing of fracture stability under continuous fluoroscopy after the operation is advised.**

Key words: Pediatric; diaphyseal femoral fracture; titanium elastic nailing; complication

## INTRODUCTION

Although femoral fractures in children account for only 2% of all orthopedic injuries, they have a significant impact on both the patients and their families, and the utilization of trauma resources as these fractures almost always lead to hospitalization (1–3). During the past 20 years, titanium elastic nailing (TEN) has become the most widely used treatment for diaphyseal femoral fractures in school-aged children over 6 years of age (4–6). The advantages of TEN include its minimal invasiveness and the ability for direct mobilization to maintain joint movement and muscle tone as well as normal circulation (7–10). Hospitalization is usually short term and reduces the treatment cost compared to traditional treatments for traction and spica cast (11, 12). In addition, psychological recovery is accelerated by early resumption of functional activity, allowing for a rapid return to school and ordinary family life (11–14). Despite the various advantages of TEN, however, complication rates of up to 60% have been reported, due mostly to incorrect operative techniques and poor patient selection (15–22). The most common reported complication is soft-tissue irritation at the TEN entry side (15–22). Nail prominence can lead to more serious complications such as skin breakdown; superficial or deep infection, such as osteomyelitis; early implant removal; and risk of re-fracture (5, 8, 9, 11, 20). Other common complications include the inability to achieve a stable reduction or loss of reduction that can lead to delayed fracture union (up to 16% of reported complications), angular malunion, or uncommon rotational malunion (17, 22). In the present study, we critically assessed the complications and pitfalls associated with femoral diaphyseal fractures treated with TEN in a limited pediatric cohort in which the incidence of fractures suitable for TEN is quite low.

## MATERIAL AND METHODS

The study covered all children and adolescents younger than 18 years with a diaphyseal femoral fracture treated at Tampere University Hospital in Finland during a 5-year period from 1 January 2003 to 31 December 2007. Data were collected by applying a main diagnosis of diaphyseal femoral fracture (S72.3) and two operation codes (NFJ60, NFJ64) from the electronic hospital registry. Information obtained from patient files included patient age, sex, weight, injury mechanism, and fracture type. Fractures were classified according to the Orthopaedic Trauma Association and Gustilo-Andersson classifications. The surgical technique for fixation and complications were recorded

from pre- and postoperative x-rays and patient records. Fracture stability/instability was evaluated by comparing fracture position changes between intraoperative x-rays and postoperative x-rays. Cases where the position of the fracture was changed were considered as instable and a cast was applied. The TEN-nail/medullary canal diameter (ND/MD) ratio was evaluated. Duration and time of day of the surgery (day/night) as well as experience of the surgeon (resident/senior) were collected from the patient's surgical record. The surgeon was considered senior after 10 years clinical experience. The periosteal or secondary callus formation was measured from the follow-up x-rays at the first postoperative clinical visit (4–6 weeks after the initial operation) before gradual limb weight-bearing permission was granted. Physical exercises were forbidden for 3 months. Nail tip prominence was recorded as the maximum transverse distance measured from the side of the femur to the distal tip of the nail on the anterior-posterior or lateral radiographs. The distance of the TENs were measured directly after the initial operation and at the first control (mean of 4 weeks after operation). Patients were followed up from 15 to 57 months (mean 42 months), and the follow-up included radiological and clinical evaluation. Functional outcome was assessed clinically by comparing the operated side to the uninjured side.

A total of 102 patients with a diaphyseal femoral fracture younger than 18 years were treated in pediatric unit in Tampere University Hospital during the 5-year study period. Patients older than 16 years were treated with stable intramedullary nailing or plating, and patients younger than 5 years of age were treated with a spica cast. A total of 32 patients (mean = 6.4 fractures per year) suitable for TEN were included in the study. Of these, 22 (70%) were boys and 10 (30%) girls. The mean age of both boys and girls was 9 years. Injuries were mainly related to high-energy accidents such as motor vehicle or snowboard accidents (21, 66%) or playground injuries (9, 28%), such as falling to ground from monkey bars in healthy children. Only two injuries (6%) occurred following very low-energy activities, such as stretching or walking: one in a patient with neuromuscular disease and another with a simple underlying diaphyseal femoral cyst.

## RESULTS

Of 32 fractures, 23 (72%) were united without any problems, and 9 (28%) fractures were associated with skin irritation or fracture instability. All fractures were considered united at the 12-week control and patients were allowed to start free mobilization at that time.

TABLE 1

*Differences between two study groups: patients without postoperative complications and those with postoperative complications.*

	Patients without complications (n = 23)	Patients with complications (n = 9)
Sex		
Female/male	6/17	4/5
Mean age	9.0 years	9.0 years
Mean weight	32 kg (17–57 kg)	35 kg (17–56 kg)
Operator		
Senior/resident	18/5	7/2
Time of surgery		
Day/night	22/1	8/1
Mean operation time	90 min	84 min
Nail insertion		
Retrograde/antegrade	23/0	9/2 two extra TEN-nails were inserted antegrade)
Number of TEN-nails	In all patients, 2 TEN-nails	In 7 patients, 2 TEN-nails In 2 patients, 3 TEN-nails
Mean ND/MD ratio	66%	55%
Mean time of the first control	4 weeks	4 weeks
Mean width of the callus In first control	9.2 mm	5.3 mm

TEN-nails: titanium elastic nailing; ND/MD: TEN-nail/medullary canal diameter.

TABLE 2

*Fractures divided according to the OTA classification and three study groups: patients without postoperative complications and those with postoperative nail prominence or fracture instability.*

OTA classification	Patients without complications (n = 23)	Patients with nail prominence (n = 5)	Patients with fracture instability (n = 4)
32-A2	6 (26%)	1 (20%)	2 (50%)
32-A3	10 (43%)	3 (60%)	1 (25%)
32-B1	3 (13%)	1 (20%)	0 (0%)
33-A1	4 (17%)	0 (0%)	1 (25%)
33-A3	0 (0%)	0 (0%)	0 (0%)

OTA: Orthopaedic Trauma Association.

Two same-size TENs were inserted in all fractures except in two patients who required insertion of three TENs. Most operations were performed by a senior orthopedic surgeon (25, 78%).

Complications were mainly related to the ND/MD ratio, that is, fracture instability and prominence of the TEN at the entry site causing skin irritation and delayed mobilization (Table 1). There was no association between the fracture type and occurrence of complication (Table 2). Two patient fractures were classified as Gustilo-Andersson grade I and II; these fractures united without complications.

Patients with postoperative complications included five patients (16%) with pain or skin irritation at the TEN entry side in the distal femur. In three of five patients, two same-size TENs were inserted retrogradely, while in the other two patients, three TENs were inserted; two same-size TENs inserted retrogradely and a third 1.5-mm TEN inserted antero-gradely. The complication was observed immediately after the operation or at the first control but did not lead to skin breakdown or reoperation during the follow-up. This complication was strongly associated

with nail ends that remained extended at the entry site without being bent toward the side of femur (Fig. 1). All TENs causing pain or skin irritation extended mean 17 mm (10–35 mm) from the cortex and were left unbent toward the skin. In all patients, pain and skin irritation delayed knee motion and overall mobilization until the TEN removal (mean = 4 months compared with 6 months in patients with instability problem and 9 months in patients without complications). A senior pediatric orthopedic surgeon operated on four of the five patients.

In four patients (12%), the fractures were considered unstable after the primary operation (Fig. 2). Fracture was considered unstable if the fracture position was changed between intra- and postoperative x-rays and ND/MD ratio was below 80% at the same time. The differences between groups were considered to be only minor, except for in the ND/MD ratio and periosteal callus formation (Table 3). The ND/MD ratio varied from 36% to 56% (mean 46%) and was lower in those with unstable fractures than in the other groups. All four patients were immobilized with an over-the-knee cast and/or wheelchair at least until the



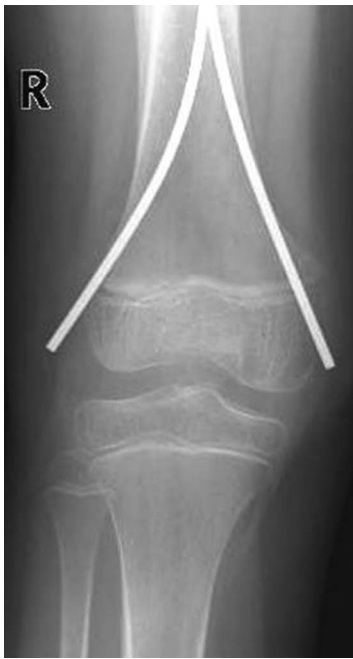

Fig. 1. An 8-year-old girl with nail prominence causing pain and skin irritation.

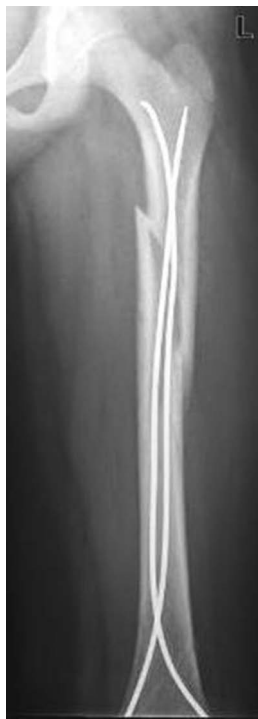

Fig. 2. A 10-year-old boy with postoperative fracture instability.

first control (3–5 weeks). A senior pediatric orthopedic surgeon operated on three of the four patients.

Two of the four patients were previously healthy, one patient had a neuromuscular disease, and the other's fracture was caused by a simple cyst (cyst diameter was as wide as the intramedullary width of femur) in the diaphyseal femur.

The patient with neuromuscular disease required reoperation because a TEN-nail slid out from the intramedullary canal soon (2 weeks) after the primary operation. The ND/MD ratio was 46%. A same-size TEN-nail was reinserted and trimmed, but it slid out again, producing a skin prominence. The TEN was finally removed after 2 months. There was no problem with the other TEN-nail, which was removed 10 months after the primary operation.

The patient with a fracture caused by the simple cyst was immobilized immediately after the primary operation. The ND/MD ratio in this patient was 55%. Despite over-the-knee cast immobilization for 7 weeks after the primary operation, a 12° varus deformity developed and was noticed at the 3-month control, when total bone union was recorded. A corrective osteotomy was performed 6 months after the primary fracture operation. There were no further complications associated with the primary fracture or corrective osteotomy.

In this study, there were no complications associated with the removal of the TEN-nails.

## DISCUSSION

The principal aim of this study was to critically analyze postoperative complications associated with diaphyseal femoral fractures treated with TEN in a limited pediatric cohort in which the incidence of femoral diaphyseal fractures suitable for TEN is quite low. The complication rate was 28%, and the two main complications were nail prominence caused by long unbent distal TEN ends at the insertion side and fracture instability after surgery, resulting from the application of TENs that were too thin.

Based on the literature, elastic titanium nailing is currently the most popular operative method of fixation of femoral diaphyseal fractures in children, despite reported complication rates of up to 60% (4, 6, 9, 16). In our study, the low complication rate of 28% may be partly explained by the experience of the surgeon. On the other hand, complications concerning the TEN technique also occurred in patients operated on by experienced senior orthopedic surgeons. Predictors of complications and/or outcome have been reported in several large studies from centers treating considerable numbers of patients per year (18, 20, 22). The most common complication associated with TEN is pain or skin irritation at the nail insertion site caused by a prominent nail end (19, 20). In our study, nail prominence was the most reported complication causing pain and delayed knee mobilization. Patients with nail irritation were in average heavier and older than the other patients, so it is possible that the amount of subcutis was considered by an operating surgeon to be sufficient enough to cover unbent nail. Additionally, inconvenience and delayed mobilization nail prominence can lead to more severe complications like deep infection or osteomyelitis after skin breakdown and early implant removal with the risk of re-fracture (15, 19). To prevent these complications, it is recommended that the nail ends be trimmed to 1–2 cm from the cortex and unbent nail ends should be applied close to the supracondylar flare at approximately the level of

TABLE 3

*Differences between patients without postoperative complications and those with postoperative nail prominence or fracture instability.*

	Patients without complications (n = 23)	Patients with nail prominence (n = 5)	Patients with postoperative fracture instability (N = 4)
Mean age	9.0 years	8.9 years	10.2 years
Mean weigh	32 kg	45 kg	41 kg
Mean ND/MD ratio	66%	62%	46%
Amount of nails in fracture	All patients, 2 TEN-nails	3 patient, 2 TEN-nails 2 patients, 3 TEN-nails	All patients, 2 TEN-nails
The mean prominence of the TEN-nail from the cortex	3.0 mm	17.0 mm	2.0 mm
Callus formation at the first clinical visit (mean 4 weeks)	9.2 mm	7.0 mm	5.4 mm
Mean time of nail removal	9 months	4 months	6 months

TEN-nails: titanium elastic nailing; ND/MD: TEN-nail/medullary canal diameter.

the physis (15, 20, 21). Technical modifications to standardize the cut point of the nail or to improve the nails by precurving the tip and shaft could also solve some of the nail prominence problems (23, 24). After skin closure, the nail ends under the skin should be palpated while moving the knee to exclude a disturbing nail prominence (21).

In our study, fracture instability was recognized in four patients immediately after the primary operation. In these patients periosteal callus formation was reduced (5.4 mm compared to 9.2 mm in patients without complications) at the first control. Based on animal studies performed by Claes et al. (25) and Aro and Chao (26), periosteal (or secondary) callus formation occurs faster with transverse stable fractures and is delayed in unstable fractures with wide fracture gaps. Instability, leading to a loss of reduction and malunion, is associated with the use of mismatched nail size as well as patients heavier than 49 kg and older than 10 years (17, 18, 21, 27). In the present study, neither patient weight nor age exceeded previous recommendations (17, 18, 21, 27). According to Flynn and Schwend (5), to prevent fracture instability, the ND/MD ratio of the narrowest diameter of the medullary canal should be up to 80% and both TEN-nails should be of the same diameter. Knee immobilization for up to 2 months with a hip-knee-ankle-foot orthosis or cast is advisable after fracture instability (9). In our study, patients with fracture instability were immobilized with an over-the-knee cast and/or wheelchair. Despite immobilization, one patient with over-the-knee cast developed varus deformation. Flynn et al. (9) recommend knee immobilization for up to 2 months with a hip-knee-ankle-foot orthosis or cast after fracture instability. Based on our study, we recommend to focus on to preventing instability, instead of postoperative casting, by selecting wide-enough TENs and testing the fracture stability under fluoroscopy after insertion of the TEN-nails.

In our study, all TENs were removed without complications. Routine removal of TEN-nails is controversial; a clear recommendation does not exist, although the removal complication rates are reported as high as 34% (22, 28, 29). Most authors still recommend nail

removal within 1 year after the operation to prevent difficulties in future orthopedic procedures, nail irritation or prominence problems, and so on (9). In our study, most of the problems arise from TEN irritation. These problems could have been avoided by inserting the TEN-nails into the intramedullary canal and left unrecovered as rigid intramedullary nails. Giving recommendations on the subject is, however, difficult because future risks of unrecovered TEN are not known due to lack of long-term follow-up studies.

Based on this study, the pitfalls of TEN-nailing in pediatric surgery unit in which the incidence of femoral diaphyseal fractures suitable for TEN is low are associated with implant application and selection of proper-size TENs. To avoid these complications, we recommend first measuring the width of the intramedullary canal preoperatively and then choosing two wide-enough, same-size TENs. After positioning the chosen TENs, fracture stability should be verified under continuous fluoroscopy and free knee movement without nail prominence confirmed.

#### DECLARATION OF CONFLICTING INTERESTS

None declared.

#### REFERENCES

1. Cox PJA, Clarke NMP: Improving the outcome of paediatric orthopaedic trauma: an audit of inpatient management in Southampton. *Ann R Coll Surg Engl* 1997;79:441-446.
2. McCartney D, Hinton A, Heinrich SD: Operative stabilization of pediatric femur fractures. *Orthop Clin North Am* 1994;25(4):635-650.
3. Nafei A, Teichert G, Mikkelsen S et al: Femoral fractures in children: an epidemiological study in a Danish urban population, 1977-86. *J Pediatr Orthop* 1992;12(4):499-502.
4. Baldwin K, Hsu J, Wenger D et al: Treatment of femur fractures in school-aged children using elastic stable intramedullary nailing: a systematic review. *J Pediatr Orthop B* 2011;20(5):303-308.
5. Flynn JM, Schwend R: Management of pediatric femoral shaft fractures. *J Am Acad Orthop Surg* 2004;12(5):347-359.
6. Sanders J, Browne R, Mooney J et al: Treatment of femoral fractures in children by pediatric cohort: results of a 1998 survey. *J Pediatr Orthop* 2001;21(4):436-441.
7. Hunter J: Femoral shaft fractures in children. *Injury* 2005;36:A86-A93.

8. Flynn JM, Luedtke L, Ganey T: Comparison of titanium elastic nails with traction and spica cast to treat femoral fractures in children. *J Bone Joint Surg Am* 2004;86:770–777.
9. Flynn JM, Hresko T, Reynolds RAK et al: Titanium elastic nails for pediatric femur fractures: a multicenter study of early results with analysis of complications. *J Pediatr Orthop* 2001;21(1):4–8.
10. Mazda K, Khairouni A, Pennecot G et al: Closed flexible intramedullary nailing of the femoral shaft fractures in children. *J Pediatr Orthop B* 1997;6(3):198–202.
11. Heinrich SD, Drvaric DM, Darr K et al: The operative stabilization of pediatric diaphyseal femur fractures with flexible intramedullary nails: a prospective analysis. *J Pediatr Orthop* 1994;14(4):501–507.
12. Parsch KD: Modern trends in internal fixation of femoral shaft fractures in children. A critical review. *J Pediatr Orthop B* 1997;6:117–125.
13. Song HR, Oh CW, Shin HD: Treatment of femoral shaft fractures in young children: comparison between conservative treatment and retrograde flexible nailing. *J Pediatr Orthop B* 2004;13:275–280.
14. Stans AA, Morrissy RT, Renwick SE: Femoral shaft fracture treatment in patients age 6–16 years. *J Pediatr Orthop* 1999;19(2):222–228.
15. Parikh SN, Jain VV, Denning J et al: Complications of elastic stable intramedullary nailing in pediatric fracture management: AAOS exhibit selection. *J Bone Joint Surg Am* 2012;94(24):e184.
16. Sink EL, Faro F, Polousky J et al: Decreased complications for pediatric femur fractures with a change in management. *J Pediatr Orthop* 2010;30(7):633–637.
17. Ho CA, Skaggs DL, Tang CW et al: Use of flexible intramedullary nails in pediatric femur fractures. *J Pediatr Orthop* 2006;26(4):497–504.
18. Moroz LA, Launay F, Kocher MS et al: Titanium elastic nailing of fractures of the femur in children. Predictors of complications and poor outcome. *J Bone Joint Surg Br* 2006;88(10):1361–1366.
19. Lascombes P, Haumont T, Journeau P: Use and abuse of flexible intramedullary nailing in children and adolescents. *J Pediatr Orthop* 2006;26(6):827–834.
20. Luhmann SJ, Schootman M, Schoenecker PL et al: Complications of titanium elastic nails for pediatric femoral shaft fractures. *J Pediatr Orthop* 2003;23(4):443–447.
21. Narayanan UG, Hyman JE, Wainwright AM: Complications of elastic stable intramedullary nail fixation of pediatric femoral fractures, and how to avoid them. *J Pediatr Orthop* 2004;24(4):363–369.
22. Ligier JN, Metaizeau JP, Prevot JP et al: Elastic stable intramedullary nailing of femoral shaft fractures in children. *J Bone Joint Surg Br* 1988;70(1):74–77.
23. Lascombes P, Nespolo A, Poircuittie JM et al: Early complications with flexible intramedullary nailing in childhood fracture: 100 cases managed with precurved tip and shaft nails. *Orthop Traumatol Surg Res* 2012;98(4):369–375.
24. McDonell SM, Alsousou J, Handley RC: A simple technique for easy removal of titanium elastic nails. *Ann R Coll Surg Engl* 2009;91(1):86.
25. Claes L, Augat P, Suger G et al: Influence of size and stability of the osteotomy gap on the success of fracture healing. *J Orthop Res* 1997;15(4):577–584.
26. Aro HT, Chao EY: Bone-healing patterns affected by loading, fracture fragment stability, fracture type, and fracture site compression. *Clin Orthop Relat Res* 1993;(293):8–17.
27. Wall EJ, Jain V, Vora V et al: Complications of titanium and stainless steel elastic nail fixation of pediatric femoral fractures. *J Bone Joint Surg Am* 2008;90:1305–1313.
28. Raney EM, Freccero DM, Dolan LA et al: Evidence based analysis of removal of orthopaedic implants in the pediatric population. *J Pediatr Orthop* 2008;28:701–704.
29. Morshed S, Humphrey M, Corrales LA et al: Retention of flexible intramedullary nails following treatment of pediatric femur fractures. *Arch Orthop Trauma Surg* 2007;127(7):509–514.

Received: November 14, 2013

Accepted: February 24, 2014