



PÄIVI ROVIO

## Uterine Leiomyomas

Studies on Etiology, Ultrasound Diagnostics and Surgical Treatment



ACADEMIC DISSERTATION

To be presented, with the permission of  
the Faculty of Medicine of the University of Tampere,  
for public discussion in the Small Auditorium of Building K,  
Medical School of the University of Tampere,  
Teiskontie 35, Tampere, on October 31st, 2008, at 12 o'clock.

UNIVERSITY OF TAMPERE

ACADEMIC DISSERTATION

University of Tampere, Medical School

Tampere University Hospital, Department of Obstetrics and Gynecology  
Finland

*Supervised by*

Professor Pentti Heinonen

University of Tampere

Finland

*Reviewed by*

Docent Ilkka Järvelä

University of Oulu

Finland

Professor Marjo Tuppurainen

University of Kuopio

Finland

Distribution

Bookshop TAJU

P.O. Box 617

33014 University of Tampere

Finland

Tel. +358 3 3551 6055

Fax +358 3 3551 7685

taju@uta.fi

www.uta.fi/taju

http://granum.uta.fi

Cover design by

Juha Siro

Acta Universitatis Tamperensis 1363

ISBN 978-951-44-7503-0 (print)

ISSN 1455-1616

Acta Electronica Universitatis Tamperensis 784

ISBN 978-951-44-7504-7 (pdf)

ISSN 1456-954X

http://acta.uta.fi

Tampereen Yliopistopaino Oy – Juvenes Print

Tampere 2008

To Esa, Vilma, Helmi, Otso and "Orvokki"



# CONTENTS

CONTENTS.....	5
1 LIST OF ORIGINAL COMMUNICATIONS.....	8
2 ABBREVIATIONS.....	9
3 ABSTRACT.....	10
4 TIIVISTELMÄ.....	12
5 INTRODUCTION.....	14
6 REVIEW OF THE LITERATURE.....	16
6.1 Uterine leiomyomas.....	16
6.1.1 General characteristics and incidence.....	16
6.1.2 Classification of uterine leiomyomas.....	16
6.1.3 Etiology of uterine leiomyomas.....	18
6.1.3.1 Genetics.....	18
6.1.3.2 Hormones.....	19
6.1.3.2.1 Estrogen.....	19
6.1.3.2.2 Progesterone.....	19
6.1.3.3 Growth factors.....	20
6.1.4 Risk factors for uterine leiomyomas.....	20
6.1.4.1 Age and parity.....	22
6.1.4.2 Family history and ethnicity.....	22
6.1.4.3 Life style factors.....	22
6.1.4.4 Endo- and exogenous hormonal factors.....	23
6.1.4.5 Uterine sarcoma.....	24
6.1.4.6 Natural history of uterine leiomyomas.....	24
6.1.5 Vitamin D and cell proliferation.....	25
6.2 Symptomatology of uterine leiomyomas.....	26
6.2.1 Abnormal bleeding.....	26
6.2.2 Pain and pressure effects.....	27
6.3 Diagnostics of uterine leiomyomas.....	28
6.3.1 Imaging.....	28
6.3.1.1 Sonography, saline-infusion sonography and hysteroscopy.....	28
6.3.1.2 Magnetic resonance imaging.....	30

6.4	Uterine leiomyomas and reproduction .....	30
6.4.1	Fertility .....	30
6.4.2	Pregnancy .....	31
6.5	Treatment of uterine leiomyomas .....	32
6.5.1	Surgical treatment.....	33
6.5.1.1	Hysterectomy .....	33
6.5.1.2	Abdominal myomectomy.....	33
6.5.1.3	Laparoscopic myomectomy .....	35
6.5.1.4	Laparoscopic-assisted myomectomy .....	36
6.5.1.5	Vaginal myomectomy .....	36
6.5.1.6	Laparoscopic-assisted vaginal myomectomy .....	37
6.5.1.7	Hysteroscopic myomectomy.....	37
6.5.1.8	Other techniques .....	39
6.5.2	Nonsurgical treatment .....	40
6.5.2.1	Myoma embolization .....	40
6.5.2.2	Magnetic resonance guided focused ultrasound surgery .....	42
6.5.2.3	Hormonal treatment .....	42
6.5.2.3.1	Gonadotropin-releasing hormone agonists .....	42
6.5.2.3.2	Others .....	43
7	AIMS OF THE STUDY .....	45
8	PATIENTS AND METHODS.....	46
8.1	Patients and study designs.....	46
8.2	Vitamin D assay for leiomyoma and myometrial samples (I) .....	48
8.3	Determination of uterine volume (II-III) .....	49
8.3.1	Ultrasound measurements and calculation of volume.....	49
8.3.2	Measurements of uterine preparates.....	50
8.4	Operative techniques in myomectomy and follow-up (IV-V) .....	51
8.4.1	Transvaginal myomectomy (IV) .....	51
8.4.2	Endometrial resection and myomectomy (V) .....	51
8.5	Statistical analysis .....	52
8.6	Ethical considerations .....	53
9	RESULTS .....	54
9.1	The effect of 1,25(OH) <sub>2</sub> D <sub>3</sub> and 25(OH)D <sub>3</sub> vitamin D derivates on leiomyoma and myometrial cells.....	54

9.2 Accuracy of a combination formula in estimating the weight of the uterus and quality assurance of these measurements (II, III).....	55
9.2.1 Comparison of two different formulas and real uterine weight (II).....	56
9.2.2 Sources of variation (III) .....	57
9.3 Clinical effectiveness and safety of vaginal myomectomy by traction method (IV) .....	59
9.3.1 Perioperative characteristics .....	59
9.3.2 Follow-up.....	60
9.4 Hysterectomy rates after hysteroscopic endometrial resection with or without myomectomy (V) .....	60
9.4.1 Perioperative characteristics .....	60
9.4.2 Follow-up.....	61
10 DISCUSSION .....	63
10.1 Vitamin D derivates and the proliferation of leiomyoma cells.....	63
10.2 Estimation of the size of the myomatous uterus.....	65
10.2.1 Quality control of a combination formula .....	66
10.3 Surgical treatments of uterine myomas .....	67
10.3.1 Clinical effectiveness and safety of vaginal myomectomy .....	68
10.3.2 Hysteroscopic myomectomy associated with endometrial resection.....	69
11 SUMMARY AND CONCLUSIONS .....	72
12 ACKNOWLEDGEMENTS .....	74
13 REFERENCES.....	76
14 ORIGINAL COMMUNICATIONS .....	101

# 1 LIST OF ORIGINAL COMMUNICATIONS

This thesis is based on the following original publications, which are referred to in the text by their Roman numerals. Some unpublished data are also presented.

- I Bläuer M, Rovio PH, Ylikomi T, Heinonen PK: Vitamin D inhibits myometrial and leiomyoma cell proliferation *in vitro*. Fertil Steril, in press.
- II Rovio PH, Luukkaala T, Vuento M, Oksa S, Sundström H, Heinonen PK (2008): Ultrasonographic assessment of weight of the myomatous uterus: A pilot study using a new combined geometrical formula. Eur J Obstet Gynecol Reprod Biol 137:193-197.
- III Rovio PH, Luukkaala T, Vuento M, Oksa S, Heinonen PK (2008): Quality assurance in ultrasonographic measurements of the myomatous uterus. Open Medical Imaging Journal 2:62-66.
- IV Rovio PH, Heinonen PK (2006): Transvaginal myomectomy with screw traction by colpotomy. Arch Gynecol Obstet 273:211-215.
- V Rovio PH, Helin R, Heinonen PK: Long-term outcome of hysteroscopic endometrial resection with or without myomectomy in patients with menorrhagia. Arch Gynecol Obstet, in press.



## 2 ABBREVIATIONS

E <sub>2</sub>	estradiol
EGF	epidermal growth factor
ER	estrogen receptor
BFGF	basic fibroblast growth factor
BMI	body mass index
GnRH	gonadotropin-releasing hormone
IGF	insulin-like growth factor
LNG-IUS	levonorgestrel-releasing intrauterine system
MPA	medroxyprogesterone acetate
MRI	magnetic resonance imaging
MRNA	messenger ribonucleic acid
PDGF	platelet-derived growth factor
PR	progesterone receptor
PTH	parathyroid hormone
R&R	repeatability and reproducibility
SMA	smooth muscle actin
TGF- $\beta$	transforming growth factor- $\beta$
VDR	vitamin D receptor
VEGF	vascular endothelial growth factor
1,25(OH) <sub>2</sub> D <sub>3</sub>	1 $\alpha$ ,25-dihydroxycholecalciferol, calcitriol
2D	two-dimensional ultrasound
3D	three-dimensional ultrasound
25(OH)D <sub>3</sub>	25-hydroxycholecalciferol

### 3 ABSTRACT

Uterine leiomyomas constitute a substantial health issue for women and these benign tumors represent the most common single indication for hysterectomy. Leiomyomas have a major impact on economic costs and the quality of life of the patient.

Vitamin D is a potent anti-proliferative and immunomodulatory secosteroid hormone. Apart from its well-established role in the maintenance of calcium homeostasis, vitamin D modulates cell proliferation, differentiation, cancer invasion and angiogenesis. Despite extensive research on the role of vitamin D in the inhibition of cell growth in a large variety of tissues, there are no reports concerning the possible growth-modulatory effects of vitamin D on benign uterine tumor cells. The first aim of the present study was to assess the potential effect of 1,25(OH)<sub>2</sub>D<sub>3</sub> and 25(OH)D<sub>3</sub> vitamin D derivatives on the growth of leiomyoma and myometrial cells *in vitro*. Samples of leiomyomas and normal myometrial tissues were obtained from six premenopausal women with uterine leiomyomas undergoing hysterectomy. Paired cultures were established and the effect of these two compounds examined using a colorimetric crystal violet assay. Vitamin 1,25(OH)<sub>2</sub>D<sub>3</sub> effectively and concentration-dependently inhibited the growth of myometrial and leiomyoma cells. Hypovitaminosis D may play a role in the etiology and growth of leiomyoma cells.

Manual palpation and estimation of the size of the uterus is an important part of the routine gynecological examination, as it is necessary to exclude abnormal growth of this reproductive organ due to benign or malignant tumors. The size of the uterus is also a crucial factor in assessing the method of hysterectomy most appropriate for the patient. The dominant practice is to estimate the size of the nonpregnant uterus by bimanual examination and compare it to a pregnant uterus of comparable size. However, only a rough estimate may be obtained by this method, and other more accurate means for the purpose have been developed. Gynecological ultrasound and use of the geometric formula of the prolate ellipsoid has been the most common means of estimating the uterine dimensions by imaging techniques. This method has also involved a potential for errors in estimation of uterine size.

The second aim here was to evaluate the accuracy of a new formula combining the prolate ellipsoid (uterine corpus) and cylinder (uterine cervix) formulas in estimating the preoperative weight of the total myomatous uterus, using a transvaginal ultrasound probe to obtain the uterine dimensions for the formulas. The third aim was to establish different sources of variation in these measurements using repeatability and reproducibility method. The length, width and anteroposterior diameter of the uterine corpus, and the length and anteroposterior diameter of the cervix were preoperatively determined using a transvaginal ultrasound probe in 12 women with symptomatic leiomyomas scheduled to undergo hysterectomy. Three

investigators repeated all rounds of measurement three times, producing in total of 108 findings. The geometric formula of prolate ellipsoid was compared to a formula combining the ellipsoid and cylinder formulas for accuracy in predicting overall uterine size (corpus and cervix) through correlation with hysterectomy specimens.

The new combination formula was more accurate in predicting the true total weight of the uterus than the plain prolate ellipsoid formula, and the transvaginal ultrasound probe proved useful in evaluating the dimensions of the uterine corpus and cervix. Variation due to differences across trials (repeatability), across physicians (reproducibility), and across patients (variability) was then estimated. The more experienced the physician was in taking the ultrasound measurements, the less deviation was observed between her own three measurements. The experience of the physician thus had an effect on repeatability (differences across measurements), but not on reproducibility (differences across physicians), in estimating uterine weight by ultrasound.

Surgery is the cornerstone of treatment for leiomyomas. Hysterectomy serves as a terminal procedure, while myomectomy is a treatment of choice for women who desire future pregnancies or otherwise wish to retain their uterus. The fourth aim was to evaluate the clinical effectiveness and safety of the enucleation of uterine leiomyomas by traction method via colpotomy. Ten women with menorrhagia, pelvic pain or secondary infertility associated with single uterine myomas underwent transvaginal myomectomy with screw traction by colpotomy. Traction myomectomy was completed vaginally in all patients. All women reported relief of their symptoms after a mean follow-up of 24 months. Three patients had a term delivery postoperatively. Traction myomectomy by colpotomy proved to be a feasible approach for selected patients wishing to preserve their ability to conceive. A single well-lined myoma of 5-8 cm diameter and accessible via colpotomy is a suitable subject for the procedure.

The fifth aim was to study long-term outcomes and hysterectomy rates after hysteroscopic endometrial resection with or without myomectomy for menorrhagia. Endometrial resection and concomitant hysteroscopic myomectomy was performed in 53 women involving submucous myomas with an intramural extension of less than 50 % and smaller than 5 cm in diameter. Each subject was matched with a patient who had no submucous myomas and who had been treated by endometrial resection only. During the mean follow-up period of 6.5 years, hysterectomy was performed in 26.9 % of the patients with myomectomy and in 17.0 % of those without ( $p=0.22$ ). Most (75.6 %) of the 82 women who had not required hysterectomy had reached menopause. All the patients without hysterectomy in both groups reported amenorrhoea or slight bleeding, and this response persisted for years after the treatment. Endometrial resection may be combined with hysteroscopic myomectomy without a significant increase or decrease in hysterectomy rates during a long-term follow-up.

# 4 TIIVISTELMÄ

Kohtumyoomilla on merkittävä vaikutus naisen terveyteen ja elämänlaatuun. Nämä hyvänlaatuiset kasvaimet ovat myös yleisin yksittäinen kohdunpoistoleikkauksen syy.

D- vitamiini on tehokas antiproliferatiivinen ja immunitettä säätelevä steroidihormoni, jonka vaikutukset kalsiumtasapainoon tunnetaan hyvin. Se moduloi solujen proliferaatiota ja erilaistumista, syöpäinvaasiota sekä verisuonten uudismuodostusta. Vaikka D- vitamiinin merkitystä solujen kasvun estossa on tutkittu lukuisilla eri kudostyypeillä, julkaisuja D- vitamiinin mahdollisista vaikutuksista hyvänlaatuisten kohtulihaskasvainsolujen kasvun säätelyyn ei ole. Nykytutkimuksen ensimmäinen tavoite oli selvittää  $1,25(\text{OH})_2\text{D}_3$  - ja  $25(\text{OH})\text{D}_3$  - D- vitamiinijohdannaisten vaikutus myooma- ja kohtulihassolujen kasvuun *in vitro*. Kuudelta vaihdevuosi- ikää lähestyvältä naiselta otettiin myooma- ja kohtulihasnäytteet kohdunpoistoleikkauksen yhteydessä. Näistä muodostettiin soluviljelmät ja edellä mainittujen D- vitamiinijohdannaisten vaikutukset viljelmiin tutkittiin kristalliviolettikolorimetrialla.  $1,25(\text{OH})_2\text{D}_3$  esti tehokkaasti ja konsentraatioriippuvaisesti kohtulihassolujen ja myoomasolujen kasvua. D- vitamiinin puutteella saattaa olla merkitystä myoomasolujen etiologiassa ja kasvussa.

Kohdun tunnustelu ja sen koon arviointi on tärkeä osa gynekologista tutkimusta hyvän- tai pahanlaatuisten kasvainten aiheuttaman poikkeavan kasvun poissulkemiseksi. Kohdun koko on myös merkittävä tekijä valittaessa potilaalle parhaiten soveltuvaa kohdunpoistomenetelmää. Yleinen käytäntö on ilmoittaa koko käyttäen hyväksi vastaavia raskausviikkoja. Näin päästään kuitenkin vain karkeaan arvioon ja tarkempia menetelmiä on pyritty kehittämään tätä tarkoitusta varten. Kuvantamistekniikoista yleisin tapa on ollut gynekologinen ultraäänitutkimus yhdistettynä matemaattisen ellipsoidin kaavan käyttöön. Tässäkin menetelmässä on ollut virhelähteitä.

Tämän tutkimuksen toinen tavoite oli selvittää uudenlaisen, ellipsoidin (kohdun runko- osa) ja sylinterin (kohdun kaulaosa) kaavan yhdistävän matemaattisen kaavan tarkkuus leikkausta edeltävän kohdun kokonaispainon arvioinnissa hyödyntäen emättimen kautta tehtävää ultraäänitutkimusta kohtumittojen otossa. Kolmas tavoite oli selvittää erilaisia tilastollisen variaation lähteitä näissä mittauksissa toistettavuustutkimusta käyttäen. Kohdunrunгон pituus, leveys ja paksuus sekä kohdunkaulan pituus ja paksuus määritettiin emättimen kautta ultraäänellä ennen kohdunpoistoleikkausta 12 potilaalta, joilla oli oireita aiheuttavat myoomat. Kolme tutkijaa suoritti mittaukset kolme kertaa, jolloin mittaustulosten kokonaismäärä oli 108. Ellipsoidin kaavan ja ellipsoidin ja sylinterin yhdistelmäkaavan tarkkuutta kohdun kokonaiseen arvioinnissa verrattiin poistetun kohdun todelliseen kokoon.

Uusi yhdistelmäkaava ennusti tarkemmin kohdun todellisen kokonaispainon kuin pelkkä ellipsoidin kaava. Tutkimusten, lääkäreiden ja potilaiden keskinäisistä eroista johtuva variaatio selvitettiin. Mitä kokeneempi lääkäri oli ultraäänimittausten otossa, sitä vähemmän hajontaa todettiin hänen kolmen oman mittauksensa välillä. Lääkärin kokeneisuudella oli siten vaikutusta eroihin mittausten kesken, muttei eroihin lääkäreiden kesken arvioitaessa kohdun painoa ultraäänellä.

Myoomien hoidon kulmakivi on leikkaus. Kohdunpoistoleikkaus on lopullinen toimenpide, kun taas myooman poisto on paras vaihtoehto potilaalle, joka toivoo vielä raskauksia tai muusta syystä kohdun säästämistä. Tutkimuksen neljäs tavoite oli arvioida emättimen pohjukan kautta tehtävän myooman poiston kliinistä tehokkuutta ja turvallisuutta. Tämä toimenpide tehtiin kymmenelle potilaalle, joilla esiintyi yksittäiseen myoomaan liittyen runsaita kuukautisvuotoja, lantion seudun kipua tai sekundaarista hedelmättömyyttä. Myooman poisto onnistui kaikilla potilailla emättimen kautta. Keskimääräisen 24 kuukauden seuranta- ajan jälkeen kaikki potilaat ilmoittivat oireiden helpottaneen. Kolme potilasta synnytti täysiaikaisen lapsen toimenpiteen jälkeen. Leikkaus osoittautui käyttökelpoiseksi vaihtoehdoksi valikoiduille potilaille, jotka toivoivat pystyvänsä säilyttämään raskausmahdollisuutensa. Leikkaukseen soveltuu parhaiten potilas, jolla on yksittäinen, hyvin rajautuva, 5-8 cm halkaisijaltaan oleva myooma, johon on mahdollista yltää emättimen kautta.

Tutkimuksen viides tavoite oli selvittää kohdun tähytyksessä tehtävän pelkän kohdun limakalvon höyläyksen ja tämän sekä toimenpiteeseen yhdistetyn myooman poiston jälkeisiä pitkäaikaistuloksia sekä kohdunpoistomääriä. Kohdun limakalvon höyläys yhdistettynä myooman poistoon tehtiin 53 naiselle. Näillä potilailla oli kohdun limakalvon alainen myooma, jonka halkaisija oli alle 5 cm ja josta alle puolet sijaitsi kohdun lihaskerroksessa. Jokaiselle potilaalle etsittiin verrokki, jolla ei ollut kohdun limakalvon alaisia myoomia ja jolle tehtiin pelkkä kohdun limakalvon höyläys. Keskimääräisen 6.5 vuoden seuranta- ajan jälkeen kohdunpoistoleikkaus tehtiin 26.9 %:lle potilaista, joille oli tehty samalla myooman poisto ja 17.0 %:lle, joille oli tehty pelkkä kohdun limakalvon höyläys. Valtaosa (75.6 %) 82 potilaasta, joille ei ollut tehty kohdunpoistoa, oli ehtinyt vaihdevuosi- ikään. Kaikki potilaat, joille ei ollut tehty kohdunpoistoleikkausta, ilmoittivat kuukautisten jääneen pois tai olevan niukat molemmissa tutkimusryhmissä. Tämä vaste säilyi vuosia hoidon jälkeen. Kohdun limakalvon poisto voidaan yhdistää kohdun tähytyksessä tehtävään myooman höyläykseen ilman että kohdunpoisto- määrät merkittävästi vähenevät tai kasvavat pitkän seurannan aikana.

# 5 INTRODUCTION

Uterine leiomyomas are the most general pelvic tumors in women and represent the single commonest indication for hysterectomy. These benign neoplasms have a major impact on women's health, as they can cause significant morbidity, including heavy or prolonged menstrual bleeding, pelvic pressure or pain, and, more rarely, reproductive dysfunction. Thus, both the economic cost and the effect on quality of life are notable.

Despite extensive research on the factors involved in the initiation and growth of uterine leiomyomas, the precise causes of these tumors still remain unknown. Chromosomal abnormalities have been found in 40-50 % of uterine leiomyomas (Nilbert and Heim 1990, Ligon and Morton 2000). Intrinsic abnormalities of the myometrium, congenitally elevated myometrial estrogen receptors (ER), hormonal changes, or a response to ischemic injury during menstruation may possibly be responsible for the initiation of genetic changes found in these neoplasms (Richards and Tiltman 1996, Stewart and Nowak 1996, Rein 2000). When these changes have developed, they are further influenced by ovarian steroids (promoters) and growth factors (effectors) (Rein and Nowak 1992, Mangrulkar et al. 1995, Rein et al. 1995).

Leiomyomas are the most common reason for enlargement of the uterus. Manual palpation and estimation of the size of the uterus forms an important part of the gynecological examination, as it is necessary to exclude abnormal growth of this reproductive organ due to benign or malignant tumors. The size of the uterus is also a crucial factor in assessing the method of hysterectomy most appropriate for the patient (Kovac 1995). The size, number and position of myomas should be established with an eye to optimal choice of patients for medical therapy, noninvasive or invasive procedures. Sonography with or without saline infusion, hysteroscopy or magnetic resonance imaging (MRI) can be utilized for the purpose.

Only symptomatic or rapidly growing uterine leiomyomas should be actively treated, and surgery remains a cornerstone of therapy. Hysterectomy represents a terminal procedure, while myomectomy and myolysis are treatments of choice for women desiring future pregnancies or otherwise wishing to retain their uterus. Myoma embolization or magnetic resonance-guided focused ultrasound surgery are nonsurgical options for patients who have completed childbearing. Hormonal therapy may be used to relieve symptoms associated with uterine leiomyomas and it may enable conservation of the uterus. However, symptoms often rapidly return after discontinuation of the treatment.

The aim of this study was to bring out certain new aspects of the etiology, diagnostics and surgical treatment of uterine leiomyomas. The first objective was to determine the effects of two vitamin D derivatives on the growth of leiomyoma and myometrial cells *in vitro*. The study also sought to evaluate the accuracy of a

formula combining the prolate ellipsoid and cylinder formulas in estimating the weight of the myomatous uterus prior to hysterectomy, using transvaginal sonography. Different sources of variation in estimating the preoperative uterine weight were also analyzed. In addition, the clinical effectiveness and safety of a novel traction modification of vaginal myomectomy was studied. The last aim was to compare hysterectomy rates after hysteroscopic endometrial resection with or without myomectomy for menorrhagia and to establish the long-term outcomes of these two procedures.

# 6 REVIEW OF THE LITERATURE

## 6.1 Uterine leiomyomas

### 6.1.1 General characteristics and incidence

Leiomyomas are benign, monoclonal smooth muscle cell neoplasms presenting in both sexes, approximately 95 % occurring within the female uterus (Cotran et al. 1989). These tumors arise from the uterine myometrium and are composed of extracellular matrix containing collagen, fibronectin and proteoglycan. The collagen fibrils are in disarray and abnormally formed (Ferenczy et al. 1971, Kawaguchi et al. 1989, Stewart et al. 1994). The leiomyomas and the myometrium share the same ultrastructure (Kawaguchi et al. 1985). Uterine leiomyomas can present as isolated microscopic growths but are more commonly multiple and may reach massive proportions, weighing more than 45 kg (Conley and Lacey 1987).

Uterine leiomyomas are the most common solid pelvic tumors in women, occurring in an estimated 20-50 % of all women over the age of 30 years (Wallach 1992). The incidence of leiomyomas is found to be 60 % among African-American women by the age of 35, the number increasing to over 80 % by the age of 50. Corresponding incidences among Caucasian women are of 40 % by 35, and almost 70 % by 50, respectively (Day Baird et al. 2003). It is estimated that in Finland every second woman has uterine leiomyomas (Luoto et al. 1994). In a study by Cramer and Patel (1990), a gross serial sectioning at 2-mm intervals applied in hysterectomy specimens from 100 consecutive women revealed leiomyomas in 77 %. Leiomyomas occur during reproductive life and they have tendency to regress after menopause. Women are most likely to be diagnosed with leiomyomas at the age of 40-50 (Merril and Creasman 1986), although these tumors have been found in girls as young as 11 years (Novak and Woodruff 1979).

### 6.1.2 Classification of uterine leiomyomas

Leiomyomas are classified according to their location (Figure 1) in the uterus. Firstly, they can be situated cervically or corporeally, the former constituting only a small fraction of the total number (Novak and Woodruff 1979, Jones and Jones 1981). The most common location in the cervix is the posterior wall, although lateral and anterior leiomyomas also have been found. A majority of leiomyomas occur in the uterine corpus (Novak and Woodruff 1979). Secondly, although



recognizing that myomas are of variable shape and size, they are commonly subdivided into subserous, intramural and submucous varieties.

Intramural leiomyomas, which are also most common, are situated in the myometrium without connection to the uterine mucosa or serosa. As these tumors grow, they distort the intrauterine cavity as well as the outer margin of the uterus. Solitary intramural leiomyomas may also enlarge the uterus symmetrically (Merrill and Creasman 1986).

Subserous leiomyomas are situated immediately beneath the uterine serosa and swell the outer margin of the uterus. As they grow, they may eventually become pedunculated (Merrill and Creasman 1986). The incidence of this type of leiomyoma is not well known (Buttram and Reiter 1981). In rare cases, a pedunculated tumor may become attached to adjacent inner organs, peritoneum or omentum, lose their original blood circulation and develop a secondary one from adjacent structures. Such leiomyomas are called parasitic. Intraligamentary tumors develop when a subserous leiomyoma grows into the ligamentum latum.

Submucous tumors grow immediately beneath the endometrium, bulging towards the intrauterine cavity (Merrill and Creasman 1986) and constituting approximately 5-10 % of all leiomyomas (Novak and Woodruff 1979, Buttram and Snabes 1992, Ubaldi et al. 1995). These leiomyomas may also become pedunculated and eventually emerge in the uterine cervix or vagina (Merrill and Creasman 1986). Large leiomyomas may present as a mixture of different location varieties, as the outer margin of a massive leiomyoma may protrude subserously, the middle part situated intramurally and the inner part reaching the submucous space.

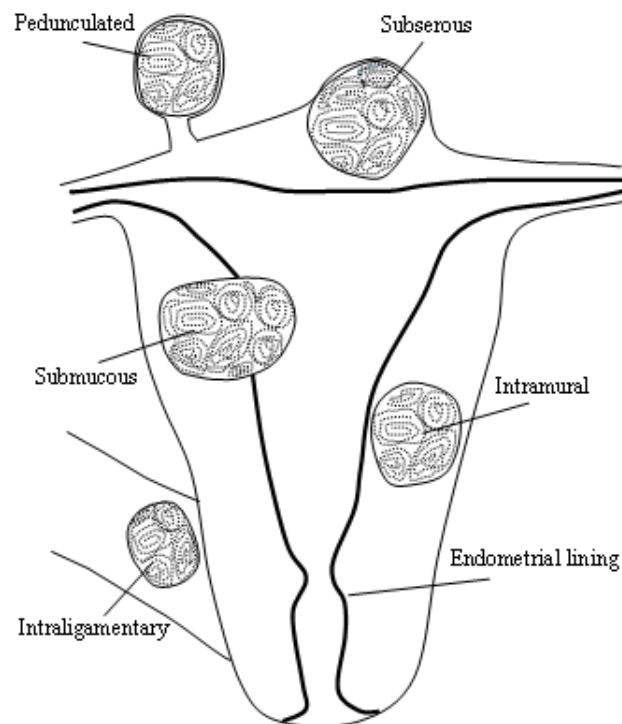


Figure 1. Location of uterine leiomyomas

### 6.1.3 Etiology of uterine leiomyomas

Although the exact pathophysiology of leiomyomas remains unknown, a significant amount of research data is available concerning the genetics, molecular biology, hormonal aspects and epidemiology of these tumors. Intrinsic myometrial abnormalities, congenitally elevated ERs in the myometrium, hormonal changes, or a response to menstrual ischemic injury are all factors possibly responsible for the initiation of acquired genetic changes found in these neoplasms (Richards and Tiltman 1996, Stewart and Nowak 1996, Rein 2000). Hormones (promoters) and growth factors (effectors) further have an influence on these developed changes (Rein and Nowak 1992, Mangrulkar et al. 1995, Rein et al. 1995).

#### 6.1.3.1 Genetics

Multiple studies of clonality have concluded that leiomyoma cells arise from single cells (Linder and Gartler 1965, Townsend et al. 1970) and that uterine leiomyomas are monoclonal in origin (Mashal et al. 1994, Hashimoto et al. 1995). Nonrandom chromosomal abnormalities have been reported in approximately 40-50 % of uterine leiomyomas (Nilbert and Heim 1990, Ligon and Morton 2000), the two most common being a translocation between chromosomes 12 and 14, specifically t(12;14) (q14-q15;q23-q24), presenting in about 20 % of karyotypically abnormal leiomyomas, and a deletion of chromosome 7, del(7)(q22q32), presenting in about 17 %, respectively (Ligon and Morton 2000). Aberrations of 6p21 have been established, their occurrence being less than five per cent in leiomyomas. Several other cytogenetic abnormalities have also been identified in these tumors (Nilbert and Heim 1990, Vanni et al. 1992).

A hereditary predisposition to leiomyomas is suggested by twin and family studies. More hospitalizations for treatment of leiomyomas are reported in monozygous than dizygous twins, though, a reporting bias may have resulted in these findings (Treolar et al. 1992). It has been shown that first-degree relatives of women with leiomyomas have a 2.5 times increased risk of developing these tumors (Vikhlyaeva et al. 1995, Schwartz et al. 2000), and women reporting leiomyomas in two first-degree relatives are more than twice as likely to have strong expression of a myoma-related growth factor (vascular endothelial growth factor alpha, VEGF- $\alpha$ ) than women with leiomyomas but without a family history (Okolo et al. 2005).

Leiomyomas are found in two syndromes in kindred with other specific abnormalities: Reed's syndrome, or multiple leiomyomatosis, which is characterized by the appearance of multiple leiomyomas in the skin, uterus or both, and Bannayan-Zonana syndrome with other benign tumors including lipomas and hemangiomas (Reed et al. 1973, Marsh et al. 1997). Recent studies concerning several families in England and Finland with multiple uterine and cutaneous leiomyomas, and a subset of these with papillary renal carcinoma, have linked this disorder to a predisposing gene in the region of chromosome 1q42.3-q43 (Alam et al. 2001, Kiuru et al. 2001, Launonen et al. 2001).

### 6.1.3.2 Hormones

#### 6.1.3.2.1 Estrogen

Since uterine leiomyomas rarely occur before puberty, evolve during the fertile years and soon lessen in size postmenopausally, estrogen has been suggested as an important promoter of myoma growth. The risk of leiomyomas is increased in obese women with greater aromatization of androgens to estrone in the fat, and in nulliparous women who might have more anovulatory cycles (Ross et al. 1986, Romieu et al. 1991, Cramer 1992, Parazzini et al. 1996a). The use of transdermal (Polatti et al. 2000) or injected (Frigo et al. 1995) estrogen replacement therapy or tamoxifen (Dilts et al. 1991, Le Bouedec et al. 1995, Kang et al. 1996) also increases the growth of these tumors. Exercise and increased parity protect against leiomyomas, as they are associated with decreased exposure to estrogen (Cook and Walker 2004). Furthermore, leiomyomas regress dramatically in size during therapy with gonadotropin-releasing hormone (GnRH) agonists, resulting in a hypoestrogenic state (Friedman et al. 1989). Higher estradiol (E<sub>2</sub>) concentrations (Otubu et al. 1982, Folkerd et al. 1984) and more frequent expression or overexpression of aromatase activity in leiomyomas than in matched myometrial samples (Folkerd et al. 1984, Yamamoto et al. 1984, Sumitani et al. 2000,) have been demonstrated. The concentrations of both ER and progesterone receptors (PR) are higher in leiomyomas than in the myometrium (Sadan et al. 1987, Nisolle et al. 1999) and when compared with matched myometrium, they are elevated in leiomyomas during all phases of the menstrual cycle (Sadan et al. 1987).

#### 6.1.3.2.2 Progesterone

The natural cyclical course of progesterone during the female's life resembles that of estrogen (Rein et al. 1995), as it is also present during reproductive life and is suppressed after menopause. Biochemical and histological studies indicate that progesterone may have an important role in the growth of leiomyomas. Compared with the normal myometrium, elevated concentrations of PRs A and B have been detected (Englund et al. 1998, Nisolle et al. 1999). Furthermore, simultaneous administration of medroxyprogesterone acetate (MPA) has been shown to inhibit the myoma and uterine volume shrinkage effect of a GnRH agonist (Friedman et al. 1988, Carr et al. 1993). Wise and associates (2004) established an inverse association between the use of injectable contraceptives containing progestin and the risk of leiomyomas. In addition, RU 486, a synthetic steroid with antiprogestin and antiglucocorticoid properties, has been shown to induce a lessening of size of these tumors (Murphy et al. 1993). This regression was suggested to be attained through a direct antiprogestin effect, as a concomitant reduction in PR but not ER in the myomas was found.

### 6.1.3.3 Growth factors

Multiple growth factors, proteins or polypeptides locally produced by smooth muscle cells and fibroblasts, together with their receptors, have been found in both uterine leiomyomas and the myometrium. They act as controllers of cell proliferation and seem to stimulate myoma growth, primarily by increasing the extracellular matrix. It has been established that upon administration of estrogen or progesterone, the production of certain growth factors increases or decreases in tissue culture cell lines or laboratory animals *in vivo*, suggesting that growth factors are regulated by these hormones (Presta 1988, Cullinan-Bove and Koos 1993, Fujimoto et al. 1997, Reynolds et al. 1998). The growth factors most extensively studied in the context of leiomyomas are transforming growth factor- $\beta$  (TGF)- $\beta$ , basic fibroblast growth factor (bFGF), epidermal growth factor (EGF), platelet-derived growth factor (PDGF), vascular endothelial growth factor (VEGF), insulin-like growth factor (IGF) and prolactin.

TGF- $\beta$  and TGF- $\beta$  receptors I-III have been detected in human myometrial tissue (Chegini et al. 1994, Tang et al. 1997) and in leiomyomas (Arici and Sozen 2000, Nowak 2000). TGF- $\beta$ s promote mitogenesis and upregulate the synthesis of many components of the extracellular matrix, leading to fibrosis (Lyons and Moses 1990). An increased expression for bFGF and bFGF mRNA (messenger ribonucleic acid) in leiomyomas has been found compared to the myometrium (Mangrulkar et al. 1995). bFGF causes proliferation of leiomyoma and myometrial cells (Stewart and Nowak 1996), and promotes angiogenesis. mRNA for PDGF (Boehm et al. 1990) and EGF receptor (Yeh et al. 1991) have been found in leiomyomas and myometrium, both acting as mitogens for smooth muscle cells (Fayed et al. 1989, Nowak 1999). VEGF stimulates angiogenesis, increases capillary permeability and acts synergistically with bFGF (Hyder et al. 2000). Both smooth muscle cells of the myometrium and leiomyomas express VEGF mRNA and VEGF protein (Harrison-Woolrych et al. 1995, Dixon et al. 2000). IGF-I is responsible for myogenesis, IGF-II for terminal differentiation of skeletal muscle cells and the down-regulation of IGF-I receptor gene expression (Rosenthal et al. 1994, Strawn et al. 1995). MRNAs for IGF-I and IGF-II and their receptors have been established in both the myometrium and leiomyomas. IGF-I acted as a mitogenic in leiomyoma cell cultures (Strawn et al. 1995). Prolactin hormone production has been demonstrated in the endometrium, myometrium, and uterine leiomyomas (Maslar and Riddick 1979, Walters et al. 1983, Daly et al. 1984) and prolactin is mitogenic for vascular smooth muscle (Sauro and Zorn 1991).

### 6.1.4 Risk factors for uterine leiomyomas

Several factors have been connected to the risk of uterine leiomyomas (Table 1)

Table 1. Factors associated with the risk of uterine leiomyomas.

Factors	Risk increased	Risk decreased	Controversial results
Increasing age	x		
Increasing parity		x	
Smoking		x	
Relatives with uterine leiomyomas	x		
African-American ethnicity	x		
Obesity	x		
Athletics		x	
Frequent consumption of beef, other meat, ham	x		
Limited consumption of green vegetables, fruit and fish	x		
Early onset of menarche	x		
Late onset of menarche		x	
Postmenopausal status		x	
Oral contraceptives			x
Hormone therapy			x

#### *6.1.4.1 Age and parity*

A number of epidemiologic studies have found an increase with age in the prevalence of leiomyomas during the fertile years (Ross et al. 1986, Wilcox et al. 1994, Velebil et al. 1995, Marshall et al. 1997). It is not known whether the risk of new leiomyomas truly increases in patients of this age or whether it results from increased growth or symptoms of already existing leiomyomas.

The more parous the woman is the more the incidence and number of leiomyomas decreases (Lumbiganon et al. 1996, Parazzini et al. 1996a, Baird and Dunson 2003). Parazzini and associates (1988) found that parous women have a half of the relative risk of uterine leiomyomas compared to that in nulliparous women. Childbearing at the age of 25 to 29 years was shown to offer the greatest protection against leiomyoma formation in a study by Baird and Dunson (2003). If a woman becomes pregnant before the age of 25 myomas may not yet have developed. On the other hand, leiomyomas may be too large to decrease in size if the pregnancy occurs beyond the age of 30 (Baird and Dunson 2003).

#### *6.1.4.2 Family history and ethnicity*

A 2.5 fold increased risk of leiomyoma formation has been shown in first-degree relatives of women with these tumors (Vikhlyaeva et al. 1995, Schwartz et al. 2000). The incidence rates of leiomyomas among Hispanic and Asian women are similar to those of white women (Marshall et al. 1997). However, African-American women have a 2.9 times higher risk of leiomyomas compared to Caucasians, and these tumors also present at a younger age, and are more numerous, more symptomatic and larger (Kjerulff et al. 1996, Marshall et al. 1997). It is not known whether these differences are genetic or due to environmental factors, diet or circulating levels or metabolism of estrogen.

#### *6.1.4.3 Life style factors*

Whereas several reports imply an association between obesity and an increased incidence of uterine leiomyomas, studies examining the association between diet and these tumors are sparse. In a study of 843 women with uterine myomas compared to 1557 women without, Chiaffarino and associates (1999) found that women in the former group reported more frequent consumption of beef, other red meat and ham and less frequent usage of green vegetables, fruit and fish. The risk of leiomyomas rises with increasing body mass index (BMI) (Ross et al. 1986, Lumbiganon et al. 1996, Marshall et al. 1998b), being approximately 21 % for each 10-kg increase in body weight (Ross et al. 1986) and for each unit increase in BMI, the leiomyoma risk becomes 6 % higher (Lumbiganon et al. 1996). Shikora and associates (1991) reported comparable findings in women with greater than 30 %

body fat. In contrast, data from three studies showed little or no increased risk associated with elevated BMI (Parazzini et al. 1988, Romieu et al. 1991, Samadi et al. 1996). Wyshak and colleagues (1986) established that compared with nonathletes, former college athletes have a 40 % lower prevalence of leiomyomas. Lean body mass may lower conversion rates of androgens to estrogens, possibly reducing the risk of leiomyomas, whereas obesity may have the opposite effect.

An inverse relationship between risk of uterine leiomyomas and cigarette smoking has been established by most epidemiologic studies (Ross et al. 1986, Romieu et al. 1991, Lumbiganon et al. 1996, Parazzini et al. 1996b). Current smoking, but not past smoking, has been found to lower this risk (Ross et al. 1986, Wyshak et al. 1986, Parazzini et al. 1988, Lumbiganon et al. 1996, Parazzini et al. 1996b, Samadi et al. 1996). In contrast, Marshall and colleagues (1998b) found no sign of reduced risk in smokers. Bioavailability at estrogen target tissues is reduced by the increased 2-hydroxylation of E<sub>2</sub> occurring in smokers (Michnovicz et al. 1986). Nicotine inhibition of aromatase has been also found to lower the conversion of androgens to estrone (Barbieri et al. 1986).

#### *6.1.4.4 Endo- and exogenous hormonal factors*

An inverse association between age at menarche and risk of leiomyomas has been presented, as early onset of menstruation ( $\leq 10$  years old) has been found to increase and late onset ( $\geq 16$  years) to lower the risk of these tumors (Marshall et al. 1998a). Several studies show that postmenopausal women are at a 70-90 % reduced risk of uterine leiomyomas (Ross et al. 1986, Parazzini et al. 1988, Romieu et al. 1991, Samadi et al. 1996). In a study by Cramer and Patel (1990), a gross serial sectioning at 2-mm intervals applied in hysterectomy specimens showed a comparable incidence of leiomyomas in pre- and postmenopausal patients (74 and 84 %, respectively), but the tumors were smaller and less numerous in the latter group.

Despite extensive studies concerning the relationship between the use of oral contraceptives and uterine leiomyomas, no clear patterns have been detected. Compared to never-users, the risk of uterine leiomyomas in women who have used oral contraceptives has been observed to be increased (Ramcharan et al. 1980), similar (Romieu et al. 1991, Parazzini et al. 1992, Samadi et al. 1996), and reduced (Ross et al. 1986, Lumbiganon et al. 1996).

Similarly, the effect of hormone therapy on leiomyomas remains controversial. In a study by Palomba and associates (2002b), seventy-seven per cent of postmenopausal women taking 2 mg oral micronized E<sub>2</sub> and 2.5 mg MPA daily had either no change or a decrease in myoma diameter, and 23 % had a slight increase one year after treatment. A mean diameter increase of 3.2 cm was however found in fifty percent of women taking 2 mg oral E<sub>2</sub> and 5 mg of MPA daily. After one year of use of transdermal estrogen and oral progesterone, postmenopausal women with known leiomyomas were detected to have an average 0.5 cm increase in the diameter of these tumors. When taking both estrogen and progesterone orally, no increase in myoma size was found (Reed et al. 2004). Treatment of postmenopausal women with leiomyomas with a daily combination of 0.05 mg transdermal E<sub>2</sub> and

2.5 mg MPA for 12 months resulted in no change or reduction in uterine size in 74 % of patients and in a slight increase in 26 % (Palomba et al. 2001). Comparable findings were noted in plain transdermal E<sub>2</sub> users. Cook and Walker (2004) demonstrated that postmenopausal women who for one year used raloxifene, a selective estrogen-receptor modulator, had a reduction in leiomyoma size, but this effect was not detected in premenopausal women.

#### 6.1.4.5 Uterine sarcoma

Leiomyosarcoma is a rare malignant tumor constituting 2-7 % of uterine cancers (Hendrickson and Kempson 1995, Zaloudek and Hendrickson 2002). The frequency of this malignancy is 0.64/100 000 women per year, with a prevalence of 0.23-1 % in patients operated for presumed leiomyoma (Harlow et al. 1986, Leibsohn et al. 1990, Parker et al. 1994). Cytogenetic studies suggest that leiomyosarcomas arise *de novo* via distinct pathogenetic pathways, although benign myomas and sarcomas may coexist in the same patient, (Levy et al. 2000, Stewart 2001). In contrast to leiomyosarcomas, leiomyomas remain differentiated and evince chromosomal rearrangements similar to other benign lesions (Walker and Stewart 2005).

Parker and colleagues (1994) analyzed the medical records of 371 women operated for rapid growth of leiomyomas, and one leiomyosarcoma was found in this group (0.27 %). None of the 198 patients who met a published definition of rapid growth had a uterine sarcoma. On this basis, a rapid increase in uterine size in premenopausal women very rarely indicates the presence of this malignancy.

#### 6.1.4.6 Natural history of uterine leiomyomas

Studies following a large cohort of women with leiomyomas to investigate the natural history of their growth and symptoms are scarce. Lethaby (2003) followed 106 women over 12 months and no significant change in symptoms or quality of life was detected in these patients. Another study prospectively followed 64 asymptomatic premenopausal women using saline-infusion sonograms over an average of 2.5 years (Dewaay et al. 2002). Sixteen percent of the women had at least one myoma at the initial ultrasound. After the follow-up period, 4 of these 11 women had at least one myoma which was no longer detectable. In contrast, the leiomyomas persisting during 2.5 years tended to increase in size, and the average growth was 1.2 cm. Growth patterns varied among patients, however, from a decrease of 0.9 cm in size to an increase of 6.8 cm. The cumulative incidence rate of new myomas was 13 % during 2.5 years.

Possibly since each uterine leiomyoma is monoclonal, individual tumors will show characteristic growth patterns (Wallach and Vlahos 2004). Although the size of a myoma may remain unchanged for many years, the general pattern is slow growth over the long-term during the premenopausal years, followed by fairly rapid growth during the fifth decade of a woman's life, immediately prior to menopause (Marshall et al. 1997, Dewaay et al. 2002, Wallach and Vlahos 2004).



### 6.1.5 Vitamin D and cell proliferation

Vitamin D is a potent anti-proliferative and immunomodulatory secosteroid hormone with a well-established role in the maintenance of calcium homeostasis. Synthesis of the active form of vitamin D, 1,25(OH)<sub>2</sub>D<sub>3</sub> (1 $\alpha$ ,25-dihydroxycholecalciferol, i.e. calcitriol) takes place through sunlight-induced conversion of 7-dehydrocholesterol to vitamin D<sub>3</sub> and its successive hydroxylations to 25(OH)D<sub>3</sub> (25-hydroxycholecalciferol) and 1,25(OH)<sub>2</sub>D<sub>3</sub> in the liver and the kidney. Vitamin D<sub>3</sub> may also be consumed in the diet (Holick 2004). The signalling of 1,25(OH)<sub>2</sub>D<sub>3</sub> is mediated via its ubiquitously expressed nuclear receptor, the vitamin D receptor (VDR), which is present in both the myometrium and endometrium of the human uterus throughout the menstrual cycle (McDonnell et al. 1987, Baker et al., 1988, Vienonen et al. 2004). A role has been suggested for 1,25(OH)<sub>2</sub>D<sub>3</sub> in normal uterine organogenesis and fetal-placental development (Yoshizawa et al. 1997, Evans et al. 2006).

1,25(OH)<sub>2</sub>D<sub>3</sub> maintains mineral homeostasis by stimulating renal calcium reabsorption, intestinal absorption of phosphate and calcium, and mobilization of calcium from bone (DeLuca 1988, Haussler et al. 1998, Jones et al. 1998). 1,25(OH)<sub>2</sub>D<sub>3</sub> is greatly dependent on the synthesis and function of parathyroid hormone (PTH), which acts as the main renal activator of 1 $\alpha$ -hydroxylase (DeLuca 1988, Haussler et al. 1998, Jones et al. 1998). In turn, 1,25(OH)<sub>2</sub>D<sub>3</sub> provides a negative feedback for calcium homeostasis by down-regulating transcription of both PTH and 1 $\alpha$ -hydroxylase. Besides its predominant expression in the kidney, 1 $\alpha$ -hydroxylase activity has been shown in a wide range of other tissues, including the uterus, indicating the possibility of local production of 1,25(OH)<sub>2</sub>D<sub>3</sub> (Hewison et al. 2001, Hewison et al. 2004).

1,25(OH)<sub>2</sub>D<sub>3</sub> has also nonendocrine actions which do not appear to be either PTH-dependent or subject to classic autoregulation (Hewison et al. 2000, Hewison et al. 2004). It modulates cell proliferation, differentiation, cancer invasion and angiogenesis (Schwartz et al. 1997, Lokeshwar et al. 1999, Mantell et al. 2000, Ylikomi et al. 2002, Bouillon et al. 2008). Vitamin D deficiency may stimulate cell proliferation (Ylikomi et al. 2002). The vitamin D [1,25(OH)<sub>2</sub>D<sub>3</sub>]-induced antiproliferative action is mediated predominantly through a G<sub>1</sub>/S phase block of the cell cycle. 1,25(OH)<sub>2</sub>D<sub>3</sub> regulates many of the cell cycle regulatory genes and reduces or increases the kinase activities of cyclin-dependent kinases. This results in a decreased number of cells in the S phase and an accumulation of cells in the G<sub>0</sub>-G<sub>1</sub> phase (Wang et al. 1996, Simboli-Campbell et al. 1997, Zhuang and Burnstein 1998). The cyclin-dependent kinase inhibitors p21 and/or p27 are genomic targets of the 1,25(OH)<sub>2</sub>D<sub>3</sub>-VDR complex in many cell types (Hager et al. 2001, Audo et al. 2003). 1,25(OH)<sub>2</sub>D<sub>3</sub> also blocks mitogenic signalling, including that of estrogen, EGF and IGF-I, and up-regulates growth inhibitors such as TGF- $\beta$  (Colston and Hansen 2002). 1,25(OH)<sub>2</sub>D<sub>3</sub> activates VDR-mediated apoptosis (Welsh et al. 1995).

Both epidemiologic and *in vitro* studies suggest that vitamin D may be an important factor in the development and progression of malignancy (Garland et al. 1989, Ross et al. 1994, Tangrea et al. 1997, Ahonen et al. 2000a). The incidence of prostate (Hanchette and Schwartz 1992), breast (Garland et al. 1990) and colon

cancer (Apperly 1941) increases when moving away from the equator towards circumpolar regions. Recently, indirect evidence on the vitamin D and sun dependence of a number of other malignancies has been introduced: ovarian cancer, non-Hodgkin lymphoma, bladder, esophagus, rectum, kidney, lung, pancreas, gastric and endometrium carcinoma (Grant 2002). Connection between hypovitaminosis D and multiple cancers has also been suggested (Garland et al. 1989, Hanchette and Schwartz 1992, Grant, 2002).  $1,25(\text{OH})_2\text{D}_3$  has been shown to inhibit the growth of human breast (Frampton et al. 1983), prostate (Blutt and Weigel 1999) and ovarian (Saunders et al. 1992, Saunders et al. 1993, Ahonen et al. 2000b) cancer cells *in vitro*. In breast cancer VDR- positive patients have had longer disease-free survival than VDR-negative patients (Colston et al. 1989). Expression of VDR at protein level was detected more often in cervical carcinomas than in normal cervical tissues (Reichrath et al. 1998, Friedrich et al. 2002). VDR expression has been established in endometrial adenocarcinomas and ovarian tumors (Saunders et al. 1992, Yabushita et al. 1996) Potent anti-proliferative and immunosuppressive responses to  $1,25(\text{OH})_2\text{D}_3$  have led to the use of vitamin D analogs as therapy for diseases such as psoriasis and leukemia (Bouillon et al. 1995, Jones et al. 1998, Hewison et al. 2001).

Despite extensive research on the role of vitamin D in the inhibition of cell growth in a large variety of tissues, there are no reports concerning the possible growth-modulatory effects of vitamin D on benign uterine tumor cells.

## 6.2 Symptomatology of uterine leiomyomas

Even large leiomyomas are often asymptomatic (Conley and Lacey 1987). Regardless of this fact, it is estimated that 60 % of laparotomies are performed because of leiomyomas (Merrill and Creasman 1986). Possible symptoms depend on the location, size and number of uterine leiomyomas and whether the patient is pregnant (Buttram and Reiter 1981, Conley and Lacey 1987). Twenty to fifty per cent of patients with leiomyomas report symptoms (Buttram and Reiter 1981, Conley and Lacey 1987).

### 6.2.1 Abnormal bleeding

Uterine leiomyomas do not necessarily result in menorrhagia, as approximately one third of women with these tumors report abnormal bleeding (Buttram and Reiter 1981). The most typical pattern for leiomyomas is menorrhagia or hypermenorrhea, prolonged or excessively heavy menstruation (Stewart 2001). If bleeding occurs at the other times during menstrual cycle, endometrial disease should be ruled out, as this symptom is not characteristic of uterine leiomyomas. Heavy menstruation may result in medical problems, particularly iron-deficiency anemia. (Stewart 2001).

The location of the leiomyoma seems to be more essential factor than size in evaluating bleeding symptoms, and submucous myomas are most likely to result in menorrhagia (Stewart 2001). However, in a study by Wegienka and associates (2003), heavy menstruation and length of periods were associated with size of myomas, but not presence of submucous or numerous myomas. The authors found that of 878 randomly sampled women aged 35-49 years, 64 % had leiomyomas. Compared with 28 % of the women without leiomyomas, 46 % of those with myomas reported heavy menstruation. Marino and colleagues (2004) detected leiomyomas in 21.4 % of healthy women examined by sonography. There was no correlation between the presence of myomas and heaviness of menstruation or length of cycle. The location (insufficient numbers to analyze submucosal), position, number or volume of myomas were not associated with menstrual cycle features.

Theories for menorrhagia in women with uterine leiomyomas include compression of veins by myomas resulting in venous ectasia, or altered function, expression or storage of vasoactive growth factors produced by myomas (Farrer-Brown et al. 1970, Farrer-Brown et al. 1971, Stewart and Nowak 1998).

## 6.2.2 Pain and pressure effects

Approximately 30 % of women with uterine leiomyomas experience abdominal pain. This usually results from acute degeneration and necrosis, torsion of a pedunculated subserosal tumor or prolapse of pedunculated submucous tumors. Chronic pelvic pain is atypical for leiomyomas and if this is a presenting symptom other predisposing factors should be considered. (Hutchins 1995a). Lippman and associates (2003) found leiomyomas in 15 % of 635 healthy women evaluated by transvaginal ultrasound. The women with myomas were only slightly more likely to report noncyclic pelvic pain or moderate or severe dyspareunia and had no higher incidence of moderate or severe dysmenorrhea than women without myomas. There were no correlation between the number or total volume of myomas and pain.

As tumors grow, an increase in abdominal girth and a variety of abdominal and pelvic pressure symptoms tend to occur (Hutchins 1995a). As the myomatous uterus is irregular, specific symptoms can be caused by myomas in particular locations. Anterior myomas may result in urinary symptoms and posterior to constipation (Stewart 2001). Pressure on the urinary bladder may result in frequency and stress incontinence (Carlson et al. 1993). Enlarging myomas rarely cause ureteral obstruction or urinary retention (Buttram and Reiter 1981). Pron and colleagues (2003) showed that frequency and urgency was greatly improved in 53 %, moderately improved in 15 %, slightly improved in 18 %, and unchanged or worse in 14 % of 306 women following a 35 % mean volume reduction in a myomatous uterus after uterine artery embolization, indicating that myomas are truly associated with urinary symptomatology.

## 6.3 Diagnostics of uterine leiomyomas

Manual palpation and estimation of the size of the uterus is an important part of the routine gynecological examination, as it is necessary to exclude abnormal growth of this reproductive organ due to benign or malignant tumors. The size of the uterus is also a crucial factor in assessing the method of hysterectomy most appropriate for the patient (Kovac 1995). The dominant practice is to estimate the size of the nongravid uterus by bimanual examination and compare it with a pregnant uterus of comparable size. Indirect estimation of size may be performed by sounding the uterine cavity.

Uterine leiomyomas are the most common reason for enlargement of the uterus. Pelvic examination usually reveals clinically significant subserosal and intramural myomas, diagnosis being based on an enlarged, irregular, firm and nontender uterus (Cantuaria et al. 1998, ACOG 2001). However, the obesity and muscle tension of the patient may hamper this evaluation. Even in favorable conditions the impression of the size of the uterus may remain subjective (Flickinger et al. 1986). Moreover, saline-infusion sonography, hysteroscopy or MRI is often required for the diagnosis of submucous myomas (Cantuaria et al. 1998).

### 6.3.1 Imaging

It is important to evaluate accurately the size, number and position of myomas so as to optimally select the patients for medical therapy, noninvasive or invasive procedures. Sonography with or without saline infusion, hysteroscopy and MRI can be utilized for this purpose.

#### *6.3.1.1 Sonography, saline-infusion sonography and hysteroscopy*

Gynecological ultrasound has proved to be the most accurate means of estimating the uterine dimensions (Flickinger et al. 1986) and a number of clinicians have introduced ultrasonographic evaluation for this purpose. Transvaginal sonography is the most readily available and cheapest technique and may be useful in distinguishing leiomyomas from other diseases. In the case of large myomas a combination of transabdominal and transvaginal sonography may prove appropriate for adequate imaging. Leiomyomas usually appear as symmetrical, well-defined, hypoechoic, and heterogeneous masses. Ultrasound may be inadequate for determining the precise number and position of myomas, although transvaginal sonography is considered fairly reliable for uteri containing four myomas or fewer or less than 375 mL in total volume (Dueholm et al. 2002).

Previous studies on the estimation of the volume and weight of the uterus have mainly been carried out using an abdominal ultrasound probe (Piiroinen 1975, Flickinger et al. 1986, Goldstein et al. 1988, Platt et al. 1990, Saxton et al. 1990, Wiener and Newcombe 1992, Kovac 1995, Kung and Chang 1996, Dekel et al.

1998). Only two researchers have estimated uterine weights with a transvaginal ultrasound probe and compared the estimates to the true weights of excised specimens (Becker et al. 1994, Dekel et al. 1998).

The most common mode of estimating the size of the uterus is to use the geometric formula of the prolate ellipsoid:  $\text{volume} = 0.5236 \times L \times W \times AP$ , where L stands for length (cm), W for width (cm), and AP for anteroposterior diameter (cm) of the uterine corpus (Grossman et al. 1982, Flickinger et al. 1986, Goldstein et al. 1988, Platt et al. 1990, Wiener and Newcombe 1992, Bakos et al. 1994, Kung and Chang 1996, Dekel et al. 1998). Some investigators have measured only the length of the uterine corpus for the formula, leaving the mass of the uterine cervix outside the estimation of total uterine volume (Grossman et al. 1982, Goldstein et al. 1988, Bakos et al. 1994, Dekel et al. 1998). Others have measured the length of the uterus from its fundus to the external os of the cervix, the cervix being considered to lie in the ellipsoid (Flickinger et al. 1986, Platt et al. 1990, Wiener and Newcombe 1992, Kovac 1995, Kung and Chang 1996). In this latter approach there is empty space in the ellipsoid around the cervix, and this makes for overestimation of total uterine size. In the former system, the volume of the cervix is left outside the measurement, which in turn may cause underestimation of total uterine weight. Both methods may thus cause errors in estimation of uterine size. Previous studies have mainly concerned non-pathological uteruses (Piironen 1975, Flickinger et al. 1986, Platt et al. 1990, Wiener and Newcombe 1992, Bakos et al. 1994).

The average size of the nonpathological, nonpregnant uterus varies from 70 g in a nulliparous woman to 75-125 g in a multiparous woman (Kovac and Ameo 1999). The volume of the uterus changes during the menstrual cycle (Bakos et al. 1994). Becker and associates (1994) used transvaginal ultrasound to obtain normal ranges for uterine dimensions to estimate the weight of the apparently normal uterus. Using linear regression analysis, they derived a formula for assessing uterine weight:  $\text{uterine length} \times \text{depth} \times \text{width} \times 0.00038 + 24$ . Kung and Chang (1996) used abdominal ultrasound to measure uterine dimensions and calculated uterine volume using the formula for the prolate ellipsoid. By linear regression analysis, they established a formula for uterine volume and true uterine weight:  $50 + 0.71 \times \text{volume (cm}^3\text{)}$ .

Platt and colleagues (1990) determined uterine weight and volume as assessed by water displacement of 156 hysterectomy specimens. From the data gathered, an estimate of density (weight in grams/volume in mL) was obtained for each specimen. The mean density was found to be 1.03. When this mean was compared to 1 with a t-test, no statistically significant difference was found. The researchers concluded that the uterine weight can be determined from an estimation of uterine volume with 1 mL approximately equal to 1 g of uterine tissue.

Ultrasound scanning has not been utilized to establish the separate volume of the cervix, while MRI has been employed in patients with cervical malignancy. Most commonly, the formula for the ellipsoid has also been used for estimating the volume of a tumor and the cervix (Toita et al. 1999). As the real shape of the cervix is in fact more like a cylinder than an ellipse/ellipsoid, Dumanli and associates (2000) compared the geometric formulas of these two in MRI and found the formula for a cylinder to be significantly more accurate.

Three-dimensional ultrasound (3D) has been introduced in clinical application for the estimation of organ volume (Brunner et al. 1995, Riccabona et al. 1995). Compared to the two-dimensional (2D) method, 3D ultrasound offers improved accuracy and provides precise volume measurements of objects of different shapes (Riccabona et al. 1995, Kyei-Mensah et al. 1996). Chou and associates (1997) compared the accuracy of these two modalities with a vaginal ultrasonography probe in estimating the volume of a cervical carcinoma. True cervical carcinoma volume was measured more accurately by the 3D than 2D ultrasound system. No studies have been published to date comparing 3D and 2D vaginal ultrasonography in estimating total uterine volume.

Saline-infusion sonography is a method in which saline is inserted via a catheter into the uterine cavity to gain contrast and better identify submucous myomas and other intrauterine conditions. In unclear cases, hysteroscopy may be performed for the diagnosis of submucous leiomyomas. However, local anesthetic or sedation has to be used for this approach. An advantage for hysteroscopy is that a submucous leiomyoma may be treated by resection during the same procedure.

### 6.3.1.2 *Magnetic resonance imaging*

MRI is considered to be the most accurate imaging technique for the detection and localization of leiomyomas (Hricak et al. 1986, Mayer and Shipilov 1995), and in determination of the nature of these tumors, it has been shown to be more sensitive than ultrasound (Dudiak et al. 1988). In a study by Dueholm and associates (2002), transvaginal sonography, saline-infusion sonography, hysteroscopy and MRI were all performed in each of 106 women prior to hysterectomy, and the findings compared with the pathologic results. Submucous myomas were best identified with MRI (100 % sensitivity, 91 % specificity). Identification was approximately the same with transvaginal sonography (sensitivity 83 %, specificity 90 %), saline-infusion sonography (sensitivity 90 %, specificity 89 %), and hysteroscopy (sensitivity 82 %, specificity 87 %). Goto and colleagues (2002) found 100 % specificity, 100 % positive predictive value, 100 % negative predictive value, and 100 % diagnostic accuracy for leiomyosarcoma when diagnosing with total serum lactic acid dehydrogenase (LDH), LDH isoenzyme 3, and gadolinium-enhanced MRI (Gd-DTPA).

## 6.4 Uterine leiomyomas and reproduction

### 6.4.1 Fertility

Leiomyomas are the only etiologic factor in 1% to 2.4% of infertile women and about 5% to 10% of women suffering from sterility have at least such tumor (Donnez and Jadoul 2002). Leiomyomas may interfere with sperm transport or

embryo implantation by inducing increased uterine contractility, chronic endometrial inflammation and abnormal local endocrine patterns and vascularization (Hunt and Wallach 1974, Buttram and Reiter 1981, Donnez and Jadoul 2002). Randomized, sufficiently powered studies determining the effect of myomas on fertility are still lacking. It has been established by retrospective and case control studies that submucosal and intramural myomas which protrude into the endometrial cavity are associated with lowered pregnancy and implantation rates in patients trying to conceive spontaneously or undergoing *in vitro* fertilization (Narayan et al. 1994, Farhi et al. 1995, Varasteh et al. 1999, Bernard et al. 2000) and the pregnancy rate improves after their removal (Garcia and Tureck 1984, Goldenberg et al. 1995, Fernandez et al. 2001). It is a commonly accepted fact that submucous myomas reduce fertility, and after their extirpation, pregnancy rates improve. It is not clear whether myomas without distortion of the endometrial cavity have an effect on spontaneous conception and assisted reproductive technology outcomes. Many studies suggest an adverse effect on clinical pregnancy and implantation rates in women undergoing *in vitro* fertilization, particularly with large myomas (e.g., >4 cm) (Elder-Geva et al. 1998, Stovall et al. 1998, Buletti et al. 1999, Hart et al. 2001, Oliveira et al. 2004, Gianaroli et al. 2005, Feinberg et al. 2006), whereas others have found no such an association (Dietterich et al. 2000, Jun et al. 2001, Surrey et al. 2001, Yarali and Bukulmez 2002, Wang and Check 2004, Klatsky et al. 2007). Klatsky and colleagues (2007) conducted a sufficiently powered study and established a difference in pregnancy rates. The assumption that subserous leiomyomas do not affect fertility or spontaneous abortion was reinforced in a systematic literature review by Pritts and associates (2008). There was no clear evidence that myomectomy for intramural leiomyomas is beneficial for fertility.

#### 6.4.2 Pregnancy

A low incidence of leiomyomas (1.5 %) has been observed during pregnancy (Cooper and Okolo 2005). Rosati and associates (1992) found that most of these tumors do not grow during pregnancy, as 69 % of the pregnant women with a single leiomyoma in their study had no increase in leiomyoma volume. The greatest growth was observed before the 10th gestational week in the 31 % of women found to have an increase in myoma volume. One month postpartum, a reduction in myoma size was detected. Signs of myoma degeneration have been detected in approximately 5 % of pregnant women (Lev-Toaff et al. 1987, Vergani et al. 1994).

Vergani and associates (1994) found no significant differences in the incidence of preterm delivery, premature rupture of membranes, fetal growth restriction, placenta previa, placental abruption, postpartum hemorrhage or retained placenta in a study of 12 600 pregnant women when the outcomes of 167 women with myomas were compared with women without these tumors. Only cesarean section was more common among myoma patients (23 % vs 12 %,  $P < 0.001$ ). However, in a study by Qidwai and colleagues (2006) the risk of preterm delivery (19.2 % vs 12.7 %), placenta previa (3.5 % vs 1.8 %), postpartum hemorrhage (8.3 % vs 2.9 %) and cesarean section (49.1 % vs 21.4 %) was elevated. The mechanical compression

due to leiomyomas very rarely causes injuries to the fetus, as only four such cases during 25 years have been reported (Romero et al. 1981, Graham 1985, Chuang et al. 2001, Joo et al. 2001).

## 6.5 Treatment of uterine leiomyomas

There are a number of options for the treatment of uterine leiomyomas (Table 2).

*Table 2.* Treatment modalities for uterine leiomyomas

---

<b>Surgical treatment</b>
Hysterectomy
Abdominal myomectomy
Laparoscopic myomectomy
Laparoscopic-assisted myomectomy
Vaginal myomectomy
Laparoscopic-assisted vaginal myomectomy
Hysteroscopic myomectomy
Interstitial laserphotocoagulation
Laparoscopic cryomyolysis
Interstitial magnetic resonance imaging guided thermo-ablation
Interstitial magnetic resonance imaging guided cryotherapy
Laparoscopic uterine artery occlusion

---

<b>Nonsurgical treatment</b>
Myoma embolization
Magnetic resonance guided focused ultrasound surgery

---

<b>Hormonal treatment</b>
Gonadotropin-releasing hormone agonists
Others (mifepristone, danazol, gestrinone, raloxifene, levonorgestrel-releasing intrauterine system)

---



## 6.5.1 Surgical treatment

Surgery is the cornerstone of treatment for leiomyomas. Hysterectomy serves as a terminal procedure, while myomectomy and myolysis are treatments of choice for women who desire future pregnancies or otherwise wish to retain their uterus.

### 6.5.1.1 Hysterectomy

In women who have completed childbearing, hysterectomy for symptomatic leiomyomas is an attractive option. Leiomyomas are the most common indication for this procedure, accounting for 30 % of hysterectomies in Caucasians and over 50 % in black women, respectively (Evidence Report 2001). In Finland, approximately nine thousand hysterectomies were performed per year in 1987-1989 and leiomyomas were detected in every second of these (Luoto et al. 1994). Hysterectomy may be performed abdominally, laparoscopically or vaginally with laparoscopic assistance under general anesthesia or vaginally in spinal block. The preoperative evaluation of the patient is an essential factor in assessing the method of hysterectomy most suitable for the patient and specific guidelines for uterine size, risk factors, and uterine and adnexal mobility and accessibility should be used (Kovac 1995). These also reduce the need for abdominal operations.

In a study by Kjerulff and colleagues (2000), decreased symptom severity, depression and anxiety levels and better quality of life were observed in more than 90 % of women who had undergone hysterectomy for benign diseases. In a large population-based cohort study, Altman and associates (2007) established that hysterectomy, irrespective of surgical technique, increased the risk of stress-urinary-incontinence surgery later in life. Hysterectomy is a major operation, as there is significant morbidity in 3 % of cases and minor morbidity in approximately 14 % (Lumsden et al. 2000). A mortality rate of 0.02 % after abdominal hysterectomy, 0.06 % after vaginal hysterectomy and 0.04 % after laparoscopic hysterectomy in benign conditions have been recorded (Mäkinen et al. 2001).

### 6.5.1.2 Abdominal myomectomy

Myomectomy by various techniques is an alternative procedure for women who wish to retain the possibility of childbearing. The traditional approach has been through a laparotomy incision. In the case of women with multiple myomas or a significantly enlarged uterus (i.e., >14 week size or myomas > 8 cm), myomectomy by laparotomy or minilaparotomy incision is often the technique of choice (Hillis et al. 1996, Dubuisson et al. 2000a). Mostly, a low transverse abdominal incision provides adequate access to the tumors. Vertical incision may be required if the uterus reaches substantially above the umbilicus or when extensive adhesions are anticipated (Hutchins, 1995b). After access to the peritoneal cavity is achieved, the size, location and number of myomas are evaluated. The utmost effort is made to

conservate the uterine blood supply and minimize the bleeding. Limiting the number of incisions on the uterus to a single anterior vertical incision wherever possible is advocated by most authors (Buttram and Reiter 1981, Garcia and Pfeifer 1993, Wallach 1992). The posterior uterine incision should be avoided, as it is associated with an increase in adnexal adhesions (Buttram and Reiter 1981, Tulandi et al. 1993). In the case of solitary and large myomas it is best to locate the incision where the overlying myometrium is thinnest.

The uterine incision is made through the myometrium into the myoma and the tumor is grasped and traction applied. The myoma is enucleated from its myometrial bed with a combination of sharp and blunt dissection. The size of both the uterine and skin incisions may be reduced by morcellation of myomas during their removal. After extirpation of a leiomyoma, meticulous closure of all empty space is essential. An improperly closed defect may result in postoperative bleeding, intramural hematomas, anemia and febrile morbidity. Moreover, there is an increased risk of uterine rupture in pregnancy (Hutchins 1995b). A multilayered closure of the myometrium using absorbable suture should be used. If narrow deep pockets are found, suturing in concentric circles to obliterate empty space is advisable. When the endometrial cavity is entered, the endometrium is closed as an individual layer. The serosal layer is closed using a continuous stitch (Hutchins 1995b).

Intraoperative complications include blood loss and injury to the bowel or urinary tract. The volume of blood loss during abdominal myomectomy varies with the size and location of the myomas. An average blood loss of 230-800 mL has been reported in studies of abdominal myomectomy for uterine sizes exceeding 14 gestational weeks (Sawin et al. 2000, West et al. 2006). Mechanical techniques including tourniquets and clamps to occlude the uterine and ovarian arteries have been shown to be effective in reducing blood loss during the operation (Taylor et al. 2005). Nonmechanical techniques have also been used with success (Kongnyuy and Wiysonge 2007, Gutmann and Corson 2005).

Abdominal myomectomy is successful in relieving symptoms in about 80 % of cases (Buttram and Reiter 1981), while satisfaction rates in excess of 90 % have been reported after hysterectomy (Dwyer et al. 1993). Following abdominal myomectomy performed for infertility, a 57 % pregnancy rate has been recorded (Vercellini et al. 1998). The cumulative myoma recurrence rate after abdominal myomectomy has been found to be 27-51 % during five to ten years of follow-up (Candiani et al. 1991, Fedele et al. 1995).

The operative time, blood loss and hospital stay are comparable with abdominal hysterectomy (Hillis et al. 1996, Iverson et al. 1996). The risk of unexpected need for hysterectomy at the time of myomectomy is less than one per cent for experienced surgeons (ACOG 2001). There is no clinically significant difference in perioperative morbidity between abdominal myomectomy and hysterectomy (39 % versus 40 %) (Sawin et al. 2000).

Postoperative adhesions are formed in 98 % of cases (Dubuisson et al. 1998). Compared to the situation after classical cesarean delivery (about 3.7 %) (Stotland et al. 2002), the risk of uterine rupture before labor is very low after abdominal myomectomy (about 0.002 %) (Garnet 1964, Dubuisson et al. 2000b). A delay of

three to six months prior to attempting to conceive is advisable for women who undergo myomectomy with significant uterine disruption.

### 6.5.1.3 *Laparoscopic myomectomy*

Laparoscopic myomectomy was first described by Semm (1977). Later the technique became more common and several researchers reported good results (Daniell and Gurley 1991, Nezhat et al 1991, Mais et al. 1996). The method can be considered for patients with a small number of subserosal or intramural leiomyomas or with a uterus less than 17 weeks' gestational size. Proper endoscopic visualization of the operation cannot be achieved, if the uterus is too large. Dubuisson and associates (2001) found that a leiomyoma size  $\geq 5.0$  cm, intramural location, anterior position and preoperative use of a GnRH-agonist were all factors leading to an increased risk of conversion to an open procedure. In contrast, Sinha and colleagues (2008) showed that regardless of the size, number or location of the leiomyomas, myomectomy can be performed laparoscopically by experienced surgeons. A total number of 912 myomas were laparoscopically removed in 505 patients and only one conversion to laparotomy was registered. The mean size of the removed tumors was  $5.9 \pm 3.3$  cm. The advantages of the use of GnRH agonists prior to laparoscopic myomectomy include correction of anemia preoperatively, and a slight reduction in blood loss during surgery (Lethaby et al. 2004). It may, however, complicate myoma enucleation by altering the myoma-myometrium interface (Campo and Carcea 1999).

The uterine serosa is first incised with scissors or a monopolar needle and the incision then extended into the myoma. The tumor is grasped and traction applied. Securing hemostasis in the process, the myoma is dissected from the surrounding myometrium. Once the myoma has been extracted, additional hemostasis is obtained. The myoma cavity is sutured using laparoscopic instruments. The myoma is removed either by using laparoscopic morcellator or by extending a port site to accommodate a small myoma, or piece by piece in the case of a larger tumor (Gomel and Taylor 1995).

There are several technical limitations to laparoscopic myomectomy. If myomas are large or multiple, operating time and blood loss can be substantial. If a myoma is situated deep in the myometrium, repair of the uterine wall can be difficult or even impossible and increase the risk of uterine rupture during pregnancy (Breech and Rock 2003). Eleven uterine ruptures have been reported in laparoscopic myomectomy between the years 1992 and 2005 (Parker 2006). A study by Cobellis and associates (2002) found that gross inspection of myomectomy scars during cesarean section showed a thinner scar with more tension in five women with prior laparoscopic myomectomy than in ten women with earlier abdominal myomectomy. Removal of the resected or morcellated pieces of the myoma from the abdominal cavity may also be challenging (Breech and Rock 2003). A risk of 1.8- 8 % of conversion to open myomectomy has been reported (Nezhat et al. 1991, Dubuisson et al. 1996, Seiner et al. 1997). Adhesion rates of 35.6-41.3 % have been reported

after laparoscopic myomectomy (Nezhat et al. 1991, Stringer and Strassner 1996, Dubuisson et al. 1998), which is clearly less than following open myomectomy.

Compared to abdominal myomectomy, the laparoscopic approach is associated with a shorter postoperative recovery period and hospital stay (Miller 2000), but is technically challenging and time-consuming, and only selected leiomyomas are suitable for the technique (Miskry and Magos 1999).

#### *6.5.1.4 Laparoscopic-assisted myomectomy*

In 1994, Nezhat and associates described a laparoscopic-assisted myomectomy, a method combining laparoscopy and mini-laparotomy in the removal of uterine leiomyomas (Nezhat et al. 1994). A minilaparotomy incision is made after partial laparoscopic enucleation of the tumor. Enucleation is finished outside the abdominal cavity and the uterine incision closed as in laparotomy. The uterus is replaced in the abdominal cavity and the abdominal incision sutured (Tulandi and Al-Took 1999). Minilaparotomy permits thorough removal of the myomas and effective closure of the uterine defect (Gomel and Taylor 1995).

Laparoscopic-assisted myomectomy is as effective as abdominal myomectomy, but the cutaneous incision is smaller, hospital stay shorter, recovery faster and blood loss lesser. The operating time in laparoscopic-assisted myomectomy has varied from 94-127 min and the mean blood loss has been 110-267 ml (Nezhat et al. 1994). The uterine incision is effectively manually closed with conventional instruments (Tulandi and Al-Took 1999).

#### *6.5.1.5 Vaginal myomectomy*

Bessenay and associates (1998) mentioned that vaginal myomectomy was first described in 1842. The modern technique was first reported by Magos and associates in 1994. Only few reports have been published on this procedure (Magos et al. 1994, Davies et al. 1999, Birsan et al. 2003, Agostini et al. 2004). There must be adequate vaginal access, good uterine mobility and a maximum myoma dimension of 11 cm to permit this procedure (Davies et al. 1999). Depending on the location of the myoma, anterior or posterior colpotomy is made to reach it, the myoma is enucleated, and the uterine wall sutured as in laparoscopic or abdominal myomectomy. Posterior leiomyomas are easier of access, as there is more space for colpotomy and uterine manipulation in the posterior pelvic compartment.

Agostini and associates (2004) reported a retrospective study of 45 patients out of whom 40 underwent posterior colpotomy. Only one myoma was found in 93.3% of patients, two myomas in 2.2% and three in 4.4% of patients. The mean mass of the excised myomas was 207 g. Davies and associates (1999) conducted a prospective study of 35 patients who underwent anterior or posterior colpotomy and excision of a mean number of 2.5 myomas per patient with a mean mass of 114 g.

In a study by Davies and colleagues (1999), the mean operating time was 78 minutes and blood loss 313.6 mL. Four patients (11.4 %) developed a pelvic

hematoma postoperatively and one of these required draining (Davies et al. 1999). Seventy-four per cent of patients reported symptom relief three months postoperatively and three patients had become pregnant and given birth.

Birsan and associates (2003) compared the feasibility and complications of vaginal and laparoscopic myomectomy. The mean operating time was shorter and the need for postoperative analgesics lower in the vaginal group. There were no differences in mean perioperative blood loss, length of postoperative hospital stay or the time of return to normal activity between these two groups.

#### *6.5.1.6 Laparoscopic-assisted vaginal myomectomy*

Pelosi and Pelosi (1997) were first to describe the laparoscopic-assisted transvaginal myomectomy. Other researchers have since used their own modifications of the technique (Goldfarb and Fanarjian 2001). Laparoscopic enucleation of leiomyomas is performed as described above. A laparoscopic myoma screw is inserted into the myoma and the tumor guided to the fossa Douglas. Vaginal posterior colpotomy is made and the myoma removed via this. The uterine incision is sutured via colpotomy by a technique described elsewhere (Goldfarb and Fanarjian 2001).

In a series of 11 patients, the mean operating time for laparoscopic-assisted vaginal myomectomy has been 93 minutes and blood loss 125 cc. Three patients had urinary retention and one patient fever postoperatively (Goldfarb and Fanarjian, 2001). Transvaginal removal of the leiomyoma avoids the need for port site extension; however, the longer operative time, the risk of infection, bowel or ureteral injury, and the need to maintain two surgical sites must be considered (Gomel and Taylor 1995).

#### *6.5.1.7 Hysteroscopic myomectomy*

Hysteroscopic myomectomy is the option of choice for women with symptomatic intracavitary leiomyomas (Lefebvre et al. 2003), including those with abnormal uterine bleeding, pain, infertility (Farhi et al. 1995), or recurrent pregnancy loss. These leiomyomas are classified by a method developed by Wamsteker and associates (1993) and adopted by the European Society of Gynaecological Endoscopy (ESGE), which takes account of the degree of myometrial penetration of the submucous tumor. Pedunculated submucous leiomyomas without intramural extension are classified as G0, sessile tumors with less than 50 % intramural extension as G1 and myomas with more than 50 % intramural extension as G2 type. Submucous myoma types G0 and G1 can be resected by hysteroscopic myomectomy. Repeated resection is needed for tumors extending more than 50 % intramurally in order to ensure bleeding control, and more complications are associated with them (Wamsteker et al. 1993).

Combination of endometrial ablation and myomectomy has been reported with varying levels of success (Wortman and Daggett 1995, O'Connor and Magos 1996, Loffer 2005). Studies examining the long-term impact of endometrial resection

combined with myomectomy are sparse (Loffer 2005). Hysteroscopic surgery is a commonly accepted alternative to hysterectomy in the treatment of menorrhagia (Abbott and Garry 2002) and a variety of transcervical methods of endometrial ablation have been utilized. Hysteroscopic resection of the endometrium is one of the oldest, and its operative outcomes, perioperative complications and short-term follow-up results are well documented (Lethaby et al. 2000a).

Hysteroscopic myomectomy is performed under general or spinal anesthesia. The cervix is dilated to Hegar 9-10 mm and a standard resectoscope advanced transcervically. The uterine cavity is distended by an electrolyte-free, low-viscosity solution such as 1.5 % glycine, 3 % D-sorbitol or 5 % mannitol. The recent development of a bipolar hysteroscopic system and bipolar scissors, and the use of a special morcellator also allows surgery to be performed in electrolyte-rich media such as normal saline (Emanuel and Wamsteker 2005). It is important to keep the pressure below the patient's mean arterial pressure to limit fluid intravasation and to measure precisely the inflow and outflow during the procedure. A wire monopolar or bipolar cutting loop is passed superior to the myoma and withdrawn toward the operator while keeping the resectoscope fixed in place. The myoma is shaved down to the level of the endometrium, until the uterine cavity is normalized or the myoma has been satisfactorily debulked. If the myoma is entirely situated in the uterine cavity, the stalk of the myoma is cut with the loop and then the myoma cut into pieces, which are removed by forceps from the uterine cavity. In the case of a large myoma, it is recommended to perform the procedure in two sessions. The myoma is resected as much as is safely possible in the first hysteroscopy, and after two months, the rest of the myoma is removed.

Endometrial ablation, either alone or in combination with hysteroscopic myomectomy, may alleviate bleeding with minimal invasiveness in women with uterine leiomyomas who have completed childbearing. Loffer (2005) reported a hysterectomy rate of 17.8 % among 73 women undergoing hysteroscopic myomectomy combined with endometrial ablation, and a rate of 22.1 % among 104 women with hysteroscopic myomectomy only. Derman and associates (1991) examined endometrial ablation with hysteroscopic myomectomy and found only an eight per cent risk of second surgery after a mean of six years of follow-up.

Complication rates increase with increasing number and size of myomas. Hemorrhage, cervical laceration, infection, uterine perforation or fluid overload is experienced by up to 6.6 % of women undergoing hysteroscopic myomectomy (Taylor and Gomel 2008). Twenty-two per cent will require a second procedure for incomplete resection or symptom recurrence (Batra et al. 2004). Campo and associates (2005) found myoma recurrence in 6 % of women two years postoperatively. Over 90 % of menorrhagia patients experience relief of symptoms after hysteroscopic resection of submucous leiomyoma. The pregnancy rate after the procedure is reported to be approximately 48 % (Fernandez et al. 2001).

#### 6.5.1.8 *Other techniques*

Several new mini-invasive techniques have been developed for treatment of uterine leiomyomas. The series in question are, however, small and there are no studies concerning the long-term outcomes of these methods.

Visvanathan and colleagues (2002) described interstitial laserphotocoagulation, which involves the insertion of optical fibers into the leiomyoma by laparoscopy. Low-power laser energy is then connected to the fibers, causing localized coagulation. Thirty myomas were treated in 24 patients and median reduction of myoma volume was 40 % in MRI in twelve patients followed for one year. Forty-four per cent of patients with menorrhagia reported a subjective improvement. Of three patients with infertility, one delivered a healthy infant vaginally at term 33 months after the procedure.

Zreik and colleagues (1998) described a method for laparoscopic cryomyolysis for leiomyomas. At laparoscopy and under ultrasound monitoring, a monopolar hook is used to create a tract extending from the serosa of the myoma to within 1 cm of the inferior capsule and at the location of the primary blood supply of the myoma. The hook is replaced with a cryoprobe, cooled to temperatures below -90 °C destroying tissues through sclerohyaline degeneration (Zupi et al. 2004). Twenty patients were treated with this technique and after six months the mean volume reduction of leiomyomas was 56.9 %. Fifteen patients had complete elimination of symptoms, and four reported marked improvement.

Law and Regan (2000) described a method of interstitial MRI guided thermo-ablation. Under local anesthesia, four compatible 18-gauge Turner needles were introduced under MRI guidance in a square configuration 1 cm apart into the center of the targeted leiomyoma in thirty women. The inner trochars were then replaced by bare laser fibres, and a diode laser transmitted to these. Thermal ablation was terminated when the real-time image processing software showed a tissue temperature greater than 55 °C, resulting in irreversible tissue necrosis. The mean duration of applied laser therapy was 15 minutes. Four women went on to subsequent surgery and 26 declined their planned hysterectomy. Three months after the procedure, the myoma volume had decreased by a mean of 37.5 %. All women reported notable improvement in symptoms at three months post-ablation. Cowan and colleagues (2002) have employed a similar technique, using cryotherapy instead of thermo-ablation. They described nine cases in which 65 % myoma shrinkage was achieved and primary symptoms were either improved or resolved.

In laparoscopic uterine artery occlusion, the uterine artery is closed with two to three endoclips on each side using the lateral approach to the origin of the uterine artery from the internal iliac artery (Hald et al. 2004, Hald et al. 2007). The utero-ovarian ligaments are also coagulated bilaterally with bipolar forceps. A reduction in the amount of bleeding in 93 % and in bulk symptoms in 85 % of the patients (n=28) after the procedure has been reported (Hald et al. 2007). Uterus volume was reduced by 37 % and the dominant leiomyoma by 36 % (Hald et al. 2004). Temporary damage to the obturator nerve was found in 14 % of women (Hald et al. 2004).

Hald and colleagues (2007) compared clinical outcomes six months after treatment with bilateral laparoscopic occlusion of the uterine artery versus uterine leiomyoma embolization. The percentage reduction in Pictorial Bleeding Assessment Chart scores did not differ between the treatment groups (52 % after uterine leiomyoma embolization and 53 % after laparoscopy,  $p=0.96$ ). Four per cent of patients in the the group treated with uterine leiomyoma embolization complained of heavy bleeding after six months, compared to 21 % of patients in the other group ( $p=0.44$ ).

## 6.5.2 Nonsurgical treatment

### 6.5.2.1 *Myoma embolization*

Uterine artery embolization is a technique based on limitation of myometrial arterial blood flow, resulting in infarction of leiomyomas (Ravina et al. 1995, Spies et al. 2001). The approach has been widely utilized for post-partum hemorrhage, post-operative bleeding and arteriovenous malformations (Poppe et al. 1987, Abbas et al. 1994). The first embolization of a leiomyoma was described by Ravina and colleagues (1995). Initially, embolization had been utilized before myomectomy and hysterectomy for reducing bleeding complications. Several series have since been published (Worthington-Kirsch et al. 1998, Hutchins Jr et al. 1999, Walker et al. 1999).

Before myoma embolization is carried out it is particularly important that the diagnosis has been confirmed and embolization is indicated (Scoutt et al. 1995, Dequesne and Schmidt 1998). The procedure is performed under regional or local anesthesia with conscious sedation and analgesics (Worthington-Kirsch et al. 2002) and most commonly via the right femoral artery. A catheter is passed into the distal portion of one of the uterine arteries under fluoroscopic guidance, followed by infusion of an embolizing agent (gelatin sponges, polyvinyl alcohol particles or tris-acryl gelatin microspheres). The embolization is completed when total occlusion of the uterine artery with stasis of contrast material is detected (Ravina et al. 1995, Walker et al. 1999, Worthington-Kirsch et al. 2002). Following the procedure, post-embolization syndrome, including pelvic pain and cramping, nausea, vomiting, low-grade fever, fatigue, myalgias, malaise and leukocytosis may occur within the first 48 hours. These symptoms gradually improve over seven days (Walker et al. 2002).

Patient satisfaction of 78-97 % and a significant enhancement in the quality of life have been reported after embolization (Spies et al. 2002a). An overall improvement of 61-96 % for leiomyoma-related complaints (84-96 % for hypermenorrhea, 81-97 % for menorrhagia, 70-88 % for lower abdominal pain, and 61-94 % for pressure symptoms) has been confirmed (David and Ebert 2004). Shrinkage of the uterus (median values 23-60 %) and of the dominant leiomyoma (42-78 %) has been detected (Vogl et al. 2003), with a constant decrease in leiomyoma size extending over a period of up to one year after the procedure (McLucas et al. 2001).



The technical success rate for uterine artery embolization has been found to be at 95-100% (Radeleff et al. 2003). Inguinal hematomas occur in 0-3.2 %. In 6.7 % of patients, vaginal expulsion of myoma material may be observed and a chronic smelly discharge has emerged in up to 5 % (Spies 2004). Infections are reported in 0-11 % and premature menopause-induced amenorrhea in a maximum of 13.6 %. A mortality rate of 0.01 % has been found (Agency for Healthcare Research and Quality 2006).

Spontaneous abortion was noted in 32 % of women in a study of 34 pregnancies after uterine artery embolization (Goldberg et al. 2004). In a study by Goldberg and associates (2002), the premature delivery rate was 28 % and malposition was found in 17 %. Small for gestational age children were seen in 7 %, the cesarean section rate was 58 %, and increased postpartum bleeding was detected in 13 %. Higher rates of preterm delivery and malpresentation have been reported in pregnancies after uterine artery embolization than after laparoscopic myomectomy (Goldberg et al. 2004). For these reasons, uterine artery embolization should be regarded as (relatively) contraindicated in patients desiring to preserve their fertility (ACOG 2004).

In a recent study comparing uterine artery embolization (n= 106) and surgery (n= 51; 43 hysterectomies, 8 myomectomies) for symptomatic uterine leiomyomas found no significant differences in quality of life scores between these two groups one year after treatment (the REST investigators 2007). The median duration of hospitalization and time before return to work were shorter in the embolization than in the surgical group. Repeated embolization or hysterectomy for insufficient symptom control was needed in 9 % of the patients in the embolization group. At one year of follow-up, total costs for uterine artery embolization were significantly lower than those associated with surgery.

Broder and associates (2002) found that during a follow-up of 3-5 years after leiomyoma enucleation or uterine artery embolization, both treatment satisfaction and improvement of symptoms were similarly high in both groups, but that embolization patients underwent significantly more invasive procedures (myoma enucleation, repeat embolization, hysterectomy) because of myoma-associated complaints (29 % versus 3 %). Razavi and colleagues (2003), however, were not able to confirm this. Pinto and associates (2003) conducted a prospective randomized controlled clinical study in which leiomyoma therapy by uterine artery embolization (40 patients) was compared with abdominal hysterectomy (20 patients). Bleeding control was achieved in 86 % of embolization patients and, naturally, 100 % of hysterectomy patients. After embolization, the mean hospital stay was four days shorter. During or following uterine artery embolization, minor complications occurred in 25 % and only one serious complication (deep venous thrombosis) was detected. Major complications were significantly higher in the hysterectomy group, 20 % occurring intraoperatively (bladder injury, blood transfusions) and 45 % postoperatively (thrombosis, wound abscess, transfusions).

A morbidity of five per cent has been noted in the course of uterine artery embolization (Spies et al. 2002b). American studies report a total morbidity of 38.6 % after myomectomy and 40.1 % after hysterectomy (Sawin et al. 2000).

### 6.5.2.2 *Magnetic resonance guided focused ultrasound surgery*

The noninvasive focused ultrasound surgery system creates an ultrasound beam of approximately 1-1.5 MHz frequency producing coagulative necrosis at a precise focal point within the body. The location and extent of treatment is monitored by real-time MRI and thermal mapping (Chung et al. 1999, Hynynen et al. 1996), and the treatment can be performed as an outpatient procedure (Stewart et al. 2003). Leiomyomas which are resectable with a hysteroscope, near the bowel or bladder, heavily calcified, or in women desiring future pregnancy are contraindications for the treatment. Morita and associates (2007) found a reduction of 33 % in the mean fibroid size in 39 women after six months of follow-up.

This method appears to target treatment for myomas with high safety. Patients have few complaints after magnetic resonance-guided focused ultrasound surgery, in contrast to uterine artery embolization, after which postprocedure pain and fever are usual. No cases of postembolization syndrome or marked pain after focused ultrasound surgery have been reported (Stewart et al. 2003).

### 6.5.2.3 *Hormonal treatment*

Medical therapy aims to relieve symptoms and may enable conservation of the uterus. However, as symptoms often rapidly return after discontinuation of the treatment, many women prefer direct surgery.

#### 6.5.2.3.1 *Gonadotropin-releasing hormone agonists*

GnRH agonists create a menopause mimicking hypogonadotropic hypogonadal state. They may be utilized to reduce tumor size and vascularity before surgery or as a temporary medication in perimenopausal women (Wallach 1992). A significant, rapid shrinkage of 35- 65 % in uterine size is observed (Shaw 1991), occurring mostly during the first three months of therapy (Broekmans 1996). Friedman and associates (1991) found resolution of menorrhagia in 36 of 37 women after six months of leuprolide acetate. Menses return in 4-8 weeks after discontinuation of the treatment (Palomba et al. 1999).

A rapid regrowth of myomas to pretreatment size occurs within a few months after discontinuing treatment (Wallach 1992) and uterine size returns to original levels within 4-6 months (Letterie et al. 1989). The severe hypoestrogenic state may also result in marked symptoms, bone loss leading to osteoporosis after long-term use being the most serious complication (Friedman et al. 1988). Significant bone loss is detected after half a year of treatment (Leather et al. 1993), and for this reason, GnRH analogues cannot be administered for more than three to six months. Side-effects including hot flushes, vaginal dryness and frontal headaches are reported in 95 % of patients (Letterie et al. 1989). Low doses of estrogen and progestins may be used along with GnRH analogue treatment to limit side-effects

and bone loss. The results concerning the benefit of this “add back” therapy are controversial (Friedman et al. 1994, Pierce et al. 2000).

When GnRH analogues were used before either hysterectomy or myomectomy, pre- and postoperative hemoglobin were significantly improved, and uterine and myoma volume and pelvic symptoms decreased. Hysterectomy was easier and operating time shorter. The need for vertical incision and blood loss was diminished both for hysterectomy and myomectomy. More vaginal hysterectomies could be made instead of abdominal procedures. Duration of hospital stay was shorter. (Lethaby et al. 2000b). However, GnRH analogues may render the surgical planes more difficult to differentiate, which makes myoma enucleation more troublesome (ACOG 2001). Comparable results have been detected with GnRH- antagonists (Felberbaum et al. 1998).

#### 6.5.2.3.2 Others

Mifepristone, a PR modulator with primarily antagonistic properties, has been found to reduce myoma size in a number of trials (Steinauer et al. 2004, Eisinger et al. 2005, Fiscella et al. 2006), shrinkage being from 26 % to 74 % after three or more months of treatment (Steinauer et al. 2004). After six months from ending therapy, myoma regrowth has been shown in 18 % of women (Zeng et al. 1998). Adverse effects include amenorrhea in over 90 % of women, hot flushes, elevated hepatic enzymes, and endometrial hyperplasia (Steinauer et al. 2004).

Danazol is an isoxazole derivative of 17  $\alpha$ -ethinyl testosterone with androgenic and progestin-like effects (De Leo 1997). In one study, myoma volume was reduced by an average of 23.6 % after four months of treatment (De Leo 1999).

Gestrinone, a synthetic derivative of ethynyl-nor-testosterone, is a steroid with antiestrogen and antiprogestone properties and which has been shown to reduce uterine volume and stop bleeding (Coutinho 1990). In a study by La Marca and colleagues (2004), a 32 % reduction in uterine volume and a 35.2 % in myoma volume were observed after six months of therapy (La Marca 2004).

In a study by Palomba and associates (2001), raloxifene, a selective estrogen-receptor modulator, (60 mg/day for 12 months) reduced leiomyoma size when compared to placebo in postmenopausal women with uterine leiomyomas. Results in premenopausal women have been conflicting (Palomba et al. 2002a, Jirecek et al. 2004).

The levonorgestrel-releasing intrauterine system (LNG-IUS) is a well tolerated and effective contraceptive method (Luukkainen et al. 2001). A significant reduction in menstrual blood loss and improvement in anemia have been established in users of this system (Hubacher and Grimes 2002, Monteiro et al. 2002, Hurskainen et al. 2004, Rosa e Silva et al. 2005). In a recent prospective cohort study (Magalhaes et al. 2007), a significant mean uterine volume reduction of 36.4 cm<sup>3</sup> in patients with idiopathic menorrhagia and 63.6 cm<sup>3</sup> in patients with leiomyomas using a LNG-IUS was found during 36 months of follow-up. After three years of use, amenorrhea was higher in the contraception group (57.1 %) and

in women with idiopathic menorrhagia (53.4 %) than in women with menorrhagia due to leiomyomas (44.5 %) ( $p=0.027$ ).

Oral contraceptives and progestational derivatives are often used for abnormal uterine bleeding, but they seem mostly to have limited efficacy in the treatment of uterine leiomyomas (Friedman et al. 1988, Carr et al. 1993). The use of oral contraceptive pills or progestin-only injectable contraception may reduce the risk of developing leiomyomas (Lumbiganon et al. 1996, Wise et al. 2004). Oral contraceptives may reduce bleeding in some women with leiomyomas and menorrhagia, but not in all such patients.

# 7 AIMS OF THE STUDY

The present study was undertaken to investigate certain aspects of the etiology, diagnosis and management of uterine leiomyomas. The specific aims were:

1. To determine the potential effect of  $1,25(\text{OH})_2\text{D}_3$  and  $25(\text{OH})\text{D}_3$  vitamin D derivatives on the growth of leiomyoma and myometrial cells *in vitro* (I).
2. To evaluate the accuracy of a formula combining the prolate ellipsoid (uterine corpus) and cylinder (uterine cervix) formulas in estimating the preoperative weight of the total myomatous uterus and to determine the validity of transvaginal ultrasound in assessing uterine size through correlation with hysterectomy specimens (II).
3. To analyze different sources of variation in estimating the preoperative weight of the myomatous uterus (III).
4. To describe a novel traction modification of vaginal myomectomy and to assess the clinical effectiveness and safety of this method (IV).
5. To compare hysterectomy rates after hysteroscopic endometrial resection with or without myomectomy for menorrhagia and to establish the long-term outcomes of these two procedures (V).

# 8 PATIENTS AND METHODS

## 8.1 Patients and study designs

The patients searching treatment for symptomatic uterine leiomyomas were recruited to the study protocols from the Department of Obstetrics and Gynecology, Tampere University Hospital, Finland. The study material, design and main outcome measures in studies I-V are summarized in Table 3.

Women with preoperatively detected uterine leiomyomas were included and patients with suspected malignancy excluded in all studies (I- V). The leiomyoma diagnosis was reached after careful preoperative pelvic examination and transvaginal ultrasound scanning in all cases. Some specific criterias were set: for study I, no hormonal therapy for at least six months prior to surgery; for study IV, patients with leiomyoma palpable upon vaginal examination, good uterine mobility, adequate vaginal access, well-lined leiomyoma and no detectable adnexal pathology were candidates for vaginal myomectomy; for study V, women with a uterus larger than the size of a 12-week pregnancy or who had submucous leiomyomas larger than 5 cm in diameter and extending more than 50 % intramurally were excluded from hysteroscopic surgery. Women with uterovaginal prolapse, endometrial hyperplasia, untreated adnexal disease or acute pelvic inflammatory disease and those desiring future pregnancy were not included.

Studies II and III comprised the same subjects. Four of them were nulliparous and three postmenopausal.

Study IV involved patients who desired to preserve their fertility. None of them had had previous pelvic surgery and six were nulliparous. Preoperative ultrasound examination showed leiomyomas ranging from 5.6 to 8.0 cm in size (mean 6.7 cm) and located posteriorly in seven cases and anteriorly in three.

Study group V comprised 53 women who had undergone hysteroscopic endometrial resection and myomectomy, and each of them was matched retrospectively in age, parity and nearest date of operation with a patient treated by plain endometrial resection during the same period of time. All patients suffered from menorrhagia and were candidates for hysterectomy.

*Table 3.* Study material, design and main outcome measures in Studies I-V.

Study	Number of patients	Age (years) mean (range)	Characteristics of subjects	Design	Main outcome measures
I	6	43.8 (38-49)	Samples of subserous or intramural leiomyomas and matched myometrial tissues	Prospective	The effect of 1,25(OH) <sub>2</sub> D <sub>3</sub> and 25(OH)D <sub>3</sub> on cell growth
II	12	49.5 (42-56)	Women with symptomatic leiomyomas scheduled to undergo hysterectomy	Prospective	Comparison of two geometrical formulas for accuracy in predicting uterine size
III	12	49.5 (42-56)	Women with symptomatic leiomyomas scheduled to undergo hysterectomy	Prospective	Variation due to differences across repeated measurements, across physicians, across patients
IV	10	32.3 (26-40)	Women with symptomatic subserous or intramural leiomyomas	Retrospective	Feasibility and outcome of vaginal myomectomy
V	106	44.8 (34-59)	Women with or without submucous leiomyomas	Retrospective	Subsequent hysterectomy

## 8.2 Vitamin D assay for leiomyoma and myometrial samples (I)

Immediately after removal of the uterus, samples 1 cm<sup>3</sup> of benign leiomyomas and of adjacent matched myometrial tissue were obtained and tissue specimens transported to the laboratory. The specimens were cut into small pieces and digested and the cells collected by centrifugation. The isolated cells were seeded in 75-cm<sup>2</sup> flasks in culture medium supplemented with 1nM E<sub>2</sub> (Sigma) and propagated at 37°C in a humidified atmosphere containing 5% CO<sub>2</sub> in air. Cells from subconfluent primary or secondary cultures were used in all experiments.

For immunohistochemical analysis cells were seeded on 4-chamber cell culture slides at 5000 cells/chamber and cultured until subconfluency. Thereafter, the cells were fixed and permeabilized. Characterization of the cell cultures was done by immunohistochemical means with antibodies against two proteins associated with the smooth muscle phenotype, smooth muscle actin (SMA) and desmin and the intermediate filament protein distinctive of the fibroplastic phenotype, vimentin. Staining was performed and the percentage of cells expressing SMA, desmin or vimentin was determined by calculating the number of immunopositive and immunonegative cells in five randomly selected microscopic fields. Antibodies specific for VDR, ER and PR were employed to assess steroid receptor expression in the cultivated cells. VDR was visualized in tissue samples by immunohistochemical staining with the rat monoclonal anti-VDR antibody. In the controls the primary antibodies were omitted and staining done with nonimmunized mouse or rat immunoglobulin G (IgG).

Leiomyoma cells and matched normal myometrial cells were seeded onto 96-well microtiter plates and allowed to attach for 48 h in culture medium supplemented with 1nM E<sub>2</sub>. The medium was then replaced and the cells treated with the indicated concentrations of 1,25(OH)<sub>2</sub>D<sub>3</sub> or 25(OH)D<sub>3</sub> in culture medium supplemented with 1 nM E<sub>2</sub>. Ethanol vehicle was included in the control treatment. The medium was renewed every three days. Relative cell numbers were assessed at 0, 3, 6, 9, 12 and 15 days using the colorimetric crystal violet assay (Kueng et al. 1989). Eight determinations were used to calculate the mean optical density at each time point. The absorbance value for day 0 was set at 0 by subtracting the value for that day from each value obtained from the subsequent timepoint measurements (days 3 to 15). Growth curves were created on the basis of the resultant absorbance values. Day 9 was used to compare the effect of the hormone treatments.



## 8.3 Determination of uterine volume (II-III)

### 8.3.1 Ultrasound measurements and calculation of volume

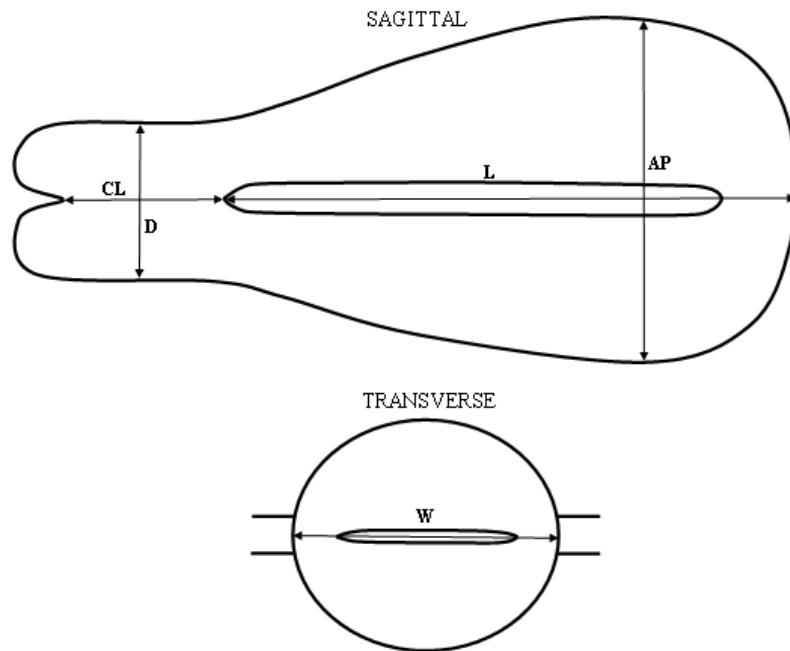
Each patient, supine and with an empty bladder, underwent a thorough preoperative pelvic examination and imaging with an ultrasound sector scanner with a 6 MHz transvaginal probe conducted by three investigators. One of these (physician 1) was a highly experienced senior gynecologist with oncological subspeciality. The other two physicians were resident postgraduates training in Obstetrics and Gynecology. Physician 2 was experienced in measuring uterine dimensions by vaginal and abdominal ultrasound, and the other (physician 3) was not. A 3.75 MHz abdominal probe was utilized, if the field of the vaginal probe was not wide enough to reach the dimensions of a large uterus.

The anteroposterior diameter (AP) of the uterine corpus was determined from a sagittal scan parallel to the midline axis of the body and length (L) by measuring from the internal os of the cervix to the dome of the fundus or mass. Cervical length (CL) was measured from the internal to the external os of the cervix and the cervical anteroposterior diameter (D) was established. The vaginal probe was then rotated parallel to the coronal axis to view the largest cross-sectional area and to determine the maximal width (W) of the uterine corpus (Figure 2).

Each physician determined all measurements independently and repeated the rounds of measurements altogether three times during the scanning of each patient, multiplying thus the findings for the study. Although there were only twelve patients, the total number of findings was 108 (12 subjects x 3 investigators x 3 rounds of measurement). This was the pivotal term in providing sufficient information for the analysis, not the size of the study population.

The volume of the uterine corpus was calculated from a geometric formula for a prolate ellipsoid (A) based on the length, width and anteroposterior diameter of the corpus, and the volume of the cervix from a geometric formula for a cylinder (B) based on length and anteroposterior diameter of cervix (Figure 3).

The total volume was obtained by summing these two volumes. To calculate the total uterine volume with the plain formula for an ellipsoid, the same ellipsoid formula was used as above, but the length (L) used comprised the length of the corpus summed with the length of the cervix.



*Figure 2.* Uterine measurements. The sagittal sonogram illustrates the technique for measurement of maximal uterine and cervical length and anteroposterior diameter. The transverse sonogram shows the maximal transverse uterine diameter. AP, anteroposterior diameter of the uterine corpus; L, length of the corpus; CL, cervical length; D, anteroposterior diameter of the cervix; W, width of the uterine corpus.

<p>(A) <math>0.5236 \times L \times W \times AP</math></p> <p>(B) <math>\pi (D/2)^2 \times CL</math></p>
--

*Figure 3.* Formulas for prolate ellipsoid (A) and cylinder (B). AP, anteroposterior diameter of the uterine corpus; L, length of the corpus; CL, cervical length; D, anteroposterior diameter of the cervix; W, width of the uterine corpus.

### 8.3.2 Measurements of uterine prepartes

Immediately after removal at hysterectomy, Fallopian tubes and ovaries were removed from the uterus, the cervix cut from the corpus and the measurements performed. Using a pair of compasses and a centimetres scale, the three maximal

dimensions of length, depth and width of the corpus and length and diameter of the cervix were obtained at the same axis as that described for the ultrasonographic measurements. The weights of the uterine corpus and cervix were measured with a digital scale and summed. The uterine corpus and cervix were then separately immersed in a graduated plastic cylinder, partially prefilled with water, and the volumes determined by water displacement. The volumes noted were summed.

## 8.4 Operative techniques in myomectomy and follow-up (IV-V)

### 8.4.1 Transvaginal myomectomy (IV)

All operations were carried out by one physician. Posterior or anterior vaginal colpotomy was performed and the uterine serosa covering the myoma grasped with Schroeder forceps and directed to the colpotomy incision. A midline incision was made on the myoma up to the pseudocapsule. A Doyen myoma screw was then twisted into the myoma until firmly in place. Constant traction was maintained by the screw following extraction of the myoma together with the uterine fundus through the colpotomy into the vagina. The myoma was then enucleated and extracted under visual control. The uterine incision was repaired in layers as in myomectomy in laparotomy, using conventional instruments and sutures. The uterus was placed in the peritoneal cavity and the colpotomy incision closed.

The main outcome measures in study IV included feasibility of procedure, operative complications, postoperative recovery, pregnancies and relief of symptoms. Subjects were seen at the outpatient clinic two months after the operation. Those for whom this contact was not registered in the hospital records were interviewed by telephone. The mean follow-up period was 24 months (range 5 months - 43 months) and each patient had at least one vaginal ultrasound examination during that time. Data on possible symptoms, fertility and outcome of pregnancies during the follow-up period were recorded.

### 8.4.2 Endometrial resection and myomectomy (V)

The endometrium was resected using a standard unipolar resectoscope method distending the uterine cavity with 2.2 % isotonic glycine. Myomectomy was performed prior to endometrial resection using the shaving technique in which a loop is actively drawn toward the operator while keeping the resectoscope fixed in place. Complete resection was the main goal in all procedures. With intramural extension of fibroid the resection was considered complete if the pseudocapsular tissue of the intramural part and the entire resected area could be visualized. To determine the result of myomectomy, transabdominal or transrectal ultrasound was

performed in sporadic cases. Fluid balance was closely monitored throughout the procedure. After surgery, the inflow and outflow volumes were measured and the glycine deficit calculated. The perioperative blood loss was estimated.

A subsequent hysterectomy was the endpoint of study V. The patients' hospital records were examined to obtain details on preoperative history, operative procedures, further surgical treatment and documented follow-up. Patients who had not undergone a hysterectomy during the follow-up period were sent a postal questionnaire to assess the long-term effects. Patients were asked whether they had had amenorrhea, slight menstruation, no improvement in menstrual flow or increased menstrual flow. The mean follow-up period was 76 months (range four to 132 months) in the women with myomectomy and 79 months (five to 123 months) in those with no myomectomy. One patient with myomectomy was lost to follow-up.

## 8.5 Statistical analysis

In study I, means  $\pm$  SEM were calculated for each treatment with vitamin D derivatives and statistical differences were assessed using the Wilcoxon signed ranks test. A probability value (p) of 0.05 or less was considered statistically significant.

In study II, the normality of the distribution of the variables studied was assessed by the Kolmogorov-Smirnov test. The distributions of all variables were skewed. Values of continuous variables were expressed as median, quartile ranges and both minimum and maximum. Differences between the traditional and new equation compared to real uterine weight were tested by the Wilcoxon Signed Ranks test. Statistical analyses were performed on SPSS 12.0.1 for Windows (SPSS Inc., Chicago, IL, USA). A p-value less than 0.05 was considered statistically significant.

In study III the repeatability and reproducibility (R&R) method was applied. As the distribution of the difference between real and calculated uterine weight was skewed, the range method was used. The following variance components were estimated: repeatability (difference across measurements), reproducibility (difference across physicians) and variability (difference across patients). Statistical analyses were performed on Statistica/W (Version 5.1, 98 edition, Statsoft. Inc, Tulsa, OK, USA).

In study IV, means  $\pm$  SEM were calculated for characteristics and operative details for each patient.

In study V, the incidence of subsequent hysterectomy was calculated by survival analysis (Kaplan-Meier) in both study groups and the curves compared by the log rank test. For statistical analysis unpaired Student's t test for continuous data and Fisher's exact test for nominal or ordinal data were used. Statistical analysis was performed using SPSS for Windows, version 11.5 (SPSS Inc., Chicago, IL, USA). The level of significance was set at  $p < 0.05$ .

## 8.6 Ethical considerations

The Ethics Committee of Tampere University Hospital approved the study protocols. Informed consent was obtained from each patient before entering the study.

## 9 RESULTS

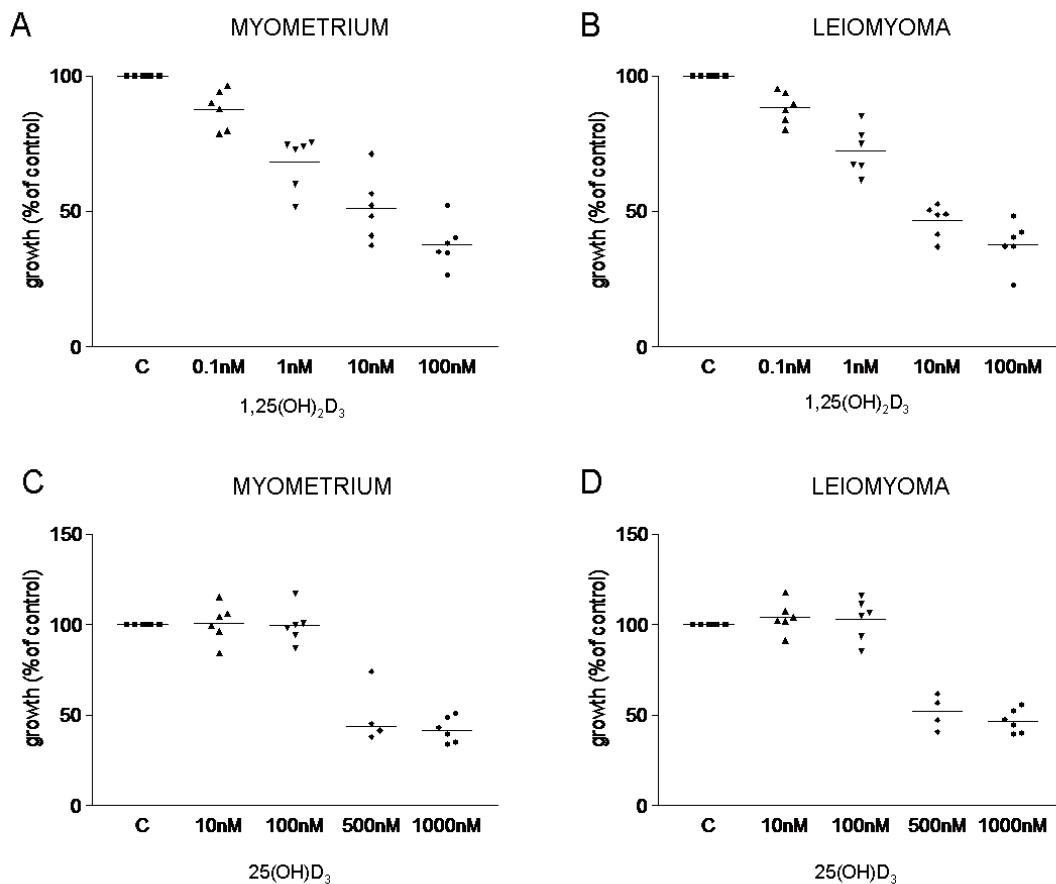
### 9.1 The effect of 1,25(OH)<sub>2</sub>D<sub>3</sub> and 25(OH)D<sub>3</sub> vitamin D derivatives on leiomyoma and myometrial cells

Upon immunohistochemical characterization with antibodies against SMA, desmin and vimentin the cell cultures of myometrium and leiomyoma were found to be composed mainly of smooth muscle cells. Whereas ER and PR expression was detected in all intact tissue samples, the overall ER staining in cultured cells proved negative with the exception of a few immunopositive nuclei. PRs were not found. VDR was present in all myometrial samples and their matched leiomyoma specimens.

Exponential growth of both cell types without significant differences in their mean rates of proliferation was shown in the growth curves of normal myometrial and leiomyoma cell cultures from six patients. A marked variance in growth rates was noted between individuals, whereas no consistent differences were detected between the growth rates of paired myometrial and leiomyoma cell cultures originating from the same patient.

The normal myometrial and leiomyoma cells were treated for nine days with increasing doses of 1,25(OH)<sub>2</sub>D<sub>3</sub> and 25(OH)D<sub>3</sub>. In both myometrial and leiomyoma cells, a similar concentration-dependent growth inhibition was detected with 1,25(OH)<sub>2</sub>D<sub>3</sub> (Figures 4A and B). In both cell types, the lowest amount of 1,25(OH)<sub>2</sub>D<sub>3</sub> tested (0.1nM) inhibited growth by 12% when compared to controls. For 1nM 1,25(OH)<sub>2</sub>D<sub>3</sub> the corresponding percentages for myometrial and leiomyoma cells were 32% and 28%, and for 10 nM 1,25(OH)<sub>2</sub>D<sub>3</sub>, 49% and 53%. The highest concentration of 1,25(OH)<sub>2</sub>D<sub>3</sub> (100 nM) inhibited growth by 62% in both cell types. All the differences detected were statistically significant ( $p < 0.05$ ).

As illustrated in Figures 4C and D, a slight stimulation of cell proliferation was observed with the lowest 25(OH)D<sub>3</sub> concentrations (10 nM and 100 nM) in some myometrial and leiomyoma cultures. When treated with the compound in a 1000 nM concentration, the growth of both cell types fell to approximately 50% of that of the control cultures, the magnitude of inhibition being statistically significant ( $p < 0.05$ ). In the case of 500 nM 25(OH)D<sub>3</sub>, statistical significance was not reached ( $p = 0.068$ ).



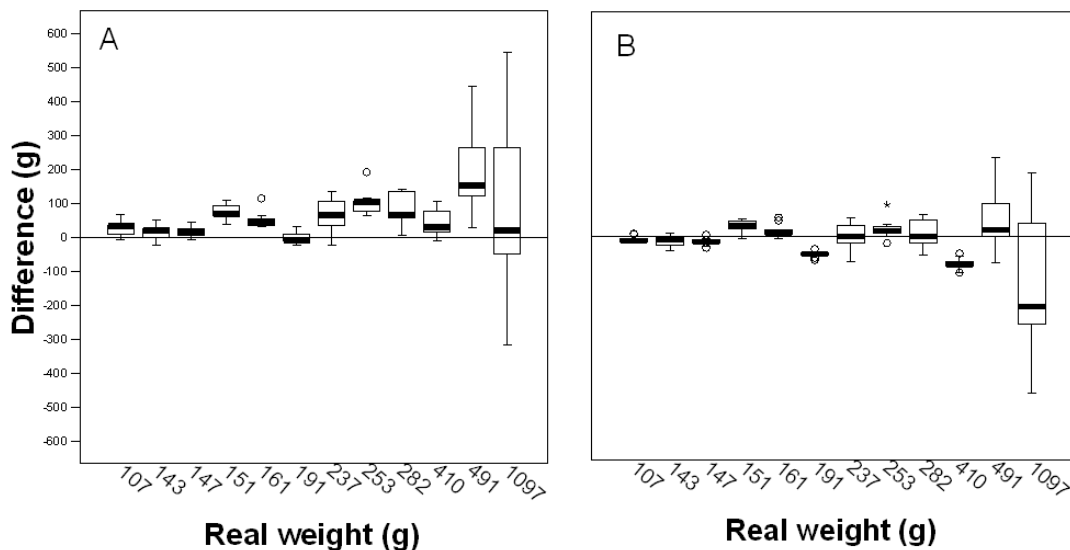
*Figure 4.* Effect of various concentrations of 1,25(OH)<sub>2</sub>D<sub>3</sub> (A and B) or 25(OH)D<sub>3</sub> (C and D) on myometrial and leiomyoma cells. Proliferation was determined using the colorimetric crystal violet assay after nine days of treatment with increasing doses of the two compounds as indicated. The values represent percentages of control standardized as 100 %. Six individual cultures were examined at each concentration (in 500 nM 25(OH)D<sub>3</sub>, n=4). Horizontal lines represent the median.

## 9.2 Accuracy of a combination formula in estimating the weight of the uterus and quality assurance of these measurements (II, III)

All preoperative measurements of the uterine corpus and cervix could be obtained with a transvaginal ultrasound probe except in two of the 12 patients, whose uteruses were the largest. Part of the measurements had to be taken transabdominally, as the ultrasound field of the vaginal probe was not wide enough to encompass the whole uterus in these patients.

### 9.2.1 Comparison of two different formulas and real uterine weight (II)

The differences between the real weight of the total uterus (corpus and cervix) and the weight calculated with the prolate ellipsoid formula and that calculated with the formula combining the prolate ellipsoid and cylinder formulas are presented in Figure 5. The plain formula for the prolate ellipsoid tends to overestimate the weight of the uterus. The new combination formula is more accurate in predicting the true total weight of the uterus, especially when the true weight is less than 500 g. The difference between the weight estimated by the prolate ellipsoid formula and the true weight was statistically significant among the three investigators on most measurement occasions. No significant differences were found when the combination formula was used. The greatest error between the formula combining the prolate ellipsoid and cylinder formulas and the true weight of the uterus was found only with the largest uterus.



*Figure 5.* Differences between the actual uterine weight and the estimated uterine weight calculated by traditional formula (A) and combination formula (B) in 12 subjects using a transvaginal ultrasound probe in evaluating the dimensions of the myomatous uterus. Medians (black line), interquartile ranges (box) and ranges (line bar) are given. Outliers and extreme findings are expressed as dots or stars. The boxplots express combined deviations of real weights of nine measurements.



As illustrated in Figure 6, there was a good correlation between the true weight of the hysterectomy specimen and the volume obtained from water displacement.

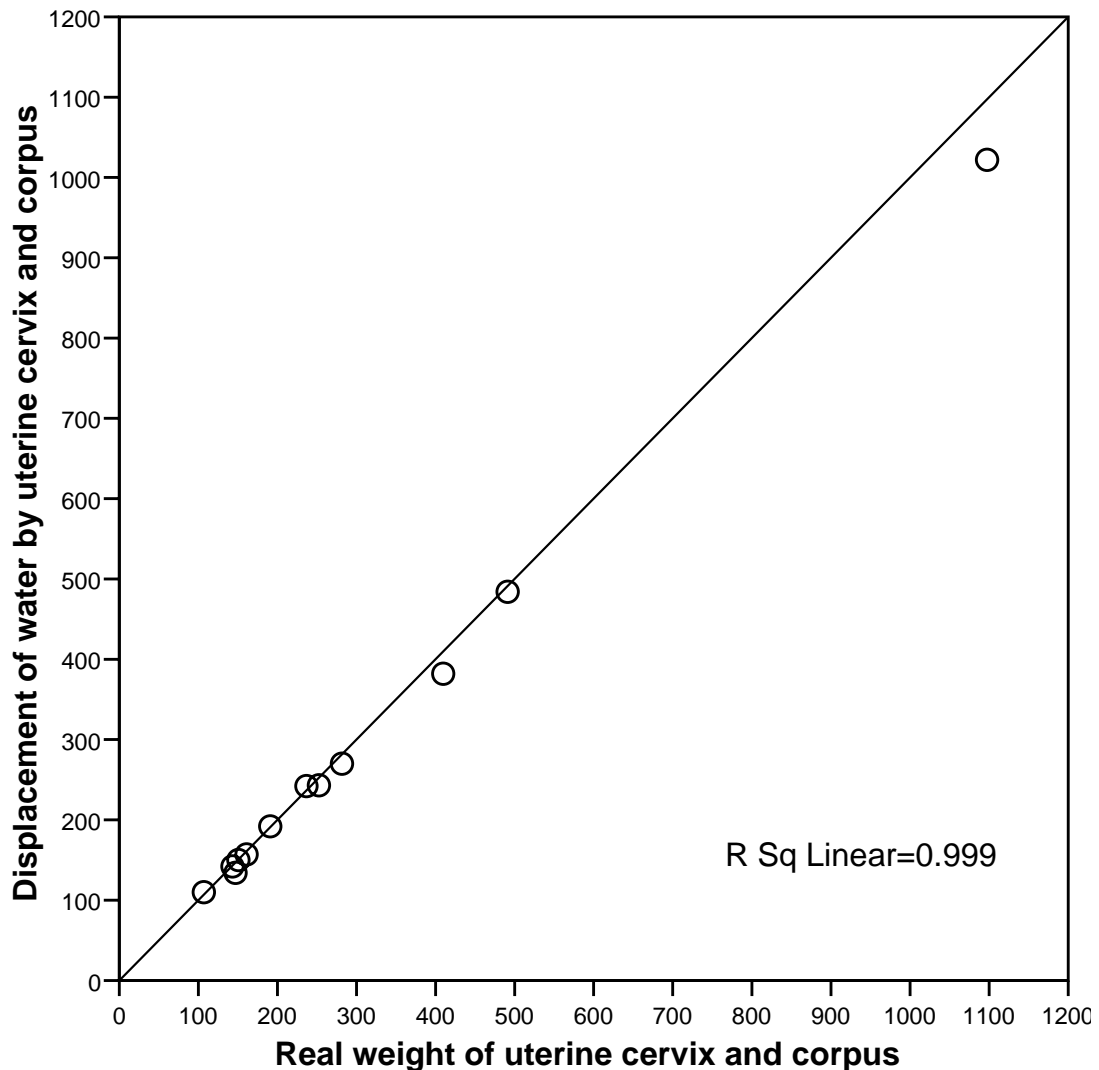


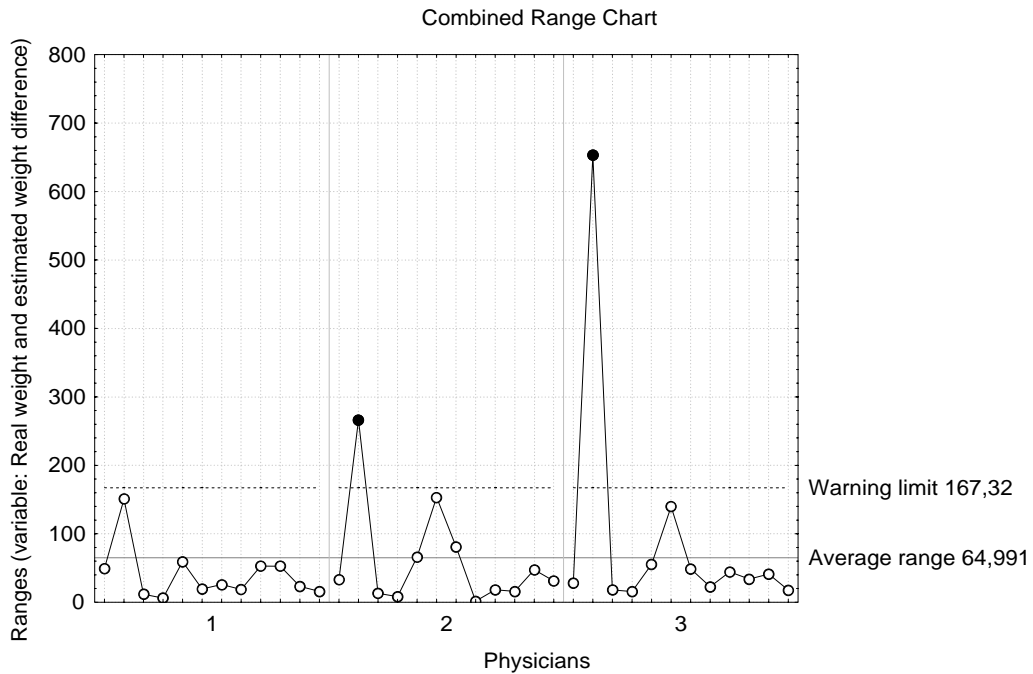
Figure 6. The real weight of the uterine cervix and corpus (grams) compared to the displacement of water by uterine cervix and corpus (n=12 patients).

### 9.2.2 Sources of variation (III)

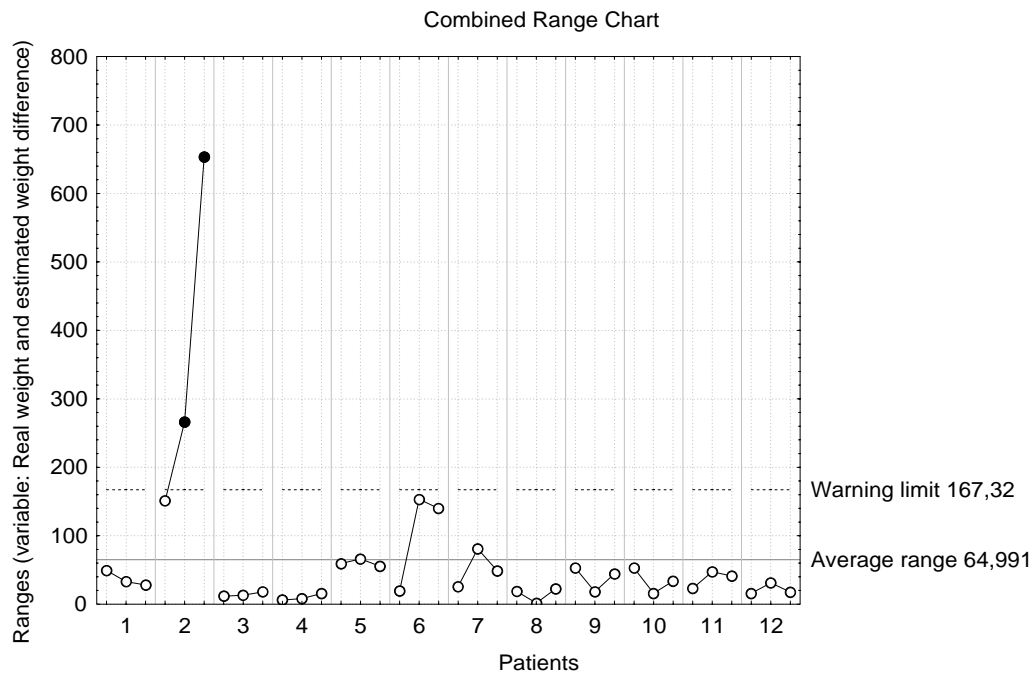
The difference error between real uterine weight and weight measured by ultrasound was 28 % due to combined R&R, consisting mainly of repeatability (variation across measurements), i.e. the physician failed to obtain completely the same measurement results from each three measuring round. The experience of the physician had no effect as variation due to physicians was < 1 %. Patient-to-patient variation, which was 72 %, was the greatest.

The largest uterus (patient 2) caused the most variation between estimated and real weight. The more experienced the physician was, the smaller was the variation,

and the more experienced the physician was in taking ultrasound measurements, the less variation there was between her own three measurements (Figure 7). The variation between real and estimated weight in patient 2 seemed to be higher than that in other patients, which also showed some dependence on the experience of the physician (Figure 8).



*Figure 7.* Combined range chart: physicians by patients for difference of real weight and estimated weight by combination formula. Patients are shown in study order by most experienced physician (1) to least experienced physician (3). The warning limit represents three times the standard deviation (99 % of observations were below the line).



*Figure 8.* Combined range chart: patients by physicians for difference of real weight by combination formula. Physicians are shown by most experienced to least experienced by patients shown in study order.

If the two patients with the largest uteruses (patients 2 and 6) are removed from the study, the variation in the measurements by all physicians varies very modestly. The variation between measurements (repeatability) falls to 22.4 % and combined R&R to 23.7 %, also including the increase in variation of 1.4 % between physicians (reproducibility). Thus the differences both between the three physicians and between their own measurements (average range 32 grams, warning limit 82 grams) decrease. The differences in the physicians' experience appear only in measurements of the largest uteruses.

### 9.3 Clinical effectiveness and safety of vaginal myomectomy by traction method (IV)

#### 9.3.1 Perioperative characteristics

Traction myomectomy was completed vaginally without laparotomy in all patients and no vaginal lacerations occurred. The right uterosacral ligament had to be cut in two patients for better vaginal access to the myoma and the ligament was sutured to the uterus after removal of the myoma. The mean weight of the removed

leiomyomas was 153 grams. The endometrial cavity opened in three cases during the operation. All patients had a single leiomyoma except for one, who underwent laparoscopic removal of an intraligamentary myoma prior to vaginal myomectomy.

The mean estimated operative blood loss was 385 mL (range 50-1000 mL) and four women received blood transfusions, including two with preoperative anemia.

There were no postoperative rehospitalizations. One patient developed a four cm anterior hematoma between the cervical uterus and the bladder, which did not require operative treatment. One patient with anterior and posterior colpotomy had macroscopic hematuria, which was resolved with one week's urinary catheter treatment.

### 9.3.2 Follow-up

There were no signs of leiomyoma recurrence during the follow-up period. The patients with menorrhagia reported improvement and those with abdominal pain proved asymptomatic. Three patients have conceived since the operation, including two normal vaginal deliveries and one cesarean section. The interval between operation and delivery was 16, 16 and 13 months and the duration of pregnancies 270, 294 and 271 days, respectively. One woman with secondary infertility had preoperatively achieved two pregnancies after assisted reproduction treatment; after myomectomy she conceived without treatment. No uterine rupture has been detected.

## 9.4 Hysterectomy rates after hysteroscopic endometrial resection with or without myomectomy (V)

### 9.4.1 Perioperative characteristics

The estimated blood loss was greater and the duration of the operation longer in patients undergoing myomectomy. One severe complication was encountered in this group. Uterine perforation occurred during myomectomy and led to profuse hemorrhage requiring an emergency hysterectomy. Otherwise complications were minor and were treated by antibiotics (intrauterine infection), with a Foley catheter (hemorrhage) or with a blood patch (postspinal headache).

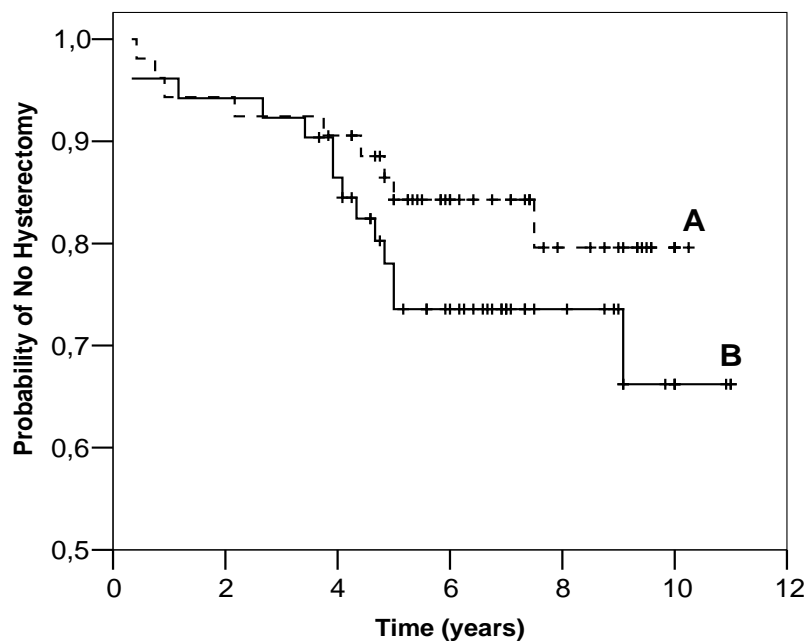
The hysteroscopic resection of a leiomyoma was complete in all cases except four (7.5 %).

The mean (SD) leiomyoma size was 2.1 (1.1) cm, ranging from one to five cm. Thirty-two (60.4 %) women had only one submucous leiomyoma and 21 had two or more.

## 9.4.2 Follow-up

Late complications occurred in seven (6.6 %) patients. Three women developed hematometra in both groups. After endometrial resection, one pregnancy occurred ending in spontaneous miscarriage with placenta accreta and subsequent hysterectomy. During the follow-up period, 18 (34.6 %) out of the 52 women with myomectomy and 21 (39.6 %) out of the 53 women without myomectomy underwent at least one gynecological procedure. Endometrial ablation was repeated in three cases in each group because of hematometra.

Hysterectomy was performed in 14 (26.9 %) cases with myomectomy and in nine (17.0 %) with endometrial resection only. A relationship between the probability of not requiring subsequent hysterectomy and the time since the endometrial resection procedure was shown in survival analysis in both groups (Figure 9). The difference between the groups did not reach statistical significance (log rank test,  $p=0.22$ ). The mean size (SD) of the myoma resected in hysteroscopy was 2.7 (1.3) cm in patients ending in hysterectomy and the same figure among patients without hysterectomy was 2.0 (1.0) cm ( $p=0.24$ ).



*Figure 9.* Probability of not needing hysterectomy in patients with endometrial resection without myomectomy (A), and in patients with endometrial resection and concomitant myomectomy (B). Kaplan-Meier curves are illustrated (log rank test,  $p=0.22$ ).

The main indications for subsequent hysterectomy were pain and spotting in seven out of 14 cases with hysteroscopic myomectomy and four out of nine patients with endometrial resection only, two with persistent menorrhagia or enlarged uterus in both groups, two with ovarian cyst in the myomectomy group. All the patients with incomplete myomectomy ended in hysterectomy during the follow-up period. One complication associated with hysteroscopic surgery occurred in one case with myomectomy and one case associated with a late consequence of endometrial resection (placenta accreta) indicated hysterectomy.

The mean weight of the uterus was 390 grams (range 140-1700 grams) in patients with myomectomy and 270 grams (120-800 grams) in those without. Leiomyomas were found in 12 out of 14 women undergoing hysterectomy after hysteroscopic myomectomy and in four out of nine with hysterectomy after endometrial resection ( $p=0.06$ ). Adenomyosis was confirmed in three and six cases, respectively. One patient with myomectomy had endometrial hyperplasia, but no cases of uterine malignancy were found.

Long-term follow-up data were available for 82 women who did not need hysterectomy. Most of them (75.6 %) had reached menopause. All patients in both groups reported amenorrhoea or slight bleeding, and this response persisted for years after the treatment.

# 10 DISCUSSION

Uterine leiomyomas are a problem commonly encountered in gynecology, and they impact substantially on women's health. Despite wide research in the area, the precise causes for the genesis and growth of these tumors remain unclear. New methods for the diagnosis and treatment of uterine leiomyomas have been developed during recent years. Ultrasound scanning with or without saline infusion, hysteroscopy or MRI can be used for the follow-up or preoperative evaluation of the size of the uterus and uterine leiomyomas. Surgery is still the mainstay treatment for these benign neoplasms, hysterectomy being the ultimate procedure. Myomectomy by various techniques, myolysis and laparoscopic uterine artery occlusion are alternative options. Uterine artery embolization and magnetic resonance guided focused ultrasound surgery represent nonsurgical treatment modalities. Hormonal treatment may be briefly used for relief of symptoms or be utilized preoperatively so as to reduce the uterine size and procedure-related blood loss.

In the present study, new aspects of the etiology, diagnostics and treatment of uterine leiomyomas were sought. The possible role of vitamin D was detected as an etiologic factor in the growth of leiomyoma and myometrial cells. A new geometrical combination formula for determining the weight of the myomatous uterus by transvaginal ultrasound was tested to facilitate the follow-up and preoperative evaluation of the uterus and leiomyomas. The quality of this formula was also assessed. A practical point of view was chosen, as the 2D vaginal ultrasonography probe is commonly available in gynecological clinics and widely used for the follow-up of uterine leiomyomas.

Two uterus-sparing surgical methods, vaginal myomectomy and hysteroscopic endometrial resection with or without myomectomy, were evaluated in the treatment of leiomyomas.

## 10.1 Vitamin D derivatives and the proliferation of leiomyoma cells

The cell growth-inhibiting role of vitamin D has been widely studied in various tissues, but there are no previous reports concerning the possible growth-modulatory effects of vitamin D on benign uterine tumor cells. Some clinical findings warrant such inquiry. In countries like Finland, which have seasonally low ultraviolet irradiation, vitamin D deficiency is common in the population (Kauppinen-Mäkelin et al. 2001, Lamberg-Allardt et al. 2001, Välimäki et al. 2004). Uterine leiomyomas are also common, as they are found in about 50 % of Finnish women undergoing

hysterectomy (Luoto et al. 1994). In the United States of America, hypovitaminosis D has been detected in 42 % of African-American women of reproductive age compared with 4 % in white women (Nesby-O'Dell et al. 2002) and the incidence of leiomyoma is approximately 2-3 times greater among African-American than among Caucasian women (Marshall et al. 1997, Baird et al. 2003). There is no explanation for this phenomenon. A correlation between skin pigmentation, solar exposure and vitamin D status has been found (Nesby-O'Dell et al. 2002, Holick 2004).

A study was conducted here to establish whether  $1,25(\text{OH})_2\text{D}_3$  and  $25(\text{OH})\text{D}_3$  vitamin D derivatives have some impact on the growth of leiomyoma and myometrial cells *in vitro*. The results show that primary or secondary cultures of both normal myometrial and leiomyoma cells are highly sensitive to the growth-inhibiting effect of  $1,25(\text{OH})_2\text{D}_3$ .  $1,25(\text{OH})_2\text{D}_3$  was able significantly to suppress the growth of both cell types at a concentration as low as 0.1 nM, which lies within the physiological concentration range (48-156 pM) of  $1,25(\text{OH})_2\text{D}_3$  (Lou et al. 2004). These results add to previous data on the inhibitory effect of  $1,25(\text{OH})_2\text{D}_3$  on primary cultures of human cells from various organs (Itin et al. 1994, Barreto et al. 2000, Lou et al. 2004).

In many cell types, low concentrations of  $1,25(\text{OH})_2\text{D}_3$  have been shown to stimulate rather than inhibit cell proliferation (Munker et al. 1986, Itin et al. 1994, Love-Schimenti et al. 1996, Miettinen et al. 2004). Here, however, 0.1nM concentration of  $1,25(\text{OH})_2\text{D}_3$  inhibited cell growth by as much as 12%, the percentage gradually increasing to over 60% with 100 nM  $1,25(\text{OH})_2\text{D}_3$ . Myometrial and leiomyoma cells are clearly target cells for  $1,25(\text{OH})_2\text{D}_3$ .

By contrast, the effects of the two lowest concentrations of  $25(\text{OH})\text{D}_3$  investigated were growth-promoting, as previously reported in primary cells of human prostatic epithelium (Barreto et al. 2000) and epidermis (Itin et al. 1994). The growth-inhibitory effect detected when a 500 nM or 1000 nM concentration of the metabolite was used may indicate local conversion of  $25(\text{OH})\text{D}_3$  to the active metabolite  $1,25(\text{OH})_2\text{D}_3$  (Zehnder et al. 2001, Evans et al. 2004).  $25(\text{OH})\text{D}_3$  itself may also function as an active hormone, its growth-modulating effects being mediated via direct binding to VDR (Lou et al. 2004).

Cell number was chosen as end point in the present study, as it sums up all potential effects of vitamin D on cell growth: cell cycle arrest, apoptosis, and regulation of growth factor signalling, thereby giving a straightforward insight into the efficacy of vitamin D action (Ylikomi et al. 2002). Further studies are required to show which of the numerous regulatory mechanisms are responsible for the precise growth-inhibitory effects of  $1,25(\text{OH})_2\text{D}_3$  and  $25(\text{OH})\text{D}_3$  in human myometrial and leiomyoma cells.

The present study revealed that vitamin  $1,25(\text{OH})_2\text{D}_3$  inhibited concentration-dependently the growth of myometrial and leiomyoma cells *in vitro*, and suppression was already detected at physiological vitamin D levels. Whether this also takes place *in vivo* remains to be studied. A link between vitamin D status and proliferative disorders of the myometrium *in vivo* is an intriguing clinical possibility. Hypovitaminosis D may have an important role in the etiology and growth of leiomyoma cells, but it is hardly the only predisposing factor in these



clonal smooth muscle tumors. More research is needed to ascertain whether women suffering from hypovitaminosis D also have more uterine leiomyomas than women with adequate vitamin D supplies.

## 10.2 Estimation of the size of the myomatous uterus

It is important to estimate the size of the uterus so as to exclude abnormal growth of this reproductive organ due to benign or malignant tumors. It is also an essential factor in assessing the method of hysterectomy most appropriate for the patient (Kovac 1995). A common practice is to estimate the size of the nongravid uterus by bimanual examination and compare it to a pregnant uterus of comparable size. However, only a rough estimate may be gained by this method (Flickinger et al. 1986), and other, more accurate means for the purpose have been developed.

Gynecological ultrasound and use of the geometric formula of the prolate ellipsoid have been the most common means of estimating the uterine dimensions (Grossman et al. 1982, Flickinger et al. 1986, Goldstein et al. 1988, Platt et al. 1990, Wiener and Newcombe 1992, Bakos et al. 1994, Kung and Chang 1996, Dekel et al. 1998). No formula combining the geometrical formulas of the prolate ellipsoid (uterine corpus) and cylinder (uterine cervix) to estimate total uterine weight has previously been used. A new approach to assessing the weight of the total uterus was here developed on this basis. The assumption was that if the weight of the uterine corpus (formula of a prolate ellipsoid) and the cervix (formula of a cylinder) are separately calculated and then summed, the result would be more accurate in comparison to the true total uterine weight than if only the traditional formula for a prolate ellipsoid had been used. Dumanli and associates (2000) measured both the anterior - posterior and transverse diameter of the cervix for the geometric formula and reported that the average difference between these diameters was less than 1 mm. Therefore, to simplify the method, only measurements of the anterior-posterior aspect of the uterine cervix diameter were obtained using the formula for a cylinder. The preliminary results proved that a combination of the two formulas is more accurate in predicting the true total weight of the uterus than the plain formula for the prolate ellipsoid. The largest uteruses caused greater error in comparison to their true weight than the smaller ones.

Platt and colleagues (1990) showed that the weight of a hysterectomy specimen correlated with the volume of the same specimen assessed by water displacement. In the present study, this finding was confirmed.

Non-pathological uteruses have mainly been the focus in earlier studies (Piiroinen 1975, Flickinger et al. 1986, Platt et al. 1990, Wiener and Newcombe 1992, Bakos et al. 1994). In the present study it was sought to establish whether the different formulas would be equally suitable in estimating the weight of myomatous uteruses. Patients with leiomyomas were chosen, as in clinical practice they present most frequently for evaluation of uterine size, e.g. in the context of determination of the surgical approach to be used in hysterectomy (Kovac 1995). Attention should be paid to the fact that the specific weight of the myoma tissue may differ from that of

the normal uterine wall, and as the true weight of the myomatous uterus increases, this may cause errors in calculations.

### 10.2.1 Quality control of a combination formula

As the combination formula for the prolate ellipsoid and cylinder was found to be more precise in predicting the true total weight of the myomatous uterus, a further assessment to test the quality of this new method was conducted. Quality assurance in health care is a process monitoring and evaluating the quality of care given to an individual patient, to a certain patient group or to a population, and assurance of low overall variation in the treatment process is crucial. In the analysis of industrial processes, the R&R method is widely applied (Duncan 1986), but studies utilizing this system in medicine are sparse.

In one study, eleven radiation oncologists planned radiotherapy three times for three different kinds of breast cancer patients without knowing that they were dealing with the same patient three times (Holli et al. 1999). There were some clearly outlying physicians, although interphysician variation was not high. The highest variation was in repeatability (intrapatient variation) and patient-to-patient variation accounted for the major part of the variation. Merce and associates (2005) established the intraobserver and interobserver reproducibility of the parameters of ovarian response and oocyte ability and the influence of ovarian functional stage. Twenty-nine women were examined by 3D ultrasonography and power Doppler angiography (PDA), and ovarian volume, follicle number, vascularization index, flow index, and vascularization-flow index were analyzed. Excellent intraobserver and interobserver reproducibility was shown for ovarian volume, follicle counts and 3D indices. Reliability was not influenced by ovarian functional stage.

Two sources of variation were identified in the present study: variation across trials (repeatability) and difference across physicians (reproducibility), and a combination of these. The more experienced the physician was in taking ultrasound measurements, the less variation there was between her own three measurements. Acceptable variation should be that caused by patients. In the ideal case interphysician variation, intrapatient variation and combined repeatability and reproducibility do not exceed 10%. In our study variation between the measurements of each physician approached 30%, which is still acceptable (Barrentine 1991). This may be an effect of the method of taking measurements by ultrasound, as the ultrasound probe has to be rotated from the sagittal plane to the coronal axis of the organ during measurement. During this rotative movement, the probe may depart slightly from its original position.

The two patients with the largest uteruses caused the most variation in estimated and real weight. The results may have been affected by the fact that the ultrasound field of the vaginal probe was not wide enough to encompass the whole mass of the myomatous uterus in these patients, and part of the measurements had to be taken with a transabdominal ultrasound probe. However, the penetration depth of a transabdominal probe differs from that of a transvaginal ultrasound probe (Lyons et

al. 1992), and in the case of a large myomatous uterus, it may be better to measure the uterine cervix with a transvaginal probe and the uterine corpus with a transabdominal probe. This method probably causes less variation between estimated and real weight than use of the vaginal ultrasound probe alone.

The study population was rather small, as there were only 12 patients. However, the total number of findings was 108, and a difference in level between the traditional ellipsoid formula and the combination formula in comparison with the actual weight of the myomatous uterus was established, despite the limitation of a small population size. At the beginning of the study, R&R method was chosen for the statistical analysis as the number of the patients was also sufficient for this assessment.

3D ultrasound creates precise volume measurements of objects of different shapes and offers improved accuracy compared to the 2D method (Riccabona et al. 1995, Kyei-Mensah et al. 1996). On the other hand, MRI is an excellent method to establish the number, position and size of uterine leiomyomas (Dueholm et al. 2001). 3D ultrasound and MRI could have been more accurate options in estimating the volume of the myomatous uterus, but the high price of the requisite equipment limits their overall use in gynecology. 2D vaginal ultrasonography probes are also commonly available in gynecological clinics.

The transvaginal ultrasound probe was shown to be a viable tool in establishing the dimensions of the uterus and cervix. The image is constituted near the object and obesity does not affect the quality of the view, in contrast to using the abdominal probe. The formulas for the prolate ellipsoid and cylinder could be easily inserted into the computer of the ultrasound device and used in daily clinical work for preoperative weight estimation of the uterus. Besides the usefulness of the combination formula in assessing the method of hysterectomy most appropriate for the patient, it may be utilized in follow-up of the size of a myomatous uterus. The present study showed that every investigator was able to obtain a reliable measurement of the volume of the uterus by ultrasound with this method. The experience of the physician had an effect on repeatability but not on reproducibility in estimating uterine weight by ultrasound. Experience diminished the variability between the investigator's own measurements. It is crucial to ensure high quality in health care, and these results indicate the importance of conscientiousness in taking measurements of the uterus and cervix.

### 10.3 Surgical treatments of uterine myomas

There are several surgical modalities for the treatment of uterine leiomyomas. In this study, attention focused on two different methods, as they serve as an option for women in opposite life situations. Myomectomy is the operation of choice for symptomatic women who wish to retain the potential for childbearing or for other reasons (Berkeley et al. 1983, Rosenfeld 1986, Smith and Uhler 1990). Hysteroscopic myomectomy with endometrial resection is indicated for women who

do not desire future pregnancies and do not want hysterectomy. On the other hand, both operations share the same uterus-sparing feature.

### 10.3.1 Clinical effectiveness and safety of vaginal myomectomy

As an alternative to hysterectomy or laparotomic or laparoscopic myomectomy, vaginal myomectomy can in certain cases be considered. A careful preoperative gynecological examination and evaluation of the myoma is important in selecting subjects for this treatment, as adequate vaginal access, good uterine mobility and a maximum myoma dimension of 11 cm are crucial for the method (Davies et al. 1999). Accurate mapping of the myoma, measuring its diameter and confirming that it is well-lined has to be performed by transvaginal ultrasound scanning. It is also important to ascertain by vaginal palpation the possibility to reach and bring the myoma to the colpotomy during the operation. Estimation of a myoma diameter over five cm and less than eight cm was considered suitable to pull through a colpotomy without vaginal laceration and damage to adjacent structures. Smaller leiomyomas are rarely an indication for myomectomy and it is difficult to fix the screw to them.

Results from ten patients confirm previous findings showing the feasibility of vaginal myomectomy by colpotomy (Magos et al. 1994, Davies et al. 1999, Agostini et al. 2004). This technique was refined for selected cases with a single myoma, using a method which utilizes screw traction and delivery of the myoma completely into the vagina. Traction of the myoma by screw involves extrusion of the fundal part of the uterus into the vagina without instrumental manipulation of the uterus. As by laparotomic route, enucleation of the myoma and closure of the uterine wall can be performed using conventional instruments. Morcellation and bisection of the myoma in colpotomy may be technically difficult in a narrow space, and bleeding may hamper visibility in the operation area, predisposing to injuries outside the myoma. The myoma screw has been utilized in laparoscopic and laparotomic myomectomies, but not as used in the present study.

Anterior colpotomy is more difficult to perform than posterior. Davies and associates (1999) reported that posterior colpotomy was the approach in 62.5 % (n=22), compared with seven (70 %) out of ten cases in the present study. Posterior colpotomy is technically the easier route, as there is more space for screw traction. We have no experience of using our technique in the case of fundal or lateral leiomyomas. Pelosi and Pelosi (1997) have described laparovaginal myomectomy to treat myomas located fundally or posteriorly.

A potential risk associated with myomectomy is the difficulty of achieving hemostasis (Buttram and Reiter 1981, Nezhat et al. 1998). The operative blood loss during myomectomy can be reduced by preoperative treatment with GnRH analogues (Friedman et al. 1989). In the present study the blood loss was heavier in the first cases but was reduced by practice and operations. There was no conversion to laparotomy and no serious complications occurred. Blood transfusions were given to four patients, two of them being anemic preoperatively. Pelvic hematoma has been the most common postoperative complication (11 %), involved in one case in

the study by Davies and associates (1999). As vaginal myomectomy may carry a potential for infectious morbidity (Pelosi and Pelosi 1997, Agostini et al. 2004), utilization of prophylactic antibiotics and thorough hemostasis to prevent hematoma of the pelvis are cornerstones in reducing the risk of pelvic infection

Agostini and colleagues (2008) evaluated the morbidity associated with vaginal myomectomy by posterior colpotomy in 108 women and detected 27 intra- or post-operative complications (25%). Conversion to laparotomy was required for successful myomectomy in 17 cases (15.7%). One case involved rectal injury (0.9%), three hemorrhages (2.8%), one hematoma (0.9%) and five abscesses (4.7%). The mean weight of fibromas was significantly higher in the group of patients undergoing laparotomy (19 cases) than in the vaginal myomectomy-only group (89 cases) ( $270 \pm 197\text{g}$  versus  $181 \pm 143\text{g}$ ,  $p=0.02$ ). The researchers concluded that the main risks of the procedure were the possible need for conversion and pelvic abscess. Otherwise the morbidity attending vaginal myomectomy was low.

The present study is limited of a low number of cases, as there were only ten patients. However, all women who had undergone vaginal myomectomy between January 2001 to March 2004 at the Department of Obstetrics and Gynecology, University Hospital of Tampere, Finland were included. The aim of the pilot study was to describe a novel traction modification of vaginal myomectomy and to assess the clinical effectiveness and safety of this method.

Vaginal traction myomectomy is a feasible approach. In the present study, all patients recovered uneventfully, which is in concord with data reported after laparoscopic myomectomy. Three women have delivered since the operation, which confirms that the uterine wall has healed and allowed the uterus to sustain pregnancy. As the uterine wall is firmly closed, the risk of uterine rupture may be reduced compared to laparoscopic myomectomy. Unlike myomectomy in laparotomy, laparoscopic myomectomy or laparoscopic-assisted transvaginal myomectomy, no skin incisions are needed. A single well-lined myoma with a diameter of five to eight cm and accessible via colpotomy is an optimal target for the procedure.

### 10.3.2 Hysteroscopic myomectomy associated with endometrial resection

Hysteroscopic surgery is a widely recognized alternative to hysterectomy in the treatment of patients suffering from menorrhagia (Abbott and Garry 2002), and submucous leiomyomas are common in these women (Nagele et al. 1996). There are reports of varying levels of success concerning the combination of endometrial ablation and myomectomy (Wortman and Daggett 1995, O'Connor and Magos 1996, Loffer 2005), but the long- term impact of this procedure is not well known. On this basis, a study was conducted involving patients with menorrhagia who did not desire any future pregnancies.

As subsequent hysterectomy was the only clear parameter examined, it was chosen as the endpoint of the study. Hysterectomy was avoided in 73.1 % of the women with endometrial resection and concomitant hysteroscopic myomectomy,

and in 83 % of those with only endometrial resection with a mean follow-up period of 6.5 years.

After endometrial resection, hysterectomy rates of 15-24 % have been reported with a follow-up period of four years or more (Aberdeen Endometrial Ablation Group 1999, Cooper et al. 2001, Boujida et al. 2002, Engelsen et al. 2006, Heinonen et al. 2006). In the present study, combination treatment did not significantly increase the hysterectomy rate (26.9 %) when compared with that (17.0 %) with plain endometrial resection. Pooley and associates (1998) showed a cumulative hysterectomy rate of five years in women with (25.7 %) and without (27.5 %) uterine fibroids in a survey of 380 women with menorrhagia treated with transcervical resection of the endometrium. The existence of myomas was found to be the only factor related to the increased possibility of subsequent hysterectomy after endometrial ablation-resection in a study by Comino and Torrejón (2004).

Studies concerning outcomes of endometrial resection with concomitant hysteroscopic myomectomy are few. Loffer (2005) reported long-term outcomes of women with hysteroscopic myomectomy with or without concomitant endometrial ablation. He presented a hysterectomy rate of 17.8 % among 73 women undergoing hysteroscopic myomectomy and endometrial ablation and a rate of 22.1 % among 104 women undergoing hysteroscopic myomectomy without endometrial ablation. Rates were not decreased by adding endometrial ablation to the resection of submucosal myomas. In the present study, all patients underwent endometrial resection and those with submucous myomas had concomitant hysteroscopic myomectomy. The results indicate that endometrial ablation/ resection may be combined with hysteroscopic myomectomy without a significant increase or decrease in hysterectomy rates during a long-term follow-up.

It is important to evaluate the realistic possibility of hysteroscopic myomectomy preoperatively by locating the presence of submucous myomas by transvaginal ultrasound scanning. Submucous leiomyomas have been found in 16-35 % of women with menorrhagia treated with endometrial resection (O'Connor and Magos 1996, Bøe Engelsen et al. 2006, Boujida et al. 2002, Heinonen et al. 2006, Comino and Torrejon 2004). Submucous myomas extending over 50 % into the uterine cavity were subjects for hysteroscopic surgery in the present study. Because the uterine cavity may be narrow and adhesive after endometrial resection, repeated myomectomy was avoided. Submucous leiomyomas protruding intramurally more than 50 % need repeat resection to achieve bleeding control, and are associated with more complications (Wamsteker et al. 1993). Van Dongen and colleagues (2006) found that incomplete hysteroscopic myomectomy without endometrial resection does not always necessitate subsequent surgery and a wait-and-see policy may be considered. It is probable that eventual necrosis and disappearance of the remaining portions of the myoma occur (Dueholm et al. 1998). In one study, subsequent hysterectomy rates were not increased by insufficient removals of myomas (Loffer 2005).

Both study groups reported slight menstrual bleeding or amenorrhea, this response persisting for years postoperatively. Because of the long follow-up period, most of the patients (75.6 %) meanwhile reached menopause. For this reason, the

true impact of the surgery on bleeding control was difficult to evaluate and the subsequent surgery was selected as the endpoint in the study.

The long-term impact seems to be permanent and endometrial resection with or without myomectomy does not merely postpone hysterectomy. Hysteroscopic myomectomy may be combined with endometrial resection in patients with pedunculated submucous or sessile submucous leiomyomas with intramural extension less than 50 % and smaller than five cm in diameter without a significant increase or decrease in hysterectomy rates during a long-term follow-up. The present study was limited by the low number of patients involved and further comparison with a larger population is warranted.

# 11 SUMMARY AND CONCLUSIONS

The present study was designed to examine the effects of two vitamin D derivatives on the growth of leiomyoma and myometrial cells *in vitro*, seeking possible etiologic factors underlying uterine leiomyomas. Furthermore, ultrasound diagnostics for these tumors were assessed: the accuracy of a formula combining the prolate ellipsoid and cylinder formulas in estimating the weight of the myomatous uterus prior to hysterectomy using transvaginal sonography was evaluated and different sources of variation in this process were analyzed. Two surgical uterus-sparing treatments for uterine leiomyomas were examined. The clinical effectiveness and safety of a novel traction modification of vaginal myomectomy was studied. Finally, hysterectomy rates after hysteroscopic endometrial resection with or without myomectomy for menorrhagia were compared and the long term outcomes of these two procedures established.

The main findings and conclusion of the study were:

1. Vitamin  $1,25(\text{OH})_2\text{D}_3$  effectively and concentration-dependently inhibits the growth of myometrial and leiomyoma cells *in vitro*. Both myometrial and leiomyoma cells are sensitive to  $1,25(\text{OH})_2\text{D}_3$ , as suppression is already detected at physiological vitamin D levels. Hypovitaminosis D may have a role in the etiology and growth of leiomyoma cells. Further clinical research is warranted to find out whether women with hypovitaminosis D also have more uterine leiomyomas than women with efficient vitamin D supplies.

2. A combination formula for the prolate ellipsoid and cylinder is more accurate in predicting the true total weight of the myomatous uterus than the prolate ellipsoid formula. The transvaginal ultrasound probe is a viable tool in assessing the dimensions of the uterus and cervix. The formulas for the prolate ellipsoid and cylinder could be easily inserted into the computer of the ultrasound device and used in daily clinical work for estimation of uterine weight.

3. The experience of the physician has an effect on repeatability (differences across measurements) but not on reproducibility (differences across physicians) in estimating uterine weight by ultrasound. The more experienced the physician is in taking ultrasound measurements, the less deviation is observed between her own three measurements. Every investigator is able to perform a reliable measurement of the volume of the uterus by ultrasound, but it is important to pay meticulous attention to detail in assessing the dimensions of reproductive organs.

4. Traction myomectomy by colpotomy is a feasible and safe treatment option for selected patients wishing to preserve their ability to conceive. A single well-lined myoma of 5-8 cm diameter and accessible via colpotomy is a suitable subject for the



procedure. No skin incisions are needed. The risk of uterine rupture may be lower than in laparoscopic myomectomy, as the uterine wall is firmly closed.

5. Hysteroscopic myomectomy may be combined with endometrial resection in patients with pedunculated submucous or sessile submucous leiomyomas with intramural extension less than 50 % and smaller than five cm in diameter without a significant increase or decrease in hysterectomy rates during a long-term follow-up. The combination treatment is a noteworthy alternative to hysterectomy in these selected cases.

# 12 ACKNOWLEDGEMENTS

This study was conducted at the Department of Obstetrics and Gynecology, Tampere University Hospital, Department of Cell Biology, School of Public Health and Medical School, University of Tampere, and Department of Obstetrics and Gynecology, Central Finland Central Hospital, Jyväskylä.

I wish to express my gratitude to Professor Pertti Kirkinen, Head of the Department of Obstetrics and Gynecology of Tampere University Hospital, for his kind encouragement and interest in my research.

I warmly and sincerely thank my brilliant supervisor, Professor Pentti Heinonen, M.D., Ph.D., who suggested to me the topic for investigation and patiently supported and guided me throughout the study. I have been deeply impressed by his broad clinical experience and enthusiastic attitude towards science. During the various stages of this work he always made himself available for questions and discussions.

I am very grateful to my co-authors, Tiina Luukkaala, M.Sc., for her friendly and skilled assistance in statistical analysis; Merja Bläuer, Ph.D., Riikka Helin, M.D., Sinikka Oksa, M.D., Helena Sundström, M.D., Ph.D., Maarit Vuoto, M.D., Ph.D., and Professor Timo Ylikomi, M.D., Ph.D., for their professional help and invaluable contribution to this study. I have had many life enriching moments with you.

Docent Ilkka Järvelä, M.D., Ph.D., and Professor Marjo Tuppurainen, M.D., Ph.D., who kindly agreed to be official reviewers of this thesis, are sincerely thanked for their careful review and valuable advice and criticism on the manuscript.

I owe a debt of gratitude to late Professor Pekka Laippala, Ph.D., who suggested to me the repeatability and reproducibility method for statistical analysis in study III, for his kind and constructive comments concerning my research work.

Special acknowledgements go to Mirja Hyppönen from the Department of Cell Biology for her excellent technical assistance. I also wish to thank Heini Huhtala, M.Sc., for her valuable statistical advice. I am grateful to the whole staff of the Department of Obstetrics and Gynecology in Tampere University Hospital, especially to the staff in the Operating Theatres of Gynecology for their kind help in collecting the study material.

I wish to thank Mr. Michael Freeman, B.A., for reviewing the language of the original publications and Mr. Robert MacGilleon, M.A., for linguistic corrections of this thesis.

I owe a special debt of gratitude to the honorable members of my thesis committee, Docent Tapio Kuoppala, M.D., Ph.D., and Kari Nieminen, M.D., Ph.D. Their humourous way of thinking and friendly encouragement has cheered me up several times at moments of disappointment.

Eija Tomás, M.D., Ph.D., and all the present and former colleagues at the Department of Obstetrics and Gynecology in Tampere University Hospital deserve my sincerest gratitude for their support and interest. My special acknowledgement belongs to Outi Palomäki, M.D., Ph.D., and Kati Tihtonen, M.D., Ph.D., for giving me so much precious, practical advice during this study. The singing colleagues in Toka Parkasu are also acknowledged for the refreshment and joy offered by music. I also want to thank all colleagues at the Department of Obstetrics and Gynecology in Central Finland Central Hospital for clinical training during my residency.

I warmly thank all the patients who participated in these studies and made this work possible.

I am very grateful to all my friends, especially Docent Jari Eskola and Professor Emerita Liisa Lautamatti for their ongoing support and kindness. You have helped me so many ways during these years. Jari's pancakes and Liisa's magic have been unquestionably effective in enlightening my spirit.

I wish to express most heartfelt thanks to my parents Ulla and Eero Tupala, for all their love and care throughout my life, and to my brother Juha-Pekka Tupala, my sister Hanna-Leena Parkkinen and her husband Juha-Matti, for their endless positiveness and also for excellent technical advice during my study.

Finally, my warmest and profoundest gratitude belongs to my dear husband, the Savonian-Karelian Bear Esa, and our wonderful children, Vilma, Helmi, Otso and still intrauterine inhabitant "Orvokki". You all have always brought me joy, encouragement and love, through good and bad times. You have also taught me what is the most important thing in the world.

This study was supported by grants from the competitive research funding of the Pirkanmaa Hospital District, the Medical Research Fund of Central Finland Central Hospital, the Research Fund of the Finnish Gynecological Association, the Emil Aaltonen Foundation and the Sector of Children and Women, Tampere University Hospital, which are all gratefully acknowledged.

# 13 REFERENCES

Abbas FM, Currie JL, Mitchell S, Osterman F, Rosenshein NB and Horowitz IR (1994): Selective vascular embolization in benign gynecologic conditions. *J Reprod Med* 39:492-496.

Abbott JA and Garry R (2002): The surgical management of menorrhagia. *Hum Reprod Update* 8:68-78.

Aberdeen Endometrial Ablation Trials Group (1999): A randomised trial of endometrial ablation versus hysterectomy for the treatment of dysfunctional bleeding: outcome at four years. *Br J Obstet Gynaecol* 106:360-366.

ACOG practice bulletin (2001): Surgical alternatives to hysterectomy in the management of leiomyomas. *Int J Gynaecol Obstet* 73:285-293.

ACOG Committee Opinion (2004): Uterine artery embolization. *Obstet Gynecol* 103:403-404.

Agency for Healthcare Research and Quality (2006): HCUPnet, National Inpatient Sample. Available at: <http://hcup.ahrq.gov/HCUPnet.asp>.

Agostini A, Deval B, Birsan A, Ronda I, Bretelle F, Roger V, Cravello L, Madelenat P and Blanc B (2004): Vaginal myomectomy using posterior colpotomy: feasibility in normal practice. *Eur J Obstet Gynecol Reprod Biol* 116:217-220.

Agostini A, Gerbeau S, Al Nakid M, Ronda I, Cravello L and Blanc B (2008): Complications of vaginal myomectomy by posterior colpotomy. *Eur J Obstet Gynecol Reprod Biol*: 138:100-104.

Ahonen MH, Tenkanen L, Teppo L, Hakama M and Tuohimaa P (2000a): Prostate cancer risk and prediagnostic serum 25-hydroxyvitamin D levels (Finland). *Cancer Causes Control* 11:847-852.

Ahonen MH, Zhuang YH, Aine R, Ylikomi T and Tuohimaa P (2000b): Androgen receptor and vitamin D receptor in human ovarian cancer: growth stimulation and inhibition by ligands. *Int J Cancer* 86:40-46.

Alam NA, Bevan S, Churchman M, Barclay E, Barker K, Jaeger EE, Nelson HM, Healy E, Pembroke AC, Friedmann PS, Dalziel K, Calonje E, Anderson J, August PJ, Davies MG, Felix R, Munro CS, Murdoch M, Rendall J, Kennedy S, Leigh IM, Kelsell DP, Tomlinson IP and Houlston RS (2001): Localization of a gene (MCUL1) for multiple cutaneous leiomyomata and uterine fibroids to chromosome 1q42.3-q43. *Am J Hum Genet* 68:1264-1269.

Altman D, Granath F, Cnattingius S and Falconer C (2007): Hysterectomy and risk of stress-urinary-incontinence surgery: nationwide cohort study. *Lancet* 370:1494-1499.

Apperly FR (1941): The relation of solar radiation to cancer mortality in North America. *Cancer Research* 1:191-195.

Arici A and Sozen I (2000): Transforming growth factor-beta3 is expressed at high levels in leiomyoma where it stimulates fibronectin expression and cell proliferation. *Fertil Steril* 73:1006-1011.

Audo I, Darjatmoko SR, Schlamp CL, Lokken JM, Lindstrom MJ, Albert DM and Nickells RW (2003): Vitamin D analogues increase p53, p21, and apoptosis in a xenograft model of human retinoblastoma. *Invest Ophthalmol Vis Sci* 44:4192-4199.

Baird DD and Dunson DB (2003): Why is parity protective for uterine fibroids? *Epidemiology* 14:247-250.

Baird DD, Dunson DB, Hill MC, Cousins D and Schectman JM (2003): High cumulative incidence of uterine leiomyoma in black and white women: ultrasound evidence. *Am J Obstet Gynecol* 188:100-107.

Baker AR, McDonnell DP, Hughes M, Crisp TM, Mangelsdorf DJ, Haussler MR, Pike, JW, Shine J and O'Malley BW (1988): Cloning and expression of full-length cDNA encoding human vitamin D receptor. *Proc Natl Acad Sci U S A* 85:3294-3298.

Bakos O, Lundkvist Ö, Wide L and Bergh T (1994): Ultrasonographical and hormonal description of the normal ovulatory menstrual cycle. *Acta Obstet Gynecol Scand* 73:790-796.

Barbieri RL, McShane PM and Ryan KJ (1986): Constituents of cigarette smoke inhibit human granulosa cell aromatase. *Fertil Steril* 46:232-236.

Barrentine L (1991): *Concepts for R&R Studies*. ASQC Quality Press, Milwaukee, Wisconsin.

Barreto AM, Schwarz GG, Woodruff R and Cramer SD (2000): 25-Hydroxyvitamin D<sub>3</sub>, the prohormone of 1,25-dihydroxyvitamin D<sub>3</sub>, inhibits the proliferation of primary prostatic epithelial cells. *Cancer Epidemiol Biomarkers Prev* 9:265-270.

Batra N, Khunda A and O'Donovan PJ (2004): Hysteroscopic myomectomy. *Obstet Gynecol Clin North Am* 31:669-685.

Becker R, Entezami M, Hese S, Vollert W, Loy V and Weizel HK (1994): Gynäkologische Sonographie II. Normalwerte der standardisierten Uterusbiometrie. *Ultraschall Klin Prax* 8:241-247.

Berkeley AS, DeCherney AH and Polan ML (1983): Abdominal myomectomy and subsequent fertility. *Surg Gynecol Obstet* 156:319-322.

Bernard G, Daraï E, Poncelet C, Benifla JL and Madelenat P (2000): Fertility after hysteroscopic myomectomy: effect of intramural myomas associated. *Eur J Obstet Gynecol Reprod Biol* 88:85-90.

Bessenay F, Cravello L, Roger V, Cohen D and Blanc B (1998): Myomectomie per vaginale. *Contracept Fertil Sex* 26:448-451.

Birsan A, Deval B, Detchev R, Poncelet C and Daraï E (2003): Vaginal and laparoscopic myomectomy for large posterior myomas: results of a pilot study. *Eur J Obstet Gynecol Reprod Biol* 110:89-93.

Blutt SE and Weigel NL (1999): Vitamin D and prostate cancer. *Proc Soc Exp Biol Med* 221:89-98.

Bøe Engelsen IB, Woie K and Hordnes K (2006): Transcervical endometrial resection: Long-term results of 390 procedures. *Acta Obstet Gynecol Scand* 85:82-87.

Boehm KD, Daimon M, Gorodeski IG, Sheean LA, Utian WH and Ilan J (1990): Expression of the insulin-like and platelet-derived growth factor genes in human uterine tissues. *Mol Reprod Dev* 27:93-101.

Bouillon R, Bischoff-Ferrari H and Willett W (2008): Vitamin D and health: perspectives from mice and man. *J Bone Miner Res* 7:974-979.

Bouillon R, Garmyn M, Verstuyft A, Segaert S, Casteels K and Mathieu C (1995): Paracrine role for calcitriol in the immune system and skin creates new therapeutic possibilities for vitamin D analogs. *Eur J Endo* 133:7-16.

Boujida VH, Philipsen T, Pelle J and Joergensen JC (2002): Five-year follow-up of endometrial ablation: endometrial coagulation versus endometrial resection. *Obstet Gynecol* 99:988-992.

Breech LL and Rock JA (2003): Leiomyomata uteri and myomectomy. In: *Te Linde's Operative Gynecology*, pp. 753-798. Eds. JA Rock and HW Jones, Lippincott Williams & Wilkins, Philadelphia.

Broder MS, Goodwin S, Chen G, Tang LJ, Costantino MM, Nguyen MH, Yegul TN and Erberich H (2002): Comparison of long-term outcomes of myomectomy and uterine artery embolization. *Obstet Gynecol* 100:864-868.

Broekmans FJ (1996): GnRH agonists for uterine leiomyomas. *Hum Reprod* 11(Suppl 3):3-25.

Brunner M, Obruca A, Bauer P and Feichtinger W (1995): Clinical application of volume estimation based on three-dimensional ultrasonography. *Ultrasound Obstet Gynecol* 6:358-361.

Buletti C, De Ziegler D, Polli V and Flamingi C (1999): The role of leiomyomas in infertility. *J Am Assoc Gynecol Laparosc* 6:441-445.

Buttram VC Jr. and Reiter RC (1981): Uterine leiomyomata: etiology, symptomatology and management. *Fertil Steril* 36:433-445.

Buttram VC Jr. and Snabes MC (1992): Indications for myomectomy. *Semin Reprod Endocrinol* 10:378-384.

Campo S and Carcea N (1999): Laparoscopic myomectomy in premenopausal women with and without preoperative treatment using gonadotrophin-releasing hormone analogues. *Hum Reprod* 14:44-48.

Campo S, Campo V and Gambadauro P (2005): Short-term and long-term results of resectoscopic myomectomy with and without pre-treatment with GnRH analogs in premenopausal women. *Acta Obstet Gynecol Scand* 84:756-760.

Cantuarria GH, Angioli R, Frost L, Duncan R and Penalver MA (1998): Comparison of bimanual examination with ultrasound examination before hysterectomy for uterine leiomyoma. *Obstet Gynecol* 92:109-112.

Candiani GB, Fedele L, Parazzini F and Villa L (1991): Risk of recurrence after myomectomy. *Br J Obstet Gynaecol* 98:385-389.

Carlson KJ, Nichols DH and Schiff I (1993): Indications for hysterectomy. *N Engl J Med* 328:856-60.

Carr BR, Marshburn PB, Weatherall PT, Bradshaw KD, Breslau NA, Byrd W, Roark M and Steinkampf MP (1993): An evaluation of the effect of gonadotropin-

releasing hormone analogs and medroxyprogesterone acetate on uterine leiomyomata volume by magnetic resonance imaging: a prospective, randomized, double-blind, placebo-controlled, crossover trial. *J Clin Endocrinol Metab* 76:1217-1223.

Chegini N, Zhao Y, Williams RS and Flanders KC (1994): Human uterine tissue throughout the menstrual cycle expresses transforming growth factor-beta 1 (TGF beta 1), TGF beta 2, TGF beta 3 and TGF beta type II receptor messenger ribonucleic acid and protein and contains [<sup>125</sup>I]TGF beta 1-binding sites. *Endocrinology* 135:439-449.

Chiaffarino F, Parazzini F, La Vecchia C, Chatenoud L, Di Cintio E and Marsico S (1999): Diet and uterine myomas. *Obstet Gynecol* 94:395-398.

Chou C-Y, Hsu K-F, Wang S-T, Huang S-C, Tzeng C-C and Huang K-E (1997): Accuracy of three-dimensional ultrasonography in volume estimation of cervical carcinoma. *Gynecol Oncol* 66:89-93.

Chuang J, Tsai HW and Hwang JL (2001): Fetal compression syndrome caused by myoma in pregnancy: a case report. *Acta Obstet Gynecol Scand* 80:472-473.

Chung AH, Jolesz FA and Hynynen K (1999): Thermal dosimetry of a focused ultrasound beam in vivo by magnetic resonance imaging. *Med Phys* 26:2017-2026.

Cobellis L, Pecori E and Cobellis G (2002): Hemostatic technique for myomectomy during cesarean section. *Int J Gynaecol Obstet* 79:261-262.

Colston KW, Berger U and Coombes RC (1989): Possible role for vitamin D in controlling breast cancer cell proliferation. *Lancet* 1:188-191.

Colston KW and Hansen CM (2002): Mechanisms implicated in the growth regulatory effects of vitamin D in breast cancer. *Endocr Relat Cancer* 9:45-49.

Comino R and Torrejon R (2004): Hysterectomy after endometrial ablation-resection. *J Am Assoc Gynecol Laparosc* 11(4):495-499.

Conley G and Lacey MD (1987): Benign Disorders of the Uterine Corpus. In: *Current Obstetric & Gynecologic Diagnosis & Treatment 1987*, p. 657. Eds. ML Pernoll and RC Benson, Appleton & Lange, Norwalk, Connecticut/Los Altos, California

Cook JD and Walker CL (2004): Treatment strategies for uterine leiomyoma: the role of hormonal modulation. *Semin Reprod Med* 22:105-111.

Cooper KG, Jack SA, Parkin DE and Grant AM (2001): Five-year follow up of women randomised to medical management or transcervical resection of the endometrium for heavy menstrual loss: clinical and quality of life outcomes. *Br J Obstet Gynaecol* 108:1222-1228.

Cooper NP and Okolo S (2005): Fibroids in pregnancy-common but poorly understood. *Obstet Gynecol Surv* 60:132-138.

Cotran SR, Kumar V and Robbins SL (1989): *Robbins Pathologic Basis of Disease*. WB Saunders Company, Philadelphia.

Coutinho EM (1990): Treatment of large fibroids with high doses of gestrinone. *Gynecol Obstet Invest* 30:44-47.

Cowan BD, Sewell PE, Howard JC, Arriola RM and Robinette LG (2002): Interventional magnetic resonance imaging cryotherapy of uterine fibroid tumors: preliminary observation. *Am J Obstet Gynecol* 186:1183-1187.

Cramer DW (1992): Epidemiology of myomas. *Semin Reprod Endocrinol* 10:320-324.

Cramer SF and Patel A (1990): The frequency of uterine leiomyomas. *Am J Clin Pathol* 94:435-438.

Cullinan-Bove K and Koos RD (1993): Vascular endothelial growth factor/vascular permeability factor expression in the rat uterus: rapid stimulation by estrogen correlates with estrogen-induced increases in uterine capillary permeability and growth. *Endocrinology* 133:829-837.

Daly DC, Walters CA, Prior JC, Kuslis ST, Chapitis J, Anderoli J and Riddick DH (1984): Prolactin production from proliferative phase leiomyoma. *Am J Obstet Gynecol* 148:1059-1063.

Daniell JF and Gurley LD (1991): Laparoscopic treatment of clinically significant symptomatic uterine fibroids. *J Gynecol Surg* 7:37-39.

David M and Ebert AD (2004): Treatment of uterine fibroids by embolization-Advantages, disadvantages, and pitfalls. *Eur J Obstet Gynecol Reprod Biol* 123:131-138.

Davies A, Hart R and Magos AL (1999): The excision of uterine fibroids by vaginal myomectomy: a prospective study. *Fertil Steril* 71:961-964.

Day Baird D, Dunson DB, Hill MC, Cousins D and Schectman JM (2003): High cumulative incidence of uterine leiomyoma in black and white women: ultrasound evidence. *Am J Obstet Gynecol* 188:100-107.

De Leo V, Morgante G, Lanzetta D, D'Antona D and Bertieri RS (1997): Danazol administration after gonadotrophin-releasing hormone analogue reduces rebound of uterine myomas. *Hum Reprod* 12:357-360.

De Leo V, la Marca A and Morgante G (1999): Short-term treatment of uterine fibromyomas with danazol. *Gynecol Obstet Invest* 47:258-262.

Dekel A, Farhi J, Levy T, Orvieto R, Shalev Y, Dicker D, Bar-Hava I and Ben-Rafael Z (1998): Preoperative ultrasonographic evaluation of nongravid, enlarged uteri-correlation with bimanual examination. *Eur J Obstet Gynecol Reprod Biol* 80:205-207.

DeLuca HF (1988): The vitamin D story: A collaborative effort of basic science and clinical medicine. *FASEB J* 2:224-236.

Dequesne J and Schmidt N (1998): Laser hysteroscopic resection of fibroids. In: *Endoscopic Surgery for Gynecologists*, pp. 534-539. Eds. C Sutton and M Diamond, WB Saunders, London.

Derman SG, Rehnstrom J and Neuwirth RS (1991): The long term effectiveness of hysteroscopic treatment of menorrhagia and leiomyomas. *Obstet Gynecol* 77:591-594.

DeWaay DJ, Syrop CH, Nygaard IE, Davis WA and Van Voorhis BJ (2002): Natural history of uterine polyps and leiomyomata. *Obstet Gynecol* 100:3-7.

Dietterich C, Check JH, Choe JK, Nazari A and Fox F (2000): The presence of small uterine fibroids not distorting the endometrial cavity does not adversely affect conception outcome following embryo transfer in older recipients. *Clin Exp Obstet Gynecol* 27:168-170.

Dilts PV Jr., Hopkins MP, Chang AE and Cody RL (1991): Rapid growth of leiomyoma in patient receiving tamoxifen. *Am J Obstet Gynecol* 166:167-168.



Dixon D, He H and Haseman JK (2000): Immunohistochemical localization of growth factors and their receptors in uterine leiomyomas and matched myometrium. *Environ Health Perspect* 108(suppl 5):795-802.

Donnez J and Jadoul P (2002): What are the implications of myomas on fertility? A need for a debate? *Hum Reprod* 17:1424-1430.

Dubuisson JB, Chapron C and Levy L (1996): Difficulties and complications of laparoscopic myomectomy. *J Gynaecol Surg* 12:159-165.

Dubuisson JB, Fauconnier A, Chapron C, Kreiker G and Norgaard C (1998): Second look after laparoscopic myomectomy. *Hum Reprod* 15:2102-2106.

Dubuisson JB, Fauconnier A, Babaki-Fard K and Chapron C (2000a): Laparoscopic myomectomy: a current view. *Hum Reprod Update* 6:588-594.

Dubuisson JB, Fauconnier A, Deffarges JV, Norgaard C, Kreiker G and Chapron C (2000b): Pregnancy outcome and deliveries following laparoscopic myomectomy. *Hum Reprod* 15:869-873.

Dubuisson JB, Fauconnier A, Fourchette V, Katayoun B-F, Coste J and Charpon C (2001): Laparoscopic myomectomy: predicting the risk of conversion to an open procedure. *Hum Reprod* 16:1726-1731.

Dudiak CM, Turner DA, Patel SK, Archie JT, Silver B and Norusis M (1988): Uterine leiomyomas in the infertile patient: preoperative localization with MR imaging versus US and hysterosalpingography 167:627-630.

Dueholm M, Forman A and Ingerslev J (1998): Regression of residual tissue after incomplete resection of submucous myomas. *Gynaecol Endosc* 7:309-314.

Dueholm M, Lundorf E, Hansen ES, Ledertoug S and Olesen F (2001): Evaluation of the uterine cavity with magnetic resonance imaging, transvaginal sonography, hysterosonographic examination, and diagnostic hysteroscopy. *Fertil Steril* 76:350-357.

Dueholm M, Lundorf E, Hansen ES, Ledertoug S and Olesen F (2002): Accuracy of magnetic resonance imaging and transvaginal ultrasonography in the diagnosis, mapping and measurement of uterine myomas. *Am J Obstet Gynecol* 186:409-415.

Dumanli H, Fielding JR, Gering DT and Kikinis R (2000): Volume assessment of the normal female cervix with MR imaging: Comparison of the segmentation technique and two geometric formulas. *Acad Radiol* 7:502-505.

Duncan AJ (1986): *Quality control and industrial statistics*. Homewood, Irwin, Illinois.

Dwyer N, Hutton J and Stirrat GM (1993): Randomised controlled trial comparing endometrial resection with abdominal hysterectomy for the surgical treatment of menorrhagia. *Br J Obstet Gynaecol* 100:237-243.

Eisinger SH, Bonfiglio T, Fiscella K, Meldrum S and Guzick DS (2005): Twelve-month safety and efficacy of low-dose mifepristone for uterine myomas. *J Minim Invasive Gynecol* 12:227-233.

Elder-Geva T, Meagher S, Healy DL, Maclachlan V, Breheny S and Wood C (1998): Effect of intramural, subserosal, and submucosal uterine fibroids on the outcome of assisted reproductive technology treatment. *Fertil Steril* 70:687-691.

Emanuel MH and Wamsteker K (2005): The Intra Uterine Morcellator: a new hysteroscopic operating technique to remove intrauterine polyps and myomas. *J Minim Invasive Gynecol* 12:62-66.

Englund K, Blanck A, Gustavsson I, Lundkvist U, Sjoblom P, Norgren A and Lindblom B (1998): Sex steroid receptors in human myometrium and fibroids: changes during the menstrual cycle and gonadotropin-releasing hormone treatment. *J Clin Endocrinol Metab* 83:4092-4096.

Evans KN, Bulmer JN, Kilby MD and Hewison M (2004): Vitamin D and placental-decidual function. *J Soc Gynecol Investig* 5:263-271.

Evans KN, Nguyen L, Chan J, Innes BA, Bulmer JN, Kilby MC and Hewison M (2006): Effects of 25-hydroxyvitamin D3 and 1,25-dihydroxyvitamin D3 on cytokine production by human decidual cells. *Biol Reprod* 75:816-822.

Evidence Report/Technology Assessment: Number 34. AHRQ publication No. 01-E051, January (2001): Management of Uterine Fibroids. Summary. Agency for Healthcare Research and Quality, Rockville, MD. <http://www.ahrq.gov/clinic/epcsums/utersumm.htm>.

Farhi J, Ashkenazi J, Feldberg D, Dicker D, Orvieto R and Ben Rafael Z (1995): Effect of uterine leiomyomata on the results of in-vitro fertilization treatment. *Hum Reprod* 10:2576-2578.

Farrer-Brown G, Beilby JO and Tarbit MH (1970): The vascular patterns in myomatous uteri. *J Obstet Gynaecol Br Commonw* 77:967-975.

Farrer-Brown G, Beilby JO and Tarbit MH (1971): Venous changes in the endometrium of myomatous uteri. *Obstet Gynecol* 38:743-751.

Fayed YM, Tsibris JC, Langenberg PW and Robertson AL Jr. (1989): Human uterine leiomyoma cells: binding and growth responses to epidermal growth factor, platelet-derived growth factor, and insulin. *Lab Invest* 60:30-37.

Fedele L, Parazzini F, Luchini L, Mezzopane R, Tozzi L and Villa L (1995): Recurrence of fibroids after myomectomy: a transvaginal ultrasonographic study. *Hum Reprod* 10:1795-1796.

Feinberg EC, Larsen FW, Catherino WH, Zhang J and Armstrong AY (2006): Comparison of assisted reproductive technology utilization and outcomes between Caucasian and African American patients in an equal-access-to-care setting. *Fertil Steril* 85:888-894.

Felberbaum RE, Germer U, Ludwig M, Riethmüller-Winzen H, Heise S, Buttge I, Bauer O, Reissmann T, Engel J and Diedrich K (1998): Treatment of uterine fibroids with a slow-release formulation of the gonadotrophin releasing hormone antagonist Cetrorelix. *Hum Reprod* 13:1660-1668.

Ferenczy A, Richart RM and Okagaki TA (1971): A comparative ultrastructural study of leiomyosarcoma, cellular leiomyoma and leiomyoma of the uterus. *Cancer* 28:1004-1014.

Fernandez H, Sefrioui O, Virelizier C, Gervaise A, Gomel V and Frydman R (2001): Hysteroscopic resection of submucosal myomas in patients with infertility. *Hum Reprod* 16:1489-1492.

Fiscella K, Eisinger SH, Meldrum S, Feng C, Fisher SG and Guzick DS (2006): Effect of mifepristone for symptomatic leiomyomata on quality of life and uterine size: a randomised controlled trial. *Obstet Gynecol* 108:1381-1387.

Flickinger LD, D'Ablaing G and Mishell DR (1986): Size and weight determinations of nonpregnant, enlarged uteri. *Obstet Gynecol* 68:855-858.

Folkerd EJ, Newton CJ, Davidson K, Anderson MC and James VH (1984): Aromatase activity in uterine leiomyomata. *J Steroid Biochem* 20:1195-1200.

Frampton RJ, Omond SA and Eisman JA (1983): Inhibition of human cancer cell growth by 1.25-dihydroxyvitamin D<sub>3</sub> metabolites. *Cancer Res* 43:4443-4447.

Friedman AJ, Barbieri RL, Doubilet PM, Fine C and Schiff I (1988): A randomized, double-blind trial of a gonadotropin releasing-hormone agonist (leuprolide) with or without medroxyprogesterone acetate in the treatment of leiomyomata uteri. *Fertil Steril* 49:404-409.

Friedman AJ, Harrison-Atlas D, Barbieri RL, Benacerraf B, Gleason R and Schiff I (1989): A randomized, placebo-controlled, double-blind study evaluating the efficacy of leuprolide acetate depot in the treatment of uterine leiomyomata. *Fertil Steril* 51:251-256.

Friedman AJ, Hoffman DI, Comite F, Browneller RW and Miller JD (1991): Treatment of leiomyomata uteri with leuprolide acetate depot: a double-blind, placebo-controlled, multicenter study. The Leuprolide Study Group. *Obstet Gynecol* 77:720-725.

Friedman AJ, Daly M, Juneau-Norcross M, Gleason R, Rein MS and LeBoff M (1994): Long-term medical therapy for leiomyomata uteri: a prospective, randomised study of leuprolide acetate depot plus either oestrogen-progestin or progestin "add-back" for 2 years. *Hum Reprod* 9:1618-1625.

Friedrich M, Meyberg R, Axt-Fliedner R, Villena-Heinsen C, Tilgen W, Schmidt W and Reichrath J (2002): Vitamin D receptor (VDR) expression is not a prognostic factor in cervical cancer. *Anticancer Res* 22:299-304.

Frigo P, Eppel W, Asseryanis E, Sator M, Golaszewski T, Gruber O, Lang C and Huber J (1995): The effects of hormone substitution in depot form on the uterus in a group of 50 perimenopausal women-a vaginosonographic study. *Maturitas* 21:221-225.

Fujimoto J, Hori M, Ichigo S and Tamaya T (1997): Ovarian steroids regulate the expression of basic fibroblast growth factor and its mRNA in fibroblasts derived from uterine endometrium. *Ann Clin Biochem* 34:91-96.

Garcia CR and Tureck RW (1984): Submucosal leiomyomas and infertility. *Fertil Steril* 42:16-19.

Garcia CR, Pfeifer SM (1993): Myomectomy. In: *Gynecologic and Obstetric Surgery*, p. 606. Ed. DH Nichols, Mosby, St. Louis.

Garland CF, Comstock GW, Garland FC, Helsing KJ, Shaw EK and Gorham ED (1989): Serum hydroxyvitamin-25 D and colon cancer: eight-year prospective study. *Lancet* 2:1176-1178.

Garland FC, Garland CF, Gorham ED and Young JF (1990): Geographic variation in breast cancer mortality in the United States: a hypothesis involving exposure to solar radiation. *Prev Med* 19:614-622.

Garnet JD (1964): Uterine rupture during pregnancy. An analysis of 133 patients. *Obstet Gynecol* 23:898-905.

Gianaroli L, Gordts S, D'Angelo A, Magli MC, Brosens I, Cetera C Campo R and Ferraretti AP (2005): Effect of inner myometrium fibroid on reproductive outcome after IVF. *Reprod Biomed Online* 10:473-477.

Goldberg J, Pereira L and Berghella V (2002): Pregnancy rate after uterine artery embolization. *Obstet Gynecol* 100:869-872.

Goldberg J, Pereira L, Berghella V, Diamond J, Daraï E, Seiner P and Seracchioli R (2004): Pregnancy outcomes after treatment for fibromyomata: uterine artery embolization versus laparoscopic myomectomy. *Am J Obstet Gynecol* 191:18-21.

Goldenberg M, Sivan E, Sharabi Z, Bider R, Rabinovici J and Seidman DS (1995): Outcome of hysteroscopic resection of submucous myomas for infertility. *Fertil Steril* 64:714-716.

Goldfarb HA and Fanarjian NJ (2001): Laparoscopic-assisted vaginal myomectomy: a case report and literature review. *JLS* 5:81-85.

Goldstein SR, Horii SC, Snyder JR, Raghavendra BN and Subramanyam B (1988): Estimation of nongravid uterine volume based on nomogram of gravid uterine volume: Its value in gynecologic uterine abnormalities. *Obstet Gynecol* 72:86-90.

Gomel V and Taylor PJ (1995): Diagnostic and operative gynaecologic laparoscopy. Mosby, St. Louis.

Goto A, Takeuchi S, Sugimura K and Maruo T (2002): Usefulness of Gd-DTPA contrast-enhanced dynamic MRI and serum determination of LDH and its isozymes in the differential diagnosis of leiomyosarcoma from degenerated leiomyoma of the uterus. *Int J Gynecol Cancer* 12:354-361.

Graham MJ Jr (1985): The association between limb anomalies and spatially-restricting uterine environments. *Prog Clin Biol Res* 163C:99-103.

Grant WB (2002): An estimate of premature cancer mortality in the U.S. due to inadequate doses of solar ultraviolet-B radiation. *Cancer* 94:1867-1875.

Grossman M, Flynn JJ, Aufrichtig D and Handler CR (1982): Pitfalls in ultrasonic determination of total intrauterine volume. *J Clin Ultrasound* 10:17-20.

Gutmann JN and Corson SL (2005): GnRH agonist therapy before myomectomy or hysterectomy. *J Minim Invasive Gynecol* 12:529-537.

Hager G, Formanek M, Gedlicka C, Thurnher D, Knerer B and Kornfehl J (2001): 1,25(OH)<sub>2</sub> vitamin D<sub>3</sub> induces elevated expression of the cell cycle-regulating genes P21 and P27 in squamous carcinoma cell lines of the head and neck. *Acta Otolaryngol* 121:103-109.

Hald K, Langebrette A, Klow NE, Noreng JN, Berge BA and Istre O (2004): Laparoscopic occlusion of uterine vessels for the treatment of symptomatic fibroids: Initial experience and comparison to uterine artery embolization. *Am J Obstet Gynecol* 190:37-43.

Hald K, Klow NE, Qvigstad E and Istre O (2007): Laparoscopic occlusion compared with embolization of uterine vessels. *Obstet Gynecol* 109:20-27.

Hanchette CL and Schwartz GC (1992): Geographic patterns of prostate cancer mortality. Evidence for a protective effect of ultraviolet radiation. *Cancer* 70:2861-2869.

Harlow BL, Weiss NS and Lofton S (1986): The epidemiology of sarcomas of the uterus. *JNCI* 76:399-402.

Harrison-Woolrych ML, Charnock-Jones DS and Smith SK (1994): Quantification of messenger ribonucleic acid for epidermal growth factor in human

myometrium and leiomyomata using reverse transcriptase polymerase chain reaction. *J Clin Endocrinol Metab* 78:1179-1184.

Harrison-Woolrych ML, Sharkey AM, Charnock-Jones DS and Smith K (1995): Localization and quantification of vascular endothelial growth factor messenger ribonucleic acid in human myometrium and leiomyomata. *J Clin Endocrinol Metab* 80:1853-1858.

Hart R, Khalaf Y, Yeong CT, Seed P, Taylor A and Braude P (2001): A prospective controlled study of the effect of intramural uterine fibroids on the outcome of assisted conception. *Hum Reprod* 16:2411-2417.

Hashimoto K, Azuma C, Kamiura S, Kimura T, Nobunaga T, Kanai T, Sawada M, Noguschi S and Saji F (1995): Clonal determination of uterine leiomyomas by analyzing differential inactivation of the X-chromosome-linked phosphoglycerokinase gene. *Gynecol Obstet Invest* 40:204-208.

Haussler MR, Whitfield GK, Haussler CA, Hsieh JC, Thompson PD, Selznick SH, Dominguez CE and Jurutka PW (1998): The nuclear vitamin D receptor: biological and molecular regulatory properties revealed. *J Bone Miner Res* 13:325-349.

Heinonen PK, Helin R and Nieminen K (2006): Long-term impact and risk factors for hysterectomy after hysteroscopic surgery for menorrhagia. *Gynecol Surg* 3:265-269.

Hendrickson MR and Kempson RL (1995): Pure mesenchymal neoplasms of the uterine corpus. In: Haines and Taylor *Obstetrical and Gynaecological Pathology*, p. 519. Eds. H Fox and M Wells, Churchill Livingstone, New York.

Hewison M, Zehnder D, Bland R and Stewart PM (2000): 1 $\alpha$ -hydroxylase and the action of vitamin D. *J Mol Endocrinol* 25:141-148.

Hewison M, Gacad MA, Lemire J and Adams JS (2001): Vitamin D as a cytokine and hematopoietic factor. *Rev Endocr Metab Disord* 2:217-227.

Hewison M, Zehnder D, Chakraverty R and Adams JS (2004): A novel role for extra-renal 1 $\alpha$ -hydroxylase. *Mol Cell Endocrinol* 215:31-38.

Hillis SD, Marchbanks PA and Peterson HB (1996): Uterine size and the risk of complications among women undergoing abdominal hysterectomy for leiomyomas. *Obstet Gynecol* 87:415-419.

Holick MF (2004): Vitamin D: importance in the prevention of cancers, type 1 diabetes, heart disease, and osteoporosis. *Am J Clin Nutr* 79:362-371.

Holli K, Laippala P, Ojala A and Pitkänen M (1999): Quality control in health care: an experiment in radiotherapy planning for breast cancer patients after mastectomy. *Int J Radiat Oncol Biol Phys* 44:827-833.

Hricak H, Tscholakoff D, Heinrichs L, Fisher MR, Dooms GC, Reinhold C and Jaffe RB (1986): Uterine leiomyomas: correlation of MR, histopathologic findings, and symptoms. *Radiology* 158:385-391.

Hubacher D and Grimes DA (2002): Noncontraceptive health benefits of intrauterine devices: a systematic review. *Obstet Gynecol Surv* 57:120-128.

Hunt JE and Wallach EE (1974): Uterine factors in infertility-an overview. *Clin Obstet Gynecol* 17:44-64.

Hurskainen R, Teperi J, Rissanen P, Aalto AM, Grenman S, Kivelä A, Kujansuu E, Vuorma S, Yliskoski M and Paavonen J (2004): Clinical outcomes and costs with

the levonorgestrel-releasing intrauterine system or hysterectomy for treatment of menorrhagia: randomized trial 5-year follow-up. *JAMA* 291:1456-1463.

Hutchins FL Jr. (1995a): Uterine fibroids. Diagnosis and indications for treatment. *Obstet Gynecol Clin North Am* 22:659-664.

Hutchins FL Jr. (1995b): Uterine fibroids. Abdominal myomectomy as a treatment for symptomatic uterine fibroids. *Obstet Gynecol Clin North Am* 22:781-789.

Hutchins FL Jr., Worthington-Kirsch RL and Berkowitz RP (1999): Selective uterine artery embolization as primary treatment for symptomatic leiomyomata uteri. *J Am Assoc Gynecol Laparosc* 6:279-284.

Hyder SM, Huang JC, Nawaz Z, Boettger-Tong H, Mäkelä S, Chiappetta C and Stancel GM (2000): Regulation of vascular endothelial growth factor expression by estrogens and progestins. *Environ Health Perspect* 108(suppl 5):785-790.

Hynynen K, Freund WR, Cline HE, Chung AH, Watkins RD, Vetro JP and Jolesz FA (1996): A clinical, noninvasive, MR imaging-monitored ultrasound surgery method. *Radiographics* 16:185-195.

Itin PH, Pittelkow MR and Kumar R (1994): Effects of vitamin D metabolites on proliferation and differentiation of cultured human epidermal keratinocytes grown in serum-free or defined culture medium. *Endocrinology* 135:1793-1798.

Iverson RE Jr., Chelmow D, Strohbehm K, Waldman L and Evantash EG (1996): Relative morbidity of abdominal hysterectomy and myomectomy for management of uterine leiomyomas. *Obstet Gynecol* 88:415-419.

Jirecek S, Lee A, Pavo I, Crans G, Eppel W and Wenzl R (2004): Raloxifene prevents the growth of uterine leiomyomas in premenopausal women. *Fertil Steril* 81:132-136.

Jones G, Strugnell SA and DeLuca HF (1998): Current understanding of the molecular actions of vitamin D<sub>3</sub>. *Physiol Rev* 78:1193-1231.

Jones WJ Jr. and Jones GS (1981): *Novak's Textbook of Gynecology*. Williams & Wilkins, Baltimore.

Joo JG, Inovay J, Silhavy M and Papp Z (2001): Successful enucleation of a necrotizing fibroid causing oligohydramnios and fetal postural deformity in the 25th week of gestation. A case report. *J Reprod Med* 46:923-925.

Jun SH, Ginsurg ES, Racowsky C, Wise LA and Hornstein MD (2001): Uterine leiomyomas and their effect on in vitro fertilization outcome. *J Assist Reprod Genet* 18:139-143.

Kang J, Baxi L and Heller D (1996): Tamoxifen-induced growth of leiomyomas. A case report. *J Reprod Med* 41:119-120.

Kauppinen-Mäkelin R, Tähtelä R, Löyttyniemi E, Kärkkäinen J and Välimäki MJ (2001): A high prevalence of hypovitaminosis D in Finnish medical in- and outpatients. *J Intern Med* 249:559-563.

Kawaguchi K, Fujii S, Konishi I, Okamura H and Mori T (1985): Ultrastructural study of cultured smooth muscle cells from uterine leiomyoma and myometrium under the influence of sex steroids. *Gynecol Oncol* 21:32-41.

Kawaguchi K, Fujii S, Konishi I, Nanbu Y, Nonogaki H and Mori T (1989): Mitotic activity in uterine leiomyomas during the menstrual cycle. *Am J Obstet Gynecol* 160:637-641.

Kiuru M, Launonen V, Hietala M, Aittomäki K, Vierimaa O, Salovaara R, Arola J, Pukkala E, Sistonen P, Herva R and Aaltonen LT (2001): Familial cutaneous leiomyomatosis is a two-hit condition associated with renal cell cancer of characteristic histopathology. *Am J Pathol* 159:825-829.

Kjerulff KH, Langenberg P, Seidman JD, Stolley PD and Guzinski GM (1996): Racial differences in severity, symptoms and age at diagnosis. *J Reprod Med* 41:483-490.

Kjerulff KH, Langenberg PW, Rhodes JC, Harvey LA, Guzinski GM and Stolley PD (2000): Effectiveness of hysterectomy. *Obstet Gynecol* 95:319-26.

Klatsky PC, Lane DE, Ryan IP and Fujimoto VY (2007): The effect of fibroids without cavity involvement on ART outcomes independent of ovarian age. *Hum Reprod* 22:521-526.

Kongnyuy E and Wiysonge C (2007): Interventions to reduce haemorrhage during myomectomy for fibroids. *Cochrane Database Syst Rev* 1:CD005355.

Kovac RS (1995): Guidelines to determine the route of hysterectomy. *Obstet Gynecol* 85:18-23.

Kovac RS and Ameo RA (1999): Choosing the approach to hysterectomy. *Contemp Ob Gyn December*:35-49.

Kueng W, Silber E and Eppenberger U (1989): Quantification of cells cultured on 96-well plates. *Anal Biochem* 182:16-19.

Kung F-T and Chang S-Y (1996): The relationship between ultrasonic volume and actual weight of pathologic uterus. *Gynecol Obstet Invest* 42:35-38.

Kyei-Mensah A, Shaker A, Zaidi J, Campell S, Pittrof R and Tan SL (1996): Transvaginal three-dimensional ultrasound: accuracy of follicular volume measurements. *Fertil Steril* 65:371-376.

La Marca A, Giulini S, Vito G, Orvieto R, Volpe A and Jasonni VM (2004): Gestrinone in the treatment of uterine leiomyomata: effects on uterine blood supply. *Fert Ster* 82:1694-1696.

Lamberg-Allardt CJ, Outila TA, Kärkkäinen MU, Rita HJ and Valsta LM (2001): Vitamin D deficiency and bone health in healthy adults in Finland: could this be a concern in other parts of Europe? *J Bone Miner Res* 16:2066-2073.

Launonen V, Vierimaa O, Kiuru M, Isola J, Roth S, Pukkala E, Sistonen P, Herva R and Aaltonen LA (2001): Inherited susceptibility to uterine leiomyomas and renal cell cancer. *Proc Natl Acad Sci USA* 98:3387-3392.

Law P and Regan L (2000): Interstitial thermo-ablation under MRI guidance for the treatment of fibroids. *Curr Opin Obstet Gynecol* 12:277-282.

Le Bouedec G, de Latour M and Dauplat J (1995): Expansive uterine myoma during tamoxifen therapy. 11 cases. *Presse Med* 24:1694-1696.

Leather AT, Studd JW, Watson NR and Holland EF (1993): The prevention of bone loss in young women treated with GnRH analogues with "add-back" estrogen therapy. *Obstet Gynecol* 81:104-107.

Lefebvre G, Vilos G, Allaire C, Jeffrey J, Arneja J, Birch C, Fortier M and Wagner MS (2003): The management of uterine leiomyomas. *J Obstet Gynaecol Can* 25:396-418.

Leibsohn S, d'Ablaing G, Mishell DR Jr. and Schlaerth JB (1990): Leiomyosarcoma in a series of hysterectomies performed for presumed uterine leiomyomas. *Am J Obstet Gynecol* 162:968-974.

Lethaby A, Shepperd S, Cooke I and Farquhar C (2000a): Endometrial resection and ablation versus hysterectomy for heavy menstrual bleeding. *Cochrane Database Syst Rev* 2:CD000329.

Lethaby A, Vollenhoven B and Sowter M (2000b): Pre-operative GnRH analogue therapy before hysterectomy or myomectomy for uterine fibroids. *Cochrane Database Syst Rev* 2:CD000547.

Lethaby A (2003): Fibroids (uterine myomatosis, leiomyomas). *Clin Evid* 7:1666-1678.

Lethaby A, Vollenhoven B and Sowter M (2004): Pre-operative GnRH analogue therapy before hysterectomy or myomectomy for uterine fibroids. *Cochrane Database Syst Rev* 1.

Letterie GS, Coddington CC, Winkel CA, Shawker TH, Loriaux DL and Collins RL (1989): Efficacy of a gonadotropin-releasing hormone agonist in the treatment of uterine leiomyomata: long-term follow-up. *Fertil Steril* 51:951-956.

Lev-Toaff AS, Coleman BG, Arger PH, Mintz MC, Arenson RL and Toaff ME (1987): Leiomyomas in pregnancy: sonographic study. *Radiology* 164:375-380.

Levy B, Mukherjee T and Hirschhorn K (2000): Molecular cytogenetic analysis of uterine leiomyoma and leiomyosarcoma by comparative genomic hybridization. *Cancer Genet Cytogenet* 121:1-8.

Ligon AH and Morton CC (2000): Genetics of uterine leiomyomata. *Genes Chromosomes Cancer* 28:235-245.

Linder D and Gartler SM (1965): Glucose-6-phosphate dehydrogenase mosaicism: utilization as a cell marker in the study of leiomyomas. *Science* 150:67-69.

Lippman SA, Warner M, Samules S, Olive D, Vercellini P and Eskenazi B (2003): Uterine fibroids and gynecologic pain symptoms in a population-based study. *Fertil Steril* 80:1488-1494.

Loffer FD (2005): Improving results of hysteroscopic submucosal myomectomy for menorrhagia by concomitant ablation. *J Minim Invasive Gynecol* 12:254-260.

Lokeshwar BL, Schwartz GG, Selzer MG, Burnstein KL, Zhuang SH, Block NL and Binderup L (1999): Inhibition of prostate cancer metastasis in vivo: a comparison of 1,25-dihydroxyvitamin D (calcitriol) and EB1089. *Cancer Epidemiol Biomarkers Prev* 8:241-248.

Lou Y-R, Laaksi I, Syväälä H, Bläuer M, Tammela TLJ, Ylikomi T and Tuohimaa P (2004): 25-Hydroxyvitamin D3 is an active hormone in human primary prostatic stromal cells. *FASEB J* 18:332-334.

Love-Schimenti CD, Gibson DF, Ratnam AV and Bikle DD (1996): Antiestrogen potentiation of antiproliferative effects of vitamin D3 analogues in breast cancer cells. *Cancer Res* 56:2789-2794.

Lumbiganon P, Rugpao S, Phandhu-fung S, Laopaiboon M, Vudhikamraksa N and Werawatakul Y (1996): Protective effect of depot-medroxyprogesterone acetate on surgically treated uterine leiomyoma: a multicentre case-control study. *Br J Obstet Gynaecol* 103:909-914.



Lumsden MA, Twaddle S, Hawthorn R, Traynor I, Gilmore D, Davis J, Deeny M, Cameron IT and Walker JJ (2000): A randomised comparison and economic evaluation of laparoscopic-assisted hysterectomy and abdominal hysterectomy. *Br J Obstet Gynaecol* 107:1386-1391.

Luoto R, Kaprio J, Keskimäki I and Rutanen E-M (1994): Kohdunpoisto Suomessa- Ilmaantuvuus, indikaatiot ja leikkaustavat. *Suomen Lääkärilehti* 49:906-913.

Luukkainen T, Pakarinen P and Toivonen J (2001): Progestin-releasing intrauterine systems. *Semin Reprod Med* 19:355-363.

Lyons EA, Gratton D and Harrington C (1992): Transvaginal sonography of normal pelvic anatomy. *Rad Clin N Am* 30:663-675.

Lyons RM and Moses HL (1990): Transforming growth factors and the regulation of cell proliferation. *Eur J Biochem* 187:467-473.

Magalhaes J, Aldrighi JM and de Lima GR (2007): Uterine volume and menstrual patterns in users of levonorgestrel-releasing intrauterine system with idiopathic menorrhagia or menorrhagia due to leiomyomas. *Contraception* 75:193-198.

Magos AL, Bournas N, Sinha R, Richardson RE and O'Connor H (1994): Vaginal myomectomy. *Br J Obstet Gynaecol* 101:1092-1094.

Mais V, Ajossa S, Guerriero S, Mascia M, Solla E and Melis GB (1996): Laparoscopic versus abdominal myomectomy: a prospective, randomized trial to evaluate benefits in early outcome. *Am J Obstet Gynecol* 174:654-658.

Mäkinen J, Johansson J, Tomás C, Tomás E, Heinonen PK, Laatikainen T, Kauko M, Heikkinen AM and Sjöberg J (2001): Morbidity of 10 110 hysterectomies by type of approach. *Hum Reprod*. 16:1473-1478.

Mangrulkar RS, Ono M, Ishikawa M, Takashima S, Klagsbrun M and Nowak RA (1995): Isolation and characterization of heparin-binding growth factors in human leiomyomas and normal myometrium. *Biol Reprod* 53:636-646.

Mantell DJ, Owens PE, Bundred NJ, Mawer EB and Canfield AE (2000): 1 alpha,25-dihydroxyvitamin D(3) inhibits angiogenesis in vitro and in vivo. *Circ Res* 87:214-220.

Marino JL, Eskenazi B, Warner M, Samuels S, Vercellini P, Gavoni N and Olive D (2004): Uterine leiomyoma and menstrual cycle characteristics in a population-based cohort study. *Hum Reprod* 19:2350-2355.

Marsh DJ, Dahia PL, Zheng Z, Liaws D, Parsons R, Gorlin RJ and Eng C (1997): Germline mutations in PTEN are present in Bannayan-Zonana syndrome. *Nat Genet* 16:333-334.

Marshall LM, Spiegelman D, Barbieri RL, Goldman MB, Manson JE, Colditz GA, Willett WC and Hunter DJ (1997): Variation in the incidence of uterine leiomyoma among premenopausal women by age and race. *Obstet Gynecol* 90:967-973.

Marshall LM, Spiegelman D, Goldman MB, Manson JE, Colditz GA, Barbieri RL, Stampfer MJ and Hunter DJ (1998a): A prospective study of reproductive factors and oral contraceptive use in relation to the risk of uterine leiomyomata. *Fertil Steril* 70:432-439.

Marshall LM, Spiegelman D, Manson JE, Goldman MB, Barbieri RL, Stampfer MJ, Willett WC and Hunter DJ (1998b): Risk of uterine leiomyomata among premenopausal women in relation to body size and cigarette smoking. *Epidemiology* 9:511-517.

Mashal RD, Fejzo MLS, Friedman AJ, Mitchner N, Nowak RA, Rein MS, Morton CC and Sklar J (1994): Analysis of androgen receptor DNA reveals the independent clonal origins of uterine leiomyomata and the secondary nature of cytogenetic aberrations in the development of leiomyomata. *Genes Chromosomes Cancer* 11:1-6.

Maslar IA and Riddick DH (1979): Prolactin production by human endometrium during the normal menstrual cycle. *Am J Obstet Gynecol* 135:751-754.

Mayer DP and Shipilov V (1995): Ultrasonography and magnetic resonance imaging of uterine fibroids. *Obstet Gynecol Clin North Am* 22:667-725.

McDonnell DP, Mangelsdorf DJ, Pike JW, Haussler MR and O'Malley BW (1987): Molecular cloning of complementary DNA encoding the avian receptor for vitamin D. *Science* 235:1214-1217.

McLucas B, Adler L and Perella R (2001): Uterine fibroid embolization: non-surgical treatment for symptomatic fibroids. *J Am Coll Surg* 192:92-105.

Merce LT, Gomez B, Engels V, Bau S and Bajo JM (2005): Intraobserver and interobserver reproducibility of ovarian volume, antral follicle count, and vascularity indices obtained with transvaginal 3-dimensional ultrasonography, power Doppler angiography, and the virtual organ computer-aided analysis imaging program. *J Ultrasound Med* 24:1279-1287.

Merrill JA and Creasman WT (1986): Lesions of the Corpus Uteri. In: *Obstetrics and gynecology*, pp. 1068-1083. Eds. DN Danforth and JR Scott. J.B. Lippincott Company, Philadelphia.

Michnovicz JJ, Hershcopf RJ, Naganuma H, Gradlow HL and Fishman J (1986): Increased 2-hydroxylation of estradiol as a possible mechanism for the anti-estrogenic effect of cigarette smoking. *N Engl J Med* 315:1305-1309.

Miettinen S, Ahonen M, Lou Y-R, Manninen T, Tuohimaa P, Syväla H and Ylikomi T (2004): Role of 24-hydroxylase in vitamin D<sub>3</sub> growth response of OVCAR-3 ovarian cancer cells. *Int J Cancer* 108:367-373.

Miller CE (2000): Myomectomy. Comparison of open and laparoscopic techniques. *Obstet Gynaecol Clin North Am* 27:407-420.

Miskry T and Magos A (1999): Laparoscopic myomectomy. *Semin Laparosc Surg* 6:73-79.

Monteiro I, Bahamondes L, Diaz J, Perrotti M and Petta C (2002): Therapeutic use of levonorgestrel-releasing intrauterine system in women with menorrhagia: a pilot study (1). *Contraception* 65:325-328.

Morita Y, Ito N, Hikida H, Takeuchi S, Nakamura K and Ohashi H (2007): Non-invasive magnetic resonance imaging-guided focused ultrasound treatment for uterine fibroids-early experience. *Eur J Obstet Gynecol* (in press).

Munker R, Norman A and Koeffler HP (1986): Vitamin D compounds. Effect on clonal proliferation and differentiation of human myeloid cells. *J Clin Invest* 78:424-430.

Murphy AA, Kettel LM, Morales AJ, Roberts VJ and Yen SS (1993): Regression of uterine leiomyomata in response to the antiprogestosterone RU 486. *J Clin Endocrinol Metab* 76:513-517.

Nagele F, O'Connor H, Davies A, Badawy A, Mohammed H and Magos A (1996): 2500 outpatient diagnostic hysteroscopies. *Obstet Gynecol* 88:87-92.

Narayan R, Rajat, Goswamy K (1994): Treatment of submucous fibroids, and outcome of assisted conception. *J Am Assoc Gynecol Laparosc* 1:307-311.

Nesby-O'Dell S, Scanlon KS, Cogswell ME, Gillespie C, Hollis BW, Looker AC, Allen C, Dougherty C, Gunter EW and Bowman BA (2002): Hypovitaminosis D prevalence and determinants among African American and white women of reproductive age: third National Health and Nutrition Examination Survey. *Am J Clin Nutr* 76:187-192.

Nezhat C, Nezhat F, Silfen SL, Schaffer N and Evans D (1991): Laparoscopic myomectomy. *Int J Fertil* 36:275-280.

Nezhat C, Nezhat F, Bess O, Nezhat CH and Mashiach R (1994): Laparoscopically assisted myomectomy: a report of a new technique in 57 cases. *Int J Fertil* 39:39-44.

Nezhat FR, Roemisch M, Nezhat CH, Seidman DS and Nezhat CR (1998): Recurrence rate after laparoscopic myomectomy. *J Am Assoc Gynecol Laparosc* 5:237-240.

Nilbert M and Heim S (1990): Uterine leiomyoma cytogenetics. *Genes Chromosomes Cancer* 2:3-13.

Nisolle M, Gillerot S, Casanas-Roux F, Squifflet J, Berliere M and Donnez J (1999): Immunohistochemical study of the proliferation index, oestrogen receptors and progesterone receptors A and B in leiomyomata and normal myometrium during the menstrual cycle and under gonadotrophin-releasing hormone agonist therapy. *Hum Reprod* 14:2844-2850.

Novak ER and Woodruff DJ (1979): *Novak's Gynecologic and Obstetric Pathology with Clinical and Endocrine Relations*. J.B. Lippincott Company, Philadelphia.

Nowak RA (1999): Fibroids: pathophysiology and current medical treatment. *Baillieres Best Pract Res Clin Obstet Gynaecol* 13:223-238.

Nowak RA (2000): Novel therapeutic strategies for leiomyomas: targeting growth factors and their receptors. *Environ Health Perspect* 108(suppl 5):849-853.

O'Connor H and Magos A (1996:) Endometrial resection for the treatment of menorrhagia. *N Engl J Med* 335:151-156.

Okolo SO, Gentry CC, Perrett CW and Maclean AB (2005): Familial prevalence of uterine fibroids is associated with distinct clinical and molecular features. *Hum Reprod* 20:2321-2324.

Oliveira FG, Abdelmassih VG, Diamond MP, Dozortsey D, Melo NR and Abdelmassih R (2004): Impact of subserosal and intramural fibroids that do not distort the endometrial cavity on the outcome of in vitro fertilization intracytoplasmic sperm injection. *Fertil Steril* 8:582-587.

Otubu JA, Buttram VC, Besch NF and Besch PK (1982): Unconjugated steroids in leiomyomas and tumor-bearing myometrium. *Am J Obstet Gynecol* 143:130-133.

Palomba S, Affinito P, Di Carlo C, Bifulco G and Nappi C (1999): Long-term administration of tibolone plus gonadotropin-releasing hormone agonist for the treatment of uterine leiomyomas: effectiveness and effects on vasomotor symptoms, bone mass, and lipid profiles. *Fertil Steril* 72:889-895.

Palomba S, Sammartino A, Di Carlo C, Affinito P, Zullo F and Nappi C (2001): Effects of raloxifene treatment on uterine leiomyomas in postmenopausal women. *Fertil Steril* 76:38-43.

Palomba S, Orio F Jr, Morelli M, Russo T, Pellicano M, Zupi E, Lombardi G, Nappi C, Panici PL and Zullo F (2002a): Raloxifene administration in premenopausal women with uterine leiomyomas: a pilot study. *J Clin Endocrinol Metab* 87:3603-3608.

Palomba S, Sena T, Morelli M, Noia R, Zullo F and Mastrantonio P (2002b): Effect of different doses of progestin on uterine leiomyomas in postmenopausal women. *Eur J Obstet Gynecol Reprod Biol* 102:199-201.

Parazzini F, La Vecchia C, Negri E, Cecchetti G and Fedele L (1988): Epidemiologic characteristics of women with uterine fibroids: a case-control study. *Obstet Gynecol* 72:853-857.

Parazzini F, Negri E, La Vecchia C, Fedele L, Rabaiotti M and Luchini L (1992): Oral contraceptive use and risk of uterine fibroids. *Obstet Gynecol* 79:430-433.

Parazzini F, Negri E, La Vecchia C, Chatenoud L, Ricci E and Guarnerio P (1996a): Reproductive factors and risk of uterine fibroids. *Epidemiology* 7:440-442.

Parazzini F, Negri E, La Vecchia C, Rabaiotti M, Luchini L, Villa A and Fedele L (1996b): Uterine myomas and smoking. Results from an Italian study. *J Reprod Med* 41:316-320.

Parker WH, Fu YS and Berek JS (1994): Uterine sarcoma in patients operated on for presumed leiomyoma and rapidly growing leiomyoma. *Obstet Gynecol* 83:414-418.

Parker WH (2006): Laparoscopic myomectomy and abdominal myomectomy. *Clin Obstet Gyn* 49:789-797.

Pelosi III M and Pelosi M (1997): Laparoscopic-assisted transvaginal myomectomy. *J Am Assoc Gynecol Laparosc* 4:241-246.

Pierce SJ, Gazvani MR and Farquharson RG (2000): Long-term use of gonadotropin-releasing hormone analogs and hormone replacement therapy in the management of endometriosis: a randomised trial with a 6-year follow-up. *Fertil Steril* 74:964-968.

Piironen O (1975): Studies in diagnostic ultrasound: Size of the non-pregnant uterus in women of childbearing age and uterine growth and foetal development in the first half of normal pregnancy. *Acta Obstet Gynecol Scand* 46(Suppl):26-29.

Pinto I, Chimeno P, Romo A, Paúl L, Haya J, de la Cal MA and Bajo J (2003): Uterine fibroids: uterine artery embolization versus abdominal hysterectomy for treatment—a prospective, randomized, and controlled clinical trial. *Radiology* 226:425-431.

Platt JF, Bree RL and Davidson D (1990): Ultrasound of the normal nonpregnant uterus: correlation with gross and histopathology. *J Clin Ultrasound* 18:15-19.

Polatti F, Viazzo F, Colleoni R and Nappi RE (2000): Uterine myoma in postmenopause: a comparison between two therapeutic schedules of HRT. *Maturitas* 37:27-32.

Pooley AS, Ewen SP and Sutton CJG (1998): Does transcervical resection of the endometrium for menorrhagia really avoid hysterectomy? Life table analysis of a large series. *J Am Assoc Gynecol Laparosc* 5:229-235.

Poppe W, Van Assche FA, Wilms G, Fawril A and Baert A (1987): Pregnancy after transcatheter embolization of a uterine arteriovenous malformation. *Am J Obstet Gynecol* 156:1179-1180.

Presta M (1988): Sex hormones modulate the synthesis of basic fibroblast growth factor in human endometrial adenocarcinoma cells: implications for the neovascularization of normal and neoplastic endometrium. *J Cell Physiol* 137:593-597.

Pritts EA, Parker WH and Olive DL (2008): Fibroids and infertility: an updated systematic review of the evidence. *Fertil Steril* (in press).

Pron G, Bennett J, Common A, Wall J, Asch M and Sniderman K (2003): The Ontario Uterine Fibroid Embolization Trial. Part 2. Uterine fibroid reduction and symptom relief after uterine artery embolization for fibroids. *Fertil Steril* 79:120-127.

Qidwai GI, Caughey AB and Jacoby AF (2006): Obstetric outcomes in women with sonographically identified uterine leiomyomata. *Obstet Gynecol* 107:376-382.

Radeleff B, Rimbach S, Kauffmann GW and Richter GM (2003): Risiken und Komplikationen der Embolisationstherapie von Uterusmyomen. *Radiologe* 43:641-650.

Ramcharan S, Pellegrin FA, Ray RM and Hsu JP (1980): The Walnut Creek Contraceptive Drug Study. A prospective study of the side effects of oral contraceptives. Volume III, an interim report: A comparison of disease occurrence leading to hospitalization or death in users and nonusers of oral contraceptives. *J Reprod Med* 1980 25(suppl 6):345-372.

Ravina JH, Herbreteau D, Ciraru-Vigneron N, Bouret JM, Houdart E, Aymard A and Merland JJ (1995): Arterial embolisation to treat uterine myomata. *Lancet* 346:671-672.

Razavi MK, Hwang G, Jahed A, Modanloo S and Chen B (2003): Abdominal myomectomy versus uterine fibroid embolization in the treatment of symptomatic uterine leiomyomas. *Am J Roentgenol* 180:1571-1575.

Reed SD, Cushing-Haugen KL, Daling JR, Scholes D and Schwartz SM (2004): Postmenopausal estrogen and progestogen therapy and the risks of uterine leiomyomas. *Menopause* 11:214-222.

Reed WB, Walker R and Horowitz R (1973): Cutaneous leiomyomata with uterine leiomyomata. *Acta Dermatol Venereol* 53:409-416.

Reichrath J, Rafi L, Muller SM, Mink D, Reitnauer K, Tilgen W, Schmidt W and Friedrich M (1998): Immunohistochemical analysis of 1,25-dihydroxyvitamin D3 receptor in cervical carcinoma. *Histochem J* 30:561-567.

Rein MS and Nowak RA (1992): Biology of uterine myomas and myometrium in vitro. *Semin Reprod Endocrinol* 10:310-319.

Rein MS, Barbieri RL and Friedman AJ (1995): Progesterone: a critical role in the pathogenesis of uterine myomas. *Am J Obstet Gynecol* 172:14-18.

Rein MS (2000): Advances in uterine leiomyoma research: the progesterone hypothesis. *Environ Health Perspect* 108(suppl 5):791-793.

Reynolds LP, Kirsch JD, Kraft KC and Redmer DA (1998): Time-course of the uterine response to estradiol-17beta in ovariectomized ewes: expression of angiogenic factors. *Biol Reprod* 59:613-620.

Riccabona M, Nelson TR, Pretorius DH, Davidson TE (1995): Distance and volume measurement using three-dimensional ultrasonography. *J Ultrasound Med* 14:881-886.

Richards PA and Tiltman AJ (1996): Anatomical variation of the oestrogen receptor in the non-neoplastic myometrium of fibromyomatous uteri. *Virchows Arch* 428:347-351.

Romero R, Chervenak FA, DeVore G, Tortora M and Hobbins JC (1981): Fetal head deformation and congenital torticollis associated with a uterine tumor. *Am J Obstet Gynecol* 141:839-840.

Romieu I, Walker AM and Jick S (1991): Determinants of uterine fibroids. *Post Market Surveill* 5:119-133.

Rosa e Silva JC, de Sa Rosa e Silva AC, dos Reis FJ, Manetta LA, Ferriani RA and Nogueira AA (2005): Use of a levonorgestrel-releasing intrauterine device for the symptomatic treatment of uterine myomas. *J Reprod Med* 50:613-617.

Rosati P, Exacoustos C and Mancuso S (1992): Longitudinal evaluation of uterine myoma growth during pregnancy. A sonographic study. *J Ultrasound Med* 11:511-515.

Rosenfeld DL (1986): Abdominal myomectomy for otherwise unexplained infertility. *Fertil Steril* 46:328-330.

Rosenthal SM, Hsiao D and Silverman LA (1994): An insulin-like growth factor-II (IGF-II) analog with highly selective affinity for IGF-II receptors stimulates differentiation, but not IGF-I receptor down-regulation in muscle cells. *Endocrinology* 135:38-44.

Ross RK, Pike MC, Vessey MP, Bull D and Yeates D and Casagrande JT (1986): Risk factors for uterine fibroids: reduced risk associated with oral contraceptives. *Br Med J (Clin Res Ed)* 293:359-362.

Ross TK, Darwish HM and DeLuca HF (1994): Molecular biology of vitamin D action. *Vitam Horm* 49:281-326.

Sadan O, van Iddekinge B, van Gelderen CJ, Savage N, Becker PJ, van der Walt LA and Robinson M (1987): Oestrogen and progesterone receptor concentrations in leiomyoma and normal myometrium. *Ann Clin Biochem* 24:263-267.

Samadi AR, Lee NC, Flancers WD, Boring JR III and Parris EB (1996): Risk factors for self-reported uterine fibroids: a case-control study. *Am J Public Health* 86:858-862.

Saunders DE, Christensen C, Lawrence WD, Malviya VK, Malone JM, Williams JR and Deppe G (1992): Receptors for 1,25-dihydroxyvitamin D3 in gynecologic neoplasms. *Gynecol Oncol* 44:131-136.

Saunders DE, Christensen C, Wappler NL, Schultz JF, Lawrence WD, Malviya VK, Malone JM and Deppe G (1993): Inhibition of c-myc in breast and ovarian

carcinoma cells by 1,25-dihydroxyvitamin D<sub>3</sub>, retinoic acid and dexamethasone. *Anticancer drugs* 4:201-208.

Sauro MD and Zorn NE (1991): Prolactin induces proliferation of vascular smooth muscle cells through a protein kinase C-dependent mechanism. *J Cell Physiol* 148:133-138.

Sawin S, Pilevsky N, Berlin J and Barnhart K (2000): Comparability of perioperative morbidity between abdominal myomectomy and hysterectomy for women with uterine leiomyomas. *Am J Obstet Gynecol* 183:1448-1455.

Saxton DW, Farquhar CM, Rae T, Beard RW, Anderson MC and Wadsworth J (1990): Accuracy of ultrasound measurements of female pelvic organs. *Br J Obstet Gynaecol* 97:695-699.

Schwartz GG, Wang MH, Zang M, Singh RK and Siegal GP (1997): 1 alpha,25-Dihydroxyvitamin D (calcitriol) inhibits the invasiveness of human prostate cancer cells. *Cancer Epidemiol Biomarkers Prev* 6:727-732.

Schwartz SM, Marshall LM and Baird DD (2000): Epidemiologic contribution to understanding the etiology of uterine leiomyomata. *Environ Health Perspect* 108 (suppl 5):821-827.

Scoutt LM, McCarthy SM, Flynn SD, Lange RC, Long F, Smith RC, Chambers SK, Kohorn E, Schwartz P and Chambers JT (1995): Clinical stage I endometrial carcinoma: pitfalls in preoperative assessment with MR imaging. *Work in progress. Radiology* 194:567-572.

Seinera P, Arisio R, Decko A, Farina C and Crana F (1997): Laparoscopic myomectomy: indications, surgical technique and complications. *Hum Reprod* 12:1927-1930.

Semm K (1977): *Atlas of Gynecologic Laparoscopy and Hysteroscopy*. WB Saunders Co, Philadelphia.

Shaw RW (1991): New approaches to the management of fibroids. *Curr Opin Obstet Gynecol* 3:859-864.

Shikora SA, Niloff JM, Bistrain BR, Forse RA and Blackburn GL (1991): Relationship between obesity and uterine leiomyomata. *Nutrition* 7:251-255.

Simboli-Campbell M, Narvaez CJ, van Weelden K, Tenniswood M, Welsh J (1997): Comparative effects of 1,25(OH)<sub>2</sub>D<sub>3</sub> and EB1089 on cell cycle kinetics and apoptosis in MCF-7 breast cancer cells. *Breast Cancer Res Treat* 42:31-41.

Sinha R, Hegde A, Mahajan C, Dubey N and Sundaram M (2008): Laparoscopic myomectomy: do size, number, and location of the myomas form limiting factors for laparoscopic myomectomy? *J Minim Invasive Gynecol* 15:292-300.

Smith DC and Uhlir JK (1990): Myomectomy as a reproductive procedure. *Am J Obstet Gynecol* 161:476-482.

Spies JB, Ascher SA, Roth AR, Kim J, Levy EB and Gomez-Jorge J (2001): Uterine artery embolization for leiomyomata. *Obstet Gynecol* 98:29-34.

Spies JB, Spector A, Roth AR, Baker CM, Mauro L and Murphy-Skrynarz K (2002a): Complications after uterine artery embolization for leiomyomas. *Obstet Gynecol* 100:873-880.

Spies JB, Warren EH, Mathias SD, Walsh SM, Roth AR and Pentecost MJ (2002b): Uterine fibroid embolization: measurement of health-related quality of life before and after therapy. *J Vasc Interv Radiol* 10:1293-12303.

Spies JB (2004): Uterine artery embolization for fibroids: understanding the technical causes of failure. *J Vasc Interv Radiol* 14:11-14.

Steinauer J, Pritts EA, Jackson R and Jacoby AF (2004): Systematic review of mifepristone for the treatment of uterine leiomyomata. *Obstet Gynecol* 103:1331-1336.

Stewart EA, Friedman AJ, Peck K and Nowak RA (1994): Relative overexpression of collagen type I and collagen type III messenger ribonucleic acids by uterine leiomyomas during the proliferative phase of the menstrual cycle. *J Clin Endocrinol Metab* 79:900-906.

Stewart EA and Nowak RA (1996): Leiomyoma-related bleeding: a classic hypothesis updated for the molecular era. *Hum Reprod Update* 2:295-306.

Stewart EA and Nowak RA (1998): New concepts in the treatment of uterine leiomyomas. *Obstet Gynecol* 92:624-627.

Stewart EA (2001): Uterine fibroids. *Lancet* 357:293-298.

Stewart EA, Gedroyc WM, Tempany CM, Quade BJ, Inbar Y, Ehrenstein T, Shushan A, Hindley JT, Goldin RD, David M, Sklair M and Rabinovici J (2003): Focused ultrasound treatment of uterine fibroid tumors: Safety and feasibility of a non-invasive thermoablative technique. *Am J Obstet Gynecol* 189:48-54.

Stotland NE, Lipschitz LS and Caughey AB (2002): Delivery strategies for women with a previous classic cesarean delivery: a decision analysis. *Am J Obstet Gynecol* 187:1203-1208.

Stovall DW, Parrish SB, Van Voorhis BJ, Hahn SJ, Sparks AET and Syrop CH (1998): Uterine leiomyomas reduce the efficacy of assisted reproduction cycles. *Hum Reprod* 13:192-197.

Strawn EY Jr., Novy MJ, Burry KA and Bethea CL (1995): Insulin-like growth factor I promotes leiomyoma cell growth in vitro. *Am J Obstet Gynecol* 172:1837-1843.

Stringer NG and Strassner HT (1996): Pregnancy in five patients after laparoscopic myomectomy with the harmonic scalpel. *J Gynaecol Surg* 12:129-133.

Sumitani H, Shozu M, Segawa T, Murakami K, Yang HJ, Shimada K and Inoue M (2000): In situ estrogen synthesized by aromatase P450 in uterine leiomyoma cells promotes cell growth probably via an autocrine/intracrine mechanism. *Endocrinology* 141:3852-3861.

Surrey ES, Lietz AK and Schoolcraft WB (2001): Impact of intramural leiomyomata in patients with a normal endometrial cavity on in vitro fertilization-embryo transfer cycle outcome. *Fertil Steril* 75:405-410.

Tang XM, Dou Q, Zhao Y, McLean F, Davis J and Chegini N (1997): The expression of transforming growth factor-betas and TGF-beta receptor mRNA and protein and the effect of TGF-betas on human myometrial smooth muscle cells in vitro. *Mol Hum Reprod* 3:233-240.

Tangrea J, Helzlsouer K, Pietinen P, Taylor P, Hollis B, Virtamo J and Albanes D (1997): Serum levels of vitamin D metabolites and the subsequent risk of colon and rectal cancer in Finnish men. *Cancer Causes Control* 8:615-625.

Taylor A, Sharma M, Tsirkas P, Di Spiezio Sardo A, Setchell M and Magos A (2005): Reducing blood loss at open myomectomy using triple tourniquets: a randomised controlled trial. *Br J Obstet Gynaecol* 112:340-345.



- Taylor E and Gomel V (2008): The uterus and infertility. *Fertil Steril* 89:1-16.
- The REST investigators (2007): Uterine-artery embolization versus surgery for symptomatic uterine fibroids. *N Engl J Med* 356:360-370.
- Toita T, Kakinohana Y, Shinzato S, Ogawa K, Yoshinaga M, Iraha S, Higashi M, Sakumoto K, Kanazawa K and Sawada S (1999): Tumor diameter/ volume and pelvic node status assessed by magnetic resonance imaging (MRI) for uterine cervical cancer treated with irradiation. *Int J Radiat Oncol Biol Phys* 43:777-782.
- Townsend DE, Sparkes RS, Baluca MC and McClelland G (1970): Unicellular histogenesis of uterine leiomyomas as determined by electrophoresis of glucose-6-phosphate dehydrogenase. *Am J Obstet Gynecol* 107:1168-1173.
- Treolar SA, Martin NG, Dennerstein L, Raphael B and Heath AC (1992): Pathways to hysterectomy: insight from longitudinal twin research. *Am J Obstet Gynecol* 167:82-88.
- Tulandi T, Murray C and Guralnick M (1993): Adhesion formation and reproductive outcome after myomectomy and second-look laparoscopy. *Obstet Gynecol* 82:213-215.
- Tulandi T and Al-Took S (1999): Endoscopic myomectomy. *Laparoscopy and hysteroscopy. Obstet Gynaecol Clin North Am* 26:135-148.
- Ubaldi F, Tournaye H, Camus M, Vander Pas H, Gepts E and Devroey P (1995): Fertility after hysteroscopic myomectomy. *Hum Reprod Update* 1:81-90.
- Välimäki VV, Alfthan H, Lehmuškallio E, Löyttyniemi E, Sahi T, Stenman UH, Suominen H and Välimäki MJ (2004): Vitamin D status as a determinant of peak bone mass in young Finnish men. *J Clin Endocrinol Metab* 89:76-80.
- Van Dongen H, Emanuel MH, Smeets MJ, Trimbos B and Jansen FW (2006): Follow-up after incomplete hysteroscopic removal of uterine fibroids. *Acta Obstet Gynecol Scand* 85:1463-1467.
- Vanni R, Van Roy N, Lecca U and Speleman F (1992): Uterine leiomyoma cytogenetics. III. Interphase cytogenetic analysis of karyotypically normal uterine leiomyoma excludes possibility of undetected trisomy 12. *Cancer Genet Cytogenet* 62:40-42.
- Varasteh NN, Neuwirth RS, Levin B and Keltz MD (1999): Pregnancy rates after hysteroscopic polypectomy and myomectomy in infertile women. *Obstet Gynecol* 94:168-171.
- Velebil P, Wingo PA, Xia Z, Wilcox LS and Peterson HB (1995): Rate of hospitalization for gynecologic disorders among reproductive-age women in the United States. *Obstet Gynecol* 86:764-769.
- Vercellini P, Maddalena S, De Giorgi O, Aimi G and Crosignani PG (1998): Abdominal myomectomy for infertility: a comprehensive review. *Hum Reprod* 13:873-879.
- Vergani P, Ghidini A, Strobelt N, Roncaglia N, Locatelli A, Lapinski RH and Mangioni C (1994): Do uterine leiomyomas influence pregnancy outcome? *Am J Perinatol* 11:356-358.
- Vienonen A, Miettinen S, Bläuer M, Martikainen P, Tomas E, Heinonen PK and Ylikomi T (2004): Expression of nuclear receptors and cofactors in human endometrium and myometrium. *J Soc Gynecol Investig* 11:104-112.

Vikhlyaeva EM, Khodzhaeva ZS and Fantschenko ND (1995): Familial predisposition to uterine leiomyomas. *Int J Gynaecol Obstet* 51:127-131.

Visvanathan D, Connell R, Hall-Craggs MA, Cutner AS and Bown SG (2002): Interstitial laser photocoagulation for uterine myomas. *Am J Obstet Gynecol* 187:382-384.

Vogl TJ, Jacobi V, Gätje R, Siebzehrübl E and Zangos S (2003): Embolisation bei symptomatischen Uterus-Myomen (UAE): Technik. Indikationsstellung und Ergebnisse. *Rofo* 175:1032-1041.

Walker CL and Stewart EA (2005): Uterine fibroids: the elephant in the room. *Science* 308:1589-1592.

Walker WJ, Green A and Sutton C (1999): Bilateral uterine artery embolization for myomata: results, complications and failures. *Min Invas Ther & Allied Technol* 8:449-454.

Walker WJ, Pelage JP and Sutton C (2002): Fibroid embolization. *Clinical Radiology* 57:325-331.

Wallach EE (1992): Myomectomy. In: Te Linde's Operative Gynaecology, pp. 647-662. Eds. JD Thompson and JA Rock, Lippincott, Philadelphia.

Wallach EE and Vlahos NF (2004): Uterine myomas: an overview of development, clinical features, and management. *Obstet Gynecol* 104:393-406.

Walters CA, Daly DC, Chapitis J, Kuslis ST, Prior JC, Kusmik WF, Riddick DH (1983): Human myometrium: a new potential source of prolactin. *Am J Obstet Gynecol* 147:639-644.

Wamsteker K, Emanuel MH, and de Kruif JH (1993): Transcervical hysteroscopic resection of submucous fibroids for abdominal uterine bleeding: results regarding the degree of intramural extension. *Obstet Gynecol* 82:736-740.

Wang QM, Jones JB and Studzinski GP (1996): Cyclin-dependent kinase inhibitor p27 as a mediator of the G1-S phase block induced by 1,25-dihydroxyvitamin D3 in HL60 cells. *Cancer Res* 56:264-267.

Wang W and Check JH (2004): Effect of corporal fibroids on outcome following embryo transfer in donor-oocyte recipients. *Clin Exp Obstet Gynecol* 31:263-264.

Wegienka G, Baird DD, Hertz-Picciotto I, Harlow SD, Steege JF, Hill MC, Schectman JM and Hartmann KE (2003): Self-reported heavy bleeding associated with uterine leiomyomata. *Obstet Gynecol* 101:431-437.

Welsh J, Simboli-Campbell M, Narvaez CJ and Tenniswood M (1995): Role of apoptosis in the growth inhibitory effects of vitamin D in MCF-7 cells. *Adv Exp Med Biol* 375:45-52.

West S, Ruiz R and Parker WH (2006): Abdominal myomectomy in women with very large uterine size. *Fertil Steril* 85:36-39.

Wiener JJ and Newcombe RG (1992): Measurements of uterine volume: A comparison between measurements by ultrasonography and water displacement. *J Clin Ultrasound* 20:457-460.

Wilcox LS, Koonin LM, Pokras R, Strauss LT, Xia X and Peterson HB (1994): Hysterectomy in the United States 1988-1990. *Obstet Gynecol* 83:549-555.

Wise LA, Palmer JR, Harlow BL, Spiegelman D, Stewart EA, Adams-Campbell LL and Rosenberg L (2004): Reproductive factors, hormonal contraception, and risk

of uterine leiomyomata in African-American women: a prospective study. *Am J Epidemiol* 159:113-123.

Worthington-Kirsch RL, Andrews RT, Siskin GP, Shlansky-Goldberg R, Lipman JC, Goodwin SC, Bonn J and Hovsepian DM (2002): II. Uterine fibroid embolization: technical aspects. *Tech Vasc Interv Radiol* 5:17-34.

Worthington-Kirsch RL, Popky GL and Hutchins FL (1998): Uterine arterial embolization for the management of leiomyomas: quality-of-life assessment and clinical response. *Radiology* 8:625-629.

Wortman M and Daggett A (1995): Hysteroscopic myomectomy. *J Am Assoc Gynecol Laparosc* 3:39-46.

Wyshak G, Frisch RE, Albright NL, Albright TE and Schiff I (1986): Lower prevalence of benign diseases of the breast and benign tumours of the reproductive system among former college athletes compared to non-athletes. *Br J Cancer* 54:841-845.

Yabushita H, Hirata M, Noguchi M and Nakanishi M (1996): Vitamin D receptor in endometrial carcinoma and the differentiation-inducing effect of 1,25-dihydroxyvitamin D<sub>3</sub> on endometrial carcinoma cell lines. *J Obstet Gynaecol Res* 22:529-539.

Yamamoto T, Takamori K and Okada H (1984): Estrogen biosynthesis in leiomyoma and myometrium of the uterus. *Horm Metab Res* 16:678-679.

Yarali H and Bukulmez O (2002): The effect of intramural and subserous uterine fibroids on implantation and clinical pregnancy rates in patients having intracytoplasmic sperm injection. *Arch Gynecol Obstet* 266:30-33.

Yeh J, Rein M and Nowak R (1991): Presence of messenger ribonucleic acid for epidermal growth factor (EGF) and EGF receptor demonstrable in monolayer cell cultures of myometria and leiomyomata. *Fertil Steril* 56:997-1000.

Ylikomi T, Laaksi I, Lou YR, Martikainen P, Miettinen S, Pennanen P, Purmonen S, Syväälä H, Vienonen A and Tuohimaa P (2002): Antiproliferative action of vitamin D. *Vitam Horm* 64:357-406.

Yoshizawa T, Handa Y, Uematsu Y, Takeda S, Sekine K, Yoshihara Y, Kawakami T, Arioka K, Sato H, Uchiyama Y, Masushige S, Fukamizu A, Matsumoto T and Kato S (1997): Mice lacking the vitamin D receptor exhibit impaired bone formation, uterine hypoplasia and growth retardation after weaning. *Nat Genet* 16:391-396.

Zaloudek CJ and Hendrickson MR (2002): Mesenchymal tumors of the uterus. In: Blaunstein's pathology of female genital tract, p.561. Ed. RJ Kurman, Springer Verlag, New York.

Zehnder D, Bland R, Williams MC, McNinch RW, Howie AJ, Stewart PM and Hewison M (2001): Extrarenal expression of 25-hydroxyvitamin d(3)-1 alpha-hydroxylase. *J Clin Endocrinol Metab* 86:888-894.

Zeng C, Gu M and Huang H (1998): A clinical control study on the treatment of uterine leiomyoma with gonadotrophin releasing hormone agonist or mifepristone. *Zhonghua Fu Chan Ke Za Zhi* 33:490-492.

Zhuang SH, Burnstein KL (1998): Antiproliferative effect of 1 alpha,25-dihydroxyvitamin D<sub>3</sub> in human prostate cancer cell line LNCap involves reduction

of cyclin-dependent kinase 2 activity and persistent G1 accumulation. *Endocrinology* 139:1197-1207.

Zreik TG, Rutherford TJ, Palter SF, Troiano RN, Williams E, Brown JM and Olive DL (1998): Cryomyolysis, a new procedure for the conservative treatment of uterine fibroids. *J Am Assoc Gynecol Laparosc* 5:33-38.

Zupi E, Piredda A, Marconi D, Townsend D, Exacoustos C, Arduini D and Szabolcs B (2004): Directed laparoscopic cryomyolysis: A possible alternative to myomectomy and/or hysterectomy for symptomatic leiomyomas. *Am J Obstet Gynecol* 190:639-643.

# 14 ORIGINAL COMMUNICATIONS

**Vitamin D inhibits myoma cell growth**

**F & S\_revision**

## **Vitamin D inhibits myometrial and leiomyoma cell proliferation in vitro**

Merja Bläuer, Ph.D.,<sup>a</sup> Päivi H. Rovio, M.D.,<sup>b</sup> Timo Ylikomi M.D.,<sup>a</sup> and Pentti K. Heinonen M.D.<sup>b,c</sup>

<sup>a</sup>Department of Cell Biology, University of Tampere; <sup>b</sup>Department of Obstetrics and Gynecology, Tampere University Hospital; and <sup>c</sup>Medical School, University of Tampere, Tampere, Finland

Supported by grants from competitive research funding of the Pirkanmaa Hospital District, Tampere and TEKES Drug 2000, Finland. The contributions of the first two authors are equal.

Reprint requests: Päivi H. Rovio, M.D., Department of Obstetrics and Gynecology, Tampere University Hospital, FI-33521, Tampere, Finland (FAX: +358 3 311 64360; E-mail: paivi.rovio@pshp.fi).

**Capsule:** Both myometrial and leiomyoma cell growth in vitro was effectively inhibited by  $1,25(\text{OH})_2\text{D}_3$ . Vitamin D may play a role in the growth of uterine leiomyomas.



**ABSTRACT**

**Objective:** To determine the effect of 1,25(OH)<sub>2</sub>D<sub>3</sub> and 25(OH)D<sub>3</sub> vitamin D derivatives on the growth of leiomyoma and myometrial cells in vitro.

**Design:** In vitro study.

**Setting:** Cell biology research laboratory.

**Patients:** Six premenopausal women with uterine leiomyomas undergoing hysterectomy.

**Interventions:** Samples of leiomyomas and normal myometrial tissue were obtained and paired cultures were established.

**Main Outcome Measures:** The effect of 1,25(OH)<sub>2</sub>D<sub>3</sub> and 25(OH)D<sub>3</sub> on cell growth was examined using a colorimetric crystal violet assay.

**Results:** In both myometrial and leiomyoma cells, 0.1nM physiological level of 1,25(OH)<sub>2</sub>D<sub>3</sub> inhibited growth by 12 % when compared to controls. The growth inhibition was concentration-dependent, the highest concentration of 1,25(OH)<sub>2</sub>D<sub>3</sub> (100 nM) inhibiting growth by 62 % in both cell types. All the differences were statistically significant (p<0.05). A slight stimulation (<4 %) of cell proliferation was observed with the lowest 25(OH)<sub>2</sub>D<sub>3</sub> concentrations. When treated with either a 500 nM or 1000 nM concentration of the compound, the growth of both cell types fell to approximately 50 % of that of the control cultures, level of inhibition with the latter concentration being statistically significant (p<0.05).

**Conclusions:** Both myometrial and leiomyoma cell growth in vitro was effectively inhibited by 1,25(OH)<sub>2</sub>D<sub>3</sub>. Vitamin D may play a role in the growth of uterine leiomyomas.

**Key Words:** Uterine leiomyoma, vitamin D, hypovitaminosis, cell growth, in vitro

## INTRODUCTION

Uterine leiomyomas (fibroids) are the most common benign clonal tumors in the female reproductive system arising from smooth muscle cells of the uterus and containing extracellular matrix. Many fibroids are asymptomatic but their presence may be associated with pressure effects, menstrual problems, pain, miscarriage and infertility (1). Leiomyoma is a leading cause of hysterectomy in the western world (2).

The precise pathophysiology of leiomyoma remains unknown, although estrogen and progesterone are recognized as promoters of tumor growth. Chromosomal abnormalities, hormonal deregulation, and growth and angiogenic factors have all been implicated in the etiology of these clonal smooth muscle cell proliferations (3-5).

Vitamin D is a potent anti-proliferative and immunomodulatory secosteroid hormone with a well-established role in the maintenance of calcium homeostasis. Synthesis of the active form of vitamin D,  $1,25(\text{OH})_2\text{D}_3$  is through sunlight-induced conversion of 7-dehydrocholesterol to vitamin  $\text{D}_3$  and its successive hydroxylations to  $25(\text{OH})\text{D}_3$  and  $1,25(\text{OH})_2\text{D}_3$  in the liver and the kidney. The signalling of  $1,25(\text{OH})_2\text{D}_3$  is mediated via its ubiquitously expressed nuclear receptor, the vitamin D receptor (VDR), which is expressed in both the myometrium and endometrium of the human uterus throughout the menstrual cycle (6-8).

The most bioactive form of vitamin D [ $1,25(\text{OH})_2\text{D}_3$ ] modulates cell proliferation, differentiation, cancer invasion and angiogenesis (9-12). Vitamin D deficiency may stimulate cell proliferation (12). The vitamin D [ $1,25(\text{OH})_2\text{D}_3$ ]-induced antiproliferative action is mediated predominantly through a G1/S phase block of the cell-cycle.  $1,25(\text{OH})_2\text{D}_3$  regulates many of the cell cycle regulatory genes and reduces or increases the kinase activities of cyclin dependent kinases (CDKs). This results in a decreased number of cells in the S phase and an accumulation of cells in the G0-G1

phase (13-15). The cyclin dependent kinase inhibitors p21 and/or p27 are genomic targets of the 1,25(OH)<sub>2</sub>D<sub>3</sub>-VDR complex in many cell types (16, 17). 1,25(OH)<sub>2</sub>D<sub>3</sub> also blocks mitogenic signalling, including that of estrogen, EGF and IGF-1, and up-regulates growth inhibitors such as TGF (18). 1,25(OH)<sub>2</sub>D<sub>3</sub> activates VDR mediated apoptosis (19).

Despite the extensive research on the role of vitamin D in the inhibition of cell growth in a large variety of tissues, there are no reports concerning the possible growth modulatory effects of vitamin D on benign uterine tumor cells. In the present study, we evaluated the potential effects of 1,25(OH)<sub>2</sub>D<sub>3</sub> and 25(OH)D<sub>3</sub> on the growth of leiomyoma and myometrial cells in vitro.

## **MATERIALS AND METHODS**

### **Tissue Collection**

The present study was conducted with the approval of the ethical committee of Tampere University Hospital ( Institutional Review Board, IRB) and a fully informed consent was obtained from each patient prior to the surgery. Samples of benign leiomyomas and of adjacent matched myometrial tissue were obtained from six premenopausal women undergoing hysterectomy during proliferative phase of the endometrium. The mean age of the patients was 44 years (range 38 - 49) and none of them had received any hormonal therapy for at least 6 months prior to the surgery. Immediately after removal of the uterus, tissue specimens were taken from intramural leiomyoma (size range 3-5 cm) and from myometrial tissue. Tissue specimens were taken into ice-cold DMEM/F12 medium (Gibco BRL, Paisley, Scotland) supplemented with 100 IU/ml penicillin, 100 g/ml streptomycin (penicillin/streptomycin solution, Gibco BRL) and 2.5 g/ml amphotericin B (Sigma, St. Louis, MO) for transport to the laboratory. A portion of each specimen was fixed in 10% neutral buffered formalin before routine processing in paraffin blocks.

## **Cell Culture**

The tissue specimens were cut into small pieces and digested in 0.1% collagenase A (Roche, Mannheim, Germany) in culture medium (phenol red-free DMEM/F12 (Gibco) supplemented with 10% dextran-coated- charcoal-treated (DCC) FCS (Gibco) and antibiotic/antimycotic agents as described above) at 37°C overnight. The digest was passed through a wire sieve and the cells were collected by centrifugation at 1000 r.p.m. for 5 min and washed several times with fresh culture medium. The isolated cells were seeded in 75-cm<sup>2</sup> flasks in culture medium supplemented with 1nM estradiol (E<sub>2</sub>, Sigma) and propagated at 37°C in a humidified atmosphere containing 5% CO<sub>2</sub> in air. Cells from subconfluent primary or secondary cultures were used in all the experiments.

## **Immunohistochemistry**

For the immunohistochemical analysis cells were seeded in 4-chamber cell culture slides (Lab-Tek II Chamber slide, Nalge Nunc, Naperville IL) at 5000 cells/chamber and cultured until subconfluency. Thereafter the cells were fixed in 2% paraformaldehyde for 20 min at room temperature and permeabilised with pre-chilled 94% ethanol for 10 min on ice. The following mouse monoclonal antibodies were used at the dilutions indicated: anti-ER (1:100) and PR (1:300) (NovoCastra, Newcastle upon Tyne, United Kingdom), anti-vimentin (1:500), anti-smooth muscle actin (SMA; 1:100), and anti-desmin (1:100) (Dako, Glostrup, Denmark). Rat monoclonal anti-VDR antibody (1:200) was from Neo Markers (Fremont, CA). In the controls the primary antibodies were omitted and staining done with nonimmunized mouse or rat IgG. The staining was performed with a broad-spectrum Zymed Histostain-Plus kit (Zymed Laboratories, South San Francisco, CA) with the following modifications to the manufacturer's protocol: primary antibodies were incubated overnight at 4°C and biotinylated secondary antibodies for 20 min at room temperature. All washings were repeated three times, 5 min each. The cells were counterstained with hematoxylin.

The percentage of cells expressing SMA, desmin or vimentin was determined by calculating the number of immunopositive and immunonegative cells in five randomly selected microscopic fields at a magnification of x 200.

VDR was visualized in paraffin-embedded tissue samples by immunohistochemical staining of deparaffinated 5 µm sections with the rat monoclonal anti-VDR antibody (1:20). For unmasking of the epitope, the sections were boiled in a microwave oven (1000 W) in 0.01 mol/l citrate buffer (pH 6.0) for 10 min prior to application of the primary antibody. The staining procedure was as described above.

### **Cell Growth Assay**

Leiomyoma cells and matched normal myometrial cells were seeded into 96-well microtiter plates at a density of 2000 cells 200 µl well (in two cases 1000 and 1500 cells/well) and allowed to attach for 48 h in culture medium supplemented with 1 nM E<sub>2</sub>. The medium was then replaced and the cells were subjected to treatment with the indicated concentrations of 1,25(OH)<sub>2</sub>D<sub>3</sub> (kindly provided by Leo Pharmaceutical Products, Ballerup, Denmark) or 25(OH)D<sub>3</sub> (Fluka, Buchs, Switzerland) in culture medium supplemented with 1 nM E<sub>2</sub>. Ethanol vehicle was included in the control treatment. The media were renewed every three days. Relative cell numbers were assessed at 0, 3, 6, 9, 12 and 15 days using the colorimetric crystal violet assay (20). The cells were fixed on the bottom of the wells by the addition of 10 µl of 11% glutaraldehyde solution to 100 µl of medium. After 15 min, the plates were washed with de-ionised water, air-dried and stained with 0.1% solution of crystal violet for 20 min. Thereafter excess dye was washed out with deionised water and the plate was air-dried. The bound dye was then dissolved with 10% acetic acid and the optical densities of the extracts were measured at 590 nm using a Victor 1420 Multilabel Counter (Wallac, Turku, Finland). Eight determinations were used to calculate the mean optical density at each time point. The absorbance value of day 0 was set to 0 by subtracting the value for that day from each value

obtained from the subsequent timepoint measurements (days 3-15). Growth curves were created based on the basis of the resultant absorbance values. Day 9 was used to compare the effect of the hormone treatments. Means  $\pm$  SEM were calculated for each treatment and statistical differences were assessed using the Wilcoxon signed ranks test. A probability value (*P*) of 0.05 or less was considered statistically significant.

## RESULTS

### Immunohistochemical Characterization

Characterization of the cell cultures was done by immunohistochemical means with antibodies against two proteins associated with the smooth muscle phenotype, SMA and desmin, and the intermediate filament protein distinctive of the fibroblastic phenotype, vimentin. VDR-, ER- and PR- specific antibodies were employed to assess steroid receptor expression in the cultivated cells. Smooth muscle actin (Figure 1A) was shown to be expressed in  $74 \pm 8$  % (mean  $\pm$  SEM) of normal myometrial and in  $67 \pm 12$  % of leiomyoma cells, the corresponding percentage values for the desmin staining (Figure 1B) being  $9 \pm 2$  and  $8 \pm 2$ , respectively. An intense vimentin immunoreactivity was observed in all cells (Figure 1C). Whereas all the intact tissue samples expressed ER and PR (data not shown), the overall ER staining in cultured cells proved negative with the exception of a few immunopositive nuclei (Figure 1D, arrow). PR was not detected (Figure 1E). Virtually all myometrium and leiomyoma cells were positive for VDR (Figure 1F) and its staining appeared characteristically in discrete foci in the nucleus. The above steroid receptor status was shared with all the six pairs of myometrium and leiomyoma cultures studied. Control stainings were negative (data not shown). Immunohistochemical analysis of tissue samples showed that VDR was present in all leiomyoma samples (Figure 2A) and their matched myometrial specimens (Figure 2B). No clear differences in staining intensities between samples could be demonstrated.

### **Growth Pattern of Cell Cultures**

The growth curves of normal myometrial and leiomyoma cell cultures from six patients are illustrated in Figure 3. The curves show exponential growth of both cell types with no significant differences in their mean rates of proliferation. The growth rates varied markedly between individuals whereas no consistent differences were detected between the growth rates of paired myometrial and leiomyoma cell cultures originating from the same patient. The initial cell number (1000 - 2000 cells) seemed not to have an impact on the final shape of the growth curves.

### **Regulation of Myometrial and Leiomyoma Cells by 1,25(OH)<sub>2</sub>D<sub>3</sub> and 25(OH)D<sub>3</sub>**

To test the effects of 1,25(OH)<sub>2</sub>D<sub>3</sub> and 25(OH)D<sub>3</sub> on the growth of normal myometrial and leiomyoma cells, the cells were treated for 9 days with increasing doses of the two compounds as indicated in Figure 3. In both myometrial and leiomyoma cells, a similar concentration-dependent growth inhibition with 1,25(OH)<sub>2</sub>D<sub>3</sub> was detected (Figure 4A and B). In both cell types, the lowest amount of 1,25(OH)<sub>2</sub>D<sub>3</sub> tested (0.1nM) inhibited growth by 12% when compared to controls. For 1nM 1,25(OH)<sub>2</sub>D<sub>3</sub> the corresponding percentages for myometrial and leiomyoma cells were 32% and 28%, and for 10 nM 1,25(OH)<sub>2</sub>D<sub>3</sub>, 49% and 53%. The highest concentration of 1,25(OH)<sub>2</sub>D<sub>3</sub> (100 nM) inhibited growth by 62% in both cell types. All the detected differences were statistically significant ( $P < 0.05$ ).

As illustrated in Figures 4C and D, a slight stimulation of cell proliferation was observed with the lowest 25(OH)D<sub>3</sub> concentrations (10 nM and 100 nM) in some myometrial and leiomyoma cultures. When treated with the compound in a 1000 nM concentration, the growth of both cell types fell to approximately 50% of that of the control cultures, the size of the inhibition being statistically

significant ( $P < 0.05$ ). In the case of 500 nM 25(OH)D<sub>3</sub>, where the number of cultures tested was 4, statistical significance was not reached ( $P = 0.068$ ).

## DISCUSSION

Our preliminary results show that primary or secondary cultures of both normal myometrial and leiomyoma cells are highly sensitive to the growth-inhibiting effect of 1,25(OH)<sub>2</sub>D<sub>3</sub>. 1,25(OH)<sub>2</sub>D<sub>3</sub> was able significantly to suppress the growth of both cell types at a concentration as low as 0.1 nM, which lies within the physiological concentration range (48 - 156 pM) of 1,25(OH)<sub>2</sub>D<sub>3</sub> (21). These results add to previous data on the inhibitory effect of 1,25(OH)<sub>2</sub>D<sub>3</sub> on primary cultures of human cells from various organs including the prostate (21, 22) and epidermis (23).

In many cell types, low concentrations of 1,25(OH)<sub>2</sub>D<sub>3</sub> have been shown to stimulate rather than inhibit cell proliferation (23-26). Here, however, the 0.1nM concentration of 1,25(OH)<sub>2</sub>D<sub>3</sub> inhibited cell growth by as much as 12%, the percentage gradually increasing to over 60% with 100 nM 1,25(OH)<sub>2</sub>D<sub>3</sub>. Myometrial and leiomyoma cells are clearly target cells of 1,25(OH)<sub>2</sub>D<sub>3</sub>. The data are consistent with the observed expression of VDR protein in the myometrial and leiomyoma tissues and cultivated cells and our previous description of VDR mRNA expression in myometrial biopsies (8). The punctuate pattern of expression within the nuclei of cultured cells has also been observed in other cell types and may display specific binding sites of VDR to target genes (21).

By contrast, the effects of the two lowest concentrations of 25(OH)D<sub>3</sub> investigated here were growth-promoting, as previously reported in primary cells of human prostatic epithelium (22) and epidermis (23). The growth-inhibitory effect detected when a 500 nM or 1000 nM concentration of the metabolite was used may indicate local conversion of 25(OH)D<sub>3</sub> to the active metabolite 1,25(OH)<sub>2</sub>D<sub>3</sub> (27, 28). Alternatively, we have previously found evidence that 25(OH)D<sub>3</sub> itself may act as an active hormone, its growth-modulating effects being mediated via direct binding to VDR



(21). As earlier reported by Shushan et al. (2004), no significant differences in the growth patterns of leiomyoma and myometrial cells were detected in our study. Fibroid transformation in uterine smooth muscle cells did not seem to affect their susceptibility to growth inhibition by vitamin D as determined here by the colorimetric crystal violet assay specifically developed and validated for the measurement of cell number in monolayer cultures (20, 29).

We chose to use cell number as an end point as it sums up all potential effects of vitamin D on cell growth: cell cycle arrest, apoptosis and regulation of growth factor signalling, thereby giving a straightforward insight into the efficacy of vitamin D action (12). The use of additional studies is required to determine which abundant regulatory mechanisms are responsible for the precise growth-inhibitory effects of  $1,25(\text{OH})_2\text{D}_3$  and  $25(\text{OH})\text{D}_3$  in human myometrial and leiomyoma cells.

The cultures established here consisted predominantly of cells expressing smooth muscle actin. The expression of desmin, another marker of smooth muscle phenotype, was, however, detected only in a small number of cells. Immunohistochemical staining for desmin has previously been shown to decrease in uterine smooth muscle cells within a few days in culture, concomitantly with an increase in vimentin expression (30). This is in accordance with our present finding of a sparse desmin but an extensive vimentin staining, the latter most likely reflecting adaptation of the cells to a living in an in vitro environment (31). Yet, probably because of differences in culture conditions, the above mode of desmin expression has not been unanimously reported (32, 33). ER and PR were below the detection limit of the immunohistochemical method. Depending on the in vitro environment, either maintenance of ER and PR or a rapid loss of the two receptor proteins has previously been observed in human leiomyoma and myometrial cultures (34, 35).

The inhibitory effect of vitamin D on uterine smooth muscle cells has not been reported previously. We found that both leiomyoma and myometrial tissues are sensitive target organs for vitamin D their cell growth being effectively inhibited by physiological vitamin D concentrations in vitro. Whether or not this also takes place in vivo remains to be studied. A link between vitamin D status and proliferative disorders of the myometrium in vivo is an intriguing clinical possibility. More research is needed to find out whether women with hypovitaminosis D also have more uterine leiomyomas than women with efficient vitamin D supplies.

In conclusion vitamin  $1,25(\text{OH})_2\text{D}_3$  inhibits concentration-dependently the growth of myometrial and leiomyoma cells. Both myometrial and leiomyoma cells were sensitive to  $1,25(\text{OH})_2\text{D}_3$ , as suppression was already detected in the physiological vitamin D levels. Hypovitaminosis D may have an important role in the etiology and growth of leiomyoma cells.

**Acknowledgements**

We thank Mirja Hyppönen for her excellent technical assistance and Heini Huhtala, M.Sc., for statistical advice.

## REFERENCES

1. Stewart EA. Uterine fibroids. *Lancet* 2001;357:293-8.
2. Farquhar CM, Steiner CA. Hysterectomy rates in the United States 1990-1997. *Obstet Gynecol* 2002;99:229-34.
3. Flake GP, Andersen J, Dixon D. Etiology and pathogenesis of uterine leiomyomas: a review. *Environ Health Perspect* 2003;111:1037-54.
4. Arslan AA, Gold LI, Mital K, Suen TC, Belitskaya-Levy I, Tang MS, et al. Gene expression studies provide clues to the pathogenesis of uterine leiomyoma: new evidence and a systematic review. *Hum Reprod* 2005;20:852-63.
5. Shushan A, Ben-Bassat H, Mishani E, Laufer N, Klein BY, Rojansky N. Inhibition of leiomyoma cell proliferation in vitro by genistein and the protein tyrosine kinase inhibitor TKS050. *Fertil Steril* 2007;87:127-35.
6. McDonnell DP, Mangelsdorf DJ, Pike JW, Haussler MR, O'Malley BW. Molecular cloning of complementary DNA encoding the avian receptor for vitamin D. *Science* 1987;235:1214-7.
7. Baker AR, McDonnell DP, Hughes M, Crisp TM, Mangelsdorf DJ, Haussler MR, et al. Cloning and expression of full-length cDNA encoding human vitamin D receptor. *Proc Natl Acad Sci U S A* 1988;85:3294-8.
8. Vienonen A, Miettinen S, Bläuer M, Martikainen P, Tomas E, Heinonen PK, et al. Expression of nuclear receptors and cofactors in human endometrium and myometrium. *J Soc Gynecol Investig* 2004;11:104-12.
9. Schwartz GG, Wang MH, Zang M, Singh RK, Siegal GP. 1 alpha,25-Dihydroxyvitamin D (calcitriol) inhibits the invasiveness of human prostate cancer cells. *Cancer Epidemiol Biomarkers Prev* 1997;6:727-32.
10. Lokeshwar BL, Schwartz GG, Selzer MG, Burnstein KL, Zhuang SH, Block NL, et al. Inhibition of prostate cancer metastasis in vivo: a comparison of 1,25-dihydroxyvitamin D (calcitriol) and EB1089. *Cancer Epidemiol Biomarkers Prev* 1999;8:241-8.
11. Mantell DJ, Owens PE, Bundred NJ, Mawer EB, Canfield AE. 1 alpha,25-dihydroxyvitamin D(3) inhibits angiogenesis in vitro and in vivo. *Circ Res* 2000;87:214-20.
12. Ylikomi T, Laaksi I, Lou YR, Martikainen P, Miettinen S, Pennanen P, et al. Antiproliferative action of vitamin D. *Vitam Horm* 2002;64:357-406.
13. Wang QM, Jones JB, Studzinski GP. Cyclin-dependent kinase inhibitor p27 as a mediator of the G1-S phase block induced by 1,25-dihydroxyvitamin D3 in HL60 cells. *Cancer Res* 1996;56:264-7.
14. Simboli-Campbell M, Narvaez CJ, van Weelden K, Tenniswood M, Welsh J. Comparative effects of 1,25(OH)2D3 and EB1089 on cell cycle kinetics and apoptosis in MCF-7 breast cancer cells. *Breast Cancer Res Treat* 1997;42:31-41.

15. Zhuang SH, Burnstein KL. Antiproliferative effect of 1 alpha,25-dihydroxyvitamin D<sub>3</sub> in human prostate cancer cell line LNCap involves reduction of cyclin-dependent kinase 2 activity and persistent G1 accumulation. *Endocrinology* 1998;139:1197-207.
16. Hager G, Formanek M, Gedlicka C, Thurnher D, Knerer B, Kornfehl J. 1,25(OH)<sub>2</sub> vitamin D<sub>3</sub> induces elevated expression of the cell cycle-regulating genes P21 and P27 in squamous carcinoma cell lines of the head and neck. *Acta Otolaryngol* 2001;121:103-9.
17. Audo I, Darjatmoko SR, Schlamp CL, Lokken JM, Lindstrom MJ, Albert DM, et al. Vitamin D analogues increase p53, p21, and apoptosis in a xenograft model of human retinoblastoma. *Invest Ophthalmol Vis Sci* 2003;44:4192-9.
18. Colston KW, Hansen CM. Mechanisms implicated in the growth regulatory effects of vitamin D in breast cancer. *Endocr Relat Cancer* 2002;9:45-9.
19. Welsh J, Simboli-Campbell M, Narvaez CJ, Tenniswood M. Role of apoptosis in the growth inhibitory effects of vitamin D in MCF-7 cells. *Adv Exp Med Biol* 1995;375:45-52.
20. Kueng W, Silber E, Eppenberger U. Quantification of cells cultured on 96-well plates. *Anal Biochem* 1989;182:16-9.
21. Lou Y-R, Laaksi I, Syväälä H, Bläuer M, Tammela TLJ, Ylikomi T, et al. 25-Hydroxyvitamin D<sub>3</sub> is an active hormone in human primary prostatic stromal cells. *FASEB J* 2004;18:332-4.
22. Barreto AM, Schwarz GG, Woodruff R, Cramer SD. 25-Hydroxyvitamin D<sub>3</sub>, the prohormone of 1,25-dihydroxyvitamin D<sub>3</sub>, inhibits the proliferation of primary prostatic epithelial cells. *Cancer Epidemiol Biomarkers Prev* 2000;9:265-70.
23. Itin PH, Pittelkow MR, Kumar R. Effects of vitamin D metabolites on proliferation and differentiation of cultured human epidermal keratinocytes grown in serum-free or defined culture medium. *Endocrinology* 1994;135:1793-8.
24. Miettinen S, Ahonen M, Lou Y-R, Manninen T, Tuohimaa P, Syväälä H, et al. Role of 24-hydroxylase in vitamin D<sub>3</sub> growth response of OVCAR-3 ovarian cancer cells. *Int J Cancer* 2004;108:367-73.
25. Munker R, Norman A, Koeffler HP. Vitamin D compounds. Effect on clonal proliferation and differentiation of human myeloid cells. *J Clin Invest* 1986;78:424-30.
26. Love-Schimenti CD, Gibson DF, Ratnam AV, Bikle DD. Antiestrogen potentiation of antiproliferative effects of vitamin D<sub>3</sub> analogues in breast cancer cells. *Cancer Res* 1996;56:2789-94.
27. Zehnder D, Bland R, Williams MC, McNinch RW, Howie AJ, Stewart PM, et al. Extrarenal expression of 25-hydroxyvitamin D(3)-1 alpha-hydroxylase. *J Clin Endocrinol Metab* 2001;86:888-94.
28. Evans KN, Bulmer JN, Kilby MD, Hewison M. Vitamin D and placental-decidual function. *J Soc Gynecol Investig* 2004;5:263-71.

29. Gillies RJ, Didier N, Denton M. Determination of cell number in monolayer cultures. *Anal Biochem* 1986;159:109-13.
30. Palmberg L, Thyberg J. Uterine smooth muscle cells in primary culture. Alterations in fine structure, cytoskeletal organization and growth characteristics. *Cell Tissue Res.* 1986;246:253-62.
31. Virtanen I, Lehto V-P, Lehtonen E, Vartio T, Stenman S, Kurki P, et al. Expression of intermediate filaments in cultured cells. *J Cell Sci* 1981;50:45-63.
32. Broaddus RR, Xie S, Hsu C-J, Wang J, Zhang S, Zou C. The chemopreventive agents 4-HPR and DFMO inhibit growth and induce apoptosis in uterine leiomyomas. *Am J Obstet Gynecol* 2004;190:686-92.
33. Yamada T, Nakago S, Kurachi O, Wang J, Takekida S, Matsuo H, et al. Progesterone down-regulates insulin-like growth factor-I expression in cultured human uterine leiomyoma cells. *Hum Reprod* 2004;19:815-21.
34. Severino MF, Murray MJ, Brandon DD, Clinton GM, Burry KA, Novy M. Rapid loss of estrogen and progesterone receptors in human leiomyoma and myometrial explant cultures. *Mol Hum Reprod* 1996;11:823-8.
35. Shushan A, Rojansky N, Laufer N, Klein BY, Shlomain Z, Levitzki R, et al. The AG1478 tyrosine kinase inhibitor is an effective suppressor of leiomyoma cell growth. *Hum Reprod* 2004;19:1957-67.

## Legends for Figures

**FIGURE 1.** Immunohistochemical characterization of myometrial and leiomyoma cells in culture.

Both cell types displayed similar staining patterns. The pictures are representative of leiomyoma cells. The majority of the cultivated cells were SMA-positive (A). Arrows in (A) point to immunonegative cells. Less than 10% of cells were positive for desmin (B). The intermediate filament vimentin was strongly expressed in all cells (C). A few scattered nuclei (arrow) were immunopositive for ER (D). PR labelling was not detected (E). VDR immunoreactivity was localized in discrete foci within the nuclei (F). *Bar = 50  $\mu$ m.*

**FIGURE 2. Immunohistochemical localization of VDR in myometrial and leiomyoma tissues.**

VDR immunoreactivity (arrows) was localized in the nuclei of smooth muscle cells in matched myometrial (A) and leiomyoma tissues (B). *Bars 50  $\mu$ m.*

**FIGURE 3.** Growth curves of paired myometrial and leiomyoma cell cultures. Cells were seeded at

1000 - 2000 cells/well in 96-well microplates and allowed to proliferate in culture medium supplemented with 1nM estradiol for 15 days. Growth medium was renewed every third day. At three-day intervals, proliferation was determined by the colorimetric crystal violet assay.

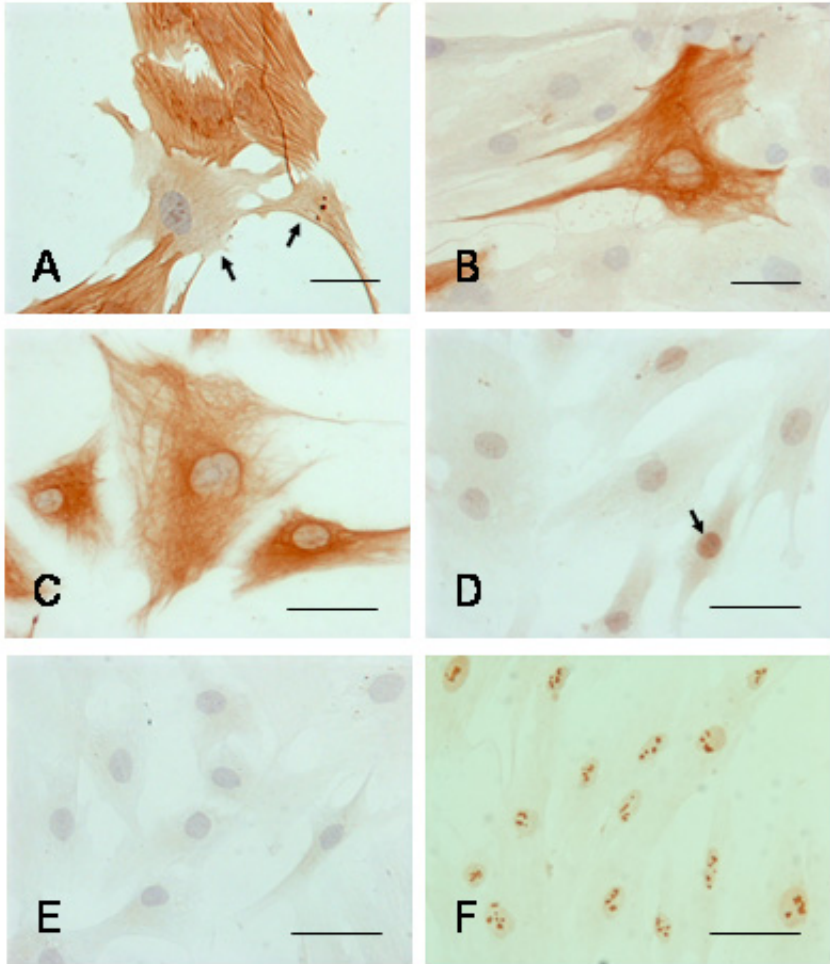
Absorbance values (ABS) were read at 590 nm. Each point represents the mean  $\pm$  SEM of cell cultures from six patients (at day 15, n = 4). Both cell types exhibited similar growth patterns with no significant differences in their mean rates of proliferation.

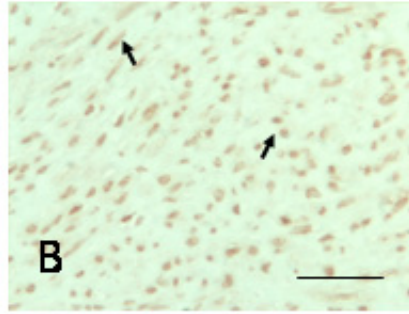
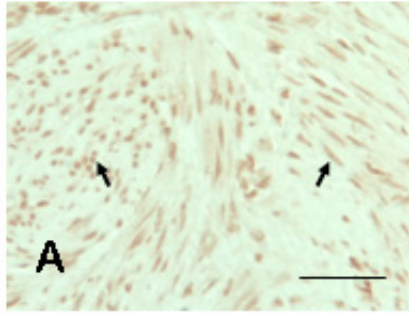
**FIGURE 4.** Effect of various concentrations of 1,25(OH)<sub>2</sub>D<sub>3</sub> (A and B) or 25(OH)D<sub>3</sub> (C and D) on

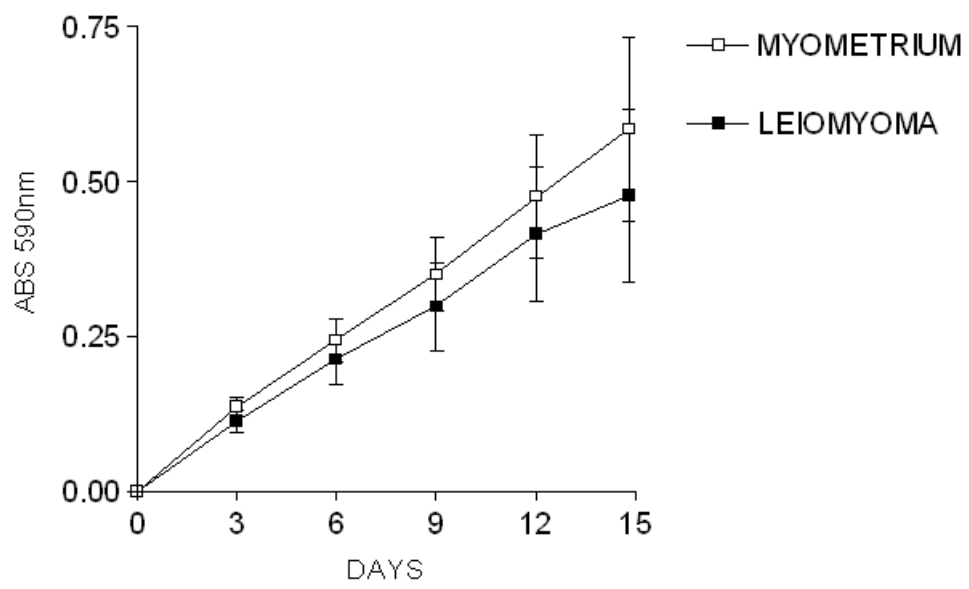
myometrial and leiomyoma cells. Proliferation was determined using the colorimetric crystal violet assay after 9 days of treatment with increasing doses of the two compounds as indicated. The cell growth is presented as a percentage of ethanol-treated controls (C on the x-axis). Six individual

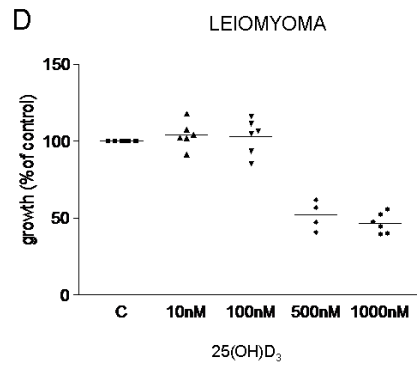
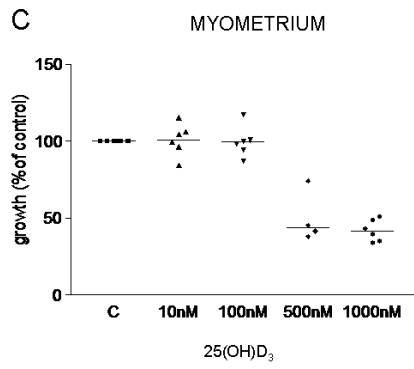
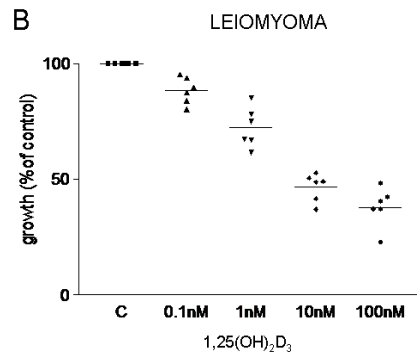
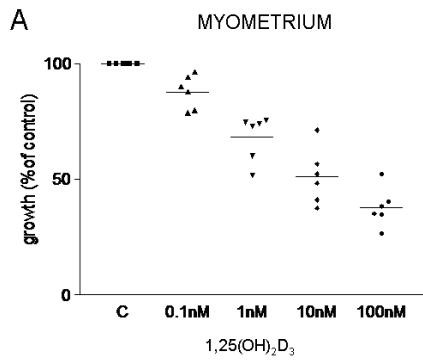
cultures were examined in each concentration (in 500 nM 25(OH)D<sub>3</sub>, n = 4). Horizontal lines represent the median..











**Ultrasonographic assessment of weight of the myomatous uterus: a pilot study using a new combined geometrical formula**

Päivi H. Rovio<sup>1</sup>, Tiina Luukkaala<sup>2</sup>, Maarit Vuento<sup>1</sup>, Sinikka Oksa<sup>1</sup>, Helena Sundström<sup>3</sup>, Pentti K. Heinonen<sup>1,4</sup>

<sup>1</sup>Department of Obstetrics and Gynecology, Tampere University Hospital, Tampere, Finland

<sup>2</sup>School of Public Health, University of Tampere, and Research Unit, Tampere University Hospital, Tampere, Finland

<sup>3</sup>Department of Obstetrics and Gynecology, Central Finland Central Hospital, Jyväskylä, Finland

<sup>4</sup>Medical School, University of Tampere, Tampere, Finland

Corresponding author: P. H. Rovio, Department of Obstetrics and Gynecology, Tampere University Hospital, P.O. Box 2000, FI-33521 Tampere, Finland.

Phone: +358 3 311 65392, FAX: +358 3 311 64360

E-mail: [paivi.rovio@pshp.fi](mailto:paivi.rovio@pshp.fi)

**Condensation**

A combination formula for the prolate ellipsoid and cylinder is more accurate in predicting the true weight of the uterus than the prolate ellipsoid formula.

**Abstract**

*Objective:* To evaluate the accuracy of a formula combining the prolate ellipsoid (uterine corpus) and cylinder (uterine cervix) formulas in estimating the preoperative weight of the total uterus using a transvaginal ultrasound probe to obtain the uterine dimensions for the formulas.

*Study Design:* Three dimensions of the uterine corpus (length, width and anteroposterior diameter) and cervical length and cervical anteroposterior diameter were preoperatively determined using a transvaginal ultrasound probe in 12 women with symptomatic leiomyomas scheduled to undergo hysterectomy. In two patients whose uteruses were the largest, part of the measurements had to be taken with a transabdominal ultrasound. Three investigators repeated all the rounds of measurements three times, producing in total 108 of findings (12 subjects x 3 investigators x 3 rounds of measurements).

The geometric formula of prolate ellipsoid was compared to a formula combining the ellipsoid and cylinder formulas for accuracy in predicting overall uterine size (corpus and cervix) through correlation with hysterectomy specimens. The weight of the uterus in grams was directly derived from the volume of the uterus.

*Results:* All measurements of the uterine corpus and cervix could be obtained preoperatively with a transvaginal ultrasound probe except in two patients who had the largest uteruses. The plain, traditional formula for the prolate ellipsoid overestimated the weight of the uterus and differences between the estimated and the true weight were statistically significant. The difference was not significant when the formula combining the formulas of the prolate ellipsoid and cylinder was used.

*Conclusion:* The new formula combining the prolate ellipsoid and cylinder formulas is more accurate in predicting the true total weight of the uterus than the plain prolate ellipsoid formula. The transvaginal ultrasound probe proved useful in evaluating the dimensions of the uterine corpus and cervix.

*Keywords:* Myomatous uterus; Ultrasonography; Uterine weight

## 1. Introduction

Estimation of the size of the uterus is an important part of the routine gynecological examination. It is necessary to exclude abnormal growth of the uterus due to benign or malignant tumors. The size of the uterus is also a crucial factor in assessing the method of hysterectomy most appropriate for the patient [1]. It is prevailing practice to estimate the size of the nongravid uterus by bimanual examination and compare it to with a pregnant uterus of comparable size. Indirect estimation of size may be attempted by sounding the uterine cavity. Even in favorable conditions the impression of the size of the uterus may remain subjective [2]. Ultrasonographic evaluation of uterine dimensions has been introduced by a number of clinicians. Earlier studies on the estimation of the volume and weight of the uterus have mainly been carried out using an abdominal ultrasound probe [1-9]. Only two researchers have estimated uterine weights with a transvaginal ultrasound probe and compared the estimates to the true weights of the excised specimens [3, 10].

The most common means of estimating the size of the uterus is to use the geometric formula of the prolate ellipsoid [2-7, 11, 12]. As the real shape of the cervix is in fact more like a cylinder than an ellipse/ellipsoid, Dumanli and associates compared the geometric formulas of these two in magnetic resonance imaging (MRI) and found the formula for a cylinder to be significantly more accurate [13]. No formula combining the geometrical formulas of the prolate ellipsoid (uterine corpus) and cylinder (uterine cervix) to estimate total uterine weight has previously been used.

The first purpose of our study was to compare the geometric formula of a prolate ellipsoid to a formula combining the formulas for the prolate ellipsoid (uterine corpus) and cylinder (uterine cervix) in regard to accuracy in predicting overall uterine size. The second was to determine the validity of transvaginal ultrasound in accurately assessing uterine size in nongravid patients with symptomatic leiomyomata through correlation with hysterectomy specimens.



## 2. Materials and Methods

### 2.1. Patients

A prospective study was conducted at the Department of Obstetrics and Gynaecology, University Hospital of Tampere, Finland. The study group comprised 12 patients with symptomatic uterine leiomyomas scheduled to undergo hysterectomy. Four of them were nulliparous. Their median age was 49.5 years (range 42-56 years) and three of them were postmenopausal. The median body mass index was 26.7 kg/m<sup>2</sup> (range 22.7-35.8 kg/m<sup>2</sup>). A written informed consent was obtained from all subjects and the study protocol was approved by the Ethics Committee of the University Hospital of Tampere.

### 2.2. Ultrasound measurements

Preoperative pelvic images were taken of each subject prior to hysterectomy by three investigators. All imaging was done using an ultrasound sector scanner (Nemio 20<sup>®</sup>, Toshiba Co., Tochigi-Ken, Japan) with a 6 MHz transvaginal probe, and with the subject supine and with an empty bladder. If the scale of the vaginal probe was not wide enough to measure the dimensions of a large uterus, a 3.75 MHz abdominal probe was used instead. The three dimensions of the uterine corpus were presented as length (L), width (W) and anteroposterior (AP) diameter. Anteroposterior diameter was determined from a sagittal scan parallel to the midline axis of the body and length by measuring from the internal os of the cervix to the dome of the fundus or mass in the same imaging plane. Cervical length (CL) was measured from the internal to the external os of the cervix and cervical anteroposterior diameter (D) was determined from the same sagittal imaging plane. The vaginal probe was then rotated parallelly to the coronal axis to view the largest cross-sectional area and to find the width of the uterine corpus at its widest point. Each physician determined all the measurements independently and repeated the rounds of measurements altogether three times

during the scanning of each patient. Thus the total number of findings were 108 (12 subjects x 3 investigators x 3 rounds of measurements).

### *2.3. Calculation of volume*

The volume of the uterine corpus was calculated from a geometric formula for a prolate ellipsoid based on the length, width and anteroposterior diameter of the corpus:  $\text{volume} = 0.5236 \times L \times W \times \text{AP}$ , where L stands for uterine length, W uterine width and AP the anteroposterior diameter of the uterus. The volume of the cervix was calculated from a geometric formula for a cylinder based on its length and anteroposterior diameter:  $\text{volume} = (D/2)^2 \times \pi \times \text{CL}$ , where D stands for cervical anteroposterior diameter and CL cervical length. The volume of the corpus and cervix were calculated together and the total volume obtained (the combination of the two formulas). To calculate the total uterine volume with the plain, traditional formula for an ellipsoid, the same ellipsoid formula was used as above, but the length (L) used in the formula was composed of the length of the corpus summed with the length of the cervix. As the density of uterine tissue is about the same as that of water (one), the uterine weight can be determined from an estimation of uterine volume with 1 mL approximately equal to 1 g of uterine tissue [6].

### *2.4. Measurements of the preparates*

At hysterectomy the uterine corpus and cervix were immediately measured after removal. Adnexes were carefully removed from the uterus and the cervix cut from the corpus before measurements. The three maximal dimensions of length, depth and width of the corpus and length and diameter of the cervix were obtained using callipers and a centimetre scale at the same axis as that described for the ultrasonographic measurements. The weights of the uterine corpus and cervix were measured with a digital scale and calculated together.

### 2.5. Statistics

The normality of the distribution of the variables studied was tested by the Kolmogorov-Smirnov test. The distributions of all variables were skewed. Values of continuous variables are expressed as median, quartile ranges and both minimum and maximum. Differences between the old and new equation compared to real weight were tested by the Wilcoxon Signed Ranks test. Statistical analyses were performed on SPSS 12.0.1 for Windows. A p-value less than 0.05 was considered statistically significant.

### 3. Results

All measurements of the uterine corpus and the cervix could be obtained preoperatively with a transvaginal ultrasound probe except in two of the 12 patients, whose uteruses were the largest (1097.4 g and 491.1 g). The ultrasound scale of the vaginal probe was not wide enough to reach the whole mass of the enlarged, myomatous uterus in these two patients and part of the measurements had to be taken with a transabdominal ultrasound probe. The median weight of the removed uterine corpus was 181.8 g (range 75.7-1074.7 g) and uterine cervix 30.2 g (range 20.5-44.5 g). The median weight of the total removed uterus (corpus and cervix) was 213.9 g (range 106.9-1097.4 g).

The differences between the real weight of the total uterus (corpus and cervix) and the weight calculated with the prolate ellipsoid formula and the weight calculated with the formula combining the prolate ellipsoid and cylinder formulas are presented in Fig. 1. The plain, traditional formula for the prolate ellipsoid tends to overestimate the weight of the uterus. The new formula combining the prolate ellipsoid and cylinder formulas is more accurate in predicting the true total weight of the uterus than the plain prolate ellipsoid formula, especially when the true weight of the uterus is less than 500 g. The difference between the weight estimated by the prolate ellipsoid formula and the true weight was statistically significant among the three investigators on most measurement

occasions (Fig. 2). No significant differences were found when the formula combining the prolate ellipsoid and cylinder formulas was used. The greatest error between the combination formula and the true weight of the uterus was found only with the largest uterus.

#### **4. Discussion**

Bimanual palpation and uterine sounding have been widely used, but gynecological ultrasound has proved to be the most accurate means of estimating the uterine dimensions [2]. Ultrasonographic estimation with a geometric formula for a prolate ellipsoid is the most common method of calculating the size of the uterus. Some investigators have measured only the length of the uterine corpus for the formula, leaving the mass of the uterine cervix outside the estimation of total uterine volume [3, 4, 11, 12]. Other investigators have measured the length of the uterus from its fundus to the external os of the cervix, the cervix being thought to lie in the ellipsoid [1-2, 5-7]. In this latter approach there is empty space in the ellipsoid around the cervix and this makes for overestimation of total uterine size. In the former system, the volume of the cervix is left outside the measurement, which in turn may cause underestimation of total uterine weight. Both methods may thus cause errors in estimation of uterine size.

Ultrasound scanning has not been used to estimate the volume of the cervix, while MRI has been employed in patients with cervical malignancy. The most common means of estimating the volume of a tumor and the cervix has been the formula for the volume of an ellipsoid [14]. Dumanli and associates proved that the volume of the cervix can be calculated significantly more accurately using the formula for a cylinder rather than an ellipsoid [13]. They measured both the anterior - posterior and transverse diameter of the cervix for the geometric formula. They reported that the average difference between these diameters was less than 1 mm. Therefore in order to simplify our method, we obtained only measurements of the anterior-posterior of the uterine cervix diameter using the formula for a cylinder.

On this basis we developed a new approach to assessing the weight of the total uterus (corpus and cervix). The assumption was that if we calculate separately the weight of the uterine corpus (formula of a prolate ellipsoid) and the cervix (formula of a cylinder) and sum the two weights together, the result would be more accurate in comparison to the true total uterine weight than if only the traditional formula for a prolate ellipsoid were used. The combination of the two formulas proved to be more accurate in predicting the true total weight of the uterus. However, the largest uteruses caused greater error in comparison to their true weight than the smaller ones. The two largest uteruses did not fit into the vaginal ultrasound scale and thus we had to take part of the measurements using an abdominal probe. This may have affected the results.

Penetration depth between a transabdominal and a transvaginal ultrasound probe is different [15]. In case of a large myomatous uterus, it may be better to measure the uterine cervix with a transvaginal probe and the uterine corpus with a transabdominal probe. Comparison of transvaginal and transabdominal assessment of the weight of the uterus is an interesting target for further study.

Previous studies have mainly been carried out on non- pathological uteruses [2, 6-8, 11]. In this preliminary study we sought to establish whether the different formulas would be equally suitable in estimating the weight of myomatous uteruses. It should be noted that the specific weight of the myoma tissue may be different from that of the normal uterine wall, and as the true weight of the myomatous uterus increases, this may cause errors in calculations. Moreover, we studied only 12 subjects, although the three investigators repeated all the rounds of measurements three times and the total number of findings was 108. Despite the limitation of a small population size, we were able to find a difference in level between the traditional ellipsoid formula and the combination formula in comparison with actual weight of the myomatous uterus.

Becker and associates used transvaginal ultrasound to obtain normal ranges of uterine dimensions for estimating the weight of the apparently normal uterus [10]. Using linear regression analysis, they derived a formula for assessing uterine weight:  $\text{uterine length} \times \text{depth} \times \text{width} \times 0.00038 + 24$ . Kung and Chang used abdominal ultrasound to measure uterine dimensions and they calculated uterine volume using the formula for the prolate ellipsoid [5]. Using linear regression analysis, they derived a formula for uterine volume and true uterine weight:  $50 + 0.71 \times \text{volume (cm}^3\text{)}$ . Comparative studies between these formulas and the method presented here are indicated.

Three-dimensional ultrasound (3D) has been introduced into clinical application for the estimation of organ volume [16-17]. 3D ultrasound can provide accurate volume measurements of regular and irregular objects and offer improved accuracy compared to the 2D method [17-18]. Chou and associates compared the accuracy of a three-(3D) and two- dimensional (2D) vaginal ultrasonography probe in estimating the volume of cervical carcinoma [19]. True cervical carcinoma volume was measured more accurately by the 3D than 2D ultrasound system. No studies comparing three- and two- dimensional vaginal ultrasonography in estimating total uterine volume have been published to date.

The transvaginal ultrasound probe proved a useful tool in assessing the dimensions of the uterus and cervix. The image is composed near the object and in contrast to using the abdominal probe, obesity does not affect the quality of the image. The formulas for the prolate ellipsoid and cylinder could be easily inserted into the computer of the ultrasound device and used in daily clinical work to estimate the preoperative weight of the total uterus.

**Acknowledgments**

This study was supported by grants from the Medical Research Funds of Tampere University Hospital and Central Finland Central Hospital, Jyväskylä, Finland.

## References

- [1] Kovac RS. Guidelines to determine the route of hysterectomy. *Obstet Gynecol* 1995;85:18-23.
- [2] Flickinger LD, D`Ablaing G, Mishell DR. Size and weight determinations of nongravid, enlarged uteri. *Obstet Gynecol* 1986;68:855-858.
- [3] Dekel A, Farhi J, Levy T et al. Preoperative ultrasonographic evaluation of nongravid, enlarged uteri - correlation with bimanual examination. *Eur J Obstet Gynecol Reprod Biol* 1998;80:205-207.
- [4] Goldstein SR, Horii SC, Snyder JR, Raghavendra BN, Subramanyam B. Estimation of nongravid uterine volume based on nomogram of gravid uterine volume: Its value in gynecologic uterine abnormalities. *Obstet Gynecol* 1988;72:86-90.
- [5] Kung F-T, Chang S-Y. The relationship between ultrasonic volume and actual weight of pathologic uterus. *Gynecol Obstet Invest* 1996;42:35-38.
- [6] Platt JF, Bree RL, Davidson D. Ultrasound of the normal nongravid uterus: Correlation with gross and histopathology. *J Clin Ultrasound* 1990;18:15-19.
- [7] Wiener JJ, Newcombe RG. Measurements of uterine volume: A comparison between measurements by ultrasonography and water displacement. *J Clin Ultrasound* 1992;20:457-460.
- [8] Piironen O. Studies in diagnostic ultrasound: Size of the non-pregnant uterus in women of childbearing age and uterine growth and foetal development in the first half of normal pregnancy. *Acta Obstet Gynecol Scand Suppl* 1975;46:26-29.
- [9] Saxton DW, Farquhar CM, Rae T, Beard RW, Anderson MC, Wadsworth J. Accuracy of ultrasound measurements of female pelvic organs. *Br J Obstet Gynaecol* 1990;97:695-699.
- [10] Becker R, Entezami M, Hese S, Vollert W, Loy V, Weizel HK. Gynäkologische Sonographie II. Normalwerte der standardisierten Uterusbiometrie. *Ultraschall Klin Prax* 1994;8:241-247.
- [11] Bakos O, Lundkvist Ö, Wide L, Bergh T. Ultrasonographical and hormonal description of the normal ovulatory menstrual cycle. *Acta Obstet Gynecol Scand* 1994;73:790-796.



- [12] Grossman M, Flynn JJ, Aufrichtig D, Handler CR. Pitfalls in ultrasonic determination of total intrauterine volume. *J Clin Ultrasound* 1982;10:17-20.
- [13] Dumanli H, Fielding JR, Gering DT, Kikinis R. Volume assessment of the normal female cervix with MR imaging: Comparison of the segmentation technique and two geometric formulas. *Acad Radiol* 2000;7:502-505.
- [14] Toita T, Kakinohana Y, Shinzato S et al. Tumor diameter/ volume and pelvic node status assessed by magnetic resonance imaging (MRI) for uterine cervical cancer treated with irradiation. *Int J Radiat Oncol Biol Phys* 1999;4:777-782.
- [15] Lyons EA, Gratton D, Harrington C. Transvaginal sonography of normal pelvic anatomy. *Rad Clin N Am* 1992;30:663-675.
- [16] Brunner M, Obruca A, Bauer P Feichtinger W. Clinical application of volume estimation based on three-dimensional ultrasonography. *Ultrasound Obstet Gynecology* 1995;6:358-361.
- [17] Riccabona M, Nelson TR, Pretorius DH, Davisodson TE. Distance and volume measurement using three- dimensional ultrasonography. *J Ultrasound Med* 1995;14:881-886.
- [18] Kyei-Mensah A, Shaker A, Zaidi J, Campell S, Pittrof R, Tan SL. Transvaginal three-dimensional ultrasound: accuracy of follicular volume measurements. *Fertil Steril* 1996;65:371-376.
- [19] Chou C-Y, Hsu K-F, Wang S-T, Huang S-C, Tzeng C-C, Huang K-E. Accuracy of three-dimensional ultrasonography in volume estimation of cervical carcinoma. *Gynecol Oncol* 1997;66:89-93.

## Legends for Figures

**Fig. 1.** Differences between the actual uterine weight and the estimated uterine weight calculated by traditional formula (A) and combination formula (B) in 12 subjects using a transvaginal ultrasound probe in evaluating the dimensions of the myomatous uterus. Medians (black line), interquartile ranges (box) and ranges (line bar) are given. Outliers and extreme findings are expressed as dots or stars. The boxplots express combined deviations of real weights of 9 measurements.

**Fig. 2.** Differences between the actual uterine weight and the estimated uterine weight calculated by two formulas in 12 subjects when 3 measurers made 3 rounds of measurements using a transvaginal ultrasound probe in evaluating the dimensions of the myomatous uterus. Medians and quartile ranges are given. Differences between formula and the real weight of the total uterus were tested by Wilcoxon Signed Ranks tests.

Figure 1.

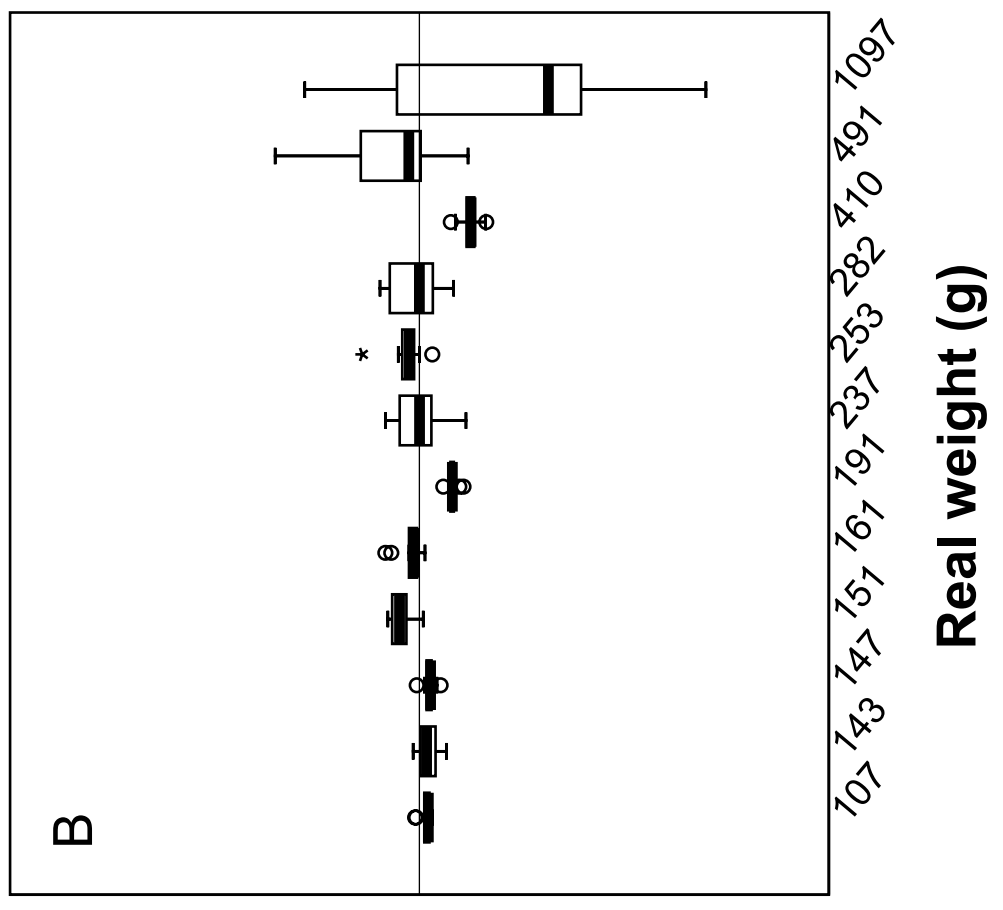
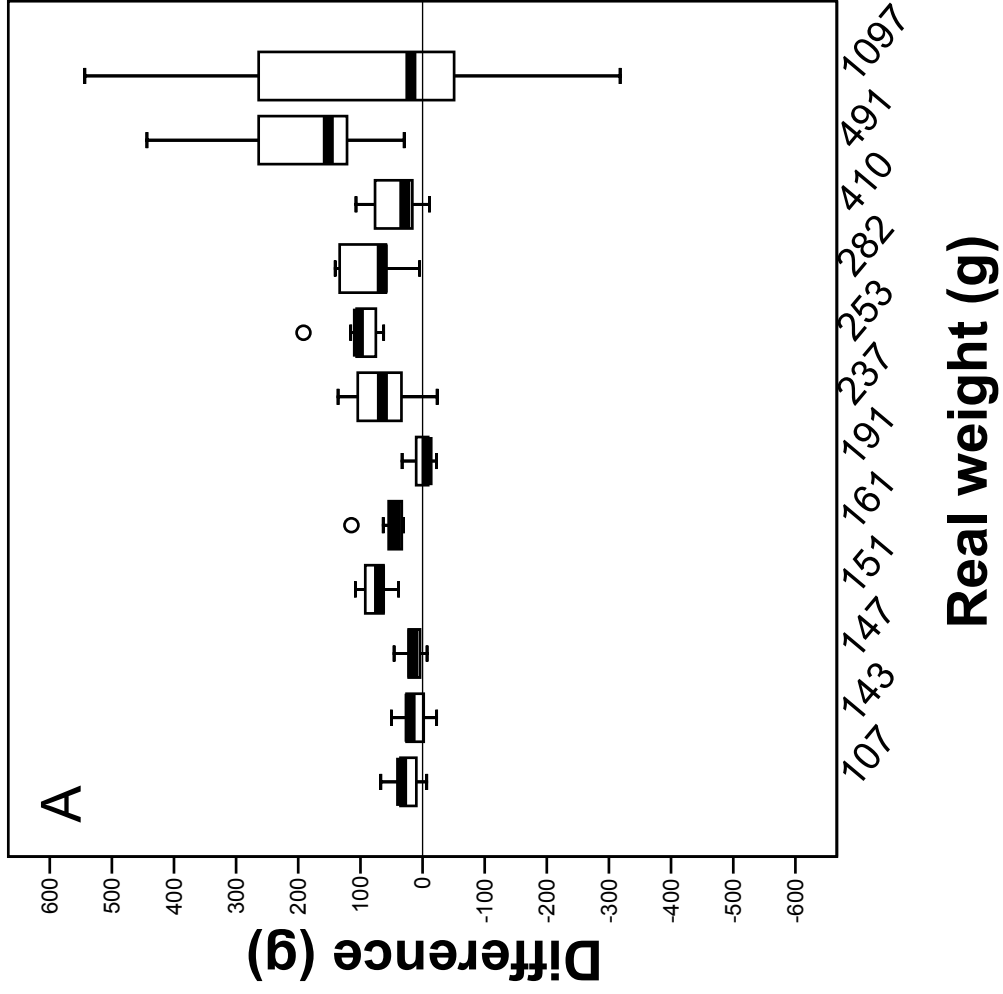
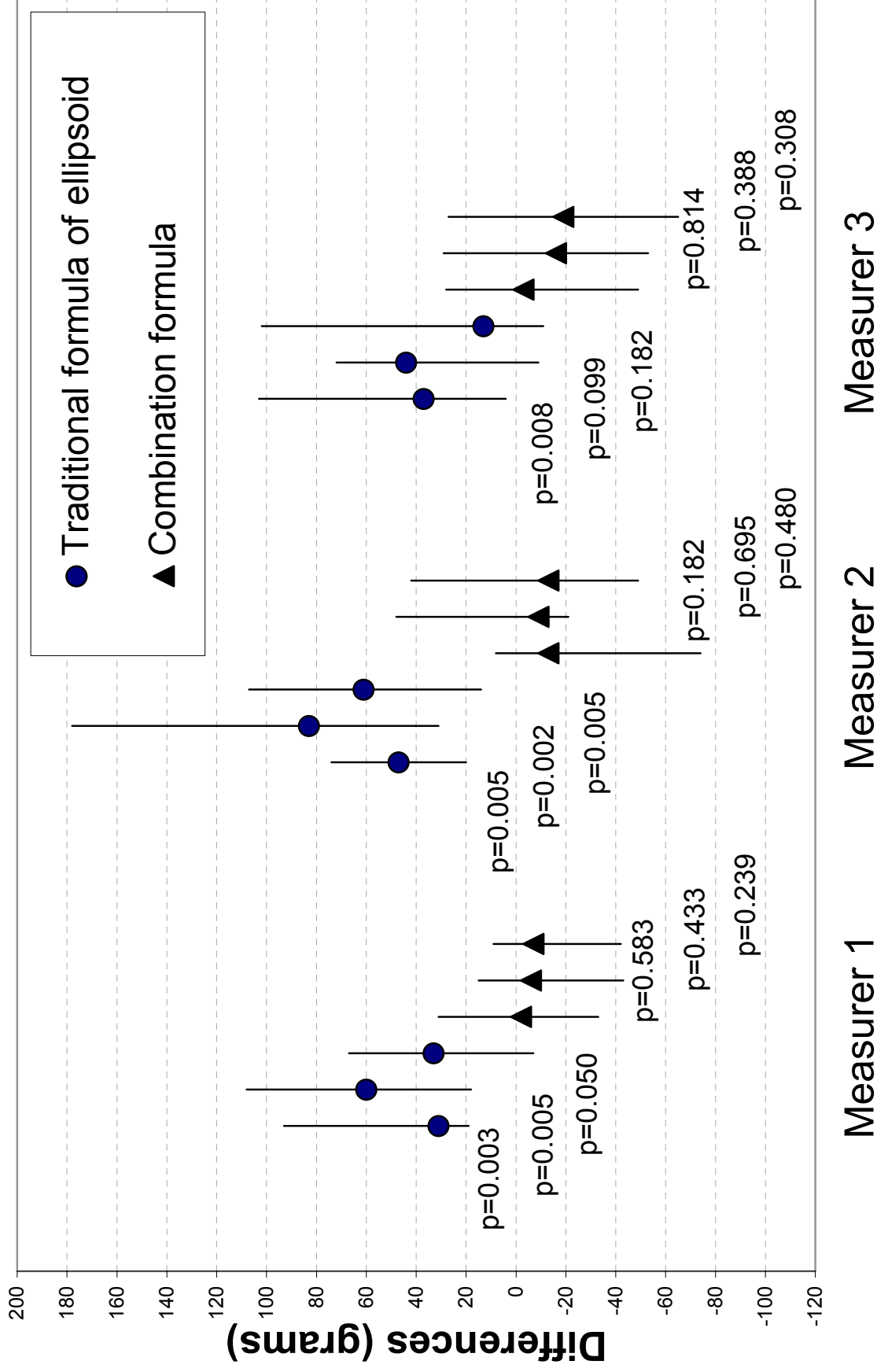


Figure 2.



Measurer 1

Measurer 2

Measurer 3

# Quality Assurance in Ultrasonographic Measurements of the Myomatous Uterus

Päivi H. Rovio<sup>\*1</sup>, Tiina Luukkaala<sup>2</sup>, Maarit Vuento<sup>1</sup>, Sinikka Oksa<sup>1</sup> and Pentti K. Heinonen<sup>1,3</sup>

<sup>1</sup>Department of Obstetrics and Gynecology, Tampere University Hospital, Tampere, Finland

<sup>2</sup>Tampere School of Public Health, University of Tampere, and Research Unit, Pirkanmaa Hospital District, Tampere, Finland

<sup>3</sup>Medical School, University of Tampere, Tampere, Finland

**Abstract:** It is important to evaluate quality control in health care. The aim of the current study was to evaluate different sources of variation in estimating the preoperative weight of the myomatous uterus by using repeatability and reproducibility (R&R) method. **Material and Methods:** Estimation of the total weight of the uterus by a formula combining the formulas for the prolate ellipsoid and cylinder was preoperatively determined using a transvaginal ultrasound probe. Three physicians repeated each round of measurements three times, producing in total 108 findings (12 subjects x 3 investigators x 3 rounds) in 12 women with symptomatic leiomyomas scheduled to undergo hysterectomy. Variation was divided into different components: physicians, patients, and repeated measurements. Variation due to differences across repeated measurements (repeatability), across physicians (reproducibility), and across patients (variability) was then estimated. The estimates of uterine weights were compared to the true weight of the hysterectomy specimen. **Results:** The more experienced the physician was in taking the ultrasound measurements the less deviation was observed between her own three measurements. Repeatability was 28 %, reproducibility 0% and patient-to-patient variation 72%. There was no significant difference between the accuracy of the measurements of the three physicians. **Conclusions:** The experience of the physician had an effect on repeatability but not on reproducibility in estimating uterine weight by ultrasound. Our results indicate the importance of conscientiousness in taking measurements of the uterus and cervix.

**Keywords:** Quality control, ultrasonography, uterine leiomyoma, uterine weight.

## INTRODUCTION

The size of the uterus has clinical significance in cases of uterine malignancy, in following up growth of myomas or when adenomyosis is suspected. It is also an important factor in assessing the hysterectomy route most appropriate for the individual patient [1]. Myomas enlarge the uterus and are the most common reason for a hysterectomy [2]. It is common gynecologic practice to estimate the size of nonpregnant enlarged uteri by bimanual examination and making a comparison with pregnant uteri of comparable size. This procedure provides a rough guide about true size of the uterus [3-4]. Ultrasonographic estimation of the volume and weight of the uterus has been introduced by a number of clinicians [3-7]. We have recently applied a new combined formula where the volume of the uterine corpus and cervix are measured separately by transvaginal ultrasound probe [8]. This proved to be a more accurate means of estimating the true volume of the total uterus than using the traditional method.

It is important to evaluate quality control in health care. This is a process which seeks to monitor and assess the actual quality of care given to an individual patient, to a certain

patient group, or to a population. When analysing and developing the quality of treatment, it is important to ensure low overall variation in the treatment process and to ascertain how this variation can be focused into different components within that process. Repeatability and reproducibility (R&R) method is widely applied in the analysis of industrial processes [9], but rarely in quality control in medicine [10].

We carried out a prospective study using R&R method to find out whether the experience of the physician has an influence on the preoperative estimation of the volume of the myomatous uterus and whether there is variation across a single physician's own measurements.

## MATERIALS AND METHODOLOGY

### Patients

The study group comprised 12 patients with symptomatic uterine leiomyomas scheduled for a hysterectomy at the Department of Obstetrics and Gynaecology, University Hospital of Tampere, Finland. Their age ranged from 42 to 56 years (median age 49.5 years) and three of patients were postmenopausal. Four used hormone replacement therapy. Body mass index ranged from 22.7 to 35.8 kg/m<sup>2</sup> (median 26.7 kg/m<sup>2</sup>) and four of the patients were nulliparous. All the subjects gave written informed consent and the study protocol was approved by the Ethics Committee of the University Hospital of Tampere.

\*Address correspondence to this author at the Department of Obstetrics and Gynecology, FI-33521, Tampere University Hospital, Finland; Tel: +358 3 3116 7682; Fax: +358 3 3116 4360; E-mail: paivi.rovio@pshp.fi

## Ultrasound Measurements

Preoperative pelvic images were taken of each subject within one week prior to hysterectomy by three physicians. One of these (physician 1) was a highly experienced senior gynecologist with oncological subspecialty. The other two physicians were resident postgraduates training in Obstetrics and Gynecology. Physician 2 was experienced in measuring uterine dimensions by vaginal and abdominal ultrasound, and the other (physician 3) was not. An ultrasound sector scanner (Nemio 20<sup>®</sup>, Toshiba Co., Tochigi-Ken, Japan) with a 6 MHz vaginal probe was used for all the imaging, with the subject supine and with an empty bladder. If the field of view of the vaginal probe was not wide enough to measure the dimensions of a large uterus, a 3.75 MHz abdominal probe was used instead. The dimensions of the uterine corpus and cervix were measured as previously described [8]. Each physician determined all the measurements independently and repeated each round of measurements three times during the scanning of each patient. Thus the total number of findings was 108 (12 subjects x 3 investigators x 3 rounds).

## Calculation of Volume

Calculation of the volume of the uterine corpus was done according to a geometric formula for a prolate ellipsoid based on the length (L), width (W) and anteroposterior diameter (AP) of the corpus:  $\text{volume} = 0.5236 \times L \times W \times \text{AP}$ . Calculation of the volume of the cervix was done according to a geometric formula for a cylinder based on its anteroposterior diameter (D) and length (CL):  $\text{volume} = \pi (D/2)^2 \times \text{CL}$ . The volume of the corpus and that of the cervix were summed and the total volume obtained.

## Measurements of the Preparates

At hysterectomy the uterine corpus and cervix were immediately measured after removal (physician 2). Fallopian tubes and ovaries were carefully removed from the uterus and the cervix cut from the corpus before measurements. The three maximal dimensions of the length, depth and width of the corpus and the length and diameter of the cervix were obtained using pair of compasses and a centimetre scale on the same axis as that described for the ultrasonographic measurements. The weights of the uterine corpus and cervix were measured with a digital scale and summed.

## Statistics

In the present study the repeatability and reproducibility (R&R) method was applied. The design of the study was experimental, the aim being estimate different sources of variation in the size of uterus by three physicians repeating the same measurements three times. Because the distribution of the difference between real and calculated weight was skewed, the range method was used.

According to the standard Gage R&R terminology physicians stand for operators, patients for parts and repeated differences between real weight and calculated weight stand for trials. In statistical terms the following variance components were estimated: repeatability (difference across measurements), reproducibility (difference across physicians) and variability (difference across patients). In other words, repeatability describes intraphysician variation, i.e., how a

given physician repeats the same planning process. Reproducibility describes interphysician variation, i.e., how different physicians follow the same planning process, and variability describes interpatient variation, i.e. how well the same physician can repeat the planning process for different kinds of patients. The total error - also known as the combined R&R effect - includes repeatability and reproducibility, and only patient-to-patient variation is excluded.

The results are presented in graphical form as range charts and summary box plots. The Repeatability & Reproducibility Summary Plot shows the individual average deviation for each physician. In the plot each trial is presented as a dot and each physician's trials are connected by a vertical line. In the range charts the warning limit is the so-called three times standard deviation (99 %) line. Observations above that limit are regarded as outliers. In the ideal case, no variation will be found due to trials or due to physicians; the only variation that exists will be due to patients. The present statistical analyses were performed by Statistica/W (Version 5.1, 98 edition, Statsoft. Inc, Tulsa, OK, USA).

## RESULTS

The weight of the total removed uterus (corpus and cervix) ranged from 106.9 to 1097.4 g (median 213.9 g). The weight of the removed uterine corpus ranged from 75.7 to 1074.7 g (median 181.8 g) and that of the uterine cervix from 20.5 to 44.5 g (median 30.2 g). Use of a transabdominal ultrasound probe was partially necessary in two patients with the largest uteruses.

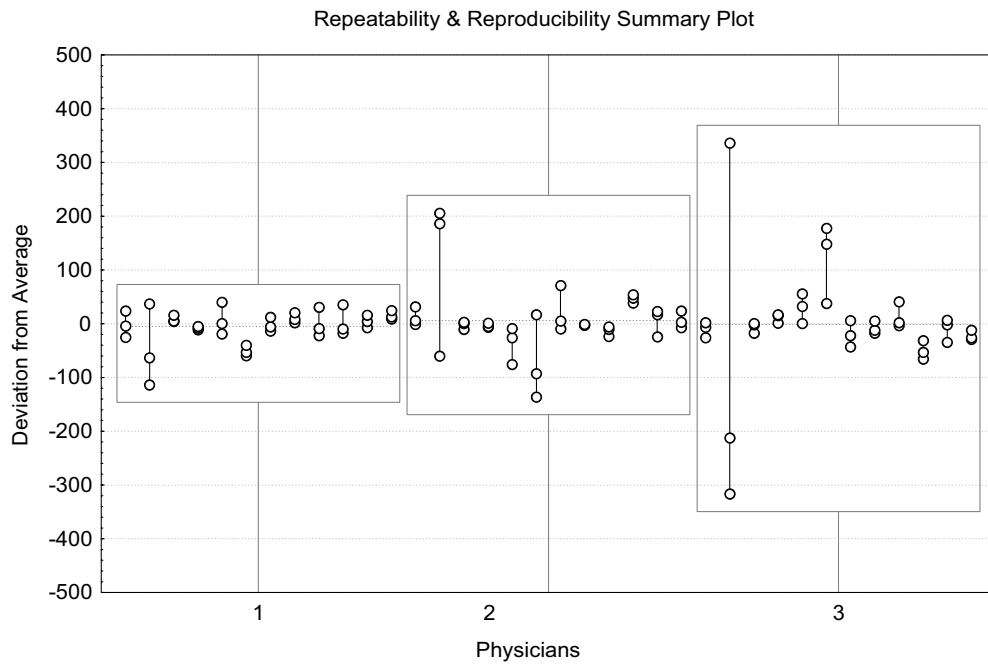
Due to combined R&R the difference error between real uterus weight and uterus weight measured by ultrasound was 28 % consisting merely of repeatability (variation across measurements). This means that physician failed to get a completely same measurement results from each three measuring round. The experience of the physician had no effect since variation due to physicians was 0 %. Patient-to-patient variation, which was 72 %, was the largest (Table 1).

**Table 1. Estimated Components of Variance in Measuring Difference Between Real Uterus Weight and Measured Weight (Number of Physicians 3, Patients 12, Measurements 3)**

Source (Expected MS)	Estimated SD	Estimated Variance	% of R & R	% of Total
Repeatability	38.46	1478.91	100.00	27.96
Reproducibility	0.00	0.00	0.00	0.00
Part to part variability	61.73	3810.82		72.04
Combined R&R	38.46	1478.91	100.00	27.96
<b>Total</b>	<b>72.73</b>	<b>5289.73</b>		<b>100.00</b>

Abbreviations: MS, Mean Score; R & R, Repeatability and Reproducibility; SD, Standard Deviation.

The largest uterus (patient 2) caused the most variation between estimated and real weight (Fig. 1). The height of the boxes around the measurements shows the variation in each physician's bias across the trials. The more experienced the physician was, the smaller was the variation. In addition, the more experienced the physician was in taking the ultrasound

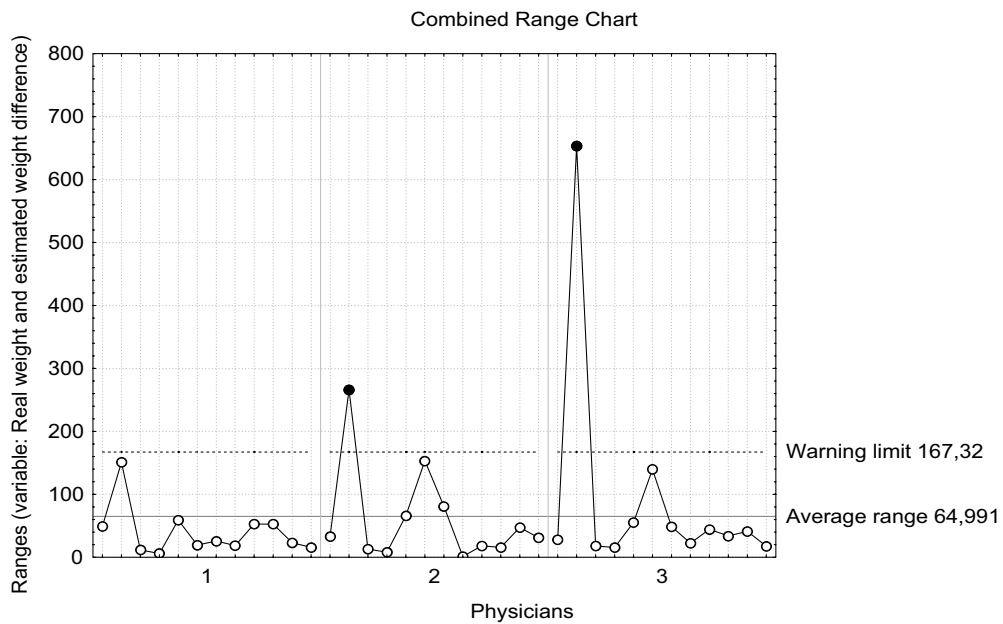


**Fig. (1).** Repeatability and reproducibility summary plot: difference of the real weight and estimated weight by combination formula. Patients are shown in study order by most experienced physician (1) to least experienced physician (3).

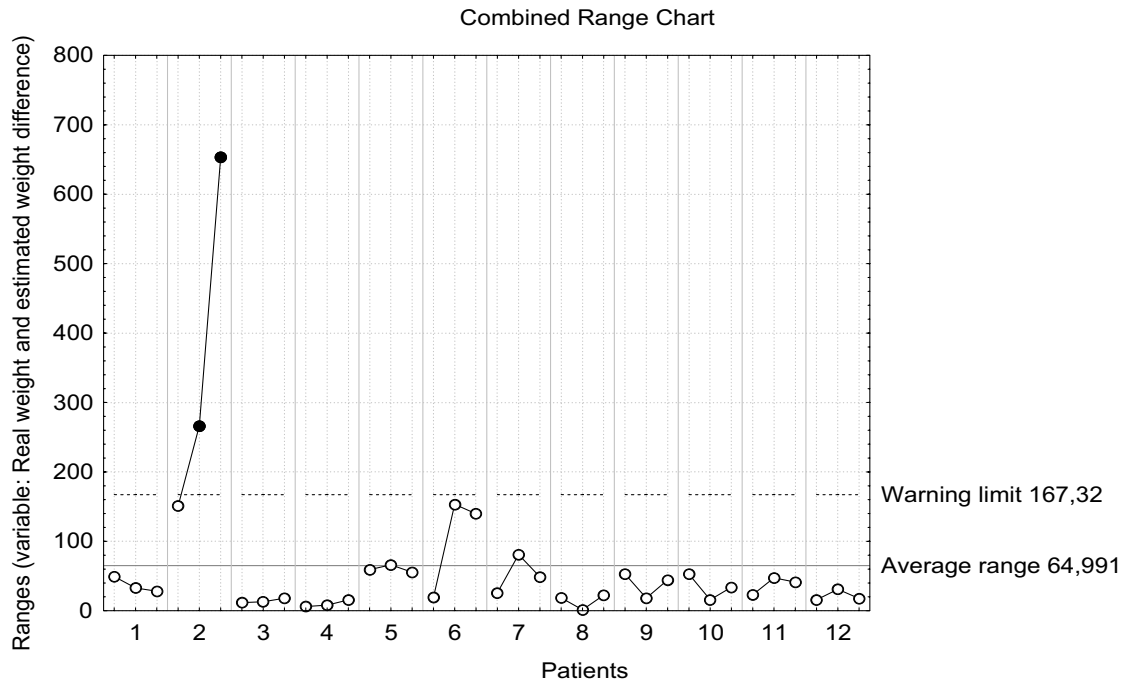
measurements the less variation there was between her own three measurements (Fig. 2). The variation between real and estimated weight in patient 2 seems to be higher than the variation in other patients, which also showed some dependence on the experience of the physician (Fig. 3).

If we remove the two patients with the largest uteruses (patients 2 and 6) from the study, the variation in the measurements of all the physicians varies very little compared to

the original study setting. The variation between measurements (repeatability) falls to 22.4 %. Combined R&R falls to 23.7 %, also including the increase in variation of 1.4 % between physicians (reproducibility). Therefore the differences both between the three physicians and between their own measurements (average range 32 grams, warning limit 82 grams) fall. The differences in the physicians' experience appears only in the measurements of the largest uteruses.



**Fig. (2).** Combined range chart: physicians by patients for difference of real weight and estimated weight by combination formula. Patients are shown in study order by most experienced physician (1) to least experienced physician (3). Warning limit presents three times standard deviation (99% of observations were below line).



**Fig. (3).** Combined range chart: patients by physicians for difference of real weight and estimated weight by combination formula. Physicians are shown by most experienced to least experienced by patients shown in study order.

## DISCUSSION

We studied patients with a myomatous uterus, as in clinical practice, they present most frequently for evaluation of uterine size, e.g. in relation to determination of the surgical approach to be used in hysterectomy [1]. We have recently reported that our formula combining the formulas for a prolate ellipsoid and a cylinder is more accurate in predicting the true total weight of the myomatous uterus than the traditional prolate ellipsoid formula alone in evaluating the dimensions of the uterine corpus and cervix with a transvaginal ultrasound probe [8].

We tested the quality of a new method for estimating the total volume of the uterus. The repeatability and reproducibility (R&R) method has rarely been used in medicine. Holli and her associates carried out a study on radiotherapy planning for breast cancer patients [10]. Eleven radiation oncologists planned radiotherapy three times for three different kinds of breast cancer patients without knowing that they were dealing with the same patient three times. Interphysician variation was not high but there were some clearly outlying physicians. The highest variation was in repeatability (intrapatient variation). Patient-to-patient variation accounted for the major part of the variation [10].

Merce and associates conducted a study to assess intraobserver and interobserver reproducibility of the parameters of ovarian response and oocyte ability and the influence of the ovarian functional stage [11]. They examined twenty-nine women with 3-dimensional ultrasonography and power Doppler angiography (PDA). They analysed ovarian volume, follicle number, vascularization index, flow index, and vascularization-flow index. They found excellent intraobserver and interobserver reproducibility for the ovarian volume, follicle counts, and 3-dimensional indices. The ovarian functional stage had no influence on reliability.

We utilized the repeatability and reproducibility method in training of ultrasound measurement of uterine volume. A combination of the volume of the uterine corpus and the volume of the cervix obtained by combining the formulas for a prolate ellipsoid and a cylinder appeared to be a useful means of estimating the actual volume of the total uterus. Despite the limitation of the small population size in this study the total number of findings (108) is sufficient for the R&R method.

Two sources of variation were identified: variation across trials (repeatability) and difference across physicians (reproducibility), and a combination of these. The more experienced the physician was in taking the ultrasound measurements the less variation there was between her own three measurements. Acceptable variation should be caused by patients. In the ideal case interphysician variation, intraphysician variation and combined repeatability and reproducibility should not exceed 10%. In our study variation between the measurements of each physician approached 30%. This may be an effect of the method of taking measurements by ultrasound. The ultrasound probe has to be rotated from the sagittal plane to the coronal axis of the organ during measurement. The probe may depart slightly from its original position during this rotation.

The two patients with the largest uteruses caused the most variation with estimated and real weight. The ultrasound scale of the vaginal probe was not wide enough to encompass the whole mass of the myomatous uterus in these patients and part of the measurements had to be taken with a transabdominal ultrasound probe. This may have affected the results. However, in the case of a large myomatous uterus it may be better to measure the uterine cervix with a transvaginal probe and the uterine corpus with a transabdominal probe. This method probably causes less variation between



estimated and real weight than use of the vaginal ultrasound probe alone.

## CONCLUSIONS

We found that every investigator was able to perform a reliable measurement of the volume of the uterus by ultrasound. The experience of the physician had an effect on repeatability but not on reproducibility in estimating uterine weight by ultrasound. Experience diminished the variability between investigator's own measurements. Our results indicate the importance of conscientiousness in taking measurements of the uterus and cervix.

## ACKNOWLEDGEMENTS

This study was supported by grants from competitive research funding of the Pirkanmaa Hospital District, Finland.

## REFERENCES

- [1] Kovac SR. Guidelines to determine the route of hysterectomy. *Obstet Gynecol* 1995; 85: 18-23.
- [2] Lepine LA, Hillis SD, Marchbanks PA, *et al.* Hysterectomy surveillance-United States, 1980-1993. *MMWR* 1997; 46: 1-15.
- [3] Flickinger LD, D'Ablaing G, III, Mishell DR, Jr. Size and weight determinations of nongravid, enlarged uteri. *Obstet Gynecol* 1986; 68: 855-8.
- [4] Saxton DW, Farquhar CM, Rae T, Beard RW, Anderson MC, Wadsworth J. Accuracy of ultrasound measurements of female pelvic organs. *Br J Obstet Gynaecol* 1990; 97: 695-9.
- [5] Goldstein SR, Horii SC, Snyder JR, Raghavendra BN, Subramanyam B. Estimation of nongravid uterine volume based on nomogram of gravid uterine volume: Its value in gynecologic uterine abnormalities. *Obstet Gynecol* 1988; 72: 86-90.
- [6] Kung F-T, Chang S-Y. The relationship between ultrasonic volume and actual weight of pathologic uterus. *Gynecol Obstet Invest* 1996; 42: 35-8.
- [7] Becker R, Entezami M, Hese S, Vollert W, Loy V, Weitzel HK. Gynäkologische Sonographie II. Normalwerte der standardisierten Uterusbiometrie. *Ultraschall Klin Prax* 1994; 8: 241-7.
- [8] Rovio PH, Luukkaala T, Vuento M, Oksa S, Sundström H, Heironen PK. Ultrasonographic weight of the myomatous uterus: a pilot study assessing a new combined geometrical formula. *Eur J Obstet Gynecol Reprod Biol* 2008; 137: 193-7.
- [9] Duncan AJ. Quality control and industrial statistics. 5th ed. Homewood, IL:Irwin; 1986.
- [10] Holli K, Laippala P, Ojala A, Pitkänen M. Quality control in health care: an experiment in radiotherapy planning for breast cancer patients after mastectomy. *Int J Radiat Oncol Biol Phys* 1999; 44: 827-33.
- [11] Merce LT, Gomez B, Engels V, Bau S, Bajo JM. Intraobserver and interobserver reproducibility of ovarian volume, antral follicle count, and vascularity indices obtained with transvaginal 3-dimensional ultrasonography, power Doppler angiography, and the virtual organ computer-aided analysis imaging program. *J Ultrasound Med* 2005; 24: 1279-87.

---

Received: March 5, 2008

Revised: June 4, 2008

Accepted: June 11, 2008

© Rovio *et al.*; Licensee *Bentham Open*.

This is an open access article distributed under the terms of the Creative Commons Attribution License (<http://creativecommons.org/licenses/by/2.5/>), which permits unrestricted use, distribution, and reproduction in any medium, provided the original work is properly cited.

## **Transvaginal myomectomy with screw traction by colpotomy**

Päivi H. Rovio · Pentti K. Heinonen

Department of Obstetrics and Gynecology, Tampere University Hospital and Medical School, FI-33014 Tampere, Finland

Running title: *Myomectomy by colpotomy*

Correspondence: P.K.Heinonen, Medical School/K-210, FI-33014 University of Tampere, Finland

e-mail: [pentti.heinonen@uta.fi](mailto:pentti.heinonen@uta.fi)

Fax: +358 3 35516164

Phone: +358 3 31164650

**Abstract**

**Introduction:** The purpose of this study was to evaluate the clinical effectiveness and safety of the enucleation of uterine leiomyomas by traction method via colpotomy.

**Methods:** Ten women with menorrhagia, pelvic pain or secondary infertility associated with single uterine myomas underwent transvaginal myomectomy with screw traction by colpotomy. The feasibility of the procedure, operative complications, postoperative recovery, pregnancies and relief of symptoms were the main outcome measures.

**Results:** Traction myomectomy was completed vaginally in all patients. The mean operating time was 71 minutes and average blood loss 385 mL. The mean size of a single myoma was 6.7 cm (range 5.6-8.0 cm), weight 153 g. One patient developed a transient hematoma. All women reported relief of their symptoms after a mean follow-up of 24 months. Three patients had a term delivery postoperatively.

**Conclusions:** Traction myomectomy by colpotomy is a feasible approach for selected patients wishing to preserve their ability to conceive. A single well-lined myoma of 5-8 cm diameter and possible to reach via colpotomy is a suitable subject for the procedure, which proved a viable surgical approach.

**Key words:** Colpotomy, leiomyoma, myomectomy

## **Introduction**

Leiomyoma is a well-lined but noncapsulated benign smooth muscle tumor of the uterus. Myoma is an important clinical problem in gynecology in that it may cause menstrual abnormalities, dysmenorrhea, pelvic pain, symptoms of pressure, infertility and miscarriage [4]. Myomectomy is the operation of choice for symptomatic women who desire to retain the potential for childbearing or for other reasons [2, 12, 13]. Abdominal myomectomy has been the prevailing option, but a variety of endoscopic alternatives have come to be widely used in removal of myomas, including laparoscopic and hysteroscopic myomectomy [9]. Uterine artery embolization is also one possible mode of treatment [7, 15].

Vaginal myomectomy is a relatively new approach [8]. This surgical technique makes possible the removal of a myoma from the uterine wall via anterior or posterior colpotomy [5]. Only few reports have been published on vaginal myomectomy [1, 3, 5, 8]. We describe a modification of this technique which is useful for non-submucous leiomyomas.

## **Patients and methods**

From January 2001 to March 2004 a pilot study was conducted at the Department of Obstetrics and Gynecology, University Hospital of Tampere, Finland, involving ten patients with single symptomatic uterine leiomyomas who were anxious to preserve their fertility. Oral informed consent was obtained from all subjects. The study protocol was approved by the Ethics Committee of the University Hospital of Tampere.

The diagnosis of leiomyomata was reached after thorough preoperative pelvic examination and transvaginal ultrasound in all patients. The size and location of the myomas were examined as accurately as possible to evaluate the patient's suitability for the operation. The inclusion criteria for vaginal myomectomy were leiomyoma palpable upon vaginal examination, good uterine mobility, adequate vaginal access, well-lined leiomyoma and no adnexal pathology detectable in preoperative transvaginal ultrasound examination. The diameter of a myoma suitable for traction

myomectomy was estimated to range from five to eight cm. One patient received GnRH agonist (goserelin acetate, AstraZeneca Co., Macclesfield, Cheshire, England) to reduce the size of the myoma. The women were apprised of the possibility of laparotomy if surgery could not be completed vaginally and of the risk of hysterectomy in the case of uncontrollable hemorrhage.

### **Surgical techniques**

All patients had general anesthesia except one who had spinal anesthesia. The women received prophylactic antibiotics (cefuroxime 1.5 g alone or with metronidazole 0.5 g intravenously) at the induction of anesthesia. Prophylactic anticoagulant therapy was not used. Patients were placed in lithotomy position and the vulva and the vagina were washed.

The posterior or anterior vaginal wall was infiltrated with 20 ml of 0.25 % lidocaine with adrenaline, and colpotomy was performed depending on the location of the myoma. After opening of the peritoneum the incision was extended laterally by digital pressure and a vaginal retractor was placed in the peritoneal cavity. The location of the uterine myoma was confirmed by digital palpation. The uterine serosa covering the myoma was grasped with Schroeder forceps and directed to the colpotomy incision. Lidocaine with adrenaline solution was infiltrated beneath the serosa covering the myoma. A midline incision was made onto the myoma up to the pseudocapsule (Figure 1A). Fixing the myoma in place by forceps a 15 or 19 cm Doyen myoma screw (Aesculap Co., Tuttlingen, Germany) was then twisted into the myoma until in place firmly. Digital palpation confirmed that screw had not penetrated through the myoma and not contacted outside the myoma or uterine serosa. The forceps were removed and constant traction maintained by screw following extraction of the myoma together with the uterine fundus through the colpotomy into the vagina (Figure 1B). The serosal surface covering the myoma was expanded to prevent uncontrolled laceration. The myoma was then enucleated and extracted under visual control (Figure 1C). The uterine incision was repaired in layers as in myomectomy in laparotomy, using conventional instruments and sutures (Figure 1D). The uterus and adnexes were carefully inspected and palpated, where after the uterus was placed in the peritoneal cavity and the colpotomy incision closed. Vaginal tamponade was not used except in two patients. Three patients used a urinary catheter, which was removed 24 hours later.

All patients were discharged within 48 hours. They were seen at the outpatient clinic two months after the operation. Those who had no outpatient contact in the hospital records were in telephone contact. The mean follow-up period was 24 months (range 5 months- 43 months). At least one vaginal ultrasound examination was performed for each patient

during that time. Data on possible symptoms, fertility and outcome of pregnancies during the follow-up periods were recorded.

## **Results**

The characteristics of the ten women are set out in Table 1. None had previous pelvic surgery. Six were nulliparous. The mean age of the patients was 32.3 years and mean body mass index 23.3 g/m<sup>2</sup> (range 19.8-29.4 kg/m<sup>2</sup>). The myoma was located posteriorly in seven cases and anteriorly in three. Preoperative ultrasound examination showed leiomyomas ranging from 5.6 to 8.0 cm in size (mean 6.7 cm). One patient with a 9.9 cm leiomyoma received GnRH agonist three months preoperatively, diminishing the leiomyoma to 8.0 cm (patient 6, Table 1).

Traction myomectomy was completed vaginally in all patients and none underwent laparotomy. Vaginal laceration did not occur in any case. The right uterosacral ligament had to be cut in two patients for better vaginal access to the myoma and the ligament was sutured to the uterus after removal of the myoma (patients 7 and 9, Table 1). The mean weight of the removed leiomyomas was 153 grams (Table 1). There were no pedunculated myomas. The endometrial cavity opened in three cases during the operation (patients 2, 5 and 6, Table 1). All patients had a single leiomyoma except for one patient (patient 3, Table 1), who underwent laparoscopic removal of intraligamentary myoma prior to vaginal myomectomy.

The mean operating time was 71 minutes and the estimated operative blood loss was 385 mL. The mean preoperative hemoglobin was 131 g/L (range 110-145 g/L), postoperative 102 g/L (range 79-125 g/L). Four women were given blood transfusions, including two who had anemia preoperatively.

Postoperative readmission to the hospital did not occur. One patient developed a four cm anterior hematoma between the cervical uterus and the bladder which however did not need operative treatment (patient 4, Table 1). One patient with anterior and posterior colpotomy had macroscopic hematuria; she used a urinary catheter for a week and her convalescence was uneventful (patient 9, Table 1).

During the follow-up period there were no signs of leiomyoma recurrence. The patients with menorrhagia reported improvement and those with abdominal pain proved asymptomatic. Three patients have conceived since the operation including two normal vaginal deliveries and one cesarean section. The interval between operation and delivery was 16, 16 and 13 months and the duration of pregnancies 270, 294 and 271 days, respectively. One woman with secondary infertility had preoperatively achieved two pregnancies after assisted reproduction treatment; after myomectomy she conceived without treatment (patient 7, Table 1) No uterine rupture has been detected in any case.

## **Discussion**

Vaginal myomectomy can be considered an alternative to myomectomy in laparotomy or in laparoscopy. Birsan and associates compared the feasibility and complications of vaginal and laparoscopic myomectomy [3]. The mean operating time was shorter and the need for postoperative analgesic treatment lower in the vaginal group. They concluded that vaginal myomectomy via colpotomy was a safe and feasible operation. Wang and coworkers reported that laparoscopically assisted vaginal myomectomy renders hemostasis and uterine repair easier than by the laparoscopic approach alone [14].

Davies and associates reported a prospective study of 35 patients who underwent anterior or posterior colpotomy and excision of a mean number of 2.5 myomas per patient with a mean mass of 114 g [5]. Agostini and associates reported a retrospective study of 45 patients from out of 40 patients underwent posterior colpotomy. Only one myoma was found in 93.3% of patients, two myomas in 2.2% and three myomas in 4.4% of patients. The mean mass of the excised myomas was 207 g [1]. Our results confirm previous findings showing the feasibility of vaginal myomectomy by colpotomy [1, 5, 8]. We refined this technique for selected cases with a single myoma, using a technique which utilizes screw traction and delivery of the myoma completely into the vagina. Traction of the myoma by screw involves extrusion of the fundal part of the uterus into the vagina without instrumental manipulation of the uterus. Enucleation of the myoma and closure of the uterine wall can be performed using conventional instruments as by laparotomic route. Morcellation and bisection of the myoma in colpotomy may be technically difficult in a narrow space, and bleeding may hamper visibility in the operation area and may predispose to injuries outside the myoma. The myoma screw has been used in laparoscopic and laparotomic myomectomies, but not the way we have used it in our study.

Preoperative evaluation of the myoma is important in selecting patients for this treatment. We estimated that a myoma diameter over five cm and less than eight cm is suitable to pull through a colpotomy without vaginal laceration and damage to adjacent structures. A screw is difficult to fix to smaller myomas and they rarely indicate myomectomy. Accurate preoperative transvaginal ultrasound scanning is important to map the myoma, to measure its diameter and to confirm that it is well-lined. Intraoperative laparoscopy is not necessary if preoperative location of the myoma is carefully performed. It is also important to ascertain by vaginal palpation that it is possible to reach the myoma during the operation and bring it to the colpotomy.



Preoperative use of GnRH agonist may reduce the diameter of the myoma for a vaginal operation. Davies and associates used this preoperative treatment in most cases (71.4 %) [5]. We administered it only in one case to reduce the myoma for vaginal removal. GnRH analogues cause softening of the myoma and surgical planes are less distinct, which makes enucleation more difficult [6]. The traction technique presumes that the instrument can be screwed firmly into the myoma and enucleation can be performed through the pseudocapsule of the myoma. For these reasons we prefer not to treat these patients preoperatively with GnRH agonist.

Posterior colpotomy is easier to perform than anterior. Davies and associates reported that posterior colpotomy was the approach in 62.5 %, compared with seven (70 %) out of ten cases in the present study [5]. Anterior colpotomy is technically the more difficult approach in that there is less space for screw traction. We have no experience of using this traction myomectomy in the case of myomas which are fundal or lateral in location. Pelosi and Pelosi [11] have described laparovaginal myomectomy to treat fundal and posterior myomas.

Difficulty of achieving hemostasis is a prominent complication associated with myomectomy [10]. Preoperative treatment of GnRH analogues can actually reduce the operative blood loss during myomectomy [6]. In addition, the size and location of the myoma, the lack of shrinkage following treatment with GnRH analogues, and the need to avoid electrosurgery in the confines of the vagina may play a part in determining operative blood loss [8]. Increased experience with the procedure reduces the operating time and the blood loss as found in the present study: the blood loss was heavier in the first cases but was reduced by practice and operations. No conversion to laparotomy was necessary and there were no serious complications.

Pelvic hematoma has been the most common postoperative complication (11 %), involved in one case in the present study [5]. A potential for infectious morbidity may be associated with

myomectomy by colpotomy [1, 11]. Use of antibiotic prophylaxis and meticulous hemostasis to prevent pelvic hematoma are cornerstones in reducing the risk of pelvic infection.

Recovery was uneventful and all patients were discharged within 48 hours postoperatively. This is comparable to data reported after laparoscopic myomectomy. Three women have delivered since the operation which confirms that the uterine wall has improved and the uterus can sustain pregnancy.

We conclude that vaginal myomectomy by traction is a feasible approach. Unlike myomectomy in laparotomy, laparoscopic myomectomy or laparoscopic-assisted transvaginal myomectomy, this approach requires no skin incisions. A single well-lined myoma with diameter of five to eight cm and accessible via colpotomy is a suitable subject for the procedure. The uterine wall closure is robust and the risk of uterine rupture may be lower than in laparoscopic myomectomy. However, randomized controlled trials are still needed to compare the vaginal route, laparoscopy and laparotomy for myomectomy.

### **Acknowledgment**

This study was supported by a grant from the Medical Research Fund of Tampere University Hospital.

## References

1. Agostini A, Deval B, Birsan A, Ronda I, Bretelle F, Roger V, Cravello L, Madelenat P, Blanc B (2004) Vaginal myomectomy using posterior colpotomy: feasibility in normal practice. *Eur J Obstet Gynecol Reprod Biol* 116:217-220
2. Berkeley AS, DeCherney AH, Polan ML (1983) Abdominal myomectomy and subsequent fertility. *Surg Gynecol Obstet* 156:319-322
3. Birsan A, Deval B, Detchev R, Poncelet C, Daraï E (2003) Vaginal and laparoscopic myomectomy for large posterior myomas: results of a pilot study. *Eur J Obstet Gynecol Reprod Biol* 110:89-93
4. Buttram VC Jr, Reiter RC (1981) Uterine leiomyomata: etiology, symptomatology, and management. *Fertil Steril* 36:433-445
5. Davies A, Hart R, Magos AL (1999) The excision of uterine fibroids by vaginal myomectomy: a prospective study. *Fertil Steril* 71:961-964
6. Friedman AJ, Rein MS, Harrison-Atlas D, Garfield JM, Doubilet PM (1989) A randomised, placebo-controlled, double blind study evaluating leuprolide acetate depot treatment before myomectomy. *Fertil Steril* 52:728-733
7. Goldberg J, Pereira L, Berghella V, Diamond J, Daraï E, Seiner P, Seracchioli R (2004) Pregnancy outcomes after treatment for fibromyomata: Uterine artery embolization versus laparoscopic myomectomy. *Am J Obstet Gynecol* 191:18-21
8. Magos AL, Bournas N, Sinha R, Richardson RE, O'Connor H (1994) Vaginal myomectomy. *Br J Obstet Gynaecol* 101:1092-1094
9. Manyonda I, Sinthamoney E, Belli A-M (2004) Controversies and challenges in the modern management of uterine fibroids. *BJOG* 111:95-102
10. Nezhat FR, Roemisch M, Nezhat CH, Seidman DS, Nezhat CR (1998) Recurrence rate after laparoscopic myomectomy. *J Am Assoc Gynecol Laparosc* 5:237-240
11. Pelosi III MA, Pelosi MA (1997) Laparoscopic-assisted transvaginal myomectomy. *J Am Assoc Gynecol Laparosc* 4:241-246
12. Rosenfeld DL (1986) Abdominal myomectomy for otherwise unexplained infertility. *Fertil Steril* 46:328-330
13. Smith DC, Uhlir JK (1990) Myomectomy as a reproductive procedure. *Am J Obstet Gynecol* 161:476-482
14. Wang C-J, Yen C-F, Lee C-L, Soong Y-K (2000) Laparoscopic-assisted vaginal myomectomy. *J Am Assoc Gynecol Laparosc* 4:510-514

15. Watson GM, Walker WJ (2002) Uterine artery embolization for the treatment of symptomatic fibroids in 114 women: reduction in size of the fibroids and women's views of the success of the treatment. *Br J Obstet Gynaecol* 109:129-135

**Table 1** Characteristics of patients, myomas and operations and postoperative outcome of 10 patients treated with traction myomectomy by colpotomy

Patient	Age (y)	Parity	Indication for operation	Myoma location	Myoma diameter (cm)	Myoma weight (g)	Operation time (min)	Blood loss (mL)	Outcome
1	27	G0P0	Growing myoma	Posterior	6.5	138	65	1000	
2	26	G2P2	Menorrhagia, pelvic pain	Anterior	8.0	300	95	1000	
3	40	G0P0	Pelvic pain	Posterior	5.9	60	135 <sup>a</sup>	150	
4	39	G0P0	Menorrhagia	Anterior	8.0	220	50	100	
5	29	G0P0	Pelvic pain, metrorrhagia	Posterior	6.0	140	40	50	Full-term pregnancy
6	26	G2P1	Miscarriage	Anterior	8.0 <sup>b</sup>	240	80	250	
7	32	G3P2	Secondary infertility	Posterior	6.8	82	35	300	Full-term pregnancy
8	37	G0P0	Pelvic pain	Posterior	5.9	145	60	400	
9	31	G1P1	Menorrhagia	Posterior	6.7	125	65	300	Full-term pregnancy
10	35	G0P0	Menorrhagia, pelvic pain	Posterior	5.6	80	85	300	

<sup>a</sup> Intraligamentary myoma also removed in laparoscopy.

<sup>b</sup> GnRh agonist administered 3 months preoperatively.

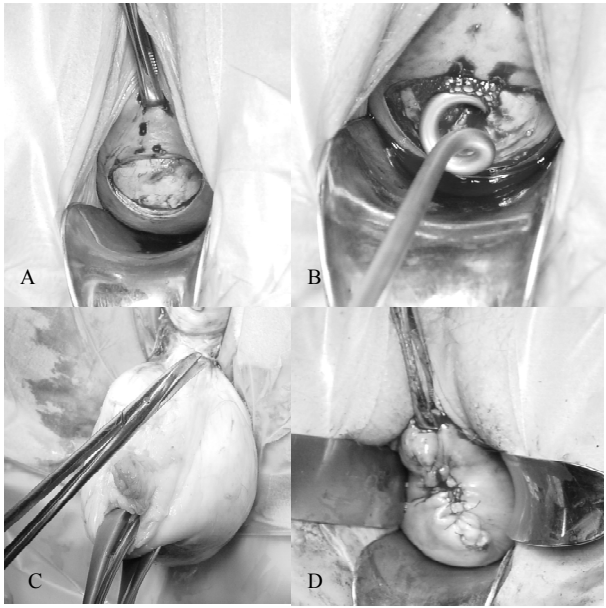


Figure 1

**Legend to the figure****Fig. 1**

Transvaginal myomectomy using screw traction via posterior colpotomy

- A. After posterior colpotomy the uterine serosa is incised using midline incision up to the pseudocapsule of the myoma
- B. Doyen myoma screw is twisted into the myoma following traction and extraction of the myoma
- C. The myoma is enucleated and extracted under visual control using conventional instruments
- D. The uterine incision is repaired in layers and the uterus is ready to be placed in the peritoneal cavity

**Long-term outcome of hysteroscopic endometrial resection with or without myomectomy in patients with menorrhagia**

Päivi H. Rovio · Riikka Helin · Pentti K. Heinonen

Department of Obstetrics and Gynecology, Tampere University Hospital and Medical School, FI-33014 Tampere, Finland

Running title: *Endometrial resection and myomectomy*

Correspondence: Päivi H. Rovio, Department of Obstetrics and Gynecology, Tampere University Hospital, FI-33521 Tampere, Finland  
e-mail: [paivi.rovio@pshp.fi](mailto:paivi.rovio@pshp.fi)



**Abstract**

*Objectives:* To evaluate the long-term outcomes and hysterectomy rates after hysteroscopic endometrial resection with or without myomectomy for menorrhagia.

*Study Design:* 53 women who had submucous myomas with intramural extension of less than 50 % and smaller than 5 cm in diameter underwent endometrial resection and concomitant hysteroscopic myomectomy. Each of them was matched with a patient who had no submucous myomas and who had been treated by endometrial resection only. These two groups were compared for operative outcomes, additional procedures, outcome of menstrual bleeding and for subsequent hysterectomy, which was the endpoint of this study.

*Results:* During the mean follow-up period of 6.5 years, 18 (34.6 %) women with endometrial resection and myomectomy and 21 (39.6 %) without myomectomy underwent at least one gynecological procedure. Hysterectomy was performed in 26.9 % (95 % CI: 16.8- 40.3) of the patients with myomectomy and in 17.0 % (95 % CI: 9.2- 29.2) of the patients without myomectomy ( $p = 0.22$ ). The main indications for hysterectomy were pain and spotting bleeding in seven out of 14 cases with myomectomy and in four out of nine with endometrial resection only. Leiomyomas were found in 12 out of the 14 women who had hysterectomy after hysteroscopic myomectomy and in four out of nine with hysterectomy after endometrial resection only ( $p = 0.06$ ). Most (75.6 %) of the 82 women who had not required hysterectomy had reached menopause. All the patients without hysterectomy in both groups reported amenorrhoea or slight bleeding, and this response maintained for years after the treatment.

*Conclusion:* Endometrial resection may be combined with hysteroscopic myomectomy without a significant increase or decrease in hysterectomy rates during a long-term follow-up.

**Keywords** Endometrial resection · Myomectomy · Hysteroscopy, · Hysterectomy · Menorrhagia

## **Introduction**

Hysteroscopic surgery is an accepted alternative to hysterectomy in the treatment of menorrhagia [1]. Several transcervical methods of endometrial ablation have been used for the purpose. Hysteroscopic resection of the endometrium is one of the oldest, and its operative outcomes, perioperative complications, and short-term follow-up results are well documented [2]. A great advantage of this technique is that it can be combined with hysteroscopic myomectomy. Submucous leiomyomas are common in patients with menorrhagia [3]. The combination of endometrial ablation and myomectomy has been reported with varying levels of success [4-6]. The long-term impact of endometrial resection combined with myomectomy is not well known.

The aim of this study was to evaluate long-term outcomes and hysterectomy rates after hysteroscopic endometrial resection with or without myomectomy for menorrhagia.

## **Materials and methods**

Study group comprised 53 women who had undergone hysteroscopic endometrial resection and myomectomy in Tampere University Hospital, Tampere, Finland between November 1990 and May 1999. Each of these women was matched retrospectively in age, parity and nearest date of operation with a patient treated by endometrial resection without myomectomy at the same period of time. The mean age (SD) of the patients with myomectomy was 44.7 (4.2) years and body mass index 25.7 (5.7) kg/m<sup>2</sup> and the patients without myomectomy 44.9 (4.7) years and 26.3 (4.9) kg/m<sup>2</sup>, respectively. Median parity

in both groups was two. Tubal ligation for sterilization had been performed in 41.5 % (myomectomy group ) and in 47.2 % (without myomectomy).

All patients suffered from menorrhagia and were candidates for hysterectomy. Cervical smear and endometrial biopsy were taken preoperatively. Women with a uterus larger than the size of a 12-week pregnancy were excluded from hysteroscopic surgery. Women with endometrial hyperplasia, uterovaginal prolapse, untreated adnexal disease, or acute pelvic inflammatory disease and those desiring future pregnancy were also excluded.

Transvaginal ultrasonography was employed to determine the size and location of myomas. All myomas were pedunculated submucous fibroids without intramural extension or sessile submucous fibroids with less than 50 % intramural extension. Patients who had submucous fibroids larger than 5 cm in diameter and fibroids with more than 50 % intramural extension were excluded from hysteroscopic surgery.

Presurgical treatment with GnRH agonist was not used in patients with leiomyomas. Preoperative endometrial suppression with hormonal therapy was used in 37 cases (34.9 %), 22 (41.5 %) with myomectomy and 15 (28.3 %) without myomectomy. Danazol was given in 19 and 12 cases, respectively, and levonorgestrel releasing intrauterine system in three cases in both groups. In other cases surgery was performed on days four to nine of the menstrual cycle.

The procedure was carried out under spinal anesthesia in 56 cases (52.8 %). The uterine cavity was distended with 2.2 % isotonic glycine (Baxter Health Care Ltd., Thetford, UK). The endometrium was resected using a 26 French unipolar resectoscope as previously described [7, 8]. Hysteroscopic myomectomy was performed prior to endometrial resection using the shaving technique in which the loop is actively drawn toward the operator while keeping the resectoscope fixed in place [9]. Complete resection was attempted in all procedures. With the intramural extension of the fibroid the resection was considered complete if the pseudocapsular tissue of the intramural part and the entire resected area could be visualized. Transabdominal or transrectal ultrasound was performed in sporadic cases to evaluate the result of the myomectomy. Fluid balance was monitored closely throughout the procedure. After surgery, the inflow and outflow volumes were measured and the glycine deficit calculated. The perioperative blood loss was estimated.

The patients' hospital records were examined to obtain details on preoperative history, operative procedures, further surgical treatment and documented follow-up. Patients who had not undergone a hysterectomy during the follow-up period were sent a postal questionnaire to assess the long-term effects. The questions concerned the need for further treatment, hormonal treatment, bleeding patterns, and success of the treatment. Patients were asked whether they had had amenorrhea, slight menstruation, or no improvement in menstrual flow or increased menstrual flow.

The mean follow-up period was 76 months (range four to 132 months) in the women with myomectomy and 79 months (five to 123 months) in those with no myomectomy. One patient with myomectomy had died for non-gynecological reason and was lost to follow-up

Subsequent hysterectomy was the endpoint and its incidence was calculated by survival analysis (Kaplan-Meier) in both groups and the curves compared by the log rank test. For the statistical analysis unpaired Student's t test for continuous data and Fisher's exact test for nominal or ordinal data were used. Statistical analysis was performed using SPSS for Windows, version 11.5 (SPSS Inc., Chicago, IL, USA). The level of significance was set at  $p < 0.05$ .

## **Results**

The duration of the operation was longer and estimated blood loss greater in patients with myomectomy than those with only endometrial resection (Table 1). One severe complication occurred in the myomectomy group. Uterine perforation occurred during the myomectomy and led to profuse hemorrhage requiring an emergency hysterectomy. Otherwise complications were minor, and were treated by antibiotics (intrauterine infection), with a Foley catheter (hemorrhage) or with a blood patch (postspinal headache).

The mean (SD) size of fibroids was 2.1 (1.1) cm (range one to five cm). Thirty-two (60.4 %) women had only one submucous fibroid and 21 had two or more. The hysteroscopic resection of a fibroid was complete in all cases except in four (7.5 %).

All the myomectomy patients had benign leiomyoma and adenomyosis was detected in four histopathology specimens. Six women without myomectomy had adenomyosis, endometrial polyps was detected in nine specimens and endometrial hyperplasia without atypia in two specimens.

Late complications occurred in seven (6.6 %) cases. In both groups three patients developed hematometra. One pregnancy occurred after endometrial resection without myomectomy, ending in spontaneous miscarriage with placenta accreta and subsequent hysterectomy.

During the follow-up period, 18 (34.6 %) out of the 52 women with myomectomy and 21 (39.6 %) out of the 53 women without myomectomy underwent at least one gynecological procedure (Table 2). Endometrial ablation was repeated in three cases in each group because of hematometra.

Hysterectomy was performed in 14 [26.9 %, 95 % confidence interval (CI): 16.8- 40.3] cases with myomectomy and in nine (17.0 %, 95 % CI: 9.2- 29.2) with endometrial resection only. Survival analysis showed in both groups a relationship between the probability of not undergoing subsequent hysterectomy and the time since the

endometrial resection procedure (Fig. 1). The difference between the groups was not statistically significant (log rank test,  $p = 0.22$ ). The mean size (SD) of the myoma resected in hysteroscopy was 2.7 (1.3) cm in patients ended in hysterectomy and the same figure among patients without hysterectomy was 2.0 (1.0) cm ( $p = 0.24$ ).

The main indications for subsequent hysterectomy were pain and spotting bleeding in seven out of 14 cases with hysteroscopic myomectomy and four out of nine patients with endometrial resection only, two with persistent menorrhagia or enlarged uterus in both groups, two with ovarian cyst in myomectomy group. One complication associated hysteroscopic surgery occurred in one case with myomectomy and one case associated with late consequence of endometrial resection (placenta accreta) indicated hysterectomy.

The mean weight of the uterus was 390 grams (range 140 -1700 grams) in patients with myomectomy and 270 grams (120 – 800 grams) in those without myomectomy.

Leiomyomas were found in 12 out of 14 women with hysterectomy after hysteroscopic myomectomy and in four out of nine women with hysterectomy after endometrial resection ( $p = 0.06$ ). Adenomyosis was confirmed in three and six cases, respectively. One patient with myomectomy had endometrial hyperplasia, but no cases of uterine malignancy were found.

Long-term follow-up data were available for 82 women who did not require hysterectomy. Nine out of the 38 women with myomectomy and 11 out of 44 without



myomectomy were premenopausal at the end of the follow-up period. All of them reported slight menstrual bleeding except one with amenorrhea.

Twenty-nine women with myomectomy and 33 without myomectomy reached menopause during the follow-up period. Fifteen women with myomectomy had used cyclical combined estrogen and progestogen regimen: 11 of them had had amenorrhoea and four slight bleeding. Ten women without myomectomy had used similar cyclical combined regimen: four reported amenorrhoea and six slight bleeding. Other postmenopausal women (14 with myomectomy and 23 without myomectomy) had amenorrhoea. They had not had hormonal replacement therapy or they had used a continuous combined regimen. Malignancy was not found in any case.

## **Discussion**

Subsequent hysterectomy was selected as the endpoint in the study because hysterectomy rates may best reflect the long-term results of hysteroscopic procedure in women suffering from menorrhagia. Our results show that with a mean follow-up period of 6.5 years, 73.1 % of the women with endometrial resection and concomitant hysteroscopic myomectomy and 83 % of the women with only endometrial resection avoided hysterectomy. Slight menstrual bleeding or amenorrhea was reported after hysteroscopic surgery, and this response maintained for years after the treatment.

After endometrial resection, hysterectomy rates of 15-24 % have been reported with a follow-up period of four years or more [10-14]. In the present study, endometrial

resection and concomitant hysteroscopic myomectomy did not significantly increase the hysterectomy rate (26.9 %) when compared with that (17.0 %) with endometrial resection only. Pooley and associates reported a cumulative hysterectomy rate of five years in women with (25.7 %) and without (27.5 %) uterine fibroids in a survey of 380 women with menorrhagia treated with transcervical resection of the endometrium [15]. Comino and Torrejón found that the existence of myomas was the only factor related to the increased possibility of subsequent hysterectomy after endometrial ablation-resection [16].

The outcomes of endometrial resection with concomitant hysteroscopic myomectomy have not been studied intensively. Loffer reported long-term outcomes of women with hysteroscopic myomectomy with concomitant endometrial ablation and without endometrial ablation [6]. Adding endometrial ablation to the resection of submucosal myomas did not decrease hysterectomy rates [6]. Our study comprised patients with menorrhagia who all underwent endometrial resection and those with submucous myomas had concomitant hysteroscopic myomectomy. Loffer reported a hysterectomy rate of 17.8 % among 73 women with hysteroscopic myomectomy and endometrial ablation and a rate of 22.1 % among 104 women with hysteroscopic myomectomy without endometrial ablation. The subsequent hysterectomy rates in the present study were 26.9 % in patients with endometrial resection and concomitant hysteroscopic myomectomy and 17.0 % in patients with endometrial resection only. These findings indicate that endometrial ablation/ resection may be combined with hysteroscopic

myomectomy without a significant increase or decrease in hysterectomy rates during a long-term follow-up.

Submucous leiomyomas have been found in 16-35 % of women with menorrhagia treated with endometrial resection [5, 10, 13, 14, 17]. It is important to map the presence of submucous myomas with a transvaginal ultrasound preoperatively and to evaluate the realistic possibility of hysteroscopic myomectomy. Submucous myomas which extended over 50 % to the uterine cavity were subjects for hysteroscopic surgery. We avoided repeated myomectomy because the uterine cavity may be narrow and adhesive after endometrial resection. Submucous leiomyomas with a more than 50 % intramural extension need repeat resection to achieve bleeding control, and they are associated with more complications [18]. In one study, incomplete removals of the myoma did not increase subsequent hysterectomy rates [6]. Dongen and associates reported that incomplete hysteroscopic myomectomy without endometrial resection does not always necessitate subsequent surgery. Instead, a wait-and-see policy may be considered [19]. Eventual necrosis and disappearance of the remaining portions of the myoma are likely [20].

Most (75.6 %) of the patients reached menopause during the long follow-up period. Postmenopausal women with cyclic combined estrogen progestogen regimen may have bleeding. In the present study, all of them reported slight bleeding or amenorrhoea. These findings indicate that the long-term impact is permanent and that endometrial resection with or without myomectomy does not merely postpone hysterectomy.

In conclusion, hysteroscopic myomectomy may be combined with endometrial resection in patients with pedunculated submucous or sessile submucous leiomyomas with intramural extension of less than 50 % and smaller than five cm in diameter without a significant increase or decrease in hysterectomy rates during a long-term follow-up.

## **Acknowledgements**

This study was supported by grants from competitive research funding of the Pirkanmaa Hospital District, Tampere, Finland.

## References

1. Abbott JA, Garry R (2002) The surgical management of menorrhagia. *Hum Reprod Update* 8(1):68-78
2. Lethaby A, Shepperd S, Cooke I, Farquhar C. Endometrial resection and ablation versus hysterectomy for heavy menstrual bleeding (Cochrane Review). In: *The Cochrane Library*, Issue 2. Wiley, Chichester, UK, 2004. pp. 1-25
3. Nagele F, O'Connor H, Davies A, Badawy A, Mohammed H, Magos A (1996) 2500 outpatient diagnostic hysteroscopies. *Obstet Gynecol* 88(1):87-92
4. Wortman M, Daggett A (1995) Hysteroscopic myomectomy. *J Am Assoc Gynecol Laparosc* 3(1):39-46
5. O'Connor H, Magos A (1996) Endometrial resection for the treatment of menorrhagia. *N Engl J Med* 335(3):151-156
6. Loffer FD (2005) Improving results of hysteroscopic submucosal myomectomy for menorrhagia by concomitant ablation. *J Minim Invasive Gynecol* 12(3):254-260
7. Tapper A-M, Heinonen PK (1995) Hysteroscopic endomyometrial resection for the treatment of menorrhagia – follow-up of 86 cases. *Eur J Obstet Gynecol Reprod Biol* 62(1):75-79
8. Tapper A-M, Heinonen PK (1999) Experience with isotonic 2.2% glycine as distension medium for hysteroscopic endomyometrial resection. *Gynecol Obstet Invest* 47(4):263-267
9. Loffer FD (1990) Removal of large symptomatic intrauterine growths by the hysteroscopic resectoscope. *Obstet Gynecol* 76(5 Pt 1):836-840

10. Engelsens IB, Woie K, Hordnes K (2006) Transcervical endometrial resection: Long-term results of 390 procedures. *Acta Obstet Gynecol Scand* 85(1):82-87
11. Aberdeen Endometrial Ablation Trials Group (1999) A randomised trial of endometrial ablation versus hysterectomy for the treatment of dysfunctional bleeding: outcome at four years. *Br J Obstet Gynaecol* 106(9):360-366
12. Cooper KG, Jack SA, Parkin DE, Grant AM (2001) Five-year follow up of women randomised to medical management or transcervical resection of the endometrium for heavy menstrual loss: clinical and quality of life outcomes. *Br J Obstet Gynaecol* 108(12):1222-1228
13. Boujida VH, Philipsen T, Pelle J, Joergensen JC (2002) Five-year follow-up of endometrial ablation: endometrial coagulation versus endometrial resection. *Obstet Gynecol* 99(6):988-992
14. Heinonen PK, Helin R, Nieminen K (2006) Long-term impact and risk factors for hysterectomy after hysteroscopic surgery for menorrhagia. *Gynecol Surg* 3(4):265-269
15. Pooley AS, Ewen SP, Sutton CJG (1998) Does transcervical resection of the endometrium for menorrhagia really avoid hysterectomy? Life table analysis of a large series. *J Am Assoc Gynecol Laparosc* 5(3):229-235
16. Comino R, Torrejon R (2004) Hysterectomy after endometrial ablation-resection. *J Am Assoc Gynecol Laparosc* 11(4):495-499
17. Gandhi SV, Fear KBC, Sturdee DW (1999) Endometrial resection: factors affecting long-term success. *Gynaecol Endosc* 8(1):41-50

18. Wamsteker K, Emanuel MH, de Kruif JH (1993) Transcervical hysteroscopic resection of submucous fibroids for abdominal uterine bleeding: results regarding the degree of intramural extension. *Obstet Gynecol* 82(5):736-740
19. Van Dongen H, Emanuel MH, Smeets MJ, Trimbos B, Jansen FW (2006) Follow-up after incomplete hysteroscopic removal of uterine fibroids. *Acta Obstet Gynecol Scand* 85(12):1463-1467
20. Dueholm M, Forman A, Ingerslev J (1998) Regression of residual tissue after incomplete resection of submucous myomas. *Gynaecol Endosc* 7(6):309-314



**Table 1** Operative details and perioperative and postoperative complications in women with endometrial resection with and without myomectomy

	Myomectomy (n = 53)	No myomectomy (n = 53)
Duration of operation, min (SD)	39 (21)	28 (10)*
Length of uterine cavity, cm (SD)	9.0 (1)	8.7 (0.9)
Estimated blood loss, mL (SD)	90 (82)	58 (62)**
Glycine used, L (SD)	6.3 (3.4)	5.3 (2.3)
Glycine deficit > 1 L (%)	0	2 (3.7)
Tubal ligation n (%)	11 (20.8)	5 (9.4)
Complication n (%)	6 (11.3)	3 (5.7)
Uterine perforation	1	0
Hemorrhage	2	1
Intrauterine infection	2	1
Postspinal headache	1	1

Values are mean (SD) or number of patients (%)

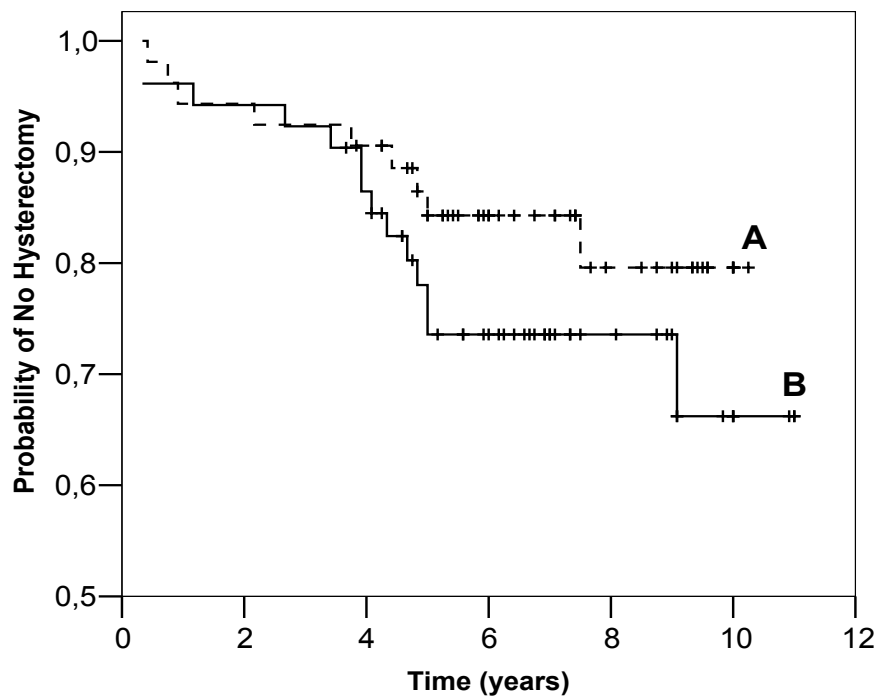
\*p < 0.001

\*\*p = 0.03

**Table 2** Further treatment after hysteroscopic endometrial resection with and without myomectomy during follow-up

Treatment	Myomectomy (n = 52)	No myomectomy (n = 53)
Any further treatment (%)	18 (34.6)	21 (39.6)
Hysterectomy	14	9
Endometrial reablation	3	3
Hysteroscopy, curettage	2	8
Cervical dilatation and drainage	1	1

Fig 1.



**Legend for the figure**

**Fig. 1** Probability of not having hysterectomy in patients with endometrial resection without myomectomy (A), and in patients with endometrial resection and concomitant myomectomy (B). Kaplan-Meier curves are illustrated (log rank test,  $p = 0.22$ ).