

Five-year follow-up of appendiceal neoplasm risk in periappendicular abscess in the Peri-Appendicitis Acuta Randomized Clinical Trial

Roosa Salminen , Tero Rautio, Pia Nordström, Tuomo Rantanen , Jari Mällinen, Juha Grönroos and Paulina Salminen

Keywords

Periappendicular abscess, appendiceal tumor, appendiceal tumor risk, complicated acute appendicitis, acute appendicitis

Date received: 25 May 2023, accepted: 18 July 2023

Introduction

Contemporary research shows alarming rates of appendiceal tumors associated with complicated acute appendicitis presenting as periappendicular abscess, and this risk is increased by patient age over 40 years.^{1–6} The Peri-Appendicitis Acuta Randomized Clinical Trial (Peri-APPAC RCT)¹ comparing interval appendectomy and follow-up with magnetic resonance imaging (MRI) after the initial successful nonoperative treatment of periappendicular abscess was prematurely terminated in 2016 owing to ethical concerns due to high appendiceal neoplasm rate in the appendectomy group with final overall neoplasm prevalence of 20% (12/60). Out of the 30 patients randomized to MRI follow-up, appendectomy was recommended to all patients. At 5 years, this study reports the long-term outcomes of the follow-up group patients declining to undergo appendectomy after study termination and all the patients diagnosed with an appendiceal tumor.

Methods

This is a post hoc follow-up of the Peri-APPAC RCT comparing interval appendectomy with

MRI follow-up for periappendicular abscess after initial successful conservative treatment in adults aged 18 to 60 years in five Finnish hospitals enrolling patients from January 2013 to April 2016. This long-term follow-up at a minimum of 5 years was added to the study protocol subsequently targeted to assess the follow-up group patients initially declining to undergo appendectomy after study termination. First, this long-term MRI follow-up was added to ensure patient safety based on the high appendiceal tumor rate at 1-year follow-up.¹ Patients gave a separate written informed consent for this imaging. Second, this observational follow-up assessed the long-term outcomes of the trial patients initially diagnosed with an appendiceal tumor by reviewing their medical records. The detailed methods and primary results have been previously published.¹ The difference between groups in age was tested using Mann–Whitney U-test. The study was approved by the Ethical Committee of Turku University Hospital district and conducted in accordance with the Declaration of Helsinki following the relevant portions of the Consolidated Standards of Reporting Trials (CONSORT) reporting guideline.

Scandinavian Journal of Surgery
2023, Vol. 112(4) 265–268
© The Finnish Surgical Society 2023
Article reuse guidelines:
sagepub.com/journals-permissions
DOI: 10.1177/14574969231192128
journals.sagepub.com/home/sjs



Corresponding author:

Paulina Salminen

Division of Digestive Surgery and Urology
Turku University Hospital
P.O. Box 52
Turku 20520
Finland

Department of Surgery
University of Turku
Turku
Finland

paulina.salminen@tyks.fi

Roosa Salminen

Department of Surgery, University of Oulu, Oulu, Finland

Tero Rautio

Department of Surgery, University of Oulu, Oulu, Finland

Division of Operative Care, Oulu University Hospital and Medical Research Center Oulu, University of Oulu, Oulu, Finland

Pia Nordström

Division of Surgery, Gastroenterology and Oncology, Tampere University Hospital, Tampere, Finland

Tuomo Rantanen

Department of Surgery, Kuopio University Hospital, Kuopio, Finland

Division of Digestive Surgery and Urology, Turku University Hospital, Turku, Finland

Jari Mällinen

Department of Surgery, University of Oulu, Oulu, Finland

Division of Operative Care, Oulu University Hospital and Medical Research Center Oulu, University of Oulu, Oulu, Finland

Juha Grönroos

Division of Digestive Surgery and Urology, Turku University Hospital, Turku, Finland

Department of Surgery, University of Turku, Turku, Finland



Creative Commons CC BY: This article is distributed under the terms of the Creative Commons Attribution 4.0 License

(<https://creativecommons.org/licenses/by/4.0/>) which permits any use, reproduction and distribution of the work without further permission provided the original work is attributed as specified on the SAGE and Open Access pages (<https://us.sagepub.com/en-us/nam/open-access-at-sage>).

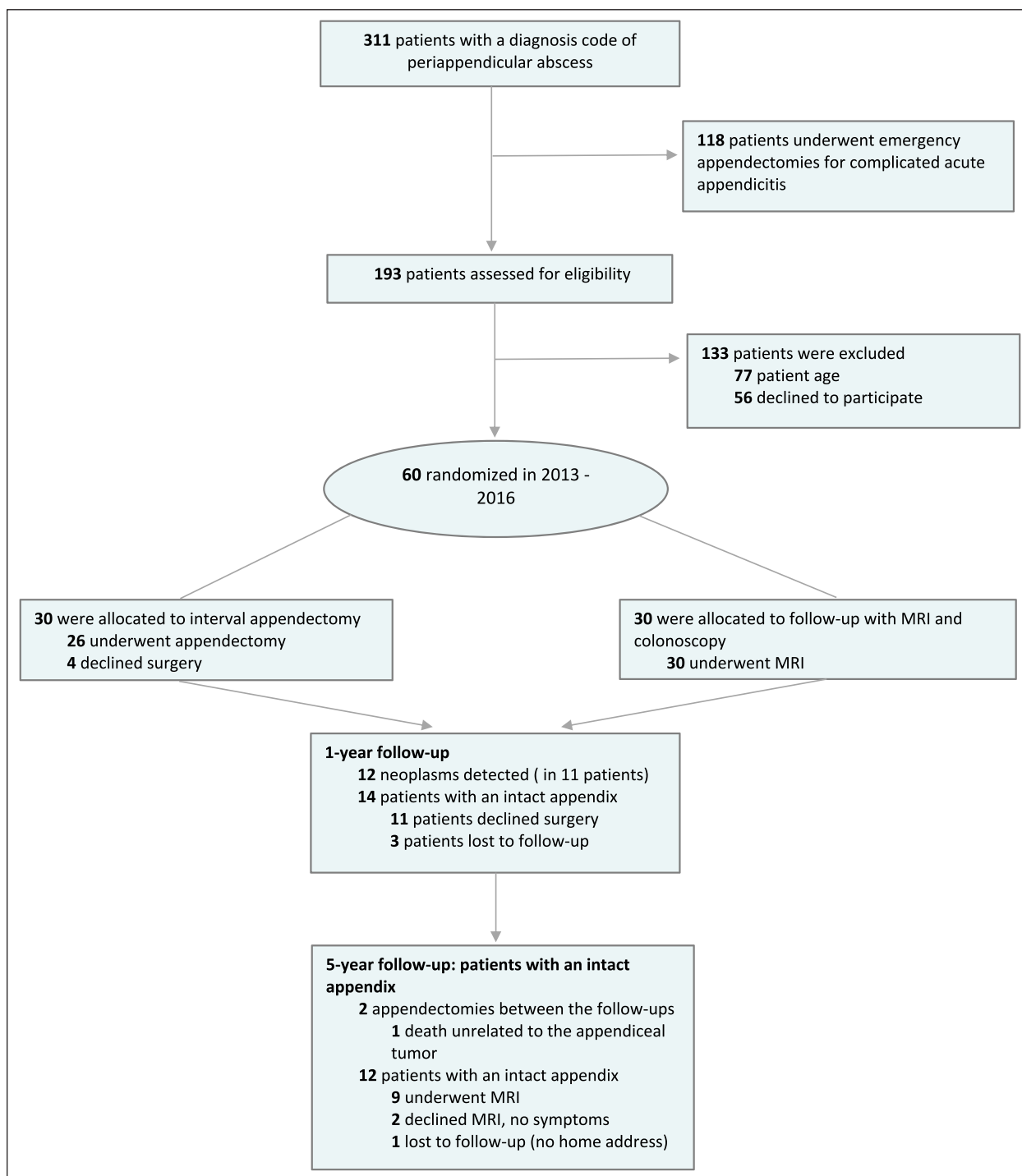


Fig. 1. Peri-APPAC trial patient flow-chart at 5-year follow-up.
Peri-APPAC: The Peri-Appendicitis Acuta.

Results

Out of the 14 patients with an intact appendix, two had undergone appendectomy after the initial follow-up with no appendiceal tumor findings (Fig. 1). Nine out of the remaining 12 patients with an intact appendix underwent MRI with normal

findings. The median age of these patients was 35 years (range 22-58 years), and detailed patient characteristics are presented in Table 1.

Overall initial appendiceal neoplasm rate after premature termination and surgical treatment of the MRI group patients consenting to appendectomy was 20% (12/60, 12 neoplasms in 11 patients).¹ At 5 years, 3 out of these 11

Table 1. Characteristics of patients with an intact appendix at 5 years and with an initial diagnosis of an appendiceal neoplasm in 2013 – 2016.

Characteristics of patients with intact appendix				
Patient: sex/age	Long-term follow-up	MRI imaging/findings or reason why not		
F/31	82 months	Yes/Appendix could not be visualized, no tumor suspicion		
M/30	95 months	Yes/Normal		
F/58	83 months	Yes/Normal		
F/31	86 months	Yes/Pancreatic cancer, liver metastasis		
M/26	103 months	Yes/Normal		
F/44	90 months	Yes/Normal		
F/25	81 months	Yes/Normal		
F/49	80 months	Yes/Normal		
F/36	92 months	Yes/Normal		
M/47		No/Appendectomy 2016, death in 2017 due to other undefined gastrointestinal malignancy		
M/22		No/Declined MRI imaging, asymptomatic		
M/53		No/Lost to follow-up (could not be reached)		
M/43		No/Appendectomy 2016, normal histopathology		
M/34		No/Declined MRI imaging, asymptomatic		
Five-year follow-up of patients with an initial diagnosis of an appendiceal neoplasm				
Patient: sex/age	Reason for intervention	Intervention/primary 1 year follow-up ^a	Histological findings	Five-year follow-up
F/56	Allocated intervention	Appendectomy/cytoreductive surgery and hyperthermic intraperitoneal chemotherapy (HIPEC)	LAMN and pseudomyxoma peritonei	Follow-up continues, last CT in 2022
M/47	Allocated intervention	Appendectomy/surveillance	LAMN	No follow-up needed after one-time follow-up CT in 2013
M/59	Allocated intervention	Appendectomy/surveillance colonoscopy	Sessile serrated adenoma	No follow-up needed after one-time colonoscopy in 2016
M/59	Recurrent symptoms	Ileocecal resection/right hemicolectomy	Adenocarcinoma of the appendix	CT in 2016 with normal findings, no follow-up after 2018
M/59	Recurrent symptoms	Appendectomy/ileocecal resection	LAMN	No follow-up needed after initial surgery
M/61	Recurrent symptoms	Appendectomy/surveillance	Mucinous cystadenoma	No follow-up needed after initial surgery
M/55	Recurrent symptoms	Appendectomy/cytoreductive surgery and hyperthermic intraperitoneal chemotherapy	Goblet cell carcinoid	Adjuvant treatments postoperatively, died of disseminated disease in 2017
F/58	MRI tumor suspicion	Appendectomy/surveillance	Sessile serrated adenoma	Diagnosed with intestinal T-cell lymphoma in 2017, died of lymphoma-related duodenal perforation in 2018
F/53	CT tumor suspicion	Chemotherapy/right hemicolectomy (palliative, disseminated disease at diagnosis)	Caecal adenocarcinoma and sessile serrated appendiceal adenoma	Palliative oncological therapy 2015–2016, died of disseminated disease in 2017
M/61	Recommended appendectomy after study termination	Appendectomy/surveillance	LAMN	Latest CT in 2017 with normal findings, no further follow-up needed
F/41	Recommended appendectomy after study termination	Appendectomy/surveillance	LAMN	Colonoscopy in 2016 with normal findings, no further follow-up needed

MRI: magnetic resonance imaging; F: female; M: male; LAMN: low-grade appendiceal mucinous neoplasm; CT: computed tomography.

^aMallinen et al.

patients had died, with two deaths related to the appendiceal neoplasm. In the remaining eight patients with appendiceal neoplasms, the long-term follow-up at 5 years after

the appendectomy was uneventful (Table 1). The median age of the patients with an appendiceal tumor was significantly higher than that of the patients with an intact

appendix undergoing MRI imaging (58 years versus 35 years, $p < 0.001$).

Discussion

Based on the premature termination of the Peri-APPAC RCT in 2016 due to the high rate of appendiceal neoplasms in the interval appendectomy group, the long-term imaging follow-up of the MRI group patients declining to undergo appendectomy was added to the study protocol to ensure patient safety and ethical conduct of clinical trials. At 5 years, there were no additional appendiceal tumors detected at MRI imaging or in the two additional appendectomies performed between the 1- and 5-year follow-up. The patients declining to undergo appendectomy even after a strong recommendation after study termination were statistically significantly younger than the patients diagnosed with an appendiceal tumor. The main limitation of this study is the small number of patients based on the premature study termination.

This long-term follow-up underlines the patient age as a major factor for an appendiceal tumor risk associated with a periappendicular abscess also demonstrated by the initial report and other studies.^{5,6} The rate of appendiceal neoplasms needs to be validated by large prospective cohort studies to further define the necessity of interval appendectomy in all age groups.

Authors' note

The funders had no role in the design and conduct of the study; collection, management, analysis, and interpretation of the data; preparation, review, or approval of the manuscript; and decision to submit the manuscript for publication. The trial is registered on ClinicalTrials.gov, Peri-APPAC (NCT 03013686).

Author contributions

P. Salminen and R. Salminen had full access to all the data in the study and take full responsibility for the integrity of the data and the accuracy of the data analyses. Dr P. Salminen had the final responsibility for the decision to submit the manuscript for publication. Concept and design: P. Salminen, R. Salminen, Rautio; acquisition, analysis, or interpretation of data: P. Salminen, R. Salminen, Rautio; drafting of the manuscript: R. Salminen, P. Salminen; critical revision of the manuscript for important intellectual content: P. Salminen, Rautio, Grönroos, Nordström, Rantanen, Mällinen; statistical analysis: P. Salminen, R. Salminen; funding: P. Salminen;

administrative, technical, or material support: P. Salminen, Rautio; supervision: P. Salminen, Rautio.

Declaration of conflicting interests

The author(s) declared the following potential conflicts of interest with respect to the research, authorship, and/or publication of this article: Dr Paulina Salminen reported lecture fees from Novo Nordisk. No other disclosures were reported.

Funding

The author(s) disclosed receipt of the following financial support for the research, authorship, and/or publication of this article: This study was supported by the Sigrid Jusélius Foundation.

Data sharing statement

The data requests can be directed to the primary investigator and will be evaluated by the study group.

ORCID iDs

Roosa Salminen  <https://orcid.org/0009-0001-9925-3993>

Tuomo Rantanen  <https://orcid.org/0000-0001-6390-1373>

References

1. Mallinen J, Rautio T, Grönroos J et al: Risk of appendiceal neoplasm in periappendicular abscess in patients treated with interval appendectomy vs follow-up with magnetic resonance imaging: 1-year outcomes of the peri-appendicitis acuta randomized clinical trial. *JAMA Surg* 2019;154(3):200–207.
2. Furman MJ, Cahan M, Cohen P et al: Increased risk of mucinous neoplasm of the appendix in adults undergoing interval appendectomy. *JAMA Surg* 2013;148(8):703–706.
3. Peltrini R, Cantoni V, Green R et al: Risk of appendiceal neoplasm after interval appendectomy for complicated appendicitis: A systematic review and meta-analysis. *Surgeon* 2021;19:e549–e558.
4. Hayes D, Reiter S, Hagen E et al: Is interval appendectomy really needed? A closer look at neoplasm rates in adult patients undergoing interval appendectomy after complicated appendicitis. *Surg Endosc* 2021;35(7):3855–3860.
5. Naar L, Kim P, Byerly S et al: Increased risk of malignancy for patients older than 40 years with appendicitis and an appendix wider than 10 mm on computed tomography scan: A post hoc analysis of an EAST multicenter study. *Surgery* 2020;168(4):701–706.
6. Alajääski J, Lietzén E, Grönroos JM et al: The association between appendicitis severity and patient age with appendiceal neoplasm histology—a population-based study. *Int J Colorectal Dis* 2022;37(5):1173–1180.