

Available online at [www.sciencedirect.com](http://www.sciencedirect.com)

ScienceDirect

journal homepage: [www.elsevier.com/locate/survophthal](http://www.elsevier.com/locate/survophthal)

## Review article

# Future directions in managing aniridia-associated keratopathy



Arianne J.H. van Velthoven <sup>a,b</sup>, Tor P. Utheim, M.D. Dr. <sup>c,d</sup>,  
 Maria Notara, Dr. <sup>e</sup>, Dominique Bremond-Gignac, M.D. Dr. <sup>f,g</sup>,  
 Francisco C. Figueiredo, M.D. Dr. <sup>h,i</sup>, Heli Skottman, Dr. <sup>j</sup>,  
 Daniel Aberdam, Dr. <sup>g</sup>, Julie T. Daniels, Dr. <sup>k</sup>, Giulio Ferrari, M.D. Dr. <sup>l</sup>,  
 Christina Grupcheva, M.D. Dr. <sup>m</sup>, Carina Koppen, M.D. Dr. <sup>n</sup>,  
 Mohit Parekh, Dr. <sup>o</sup>, Thomas Ritter, Dr. <sup>p</sup>, Vito Romano, Dr. <sup>q</sup>,  
 Stefano Ferrari, Dr. <sup>r,\*</sup>,<sup>1</sup>, Claus Cursiefen, M.D. Dr. <sup>e,s</sup>,<sup>1</sup>, Neil Lagali, Dr. <sup>t</sup>,<sup>1</sup>,  
 Vanessa L.S. LaPointe, Dr. <sup>a</sup>,<sup>1</sup>, Mor M. Dickman, M.D. Dr. <sup>a,b</sup>,<sup>1</sup>

<sup>a</sup> MERLN Institute for Technology-Inspired Regenerative Medicine, Maastricht University, Maastricht, the Netherlands

<sup>b</sup> University Eye Clinic Maastricht, Maastricht University Medical Center+, Maastricht, the Netherlands

<sup>c</sup> Department of Medical Biochemistry, Oslo University Hospital, Oslo, Norway

<sup>d</sup> Department of Ophthalmology, Oslo University Hospital, Oslo, Norway

<sup>e</sup> Department of Ophthalmology, Faculty of Medicine and University Hospital Cologne, Cologne, Germany

<sup>f</sup> Ophthalmology Department, University Hospital Necker-Enfants Malades, APHP, Paris Cité University, Paris, France

<sup>g</sup> Centre de Recherche des Cordeliers, Sorbonne Paris Cité University, Paris, France

<sup>h</sup> Department of Ophthalmology, Royal Victoria Infirmary, Newcastle upon Tyne, UK

<sup>i</sup> Biosciences Institute, Newcastle University, Newcastle upon Tyne, UK

<sup>j</sup> Faculty of Medicine and Health Technology, Tampere University, Tampere, Finland

<sup>k</sup> UCL Institute of Ophthalmology, London, UK

<sup>l</sup> Cornea and Ocular Surface Unit, Eye Repair Lab, San Raffaele Hospital, Milan, Italy

<sup>m</sup> Department of Ophthalmology and Visual Sciences, Medical University of Varna, Varna, Bulgaria

<sup>n</sup> Department of Ophthalmology, Antwerp University Hospital, Edegem, Belgium

<sup>o</sup> Schepens Eye Research Institute, Harvard Medical School, Boston, MA, USA

<sup>p</sup> Regenerative Medicine Institute, University of Galway, Galway, Ireland

<sup>q</sup> Department of Medical and Surgical Specialties, Radiological Sciences, and Public Health, Ophthalmology Clinic, University of Brescia, Brescia, Italy

<sup>r</sup> Fondazione Banca degli Occhi del Veneto, Venice, Italy

<sup>s</sup> Center for Molecular Medicine Cologne, University of Cologne, Cologne, Germany

<sup>t</sup> Division of Ophthalmology, Department of Biomedical and Clinical Sciences, Linköping University, Linköping, Sweden

\* Corresponding author: Stefano Ferrari, Fondazione Banca degli Occhi del Veneto, Via Paccagnella 11, Venice, Italy.  
 E-mail address: [stefano.ferrari@fbov.it](mailto:stefano.ferrari@fbov.it) (S. Ferrari).

<sup>1</sup> Contributed equally as last authors.

ARTICLE INFO

Article history:

Received 16 November 2022

Revised 19 April 2023

Accepted 24 April 2023

Available online 4 May 2023

Keywords:

Aniridia

Aniridia-associated keratopathy

PAX6

Keratopathy

Gene therapy

Cell therapy

Pharmacological action

Surgical procedures

ABSTRACT

Congenital aniridia is a panocular disorder that is typically characterized by iris hypoplasia and aniridia-associated keratopathy (AAK). AAK results in the progressive loss of corneal transparency and thereby loss of vision. Currently, there is no approved therapy to delay or prevent its progression, and clinical management is challenging because of phenotypic variability and high risk of complications after interventions; however, new insights into the molecular pathogenesis of AAK may help improve its management. Here, we review the current understanding about the pathogenesis and management of AAK. We highlight the biological mechanisms involved in AAK development with the aim to develop future treatment options, including surgical, pharmacological, cell therapies, and gene therapies.

© 2023 The Author(s). Published by Elsevier Inc. This is an open access article under the CC BY license (<http://creativecommons.org/licenses/by/4.0/>).

1. Introduction

Congenital aniridia is a rare disorder, with a prevalence ranging from 1:40,000 to 1:100,000.<sup>115</sup> Aniridia is a term of

Greek origin meaning “without iris,” and the absence of iris structures has long been the defining phenotypic characteristic of this disease. In addition to numerous ocular abnormalities, congenital aniridia also affects various other organs, including the brain, gut, pancreas, and olfactory and

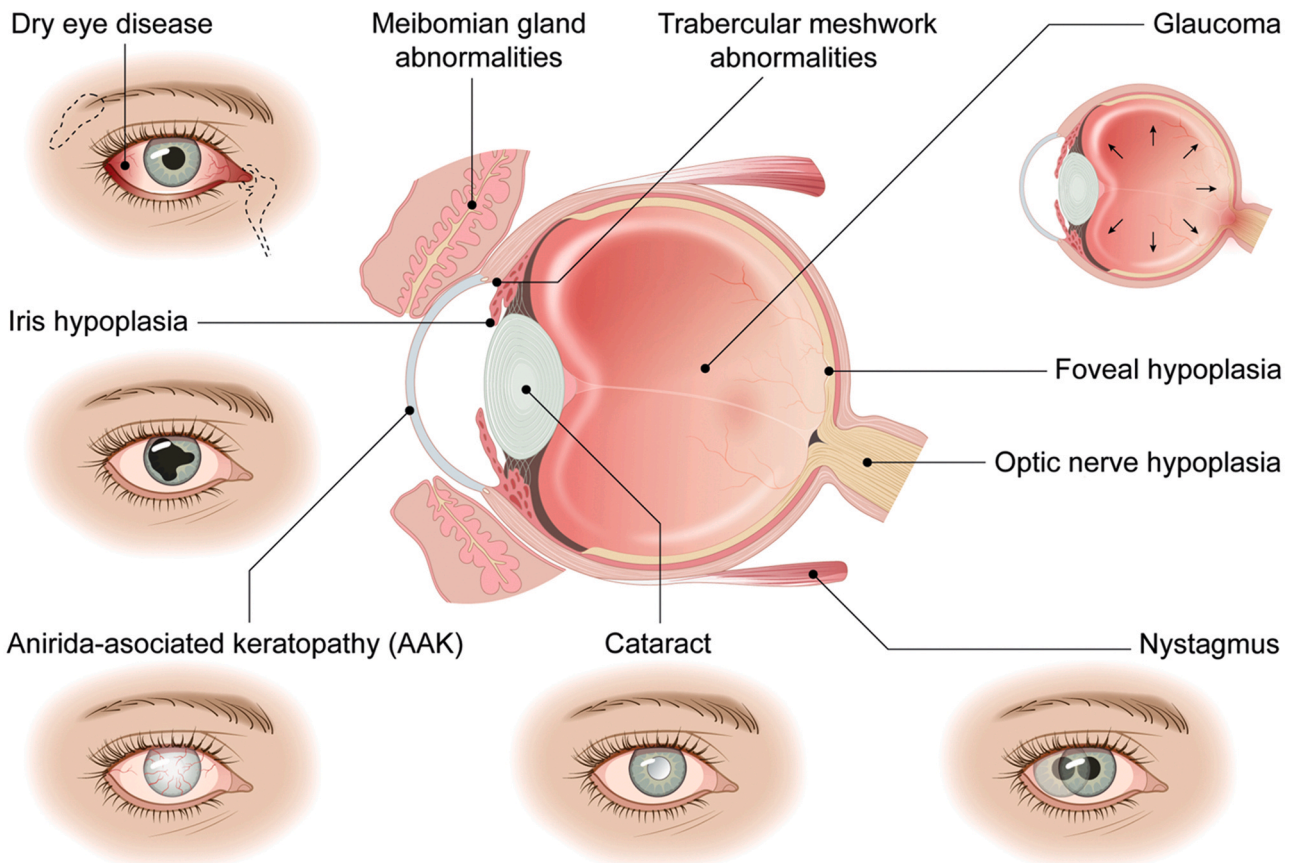
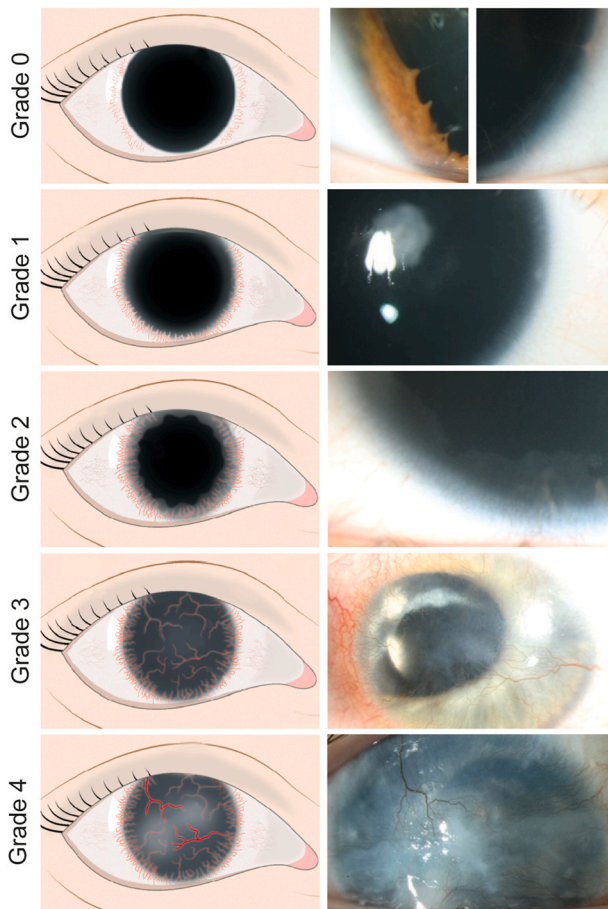


Fig. 1 – Ocular manifestations of the aniridia syndrome.



**Fig. 2 – Grading scale for aniridia-associated keratopathy (AAK).** On the left, illustrative images of the main features of each AAK grade that can be detected upon careful slit lamp microscopic examination: healthy transparent cornea with intact limbal border and fully transparent corneal epithelium (grade 0); circumferential or localized invasion of vessel crossing the limbus (within 1 mm) (grade 1); fibrovascular pannus at the corneal periphery (within 2–3 mm of the limbus) (grade 2); complete translucent and vascularized cornea (grade 3); and opaque and vascularized cornea of varying thickness (grade 4). On the right, slit lamp photographs illustrating the various AAK grades. (Reprint from<sup>83</sup> with permission).

auditory systems.<sup>11,142,53</sup> Other conditions have also been linked to aniridia, such as obesity and narcolepsy.<sup>116,9</sup> Due to the diverse systemic manifestations, the term aniridia has been widened to aniridia syndrome. Ocular manifestations include affected structures of the iris, optic nerve, trabecular meshwork, Schlemm canal, and the lacrimal and meibomian glands, and subsequent ocular complications include nystagmus, dry eye disease, corneal opacification (keratopathy), glaucoma, and cataract<sup>72</sup> (Fig. 1).

Foveal and iris hypoplasia, as well as aniridia-associated keratopathy (AAK), are the most common phenotypic anomalies of congenital aniridia, which are present in

80–100% of the cases. Due to the ocular abnormalities, the visual prognosis for aniridia is generally poor, with a best visual acuity of typically 20/100–20/200, even with access to state-of-the-art ophthalmic interventions.<sup>45</sup> As AAK is the leading cause of vision impairment in congenital aniridia, a better understanding and management of this condition would significantly enhance the visual acuity of aniridia patients. To enhance the clinical management of AAK, we present a critical review of the current status of clinical and experimental efforts towards AAK treatment. In this review, we describe the underlying pathology and various strategies for managing AAK. In addition to providing an overview of the present state of affairs, we identify future perspectives and open issues to enhance treatment.

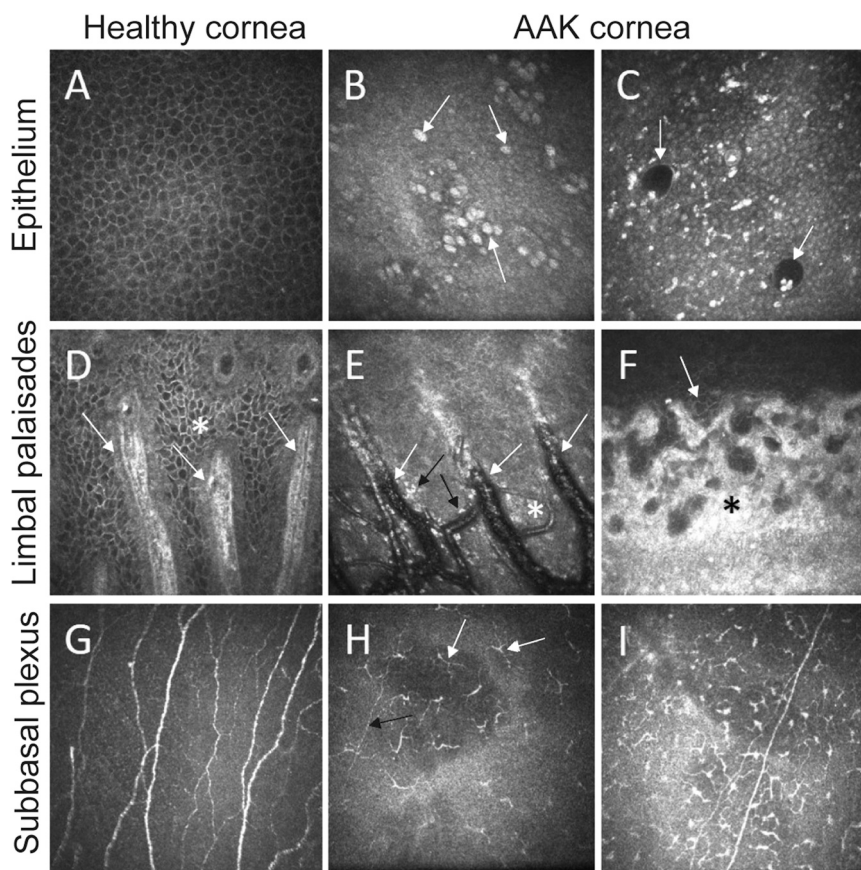
## 2. Clinical features of AAK

AAK is a progressive opacification of the cornea. It is one of the most sight-limiting and painful manifestations of congenital aniridia and, if not treated, will lead to blindness over time. AAK typically starts in the first decade of life and progresses in early adulthood. Its progression follows a characteristic pattern similar to limbal stem cell deficiency (LSCD) and can be classified using a grading scheme (Fig. 2). In a healthy cornea the limbal border is intact and well-defined (grade 0). At the earliest stage of AAK, vessels start to breach the limbal border (grade 1), followed by inward radial invasion of abnormal translucent epithelium (grade 2) that reaches the central visual axis (grade 3), and eventually develops into a thickened, uneven corneal surface with white opacities (grade 4). The rate of progression is associated to the specific PAX6 mutation.<sup>83</sup>

Other clinical features are increased stromal thickness and reduced corneal touch sensitivity.<sup>84</sup> The epithelium of the central cornea exhibits abnormal morphology even in the earliest stages of keratopathy where the cornea appears clinically normal. *In vivo* confocal microscopy in patients with aniridia has revealed multiple abnormalities including reduced corneal nerve density, invasion of inflammatory cells, opacification of the anterior stroma, goblet cell hyperplasia, and loss of basal epithelial cells<sup>84</sup> (Fig. 3). Moreover, an abnormal tear film composition and meibomian gland dysfunction are related to the development of dry eye disease in aniridia.<sup>86</sup>

Variability in the clinical expression of AAK has been widely reported<sup>45,61,95</sup>, however, the true biological and genetic variability must be distinguished from the variability resulting from differing examination techniques and methods of reporting. Because the earliest stages of AAK are often overlooked, a broader definition of AAK supported by advanced testing and imaging techniques would aid in its documentation and grading, thereby supporting the description of the true biological variation. Importantly, AAK typically co-occurs with a range of other abnormalities associated with congenital aniridia. These systemic and ocular abnormalities significantly impact the treatment and prognosis of AAK. Therefore, it is essential to consider the combined abnormalities when managing AAK. For instance,





**Fig. 3 – Features of aniridia-associated keratopathy (AAK) observed using in vivo confocal microscopy. Relative to the healthy cornea (A, D, G), corneal homeostasis in aniridia is chronically perturbed. A: Normal healthy corneal epithelium with a clear cell mosaic. B: Epithelium with a conjunctival phenotype containing goblet cells (arrows) and inflammatory cells (bright reflective objects) and (C) epithelial cysts (arrows) thought to contain mucin. D: The limbal palisades of Vogt (arrows) within an intact epithelial cell mosaic (asterisk). E: Abnormal cellular structure and blood vessels (white arrows) with sprouting new vessels (asterisk) and inflammatory cells (black arrows). F: A fibrovascular pannus (asterisk) eventually replaces the limbal border with conjunctival epithelial cells (arrow). G: Normal subbasal nerve plexus containing high density of nerves. H: Sparse distribution of nerves (black arrow) and mature antigen-presenting dendritic cells (white arrows) in the central subbasal plexus. I: High density of dendritic cells. All images are from grade 2 AAK corneas with a transparent central cornea, and are  $400 \times 400 \mu\text{m}$ . Images courtesy of N. Lagali.**

glaucoma develops in more than 50% of aniridia patients.<sup>85</sup> Additionally, patients who require corneal surgery are at higher risk of developing glaucoma than those who do not.

### 3. Fundamental basis of AAK pathogenesis

The majority (90%) of aniridia cases are caused by a haploinsufficiency of the *PAX6* gene located on chromosome 11p13, which can occur sporadically or can be inherited in an autosomal dominant manner.<sup>26</sup> Over 500 unique heterozygous loss-of-function mutations of *PAX6* have been reported to result in aniridia.<sup>88</sup> In addition, mutations in the noncoding regulatory and intronic regions of *PAX6* have also been identified in aniridia, including the neighboring genes *TRIM44* and *ELP4*.<sup>163,77</sup> The genetic heterogeneity of aniridia may partially explain the wide variability in its phenotype observed across different cohorts.<sup>153,83</sup> Additionally, several reports have

highlighted considerable phenotypic variability amongst individuals in families harboring the same mutation.<sup>157,161</sup> This suggests environmental factors or multifactorial genetics influence the effect of *PAX6* mutations in aniridia.

*PAX6* is a highly conserved gene that plays an important role in embryonic development, particularly ocular development, and its haploinsufficiency leads to the abnormal development of eye structures and subsequent complications later in life.<sup>32,90</sup>

Heterozygous loss-of-function mutations in *PAX6* typically reduce its protein abundance by 50%,<sup>101</sup> which has an effect on multiple biological processes, including angiogenesis, cytoskeletal organization, cell adhesion, retinoic acid metabolism, and oxidative stress.<sup>120,75,91,92</sup> Moreover, because *PAX6* is expressed in multiple ocular structures, its dysregulation can disrupt the interplay between them. Based on clinical observations and animal experiments, the mechanisms underlying progressive AAK appear to be multifactorial and include the reduction of cell

adhesion molecules as well as abnormal corneal healing, extracellular matrix metabolism, and corneal epithelial differentiation<sup>121,130</sup>; however, the molecular mechanisms underlying each specific pathophysiology are difficult to elucidate because PAX6 controls multiple signaling pathways, such as PI3K/AKT/mTOR and MAPK (MEK/ERK).<sup>91</sup>

AAK is often associated with progressive LSCD because findings such as inflammation and conjunctivalization (opacification and neovascularization) causing pain and loss of vision are present in both conditions. LSCD is a disease caused by a loss of limbal epithelial stem cells (LESCs) due to physical or chemical trauma. There are various theories about the role of LESCs in AAK. Some have suggested PAX6 haploinsufficiency reduces the number of LESCs over time, but in one aggressive case of multiple PAX6 and *ELP4* exon deletion, no reduction in the number of epithelial progenitor cells was detected.<sup>139</sup> Therefore, others suggest that AAK is caused by abnormal LESCF function, including proliferation and differentiation, rather than LESCF deficiency.<sup>130,134</sup> There is insufficient evidence, however, for abnormal migration and proliferative potential of LESCs in aniridia patients. An alternative theory is the mesenchymal transdifferentiation of LESCs, which is supported by the expression of conjunctival and epidermal differentiation markers (cytokeratin 13 and 10, respectively) and lack of expression of classic corneal epithelial markers (cytokeratin 3 and 12) in the corneal epithelium of AAK patients.<sup>155,93</sup> In addition, AAK is characterized by the infiltration of goblet cells in severe cases.<sup>82</sup> Together this suggests that corneal opacification might be caused by conjunctivalization, but it is unclear if it is caused by a loss of the corneal-conjunctival barrier or due to mesenchymal transdifferentiation.<sup>76,97</sup>

The normal function of LESCs depends on the instructive nature of the niche microenvironment, as influenced by the ocular surface and neighboring structures, which gives another possible explanation for the symptoms present in AAK. Namely, the corneal nerves that would normally provide trophic support and homeostasis, are reduced by 50% in their density at birth in aniridia.<sup>44,84</sup> Other abnormalities found in the AAK limbal niche are abnormal melanocytes that contain no melanosomes and melanin granules.<sup>139</sup> As a result, pigmentation deficiency of limbal cells could enhance their sensitivity to oxidative stress and inflammation. In addition, alterations in the trabecular meshwork and Schlemm canal impact the outflow of aqueous humor, causing the ocular hypertension that develops in the majority (50–75%) of AAK patients.<sup>79</sup> The dysfunction of the lacrimal and meibomian glands results in abnormal tear film osmolarity and protein composition. Elevated levels of pro-angiogenic and pro-inflammatory cytokines, including FGF2, IL-17A, IL-1 $\beta$ , IL-8, IL-9 and MIP-1 $\alpha$ , and the reduced expression of angioregressive factors, including soluble VEGF receptor-1 (sFlt-1), were found in the tear film and pannus tissue of aniridia patients.<sup>2,73,87</sup> Moreover, AAK is characterized by corneal infiltration of immune cells, including mature antigen-presenting dendritic cells and leukocytes.<sup>82</sup> Collectively, this suggests that the ocular surface is chronically inflamed, which also contributes to an abnormal limbal niche microenvironment.

Still others have hypothesized that AAK progression is driven by gradual degradation of the limbal niche.<sup>80</sup> This latter theory is supported by evidence of the loss of palisades

of Vogt, the degradation of the basal membrane and Bowman layer leading to direct contact between basal cells and mesenchymal stromal cells, and abnormal extracellular matrix (ECM) composition.<sup>139</sup> However, it is difficult to distinguish primary from secondary events in AAK progression.

Together these findings suggest an abnormal microenvironment and dysregulation of LESCF function may lead to AAK progression. For the successful management of AAK, a detailed understanding of its pathogenesis is needed. Further studies are likely to reveal that multiple mechanisms are involved.

## 4. Management of AAK and potential future directions

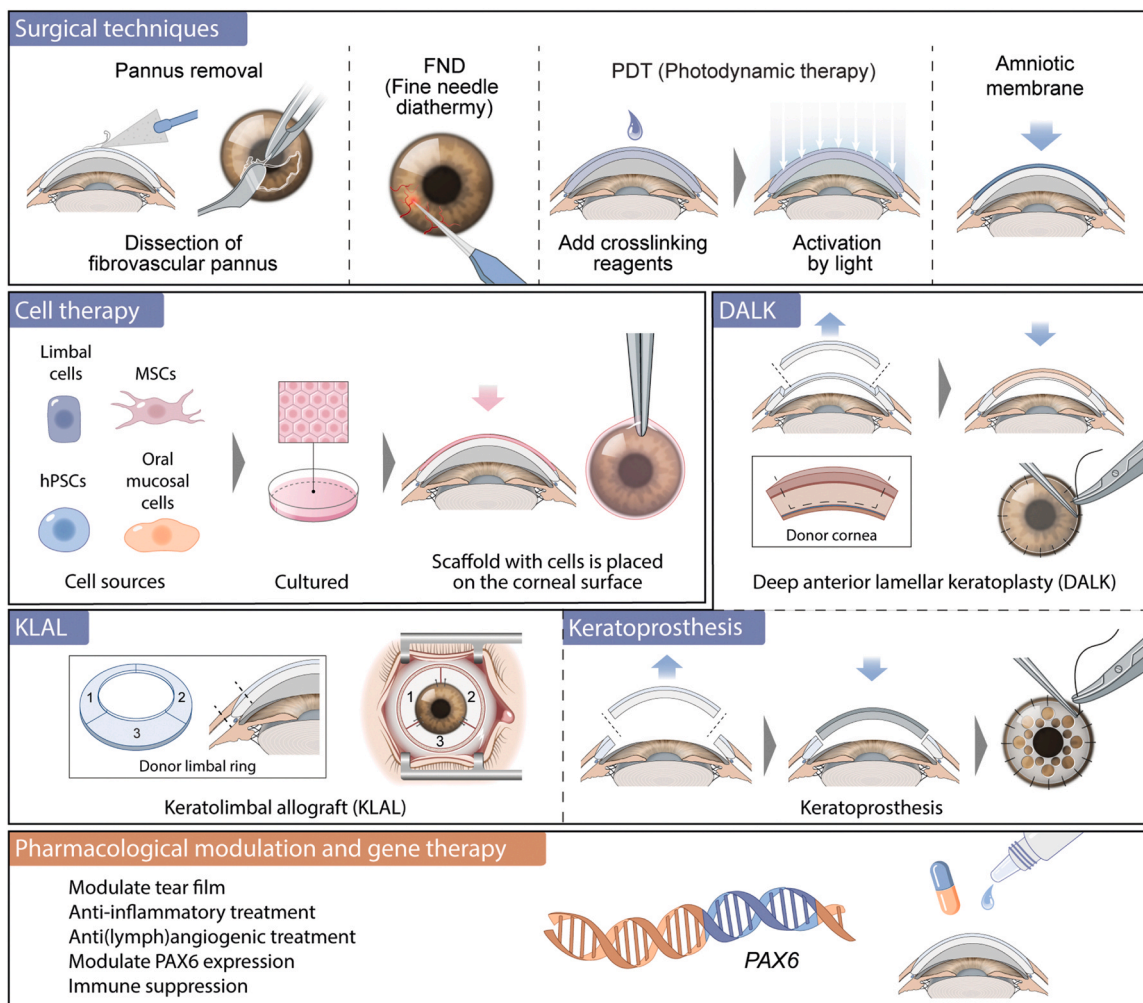
Clinical management of AAK is challenging due to the multifaceted nature of the ocular surface pathology and the high risk of complications after interventions. The treatment approach is patient-specific, guided by the disease stage and the presence of other ocular complications, including cataract, glaucoma, and dry eye. While conventional treatment is geared towards symptomatic relief, restoring functional vision, and supporting and maintaining a healthy ocular surface, new treatment approaches can slow AAK progression and prevent vision loss. In this section, the various approaches and future directions for AAK management are reviewed, including surgical techniques and pharmacological approaches (Fig. 4). It is worth noting that the treatment of AAK usually involves a combination of approaches tailored to the individual patient.

### 4.1. Surgical approaches

#### 4.1.1. Pannus removal

Eyes with advanced AAK often develop a pannus (conjunctival overgrowth into the cornea) of varying thickness, which can compromise transparency and refractive function. Pannus removal is typically performed to restore a smooth ocular surface and thereby improve vision. Afterwards, the denuded areas can be re-epithelialized by cells from the unaffected cornea and limbus if the limbal stem cells are still partially functional; however, surgical interventions in eyes with AAK are challenging because of the high risk of complications.<sup>116,149</sup> This high-risk situation involves coexisting glaucoma, progressive inflammation, limbal stem cell dysfunction, and corneal neovascularization, often leading to chronic wound healing problems and cornea melting.<sup>85</sup> Therefore, surgical interventions to improve vision are warranted in the current management of AAK.

The most common approach to improve wound healing and regeneration of the ocular surface after pannus removal is using an amniotic membrane patch to cover the denuded corneal surface.<sup>128,55</sup> Amniotic membrane can be used alone or in combination with a corneal transplant and cell therapy to treat AAK.<sup>140,21,39</sup> It is believed that the positive effect may be caused by the cytokines and growth factors present in the amniotic membrane or that it functions as a barrier that redirects conjunctival epithelialization at the denuded area.<sup>41</sup> The exact mechanism of action of the amniotic membrane remains unknown, however, and has a limited long-term effect.



**Fig. 4 – Multiple approaches for management of aniridia-associated keratopathy that have been studied or are under development. These include surgical techniques, gene therapy, cell therapy and pharmacological modulation.**

In addition, autologous serum eye drops or neurotrophic eye drops can be used to supplement the wound healing effect of amniotic membrane.

#### 4.1.2. Corneal transplantation

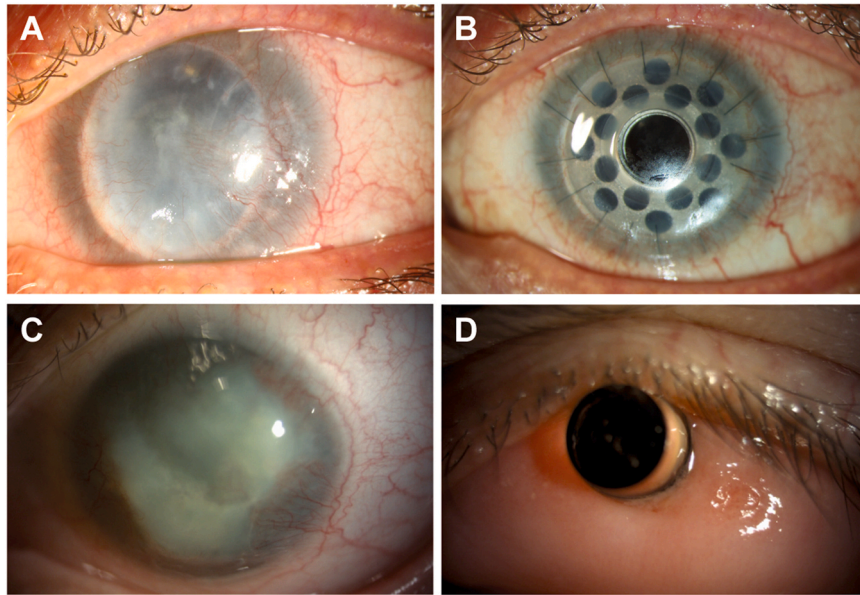
Given the immunocompromised status of the ocular surface, corneal transplantation in AAK-affected eyes is challenging because of the high risk of transplant rejection and failure.<sup>67</sup> Nonetheless, corneal transplantation may be indicated for optical and tectonic reasons. To reduce the risk of rejection, lamellar surgery is generally preferable to penetrating keratoplasty since the endothelium in aniridia is unaffected.<sup>67,84,85</sup> This can be done either as deep anterior lamellar keratoplasty, replacing the majority of the stroma down to Descemet membrane, or as anterior lamellar keratoplasty, replacing only a proportion of the anterior stroma and leaving the most posterior recipient stroma intact. In case of severe AAK with deep corneal stromal scarring and neovascularization, penetrating keratoplasty may be necessary, but it has poor success rates due to the high risk of graft rejection, wound healing problems, and neovascularization of the transplanted stroma.<sup>123</sup> In addition to a lower risk of

immune rejection,<sup>67</sup> another advantage of anterior lamellar keratoplasty is the possibility to exchange the lamellar graft if later opacification of the transplanted corneal stroma occurs. Importantly, before keratoplasty, the eye should first undergo successful limbal stem cell transplantation (LSCT) to improve the prognosis for long-term success.<sup>123</sup> Alternatively, keratolimbal allograft transplantation followed by subsequent corneal transplantation is used to treat AAK.<sup>119,64</sup> It is thought that keratolimbal allograft restores the limbus and provides a supply of allogeneic LESC, which results in a stable ocular surface in 65.9% of the eyes after 7.9 years.<sup>24</sup> Functional and quality-of-life improvements are modest, however, and the burden of multiple surgical procedures and lifelong immune suppression is considerable. A potential future improvement could be the combination of LSCT and deep anterior lamellar keratoplasty with angioregressive and antiangiogenic treatment.

#### 4.1.3. Keratoprosthesis

When corneal transplantation is infeasible or has failed repeatedly, Boston type I keratoprosthesis (Kpro) may be considered as a last resort in severe AAK-affected eyes<sup>141,42</sup>





**Fig. 5 – Keratoprosthesis surgery in advanced aniridia-associated keratopathy (AAK). A: A preoperative advanced AAK case with central corneal vascularization and corneal opacity in a failed corneal graft. B: The same eye after Boston Kpro surgery, with the clear central optic and titanium backplate visible. C: Preoperative advanced AAK case with peripheral vascularization and thick central opacities. D: The same eye after osteo-odonto keratoprosthesis surgery, with the clear central optic visible within the autologous oral mucosal tissue. Images courtesy of C. Cursiefen and D. Bremond-Gignac.**

(Fig. 5). The benefit of the Boston type I Kpro is that the optical cylinder cannot opacify or become vascularized due to the artificial nature of the central portion. It has many side effects and potential complications, however, such as retroprosthetic membrane formation, corneal melting, and glaucoma.<sup>137,141</sup> Recently, telemetric intraocular pressure sensors were implanted with Boston type I Kpro to measure intraocular pressure and help manage glaucoma.<sup>46–48</sup> In case of severe dryness of the keratinized ocular surface, osteo-odonto keratoprosthesis or Boston type II Kpro could be considered, but both require multiple invasive surgeries that increase the risk of developing aniridia-associated fibrotic responses and exacerbating glaucoma.<sup>112,60</sup>

#### 4.1.4. Cell therapy

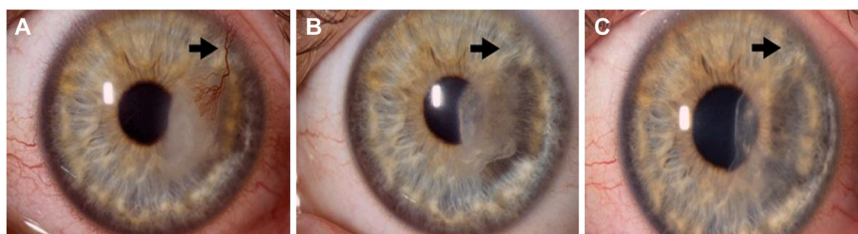
Since AAK is associated with LSCD, generally treatments to replace abnormal LSCs to restore a healthy corneal epithelium have been applied. For unilateral LSCD, a range of autologous limbal stem cell therapies have been developed, including cultivated limbal epithelial transplantation, where a biopsy from the unaffected eye is cultivated *ex vivo* and transplanted onto the denuded affected eye.<sup>124,131</sup> Bilateral insufficiency in patients with aniridia, however, prevents autologous cell transplantation and therefore requires other sources of LSCs for ocular surface reconstruction. Allogeneic and autologous cell sources, such as limbal cells, oral mucosal stem cells, differentiated human pluripotent stem cells, or mesenchymal stromal cells (MSCs) have therefore been considered to treat AAK.

Allogeneic cultivated limbal epithelial transplantation using cadaveric donor cells showed only short-term success in

treating severe AAK-affected eyes, because of graft rejection in the long-term.<sup>144,21,6</sup> Living related conjunctival–limbal allografts are more immune compatible and improve graft survival relative to corneal transplant, but compatible donors are not always available.<sup>24</sup> Therefore, researchers have focused on other cell sources.

For example, more recently cultivated oral mucosa epithelial transplant using autologous oral mucosal epithelial cells obtained from a buccal mucosal biopsy that are cultured *ex vivo* prior to transplantation are used as cell source. Cultivated oral mucosa epithelial transplant showed visual improvement in LSCD and AAK cases in more than 50% of the eyes,<sup>107,126,135,15</sup> however, long-term effects are unknown. Because oral mucosal cells do not normally express PAX6, it will be important to understand whether the mutated PAX6 gene in aniridia patients influences the differentiation into corneal epithelial cells.<sup>102</sup> Additionally, oral mucosal epithelial cells are inherently different from corneal epithelial cells and therefore may require additional manipulation to possess the properties needed to improve vision.

Human PSCs, such as embryonic stem cells and induced pluripotent stem cells, provide novel opportunities for cell therapies, but guiding their differentiation into specific cell populations to establish a corneal epithelial transplant is complex. There are several established methods for differentiation of corneal epithelial cells and limbal stem cell (LSCs) from human pluripotent stem cells (hPSCs), including corneal cell-conditioned media, growth factors, inhibitors, and small molecule approaches.<sup>154,23</sup> Recently, the first patients have been treated with induced pluripotent stem cell-derived corneal epithelial cells to treat LSCD and showed improved vision, but long-term efficacy and safety is not yet



**Fig. 6 – Fine-needle diathermy (FND) applied to regress corneal neovascularization in a non-aniridia case.<sup>78</sup> A: Preoperative eye with thick invading vessel (arrow). B, C: Two months and 15 months after FND combined with anti-VEGF therapy as a pretreatment to promote subsequent graft survival, the vessels (arrows) have almost completely regressed and transparency has been restored substantially. (Reprint from<sup>78</sup> with permission).**

known.<sup>31</sup> Overall, induced pluripotent stem cells also provide possibilities to transplant autologous cells for personalized treatment<sup>146</sup>; however, the sourcing of autologous cells from aniridia patients for reprogramming is likely undesirable because of their underlying genetic defect. Additionally, such a personalized approach is likely to be costly and therefore other strategies to avoid immune responses are being developed.<sup>125</sup>

Another example, MSCs, which possess unique immunomodulatory properties and can be sourced in large quantities, are an attractive novel source for cell therapy. For instance, they are clinically used to treat inflammatory diseases or suppress host rejection,<sup>113,35</sup> and they possess differentiation potential, homing properties and trophic effects.<sup>62</sup> Although it is difficult to differentiate them into corneal epithelial cells *in vitro*,<sup>104,57</sup> nondifferentiated MSC showed therapeutic potential for ocular surface regeneration which was attributed to their trophic effect.<sup>20,63</sup> Furthermore, recent alternative approaches use facilitated endogenous repair by recruiting MSCs to the site of injury with chemoattractants.<sup>152</sup> While these data are encouraging, it remains to be seen if the (co-)application of MSCs could be a viable approach for treating AAK in the long term.

Despite decades of research, the therapeutic mechanism of LSCT remains unclear. Transplanted cells may exert their therapeutic effects *via* trophic support or immune modulation rather than through stem cell repopulation and differentiation. Questions therefore arise from LSCT studies if transplanted cells survive in the long term and actively contribute to epithelial maintenance, or if they have an indirect effect on the clinical outcome.<sup>37,58</sup> In AAK, it is unknown how long transplanted allogeneic donor limbal cells survive in the host cornea and whether the underlying reasons for LSCT failure differ between acquired LSCT and AAK.

In addition, it is likely that the abnormal limbal niche observed in aniridia will preclude grafted stem cells from lodging in the limbal region. Without a functioning micro-environment, the transplanted cells lack adequate post transplantation support, and their function might only be transient. Therefore, reconstruction of a biomimetic limbal niche to support normal cell function is being pursued. For example, it has been shown that the biomechanical stiffness of the limbus affects the capacity of epithelial stem cells to regenerate the corneal epithelium.<sup>52</sup> Using tissue engineering

approaches, some have proposed the construction of a human corneal surface by combining cells with scaffolds.<sup>109,129,138</sup> Currently a phase I/II clinical trial of a tissue engineered product which brings together LESC and supporting stromal cells with type I collagen to treat patients with AAK is ongoing (NCT05044598). Despite decades of intensive research, we still lack an understanding of the regulatory conditions of the instructive nature of the niche microenvironment, which prevents us from harnessing the full therapeutic potential of cell-based therapies.

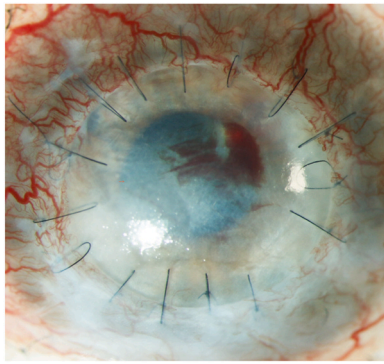
Another challenge is that current cell expansion methods for primary LESC do not significantly increase their number *in vitro*. It is unclear whether enough LESC can be transferred to the damaged ocular surface for long-term restoration of the stem cell population in AAK. Therefore, if stem cells can be better identified, isolated, and expanded/maintained in culture, stem cell-based graft quality may be improved with a more predictable clinical success. Markers including ABCB5, CD200 and ABCG2 that allow purification of the clinically-relevant cell population would significantly improve both the safety and efficacy of therapy.<sup>117,14,158</sup>

Furthermore, immunosuppression protocols, human leukocyte antigens (HLA)-matching, and outcome measures vary between studies, making it difficult to assess treatment efficacy.<sup>150</sup> Another significant problem when assessing clinical outcomes of stem cell transplantation to treat any form of LSCT, including AAK, is the lack of a universal and objective grading tool for assessing post-transplantation results.<sup>144,5</sup> Additional limitations are the high risk of complications after interventions of AAK-affected eyes leading to poor survival of cell-based grafts.<sup>123,144,7</sup> For long-term success, approaches to reduce or eliminate immunogenicity of cellular therapies are explored, such as genetically engineered HLA-typed cell lines and shielding.<sup>125</sup> Additionally, pharmacological approaches, including immunosuppression and anti(lymph)angiogenic treatments, can reduce the risk of transplantation failure. Poor long-term clinical results after LSCT suggest that new therapeutic strategies should be developed by addressing ocular immunity and supporting the limbal stem cell niche environment.

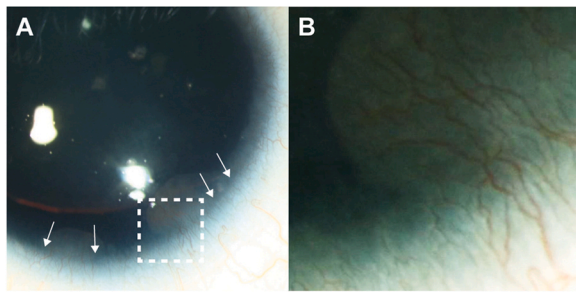
#### 4.1.5. Immuno suppression

Although the cornea is regarded as an immune-privileged tissue, graft failure frequently occurs.<sup>3</sup> The current treatment





**Fig. 7 – Interface bleeding after deep anterior lamellar keratoplasty blocks the visual axis in a high-risk vascularized cornea. This can be (partially) prevented by preoperative angioregressive treatment. Image courtesy of C. Cursiefen.**



**Fig. 8 – A: Slit lamp photograph of a cornea with aniridia-associated keratopathy progressing from grade 1–2, exhibiting thickening and neovascularization in the periphery (highlighted by arrows); B: magnified view of the dotted square in A: blood vessels and conjunctival-like tissue leave the limbal region and extend towards the central cornea. Photo courtesy of N. Lagali.**

of corneal graft rejection is based on steroids and other immune-modulating agents. Postoperative local immunosuppression is often achieved using topical steroids, such as prednisolone and dexamethasone. Additionally, systemic immune suppression, such as tacrolimus, beta-methasone, azathioprine and mycophenolate mofetil is used to control inflammation and reduce the risk of early allograft rejection.<sup>65,69</sup> Systemic and local immunosuppression have also been used in combination.<sup>132,145,43,81</sup> In clinical practice, both local and systemic immunosuppression in corneal transplantation and LSCT have been applied with variable success.<sup>159,96</sup> While the long-term use of immunosuppression post corneal transplantation is crucial for graft survival, the benefits in allogeneic cultivated limbal epithelial transplantation remain unclear as there are conflicting studies on the long-term survival of donor cells.<sup>34,37</sup> Moreover, it is difficult to draw conclusions from studies with varying

regimens. While these systemic and/or topical immunosuppression regimes are also applied in aniridia patients, the transplantation success rate remains low.<sup>144</sup> For this reason, the development of more efficient protocols for immunosuppression specifically for aniridia patients post corneal transplantation or LSCT is imperative. Ideally, the regimen should be based on local approaches to avoid severe long-term side effects of systemic immunosuppression. Furthermore, the lack of evidence for allogeneic LESCT survival beyond a relatively short period of time prompts ethical questions regarding the continuation of immunosuppression beyond 9 months, which is associated with significant side effects.

#### 4.1.6. Regression of corneal vascularization

The avascular nature of the cornea is essential for maintaining transparency, although the mechanisms behind it are not fully understood.<sup>2,4</sup> In advanced AAK significant corneal vascularization leads to opacity, but regression of surface or deeper vessels in these areas generally improve transparency (Fig. 6). Furthermore, preoperative regression of blood vessels prior to corneal transplantation is necessary to prevent recurrent vascularization and bleeding into the interface. Such bleeding can cause a prolonged wound healing response and leads to significantly reduced vision<sup>29,67,71</sup> (Fig. 7). Regression can be accomplished by various approaches, such as fine-needle diathermy and corneal crosslinking, and results in significantly prolonged corneal graft survival.<sup>136,71,99</sup> Photodynamic therapy has also been shown to regress blood and lymphatic vessels, including a significant percentage of the mature ones, promoting graft survival in a mouse model.<sup>70</sup> Pharmacological suppression of corneal vessels alongside these approaches may further prolonged the angioregressive effect and could be considered.

## 4.2. Pharmacological approaches

The ocular surface of AAK patients is characterized by increased angiogenic signaling, suggesting an imbalance between pro- and antiangiogenic factors leading to pathological hem- and lymphangiogenesis.<sup>73,82</sup> In AAK progression, inflammation and angiogenesis are associated and defined by the presence of inflammatory cells, corneal nerve deficit, limbal corneal thickening and corneal neovascularization with increasing AAK grade (Fig. 8). Often vessels start to occupy the peripheral corneal regions before extensive damage of the epithelium takes place. Blood and lymphatic vessels facilitate inflammation and the release of cytokines by propagating antigens and immune cells to the ocular surface.<sup>74</sup> Here we describe the pharmacological approaches that could modulate either inflammation, neovascularization, tear abnormalities or PAX6 protein levels.

### 4.2.1. Anti(lymph)angiogenic treatment

Antiangiogenic therapy could possibly reduce corneal neovascularization and angiogenesis in AAK progression. To achieve a corneal hem- and (lymph)angiogenic effect, it may

be beneficial to consider pharmacological suppression of corneal vessels with topical agents, such as anti-VEGF compounds. Bevacizumab, a monoclonal antibody specific to the VEGF-A ligand, is considered the first-line treatment for corneal neovascularization (used off-label), either topically or via subconjunctival injections.<sup>12,13</sup> Notably, the use of bevacizumab in a young patient to treat AAK-related corneal neovascularization reduced the number of vessels and delayed AAK progression over several years.<sup>89</sup>

Other anti-VEGF compounds, including ranibizumab, aflibercept, pegaptanib, and VEGF-receptor tyrosine kinase inhibitors demonstrated partial efficacy in treating corneal neovascularization, but are not yet approved for clinical application in the cornea and would also be considered as off-label use.<sup>100,13,17,28,36,49,66</sup> Furthermore, the blockade of the insulin receptor substrate-1 (IRS-1) by GS-101 (Aganirsen) also inhibits VEGF activity and thereby corneal hem- and (lymph)angiogenesis in phase II and III clinical trials (NCT02947867).<sup>12,27,30</sup> This broad antiangiogenic and anti-inflammatory approach has the benefit of avoiding the neurotoxic side effects of pure anti-VEGF therapy.<sup>68</sup> Because partially inhibiting progressive corneal (lymph)angiogenesis using anti-VEGF compounds is shown to be safe and effective, more compounds are expected to receive approval for topical application in the cornea. This topical regimen can also be combined with local angioregression, like fine-needle diathermy and photodynamic therapy.

In addition to possibly hindering AAK progression, antiangiogenic agents could also be used to promote graft survival by regressing neovascularization. Anti-VEGF compounds are used to regress blood vessels after LSCT to treat LSCT.<sup>22</sup> A recent study, however, demonstrated that it induced differentiation of putative LSCs *in vitro* and should be considered with caution in the context of LSCT.<sup>118</sup> In the case of mature blood vessels observed in advanced AAK, the aforementioned agents may not be as effective in regressing established blood vessels prior to LSCT. For this reason, other approaches should be explored, such as photodynamic therapy and fine-needle diathermy. Because these physical methods are already used clinically to treat other ocular conditions, clinical practice of these modalities to treat AAK may be streamlined in the near future. Alternatively, UVA-based corneal collagen crosslinking is less aggressive and avoids the rebound VEGF upregulation after fine-needle diathermy.<sup>71,98</sup> The effectiveness of these compounds and physical methods, alone or combined, in improving LSCT outcomes in aniridia remains to be explored preclinically and in clinical trials. Given the trophic influence of blood vessels on the limbal niche, it remains to be determined if a completely vessel-free limbal transplant region is conducive to long-term LESC survival. The trophic *versus* the immune function of blood vessels likely requires a careful balance for LESC survival.

#### 4.2.2. Anti inflammatory and tear film treatment

Lymph- and angiogenesis facilitate infiltration of inflammatory cells, including antigen-presenting dendritic cells and T-cells, that can lead to eventual rejection of foreign

transplanted cells or tissue.<sup>147</sup> The manipulation of dendritic cell and T-cell inhibitors has shown promise as a relatively new pharmaceutical strategy against transplant rejection. For example, coreceptor blocking agents such as CTLA4-Ig have been used to treat rheumatoid arthritis but also ocular inflammatory conditions in animal models.<sup>111,143,151,51,56</sup> Moreover, B- and T-lymphocyte attenuator is used to suppress allogeneic kidney transplants rejection by regulating T-cell receptor downstream signals and inflammatory cytokine production.<sup>164,94</sup> Because immune checkpoints are a critical component of the corneal immune privilege, immune checkpoint inhibitors could be used to attenuate transplant rejection, but research in this topic is currently lacking.

Tear abnormalities in aniridia patients result in a pro-inflammatory environment that destabilizes the ocular surface.<sup>73,87</sup> Optimizing the ocular surface using artificial tears with anti-inflammatory activity could be the first step in managing AAK. Autologous serum eye drops provide lubrication and contain various growth factors, vitamins, and immunoglobulins that support the proliferation, migration, and adhesion of corneal epithelial cells.<sup>50</sup> Autologous serum eye drops were efficient in treating the inflammatory and angiogenic factors of LSCT and LSCT.<sup>108,160,8</sup> Also in patients with mild to moderate AAK, autologous serum eye drops were beneficial in the short term.<sup>103</sup> When autologous serum is unavailable, allogeneic serum eye drops can be considered. Alternatively, amniotic membrane-derived eye drops may provide an interesting alternative, because of their regenerative and nourishing properties,<sup>114</sup> however, no commercial product is yet available, and more preclinical and clinical research is needed. For clinical research, it is critical to select patients carefully taking clinical genetics into consideration and identify early AAK onset, ideally at grade 1 or 2, for possible therapeutic intervention. Possible interventions would require careful and long-term monitoring owing to the slowly progressive nature of AAK. Nevertheless, early topical pharmacotherapy using amnion-derived or serum-derived approaches to prevent or delay AAK progression is an intriguing concept that warrants further study.

#### 4.2.3. Modulation of PAX6 levels

Another approach to halt AAK progression is to increase PAX6 protein levels in the cornea to compensate for the nonfunctional mutant allele product. Direct approaches, using a recombinant PAX6 protein fused to a cell penetrating peptide, rescued phenotypic defects of PAX6<sup>+/-</sup> cells *in vitro*.<sup>134</sup> Clinical use, however, is limited by the safety and efficiency of delivering the compounds into cells. In addition, it is difficult to determine the appropriate dosage of directly-delivered PAX6 protein, as both too little or too much PAX6 could lead to undesirable effects. An alternative therapeutic approach is to target the nonmutant allele to overproduce the protein. This concept has been demonstrated by inhibiting the MAPK kinase (MEK) pathway by several small molecules. For example, application of MEK inhibitors ritanserin and duloxetine in human corneal limbal epithelial cells led to the upregulation of PAX6 and increased PAX6 production.<sup>122,25,40</sup> Since duloxetine is already used to treat severe depression

and anxiety and relieve peripheral neuropathy, without apparent side effects, it could be easily translated to aniridia patients as soon as *in vivo* efficacy will be demonstrated. In addition, MEK inhibition by the experimental drug PD0325901 showed similar effects in a mouse model of aniridia, partially reversing the AAK phenotype;<sup>127,25</sup> however, caution of their use on aniridia patients must be considered, as MEK inhibitors have cardiac and ophthalmologic side effects when taken systemically. Another drug, ataluren, is a nonsense mutation suppresser targeting only the mutant allele. Ataluren showed elevated Pax6 protein levels *in vitro* and in an aniridia mouse model, putatively rescuing the AAK phenotype.<sup>101,156,38,54</sup> A phase II clinical trial was performed in patients with aniridia, in which ataluren was given orally with short follow-up; however, there was no statistical difference in the chosen endpoint of reading speed (NCT02647359). Furthermore, the potential efficacy is limited only to those patients with premature stop codon mutations, comprising about 70% of cases of congenital aniridia.<sup>83</sup> Similar *in vitro* data have been reported with another nonsense suppression drug (gentamicin G418).<sup>101</sup>

#### 4.2.4. Gene therapy

Gene therapy is a powerful strategy aimed at correcting disease-causing genetic alterations. Some gene therapies are already approved and used in ophthalmology, including Luxturna to treat inherited retinal dystrophy.<sup>105,148,16</sup> Genetic modulation aiming to increase expression of the haploinsufficient PAX6 gene expression is increased holds great promise to restore the physiological PAX6 protein level. Four gene therapy approaches could possibly target genetic alterations to treat aniridia: gene augmentation, gene enhancing, gene silencing or protection, and gene editing.

Gene augmentation is the delivery of a functional copy of the gene to correct for a defective copy. Many clinical trials are underway to restore the expression of a mutant gene in retinal disorders.<sup>148,16</sup> Gene enhancing modulates the activity of regulatory elements, such as promoters, enhancers, silencers, and insulators, to upregulate the expression of the existing normal gene copy.<sup>106</sup> It has been shown that DNA regulatory elements can drive PAX6 expression using transcription activators or small promoters, which could be a promising approach to increase the PAX6 protein level.<sup>18,59</sup> Gene silencers are small noncoding RNAs, such as small interfering RNA, antisense oligonucleotides, or micro-RNA, that inhibit the translation of mRNA. Gene silencing could be used to target PAX6 inhibitors to increase its expression. Furthermore, gene protectors, such as RNA decoys, could regulate RNA interference. For example, decoy gene therapy has shown to suppress PAX6-specific micro-RNA and increased Pax6 protein production in an aniridia mouse model.<sup>162</sup> Gene editing corrects the defective gene through, for example, a CRISPR/Cas9-based gene editing strategy to precisely target and correct PAX6 mutations through inclusion of the mutated base in the short-guide RNA sequence. CRISPR/Cas9-based gene editing can be used to treat dominantly inherited conditions permanently and has been used in preclinical animal models to modify mutations involved in ophthalmic diseases.<sup>19</sup> Recently, this strategy has been used to correct a PAX6 mutation in an aniridia mouse model.<sup>110</sup> Given the

diversity reported in the PAX6 mutations involved in aniridia, it is likely that a personalized approach will be needed for some patients. Although these gene therapy approaches have yielded promising results in various models of aniridia, they have to date not been translated into clinical trials.

Several techniques are available to deliver nucleic acids into the cells of the ocular surface, including viral vectors like adeno-associated virus, adenovirus and lentivirus for transduction, or liposomes, nanoparticles, and *in vivo* electroporation for transfection. The adeno-associated virus-based system has been tested in several experimental models of human ocular diseases with encouraging results.<sup>133</sup> Furthermore, because the cornea is easily accessible for local therapy, long-lasting treatment is possible using eye drops or contact lenses for topical delivery.<sup>1</sup> In addition, neighboring ocular tissues, including the sclera, stroma, or ciliary muscle, could serve as a “bio-factory” for long term expression and secretion of therapeutic proteins after injection of reporter gene-encoding plasmids.<sup>10</sup>

There are still several challenges to overcome for these approaches to be a success, especially dosing, toxicity, immune response, and off-target effects. The complex expression patterns during ocular development and the tissue-specific dosage of the PAX6 transcription factor make it challenging to develop gene therapies for aniridia. Moreover, the overexpression of PAX6 leads to corneal abnormalities.<sup>33</sup> Therefore, dosing will be crucial to reach a physiological expression level. To address issues of safety and specificity, tools to control transgene expression and control tissue-specific expression, such as by tissue-specific and inducible promoters, need to be considered.

---

## 5. Conclusion

Having explored the fundamental basis of AAK pathogenesis, we can appreciate the complexity of the disease that involves multiple mechanisms. For a detailed understanding of the disease mechanism at the molecular, cellular and developmental levels, much work remains to be done. Since AAK progression is often the most sight-limiting factor in congenital aniridia, an effective treatment would greatly enhance the quality of life. For the management of AAK, onset and progression should be classified by careful slit lamp examination of the cornea using a grading scheme. Advanced examination techniques, including *in vivo* confocal microscopy and optical coherence tomography, allow detection of additional abnormalities. Because AAK is characterized by high genetic and phenotypic variability, its management must be tailored for each individual case. To halt AAK progression, the focus should be on treating ocular surface inflammation, vascularization and the poor (neuro)trophic environment. Because the prognosis for vision recovery after any surgical intervention in aniridia is generally poor, whether or not to perform surgery and the type of intervention should be carefully considered including preoperative and postoperative care. Systemic and topical immunosuppression and anti lymph- and angiogenic treatment should always be considered in corneal transplantation or LSCT. Novel pharmacological approaches including eye drops,



immunomodulation, gene therapy and regulation of PAX6 levels are being developed. However, conducting clinical trials in a rare and heterogeneous disease such as aniridia is a challenge. Nonetheless, preclinical research using cellular and AAK animal models has demonstrated the possibility of novel therapeutics that could possibly delay or prevent the onset or progression of AAK in the future. Therefore, further efforts must be made to evaluate promising therapeutic alternatives, to eventually bring the best candidates into human clinical studies.

## 6. Disclosures

The authors declare the following financial interests/personal relationships which may be considered as potential competing interests: Maria Notara reports travel was provided by COST. Maria Notara reports a relationship with University Hospital Cologne Centre of Ophthalmology that includes: employment. Neil Lagali reports article publishing charges and travel were provided by European Cooperation in Science and Technology. Member of the Scientific Committee of Aniridia Europe, a patient organization. Chair of the EU Cooperation on Science and Technology Action ANIRIDIA-NET.

## Funding

This work was supported by the European Union's Cooperation on Science and Technology (COST) Program, under COST Action CA-18116 ANIRIDIA-NET: "Aniridia: networking to address an unmet medical, scientific, and societal challenge; DFG German Research Council FOR 2240 (www.for2240.de) to C. C. and M. N.; the European Joint Programme on Rare Diseases (EJP RD 2020) to N. L., D. B. G., D. A. (AAK-INSIGHT); the Science Foundation Ireland Investigator Award (Grant 12/IA/1624), the European Regional Development Fund and the European Union's Horizon 2020 Research and Innovation Programme (Grant 814439) to T. R.; Academy of Finland (Grant 338988) to H. S.; the Dutch Research Council ZonMw TOP (Grant 91217058, VISION) to M. M. D., S. F. and V. L. S. L.

## CRediT authorship contribution statement

*Conceptualization:* A. J. H. V., S. F., V. L. S. L., and M. M. D.; *Investigation:* A. J. H. V., D. B., H. S., D. A., C. C., and N. L.; *Resources:* M. N., F. C. F., J. T. D., G. F., C. G., C. K., M. P., T. R. and V. R.; *Writing – original draft:* A. J. H. V., D. B., H. S., D. A., C. C., and N. L.; *Writing – review & editing:* A. J. H. V., V. L. S. L., and M. M. D.; *Supervision:* A. J. H. V., S. F., V. L. S. L., and M. M. D.; *Funding acquisition:* N. L.

## Declaration of Competing Interest

The authors have no conflicts of interest to declare.

## Acknowledgments

We would like to acknowledge the illustrators Daniela Velasco for the illustrations in Figs. 1 and 4 and Sara T. Nøland for the illustrations in Fig. 2. We cordially thank Aniridia Europe for support and motivation.

## Method of Literature Search

In this perspective review, we consulted with experts in the field and formulated our understanding of AAK pathogenesis and future perspectives on AAK management.

## REFERENCES

- Alvarez-Rivera F, Rey-Rico A, Venkatesan JK, Diaz-Gomez L, Cucchiari M, Concheiro A, et al. Controlled release of rAAV vectors from APMA-functionalized contact lenses for corneal gene therapy. *Pharmaceutics*. 2020;12(4):335.
- Ambati BK, Nozaki M, Singh N, Takeda A, Jani PD, Suthar T, et al. Corneal avascularity is due to soluble VEGF receptor-1. *Nature*. 2006;443(7114):993–7.
- Ang AY, Chan CC, Biber JM, Holland EJ. Ocular surface stem cell transplantation rejection: incidence, characteristics, and outcomes. *Cornea*. 2013;32(3):229–36.
- Beebe DC. Maintaining transparency: a review of the developmental physiology and pathophysiology of two avascular tissues. *Semin Cell Dev Biol*. 2008;19(2):125–33.
- Behaegel J, Consejo A, Wouters K, Koppen C, De Cock J, Ni Dhubbghaill S. Development and validation of an open-source grading tool for outcome assessment in limbal stem cell treatment. *Cornea*. 2020;39(6):787–92.
- Behaegel J, Tassignon MJ, Lagali N, Consejo A, Koppen C, Ni Dhubbghaill S. Outcomes of human leukocyte antigen-matched allogeneic cultivated limbal epithelial transplantation in aniridia-associated keratopathy—a single-center retrospective analysis. *Cornea*. 2022;41(1):69–77.
- Behaegel J, Zakaria N, Tassignon MJ, Leysen I, Bock F, Koppen C, et al. Short- and long-term results of xenogeneic-free cultivated autologous and allogeneic limbal epithelial stem cell transplantations. *Cornea*. 2019;38(12):1543–9.
- Bernabei F, Roda M, Buzzi M, Pellegrini M, Giannaccare G, Versura P. Blood-based treatments for severe dry eye disease: the need of a consensus. *J Clin Med*. 2019;8(9):1478.
- Berntsson SG, Kristoffersson A, Daniilidou M, Dahl N, Ekstrom C, Semnic R, et al. Aniridia with PAX6 mutations and narcolepsy. *J Sleep Res*. 2020;29(6):e12982.
- Bloquel C, Bejjani R, Bigey P, Bedioui F, Doat M, BenEzra D, et al. Plasmid electrotransfer of eye ciliary muscle: principles and therapeutic efficacy using hTNF-alpha soluble receptor in uveitis. *FASEB J*. 2006;20(2):389–91.
- Bobilev AM, Hudgens-Haney ME, Hamm JP, Oliver WT, McDowell JE, Lauderdale JD, et al. Early and late auditory information processing show opposing deviations in aniridia. *Brain Res*. 2019;1720:146307.
- Bock F, Konig Y, Kruse F, Baier M, Cursiefen C. Bevacizumab (Avastin) eye drops inhibit corneal neovascularization. *Graefes Arch Clin Exp Ophthalmol*. 2008;246(2):281–4.
- Bock F, Onderka J, Dietrich T, Bachmann B, Kruse FE, Paschke M, et al. Bevacizumab as a potent inhibitor of inflammatory corneal angiogenesis and lymphangiogenesis. *Investig Ophthalmol Vis Sci*. 2007;48(6):2545–52.

14. Bojic S, Hallam D, Alcada N, Ghareeb A, Queen R, Pervinder S, et al. CD200 expression marks a population of quiescent limbal epithelial stem cells with holoclone forming ability. *Stem Cells*. 2018;36(11):1723–35.
15. Booranapong W, Kosrirukvongs P, Duangsa-Ard S, Kasetsinsombat K, Sa-Ngiamsuntorn K, Wongkajornsilp A. Transplantation of autologous cultivated oral mucosal epithelial sheets for limbal stem cell deficiency at Siriraj Hospital: a case series. *J Med Case Rep*. 2022;16(1):298.
16. Bordet T, Behar-Cohen F. Ocular gene therapies in clinical practice: viral vectors and nonviral alternatives. *Drug Discov Today*. 2019;24(8):1685–93.
17. Bucher F, Parthasarathy A, Bergua A, Onderka J, Regenfuss B, Cursiefen C, et al. Topical ranibizumab inhibits inflammatory corneal hem- and lymphangiogenesis. *Acta Ophthalmol*. 2014;92(2):143–8.
18. Buckle A, Nozawa RS, Kleinjan DA, Gilbert N. Functional characteristics of novel pancreatic Pax6 regulatory elements. *Hum Mol Genet*. 2018;27(19):3434–48.
19. Cabral T, DiCarlo JE, Justus S, Sengillo JD, Xu Y, Tsang SH. CRISPR applications in ophthalmologic genome surgery. *Curr Opin Ophthalmol*. 2017;28(3):252–9.
20. Calonge M, Perez I, Galindo S, Nieto-Miguel T, Lopez-Paniagua M, Fernandez I, et al. A proof-of-concept clinical trial using mesenchymal stem cells for the treatment of corneal epithelial stem cell deficiency. *Transl Res*. 2019;206:18–40.
21. Campbell JDM, Ahmad S, Agrawal A, Bienek C, Atkinson A, McGowan NWA, et al. Allogeneic ex vivo expanded corneal epithelial stem cell transplantation: a randomized controlled clinical trial. *Stem Cells Transl Med*. 2019;8(4):323–31.
22. Cavallini GM, Pellegrini G, Volante V, Ducange P, De Maria M, Torlai G, et al. Chemical injury treated with autologous limbal epithelial stem cell transplantation and subconjunctival bevacizumab. *Clin Ophthalmol*. 2014;8:1671–3.
23. Chakrabarty K, Shetty R, Ghosh A. Corneal cell therapy: with iPSCs, it is no more a far-sight. *Stem Cell Res Ther*. 2018;9(1):287.
24. Cheung AY, Eslani M, Kurji KH, Wright E, Sarnicola E, Govil A, et al. Long-term outcomes of living-related conjunctival limbal allograft compared with keratolimbal allograft in patients with limbal stem cell deficiency. *Cornea*. 2020;39(8):980–5.
25. Cole JD, McHaney KM, Rabiee B, Gao J, Rodriguez C, Miller DA, et al. Long-term retinal protection by MEK inhibition in Pax6 haploinsufficiency mice. *Exp Eye Res*. 2022;218:109012.
26. Crolla JA, van Heyningen V. Frequent chromosome aberrations revealed by molecular cytogenetic studies in patients with aniridia. *Am J Hum Genet*. 2002;71(5):1138–49.
27. Cursiefen C, Bock F, Horn FK, Kruse FE, Seitz B, Borderie V, et al. GS-101 antisense oligonucleotide eye drops inhibit corneal neovascularization: interim results of a randomized phase II trial. *Ophthalmology*. 2009;116(9):1630–7.
28. Cursiefen C, Cao J, Chen L, Liu Y, Maruyama K, Jackson D, et al. Inhibition of hemangiogenesis and lymphangiogenesis after normal-risk corneal transplantation by neutralizing VEGF promotes graft survival. *Investig Ophthalmol Vis Sci*. 2004;45(8):2666–73.
29. Cursiefen C, Hofmann-Rummelt C, Kuchle M, Schlotzer-Schrehardt U. Pericyte recruitment in human corneal angiogenesis: an ultrastructural study with clinicopathological correlation. *Br J Ophthalmol*. 2003;87(1):101–6.
30. Cursiefen C, Viaud E, Bock F, Geudelin B, Ferry A, Kadlecova P, et al. Aganirsen antisense oligonucleotide eye drops inhibit keratitis-induced corneal neovascularization and reduce need for transplantation: the I-CAN study. *Ophthalmology*. 2014;121(9):1683–92.
31. Cyranoski D. Woman is first to receive cornea made from 'reprogrammed' stem cells. *Nature*. 2019.
32. Daruich A, Duncan M, Robert MP, Lagali N, Semina EV, Aberdam D, et al. Congenital aniridia beyond black eyes: from phenotype and novel genetic mechanisms to innovative therapeutic approaches. *Prog Retin Eye Res*. 2022;101133.
33. Davis J, Piatigorsky J. Overexpression of Pax6 in mouse cornea directly alters corneal epithelial cells: changes in immune function, vascularization, and differentiation. *Investig Ophthalmol Vis Sci*. 2011;52(7):4158–68.
34. Daya SM, Watson A, Sharpe JR, Giledi O, Rowe A, Martin R, et al. Outcomes and DNA analysis of ex vivo expanded stem cell allograft for ocular surface reconstruction. *Ophthalmology*. 2005;112(3):470–7.
35. Deo D, Marchioni M, Rao P. Mesenchymal stem/stromal cells in organ transplantation. *Pharmaceutics*. 2022;14(4):791.
36. Detry B, Blacher S, Ercicum C, Paupert J, Maertens L, Maillard C, et al. Sunitinib inhibits inflammatory corneal lymphangiogenesis. *Investig Ophthalmol Vis Sci*. 2013;54(5):3082–93.
37. Djalilian AR, Mahesh SP, Koch CA, Nussenblatt RB, Shen D, Zhuang Z, et al. Survival of donor epithelial cells after limbal stem cell transplantation. *Investig Ophthalmol Vis Sci*. 2005;46(3):803–7.
38. Djayet C, Bremond-Gignac D, Touchard J, Secretan PH, Vidal F, Robert MP, et al. Formulation and stability of ataluren eye drop oily solution for aniridia. *Pharmaceutics*. 2020;13(1):7.
39. Dobrowolski D, Orzechowska-Wylegala B, Wowra B, Wroblewska-Czajka E, Grolik M, Szczubialka K, et al. Cultivated oral mucosa epithelium in ocular surface reconstruction in aniridia patients. *Biomed Res Int*. 2015;2015:281870.
40. Dorot O, Roux LN, Zennaro L, Oved K, Bremond-Gignac D, Pichinuk E, et al. The antipsychotropic drug duloxetine rescues PAX6 haploinsufficiency of mutant limbal stem cells through inhibition of the MEK/ERK signaling pathway. *Ocul Surf*. 2022;23:140–2.
41. Dua HS, Miri A, Elalfy MS, Lencova A, Said DG. Amnion-assisted conjunctival epithelial redirection in limbal stem cell grafting. *Br J Ophthalmol*. 2017;101(7):913–9.
42. Dyer A, De Faria A, Julio G, Alvarez de Toledo J, Barraquer RI, de la Paz MF. Long-term anatomical and functional survival of Boston type 1 keratoprosthesis in congenital aniridia. *Front Med*. 2021;8:749063.
43. Eberwein P, Bohringer D, Schwartzkopff J, Birnbaum F, Reinhard T. Allogenic limbo-keratoplasty with conjunctivoplasty, mitomycin C, and amniotic membrane for bilateral limbal stem cell deficiency. *Ophthalmology*. 2012;119(5):930–7.
44. Eden U, Fagerholm P, Danyali R, Lagali N. Pathologic epithelial and anterior corneal nerve morphology in early-stage congenital aniridic keratopathy. *Ophthalmology*. 2012;119(9):1803–10.
45. Eden U, Riise R, Tornqvist K. Corneal involvement in congenital aniridia. *Cornea*. 2010;29(10):1096–102.
46. Enders P, Cursiefen C. Device profile of the EYEMATE-IO system for intraocular pressure monitoring: overview of its safety and efficacy. *Expert Rev Med Devices*. 2020;17(6):491–7.
47. Enders P, Hall J, Bornhauser M, Mansouri K, Altay L, Schrader S, et al. Telemetric intraocular pressure monitoring after boston keratoprosthesis surgery using the Eyemate-IO Sensor: dynamics in the first year. *Am J Ophthalmol*. 2019;206:256–63.
48. Enders P, Hall J, Bornhauser M, Mansouri K, Altay L, Schrader S, et al. Telemetric intraocular pressure monitoring after

- Boston keratoprosthesis surgery. *Ophthalmology*. 2019;126(2):322–4.
49. Ferrari G, Dastjerdi MH, Okanobo A, Cheng SF, Amparo F, Nallasamy N, et al. Topical Ranibizumab as a treatment of corneal neovascularization. *Cornea*. 2013;32(7):992–7.
  50. Geerling G, MacLennan S, Hartwig D. Autologous serum eye drops for ocular surface disorders. *Br J Ophthalmol*. 2004;88(11):1467–74.
  51. Gong N, Pleyer U, Yang J, Vogt K, Hill M, Anegon I, et al. Influence of local and systemic CTLA4Ig gene transfer on corneal allograft survival. *J Gene Med*. 2006;8(4):459–67.
  52. Gouveia RM, Lepert G, Gupta S, Mohan RR, Paterson C, Connon CJ. Assessment of corneal substrate biomechanics and its effect on epithelial stem cell maintenance and differentiation. *Nat Commun*. 2019;10(1):1496.
  53. Grant MK, Bobilev AM, Branch A, Lauderdale JD. Structural and functional consequences of PAX6 mutations in the brain: implications for aniridia. *Brain Res*. 2021;1756:147283.
  54. Gregory-Evans CY, Wang X, Wasan KM, Zhao J, Metcalfe AL, Gregory-Evans K. Postnatal manipulation of Pax6 dosage reverses congenital tissue malformation defects. *J Clin Invest*. 2014;124(1):111–6.
  55. Gris O, Guell JL, Lopez-Navidad A, Caballero F, Del Campo Z. Application of the amniotic membrane in ocular surface pathology. *Ann Transplant*. 1999;4(3–4):82–4.
  56. Han B, Hu Y. Effects of CTLA4-Ig gene-modified dendritic cells on the corneal allografts. *J Huazhong Univ Sci Technol Med Sci*. 2006;26(3):366–8.
  57. Harkin DG, Foyn L, Bray LJ, Sutherland AJ, Li FJ, Cronin BG. Concise reviews: can mesenchymal stromal cells differentiate into corneal cells? A systematic review of published data. *Stem Cells*. 2015;33(3):785–91.
  58. Henderson TR, Coster DJ, Williams KA. The long term outcome of limbal allografts: the search for surviving cells. *Br J Ophthalmol*. 2001;85(5):604–9.
  59. Hickmott JW, Chen CY, Arenillas DJ, Korecki AJ, Lam SL, Molday LL, et al. PAX6 minipromoters drive restricted expression from rAAV in the adult mouse retina. *Mol Ther Methods Clin Dev*. 2016;3:16051.
  60. Hille K, Grabner G, Liu C, Colliardo P, Falcinelli G, Taloni M, et al. Standards for modified osteodontokeratoprosthesis (OOKP) surgery according to strampelli and falcinelli: the Rome-Vienna Protocol. *Cornea*. 2005;24(8):895–908.
  61. Hingorani M, Williamson KA, Moore AT, van Heyningen V. Detailed ophthalmologic evaluation of 43 individuals with PAX6 mutations. *Investig Ophthalmol Vis Sci*. 2009;50(6):2581–90.
  62. Hoang DM, Pham PT, Bach TQ, Ngo ATL, Nguyen QT, Phan TTK, et al. Stem cell-based therapy for human diseases. *Signal Transduct Target Ther*. 2022;7(1):272.
  63. Holan V, Trosan P, Cejka C, Javorkova E, Zajicova A, Hermankova B, et al. A comparative study of the therapeutic potential of mesenchymal stem cells and limbal epithelial stem cells for ocular surface reconstruction. *Stem Cells Transl Med*. 2015;4(9):1052–63.
  64. Holland EJ, Djalilian AR, Schwartz GS. Management of aniridic keratopathy with keratolimbal allograft: a limbal stem cell transplantation technique. *Ophthalmology*. 2003;110(1):125–30.
  65. Holland EJ, Mogilishetty G, Skeens HM, Hair DB, Neff KD, Biber JM, et al. Systemic immunosuppression in ocular surface stem cell transplantation: results of a 10-year experience. *Cornea*. 2012;31(6):655–61.
  66. Hos D, Bock F, Dietrich T, Onderka J, Kruse FE, Thierauch KH, et al. Inflammatory corneal (lymph)angiogenesis is blocked by VEGFR-tyrosine kinase inhibitor ZK 261991, resulting in improved graft survival after corneal transplantation. *Investig Ophthalmol Vis Sci*. 2008;49(5):1836–42.
  67. Hos D, Matthaei M, Bock F, Maruyama K, Notara M, Clahsen T, et al. Immune reactions after modern lamellar (DALK, DSAEK, DMEK) versus conventional penetrating corneal transplantation. *Prog Retin Eye Res*. 2019;73:100768.
  68. Hos D, Regenfuss B, Bock F, Onderka J, Cursiefen C. Blockade of insulin receptor substrate-1 inhibits corneal lymphangiogenesis. *Investig Ophthalmol Vis Sci*. 2011;52(8):5778–85.
  69. Hos D, Saban DR, Bock F, Regenfuss B, Onderka J, Masli S, et al. Suppression of inflammatory corneal lymphangiogenesis by application of topical corticosteroids. *Arch Ophthalmol*. 2011;129(4):445–52.
  70. Hou Y, Le VNH, Clahsen T, Schneider AC, Bock F, Cursiefen C. Photodynamic therapy leads to time-dependent regression of pathologic corneal (lymph) angiogenesis and promotes high-risk corneal allograft survival. *Investig Ophthalmol Vis Sci*. 2017;58(13):5862–9.
  71. Hou Y, Le VNH, Toth G, Siebelmann S, Horstmann J, Gabriel T, et al. UV light crosslinking regresses mature corneal blood and lymphatic vessels and promotes subsequent high-risk corneal transplant survival. *Am J Transplant*. 2018;18(12):2873–84.
  72. Ihnatko R, Eden U, Fagerholm P, Lagali N. Congenital aniridia and the ocular surface. *Ocul Surf*. 2016;14(2):196–206.
  73. Ihnatko R, Eden U, Lagali N, Dellby A, Fagerholm P. Analysis of protein composition and protein expression in the tear fluid of patients with congenital aniridia. *J Proteomics*. 2013;94:78–88.
  74. Ji YW, Lee JL, Kang HG, Gu N, Byun H, Yeo A, et al. Corneal lymphangiogenesis facilitates ocular surface inflammation and cell trafficking in dry eye disease. *Ocul Surf*. 2018;16(3):306–13.
  75. Katiyar P, Stachon T, Fries FN, Parow F, Ulrich M, Langenbacher A, et al. Decreased FABP5 and DSG1 protein expression following PAX6 knockdown of differentiated human limbal epithelial cells. *Exp Eye Res*. 2022;215:108904.
  76. Kawashima M, Kawakita T, Higa K, Satake Y, Omoto M, Tsubota K, et al. Subepithelial corneal fibrosis partially due to epithelial-mesenchymal transition of ocular surface epithelium. *Mol Vis*. 2010;16:2727–32.
  77. Kleinjan DA, Seawright A, Mella S, Carr CB, Tyas DA, Simpson TI, et al. Long-range downstream enhancers are essential for Pax6 expression. *Dev Biol*. 2006;299(2):563–81.
  78. Koenig Y, Bock F, Kruse FE, Stock K, Cursiefen C. Angioregressive pretreatment of mature corneal blood vessels before keratoplasty: fine-needle vessel coagulation combined with anti-VEGFs. *Cornea*. 2012;31(8):887–92.
  79. Kroeber M, Davis N, Holzmann S, Kritzenberger M, Shelah-Goraly M, Ofri R, et al. Reduced expression of Pax6 in lens and cornea of mutant mice leads to failure of chamber angle development and juvenile glaucoma. *Hum Mol Genet*. 2010;19(17):3332–42.
  80. Lagali N, Eden U, Utheim TP, Chen X, Riise R, Dellby A, et al. In vivo morphology of the limbal palisades of vogt correlates with progressive stem cell deficiency in aniridia-related keratopathy. *Investig Ophthalmol Vis Sci*. 2013;54(8):5333–42.
  81. Lagali N, Stenevi U, Claesson M, Fagerholm P, Hanson C, Wejdegard B, et al. Survival of donor-derived cells in human corneal transplants. *Investig Ophthalmol Vis Sci*. 2009;50(6):2673–8.
  82. Lagali N, Wowra B, Dobrowolski D, Utheim TP, Fagerholm P, Wylegala E. Stage-related central corneal epithelial transformation in congenital aniridia-associated keratopathy. *Ocul Surf*. 2018;16(1):163–72.
  83. Lagali N, Wowra B, Fries FN, Latta L, Moslemani K, Utheim TP, et al. PAX6 mutational status determines aniridia-associated keratopathy phenotype. *Ophthalmology*. 2020;127(2):273–5.



84. Lagali N, Wowra B, Fries FN, Latta L, Moslemani K, Utheim TP, et al. Early phenotypic features of aniridia-associated keratopathy and association with PAX6 coding mutations. *Ocul Surf.* 2020;18(1):130–40.
85. Landsend ECS, Lagali N, Utheim TP. Congenital aniridia - a comprehensive review of clinical features and therapeutic approaches. *Surv Ophthalmol.* 2021;66(6):1031–50.
86. Landsend ECS, Pedersen HR, Utheim OA, Xiao J, Adil MY, Tashbayev B, et al. Meibomian gland dysfunction and keratopathy are associated with dry eye disease in aniridia. *Br J Ophthalmol.* 2019;103(1):119–24.
87. Landsend ECS, Utheim OA, Pedersen HR, Aass HCD, Lagali N, Dartt DA, et al. The level of inflammatory tear cytokines is elevated in congenital aniridia and associated with meibomian gland dysfunction. *Investig Ophthalmol Vis Sci.* 2018;59(5):2197–204.
88. Landsend ES, Utheim OA, Pedersen HR, Lagali N, Baraas RC, Utheim TP. The genetics of congenital aniridia - a guide for the ophthalmologist. *Surv Ophthalmol.* 2018;63(1):105–13.
89. Lapid-Gortzak R, Santana NTY, Nieuwendaal CP, Mourits MP, van der Meulen IJE. Topical Bevacizumab treatment in aniridia. *Int Ophthalmol.* 2018;38(4):1741–6.
90. Latta L, Figueiredo FC, Ashery-Padan R, Collinson JM, Daniels J, Ferrari S, et al. Pathophysiology of aniridia-associated keratopathy: developmental aspects and unanswered questions. *Ocul Surf.* 2021;22:245–66.
91. Latta L, Ludwig N, Krammes L, Stachon T, Fries FN, Mukwaya A, et al. Abnormal neovascular and proliferative conjunctival phenotype in limbal stem cell deficiency is associated with altered microRNA and gene expression modulated by PAX6 mutational status in congenital aniridia. *Ocul Surf.* 2021;19:115–27.
92. Latta L, Nordstrom K, Stachon T, Langenbucher A, Fries FN, Szentmary N, et al. Expression of retinoic acid signaling components ADH7 and ALDH1A1 is reduced in aniridia limbal epithelial cells and a siRNA primary cell based aniridia model. *Exp Eye Res.* 2019;179:8–17.
93. Latta L, Viestenz A, Stachon T, Colanesi S, Szentmary N, Seitz B, et al. Human aniridia limbal epithelial cells lack expression of keratins K3 and K12. *Exp Eye Res.* 2018;167:100–9.
94. Lee JB, Ha SJ, Kim HR. Clinical insights into novel immune checkpoint inhibitors. *Front Pharmacol.* 2021;12:681320.
95. Lee HK, Kim MK, Oh JY. Corneal abnormalities in congenital aniridia: congenital central corneal opacity versus aniridia-associated keratopathy. *Am J Ophthalmol.* 2018;185:75–80.
96. Le Q, Chauhan T, Yung M, Tseng CH, Deng SX. Outcomes of limbal stem cell transplant: a meta-analysis. *JAMA Ophthalmol.* 2020;138(6):660–70.
97. Le Q, Deng SX, Xu J. In vivo confocal microscopy of congenital aniridia-associated keratopathy. *Eye.* 2013;27(6):763–6.
98. Le VNH, Hou Y, Bock F, Cursiefen C. Supplemental anti Vegf a-therapy prevents rebound neovascularisation after fine needle diathermy treatment to regress pathological corneal (LYMPH) angiogenesis. *Sci Rep.* 2020;10(1):3908.
99. Le VNH, Schneider AC, Scholz R, Bock F, Cursiefen C. Fine needle-diathermy regresses pathological corneal (lymph) angiogenesis and promotes high-risk corneal transplant survival. *Sci Rep.* 2018;8(1):5707.
100. Lipp M, Bucher F, Parthasarathy A, Hos D, Onderka J, Cursiefen C, et al. Blockade of the VEGF isoforms in inflammatory corneal hemangiogenesis and lymphangiogenesis. *Graefes Arch Clin Exp Ophthalmol.* 2014;52(6):943–9.
101. Liu X, Zhang Y, Zhang B, Gao H, Qiu C. Nonsense suppression induced readthrough of a novel PAX6 mutation in patient-derived cells of congenital aniridia. *Mol Genet Genomic Med.* 2020;8(5):e1198.
102. Li W, Chen YT, Hayashida Y, Blanco G, Kheirkah A, He H, et al. Down-regulation of Pax6 is associated with abnormal differentiation of corneal epithelial cells in severe ocular surface diseases. *J Pathol.* 2008;214(1):114–22.
103. Lopez-Garcia JS, Rivas L, Garcia-Lozano I, Murube J. Autologous serum eyedrops in the treatment of aniridic keratopathy. *Ophthalmology.* 2008;115(2):262–7.
104. Lopez S, Hoz L, Tenorio EP, Buentello B, Magana FS, Wintergerst A, et al. Can human oral mucosa stem cells differentiate to corneal epithelia? *Int J Mol Sci.* 2021;22(11):5976.
105. Maguire AM, Bennett J, Aleman EM, Leroy BP, Aleman TS. Clinical perspective: treating RPE65-associated retinal dystrophy. *Mol Ther.* 2021;29(2):442–63.
106. Matharu N, Ahituv N. Modulating gene regulation to treat genetic disorders. *Nat Rev Drug Discov.* 2020;19(11):757–75.
107. Ma DH, Hsueh YJ, Ma KS, Tsai YJ, Huang SF, Chen HC, et al. Long-term survival of cultivated oral mucosal epithelial cells in human cornea: generating cell sheets using an animal product-free culture protocol. *Stem Cell Res Ther.* 2021;12(1):524.
108. Medical Advisory S. Limbal stem cell transplantation: an evidence-based analysis. *Ont Health Technol Assess Ser.* 2008;8(7):1–58.
109. Mikhailova A, Ilmarinen T, Ratnayake A, Petrovski G, Uusitalo H, Skottman H, et al. Human pluripotent stem cell-derived limbal epithelial stem cells on bioengineered matrices for corneal reconstruction. *Exp Eye Res.* 2016;146:26–34.
110. Mirjalili Mohanna SZ, Hickmott JW, Lam SL, Chiu NY, Lengyell TC, Tam BM, et al. Germline CRISPR/Cas9-mediated gene editing prevents vision loss in a novel mouse model of aniridia. *Mol Ther Methods Clin Dev.* 2020;17:478–90.
111. Mohammadi P, Hesari M, Chalabi M, Salari F, Khademi F. An overview of immune checkpoint therapy in autoimmune diseases. *Int Immunopharmacol.* 2022;107:108647.
112. Moshirfar M., Hastings J., Ronquillo Y. Aniridic fibrosis syndrome. *StatPearls. Treasure Island, FL, 2022.*
113. Murphy N, Lynch K, Lohan P, Treacy O, Ritter T. Mesenchymal stem cell therapy to promote corneal allograft survival: current status and pathway to clinical translation. *Curr Opin Organ Transplant.* 2016;21(6):559–67.
114. Murri MS, Moshirfar M, Birdsong OC, Ronquillo YC, Ding Y, Hoopes PC. Amniotic membrane extract and eye drops: a review of literature and clinical application. *Clin Ophthalmol.* 2018;12:1105–12.
115. Nelson LB, Spaeth GL, Nowinski TS, Margo CE, Jackson L. Aniridia. A review. *Surv Ophthalmol.* 1984;28(6):621–42.
116. Netland PA, Scott ML, Boyle JWt, Lauderdale JD. Ocular and systemic findings in a survey of aniridia subjects. *J AAPOS.* 2011;15(6):562–6.
117. Norrick A, Esterlechner J, Niebergall-Roth E, Dehio U, Sadeghi S, Schroder HM, et al. Process development and safety evaluation of ABCB5(+) limbal stem cells as advanced-therapy medicinal product to treat limbal stem cell deficiency. *Stem Cell Res Ther.* 2021;12(1):194.
118. Notara M, Lentzsch A, Clahsen T, Behboudifard S, Braun G, Cursiefen C. Bevacizumab induces upregulation of keratin 3 and VEGFA in human limbal epithelial cells in vitro. *J Clin Med.* 2019;8(11):1925.
119. Omoto M, Shimmura S, Hatou S, Ichihashi Y, Kawakita T, Tsubota K. Simultaneous deep anterior lamellar keratoplasty and limbal allograft in bilateral limbal stem cell deficiency. *Jpn J Ophthalmol.* 2010;54(6):537–43.
120. Ou J, Lowes C, Collinson JM. Cytoskeletal and cell adhesion defects in wounded and Pax6+/- corneal epithelia. *Investig Ophthalmol Vis Sci.* 2010;51(3):1415–23.

121. Ou J, Walczysko P, Kucerova R, Rajnicek AM, McGaig CD, Zhao M, et al. Chronic wound state exacerbated by oxidative stress in Pax6<sup>+</sup>/aniridia-related keratopathy. *J Pathol.* 2008;215(4):421–30.
122. Oved K, Zennaro L, Dorot O, Zerbib J, Frank E, Roux LN, et al. Ritanserin, a potent Serotonin 2A receptor antagonist, represses MEK/ERK signalling pathway to restore PAX6 production and function in aniridia-like cellular model. *Biochem Biophys Res Commun.* 2021;582:100–4.
123. de la Paz MF, Alvarez de Toledo J, Barraquer RI, Barraquer J. Long-term visual prognosis of corneal and ocular surface surgery in patients with congenital aniridia. *Acta Ophthalmol.* 2008;86(7):735–40.
124. Pellegrini G, Traverso CE, Franzi AT, Zingirian M, Cancedda R, De Luca M. Long-term restoration of damaged corneal surfaces with autologous cultivated corneal epithelium. *Lancet.* 1997;349(9057):990–3.
125. Petrus-Reurer S, Romano M, Howlett S, Jones JL, Lombardi G, Saeb-Parsy K. Immunological considerations and challenges for regenerative cellular therapies. *Commun Biol.* 2021;4(1):798.
126. Prabhasawat P, Chirapapaisan C, Jiravarnsirikul A, Ekpo P, Uiprasertkul M, Thamphithak R, et al. Phenotypic characterization of corneal epithelium in long-term follow-up of patients post-autologous cultivated oral mucosal epithelial transplantation. *Cornea.* 2021;40(7):842–50.
127. Rabiee B, Anwar KN, Shen X, Putra I, Liu M, Jung R, et al. Gene dosage manipulation alleviates manifestations of hereditary PAX6 haploinsufficiency in mice. *Sci Transl Med.* 2020;12(573):eaaz4894.
128. Rahman I, Said DG, Maharajan VS, Dua HS. Amniotic membrane in ophthalmology: indications and limitations. *Eye.* 2009;23(10):1954–61.
129. Ramachandran C, Deshpande P, Ortega I, Sefat F, McKean R, Srivastava M, et al. Proof-of-Concept study of electrospun PLGA membrane in the treatment of limbal stem cell deficiency. *BMJ Open Ophthalmol.* 2021;6(1):e000762.
130. Ramaesh K, Ramaesh T, Dutton GN, Dhillon B. Evolving concepts on the pathogenic mechanisms of aniridia related keratopathy. *Int J Biochem Cell Biol.* 2005;37(3):547–57.
131. Rama P, Matuska S, Paganoni G, Spinelli A, De Luca M, Pellegrini G. Limbal stem-cell therapy and long-term corneal regeneration. *N Engl J Med.* 2010;363(2):147–55.
132. Reinhard T, Spelsberg H, Henke L, Kontopoulos T, Enczmann J, Wernet P, et al. Long-term results of allogeneic penetrating limbo-keratoplasty in total limbal stem cell deficiency. *Ophthalmology.* 2004;111(4):775–82.
133. Rodrigues GA, Shalaev E, Karami TK, Cunningham J, Slater NKH, Rivers HM. Pharmaceutical development of AAV-based gene therapy products for the eye. *Pharm Res.* 2018;36(2):29.
134. Roux LN, Petit I, Domart R, Concordet JP, Qu J, Zhou H, et al. Modeling of aniridia-related keratopathy by CRISPR/Cas9 genome editing of human limbal epithelial cells and rescue by recombinant PAX6 protein. *Stem Cells.* 2018;36(9):1421–9.
135. Samoila O, Gocan D. Clinical outcomes from cultivated allogenic stem cells vs. oral mucosa epithelial transplants in total bilateral stem cells deficiency. *Front Med.* 2020;7:43.
136. Schaub F, Hou Y, Zhang W, Bock F, Hos D, Cursiefen C. Corneal crosslinking to regress pathologic corneal neovascularization before high-risk keratoplasty. *Cornea.* 2021;40(2):147–55.
137. Schaub F, Matthaai M, Enders P, Siebelmann S, Hos D, Bachmann BO, et al. Treatment of vascularized high-risk eyes with a Boston keratoprosthesis. *Ophthalmologie.* 2021;118(6):544–52.
138. Schlotzer-Schrehardt U, Freudenberg U, Kruse FE. The emerging technology of tissue engineering: focus on stem cell niche. *Ophthalmology.* 2017;114(4):327–40.
139. Schlotzer-Schrehardt U, Latta L, Giessler A, Zenkel M, Fries FN, Kasmann-Kellner B, et al. Dysfunction of the limbal epithelial stem cell niche in aniridia-associated keratopathy. *Ocul Surf.* 2021;21:160–73.
140. Serna-Ojeda JC, Garcia-Mejia M, Graue-Hernandez EO, Navas A, Garfias Y. Short-term results analysis in the allogenic transplantation of limbal stem cells expanded on amniotic membrane in patients with bilateral limbal stem cell deficiency. *J Ocul Pharmacol Ther.* 2020;36(4):238–46.
141. Shah KJ, Cheung AY, Holland EJ. Intermediate-term and long-term outcomes with the Boston type 1 keratoprosthesis in aniridia. *Cornea.* 2018;37(1):11–4.
142. Shimo N, Yasuda T, Kitamura T, Matsushita K, Osawa S, Yamamoto Y, et al. Aniridia with a heterozygous PAX6 mutation in which the pituitary function was partially impaired. *Intern Med.* 2014;53(1):39–42.
143. Shi WY, Xie LX. CTLA4-Ig prevents corneal allograft rejection in mice. *Zhonghua Yan Ke Za Zhi.* 2004;40(10):696–700.
144. Shortt AJ, Bunce C, Levis HJ, Blows P, Dore CJ, Vernon A, et al. Three-year outcomes of cultured limbal epithelial allografts in aniridia and Stevens-Johnson syndrome evaluated using the clinical outcome assessment in surgical trials assessment tool. *Stem Cells Transl Med.* 2014;3(2):265–75.
145. Szaflik JP, Major J, Izdebska J, Lao M, Szaflik J. Systemic immunosuppression with mycophenolate mofetil to prevent corneal graft rejection after high-risk penetrating keratoplasty: a 2-year follow-up study. *Graefes Arch Clin Exp Ophthalmol.* 2016;254(2):307–14.
146. Takahashi K, Okita K, Nakagawa M, Yamanaka S. Induction of pluripotent stem cells from fibroblast cultures. *Nat Protoc.* 2007;2(12):3081–9.
147. Tao R, Wang L, Han R, Wang T, Ye Q, Honjo T, et al. Differential effects of B and T lymphocyte attenuator and programmed death-1 on acceptance of partially versus fully MHC-mismatched cardiac allografts. *J Immunol.* 2005;175(9):5774–82.
148. Trapani I, Auricchio A. Seeing the light after 25 years of retinal gene therapy. *Trends Mol Med.* 2018;24(8):669–81.
149. Tsai JH, Freeman JM, Chan CC, Schwartz GS, Derby EA, Petersen MR, et al. A progressive anterior fibrosis syndrome in patients with postsurgical congenital aniridia. *Am J Ophthalmol.* 2005;140(6):1075–9.
150. Utheim T.P. Limbal epithelial cell therapy: past, present, and future. *Methods Mol Biol.* 2013;1014:3–43.
151. Vabres B, Le Bas-Bernardet S, Riochet D, Cheral Y, Minault D, Hervouet J, et al. hCTLA4-Ig transgene expression in keratocytes modulates rejection of corneal xenografts in a pig to non-human primate anterior lamellar keratoplasty model. *Xenotransplantation.* 2014;21(5):431–43.
152. Vanden Berg-Foels WS. In situ tissue regeneration: chemoattractants for endogenous stem cell recruitment. *Tissue Eng Part B Rev.* 2014;20(1):28–39.
153. Vasilyeva TA, Marakhonov AV, Voskresenskaya AA, Kadyshev VV, Kasmann-Kellner B, Sukhanova NV, et al. Analysis of genotype-phenotype correlations in PAX6-associated aniridia. *J Med Genet.* 2021;58(4):270–4.
154. Vattulainen M, Ilmarinen T, Viheriala T, Jokinen V, Skottman H. Corneal epithelial differentiation of human pluripotent stem cells generates ABCB5(+) and Np63alpha(+) cells with limbal cell characteristics and high wound healing capacity. *Stem Cell Res Ther.* 2021;12(1):609.
155. Vicente A, Bystrom B, Pedrosa Domellof F. Altered signaling pathways in aniridia-related keratopathy. *Investig Ophthalmol Vis Sci.* 2018;59(13):5531–41.
156. Wang X, Gregory-Evans K, Wasan KM, Sivak O, Shan X, Gregory-Evans CY. Efficacy of postnatal in vivo nonsense suppression therapy in a Pax6 mouse model of aniridia. *Mol Ther Nucleic Acids.* 2017;7:417–28.

157. Wang GM, Prasov L, Al-Hasani H, Marrs CER, Tolia S, Wiinikka-Buesser L, et al. Phenotypic variation in a four-generation family with aniridia carrying a novel PAX6 mutation. *J Ophthalmol*. 2018;2018:5978293.
158. Watanabe K, Nishida K, Yamato M, Umemoto T, Sumide T, Yamamoto K, et al. Human limbal epithelium contains side population cells expressing the ATP-binding cassette transporter ABCG2. *FEBS Lett*. 2004;565(1–3):6–10.
159. Yazdanpanah G, Bohm KJ, Hassan OM, Karas FI, Elhusseiny AM, Nonpassopon M, et al. Management of congenital aniridia-associated keratopathy: long-term outcomes from a tertiary referral center. *Am J Ophthalmol*. 2020;210:8–18.
160. Yeh SI, Chu TW, Cheng HC, Wu CH, Tsao YP. The use of autologous serum to reverse severe contact lens-induced limbal stem cell deficiency. *Cornea*. 2020;39(6):736–41.
161. Yokoi T, Nishina S, Fukami M, Ogata T, Hosono K, Hotta Y, et al. Genotype-phenotype correlation of PAX6 gene mutations in aniridia. *Hum Genome Var*. 2016;3:15052.
162. Yongblah K, Alford SC, Ryan BC, Chow RL, Howard PL. Protecting Pax6 3' UTR from microRNA-7 partially restores PAX6 in Islets from an aniridia mouse model. *Mol Ther Nucleic Acids*. 2018;13:144–53.
163. Zhang X, Qin G, Chen G, Li T, Gao L, Huang L, et al. Variants in TRIM44 cause aniridia by impairing PAX6 expression. *Hum Mutat*. 2015;36(12):1164–7.
164. Zhang J, Zhang H, Wang Z, Yang H, Chen H, Cheng H, et al. BTLA suppress acute rejection via regulating TCR downstream signals and cytokines production in kidney transplantation and prolonged allografts survival. *Sci Rep*. 2019;9(1):12154.