



# MEFV, IRF8, ADA, PEPD, and NBAS gene variants and elevated serum cytokines in a patient with unilateral sporadic Meniere's disease and vascular congestion over the endolymphatic sac<sup>☆</sup>

Jing Zou<sup>a, b, \*</sup>, Zikai Zhao<sup>a</sup>, Guoping Zhang<sup>a</sup>, Qing Zhang<sup>a</sup>, Ilmari Pyykkö<sup>c</sup>

<sup>a</sup> Department of Otolaryngology-Head and Neck Surgery, Changhai Hospital, Second Military Medical University, Shanghai, China

<sup>b</sup> Faculty of Information Technology and Communication Sciences, Tampere University, Tampere, Finland

<sup>c</sup> Hearing and Balance Research Unit, Field of Otolaryngology, School of Medicine, Faculty of Medicine and Health Technology, Tampere University, Tampere, Finland

## ARTICLE INFO

### Article history:

Received 25 February 2022

Received in revised form

5 March 2022

Accepted 9 March 2022

### Keywords:

Meniere's disease

Autoinflammation

Autoimmune

Immune organ

Endolymphatic sac

## ABSTRACT

The etiology and underlying mechanism of Meniere's disease (MD) development are still unknown, although inflammation and autoimmunity have been implicated as underlying mechanisms. The human endolymphatic sac (ES) has been reported to have innate and adaptive immune capacity in local immune reactions. In vivo demonstration of inflammation of the ES in patients with MD is missing in the literature. We report the case of a 47-year-old female patient diagnosed with unilateral MD with genetic variants and cytokine markers indicating inflammation and vascular congestion of the ES. Endolymphatic hydrops in the right cochlea (grade 2) and vestibulum (grade 3) were detected using MRI. She carried heterozygous variants in MEFV (c.442G > C), IRF8 (c.1157G > T), ADA (c.445C > T), PEPD (c.151G > A), NBAS (c.4049T > C), CSF2RB (c.2222C > T), HPS6 (c.277G > T), IL2RB (c.1109C > T), IL12RB1 (c.1384G > T), IL17RC (c.260\_271del GCAAGAGC TGGG), LIG1 (c.746G > A), RAG1 (c.650C > A), and SLX4 (c.1258G > C, c.5072A > G). In the serum, the levels of granulocyte colony-stimulating factor (G-CSF), macrophage inflammatory protein 1 $\alpha$ , and IL7 were significantly elevated, and the level of IL2R $\alpha$  was reduced. Intratympanic administration of dexamethasone temporarily alleviated her hearing loss. Her vertigo was significantly relieved but remained slight after ES administration of corticosteroids.

© 2022 PLA General Hospital Department of Otolaryngology Head and Neck Surgery. Production and hosting by Elsevier (Singapore) Pte Ltd. This is an open access article under the CC BY-NC-ND license (<http://creativecommons.org/licenses/by-nc-nd/4.0/>).

## 1. Introduction

The etiology and underlying mechanism of Meniere's disease (MD) development are still unknown, although clinical subgroups have been proposed (Frejo et al., 2016, 2017). However, inflammation resulting from various causes might be a common underlying mechanism of MD because intratympanic dexamethasone induces acceptable vertigo control in 91% of cases (Boleas-Aguirre et al., 2008). Macrophage-like cells and lymphocytes have been detected in the endolymphatic sac (ES) of patients with MD (Yazawa et al., 1989). Both innate and adaptive immune capacity of the

human ES in local immune reactions have been indicated by gene expression analyzed using a combination of microarray analysis and immunohistochemistry (Moller et al., 2015). The existence of fully functional macrophages involved in innate and adaptive immune reactions in the human ES was further suggested by a high-resolution immunohistochemistry study (Kampfe Nordstrom et al., 2018). However, in vivo demonstration of inflammation of the ES in patients with MD is still missing in the literature. We report the case of a patient with unilateral sporadic MD with vascular congestion over the ES carrying multiple gene variations and elevated serum cytokines.

<sup>☆</sup> This work was supported by the National Natural Science Foundation of China (81771006).

<sup>\*</sup> Corresponding author. Department of Otolaryngology-Head and Neck Surgery, Changhai Hospital, Second Military Medical University, Changhai Road #168, Shanghai, 200433, China.

E-mail address: [Jing.Zou@tuni.fi](mailto:Jing.Zou@tuni.fi) (J. Zou).

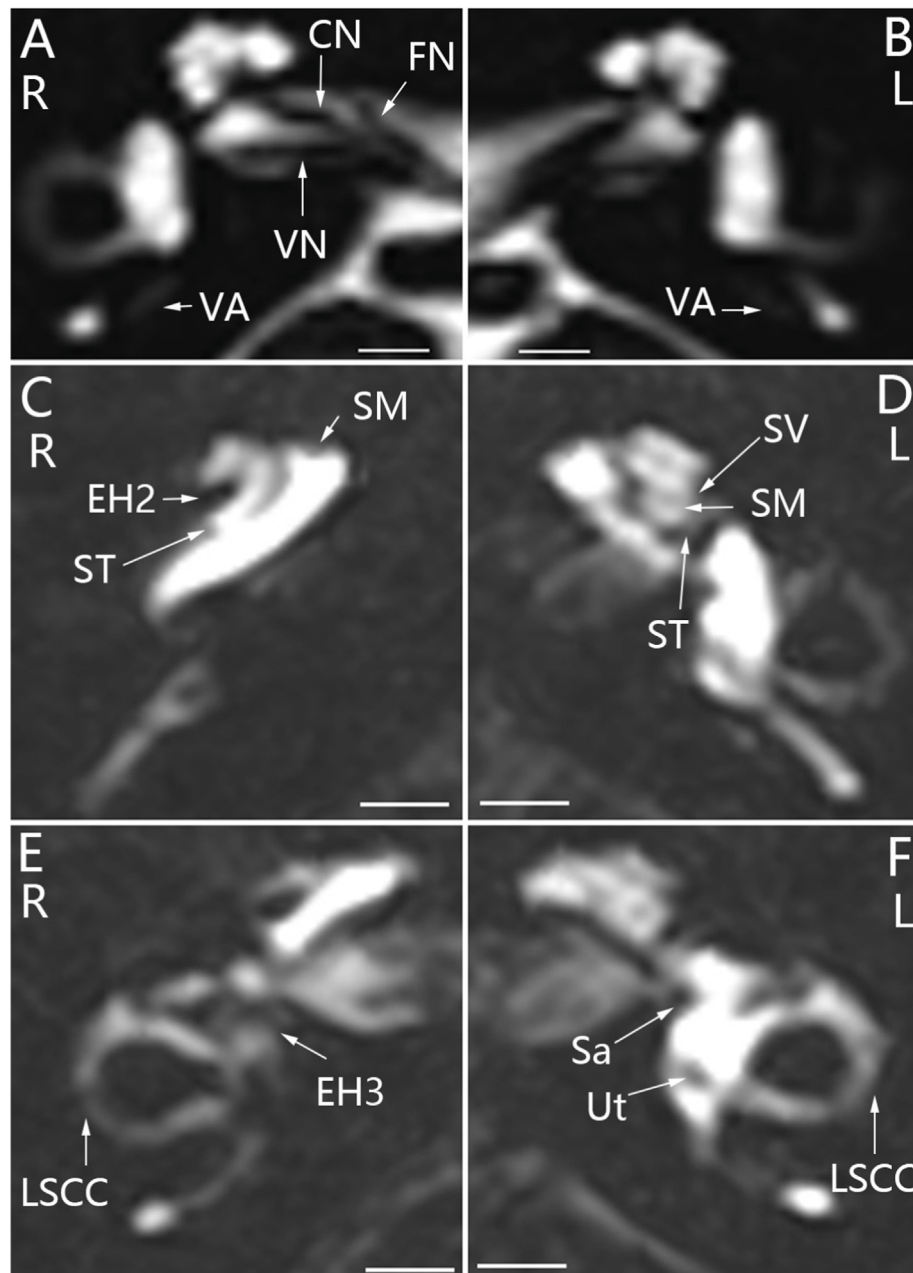
Peer review under responsibility of PLA General Hospital Department of Otolaryngology Head and Neck Surgery.

## 2. Case presentation

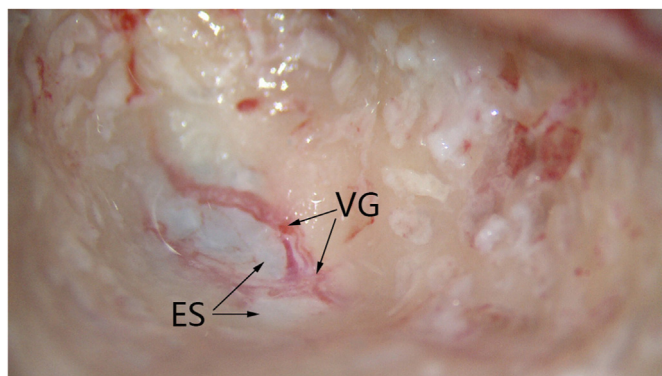
### 2.1. Clinical data

A 47-year-old woman complained of episodic vertigo and fluctuating hearing loss, tinnitus, and aural fullness in the right ear with a 6-year duration. Vertigo lasted for a maximum of 5 h and occurred once a year, but was exacerbated over the past 3 years. Five years ago, slight tinnitus appeared in the left ear but was not associated with the vertigo attack. Fluctuating hearing loss in the right ear without vertigo recurred 30 times over the past year. She

received intravenous infusions of alprostadil, vinpocetine, and dexamethasone, as well as hyperbaric oxygen therapy. Later, 5 intratympanic injections of dexamethasone were administered. Since the symptoms were not controlled, she visited author J.Z. and was diagnosed as having definite MD with MRI evidence of endolymphatic hydrops in both the cochlea and vestibule of the right ear (Fig. 1). She did not complain of symptoms of any other diseases and denied a familial history of MD. She received an intratympanic sustained delivery of dexamethasone on June 24, 2020, which was repeated 4 times. Her hearing recovered to normal (her own feeling) after the 3rd delivery on August 13, 2020, but fluctuated

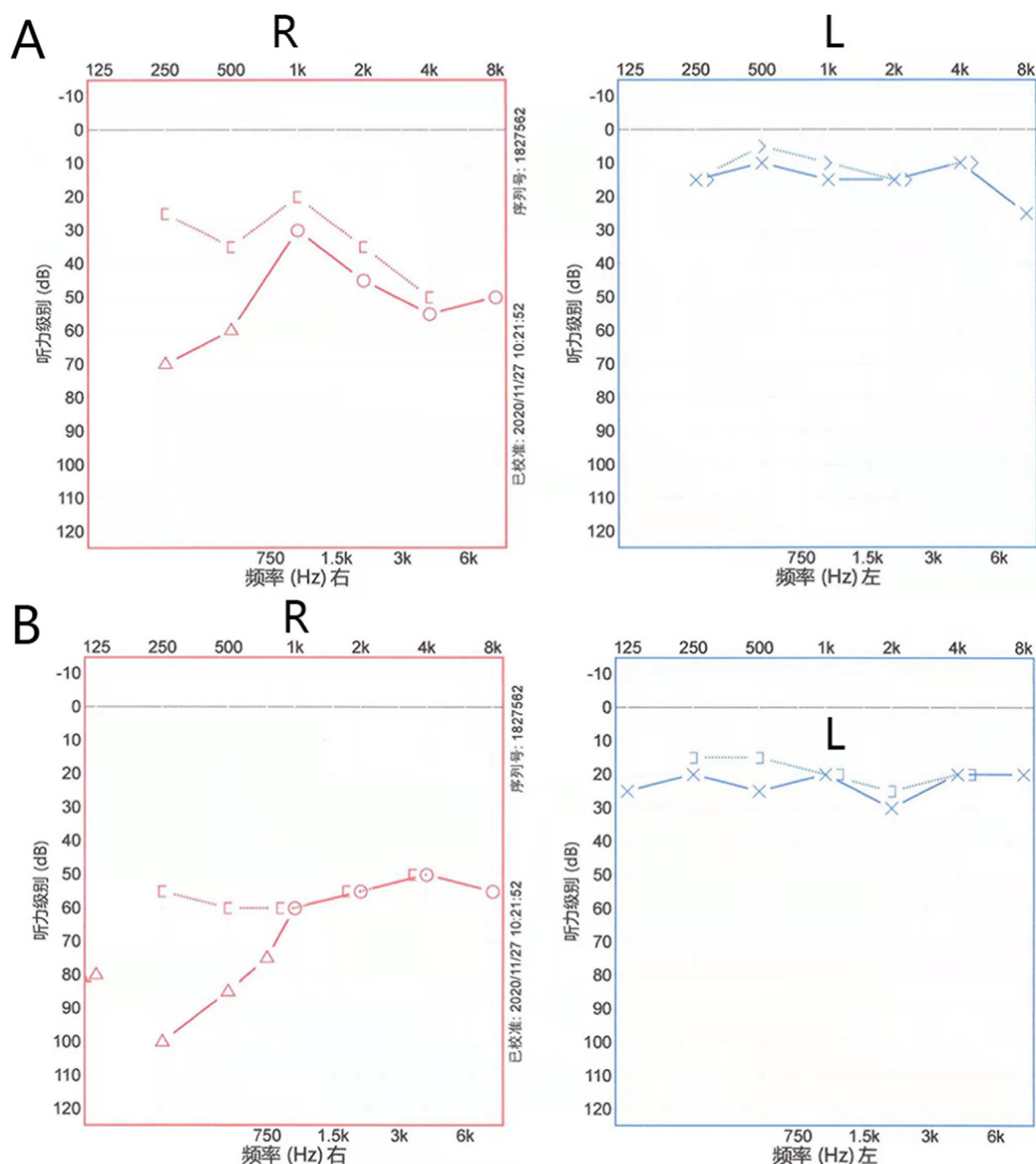


**Fig. 1.** Inner ear MRI 24 h after intratympanic administration of Gd-DTPA. T2-sampling perfection with application-optimized contrasts using a flip angle evolution (SPACE) sequence did not indicate either inner ear fibrosis or vestibular schwannoma (A, B). Cochlear grade 2 (C) and vestibular grade 3 (E) endolymphatic hydrops (EH) in the right ear (R) was demonstrated by heavily T2-weighted 3-dimensional fluid-attenuated inversion recovery reconstructed using a magnitude plus zero-filled interpolation (hT2FLAIR-MZFI) sequence acquired 24 h after intratympanic administration of Gd-DTPA mixed with dexamethasone (Zou J. et al., 2022). There was no EH in the left ear (L in D and F). CN: cochlear nerve; FN: facial nerve; LSCC: lateral semicircular canal; SM: scala media; ST: scala tympani; SV: scala vestibuli; VA: vestibular aqueduct; VN: vestibular nerve; Sa: saccule; Ut: utricle. Scale bars = 3.0 mm.



**Fig. 2.** Surgical photo of the endolymphatic sac on the right side. Significant vascular congestion (VG) over the surface and surrounding area of the endolymphatic sac (ES).

and progressed even after two further sustained deliveries of dexamethasone were repeated. Laboratory examinations showed that the levels of the complement proteins C3 (0.73 g/L) and C4 (0.13 g/L) were below the normal range. Routine blood examination showed elevated monocytes (11.2%) and basophils (1.1%). A routine urine test showed positive white blood cells (25/ $\mu$ L) and epithelial cells (15.4/HP). Blood biochemical examination showed reduced total proteins (44 g/L) and aspartate aminotransferase (13 U/L) and elevated high-density lipoprotein (1.59 mmol/L) and lipoprotein- $\alpha$  (393 mg/L). The other results, including those for immunoglobulins, transferrin,  $\beta$ 2-microglobulin,  $\alpha$ 1-microglobulin, ceruloplasmin, anti-streptolysin "O" antibody, erythrocyte sedimentation rate, rheumatoid factor, C-reactive protein, total triiodothyronine (T3), 3,3',5-triiodo-L-thyronine (3,3',5-T3), tetraiodothyronine (T4), calcitonin, thyroid stimulating hormone, thyroglobulin, anti-thyroglobulin antibodies, anti-thyroid peroxidase antibody, anti-



**Fig. 3.** Pure tone audiogram before (A) and 4.5 months postsurgery (B). L: left ear; R: right ear.

**Table 1**

The heterozygous gene variants detected in a patient with unilateral sporadic Meniere's disease.

Gene	Chr position	Transcript/Exon	Variants/AA	FreNor	REVEL	ACMG
MEFV	chr16:330 4626	NM_0002 43/exon2	c.442G > C/p.E148Q	0.315	B	Uncertain
IRF8	chr16:859 54764	NM_0021 63/exon9	c.1157G > T/p.G386V	Unkn	B	Uncertain
ADA	chr20:432 54243	NM_0000 22/exon5	c.445C > T/p.R149W	0.0000319	D	Pathogenic
PEPD	chr19:340 03549	NM_0002 85/exon2	c.151G > A/p.G51R	0.0038462	D	Uncertain
NBAS	chr2:1549 3717	NM_0159 09/exon34	c.4049T > C/p.I1350T	0.000004	LD	Uncertain
CSF2RB	chr22:373 34072	NM_0003 95/exon14	c.2222C > T/p.T741I	0.000008	B	Uncertain
HPS6	chr10:103 825508	NM_0247 47/exon1	c.277G > T/p.V93L	0.0040791	B	Uncertain
IL2RB	chr22:375 24683	NM_0008 78/exon10	c.1109C > T/p.P370L	0.0057766	B	Uncertain
IL12RB1	chr19:181 77451	NM_0055 35/exon12	c.1384G > T/p.V462L	0.0032134	B	Uncertain
IL17RC	chr3:9959 258- 9959270	NM_1534 61/exon1	c.260_271del GCAAGAGC TGGG/p.G87_W90del	0.012837	Unkn	Uncertain
LIG1	chr19:486 53050	NM_0002 34/exon9	c.746G > A/p.G249E	0.0198973	B	Uncertain
RAG1	chr11:365 95504	NM_0004 48/exon2	c.650C > A/p.A217D	0.0006427	B	Uncertain
SLX4	chr16:364 7906	NM_0324 44/exon6	c.1258G > C/p.D420H	Unkn	B	Uncertain
SLX4	chr16:363 3179	NM_0324 44/exon14	c.5072A > G/p.N1691S	0.0025674	B	Uncertain

AA: changes in amino acid; ACMG: statements and guidelines of the American College of Medical Genetics and Genomics that was used to report secondary findings in clinical exome and genome sequencing; B: benign; Chr position: chromosome position; D: disease; del: deletion; FreNor: frequencies of gene variant in the normal population, the highest frequency was taken among 1000 genomes, ESP6500 (NHLBI Exome Sequencing Project), EXAC (The Exome Aggregation Consortium), and EXAC-EAS (EXAC of 4000 eastern Asian descent); LD: limited disease; REVEL: rare exome variant ensemble learner software that was used to predict the pathogenicity of missense variants on the basis of individual tools; Unkn: unknown.

thyrotropin receptor antibody, and coagulation function, were in the normal range. Immunological detections of hepatitis B and C, syphilis, and human immunodeficiency virus were negative. She received endolymphatic sac delivery of steroids on May 12, 2021, as previously reported (Zou, 2019). Significant vascular congestion was visualized surrounding the ES during surgery (Fig. 2). A follow-up infusion of dexamethasone (5 mg/mL, 1 mL) to the area of the endolymphatic sac was performed through a preplaced catheter on July 13, 2021. From November 1 to December 16, 2021, the patient had daily mild vertigo (nonrotational) and one episode of rotational vertigo. Her hearing loss remained fluctuating and progressive (Fig. 3). The aural fullness went away on December 28, 2021.

## 2.2. Gene sequencing

Genomic DNA was extracted from the peripheral blood sample, and the whole exomes of 423 candidate genes potentially involved in diseases associated with immune reactions were selected according to Human Phenotype Ontology (<http://human-phenotype-ontology.github.io/>) and sequenced with next-generation sequencing (Zou et al., 2016). The data were analyzed, and the clinical significance of allelic variants was judged as previously reported (Zou, 2019). The following heterozygous variants were detected (Table 1): an autosomal-dominant inherited variant in Mediterranean fever (MEFV) (c.442G > C), an autosomal-dominant/recessive inherited variant in interferon regulatory factor 8 (IRF8) (c.1157G > T), autosomal-recessive inherited but pathologic variants in adenosine deaminase (ADA) (c.445C > T) and peptidase D (PEPD) (c.151G > A), and an autosomal-recessive inherited but limited pathologic variant in neuroblastoma-amplified sequence (NBAS) (c.4049T > C). The abovementioned variants in the patient were verified using Sanger sequencing (Fig. 4). Autosomal-recessive inherited variants were also detected in the following genes: colony stimulating factor 2 receptor  $\beta$  (CSF2RB) (c.2222C > T), Hermansky-Pudlak syndrome 6 (HPS6) (c.277G > T), interleukin-2 receptor  $\beta$  (IL2RB) (c.1109C > T), IL12 receptor  $\beta$ 1 (IL12RB1) (c.1384G > T), IL-17 receptor C (IL17RC) (c.260\_271del GCAAGAGC TGGG), DNA Ligase I (LIG1) (c.746G > A), recombination activating gene 1 (RAG1) (c.650C > A), and SLX4 (c.1258G > C, c.5072A > G).

## 2.3. Quantification of cytokines/chemokines

Two milliliters of blood was taken from each volunteer at 7:00 a.m. before breakfast, and the serum was stored at  $-80^{\circ}\text{C}$  until measurements. Forty-eight human cytokines/chemokines were quantified using a Bio-Plex Pro Human Cytokine Screening Panel (Bio-Plex Suspension Array System; Bio-Rad Laboratories Inc., Hercules, CA, USA) according to the manufacturer's instructions (data will be reported separately). Compared to the values of the 39 healthy control volunteers, the levels of granulocyte colony-stimulating factor (G-CSF), macrophage inflammatory protein 1 $\alpha$ , and IL7 in the serum of the patient were significantly elevated (exceeding the mean  $\pm$  2 SD). The level of IL2R $\alpha$  was below the range of the standard curve (SI-Table 1).

## 3. Discussion

According to a previous report (Frejo et al., 2017), the patient had unilateral MD type 1. It was reported that patients with Cogan's syndrome present audiovestibular symptoms similar to those of patients with Meniere's syndrome (Greco et al., 2013). However, the present patient did not have the ocular symptoms or systemic disease with a pathological mechanism of vasculitis that is associated with Cogan's syndrome. Although a histological study was unavailable, we demonstrated severe local vascular congestion, indicating vasculitis, over the ES in this patient with unilateral sporadic MD. Genetic analysis of the patient demonstrated variants in MEFV, IRF8, ADA, PEPD, and NBAS, among others.

Mutations in MEFV, the gene encoding pyrin (NLRP3), have been defined as variants mostly associated with monogenic systemic autoinflammatory diseases (Szekanecz et al., 2021). The c.442G > C and c.329T > C mutations in MEFV appeared in a Han Chinese patient with adult-onset Still's disease, which has been advocated as being in the spectrum of autoinflammatory diseases (Ou-Yang et al., 2018). IRF8 is expressed in myeloid cells (macrophages, monocytes, dendritic cells) and forms part of a group of core genes in which genetic variants constitute risk factors for a large spectrum of chronic inflammatory diseases in humans (Salem et al., 2020). However, the influence of the c.1157G > T mutation on the protein function of IRF8 is unknown.

Adenosine deaminase (ADA) is a ubiquitous enzyme important for the degradation and salvage of purine metabolites, and the

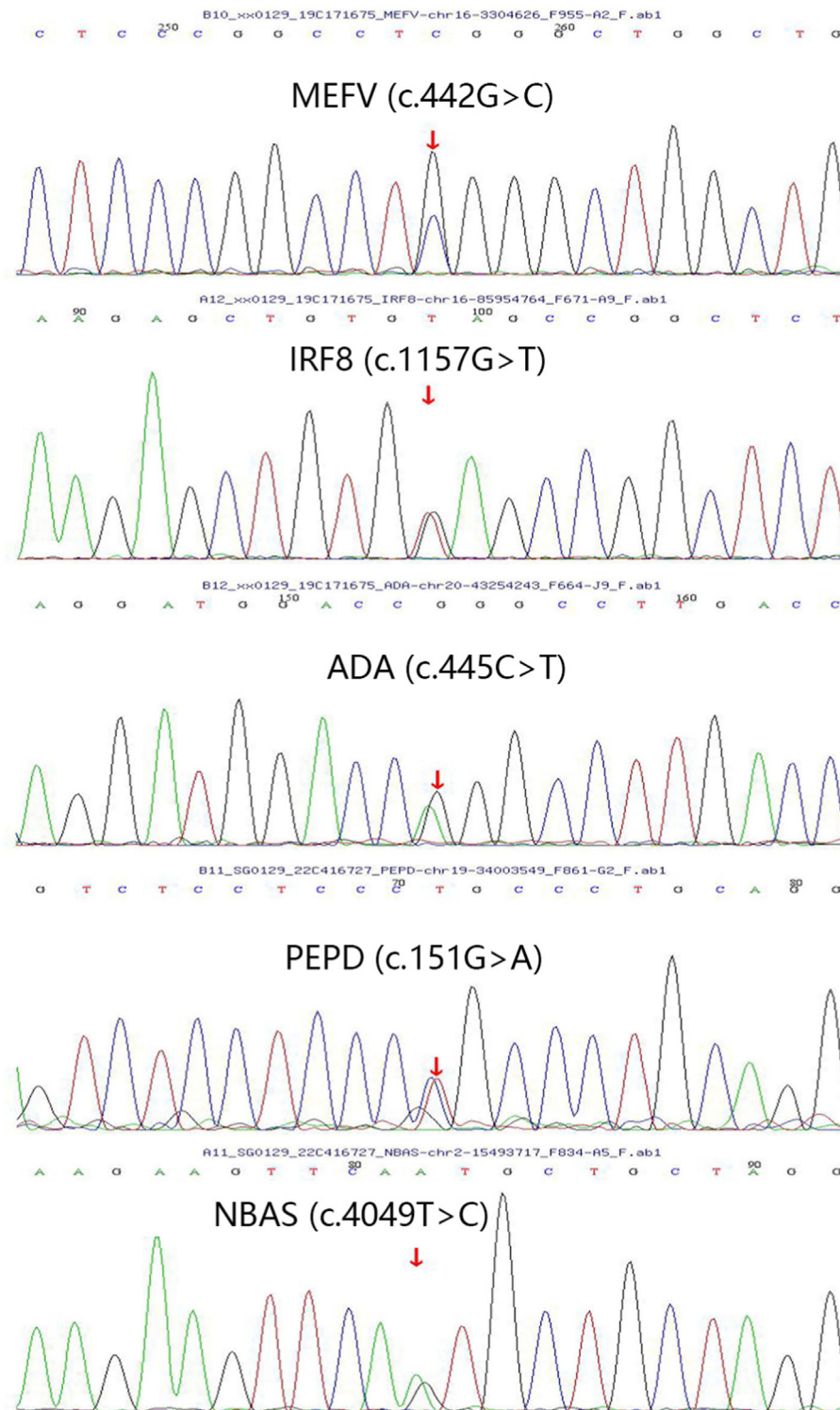


Fig. 4. Sanger sequencing of gene variants.

inherited absence of ADA leads to the accumulation of these metabolites that are toxic to rapidly proliferating cells such as lymphocytes, resulting in severe combined immunodeficiency (SCID). In addition to increased susceptibility to infections, ADA deficiency has also been reported to be associated with sensorineural loss (Albuquerque et al., 2004; Tanaka et al., 1996; Xu et al., 2019). The impact of the c.445C > T mutation on the protein function of ADA is

harmful. PEPD encodes proliadase, which catalyzes the hydrolysis of a dipeptide containing a C-terminal proline or hydroxyproline into constituent amino acids, and the most studied substrates of the enzyme are imidodipeptides, which are generated during the breakdown of collagen. It was reported that oxidative stress stimulates collagen breakdown via inductions of matrix metalloproteinases and induces inflammatory homeostasis (Eni-Aganga

et al., 2021). The c.151G > A mutation is harmful for the function of prolidase. It is possible that a disturbance of the function of prolidase promotes the inflammation induced by oxidative stress due to decreased clearance of collagen catabolites.

NBAS functions as a component of an endoplasmic reticulum (ER) tethering complex involved in retrograde Golgi-ER transport and the formation of large transport vesicles for bulky cargo (e.g., collagen) at the ER exit site in the secretory pathway. There are three clinical subgroups associated with the affected region of the NBAS protein: the combined phenotype (associated with the  $\beta$ -propeller); infantile liver failure syndrome type 2 (ILFS2; associated with Sec39); and short stature, optic atrophy, and Pelger-Huët anomaly (SOPH; associated with the C-terminal) (Staufner et al., 2020). Although there is limited impact on the function of NBAS caused by the c.4049T > C mutation, it is possible that a disruption in Golgi-ER transport and the formation of large transport vesicles at the ER exit site induced ER stress and inflammation in the current patient.

The impacts of subsequent autosomal-recessive inherited variants on protein function are unknown. CSF2RB encodes the  $\beta$ -chain of granulocyte-macrophage colony-stimulating factor receptor (GM-CSFR), which forms a high-affinity receptor in the presence of the  $\alpha$ -chain upon interacting with GM-CSF, and the activation promotes the survival, proliferation, maturation, and functional activation of a spectrum of hemopoietic lineages, including committed myeloid progenitors, neutrophils, monocytes, and eosinophils (Lock et al., 1994). The HPS6 gene is named Hermansky-Pudlak syndrome 6 and encodes the HPS6 protein, which is a subunit of the BLOC-2 protein complex that directly interacts with the dynactin p150Glued subunit of the dynein–dynactin motor complex and acts as a cargo adaptor for the retrograde motor to mediate the transport of lysosomes from the cell periphery to the perinuclear region (Li et al., 2014). Variants in the HPS6 gene were also reported in Chinese patients with Hermansky-Pudlak syndrome (Wang et al., 2021). IL2RB encodes the  $\beta$  subunit of the IL-2 receptor, which forms a complex with the  $\gamma$  subunits upon IL-2 and IL-15 stimulation and plays a central role in the control of the immune system. Patients with homozygous mutations in the IL2RB gene were shown to present with autoantibodies, hypergammaglobulinemia, and bowel inflammation, among other symptoms and signs (Zhang et al., 2019). Human IL12RB1 encodes IL12RB $\beta$ 1, which is an essential component of the IL12- and IL23-signaling complexes and promotes delayed type hypersensitivity and autoimmunity, as well as the immunological reaction that limits, for example, tuberculosis that might be accompanied by leukocytoclastic vasculitis (Robinson, 2015). IL17RC encodes the IL-17 receptor C (IL-17R C) subunit that forms the IL-17R complex together with the IL-17RA subunit and mediates inflammatory activities after binding to IL-17. The IL-17 signaling axis has been implicated in the development of rheumatoid arthritis and the impairment of IL-17 signaling in the disease progression of psoriasis (Ho et al., 2010). LIG1 encodes DNA ligase 1, which is the primary replicative ligase and interacts with proliferating cell nuclear antigen (PCNA) via an N-terminal PCNA-interacting protein box, and mutations in this gene have been implicated in several immunological diseases (Jurkiw et al., 2021). RAG1 encodes the RAG1 protein, which modulates V(D)J recombination, which assembles and diversifies immunoglobulin and T-cell receptor genes in developing B and T lymphocytes (Brecht et al., 2020). SLX4 encodes the protein SLX4, which is involved in DNA repair and the maintenance of genome stability (Young et al., 2021).

Regarding the immunological phenotype, the levels of G-CSF, MIP1 $\alpha$ , and IL7 were significantly elevated, while the level of IL2R $\alpha$  was decreased in the serum. Elevated levels of G-CSF and MIP1 $\alpha$  are associated with active inflammatory cellular infiltration. G-CSF

stimulates neutrophil production and release from the bone marrow and promotes injury at sites of inflammation. It was reported that G-CSF is also involved in endotoxemia-enhanced blood-labyrinth barrier trafficking by cooperating with TLR4 (Urdang et al., 2020). MIP1 $\alpha$  is a C–C chemokine that recruits B cells, cytotoxic T cells, and CD4<sup>+</sup> T cells to the inflammatory site (Schall et al., 1993). IL-7 is mainly produced by epithelial and stromal cells and regulates T-cell homeostasis, proliferation, and survival. Beneficial therapeutic results were reported in T-cell-mediated chronic inflammatory diseases by targeting the expansion of pathogenic memory immune cells with anti-IL-7R $\alpha$  mAbs (Belarif et al., 2018). The IL-2/IL-2R $\alpha$  signaling pathway is essential for the regulation of both the size and the content of the peripheral lymphoid compartment, probably by influencing the balance between clonal expansion and cell death following lymphocyte activation. IL-2R $\alpha$ -deficient mice develop autoimmune disorders, such as hemolytic anemia and inflammatory bowel disease (Willerford et al., 1995). Elevated soluble IL-2R $\alpha$  concentrations in adults indicate the activation of lymphocytes during infection and inflammation and with autoimmune disease (Downes et al., 2014). However, we cannot conclude the clinical relevance of the reduced soluble IL-2R $\alpha$  level in the current patient. Although autoantibody spectrum test results were negative, we cannot rule out the existence of autoantibodies against antigens of the inner ear or endolymphatic sac.

C3 and C4 are important opsonins that bind to and facilitate the clearance of immune complexes and apoptotic debris, which would otherwise promote inflammation and autoimmune diseases. Angiogenesis was found to be increased in C3<sup>−/−</sup> mice, as demonstrated by an increased capillary/muscle fiber ratio and increased proliferating endothelial cells (Gotz et al., 2021). Complete C4 deficiency was reported in SLE patients who finally developed fatal central nervous system vasculitis (Rupert et al., 2002).

The current unilateral sporadic MD patient demonstrated genetic variants and varied serum cytokine levels as well as vascular congestion over the ES, indicating vasculitis. Although malfunction of the abovementioned genes is involved in autoinflammation and autoimmunity, the clinical relevance of the detected coexistent genotypes in MD phenotypes needs further investigation.

## Declaration of competing interest

The authors declare no potential conflicts of interest with respect to the research, authorship, and/or publication of this article.

## Appendix A. Supplementary data

Supplementary data to this article can be found online at <https://doi.org/10.1016/j.joto.2022.03.001>.

## References

- Albuquerque, W., Gaspar, H.B., 2004. Bilateral sensorineural deafness in adenosine deaminase-deficient severe combined immunodeficiency. *J. Pediatr.* 144, 278–280.
- Belarif, L., Mary, C., Jacquemont, L., Mai, H.L., Danger, R., Hervouet, J., Minault, D., Thepenier, V., Nerrière-Daguin, V., Nguyen, E., Pengam, S., Largy, E., Delobel, A., Martinet, B., Le Bas-Bernardet, S., Brouard, S., Soullillou, J.P., Degauque, N., Blanco, G., Vanhove, B., Poirier, N., 2018. IL-7 receptor blockade blunts antigen-specific memory T cell responses and chronic inflammation in primates. *Nat. Commun.* 9, 4483.
- Boleas-Aguirre, M.S., Lin, F.R., Della Santina, C.C., Minor, L.B., Carey, J.P., 2008. Longitudinal results with intratympanic dexamethasone in the treatment of Meniere's disease. *Otol. Neurotol.* 29, 33–38.
- Brecht, R.M., Liu, C.C., Beilinson, H.A., Khitun, A., Slavoff, S.A., Schatz, D.G., 2020. Nucleolar localization of RAG1 modulates V(D)J recombination activity. *Proc. Natl. Acad. Sci. U. S. A.* 117, 4300–4309.
- Downes, K., Marcovecchio, M.L., Clarke, P., Cooper, J.D., Ferreira, R.C., Howson, J.M., Jolley, J., Nutland, S., Stevens, H.E., Walker, N.M., Wallace, C., Dunger, D.B.,

- Todd, J.A., 2014. Plasma concentrations of soluble IL-2 receptor alpha (CD25) are increased in type 1 diabetes and associated with reduced C-peptide levels in young patients. *Diabetologia* 57, 366–372.
- Eni-Aganga, I., Lanaghan, Z.M., Balasubramaniam, M., Dash, C., Pandhare, J., 2021. PROLIDASE: a review from discovery to its role in health and disease. *Front Mol Biosci* 8, 723003.
- Frejo, L., Soto-Varela, A., Santos-Perez, S., Aran, I., Batuecas-Caletrio, A., Perez-Guillen, V., Perez-Garrigues, H., Fraile, J., Martin-Sanz, E., Tapia, M.C., Trinidad, G., Garcia-Arumi, A.M., Gonzalez-Aguado, R., Espinosa-Sanchez, J.M., Marques, P., Perez, P., Benitez, J., Lopez-Escamez, J.A., 2016. Clinical subgroups in bilateral Meniere disease. *Front. Neurol.* 7, 182.
- Frejo, L., Martin-Sanz, E., Teggi, R., Trinidad, G., Soto-Varela, A., Santos-Perez, S., Manrique, R., Perez, N., Aran, I., Almeida-Branco, M.S., Batuecas-Caletrio, A., Fraile, J., Espinosa-Sanchez, J.M., Perez-Guillen, V., Perez-Garrigues, H., Oliva-Dominguez, M., Aleman, O., Benitez, J., Perez, P., Lopez-Escamez, J.A., Meniere's disease, C., 2017. Extended phenotype and clinical subgroups in unilateral Meniere disease: a cross-sectional study with cluster analysis. *Clin. Otolaryngol.* 42, 1172–1180.
- Gotz, P., Braumandl, A., Kubler, M., Kumaraswami, K., Ishikawa-Ankerhold, H., Lasch, M., Deindl, E., 2021. C3 deficiency leads to increased angiogenesis and elevated pro-angiogenic Leukocyte recruitment in ischemic muscle tissue. *Int. J. Mol. Sci.* 22.
- Greco, A., Gallo, A., Fusconi, M., Magliulo, G., Turchetta, R., Marinelli, C., Macri, G.F., De Virgilio, A., de Vincentiis, M., 2013. Cogan's syndrome: an autoimmune inner ear disease. *Autoimmun. Rev.* 12, 396–400.
- Ho, A.W., Gaffen, S.L., 2010. IL-17RC: a partner in IL-17 signaling and beyond. *Semin. Immunopathol.* 32, 33–42.
- Jurkiw, T.J., Tumbale, P.P., Schellenberg, M.J., Cunningham-Rundles, C., Williams, R.S., O'Brien, P.J., 2021. LIG1 syndrome mutations remodel a cooperative network of ligand binding interactions to compromise ligation efficiency. *Nucleic Acids Res* 49, 1619–1630.
- Kampfe Nordstrom, C., Danckwardt-Lilliestrom, N., Laurell, G., Liu, W., Rask-Andersen, H., 2018. The human endolymphatic sac and inner ear immunity: macrophage interaction and molecular expression. *Front. Immunol.* 9, 3181.
- Li, K., Yang, L., Zhang, C., Niu, Y., Li, W., Liu, J.J., 2014. HPS6 interacts with dynactin p150Glued to mediate retrograde trafficking and maturation of lysosomes. *J. Cell Sci.* 127, 4574–4588.
- Lock, P., Metcalf, D., Nicola, N.A., 1994. Histidine-367 of the human common beta chain of the receptor is critical for high-affinity binding of human granulocyte-macrophage colony-stimulating factor. *Proc. Natl. Acad. Sci. U. S. A.* 91, 252–256.
- Moller, M.N., Kirkeby, S., Vikesa, J., Nielsen, F.C., Caye-Thomasen, P., 2015. Gene expression demonstrates an immunological capacity of the human endolymphatic sac. *Laryngoscope* 125, E269–E275.
- Ou-Yang, L.J., Tang, K.T., 2018. A case of adult onset Still's disease with mutations of the MEFV gene who is partially responsive to colchicine. *Medicine (Baltim.)* 97, e0333.
- Robinson, R.T., 2015. IL12Rbeta1: the cytokine receptor that we used to know. *Cytokine* 71, 348–359.
- Rupert, K.L., Moulds, J.M., Yang, Y., Arnett, F.C., Warren, R.W., Reveille, J.D., Myones, B.L., Blanchong, C.A., Yu, C.Y., 2002. The molecular basis of complete complement C4A and C4B deficiencies in a systemic lupus erythematosus patient with homozygous C4A and C4B mutant genes. *J. Immunol.* 169, 1570–1578.
- Salem, S., Salem, D., Gros, P., 2020. Role of IRF8 in immune cells functions, protection against infections, and susceptibility to inflammatory diseases. *Hum. Genet.* 139, 707–721.
- Schall, T.J., Bacon, K., Camp, R.D., Kaspari, J.W., Goeddel, D.V., 1993. Human macrophage inflammatory protein alpha (MIP-1 alpha) and MIP-1 beta chemokines attract distinct populations of lymphocytes. *J. Exp. Med.* 177, 1821–1826.
- Staufner, C., Peters, B., Wagner, M., Alameer, S., Baric, I., Broue, P., Bulut, D., Church, J.A., Crusell, E., Dalgic, B., Das, A.M., Dick, A., Dikow, N., Dionisi-Vici, C., Distelmaier, F., Bozbulut, N.E., Feillet, F., Gonzales, E., Hadzic, N., Hauck, F., Hegarty, R., Hempel, M., Herget, T., Klein, C., Konstantopoulou, V., Kopajtic, R., Kuster, A., Laass, M.W., Lainka, E., Larson-Nath, C., Leibner, A., Lurz, E., Mayr, J.A., McKiernan, P., Mention, K., Moog, U., Mungan, N.O., Riedhammer, K.M., Santer, R., Palafoll, I.V., Vockley, J., Westphal, D.S., Wiedemann, A., Wortmann, S.B., Diwan, G.D., Russell, R.B., Prokisch, H., Garbade, S.F., Kolker, S., Hoffmann, G.F., Lenz, D., 2020. Defining clinical subgroups and genotype-phenotype correlations in NBAS-associated disease across 110 patients. *Genet. Med.* 22, 610–621.
- Szekanecz, Z., McInnes, I.B., Schett, G., Szamosi, S., Benko, S., Szucs, G., 2021. Autoinflammation and autoimmunity across rheumatic and musculoskeletal diseases. *Nat. Rev. Rheumatol.* 17, 585–595.
- Tanaka, C., Hara, T., Suzuki, I., Maegaki, Y., Takeshita, K., 1996. Sensorineural deafness in siblings with adenosine deaminase deficiency. *Brain Dev* 18, 304–306.
- Urdang, Z.D., Bills, J.L., Cahana, D.Y., Muldoon, L.L., Neuwelt, E.A., 2020. Toll-like receptor 4 signaling and downstream neutrophilic inflammation mediate endotoxemia-enhanced blood-labyrinth barrier trafficking. *Otol. Neurotol.* 41, 123–132.
- Wang, C., Shi, P., Li, Q., Chen, C., Zhao, X., Zhang, R., Kong, X., 2021. Hermansky-Pudlak syndrome: five Chinese patients with novel variants in HPS1 and HPS6. *Eur. J. Med. Genet.* 64, 104228.
- Willerford, D.M., Chen, J., Ferry, J.A., Davidson, L., Ma, A., Alt, F.W., 1995. Interleukin-2 receptor alpha chain regulates the size and content of the peripheral lymphoid compartment. *Immunity* 3, 521–530.
- Xu, X., Negandhi, J., Min, W., Tsui, M., Post, M., Harrison, R.V., Grunebaum, E., 2019. Early enzyme replacement therapy improves hearing and immune defects in adenosine deaminase deficient-mice. *Front. Immunol.* 10, 416.
- Yazawa, Y., Kitahara, M., 1989. Immunofluorescent study of the endolymphatic sac in Meniere's disease. *Acta Otolaryngol Suppl* 468, 71–76.
- Young, S.J., West, S.C., 2021. Coordinated roles of SLX4 and MutSbeta in DNA repair and the maintenance of genome stability. *Crit. Rev. Biochem. Mol. Biol.* 56, 157–177.
- Zhang, Z., Gothe, F., Pennamen, P., James, J.R., McDonald, D., Mata, C.P., Modis, Y., Alazami, A.M., Acres, M., Haller, W., Bowen, C., Doffinger, R., Sinclair, J., Brothers, S., Zhang, Y., Matthews, H.F., Naudion, S., Pelluard, F., Alajlan, H., Yamazaki, Y., Notarangelo, L.D., Thaventhiran, J.E., Engelhardt, K.R., Al-Mousa, H., Hambleton, S., Rooryck, C., Smith, K.G.C., Lenardo, M.J., 2019. Human interleukin-2 receptor beta mutations associated with defects in immunity and peripheral tolerance. *J. Exp. Med.* 216, 1311–1327.
- Zou, J., 2019. Autoinflammatory characteristics and short-term effects of delivering high-dose steroids to the surface of the intact endolymphatic sac and incus in refractory Meniere's disease. *J. Otolaryngol.* 14, 40–50.
- Zou, J., Duan, X., Zheng, G., Zhao, Z., Chen, S., Dai, P., Zheng, H., 2016. A novel PIK3CD C896T mutation detected in bilateral sudden sensorineural hearing loss using next generation sequencing: an indication of primary immunodeficiency. *J. Otolaryngol.* 11, 78–83.
- Zou, J., Zhao, Z., Li, H., Zhang, G., Zhang, Q., Lu, J., Pyykkö, I., 2022. Dexamethasone does not affect endolymphatic hydrops (EH) in patients with Meniere's Disease within 24 h and intratympanic administration of gadolinium plus dexamethasone simplifies high-quality imaging of EH using a novel protocol of 7 minutes. *J. Otol.* <https://doi.org/10.1016/j.joto.2022.02.002>.