

RHINOLOGY

Radiological score of computed tomography scans predicts revision surgery for chronic rhinosinusitis

Score radiologico della Tac in grado di predire la revisione chirurgica nei pazienti affetti da rinosinusite cronica

Markus Lilja^{1,2}, Anni Koskinen^{1,2}, Anna Julkunen-Iivari³, Antti Mäkitie², Jura Numminen⁴, Markus Rautiainen^{4,5}, Jyri P. Myller⁶, Antti Markkola⁷, Mikko Suvinen⁸, Mika Mäkelä¹, Risto Renkonen^{3,9}, Juha Pekkanen¹⁰, Sanna K. Toppila-Salmi^{1,3}

¹ Skin and Allergy Hospital, University of Helsinki and Helsinki University Hospital, Helsinki, Finland; ² Department of Otorhinolaryngology - Head and Neck Surgery, Helsinki University Hospital and University of Helsinki, Helsinki, Finland; ³ Haartman Institute, University of Helsinki, Helsinki, Finland; ⁴ Department of Otorhinolaryngology, Tampere University Hospital, Tampere, Finland; ⁵ Department of Otorhinolaryngology, University of Tampere, Tampere, Finland; ⁶ Department of Otorhinolaryngology, Päijät-Häme Central Hospital, Lahti, Finland; ⁷ University of Helsinki and HUS Imaging, Helsinki, Finland; ⁸ Department of Otorhinolaryngology, Tampere City Hospital, Tampere, Finland; ⁹ HUS Diagnostic Center, Helsinki, Finland; ¹⁰ Department of Public Health, University of Helsinki, Finland

SUMMARY

Objective. Evaluate computed tomography (CT) signs that predict need for revision endoscopic sinus surgery (ESS) of chronic rhinosinusitis (CRS).

Methods. CRS patients (n = 48) underwent routine sinus CT scans and baseline ESS in 2006-2011. Lund-Mackay (LM) scores and 43 other CT signs were analysed blinded from both sides. Patients filled in a questionnaire during the day of CT scanning. Follow-up data were collected from hospital records until January 2018. Associations were analysed by Fisher's exact, Mann Whitney U, Kaplan-Meier method with logrank test and Cox's proportional hazard model.

Results. Total LM score was not significantly associated with the need for revision ESS. The best predictive model was a sum of CT signs of non-detectable anatomy of inferior/middle turbinates, obstructed frontal recess, and previous sinus surgery. Using these CT findings, we formed a Radiological Score (RS) (min-max, 0-3 points). Having at least one RS point was significantly associated with the need for revision ESS during the average follow-up of 10.7 years (p = 0.008, Logrank test).

Conclusion. We identified a radiologic score that was able to predict the need for revision ESS, which is probably useful in predicting CRS outcomes.

KEY WORDS: rhinosinusitis, CRSwNP, CRSsNP, computed tomography, prediction

RIASSUNTO

Obiettivo. Valutare i segni della tomografia computerizzata (TC) predittivi della necessità di un intervento di revisione endoscopica dei seni paranasali (ESS) nella rinosinusite cronica (CRS).

Metodi. I pazienti con CRS (n = 48) sono stati sottoposti a TC dei seni paranasali e ESS dal 2006 al 2011. I punteggi di Lund-Mackay (LM) e altri 43 segni TC sono stati analizzati in cieco. I pazienti hanno compilato un questionario di valutazione al momento dell'esecuzione della TC. Sono stati revisionati i dati di follow-up dei registri ospedalieri fino a Gennaio 2018. Le analisi sono state effettuate mediante test di Fisher, Mann Whitney U, Kaplan-Meier con il test di logrank e il modello di rischio proporzionale di Cox.

Risultati. Il punteggio LM totale non era significativamente associato alla necessità di revisione mediante ESS. Il miglior modello predittivo è risultato la somma dei seguenti reperti TC: turbinati inferiori/medi non rilevabili, recesso frontale ostruito ed esiti di precedenti interventi chirurgici nasosinusal. Utilizzando questi risultati TC, abbiamo creato un punteggio radiologico (RS) (min-max, 0-3 punti). Un punteggio RS minimo di uno, è significativamente associato alla necessità di revisione ESS durante il follow-up medio di 10,7 anni (p = 0,008, test di Logrank).

Received: March 15, 2021
Accepted: September 14, 2021

Correspondence

Markus Lilja
Surgical Hospital
Kasarmikatu 11-13, 00029 HUS, Finland
Tel. +35894711
E-mail: markus.lilja@hus.fi

How to cite this article: Lilja M, Koskinen A, Julkunen-Iivari A, et al. Radiological score of computed tomography scans predicts revision surgery of chronic rhinosinusitis. Acta Otorhinolaryngol Ital 2022;42:63-74. <https://doi.org/10.14639/0392-100X-N1561>

© Società Italiana di Otorinolaringoiatria e Chirurgia Cervico-Facciale



OPEN ACCESS

This is an open access article distributed in accordance with the CC-BY-NC-ND (Creative Commons Attribution-NonCommercial-NoDerivatives 4.0 International) license. The article can be used by giving appropriate credit and mentioning the license, but only for non-commercial purposes and only in the original version. For further information: <https://creativecommons.org/licenses/by-nc-nd/4.0/deed.en>

Conclusioni. Abbiamo identificato un punteggio radiologico in grado di prevedere la necessità di revisione ESS e quindi probabilmente utile nel predire gli esiti della CRS.

PAROLE CHIAVE: rinosinusite, CRSwNP, CRSsNP, tomografia computerizzata, previsione

Introduction

Chronic rhinosinusitis (CRS) is a heterogeneous group of inflammatory diseases of the nose and paranasal sinuses lasting for at least 12 weeks¹. CRS is one of the most common chronic adult health problems in the Western world. A European multicentre postal questionnaire study estimated the prevalence of CRS at 11%². In a recent population-based survey of adults in the United States, the prevalence of CRS was 11.5%³. CRS has a severe impact on quality of life, which is comparable with other chronic diseases, such as asthma, chronic obstructive pulmonary disease and diabetes¹. The economic burden caused by CRS is significant and relates largely to loss of productivity, increased frequency of physician appointments and medical expenses¹. CRS with nasal polyps (CRSwNP) and without (CRSsNP) are considered to be phenotypes of CRS with possibly different aetiologies and pathomechanisms. In addition, there are inflammatory endotypes of CRS, which do not lead to just one main phenotype⁴.

Endoscopic sinus surgery (ESS) has been the most common type of surgery for CRS in patients with failed appropriate medical treatments¹. The variation in the use of operative management in CRS might reflect a number of factors including both under-utilisation and over-utilisation of surgery, a lack of guidelines and a lack of evidence in well-constructed randomised controlled trials. The need for revision surgery is rather common after ESS. A large prospective cohort study has shown that approximately 20% of patients responded unsatisfactorily to surgery for CRS and required revision during five-year follow-up⁵. Moreover, the study showed that revision rate was 20.6% among the patients with CRSwNP compared with 15.5% for patients with CRSsNP. A 10-year follow-up study has shown a 17% revision surgery rate in CRS altogether, and a 25% revision rate in CRSwNP⁶. Another long-term follow-up study has reported that 36.8% of CRSwNP patients underwent additional revision surgery within a 12-year period after ESS⁷. Computed tomography (CT) scans are used to evaluate the extent of pathology and the need for surgery in CRS. The characteristic findings in CRS are mucosal changes within the ostiomeatal complex and/or sinuses. In addition, the opacification of the normally aerated sinus lumen due to mucosal thickening and/or fluid content can be found. The Lund-Mackay (LM) staging is a widely used CT-staging system. It is based on the grading of opacification of si-

nuses and ostiomeatal complex. In a few studies, its ability to predict the need for revision surgery in CRS and cystic fibrosis has also been evaluated^{8,9}.

The aim of this study was to evaluate the signs in baseline sinonasal CT that might predict the need for revision ESS.

Materials and methods

Patients

This prospective cohort study was carried out at the Department of Otorhinolaryngology, Tampere University Hospital (Tampere, Finland) from 2006 to 2015. We used data of a random sample of CRS patients undergoing routine sinus CT scanning due to CRS or its suspicion during 2006-2011¹⁰. Inclusion criteria were that the patient underwent ESS within one year after sinus CT scans due to CRS and that patient follow-up data (concerning the possible revision ESS) was available. A new CT scan during follow-up was considered only for patients who underwent revision surgery. Exclusion criteria were the use of either acetylsalicylic desensitisation, allergen immunotherapy, or anti-IgE therapy prior to the sinus CT scans or during follow-up. Altogether, 48 patients were included. The decision of the baseline and revision ESS was made by a rhinologist if CRS was uncontrolled after appropriate medical therapy. The appropriate medical therapy was continued after ESS.

Data collection

Baseline data were collected by a questionnaire during the same day the sinus CT was performed¹⁰. The collected variables were gender, age, allergic rhinitis (AR), asthma, previous nasal polyps, non-steroidal anti-inflammatory drug exacerbated respiratory disease (NERD), smoking habits, previous ESS, regular use of intranasal corticosteroids, a history of ≥ 1 oral corticosteroid (OCS) course(s)/past year, number of antibiotic courses/past 2 years and duration of sinonasal symptoms data contained visual analogue scale (VAS) score of four symptoms (nasal obstruction, facial pain/pressure, postnasal drip, sense of smell) (Tab. I). Patient records were reviewed until 2018 or until death if it was earlier. The follow-up data of revision ESS and its timepoint were used. The time interval until revision surgery was calculated from the date of baseline CT scan.

CT scans

All patients underwent routine sinus multiple detector

Table I. Patient background factors. Baseline ESS was performed within one year after the CT scans. The groups are based on revision ESS within 5 years. P-values by Fisher's exact test (dichotomous variables) or Mann Whitney U test (continuous variables). Q1 = 25% percentile, Q3 = 75% percentile.

		No revision ESS in 5 years N = 40	Revision ESS in 5 years N = 8	p-value
Gender, n(%)	Female	27 (67.5)	3 (37.5)	.13
	Male	13 (32.5)	5 (62.5)	
Age (years), median (Q1-Q3)		40.4 (30.2-56.1)	43.8 (35.6-50.3)	.69
AR, n (%)	No	16 (42.1)	5 (71.4)	.23
	Yes	22 (57.9)	2 (28.6)	
Asthma, n (%)	No	27 (71.1)	5 (71.4)	1.0
	Yes	11 (28.9)	2 (28.6)	
CRSwNP, n (%)	No	26 (66.7)	5 (62.5)	1.0
	Yes	13 (33.3)	3 (37.5)	
NERD, n (%)	No	26 (83.9)	5 (71.4)	.59
	Yes	5 (16.1)	2 (28.6)	
Current smoking, n (%)	No	28 (75.7)	6 (71.4)	1.0
	Yes	9 (24.3)	2 (28.6)	
Previous ESS, n (%)	No	30 (76.9)	4 (42.9)	.19
	Yes	9 (23.1)	4 (57.1)	
Regular use of intranasal corticosteroids, n (%)	No	6 (15.8)	3 (42.9)	.13
	Yes	32 (84.2)	4 (57.1)	
A history of ≥ 1 OCS course/past year, n(%)	No	36 (90.0)	5 (62.5)	.080
	Yes	4 (10.0)	3 (37.5)	
Number of antibiotic courses/past 2 years, median (Q1-Q3)		5 (1-7.8)	4 (0-10)	.64
Duration of symptoms (years), median (Q1-Q3)		5.0 (2.8-11.8)	3.5 (1.6-5.0)	.22

AR: allergic rhinitis; CRSwNP: chronic rhinosinusitis with nasal polyps; ESS: endoscopic sinus surgery; NERD: NSAIDs exacerbated respiratory disease; NSAIDs = non-steroidal anti-inflammatory drugs; OCS: oral corticosteroid(s). Data was missing in many variations.

CT examinations for clinical purposes. Two different CT machines were used: GE LightSpeed 16 (GE Healthcare, Milwaukee, Wisconsin) and Philips Brilliance 64 (Philips, Best, Netherlands). Patients were imaged in the supine position with a kilovoltage of 120 kV and a milliampere second of 100 mAs. In the GE machine, the slice thickness was 0.625 mm with coronal reconstructions at 1.5 mm. In the Philips machine, the slice thickness was 0.9 mm with coronal reconstructions at 0.9 mm. Both were three dimensional (3D) in nature without any gap. In all cases, imaging was performed using a bone filter technique. The imaging covered the entire sinonasal area.

Evaluation of CT scans

CT scans were evaluated by an experienced head and neck radiologist (AM), who filled in a form of sinonasal structures and CRS-related changes from both scans and from both sides of each patient (Tab. II)¹⁰. All evaluated structures had 2-5 different choices. The observer also had the

possibility to fill in the choice 'not detectable' in 30/49 structures. 'Not detectable' was not an option in the items concerning LM scoring and sinus size (hypoplasia/normal/hyperplasia), Keros classification, grade of surgeon's confidence based on images, and mucosa of nasal cavity (extent of oedema). 'Not detectable' was used, for example, when the observer was unable to determine the structure of the inferior or middle turbinate (atrophy/normal/hypertrophy) due to lack of visualisation (polyps/partly resected turbinate) (Fig. 1).

Data analysis

Statistical analysis was carried out using the IBM SPSS Statistics 23 Statistical Software Package (SPSS Inc., Chicago, IL, USA). The sample size calculation produced 39 subjects, when using the ratio of controls to exposure group of 0.5, an accrual interval of 5 years, follow-up after the accrual interval of 7 years, a median revision-free survival time of controls of 10 years, an a relative risk = 0.3, $\alpha = 0.05$ and $\beta = 0.8$. Receiver operating characteris-

Table II. Fifty variables, including 49 sinonasal structures, evaluated from sinus CT scans. All structures had 2-5 different choices. All potential variables of the Radiological Score (RS) are displayed in blue or red. All variables that ended in the RS are displayed in red.

1	Lund-Mackay frontal sinus	0 normal	1 partial opacification	2 total opacification			Comment
2	Lund-Mackay anterior ethmoidal sinus	0 normal	1 partial opacification	2 total opacification			
3	Lund-Mackay ostiomeatal unit	0 not occluded		2 occluded			
4	Lund-Mackay posterior ethmoidal sinus	0 normal	1 partial opacification	2 total opacification			
5	Lund-Mackay sphenoid sinus	0 normal	1 partial opacification	2 total opacification			
6	Lund-Mackay maxillary sinus	0 normal	1 partial opacification	2 total opacification			
7	Sinus mucosal abnormalities of frontal sinus	0 none	1 thickening	2 polypoid	3 retention cyst	4 fluid retention	≥ 1 sinus sign
8	Sinus mucosal abnormalities of anterior ethmoidal sinus	0 none	1 thickening	2 polypoid	3 retention cyst	4 fluid retention	
9	Sinus mucosal abnormalities of posterior ethmoidal sinus	0 none	1 thickening	2 polypoid	3 retention cyst	4 fluid retention	
10	Sinus mucosal abnormalities of sphenoid sinus	0 none	1 thickening	2 polypoid	3 retention cyst	4 fluid retention	
11	Sinus mucosal abnormalities of maxillary sinus	0 none	1 thickening	2 polypoid	3 retention cyst	4 fluid retention	
12	Hypoplasia/normal/hyperplasia of frontal sinus	0 normal	1 hyperplasia	2 hypoplasia			
13	Hypoplasia/normal/hyperplasia of anterior ethmoidal sinus	0 normal	1 hyperplasia	2 hypoplasia			
14	Hypoplasia/normal/hyperplasia of posterior ethmoidal sinus	0 normal	1 hyperplasia	2 hypoplasia			
15	Hypoplasia/normal/hyperplasia of sphenoid sinus	0 normal	1 hyperplasia	2 hypoplasia			
16	Hypoplasia/normal/hyperplasia of maxillary sinus	0 normal	1 hyperplasia	2 hypoplasia			
17	Need for septoplasty	0 no	1 yes				5
18	Septal deviation obstructing middle meatus	0 no	1 yes				5
19	Septum turbinate	0 no	1 yes				5
20	Septum deviation	0 no	1 yes				5
21	Septum, crest	0 no	1 yes				5
22	Septum, spur	0 no	1 yes				5
23	Previous sinus surgery performed	0 no	1 yes				5 ≥ 1 side
24	Infraorbital cell	0 no	1 yes				5
25	Paradoxical middle turbinate	0 no	1 yes				5
26	Paradoxical superior turbinate	0 no	1 yes				5
27	Atrophy-normal-hypertrophy of inferior turbinate	0 normal	1 hypertrophy	2 atrophy			5 ≥ 1 turbin. sign
28	Atrophy-normal-hypertrophy of middle turbinate	0 normal	1 hypertrophy	2 atrophy			5
29	Pneumatized superior turbinate	0 no	1 yes but not obstructive	2 obstructive			5
30	Concha bullosa media	0 no	1 yes but not obstructive	2 obstructive			5

continues ►

Table II. Fifty variables, including 49 sinonasal structures, evaluated from sinus CT scans. All structures had 2-5 different choices. All potential variables of the Radiological Score (RS) are displayed in blue or red. All variables that ended in the RS are displayed in red (*follows from previous page*).

31	Concha bullosa superior	0 no	1 yes but not obstructive	2 obstructive	5
32	Mucosa of pneumatized middle turbinate	0 no	1 no opacification	2 opacification	5
33	Mucosa of pneumatized superior turbinate	0 no	1 no opacification	2 opacification	5
34	OMC region, prominent ethmoidal bulla	0 no	1 yes		5 ≥ 1 OMC sign
35	OMC region, hiatus	0 open	1 partly occluded	2 occluded	5
36	OMC region, infundibulum	0 open	1 partly occluded	2	5
37	OMC region, maxillary antrum	0 open	1 partly occluded	2	5
38	OMC region, superior attachment of uncinate process	0 cm/ethmoid	1 lamina papyracea	2 skull base	5
39	OMC region, accessory maxillary sinus ostium	0 no	1 yes		5
40	OMC region, pneumatized superior attachment of uncinate process	0 no	1 yes		5
41	Frontal recess	0 normal	1 occluded		5 ≥ 1 side
42	Sphenoethmoidal recess	0 normal	1 occluded		5 ≥ 1 side
43	Anterior ethmoidal artery	0 safe anatomy	1 unsafe anatomy		5
44	Optic nerve	0 safe anatomy	1 unsafe anatomy		5
45	Thickness of orbital lamina of ethmoidal bone	0 normal		2 thin	5
46	Contact to middle turbinate of orbital lamina ethmoidal bone	0 no	1 yes		5
47	Keros classification		1 I = low	2 II = moderate	3 III = deep
48	Grade of surgeon's confidence based on images	0 easy	1 moderate	2 difficult	
49	Mucosa of nasal cavity (extent of edema)	0 no	1 moderate swelling	2 total occlusion	≥ 1 nasal mucosal sign
50	Mucosa of nasal cavity (normal-polypous)	0 normal	1 thickening	2 polypoid	5

5 = can't be determined.

tic (ROC) analysis was used to identify cut-off point(s) at which a variable predicts the outcome revision ESS during the follow-up. The area under the curve (AUC) was used to obtain a probability of models that an individual will have uncontrolled CRSwNP after surgery. The most optimal predictor model (statistically significant AUC ≥ 0.70), was entered into revision-free survival analysis with log-rank test (revision ESS-rate) and comparative analyses (revision ESS within 5 years). Fisher's exact test (2-tailed) was used to compare dichotomous patient characteristics. The Kruskal-Wallis test and Mann Whitney U test was used to study the comparison of the continuous variables and total LM scores of sinus CT scans. Spearman rank correlation test was to study correlations. The time periods between the baseline CT scans and second

surgeries i.e. revision surgeries were analysed by the Kaplan-Meier method and compared with the log-rank test. Revision-free survival was calculated from the date of the baseline CT scans to first follow-up revision sinus surgery and/or nasal polypectomy/death/January 2018, whichever came first. Univariate Cox's proportional hazard models for interval to second surgery were constructed with the following predictor variables: gender, age, CRSwNP, asthma and/or NERD, AR, a history of ≥ 1 OCS course(s)/past year, previous ESS, LM score and RS. The variables with statistically significant association were entered into a Cox multivariable model. Statistical significance was set in all analyses at a p-value level of less than 0.05, and all tests were 2-tailed.

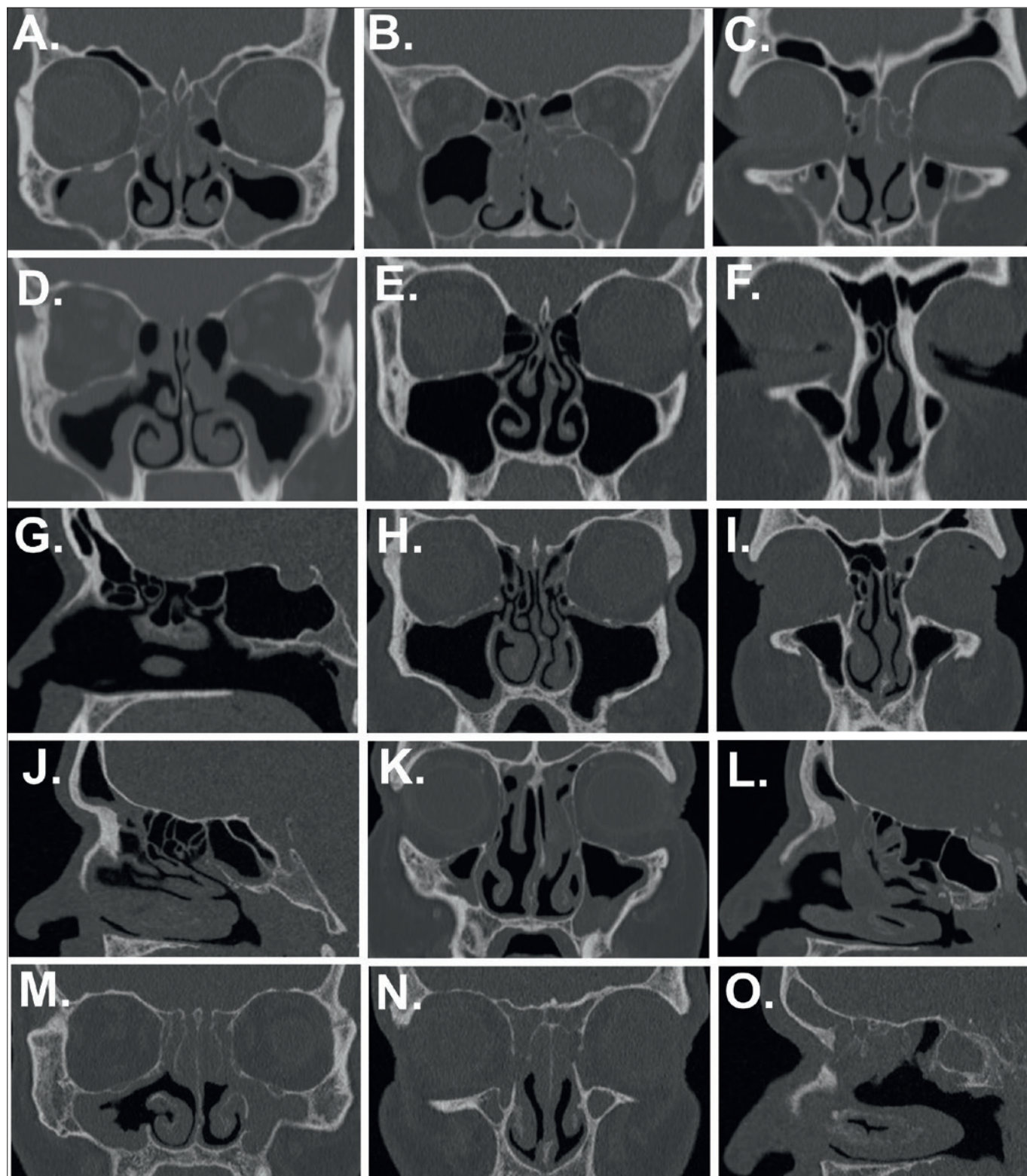


Figure 1. Examples of radiologic signs that were evaluated from sinus computed tomography (CT) scans, which were routinely performed due to clinical purposes. (A) Anatomical fine structures of middle turbinates are not detectable. (B) Middle and inferior turbinates are not detectable. (C) Obstructed frontal recess on both sides. (D) Signs of previous operation (middle meatal antrostomy on both sides) and undetectable left middle turbinate. The reasons for “not detectable” responses were poor visualisation of middle turbinate due to polypoid change or operative modification of turbinate. (E-G) Example of a patient with RS 0 score. (H-J) Example of a patient with RS 1 score. (K-L) Example of a patient with RS 2 score. (M-O) Example of a patient with RS 3 score.

Results

Baseline characteristics

Subject characteristics are presented in the CRS groups with/without revision ESS in five years (Tab. I), with information on age, gender, and the self-reported factors in the two CRS groups. There were no statistically significant differences between the revision and non-revision groups. The baseline total VAS score of symptoms or total LM score of sinus CT scans were not significantly associated with the need for revision ESS (Fig. 2A-B).

Baseline sinus CT findings

Cut-off values of continuous variables and dichotomous variables of the CT scan form were identified and created by using comparison analyses and ROC analysis (data not shown). AUC was used to obtain a probability of model that an individual will have uncontrolled CRSwNP after

surgery, which was measured by revision ESS during follow-up (Fig. 3). The dark blue line indicates the sum model of “signs of surgery + obstructed frontal recess + undetectable anatomy of inferior/middle turbinate (despite what was the reason for it)” (e.g. “Radiological Score (RS)”) was shown to have good predictive potential (AUC > 0.74, $p = 0.019$; Fig. 3) and to contain easily identifiable variables, and thus it was selected for further analyses. In ROC analysis, there were three other significant sum algorithms with good AUC levels (Fig. 3), yet they were more complex in the number and quality of signs needed, and thus they were considered to not be clinically superior to the RS. None of the individual CT scans signs had a good potential to predict the need for revision ESS (Fig. 3, AUC < 0.67). Figure 4 demonstrates formation of RS from CT scan signs of surgery, frontal recess and turbinates. RS was formed as the total sum of 1) non-detectable anatomy of inferior/middle turbinate on at least one side, ≥ 1 finding, 1 point; 2) obstructed frontal recess on at least one side ≥ 1 finding, 1 point; and 3) previous sinus surgery on at least one side, 1 point. Examples of the findings of the RS are shown in Figure 1. The total RS value ranged between 0-3 and values ≥ 1 were significantly associated with revision ESS with a 5-year follow-up (Fig. 4).

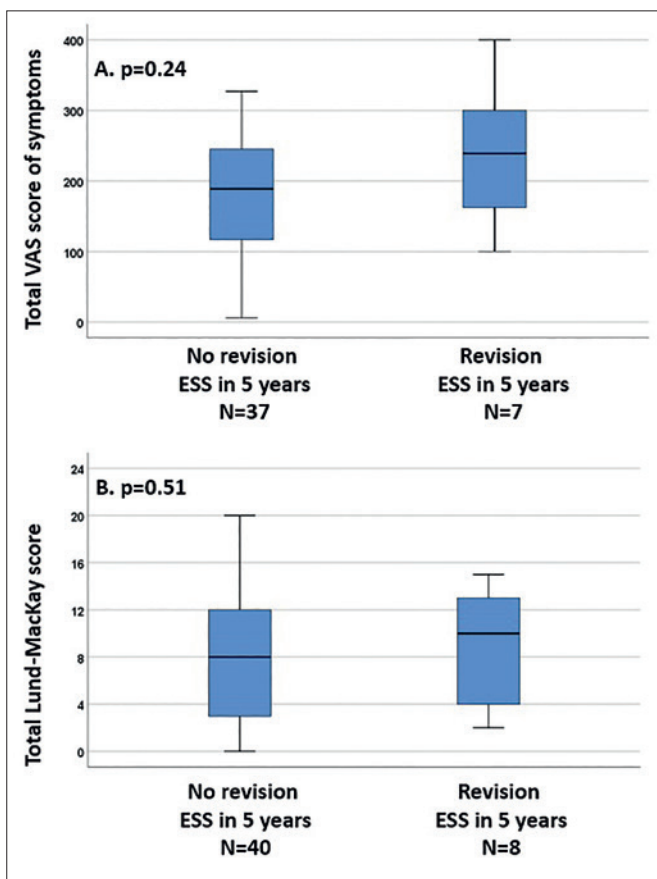


Figure 2. Comparison of (A). Total VAS score of symptoms (nasal obstruction, facial pain/pressure, postnasal drip, sense of smell) (B). Total Lund-Mackay scores of sinus computed tomography (CT) scans in the chronic rhinosinusitis (CRS) patient groups who did or did not undergo revision ESS. All patients underwent baseline ESS performed within one year after the CT scans. P-values by Mann Whitney U test.

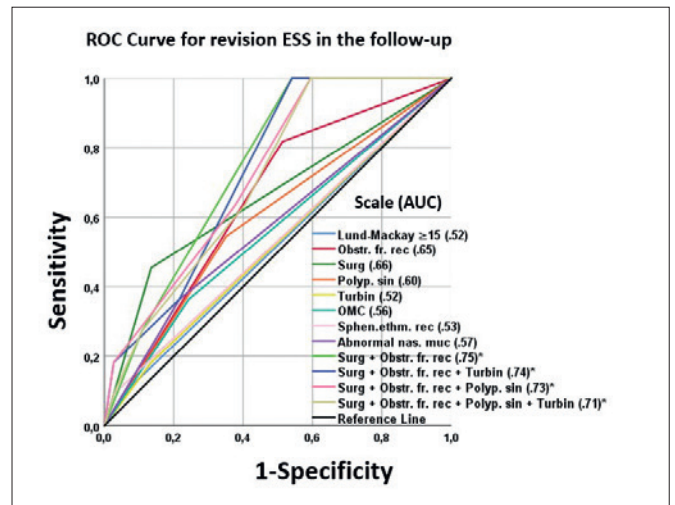


Figure 3. The receiver operating characteristic (ROC) curve plots for predictor models of baseline factors, in order to show how the radiological score was formed from the variables. The figure summarises the overall picture of different variables, and provides the possibility to compare prediction potential of different variables. Area under the ROC curve (AUC) was used to obtain a model of probability that an individual will have uncontrolled chronic rhinosinusitis (CRS) after surgery. Several individual and combined variables were tested. The number of subjects was 38 in each curve. The dark blue line indicates the sum model of “signs of surgery + obstructed frontal recess + undetectable anatomy of inferior/middle turbinate” (e.g. “Radiological Score (RS)”) was showing to have good predictive potential and to contain easily identifiable variables, and thus it was selected for further analyses. * p value < 0.05.

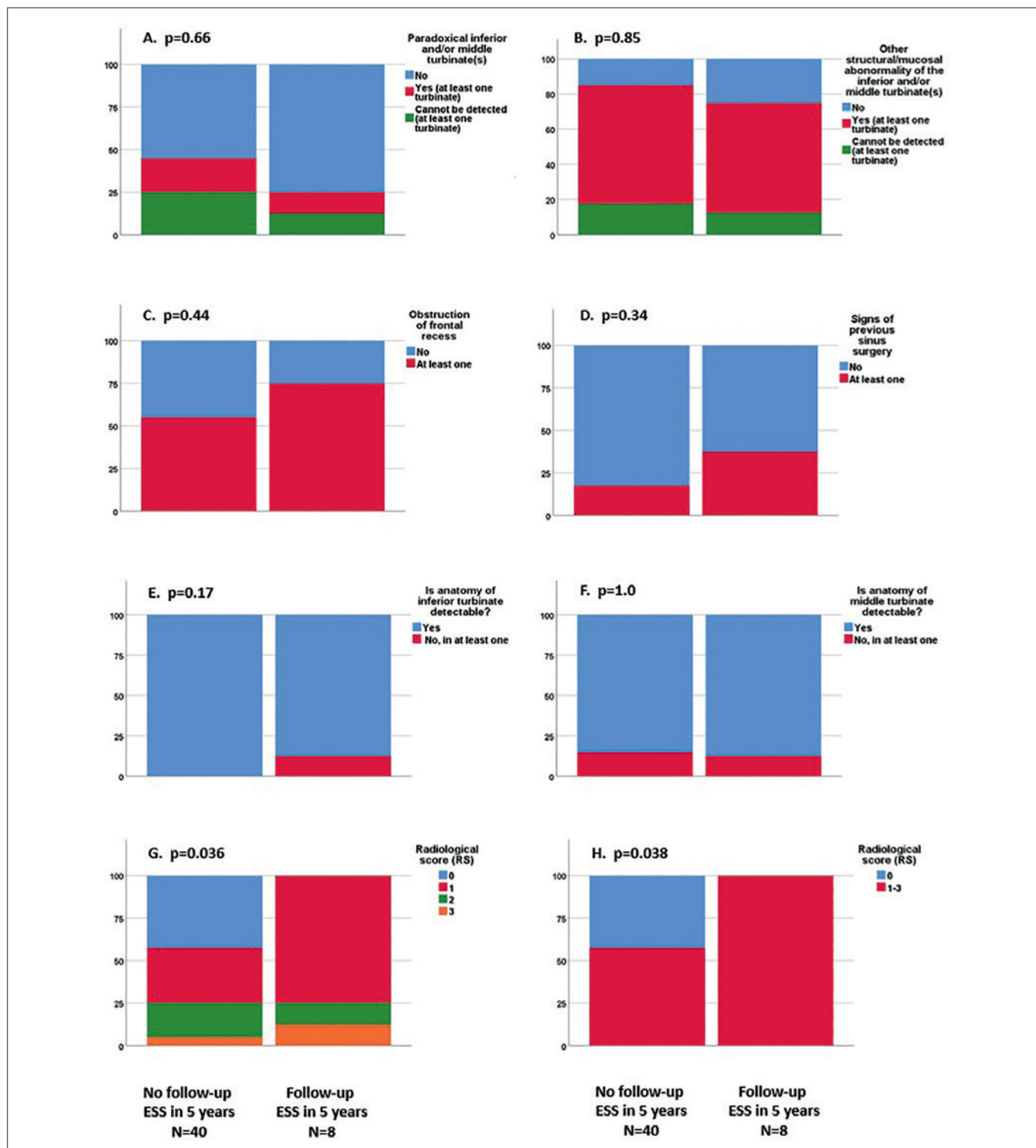


Figure 4. The proportion of different signs (Y-axis) in sinus computed tomography (CT) scans in chronic rhinosinusitis (CRS) patients with or without a revision ESS in 5 years. (A) Paradoxical inferior/middle turbinate on both sides. (B) Pooled score of other structural/mucosal turbinate abnormalities than paradoxical inferior/middle turbinate on both sides. (C) Obstruction of at least one frontal recess. (D) Signs of at least one previous surgery. (E) Pooled score of the questions A and B of inferior turbinates on both sides. Difficulty in detecting the anatomy of inferior turbinate on at least one side (no, yes)? (F) Pooled score of the questions A and B of middle turbinates on both sides. Difficulty in detecting the anatomy of middle turbinate on at least one side (no, yes)? (G) Radiological Score (RS) that was assessed from scores (C-F) as follows; C) = 1 point, D) = 1 point, E-F) at least one “yes” = 1 point. RS is ranging between 0-3 H) Pooled RS 0 point; 1-3 points. P-values by Fisher’s exact test.

The baseline total VAS score of symptoms, or the VAS -scores of the four symptoms (nasal obstruction, facial pain/pressure, postnasal drip, sense of smell), did not correlate with the RS ($p > 0.13$, $r < 0.4$).

Revision-free survival analyses

The mean (min-max) follow-up time until the first event (revision ESS /death /Jan 2018), was 7.6 (0-12) years. The sum model RS was used to predict the time until ESS in follow-up. RS associated significantly with the need for revision ESS (Fig. 5). Cox’s proportional hazards analysis was conducted to determine which factors had predictive value. Of the nine possible factors, RS, a history of OCS course and previous ESS were significantly associated with the need for revision ESS during follow-up (Table III). When entering these three variables in a multivariable model, none proved to be predictive.

Discussion

This study was carried out to evaluate whether CT scan scores using baseline scanning would be useful to predict the need for revision ESS during follow-up. Early prediction of CRS control may be help to organise follow-ups and prevent progression of disease. We found that a sum model

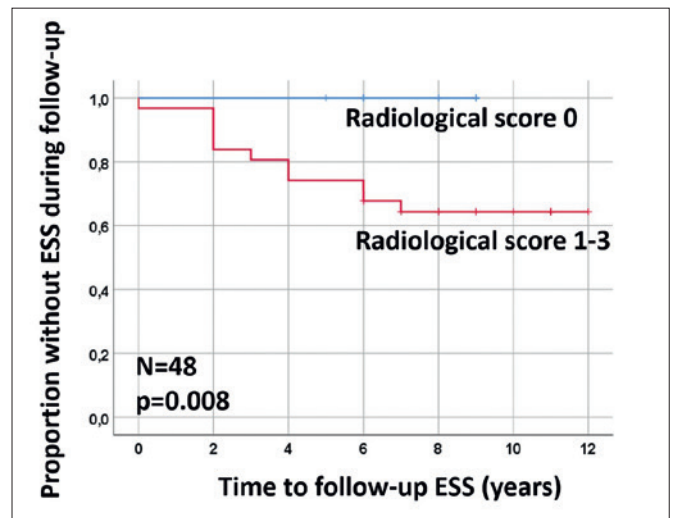


Figure 5. Predictive effect of radiological score (RS) of baseline sinus computed tomography (CT) scans to the time until the revision ESS was performed. All patients underwent baseline ESS within one year after the CT scans. Eight patients underwent revision ESS. The predictive effect was analysed according to the Kaplan-Meier method and p-values by log rank test. ESS = endoscopic sinus surgery.

of “signs of surgery + obstructed frontal recess + undetectable anatomy of inferior/middle turbinate” (shortened as “RS”) had a good predictive potential for uncontrolled CRSwNP, as measured by revision ESS. Therefore, our re-

Table III. Univariate and multivariable Cox’s proportional hazard models for the analyzed background variables supported for the need for revision ESS. Only the CRS subjects who underwent ESS at the baseline (n = 48) were included. Bold values denote statistical significance at the $p < 0.05$ level. The second model is a multivariable model adjusted by the variables that were associated with the need for revision ESS at $p < 0.05$ level in the first model.

		N All	N (%) Events	HR (95% CI)	p	aHR (95% CI)	p
Gender	Female	30	5 (16.7)	2.29 (0.70-7.52)	0.17	Not entered	
	Male	18	6 (33.3)				
Age				1.009 (0.97-1.05)	0.66	Not entered	
CRSwNP	No	31	7 (22.6)	1.06 (0.31-3.63)	0.93	Not entered	
	Yes	16	4 (25.0)				
Asthma and/or NERD	No	30	7 (23.3)	0.82 (0.21-3.18)	0.78	Not entered	
	Yes	15	3 (20.0)				
AR	No	21	6 (28.6)	0.54 (0.15-1.91)	0.34	Not entered	
	Yes	24	4 (16.7)				
≥ 1 OCS courses/year	No	41	7 (17.1)	3.90 (1.14-13.4)	.031	3.14 (0.88-11.2)	.079
	Yes	7	4 (57.1)				
Previous ESS	No	34	5 (14.7)	3.57 (1.09-11.71)	.036	2.21 (0.45-10.9)	.33
	Yes	13	6 (46.2)				
LM score				1.04 (0.92-1.17)	.53	Not entered	
Radiological score				1.93 (1.07-3.50)	.029	1.41 (0.65-3.07)	.39

aHR: adjusted Hazard Ratio; AR: allergic rhinitis; CI: confidence interval; CRS: chronic rhinosinusitis; CRSwNP: chronic rhinosinusitis with nasal polyps; ESS: endoscopic sinus surgery; HR: Hazard Ratio; LM: Lund-Mackay; NERD: NSAIDs exacerbated respiratory disease; NSAIDs: non-steroidal anti-inflammatory drugs; OCS:oral corticosteroid(s). Data was missing in many variations.

sults suggest that sinus CT scans taken before baseline ESS might be used to predict the need for the revision ESS. We found only one previous study evaluating the possibility to use CT scans in the prediction of revision ESS. Hopkins et al. have found a small but significant association between LM score and revision surgery rates at 36 months in their multicentre prospective study of 1840 patients undergoing surgery for CRS in the UK ⁸.

There were three other significant sum algorithms with good AUC level, yet they were more complex in the number and quality of signs needed, and thus they were not considered to be clinically superior to the RS, which was thus the only score that was selected for further analyses of this study. The major reasons for rejecting other interesting signs were challenges in clinical identification of the signs from CT scans and/or too complex algorithm due to several factors in the sum model. Future studies on the predictive potential of CT scan signs by using AI-based deep learning tools are still important.

Of the 49 individual signs of CT scans, the top predictors were obstructed frontal recess (AUC = 0.65), and signs of previous surgery (AUC = 0.66). However, none of the individual signs of CT scans were significantly predictive for revision ESS, probably due to small sample size and/or multiple phenotypes and radiological signs of CRS. This could indicate that individual signs of CT scans have poor potential to predict uncontrolled CRS, which is a multifactorial disease with variable findings.

There is growing consensus that patients with and without polyps have distinct differences. This is reflected in the current iteration of European Position Paper on Rhinosinusitis and Nasal Polyps (EPOS), with different treatment algorithms for these two main phenotypes ¹. It is important to recognise the progressing-disease phenotypes among patients with early-stage CRS and to treat them actively. Diagnosis of CRS phenotypes and estimation of CRS severity are currently based on patient interview, nasal endoscopy and sinus CT scans. Of these, only CT scans can provide an objective scoring option for recurrent CRSwNP phenotypes. Objective scoring might be needed, for instance when evaluating patients with the highest need for advanced therapy (such as biological treatment) in the future. Exposure to radiation is a clear disadvantage that decreases the frequent use of CT in evaluating the severity of CRS. Furthermore, despite technological improvements, it is known that there is still no safe clinically useful radiation dose for these purposes ¹¹. Our findings on the long-term predictive potential of CT signs might thus have some potential for reducing radiation exposure as well. Yet, it remains mandatory to also develop non-radiation-related objective markers for diagnostic and predictive purposes in CRS patients.

Only a few previous studies have been published on recurrent sinus surgery using revision-free survival analysis approach. Wu et al. reviewed records of 299 CRSwNP patients who underwent two or more surgeries during 1987 to 2011 ¹². They found that revision surgery and regrowth of nasal polyps appear to be affected by smoking and operative technique, but not by other factors such as asthma or advanced CT stage. In line with this we found that a high LM score of CT scans were not associated with the need for revision ESS.

Philpott et al. investigated 1249 CRS patients and 221 controls using a self-administered questionnaire in United Kingdom ¹³. A total of 396 (57%) patients with CRSwNPs/allergic fungal rhinosinusitis reported having undergone previous endoscopic nasal polypectomy, and 182 (46%) of them reported having undergone more than one surgery ¹³. Mendelsohn et al. carried out a revision-free survival analysis of a cohort of 549 CRSwNP patients who underwent ESS over a 10-year period ¹⁴. Revision surgery occurred at a high rate, especially in patients with asthma, Samter's triad, or frontal sinus disease. In our study, population of both CRSsNP and CRSwNP patients, we were not able to demonstrate association between self-reported nasal polyposis and need for revision ESS. This might reflect the fact that patients themselves are not aware of their nasal polyps. We did not have the patient data for CRSwNP. An objective indirect parameter of nasal polyps in our study was CT signs of undetectable turbinate structure/mucosa. We found that this parameter alone, however, was not associated with the need for revision ESS.

The study by Chang CC et al. on 4484 patients who underwent ESS for CRS showed that male patients and young adult patients had higher revision rates ¹⁵. In addition, Chang JE et al. found that patients with asthma or AR had higher revision rates compared with patients without these comorbidities ¹⁶. Contrary to the aforementioned studies, our previous study ¹⁷ and the current study did not find that age, gender, self-reported AR, or asthma were associated with the rate of revision ESS, which could be explained by the different populations and study set-ups. We did not detect that polypoid maxillary sinus mucosa affected the rate of revision ESS. Kuiper et al. have shown in a recent study that male CRS patients were 2.7 times more likely to have diffuse sinus opacification than females. Asthma or hay fever also increased the risk for diffuse sinus opacification. Diffuse opacification was associated with nasal blockage and smell loss ¹⁸. However, they did not investigate the predictive potential of CT signs, which could in part explain different CT signs compared to our study.

We acknowledge that symptoms and other factors affect CRS control. Due to lacking data on symptoms during fol-

low-up, we were not able to study relationships between symptoms, radiological score and revision surgery rate. The limitations of this study include small sample size and a validation study with larger sample size is warranted. Revision surgery as an endpoint outcome may have been influenced by several factors unrelated to recurrence of CRS, including wait-times for surgery and patient preferences to delay surgery for personal reasons, operative technique, and surgeons' personal preferences/skills. Although electronic health records of public hospitals have shown to cover 90% of all operations in Finland¹⁹, we acknowledge that some individuals with recurrence might have moved and/or sought treatment elsewhere. Taken together, RS may help in prediction of revision ESS risk together with other parameters such as symptoms. Early prediction of CRS control may be useful to plan surgery, other management and follow-ups, and thus to prevent progression of the disease.

Conclusions

This study provides a preliminary observation that the RS of sinus CT scans assessed before baseline ESS could be useful in predicting the need for revision ESS. More studies with large number of patients are mandatory to validate the present results.

Acknowledgements

The authors thank MSci Heini Huhtala for statistical consultation, research nurse Marja-Leena Oksanen for excellent assistance.

Conflict of interest statement

ST-S has acted as paid consultant for ERT and Roche Products. All these are outside the submitted work. All other authors declare no conflict of interest.

Funding

The study was supported in part by research grant of Aatos Erkko Foundation, Tampere Tuberculosis association, the Finnish Medical Society Duodecim, the Finnish Society of Allergology and Immunology, State funding for university-level health research (TYH2018103, TYH2019322), the Väinö and Laina Kivi Foundation, the Yrjö Jahnsson Foundation.

Authors' contributions

All authors participated on the planning and conception of the study and the analytical strategy; STS, ML and AK performed the data analyses and wrote the manuscript. All authors have assisted in data management, analyses and critical review of the manuscript.

Ethical consideration

The study was approved by the Research Ethics Committee of the Pirkanmaa Hospital District (no. 96032).

The research was conducted ethically, with all study procedures being performed in accordance with the requirements of the World Medical Association's Declaration of Helsinki.

Written informed consent was obtained from each participant.

References

- 1 Fokkens WJ, Lund VJ, Hopkins C, et al. European position paper on rhinosinusitis and nasal polyps 2020. *Rhinology* 2020;58(Suppl S29):1-464. <https://doi.org/10.4193/Rhin20.600>
- 2 Hastan D, Fokkens WJ, Bachert C, et al. Chronic rhinosinusitis in Europe - an underestimated disease. A GA(2) LEN study. *Allergy* 2011;66:1216-1223. <https://doi.org/10.1111/j.1398-9995.2011.02646.x>
- 3 Palmer JN, Messina JC, Biletch R, et al. A cross-sectional, population-based survey of U.S. adults with symptoms of chronic rhinosinusitis. *Allergy Asthma Proc* 2019;40:48-56. <https://doi.org/10.2500/aap.2019.40.4182>
- 4 Tomassen P, Vandeplass G, Van Zele T, et al. Inflammatory endotypes of chronic rhinosinusitis based on cluster analysis of biomarkers. *J Allergy Clin Immunol* 2016;137:1449-1456.e4. <https://doi.org/10.1016/j.jaci.2015.12.1324>
- 5 Hopkins C, Slack R, Lund V, et al. Long-term outcomes from the english national comparative audit of surgery for nasal polyposis and chronic rhinosinusitis. *Laryngoscope* 2009;119:2459-2465. <https://doi.org/10.1002/lary.20653>
- 6 Smith TL, Schlosser RJ, Mace JC, et al. Long-term outcomes of endoscopic sinus surgery in the management of adult chronic rhinosinusitis. *Int Forum Allergy Rhinol* 2019;9:831-841. <https://doi.org/10.1002/alr.22369>
- 7 Calus L, Van Bruaene N, Bosteels C, et al. Twelve-year follow-up study after endoscopic sinus surgery in patients with chronic rhinosinusitis with nasal polyposis. *Clin Transl Allergy* 2019;9:30. <https://doi.org/10.1186/s13601-019-0269-4>
- 8 Hopkins C, Browne JP, Slack R, et al. The lund-mackay staging system for chronic rhinosinusitis: How is it used and what does it predict? *Otolaryngol Head Neck Surg* 2007;137:555-561.
- 9 Carter JM, Johnson BT, Patel A, et al. Lund-mackay staging system in cystic fibrosis: a prognostic factor for revision surgery? *Ochsner J* 2014;14:184-187.
- 10 Julkunen A, Terna E, Numminen J, et al. Inter-observer agreement of paranasal sinus computed tomography scans. *Acta Otolaryngol* 2017;137:611-617. <https://doi.org/10.1080/00016489.2016.1262552>
- 11 Bang M, Choi SH, Park J, et al. Radiation dose reduction in paranasal sinus CT: with feasibility of iterative reconstruction technique. *Otolaryngol Head Neck Surg* 2016;155:982-987. <https://doi.org/10.1177/0194599816664335>
- 12 Wu AW, Ting JY, Platt MP, et al. Factors affecting time to revision sinus surgery for nasal polyps: a 25-year experience. *Laryngoscope* 2014;124:29-33. <https://doi.org/10.1002/lary.24213>
- 13 Philpott C, Hopkins C, Erskine S, et al. The burden of revision sinonasal surgery in the UK-data from the chronic rhinosinusitis epidemiology study (CRES): a cross-sectional study. *BMJ Open* 2015;5:e006680. <https://doi.org/10.1136/bmjopen-2014-006680>

- ¹⁴ Mendelsohn D, Jeremic G, Wright ED, et al. Revision rates after endoscopic sinus surgery: a recurrence analysis. *Ann Otol Rhinol Laryngol* 2011;120:162-166. <https://doi.org/10.1177/000348941112000304>
- ¹⁵ Chang CC, Tai CJ, Ng TY, et al. Can FESS combined with submucosal resection (SMR)/septoplasty reduce revision rate? *Otolaryngol Head Neck Surg* 2014;151:700-705. <https://doi.org/10.1177/0194599814543778>
- ¹⁶ Chang JE, White A, Simon RA, et al. Aspirin-exacerbated respiratory disease: burden of disease. *Allergy Asthma Proc* 2012;33:117-121. <https://doi.org/10.2500/aap.2012.33.3541>
- ¹⁷ Koskinen A, Salo R, Huhtala H, et al. Factors affecting revision rate of chronic rhinosinusitis. *Laryngoscope Investig Otolaryngol* 2016;1:96-105. <https://doi.org/10.1002/lio2.27>
- ¹⁸ Kuiper JR, Hirsch AG, Bandeen-Roche K, et al. A new approach to categorization of radiologic inflammation in chronic rhinosinusitis. *PLoS One* 2020;15:e0235432. <https://doi.org/10.1371/journal.pone.0235432>
- ¹⁹ Toppila-Salmi S, Rihkanen H, Arffman M, et al. Regional differences in endoscopic sinus surgery in Finland: a nationwide register-based study. *BMJ Open* 2018;8:e022173. <https://doi.org/10.1136/bmjopen-2018-022173>