



# Abdominal muscle flap for repair of large congenital diaphragmatic hernia: Ultrasound evidence for retained motor muscle function



Anna Hyvärinen<sup>a,b,\*</sup>, Ulla Sankilampi<sup>c</sup>, Erja Tyrväinen<sup>d</sup>, Kari Vanamo<sup>e</sup>

<sup>a</sup> Department of Pediatric Surgery, Tampere University Hospital, Tampere, Finland

<sup>b</sup> Faculty of Medicine and Life Sciences, University of Tampere, Tampere, Finland

<sup>c</sup> Department of Pediatrics, Kuopio University Hospital, Kuopio, Finland

<sup>d</sup> Department of Radiology, Kuopio University Hospital, Kuopio, Finland

<sup>e</sup> Department of Pediatric Surgery, Kuopio University Hospital, Kuopio, Finland

## ARTICLE INFO

### Keywords:

CDH  
Congenital diaphragmatic hernia  
Abdominal muscle flap  
Ventilatory movement  
Functional result  
Dynamic ultrasound

## ABSTRACT

Congenital diaphragmatic hernia (CDH) occurs in approximately one of 3500 live births. It includes a congenital defect of the diaphragm through which bowel and other abdominal organs herniate into the thoracic cavity. Pulmonary hypoplasia is an essential feature of the anomaly, with related overload of the right side of the heart. Most CDHs can be sutured directly after initial stabilization of the cardiopulmonary condition. However, in diaphragmatic agenesis or a large defect, alternative techniques like prosthetic patches or tissue flaps are needed. Here we describe three cases, where abdominal muscle flaps were used for diaphragmatic reconstruction. In one of the patient's dynamic ultrasound of the reconstructed diaphragm, functional ventilatory movements were demonstrated, suggesting improved functional results. None of the three patients developed recurrence, and the abdominal bulge on the side of the flap is slowly improving in the surviving patients.

## 1. Introduction

Congenital diaphragmatic hernia (CDH) occurs in approximately one of every 3500 live births [1]. Most CDHs are amenable to direct closure but in large defects alternative techniques are needed. Several options have been described, including open or laparoscopic mesh repair [2], the use of a prosthetic patch such as Gore-Tex or biologic scaffolds such as Surgisis [3,4] or a reverse latissimus dorsi flap [5]. Abdominal muscles have also been successfully utilized for reconstruction in large diaphragmatic hernias [6,7].

## 2. Material and methods

**Patient 1** was a male born on the 38th gestational week via an emergency c-section. He was the second child of a 32-year-old mother. CDH had been diagnosed at the second trimester ultrasound. The trisomy scan during the pregnancy had been negative. With a birth weight of 1900 g he was small for gestational age ( $-3.5$  SD, SGA) according to the contemporary Finnish birth size reference 8. The Apgar score was 1/4 at one and five minutes. The first arterial pH was 7.29 and CO<sub>2</sub> partial pressure 55.5 mmHg. The baby was intubated, given surfactant (Curosurf), transported to neonatal intensive care unit

(NICU) with Neopuff ventilation with 100% O<sub>2</sub> and connected to HFO respirator (Sensor Medix, FiO<sub>2</sub> 100%). Milrinone and dopamine were used as vasoactive medication, and a trial of inhaled nitric oxide was performed (20 ppm). Intravenous antibiotics (benzyl penicillin 100 000 IU/kg and tobramycin 4 mg/kg), and parenteral nutrition and sedation were started. Oxygen saturation was measured continuously from both pre- and postductal limbs. The patient's face was slightly dysmorphic with small cuplike ears, a small mouth with a long philtrum and thin upper lip. Bilateral cryptorchidism and micropenis were present. Palms and feet were short and broad. An echocardiogram on day 1 showed a structurally normal heart, and despite the maximal respiratory and vasoactive therapy, a highly elevated and occasionally suprasystemic pulmonary pressure and right to left shunt in the patent ductus arteriosus (PDA) was recorded. The operation was carried out at the age of 21 days when the pre- and postductal saturation gradient had disappeared. For the preoperative chest x-ray, see Fig. 1.

In the operation the skin and the underlying left abdominal muscles along with the peritoneum were opened obliquely 4–5 cm below the inferior costal margin, the cut directed from the xiphoid process towards the left iliac spine laterally. A left-sided CDH involving the left lobe of the liver, the stomach, the spleen and most of the intestines, along with the omentum that was attached to the left lung was

\* Corresponding author. Department of Paediatric Surgery, Tampere University Hospital, Teiskontie 35, 33520, Tampere, Finland.

E-mail address: [anna.hyvarinen@tuni.fi](mailto:anna.hyvarinen@tuni.fi) (A. Hyvärinen).

<https://doi.org/10.1016/j.epsc.2019.101199>

Received 20 March 2019; Accepted 24 March 2019

Available online 22 April 2019

2213-5766/ © 2019 The Authors. Published by Elsevier Inc. This is an open access article under the CC BY-NC-ND license

(<http://creativecommons.org/licenses/by-nc-nd/4.0/>).

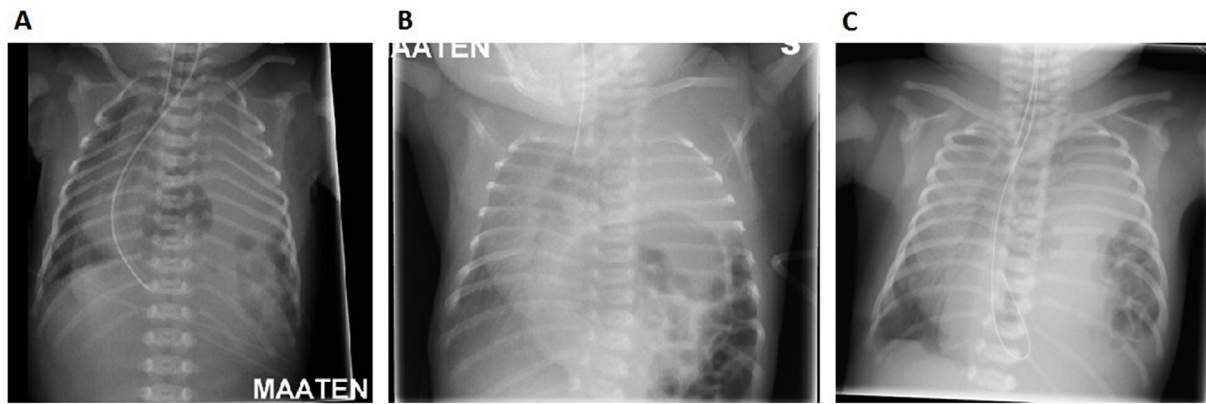


Fig. 1. Preoperative chest x-rays of patient 1. at birth day, patient 2. at six days age and patient 3. at one day's age (A, B and C, respectively).

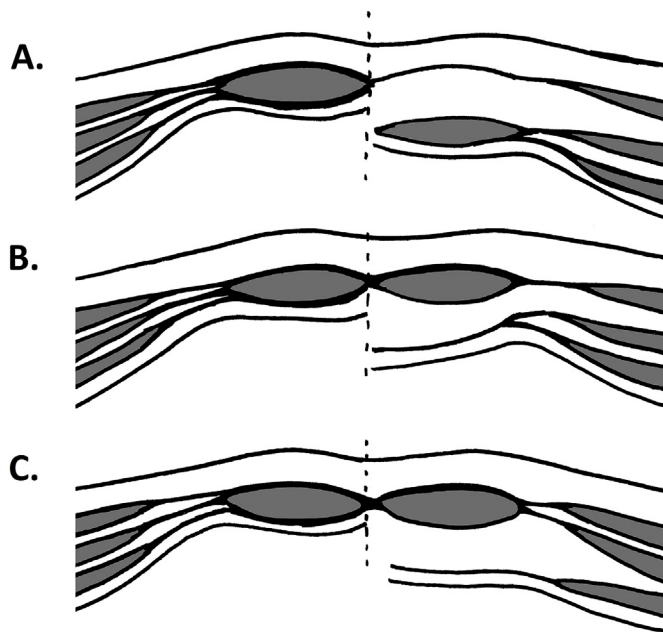


Fig. 2. Abdominal muscle flaps used for reconstruction in patient 1. (A), patient 2. (B) and patient 3. (C).

encountered. An anteromedial  $1 \times 3$  cm and a posterior 1 cm diaphragmatic rim were found, inadequate for a direct closure. A flap containing the proximal rectus abdominis muscle and transversus and obliquus internus muscles was mobilized (Fig. 2 A) and used for tension-free reconstruction of the diaphragm along with the existing diaphragmatic tissues. The remaining external oblique muscle on the left side was sutured to the intact abdominal wall on the right side of the incision, using a Surgisis prosthetic patch to avoid undue tension. The skin was mobilized and sutured in a tension-free manner.

Upon waking up from anesthesia the patient developed pneumothorax as a complication of mechanical ventilation. Two pleural drains were inserted and connected to 8 H<sub>2</sub>Ocm pleural suction. The patient recovered from the operation, but pulmonary hypertension persisted. In the chest x-rays, signs of pressure injury were detectable in both lungs. The need for oxygen remained high (FiO<sub>2</sub> 100%) and extubation turned out impossible. Finally, the patient's condition started to deteriorate with retention of CO<sub>2</sub>, and he succumbed at the age of six weeks.

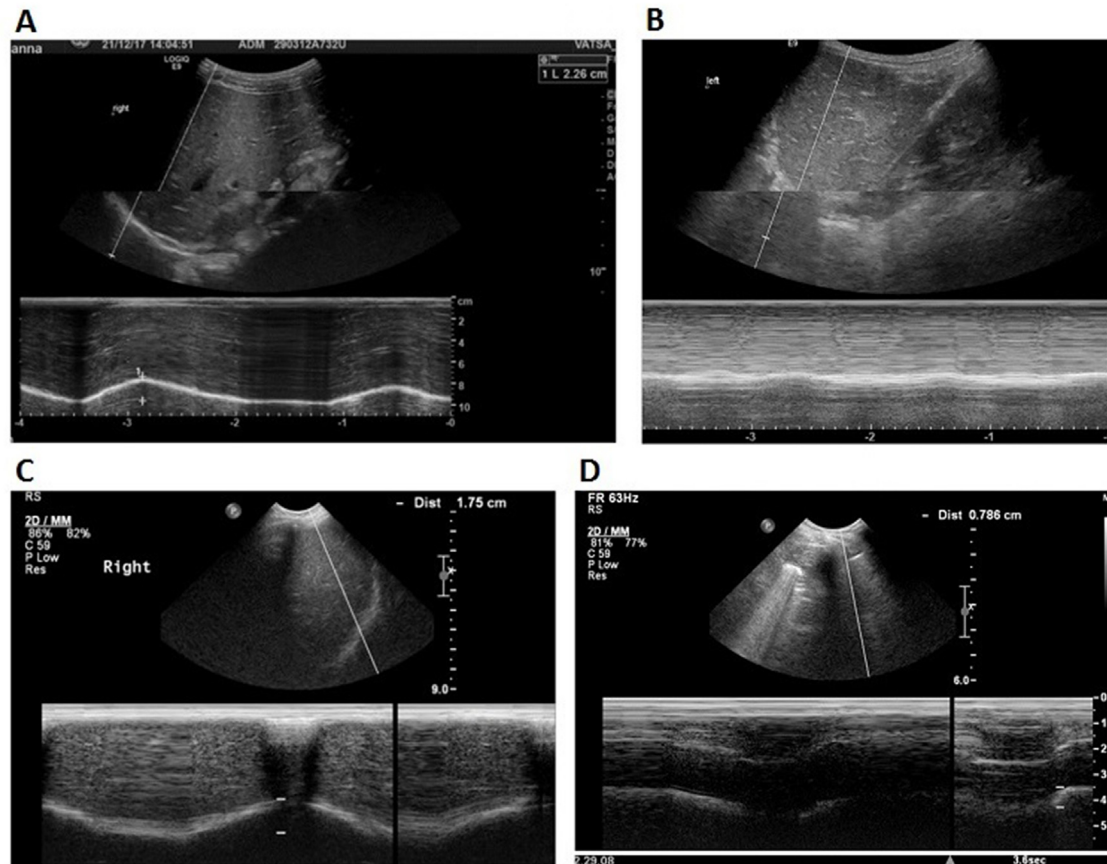
**Patient 2** was a female born at the gestational age of 35 weeks by C-section due to pre-eclampsy and increasing proteinuria of the 32-year-old primipara mother. A left sided CDH had been diagnosed at the second trimester ultrasound. The birth weight was 2285 g (1,9 SD) and

the Apgar scores were 7/8 at one and five minutes, respectively. The first arterial pH was 7,27 and CO<sub>2</sub> partial pressure 51.8 mmHg. The baby was intubated, given surfactant (Curosurf) and 100% FiO<sub>2</sub> and connected to a ventilator (Stefanie, FiO<sub>2</sub> 100%). The O<sub>2</sub> saturation was 59% and was corrected to 88% at 16 min age with initiation of the HFV. After transportation to NICU iNO, milrinone, i.v. antibiotics (benzyl penicillin 100 000 IU/kg and tobramycin 4 mg/kg) and parenteral nutrition were started. Dopamine infusion, adrenaline, pancuron and fentanyl boluses were given as needed. Cardiac echo at day 2 showed an enlarged right ventricle, a left ventricle smaller than normal and an abnormal cardiac rotation. A left-to-right flow was seen through a patent foramen ovale. A large PDA was present with right-to-left shunting. The transverse aortic arch was relatively small but estimated to be sufficient. A relative stabilization of the cardiopulmonary situation allowed the operation on the sixth day of life (Fig. 1).

In the operation, a left sided diaphragmatic hernia containing at least half of the liver, the stomach, the spleen and most of the intestine was detected. Non-rotation of the bowel was present. A small anteromedial and a 1 cm wide posterior retroperitoneal diaphragmatic rim were found. A flap involving the proximal posterior fascia of the m. rectus abdominis and transverse and obliquus internus muscles was mobilized (Fig. 2 B) and used for reconstruction of the defect along with the rudimentary diaphragmatic tissue. Closure of the abdomen was carried out with moderate tension using 4-0 PDS.

Postoperatively, intra-abdominal pressure (IAP) was closely monitored via the urinary catheter. On the seventh postoperative day the patient suddenly deteriorated. Emergency laparotomy revealed a highly congested liver. The bowel was found vital. The abdomen was left open and dressed in a preformed silo. A delayed closure of the abdominal wall was carried out on the 14th postoperative day. The patient was successfully extubated at 26 days age. The abdominal wall closure was complicated with a postoperative infection and a small abscess within the abdominal wall that was drained. Later a ventral hernia developed. At three months age the patient developed intestinal obstruction, most likely due to adhesions, that resolved with conservative treatment. At four years of age the patient had pectus excavatum with Haller index 8.5 and a left thoracolumbar scoliosis of 17° (Th10-L4). During the follow up, the scoliosis, the abnormal posture of the patient, and the ventral hernia have been gradually improving.

**Patient 3** was a male child born at the gestational age of 39 weeks with an elective C section to a 35-year-old primipara mother. The ultrasound at the second trimester had been normal. However, a CDH was detected at the gestational age of 36 weeks. Fetal MRI showed almost the entire bowel in the left thoracic cavity along with about 10% of the liver. Apgar score was 9/9 at one and five minutes, respectively. The first arterial pH was 7,06 and CO<sub>2</sub> partial pressure 101.3 mmHg. After a short initial support with 5 cmH<sub>2</sub>O PEEP with Neopuff without ventilation the baby was connected in HFO respirator (during transfer to



**Fig. 3.** Dynamic ultrasound of the respiratory movements. Normal respiratory movement (2.26 cm) of the right diaphragm (A) and no movement in the left reconstructed diaphragm (B) in the patient 2. Normal respiratory movement (1.75 cm) of the right diaphragm and synchronous respiratory movement (0.79 cm) of the left reconstructed diaphragm in the patient 3.

NICU Stephanie HFO respirator, at NICU Sensor-Medix HFO respirator) with FiO<sub>2</sub> 100% O<sub>2</sub> and iNO (13 ppi). I.v. antibiotics (bentzyl penicillin 100 000 IU/kg twice a day and tobramycin 4 mg/kg daily) and milrinone 0.75 µg/kg/min were started and dopamine, fentanyl and midazolam were given as needed. For the chest x-ray, see Fig. 1. After one-day HFO ventilator was no more needed and treatment was changed to conventional ventilator. At the age of two days the baby was doing well in conventional ventilator without iNO. At five days of age the patient was hemodynamically stable in a conventional Stephanie PTV respirator with FiO<sub>2</sub> 40%. In the operation on the fifth day of life a left-sided CDH, involving part of the liver, the spleen, stomach and almost the entire bowel was detected. Anteromedially and posteromedially, a small rudimentary diaphragmatic rim was identified, inadequate for direct closure. In the level of the diaphragm a 3 × 5 cm pulmonary sequester, with the arterial supply coming directly from the aorta, was found and excised. A flap consisting of the transversus abdominis muscle and posterior fascia of the rectus muscle was mobilized and used to reconstruct the diaphragm (Fig. 2 C). Closure of the abdominal incision turned out impossible and a preformed silo was placed to cover the intestine. At 12 days age, the abdomen was closed with a Surgisis prosthetic patch and direct closure of the skin. Extubation was possible on the 22nd postoperative day after two previous unsuccessful attempts. Skin closure was complicated by a superficial wound infection that healed with conservative treatment.

### 3. Surgical technique

The surgical technique has evolved over time. We originally made an oblique incision parallel and 4–5 cm distal to the costal margin. With this incision, however, the decision to do a muscle flap and hence the

placement of the incision must be made beforehand. If the diaphragmatic defect is amenable to suture repair, this incision is unnecessarily large. We nowadays start with an upper midline incision, through which a small to moderately large diaphragmatic defect can be relatively easily repaired. On the other hand, if the defect turns out to be a large one, the incision can be extended towards the ipsilateral anterior superior iliac spine. We then cut the muscles along the incision. To prevent a ventral hernia/bulge we nowadays use only the transverse muscle for the flap. It is usually easy to separate it from the oblique muscles and the posterior fascia of the rectus abdominis can be separated in continuity with the transverse muscle to create a U-shaped flap, the base of which is attached to the costal margin. The flap has a broad pedicle and is well vascularized and innervated by the intercostal vessels and nerves, which should be spared if seen. The size of the flap can be customized and made large enough to repair even diaphragmatic agenesis without undue tension. The flap is then turned down to meet the diaphragmatic remains and the posterior chest wall and sutured in place with nonabsorbable patch sutures. The remaining oblique muscles are then sutured to each other and the intact abdominal muscles on the contralateral side of the incision, and the skin closed in one layer. Often a prosthetic patch or even a silo is needed to accommodate the abdominal contents. Postoperatively the intra-abdominal pressure is monitored via the urinary catheter. If it exceeds 20 cm H<sub>2</sub>O, the wound is opened and a prosthetic patch or a silo is used to relieve the pressure.

### 4. Results

All patients survived the diaphragmatic operation. The first child succumbed to an intractable respiratory insufficiency at the age of six weeks, the rest have been followed regularly in the outpatient clinics,

with no evidence of recurrence or other major problems.

The main difficulty with the operation has been the small size of the abdominal cavity, necessitating the use of a prosthetic patch in all cases to close the abdominal incision. In addition, a temporary silo was necessary in two cases to reduce the intestines without undue tension. In one case, an emergency laparotomy had to be performed to relieve an abdominal compartment syndrome. These difficulties, however, are not unique to the muscle flap method, and can be encountered with any technique.

Other complications included a pneumothorax in one patient (patient 1), wound infection in two patients (patients 2 and 3) and a ventral hernia/abdominal bulging in two patients (patient 2 and 3). Patient 2 underwent also two thoracotomies and developed scoliosis and pectus excavatum, both possible complications of either thoracotomies or repair of the CDH. However, during the follow-up the scoliosis and the body contour have gradually improved.

The two long term survivors were imaged with ultrasound to study the function of the reconstructed diaphragm. Notably, the ultrasound examination demonstrated synchronous ventilatory movements of the left, reconstructed diaphragm, although the range of movement was considerably smaller compared to the right, native diaphragm of the same patient. In case 2. The range of motion was 16 mm in the right side whereas no measurable movement was detected in the left reconstructed side. In the case 3. The maximum range of motion was 17–18 mm in the right side and 7–8 mm in the left reconstructed side (Fig. 3).

## 5. Discussion

The infants born with a large CDH are a demanding patient group that needs highly skilled neonatal intensive care and a multidisciplinary team. Not all will survive and the survivors carry many sequelae including decreased respiratory function and chest wall and spinal deformities [8–10]. Both scoliosis and pectus excavatum are frequently found in patients with a history of large diaphragmatic hernia repair, independently of the method of the defect closure (abdominal muscle flap or prosthetic patch) [11,12].

In large diaphragmatic hernias prosthetic patches are favored by many pediatric surgeons for their simplicity. They can be shaped into a dome that can flatten as the child grows. In patients with ECMO, patches can be sewn into place with little disruption of the retroperitoneal space, which minimizes the risk of bleeding [13].

Several advantages may exist of using a muscle flap for primary repair of the diaphragmatic hernia instead of a prosthetic patch. Patch failure has been reported in more than half of the patients with prosthetic material [13]. Living tissue is better able to incorporate into local tissues and grow with time, which may decrease the need for re-operations. A functioning diaphragm may enhance postnatal pulmonary growth in a child who already has pulmonary hypoplasia due to CDH. The operation is not technically difficult, and no special instruments or material are needed. In a study comparing 19 muscle flaps with 32 prosthetic patches no statistically significant differences were noticed in the mortality, chest wall deformities, postoperative bowel obstruction or recurrence rates between the groups, although there were less recurrences in the group with muscle flaps [13].

The rectus abdominis, external and internal oblique and transversus abdominis muscles are innervated by the intercostal nerves 7 to 12, 5 to 12, 8 to 12 and 7 to 12, respectively [14]. Theoretically, the use of an innervated muscle flap for reconstruction of the defect in CDH could preserve motor function of the diaphragm and improve the ventilation. However, the abdominal muscles are normally relaxed when inhaling and contracting when exhaling. When used as a muscle flap for reconstruction of the defect in CDH they must work vice versa to support, rather than counteract the ventilatory movement. To our knowledge, there are no previous reports indicating coordinated ventilatory movements of a muscle flap used for reconstruction of CDH. However,

tendon transpositions have been widely utilized for improved function in hand surgery. Patients can learn to use the muscle with the transposed tendon for a new purpose.

One potential disadvantage with the muscle flap procedure is the resulting abdominal bulge at the donor site. So far, this has not been a problem and the cosmesis seems to improve with time. To lessen this donor site morbidity, we nowadays prefer to use only the transverse abdominal muscle and the posterior fascia of the rectus abdominis for the repair. Time will tell whether the remaining donor site muscles will be strong enough for normal function and cosmesis.

In large CDHs not suitable for direct suture of the defect, abdominal muscle flaps may serve as a potent alternative for prosthetic materials. A primary vascular and innervated abdominal muscle flap could reduce the risk for recurrent CDH as well as improve function, with a reconstructed diaphragm capable for functional ventilatory movements. Larger series and a longer follow-up are needed to evaluate the functional and cosmetic results of abdominal muscle flaps in these often severely ill patients.

## Patient consent

Consent to publish the case report was not obtained. This report does not contain any personal information that could lead to the identification of the patient.

## Funding

No funding or grant support.

## Authorship

All authors attest that they meet the current ICMJE criteria for Authorship.

## Declarations of interest

None.

## Conflict of interest

The authors (Dr. Anna Hyvärinen, Dr. Ulla Sankilampi, Dr. Erja Tyrväinen and Dr. Kari Vanamo) of the enclosed manuscript “Abdominal muscle flaps for repair of large congenital diaphragmatic hernias: dynamic ultrasound suggests possibility for retained motor muscle function” have no conflicts of interest.

## Appendix A. Supplementary data

Supplementary data to this article can be found online at <https://doi.org/10.1016/j.epsc.2019.101199>.

## References

- [1] Mattei P. *Surgical directives: pediatric surgery*. Philadelphia: Lippincott Williams & Wilkins; 2003.
- [2] Arca MJ, Barnhart DC, Lelli Jr. JL, et al. Early experience with minimally invasive repair of congenital diaphragmatic hernias: results and lessons learned. *JPediatrSurg* 2003;38:1563–8.
- [3] Grethel EJ, Cortes RA, Wagner AJ, et al. Prosthetic patches for congenital diaphragmatic hernia repair: Surgisis vs Gore-Tex. *JPediatrSurg* 2006;41:29–33. discussion 29–33.
- [4] Holcomb 3rd GW, Ostlie DJ, Miller KA. Laparoscopic patch repair of diaphragmatic hernias with Surgisis. *JPediatrSurg* 2005;40. E1–5.
- [5] Lee SL, Poulos ND, Greenholz SK. Staged reconstruction of large congenital diaphragmatic defects with synthetic patch followed by reverse latissimus dorsi muscle. *JPediatrSurg* 2002;37:367–70.
- [6] Barnhart DC, Jacques E, Scaife ER, et al. Split abdominal wall muscle flap repair vs patch repair of large congenital diaphragmatic hernias. *JPediatrSurg* 2012;47:81–6.
- [7] Brant-Zawadzki PB, Fenton SJ, Nichol PF, et al. The split abdominal wall muscle

- flap repair for large congenital diaphragmatic hernias on extracorporeal membrane oxygenation. *JPediatrSurg* 2007;42:1047–50. discussion 1051.
- [8] Barriere F, Michel F, Loundou AD, et al. One-year outcome for congenital diaphragmatic hernia: results from the French national register. *J Pediatr* 2018;193:2004–10.
- [9] Colvin J, Bower C, Dickinson JE, et al. Outcomes of congenital diaphragmatic hernia: a population-based study in Western Australia. *Pediatrics* 2005;116:e356–63.
- [10] Wright JC, Budd JL, Field DJ, et al. Epidemiology and outcome of congenital diaphragmatic hernia: a 9-year experience. *PaediatrPerinatEpidemiol* 2011;25:144–9.
- [11] Russell KW, Barnhart DC, Rollins MD, et al. Musculoskeletal deformities following repair of large congenital diaphragmatic hernias. *JPediatrSurg* 2014;49:886–9.
- [12] Vanamo K, Peltonen J, Rintala R, et al. Chest wall and spinal deformities in adults with congenital diaphragmatic defects. *JPediatrSurg* 1996;31:851–4.
- [13] Nasr A, Struijs MD, Ein SH, et al. Outcomes after muscle flap vs prosthetic patch repair for large congenital diaphragmatic hernias. *JPediatrSurg* 2010;45:151–4.
- [14] Feneis H, Dauber W, Meyer DB. *Pocket atlas of human anatomy: based on the international nomenclature*. Stuttgart: Georg Thieme Verlag; 1994.